

Cover Page



Universiteit Leiden

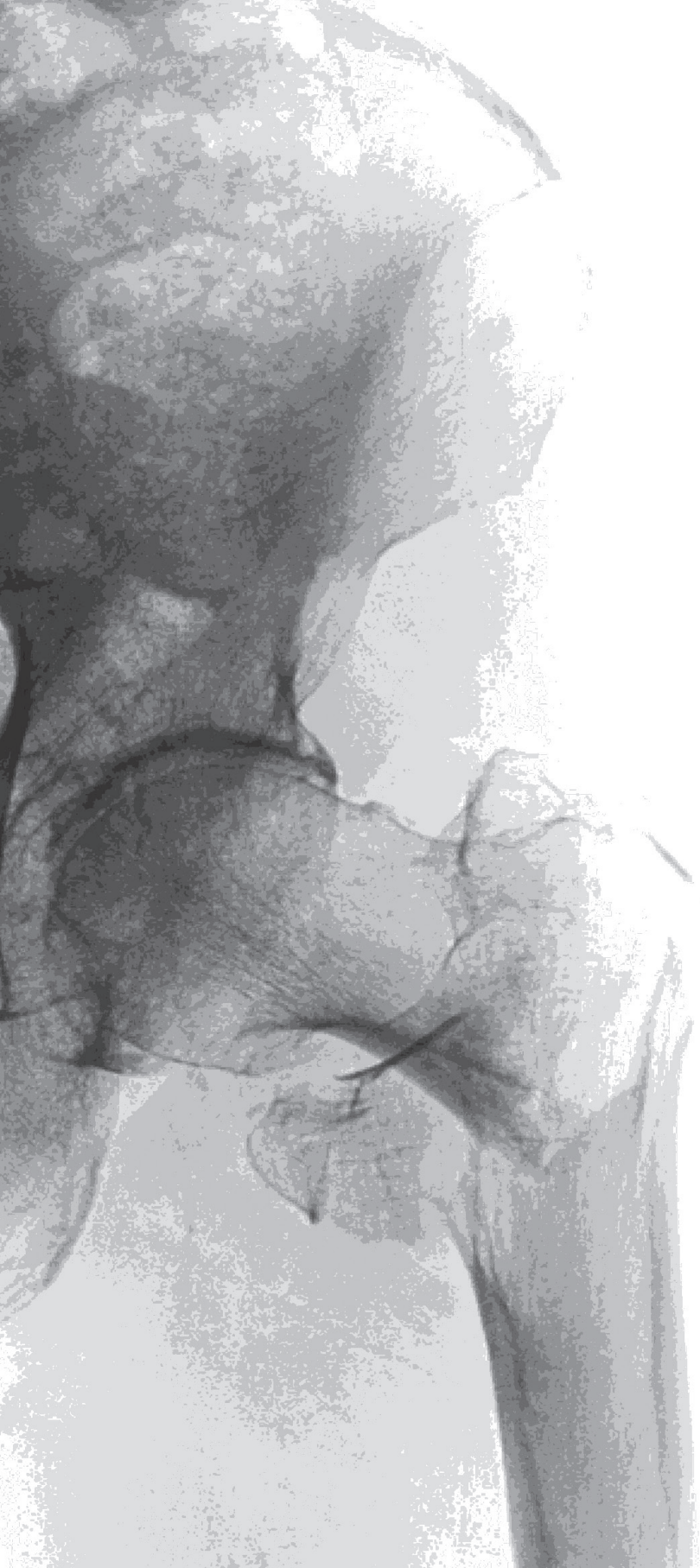

The handle <http://hdl.handle.net/1887/38039> holds various files of this Leiden University dissertation.

**Author:** Embden, Daphne van

**Title:** Facts and fiction in hip fracture treatment

**Issue Date:** 2016-02-17



# Chapter 9

## **The surgeon's eye: a prospective analysis of the anteversion in the placement of hemiarthroplasties after a femoral neck fracture.**

Daphne van Embden

Willem van Gijn

Timothy J. van der Steenhoven

Steven J. Rhemrev

## ABSTRACT

### Aim

Hip dislocation after hemiarthroplasty performed in elderly patients with a femoral neck fracture is associated with severe morbidity and costs. Optimal anteversion during the placement of the hemiarthroplasty might reduce the dislocation rate. We assessed the surgeons' intraoperative visual estimations of the femoral anteversion.

### Methods

The postoperative femoral anteversion of 20 consecutively performed hemiarthroplasties was measured on computer tomography and compared to the intraoperative visual estimations of the surgeon. Furthermore, the femoral anteversion of the contralateral non-fractured hip, which was considered the 'ideal' anatomical reference, was recorded.

### Results

The mean postoperative anteversion of the hemiarthroplasty was 20° (range 29°, S.D. 8.7). The mean femoral anteversion of the contralateral non operated femur was 14° (range 44°, S.D. 9.5).

The average difference between the anteversion angle estimated by the surgeon and the CT-measured is 9° (1° to 18°). In 14 (70%) cases the measured angle was greater than desired.

### Conclusion

The current operation technique in which the anteversion angle is estimated by the surgeon's eye shows relatively good intraoperative precision.

## INTRODUCTION

Hip dislocations occur in 2 to 6 percent of the patients with a femoral neck fracture treated by hemiarthroplasty.<sup>1,2</sup> Dislocation of a hemiarthroplasty is rare but associated with mortality rates after 6 months up to 65% and significant costs.<sup>2,3</sup> A small number of studies have been performed regarding hip dislocation after hemiarthroplasty and some factors are known to be predisposing for dislocation: type of approach, as the anterolateral approach is known to result in fewer dislocations<sup>3</sup> than a posterior approach and surgical technique.<sup>1,4,5</sup> Finally, femoral anteversion angle of the implant is believed to be of influence in the occurrence of dislocation of an implant and it is generally advised to place a prosthesis with an angle within the range of 10-20°. However, it is unclear whether the visual estimation by a surgeon regarding the femoral anteversion during the placement of a hemiprosthesis is reliable and within the intended 10-20°. In the study by Dorr et al.<sup>6</sup> a poor performance was seen of the operating surgeon, when performing *total* hip arthroplasty not hemiarthroplasty. Therefore, we assessed the quality of the surgeons' visual estimations of the femoral anteversion during the placement of a hemiarthroplasty after a femoral neck fracture.

## METHODS

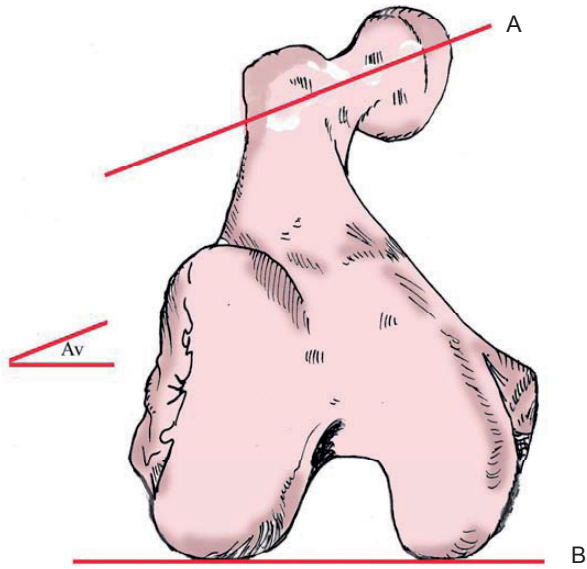
Twenty patients with a femoral neck fracture treated by hemiarthroplasty were prospective and consecutively included in a large teaching hospital in The Hague, The Netherlands in a period of one year. Informed consent was obtained.

The operation was performed according the same surgical protocol, all surgeons used an anterolateral approach and a cemented unipolar type of implant was placed.

We compared the visual estimations of the surgeon to the postoperatively measured femoral anteversion of the performed hemiarthroplasty measured by Computed Tomography (CT). Further, we measured the femoral anteversion of the contralateral non-fractured hip, which is considered the 'ideal' anatomical reference. Intraoperative, the visual estimation of the femoral anteversion by the surgeon was recorded.

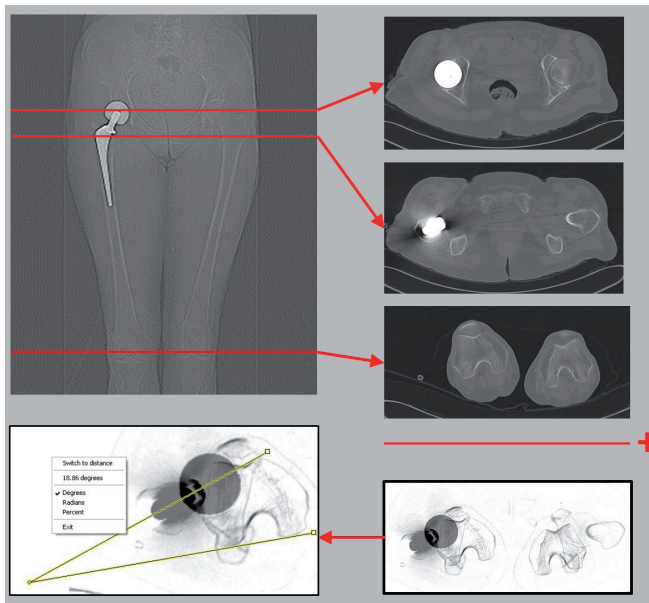
Postoperatively the femoral anteversion of the pairs was measured accordingly Figure 1 and Figure 2. The area from above both hips to under the knees was scanned in one session while the patient's legs were fixated. Three CT-slices were selected: through the femoral head, through the femoral neck and through the posterior femoral condyles and these sliced were merged to one picture. The anteversion angle could then be measured between the line alongside the femoral condyles and the line through the centres of the femoral head and neck.

Data was recorded and analysed using SPSS 17.0.



**Figure 1**

Femoral anteversion (Av): Angle between femoral neck axis (A) and condylar axis (B).



**Figure 2**

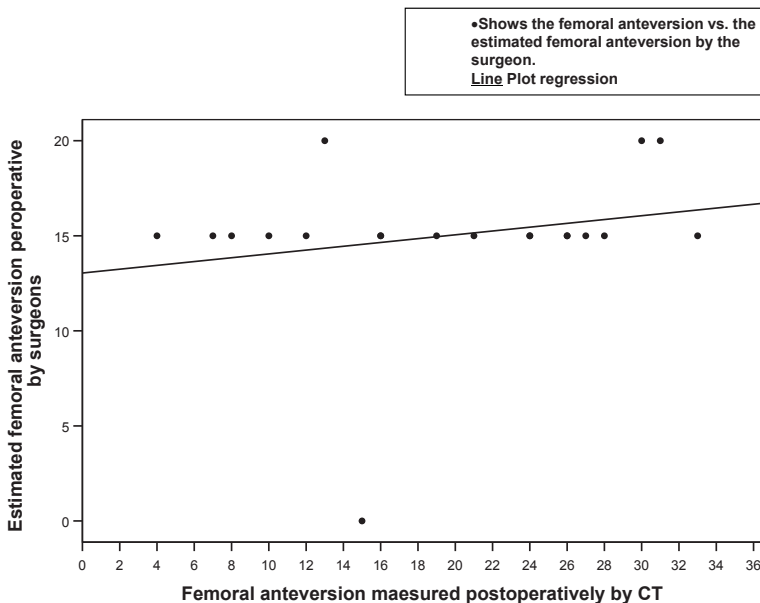
CT images were used to measure the femoral anteversion

An unpaired T-test was performed to test for significance of the differences between the estimated femoral anteversion, the CT-measured femoral anteversion of the hemiarthroplasty and the femoral anteversion of the contralateral hip.

## RESULTS

We included 16 female and 3 male patients, with 20 displaced femoral neck fractures. The mean age was 80.1 (SD 7.1) with a range of 61 to 94 years. The twenty hemiprosthesis were placed by ten experienced surgeons. No cluster-effect was seen after performing a scatter plot as some surgeons performed more than one operation.

No significant differences were seen between the groups (One-way ANOVA). The mean difference between the anteversion angle estimated by the surgeon and the CT-measured anteversion was  $9^\circ$  ( $-11^\circ$  to  $+18^\circ$ ). In 14 cases the measured angle was greater than the desired. Results of the estimated and measured femoral anteversion are shown in Table I and Figure 3. Noticeable, in one patient both hips were fractured so the



**Figure 3**

Scattergram of the surgeon's estimation and the postoperative femoral anteversion of the hemiarthroplasty.

Seventeen dots are shown in this graphs because three patients had identical estimations combined with equal postoperative femoral anteversion.

**Table 1**

Femoral anteversion of the anatomical reference (the femoral anteversion of the non-fractured femur), the estimated femoral anteversion by the surgeon and the postoperative measured femoral anteversion of the hemiarthroplasty.

Patient ID	Femoral anteversion of the non-fractured femur: anatomical reference (Degrees)	Estimated intraoperative femoral anteversion (Degrees)	Postoperatively measured femoral anteversion (Degrees)	(Absolute) difference between the estimated and postoperative femoral anteversion of the hemiarthroplasty (Degrees)
1	11	15	19	4
2	21	20	31	11
3	.	15	26	11
4	10	20	30	10
5	12	15	16	1
6	20	15	4	11
7	24	15	26	11
8	8	20	13	7
9	9	0	15	15
10	25	15	33	18
11	-6	15	24	9
12	20	15	24	9
13	38	15	12	3
14	11	15	21	6
15	10	15	8	7
16	3	15	7	8
17	11	15	28	13
18	11	15	10	5
19	16	15	27	12
20	6	15	16	1
Mean	13,68	15,00	19,50	8,60 (P <0,05; CI 6,51 – 10,69)
Median	11,00	15,00	20,00	9,00
St. Deviation	9,54	3,97	8,72	4,47
Range	44	20	29	17
Minimum	-6	0	4	1
Maximum	38	20	33	18



femoral anteversion of the contralateral hip after the second hemiarthroplasty could not be calculated. The femoral anteversion of the remaining 19 non-fractured contralateral femurs showed a mean of 14° (S.D. 9.5), with a range of 44° (-6° to +38°).

## DISCUSSION

This study assessed the performance of surgeons regarding the femoral anteversion for hemiarthroplasty after a femoral neck fracture for the first time.

Intraoperative assessment of the femoral anteversion is challenging, especially in femoral neck fractures, as the anatomical references are limited to the (fractured) femoral neck and palpation of the epicondyles. The results of this study show that most surgeons desired anteversion of 15° and 70% of the postoperative angles were greater than desired. The absolute difference between the desired and measured anteversion was at most 18° and a mean difference was seen between the estimated and postoperative anteversion of 9°, which is quite precise. A similar study assessed the femoral anteversion of a cementless total hip arthroplasty and showed that in most cases this was not within the intended 10-20°. <sup>6</sup> In our study all implants were cemented and due to the cement, the stem is not restrained to anatomical osseous boundaries and less variation of the femoral anteversion is expected. Another difference between hemi-, and total hip arthroplasty, is that in hemiarthroplasty femoral anteversion is primarily achieved by positioning of the stem, whilst in total arthroplasty it can be adjusted by the anteversion of the cup.

Only Pajarenet al<sup>5</sup>. assessed the factors related to dislocation of a hemiarthroplasty after a femoral neck fracture and concluded that besides the surgical approach, technical factors such as the length of the residual femoral neck and the change in the offset of the hip predisposes dislocation. Femoral anteversion was suggested but not assessed in this study.

In the present study the mean femoral anteversion of the contralateral hip was 14°. Anatomical studies showed a variance of femoral anteversion between 10° tot 40°. The in general advised anteversion of 15° seems to be a good resemblance of the 'ideal' femoral anteversion and should be desired during the placement of a hemiarthroplasty for femoral neck fractures. On the other hand, the surgeons in our study have underestimated the intraoperative femoral anteversion, especially compared to the femoral anteversion of the contralateral femur, which increases the chance of dislocation. Hip dislocation occurs less often after an anterolateral approach, and if dislocation of the implant occurs it is most likely anterior dislocation. <sup>7</sup> Although, never investigated, one could suggest that an intraoperative anteversion angle of less than 15° could be advis-

able. A limitation of this study is that our results might be influenced by the small group of patients and the relatively large group of surgeons.

To conclude, the current operation technique in which the anteversion angle is estimated by the surgeon's eye shows relatively good intraoperative precision. Our results show a mean anteversion angle of 20° which is in the advised range of 10-20°.

## REFERENCES

1. Enocson A, Tidermark J, Törnkvist H, et al. Dislocation of hemiarthroplasty after femoral neck fracture: better outcome after the anterolateral approach in a prospective cohort study on 739 consecutive hips. *Acta Orthop*. 2008 Apr;79(2):211-7.
2. Blewitt N, Mortimore S. Outcome of dislocation after hemiarthroplasty for fractured neck of the femur. *Injury* 1992; 23 (5): 320-2.
3. Sanchez-Sotelo J, Haidukewych GJ, Boberg CJ (2006) Hospitalcost of dislocation after primary total hip arthroplasty. *J Bone Jt Surg Am* 88:290–294.
4. Varley J, Parker MJ. Stability of hip hemiarthroplasties. *Int Orthop*. 2004 Oct;28(5):274-7. Epub 2004 Aug 17.
5. Pajarinen J, Savolainen V, Tulikoura I, et al. Factors predisposing to dislocation of the Thompson hemiarthroplasty: 22 dislocations in 338 patients. *Acta Orthop Scand*. 2003 Feb;74(1):45-8.
6. Dorr LD, Wan Z, Malik A, et al. A comparison of surgeon estimation and computed tomographic measurement of femoral component anteversion in cementless total hip arthroplasty. *J Bone Joint Surg Am*. 2009 Nov;91(11):2598-604.
7. Enocson A, Lapidus G, Törnkvist H, Tidermark J, Lapidus LJ. Direction of hip arthroplasty dislocation in patients with femoral neck fractures. *Int Orthop*. 2010 Jun; 34(5): 641-7.