



Universiteit  
Leiden

The Netherlands

## **Oesophagostomum bifurcum infection in man. A study on the taxonomy, diagnosis, epidemiology**

Krepel, H.P.

### **Citation**

Krepel, H. P. (1994, June 28). *Oesophagostomum bifurcum infection in man. A study on the taxonomy, diagnosis, epidemiology*. Retrieved from <https://hdl.handle.net/1887/13885>

Version: Corrected Publisher's Version

License: [Licence agreement concerning inclusion of doctoral thesis in the Institutional Repository of the University of Leiden](#)

Downloaded from: <https://hdl.handle.net/1887/13885>

**Note:** To cite this publication please use the final published version (if applicable).

## **Chapter 2**

### **OESOPHAGOSTOMIASIS, A COMMON INFECTION OF MAN IN NORTHERN TOGO AND GHANA**

**A.M. Polderman, H.P. Krepel, S. Baeta,  
J. Blotkamp, and P. Gigase**

### Abstract

Infection with *Oesophagostomum sp.* is normally considered a rare zoonosis and up to this time its diagnosis has been based on the demonstration of larvae and young adults in the typical nodules formed in the intestinal wall. Only in Dapaong, in North Togo, and Bawku, North Ghana, have larger series of clinical cases been described. In the rural areas around these towns, a survey was made in which stool samples were collected and cultured. Third-stage larvae of *Oesophagostomum sp.* could be found after 5-7 days of incubation at room temperature, and the prevalence of infection with this parasite was often high but varied from one village to another. It was over 30% in seven villages out of the 15 villages surveyed. Anthelmintic treatment resulted in the evacuation of adult males and females of *O. bifurcum*. It is concluded that *O. bifurcum* is a locally common parasite of humans, not requiring an animal reservoir for completion of its lifecycle.

### Introduction and history

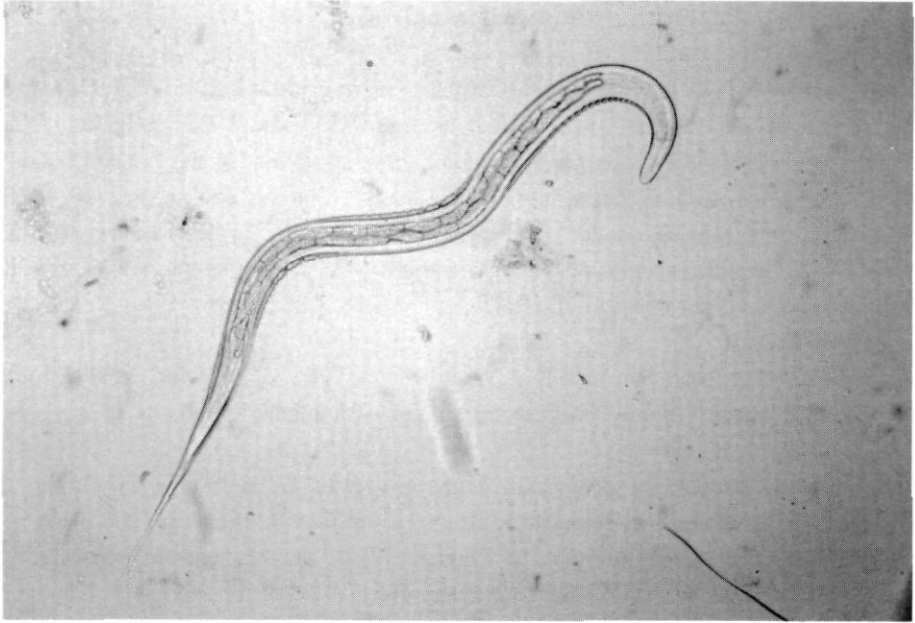In 1911, four years before his famous articles on schistosomiasis in Egypt appeared, Leiper wrote a short article which started as follows "Andrew Foy, of West African medical staff, was good enough whilst on home leave to present to the London School of Tropical Medicine a tube containing a considerable number of species of *Necator americanus*, passed by a patient at Ibi, Northern Nigeria. In the course of routine examination of individual specimens, I have been able to single out six examples of *Oesophagostomum apioistomum*....." [1].

And further: "The specimens resemble *N. americanus* very closely and would probably have been overlooked had they not been scrutinized with a hand lense".

The first report on oesophagostomiasis in humans dates from 1905 when Railliet and Henry described the parasites obtained by Brumpt from tumors of caecum and colon of "a native on the river Omo" in Southern Ethiopia [2] A very careful description of the macroscopical and microscopical pathology was given in 1910 by Wolferstan Thomas on material from a similar case observed during the Amazon expedition of 1905-1909 [3].

The adult worms described by Leiper were not only the first adult oesophagostomes described in humans, they were almost the last ones as well. On 3 April 1913 Dr. W.B. Johnson, Medical Officer in Zunguru, Nigeria, and a colleague of Dr. Foy, sent a report to London on the "Entozoal Infection Amongst Prisoners" : upon stool examination of 200 prisoners eight appeared to be infected with oesophagostomes [4]. Johnson administered thymol and eucalyptus to his patients to remove hookworms; apparently, he found oesophagostomes as well. Thereafter, in 1920, Henry and Joyeux briefly mention that in 1910 or 1911 they once found adult specimens of *Oesophagostomum brumpti* in a stool specimen obtained after anthelmintic treatment for hookworm infection in French Guinea [5]. No other reports of adult worms in man could be found.

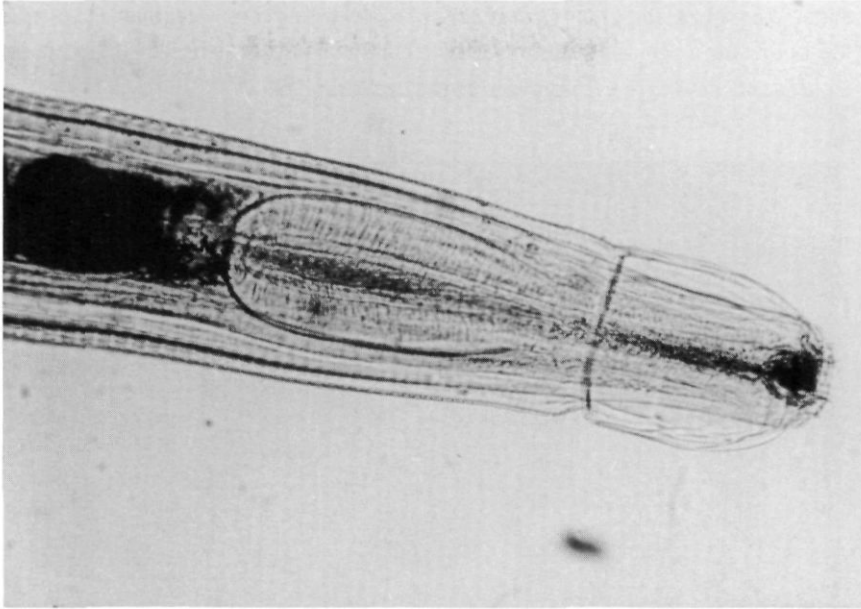
Immature worms, on the other hand, have been found in humans from time to time and have been attributed to a variety of species (*O. brumpti*, *O. stephanostomum* var *thomasi*, *O. apioistomum*, *O. aculeatum* and *O. bifurcum*). The immature worms are found in nodules and tumours in surgical material from clinical cases. In total some 15 original and reliable publications on human infections are known to us. Clearly, these cases are also fairly rare and by most authors humans are believed to be an abnormal host. Elmes and McAdam, for instance, in 1954 and Chabaud and Larivière in 1958 stress the point: young adult worms which should have entered the intestinal lumen were still found in the



**Figure 1.** Figure showing the morphological features of an L-3 larva of *Oesophagostomum bifurcum*. Magnification: 190 X.

nodules and were believed not to reach the egg-producing stage [6,7]. Haaf and van Soest, in 1964, described nine cases at Bawku hospital in northern Ghana and concluded that the species they found which was supposed to be *Oesophagostomum bifurcum*, was considered unlikely to have an animal reservoir: human contact with the most obvious reservoir, monkeys, in the area "does not seem sufficient to maintain the infection in man", whereas ruminants are common hosts for other oesophagostomes but not for *O. bifurcum*. [8]. They concluded that "the possibility that man himself may act as a source of infection, cannot yet be discarded". However, repeated attempts to culture larvae from stool specimens from patients in whom worms were found failed.

In 1987, Gigase and others reported on a large number of clinical cases of oesophagostomiasis originating from nearby Dapaong in northern Togo: "Between 1980 and 1984, 51 patients with unusual large and/or painful abdominal tumours, signs of intestinal obstruction or abscesses of the bowel were operated upon at the regional hospital in Dapaong, North West Togo" [9]. Some of the nodules were empty, suggesting that the developing larvae or young adults might have entered the intestinal lumen. If so, adult worms could be present in the bowel and eggs would be excreted with the human feces.



**Figure 2.** The anterior end of an adult *O. bifurcum* recovered from human feces. Note the cephalic groove, characteristic of the genus. Magnification: 140 X.

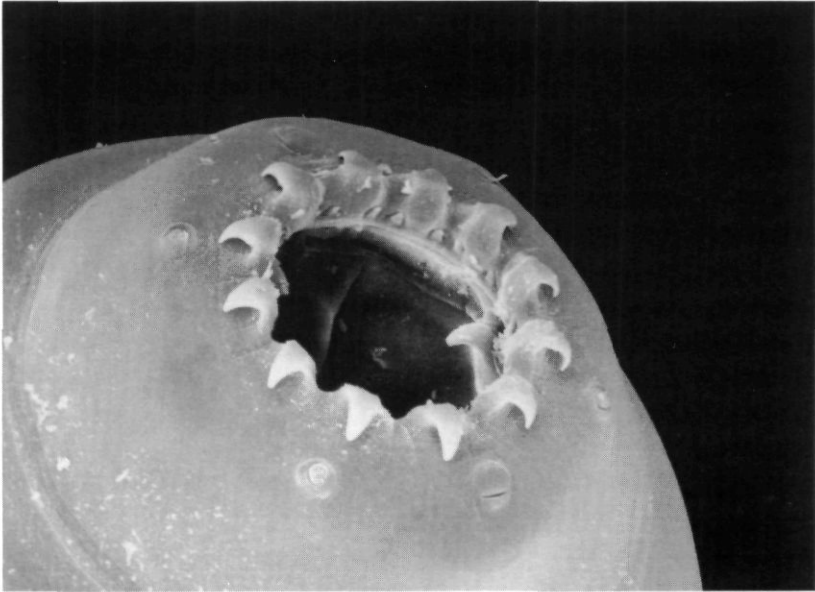
The eggs of oesophagostomes of monkeys are very similar to hookworm eggs excreted by humans: those of *O. bifurcum* are reported to be 51-72  $\mu\text{m}$  long and 29-40  $\mu\text{m}$  wide; those of *O. aculeatum* are said to be 64-80  $\mu\text{m}$  long and 32-42  $\mu\text{m}$  wide [10]. They probably cannot be differentiated morphologically from those of hookworms, and culture methods have to be used to demonstrate the development of characteristic larvae. Until now, only Haaf en van Soest and Leoutsakos and others made mention of the use of culture methods, but both failed to find *Oesophagostomum* larvae [8,11].

The principal objectives of the present study were, therefore, to establish whether adult egg-laying oesophagostomes can be found in the intestinal lumen of humans and if so, of what species. Can the infection be diagnosed by fecal culture? How common is the infection and what is the route of transmission?

### Materials and methods

The study area is typical of the Guinea Savanne; there is one long rainy season from June to September and it is hot and dry thereafter. Houses are scattered over the farm lands and the "villages" examined are in fact ill-defined agricultural areas with a rather dense

population. The most important tribes are the Moba and the Gourma; Peul tribesmen from the north are a minority. Hookworms are common (prevalence >50%) but *Ascaris lumbricoides* and *Trichuris trichiura* are rare parasites.

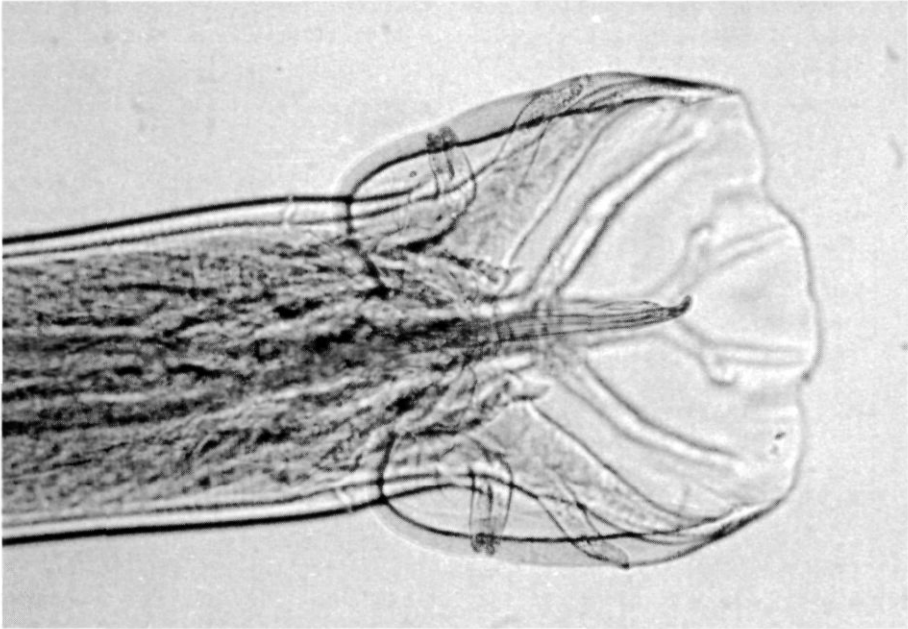


**Figure 3.** Scanning electron micrograph of the cephalic end of a female *O. bifurcum* recovered from human feces. Note the inner and outer with 12 and 24 (sometimes 10 and 20) lips respectively, and the papillae. The photo was made by the Department of Electron Microscopy, Medical Faculty, Leiden University. Magnification: 1 000 X.

Stool cultures were performed using a modification of the classical charcoal culture procedure [12]. A quantity of 1-3 grams of feces, mixed with an equal quantity of coarsely ground charcoal is placed on moist filterpaper in a petri dish and incubated for seven days at room temperature (25-35 °C). The water is poured off and centrifuged; the sediment is examined at low power (4x10) for the presence of larvae.

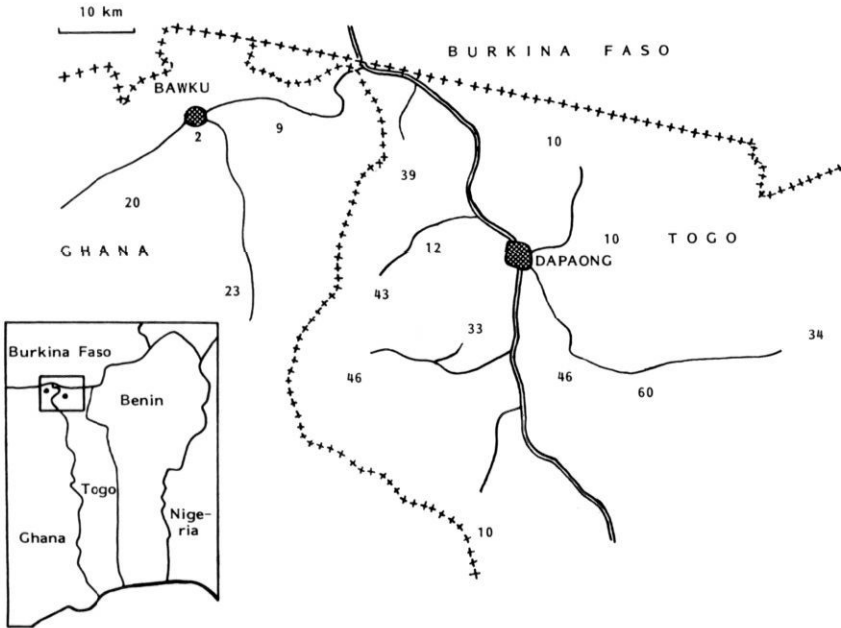
The definitive diagnosis of human infection with oesophagostomes and the determination of the species involved, could only be made reliably after recovery of the adults themselves from the intestinal lumen. To this end, patients in whose stool cultures characteristic larvae were found, were treated with pyrantel pamoate (10 mg/kg) or albendazole (one single dose of 400 mg). All feces were collected during 48 hours after treatment and

sieved over a number of wire mesh sieves with pore sizes from 1000-100  $\mu\text{m}$ . The worms obtained were examined both by light and scanning electron microscopy.



**Figure 4.** The bursa of a male. The shape and orientation of the rays is characteristic for the genus. Magnification: 190 X.

To determine the prevalence and distribution of infection with *O. bifurcum*, surveys were performed in which stool specimens were cultured from inhabitants from a number of communities in northern Togo and Ghana. No attempts have been made, as yet, to examine truly random samples of the local populations. Instead, the surveys were limited to examination of visitors to mother and child clinics, to the outpatients of the dispensaries and to those who presented voluntarily when the field surveys were carried out. We attempted to examine equal numbers of males and females of different ages. No less than 50 persons were examined in each village.



**Figure 5.** Sketch map of the northern parts of Ghana and Togo. The figure show the prevalence of the infection with *Oesophagostomum* in those localities where more than 50 persons (age 5 years and over) have been examined.

## Results

*Oesophagostomum*-like larvae were cultured from stool samples with "hookworm eggs", even though the samples were obtained from patients without apparent symptoms. The morphologic characteristics of the larvae involved are shown in Figure 1. They are 828  $\mu\text{m}$  long (748-950) and 29  $\mu\text{m}$  wide (26-42). The sheath shows a prominent transverse striation and the posterior end is tapering to a long and threadlike tip. In larvae freshly collected from fecal cultures, 16-30 triangular intestinal cells are often clearly visible. Using Little's key, the larvae will be recognized as larvae of *Oesophagostomum* sp. [13].

Treatment of patients excreting "hookworm eggs" and examination of the stools the days after treatment yielded adult specimens of both *Oesophagostomum* sp. and *Necator americanus*. Third-stage larvae obtained from eggs that were removed from the uterus of these adult oesophagostomes were morphologically identical to those obtained from the stool cultures. Details of the adult oesophagostomes recovered are given in the Figures 2-4. The mean length of the females (n=30) was 13.0 mm (11.0-16.8mm); the males

(n=20) were smaller: 10.4 mm (8.2-13.1). The cephalic groove (Fig. 2) and the shape and orientation of the rays of the male's bursa (Fig. 4) are characteristic of the genus. The dimensions along with the shape of the buccal cavity, and the details of the external and internal leafcrowns with 10-12 and 20-24 leaves respectively, are compatible with the species *O. bifurcum* [10]. The length of the spicules (842-1113  $\mu\text{m}$ ; n=20) is considered to be characteristic of the species [7,14].

The age- and sex-specific prevalence of infection is given in Table 1. The location of the villages involved and the prevalences of infection in subjects older than five years of age, are given in Figure 5. In each of the villages more than 50 persons were examined.

**Table 1.** Age- and sex-specific prevalences of infection with *O. bifurcum* in Northern Togo and Ghana (total of all villages examined)

Age(yrs)	Males			Females		
	n	+ve	%	n	+ve	%
0 - 4	426	21	(4.9%)	416	20	(4.8%)
5 - 9	358	70	(19.6%)	305	41	(13.4%)
10 - 19	332	71	(21.4%)	308	83	(26.9%)
20 - 29	169	20	(11.8%)	351	97	(27.6%)
30 - 39	125	14	(11.2%)	230	78	(33.9%)
≥ 40	115	21	(18.3%)	107	26	(24.3%)
Total	1 525	217	(14.2%)	1 717	345	(20,1%)

Discussions with older health workers in Dapaong made clear that the disease that may be caused by the infection was well known to the local people. It is known that the "Tumeur de Dapaong" (Figure 6) may burst open either to the intestinal lumen or the abdominal wall. In one of the local languages (Moba), such a mass was referred to as "Koulkoul", which means "having a turtle in your belly", and in another (Gourma) as "Tougnale", which stands for "abcess in the abdomen". Traditionally, the patients were treated by the application of heat until the abcess burst.

## Discussion

It is quite remarkable that human infections with *Oesophagostomum sp.*, up to this time believed to be rare zoonotic accidents, could not only be proven to occur, with the use of classical, almost antique methods, but also that they appeared to be very common indeed in the study area of North Togo and Ghana. Previously, the eggs found in human feces

were indiscriminately, and erroneously, referred to as hookworm eggs, whereas in this study area they appear to be a mixture of hookworm and *Oesophagostomum* eggs. To the local population, in contrast, the clinical expression of the disease is not new, but their acquaintance with this disease faded away with the introduction of modern western health care facilities, some 40 years ago.



**Figure 6.** Photo of an abscess caused by *Oesophagostomum*, fistulating through the abdominal wall.

Both male and female adult worms were recovered in subjects in whose stool specimens third-stage larvae resembling those of *Oesophagostomum*, had been found. The presence of adult worms in the intestinal lumen, in combination with the finding of eggs which could be cultured into characteristic third-stage larvae of *Oesophagostomum spec.*, confirms that the life cycle is completed in humans. Monkeys, previously believed to be the reservoir of the infection, are rare on the Togolese side of the border. They are not an essential link for transmission.

The taxonomic status of oesophagostomes has given rise to much confusion. Chabaud and Larivière's overview of the synonyms illustrates the point [7]. Specimens once described as *O. apiostomum* are now classified as either *O. bifurcum* or *O. aculeatum*. Moreover, the descriptions of several species are sometimes incomplete or based on very few specimens. *O. bifurcum* and *O. brumpti* are considered synonyms by Chabaud and Larivière, but they are split by the more recent study of Glen and Brooks, even though

only two specimens of the latter species have been properly described [7,14]. The body length of the females (11.0-16.8 mm) found in our study is too long for *O. bifurcum* according to Glen and Brooks, and would instead be within the limits of *O. aculeatum*. The latter species, however, is thought to be confined to Asia. Moreover, the dimensions of the worms may well be host-dependent, as pointed out by Chabaud and Larivière. In conclusion, the worms recovered in the present study are provisionally classified as *O. bifurcum*. A full description of a large number of the adult worms and the larval stages is in progress.

The method of culturing stools results in the frequent detection of infection with *Oesophagostomum* in this area. In most cases small numbers of *Oesophagostomum* larvae were found, although sometimes several hundreds could be counted in a culture. It is probable that many light infections have escaped diagnosis and thus the true prevalence is considerably higher than reported. A detailed analysis of the sensitivity and reproducibility of the diagnostic method is in progress.

The figures showing geographical distribution and the age- and sex-specific distribution demonstrate that the prevalence varies from 0% to over 50%. The highest prevalences are found in the rural villages, most distant from the main roads. Lower prevalences are seen in the regional centres of Bawku and Dapaong, and in the nearby communities along the principal roads. The prevalence is higher in females than in males and comparatively low in children under the age of five. Even though very young children are less infected, it is remarkable that at the age of about 10 a high prevalence may already be seen. Apparently transmission can be quite intense. The route of infection, however, remains obscure. Animal oesophagostomes, like *O. colombianum* in sheep, are mostly contracted orally, while grazing [15]. In parallel, it might be assumed that for humans too, oral infection is the most likely route of transmission.

Understanding the epidemiology of oesophagostome infections in the area is not only fascinating but relevant for the local population and its health care. The frequency of cases operated upon, as described by Gigase and others and the existence of local names to describe the clinical disease, reflect the importance of the infection [9]. The clinical manifestations were often quite impressive in Gigase's series: in 16 patients of this series, the masses were described as "enormous" or "very big". In nine cases the patients presented because of "disfiguring dimensions" of the masses or for "esthetic reasons". While the prevalence of infection was shown to be comparatively low in children under five, 22% of the surgical cases of Gigase and others were young children (Table 2). Painless abdominal masses will show more readily in young children but also the most serious complication, intestinal obstruction due to extensive adhesions around the

intestinal nodules, is rather frequent in the youngest age group. The discrepancy between surgical and epidemiological observations can only be speculated upon.

**Table 2.** *Frequency of symptoms per age group as seen in the series of surgical cases described by Gigase and others, 1987 [9].*

	Age			Total
	< 5	5-19	≥ 20	
Symptoms				
Intestinal obstruction	3	6	4	13
Painful abdominal mass	2	10	5	17
Painless abdominal mass	4	11	4	19
Others	2	0	0	2

One of the most fascinating questions is why this infection is so common in the study area while it is not recognized elsewhere. Is it due to a gross underreporting of clinical cases and inadequate diagnostic routines in other parts of Togo and neighbouring countries, or is the distribution of the infection limited to this area? The first explanation undoubtedly plays a role, but there are reasons to believe that the second one, too, is true to some extent. It is the clinical experience of one of us (S.B.) that patients with a "tumeur de Dapaong" are never seen in the south of Togo. Moreover, it is remarkable that the two foci from which series of clinical cases have been described independently, Bawku and Dapaong, are situated in different countries, but at a very close distance of some 50 kilometers. From no other country have more than a few isolated cases ever been described. Clearly, more extensive surveillance will be necessary to determine the geographic distribution of this parasitic infection in humans.

Finally, both pyrantel pamoate and albendazole have been shown to be capable of removing adult oesophagostomes from the intestinal lumen. The efficacy of these drugs, as well as the need to use them, has to be further analyzed before a policy on treatment of infected persons can be formulated.

It can be concluded that the results presented in this paper provoke a number of questions on the taxonomy, the sensitivity and reproducibility of diagnosis, transmission, natural course of infection, efficacy of treatment and ways to deal with this previously unrecognized parasitic infection of humans. Studies on these aspects are ongoing.

### **Acknowledgements**

The research in Togo was supported and assisted by the Minister of Health, Dr. A. Agbeta and the Minister of Education, Dr. T.K. Tchalim. The continuous support of Mr Amouzou, administrative director of Dapaong Hospital was of great value. In Ghana work could be carried out thanks to the cooperation of the Regional Medical Officer, Dr. A. Ganda, and the assistance of Dr. R. Steenstra and Dr. C.O. Akuamo. Valuable assistance is acknowledged of Mss A.N. Hiemstra, A. Rietveld, F. Stelma and other students in the fieldwork, and of Prof. J. Brand and Dr. V. Kumar of the Institute of Tropical Medicine in Antwerp.

This study was funded by the Netherlands Foundation for the Advancement of Tropical Research (WOTRO).

### References

1. Leiper RT, 1911. The occurrence of *Oesophagostomum apiostomum* as an intestinal parasite of man in Nigeria. *Journal of Tropical Medicine and Hygiene* 14: 116-118.
2. Railliet A, Henry A, 1905. Encore un nouveau sclérostomien (*Oesophagostomum brumpti* nov. sp.) parasite de l'homme. *Comptes Rendues de Séances de la Société de Biologie* 58: 643-645.
3. Wolferstan TH, 1910. The pathological report of a case of *Oesophagostomum brumpti* in man. *Annals of Tropical Medicine and Parasitology* 4: 57-88.
4. Johnson WB, 1913. An enquiry into the degree of entozoal infection amongst prisoners within the Zunguru Gaol, northern Nigeria. *Reports to the Colonial Office* 138: 214-224. (Abstracted in *Tropical Diseases Bulletin* 16: 190-191, 1913).
5. Henry A, Joyeux CH, 1920. Contribution à la faune helminthologique de la Haute Guinée française. *Bulletin de la Société de Pathologie Exotique* 13: 176-182.
6. Elmes BGT, McAdam IWJ, 1954. Helminthic abcess, a surgical complication of *Oesophagostomes* and hookworms. *Annals of Tropical Medicine and Parasitology* 48: 1-7.
7. Chabaud AG, Larivière M, 1958. Sur les *Oesophagostomes* parasites de l'homme. *Bulletin de la Société de Pathologie Exotique* 51: 384-393.
8. Haaf E, van Soest AH, 1964. *Oesophagostomiasis* in man in North Ghana. *Tropical and Geographical Medicine* 16: 49-53.
9. Gigase P, Baeta S, Kumar V, Brandt J, 1987. Frequency of symptomatic human oesophagostomiasis (helminthoma) in Northern Togo. in Geerts and others, ed., 1987. *Helminth zoonoses*. : Martinus Nijhoff, 228-236.
10. Popova TI, 1958. Strongyloids of animals and man, Trichonematidae. in Skrjabin, KI, ed., *Essentials of Nematology*, Vol VII.: Academy of Sciences of the USSR Helminthological laboratory.
11. Leoutsakos B, Agnadi N, Kolisiatis S, 1977. Rectal bleeding due to *Oesophagostomum brumpti*: report of a case. *Diseases of Colon and Rectum* 20: 632-634.

12. Polderman AM, Rijpstra AC, 1988. *Medische Parasitologie, handleiding bij de laboratoriumdiagnostiek*. Utrecht: Bohn Scheltema & Holkema.
13. Little MD, 1981. Differentiation of nematode larvae in coproculture: Guidelines for routine practice in medical laboratories. *WHO Technical Report Series No 666*: 144-150.
14. Glen DR, Brooks R, 1985. Phylogenetic relationships of some Strongylate nematodes of primates. *Proceedings of the Helminthological Society of Washington 52*: 227-236.
15. Dash KM, 1973. The life cycle of *Oesophagostomum columbianum* (Curtice, 1890) in sheep. *International Journal of Parasitology 3*: 843-851.