



Universiteit
Leiden
The Netherlands

Multi-modality diagnostic assessment in interventional cardiology

Pyxaras, S.

Citation

Pyxaras, S. (2018, May 8). *Multi-modality diagnostic assessment in interventional cardiology*. Retrieved from <https://hdl.handle.net/1887/62029>

Version: Not Applicable (or Unknown)

License: [Licence agreement concerning inclusion of doctoral thesis in the Institutional Repository of the University of Leiden](#)

Downloaded from: <https://hdl.handle.net/1887/62029>

Note: To cite this publication please use the final published version (if applicable).

Cover Page



Universiteit Leiden



The handle <http://hdl.handle.net/1887/62029> holds various files of this Leiden University dissertation.

Author: Pyxaras, S.

Title: Multi-modality diagnostic assessment in interventional cardiology

Issue Date: 2018-05-08

Chapter 5

Anatomical and functional assessment of Tryton bifurcation stent before and after final kissing balloon dilatation: evaluations by three-dimensional coronary angiography, optical coherence tomography imaging and fractional flow reserve.

This chapter was adapted from:

Anatomical and functional assessment of Tryton bifurcation stent before and after final kissing balloon dilatation: evaluations by three-dimensional coronary angiography, optical coherence tomography imaging and fractional flow reserve. Stylianos A. Pyxaras, Gabor G. Toth, Giuseppe Di-Gioia, Giovanni J. Ughi, Shengxian Tu, Dan Rusinaru, Tom Adriaenssens, Johan HC Reiber, Martin B. Leon, Jeroen J. Bax, William Wijns
Catheterization and Cardiovascular Interventions. 2017,
Volume 90, Issue 1, Pages E1-E10

ABSTRACT

Objectives. To assess the anatomical and functional impact of final kissing balloon inflation (FKBI) after implantation of a dedicated bifurcation stent system.

Background. Current evidence suggests clinical benefit of FKBI in patients undergoing bifurcation dilatation using the Tryton Side Branch Stent (Tryton-SBS). We hypothesized that FKBI improves anatomical reconstruction and functional results of bifurcation treated by Tryton-SBS.

Methods. An unselected group of patients with complex bifurcation coronary lesions undergoing percutaneous coronary intervention (PCI) with Tryton-SBS underwent paired anatomical assessment with two- and three-dimensional quantitative coronary analysis (2D- and 3D-QCA), and optical coherence tomography (OCT), including 3D reconstruction before and after FKBI. Functional assessment by fractional flow reserve (FFR) was performed in the main branch (MB) and side branch (SB) before and after FKBI.

Results. Paired pre- and post-FKBI data were obtained in 10 patients. By OCT imaging, FKBI increased both the SB ostial area (4.93 ± 2.81 vs. 7.43 ± 2.87 mm², $p < 0.001$) and the SB maximum diameter (3.12 ± 0.98 vs. 3.82 ± 1.10 mm, $p = 0.003$). These findings were associated with a significant increase in FFR in the SB (0.90 ± 0.05 vs. 0.94 ± 0.03 ; $p = 0.011$), with no significant change in the MB (0.91 ± 0.05 vs. 0.92 ± 0.04 ; $p = 0.470$).

Conclusions. In patients with complex bifurcation stenosis undergoing PCI with a dedicated bifurcation system, FKBI is associated with improved anatomical and functional results at the SB level, without compromising the result at the MB.

INTRODUCTION

In the setting of percutaneous coronary intervention (PCI), treatment of bifurcation stenosis remains associated with procedural complexity and worse clinical outcome (1-3). Provisional stenting technique is the current standard of care fitting for the vast majority of the cases. However, for the treatment of complex bifurcation stenoses that compromise a large side branch (SB), more complex techniques might be indicated and therefore several dedicated bifurcation devices were developed. The Tryton Side Branch Stent (Tryton-SBS; Tryton Medical, Durham, North Carolina, USA) showed satisfactory long-term clinical results when randomly compared to provisional stenting, at least with larger diameter SB (4). Analysis of retrospective patient series treated with Tryton-SBS showed improved clinical outcome in patients undergoing final kissing balloon inflation (FKBI) versus those who did not (5). This study was undertaken to analyze in detail the functional and anatomical impact of FKBI on procedural results.

To this end, we used recently developed coronary artery imaging tools that integrate visual and physiological information and are well suited for the specific assessment of bifurcation lesions treated with Tryton-SBS (6, 7). Co-registration between angiography, optical coherence tomography (OCT) and fractional flow reserve (FFR) has been developed to achieve precise correspondence of anatomical and functional elements within the coronary tree (8). In this study we seized the opportunities offered by this technology in order to assess anatomically and functionally a series of bifurcation lesions treated with Tryton-SBS, by comparing paired measurements obtained before and after FKBI.

METHODS

Patient Population

The study design is shown in **Figure 1**. Ten non-selected patients with stable coronary artery disease and complex bifurcation lesions were prospectively enrolled and treated at the Cardiovascular Research Center Aalst. Patients were scheduled for bifurcation PCI and treated according to practice guidelines, including dual antiplatelet therapy with aspirin and clopidogrel (9). Unfractionated heparin (UFH) was adjusted in order to maintain an activated clotting time ≥ 250 seconds after an initial bolus of 50-70 IU/kg.

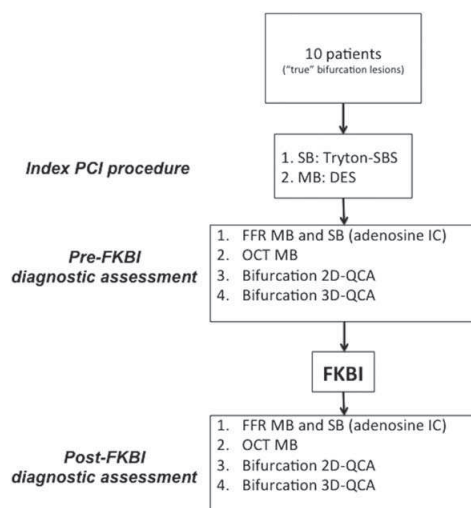


Figure 1. Study design.

Inclusion criteria were the following: “true” bifurcation lesions (i.e., Medina 1.1.1, 1.0.1, 0.1.1) where main branch (MB) and side branch (SB) are both significantly narrowed (>50% diameter stenosis) eligible for PCI; MB diameter between 3.0 and 4.5 mm; and SB diameter ≥ 2.5 mm. Visual estimate of vessel size was used for the inclusion criteria. Exclusion criteria were: type B2/C lesions according to the AHA/ACC classification (10); acute coronary syndrome; troponin elevation within 10 days before enrollment; myocardial infarction within 3 months before inclusion; presence of intermediate-to-high-grade coronary stenoses located proximally or distally to the bifurcation lesion; prior PCI within 3 months before inclusion; coronary bypass surgery within prior 6 months; chronic total occlusion; expected patient survival <1 year; left main coronary artery disease; contraindications to intravenous adenosine administration; and cardiogenic shock. All included bifurcation lesions were considered angiographically significant by two different experienced operators, and in case of disagreement a third experienced operator confirmed suitability inclusion in the study.

The primary study endpoint was to detect changes in FFR in the SB following FKBI. Secondary endpoints were differences in the following parameters before and after FKBI: MB FFR; OCT metrics: minimum SB ostial diameter, maximum SB ostial diameter, SB ostial area; two-dimensional quantitative coronary angiography (2D-QCA) metrics: reference vessel diameter (RVD), minimal lumen diameter (MLD) in proximal and distal MB and SB; three-dimensional (3D)-QCA metrics: RVD, MLD in proximal and distal MB and SB.

The study was approved by the local Ethical Committee and Informed patient consent was obtained for the diagnostic and PCI procedures, data collection and reporting. The authors wrote the manuscript and are responsible for the completeness and accuracy of data collection and analysis.

Stent device and procedural technique

The Tryton-SBS has been previously described (11, 12) and is approved for clinical use. Briefly, the deployment sequence consists in the following: (i) MB and SB predilation, leaving a guidewire in both MB and SB; (ii) positioning and deployment of the Tryton-SBS with the central transition zone markers straddling the SB origin; (iii) the guidewire initially placed in the SB is repositioned in the distal MB; (iv) a standard main vessel stent is then tracked through the proximal main vessel zone of the Tryton-SBS, and deployed into the distal MB; (v) simultaneous kissing balloon post-dilatation is performed (12). Because of large openings in the transition zone, and a proximal segment with few sparse struts designed to secure its proximal implantation, the Tryton-SBS has the potential to minimize double metallic layers, to reduce malapposition and to provide adequate scaffolding of the SB ostium and the carina.

Procedural technique was standardized as follows (**Table 1**): proximal optimization technique (POT) was recommended immediately after Tryton-SBS implantation towards the SB using non-compliant balloons up to 14 atmospheres for at least 20 seconds, with the balloon diameter being equal to the MB proximal RVD. After DES implantation in the MB, all mea-

Table 1. Detailed procedural protocol.

Proximal optimization technique (POT); towards side branch:
 Balloon type: non-compliant
 Balloon diameter = main branch proximal RVD, Length = 12 mm minimum
 Inflation: 14 ATM × at least 20 sec

Kissing balloon inflation modality:
 Balloon type: Non-compliant
 SB Balloon diameter = Side Branch RVD, Length = 12 mm minimum
 MB Balloon diameter = Main Branch distal RVD, Length = 12 mm minimum

Inflation Protocol⁶:
 Inflation #1: SB Balloon to >14 ATM × at least 20 Sec
 Inflation #2: MB Balloon to >14 ATM × at least 20 sec
 Inflation #3: SB & MB Balloon to ~ 12 ATM × at least 20 Sec

ATM: balloon pressure inflation measured in atmospheres; MB: main branch; POT: proximal optimization technique; RVD: reference vessel diameter (here visually estimated); SB: side branch.

* During final kissing balloon inflation the balloon placed in the side branch was always deflated before the one placed in the MB.

** All inflation pressure values and inflation durations were recommended by the study protocol, however the final decision was left to the operator's discretion.

surements were obtained and repeated after FKBI. Non-compliant balloons with a minimum length of 12 mm were used for FKBI and the sequence included three consecutive steps: SB balloon inflation (with recommended inflation pressure up to 14 atmospheres for at least 20 seconds); MB balloon inflation (with recommended inflation pressure up to 14 atmospheres for at least 20 seconds); and final simultaneous MB and SB inflation of the balloons (final kissing balloon inflation – FKBI, with recommended inflation pressure up to 12 atmospheres for at least 20 seconds). Final decision regarding pressure and duration of balloon inflation, as well as the choice of the drug-eluting stent placed in the MB, was left to the operator's discretion. Fluoroscopic evaluation was used to document full expansion of both balloons and the maintenance of balloon position.

Quantitative coronary angiography analysis

Angiographic images were acquired at 15 frames per second (Innova 4100, GE, USA and Axiom Artis, Siemens, Forchheim, Germany). Dedicated bifurcation software packages have been used to perform two (2D-QCA)- and three-dimensional quantitative coronary angiography (3D-QCA). Both software packages (respectively: QAngio XA 7.3; and QAngio XA-3D-RE, both supplied by Medis medical imaging systems bv, Leiden, the Netherlands), have been validated and described previously (13).

Optical coherence tomography analysis

OCT pullbacks were performed at 20 mm/s by non-occlusive flushing technique using a 2.7 F imaging catheter with a dedicated workstation (C7-XRTM OCT Intravascular Imaging

System, St. Jude Medical, St. Paul, Minnesota, USA). Blood was cleared during the pullback by injection of contrast medium at 3-4 ml/sec over the entire duration of the pullback. OCT images were recorded at 100 frames/s and converted to DICOM format at a resolution of 512×512 pixels. Z-offset calibration was performed before converting to DICOM format for the subsequent analysis.

Off-line OCT analysis was performed using QIvus 2.1 (Medis medical imaging systems bv, Leiden, the Netherlands) and the ODIERNA software (UZ Leuven, Leuven, Belgium) previously described and validated (14, 15). Correspondence of segments between X-ray angiography and OCT was established using a co-registration software (QAngioOCT Research Edition 1.0, Medis Specials bv, Leiden, the Netherlands) previously described and validated (16, 17). Accordingly, longitudinal and transversal reconstructions of the coronary segment were obtained. Diameter and area of the SB ostia have been measured using the "cut-plane" analysis of this software. Briefly, the SB ostium is reconstructed as a plane surface using only the MB OCT pullback, allowing assessment of ostial diameters and areas without necessitating access to the SB with the OCT catheter (**Figure 2**).

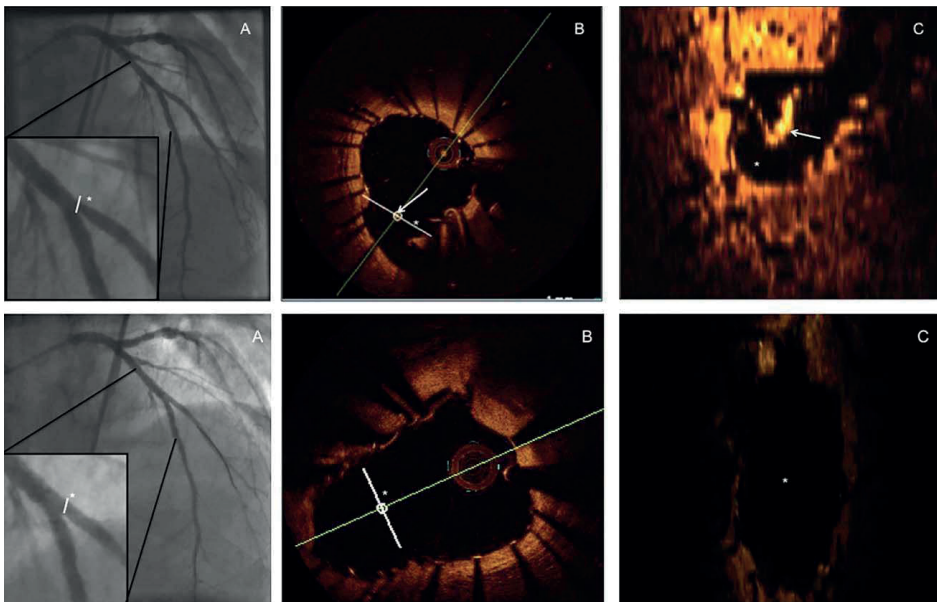


Figure 2. An LAD bifurcation treated with Tryton-SBS, before (first line) and after (second line) FKBI.

Panel A: angio with zoom on the bifurcation. *Panel B:* OCT short axis view on the site of the bifurcation LAD - D1 as seen in panel A. *Panel C:* Visualization of the ostium of the SB before FKBI, with "cut-plane" visualization technique.

The asterisk indicates the correspondence of the bifurcation between panels A, B and C. The white line indicates the correspondence of the "cut-plane" between panels A, B and C. The white arrow indicates stent struts, as visualized in OCT short axis (panel B) and "cut-plane" modality.

D1: First diagonal branch; FKBI: final kissing-balloon inflation; LAD: left anterior descending artery; OCT: optical coherence tomography; SB: side branch; Tryton-SBS: Tryton side branch stent;

OCT abnormalities were defined using quantitative thresholds. Edge dissection was defined as the presence of a linear rim of tissue, with a width of $\geq 200 \mu\text{m}$ and a clear separation from the vessel wall or plaque that was adjacent ($< 5 \text{ mm}$) to a stent edge (18). Reference lumen narrowing was defined as a lumen area $< 4.0 \text{ mm}^2$. Malapposition was identified when the stent lumen distance was greater than the sum of strut thickness plus abluminal polymer thickness, according to each stent manufacturer's specifications, plus a compensation factor of $20 \mu\text{m}$ to correct for strut blooming, and was considered significant if the stent lumen distance was greater than $200 \mu\text{m}$. Stent underexpansion was defined based on established IVUS criteria of optimal stent expansion (i.e., in-stent minimal lumen area $\geq 90\%$ of the average reference lumen area or $\geq 100\%$ of lumen area of the reference segment with the lowest lumen area). Thrombus was defined as intraluminal mass $\geq 200 \mu\text{m}$, with no direct continuity with the surface of the vessel wall or a highly backscattered luminal protrusion in continuity with the vessel wall and resulting in signal-free shadowing.

Fractional flow reserve measurement

Myocardial FFR was measured using a 0.014-inch miniaturized pressure monitoring guide wire system (RADI PressureWire, St Jude Medical Systems), as previously described (19). Intracoronary adenosine was administered to induce maximum hyperemia ($100\text{--}200 \mu\text{g}$). The median value of FFR measured in the main branches of all patients was considered as the cut-off of "normal" post-PCI FFR (20). Accordingly, a bifurcation of a single patient was considered as hemodynamically normal when both MB and SB had an end-procedural FFR value higher than the median of the end-procedural FFR value as measured in the main branches of all patients. Particular care has been made to position the proximal marker of the radio-opaque pressure wire (where the pressure transducer is placed) at the exact same position both before and after FKBI. To achieve this, angiographic SB landmarks were used and the different procedural steps were performed at the exact same angiographic angulation.

Statistical Analysis

Continuous variables were expressed as means and standard deviation, while categorical characteristics were expressed as absolute numbers and percentages. Every patient served as his own control (case-control study) and accordingly t-paired test comparison was used to assess differences in continuous variables (i.e. FFR values and OCT metrics) before and after FKBI. All statistical analyses were performed using SPSS 17.0 (SPSS Inc., Chicago, Illinois, USA).

RESULTS

Demographical and clinical characteristics of the patient sample are typical for elective PCI, with all but one stenosis located in the LAD-diagonal bifurcation (**Table 2**). Lesion features including 2D-QCA are listed in **Table 3**, with 7 out of 10 stenoses classified as Medina 1.1.1. The proximal MB had a minimal vessel diameter (MLD) of 2.01 mm and a reference vessel diameter (RVD) of 3.54 at its proximal segment, while the distal MB dimensions were 0.96 and 2.09, respectively.

Table 4 shows the comparison between anatomical (2D- and 3D-QCA, and OCT) and functional (FFR) parameters before and after FKBI for both MB and SB. **Figure 3** shows the individual changes in MB minimal luminal area (assessed by OCT) and FFR (panels A and B, respectively). Likewise, **Figure 4** shows the individual changes in SB ostial area and FFR (panels A and B, respectively). Of note, a significant increase in SB ostial area ($2.5 \pm 2.8 \text{ mm}^2$, $p < 0.001$) has been accompanied by a significant increase in SB FFR (primary end-point; 0.04 ± 0.13 , $p = 0.011$). **Figure 5** shows MB (Panel A) and SB (Panel B) FFR values before and after FKBI per single patient. No significant difference was noted before and after FKBI with respect to MLD, MLA by OCT and FFR in the MB. In comparison to OCT, 2D- and 3D-QCA were both not able to detect significant changes in MB and SB metrics before and after FKBI. All study patients had a final FFR value > 0.80 in both MB and SB.

Table 5 shows procedural characteristics, both for the total patient sample and subgroups divided according to the median final FFR value. In the subgroup with end-procedural $\text{FFR} \geq 0.92$, fewer additional balloons were used (1.3 ± 0.6 vs. 2.7 ± 1.0 balloons in patients

Table 2. Baseline demographic and clinical characteristics.

| | Total (n = 10) | Normal* final FFR (n = 5) | Abnormal* final FFR (n = 5) | p |
|-------------------------------|-------------------|---------------------------------|-----------------------------------|-------|
| Age (years), mean \pm SD | 69 \pm 10 | 75 \pm 8 | 62 \pm 7 | 0.025 |
| Male Gender, n (%) | 5 (50) | 2 (40) | 3 (60) | 0.527 |
| Diabetes, n (%) | 3 (30) | 1 (20) | 2 (40) | 0.490 |
| Hypertension, n (%) | 7 (70) | 4 (80) | 3 (60) | 0.490 |
| Hypercholesterolemia, n (%) | 6 (60) | 4 (80) | 2 (40) | 0.197 |
| Active Smoker, n (%) | 3 (30) | 1 (20) | 2 (40) | 0.490 |
| Previous MI, n (%) | 2 (20) | 1 (20) | 1 (20) | 1.000 |
| Previous PCI, n (%) | 5 (50) | 1 (20) | 4 (80) | 0.099 |
| Previous CABG, n (%) | 1 (10) | 1 (20) | 0 (0) | 0.285 |
| Chronic kidney disease, n (%) | 1 (10) | 1 (33) | 0 (0) | - |

CABG: coronary artery bypass graft; CAD: coronary artery disease; FFR: fractional flow reserve; LVEF: left ventricular ejection fraction; MI: myocardial infarction; PCI: percutaneous coronary intervention.

* The median value of FFR 0.92 measured in the main branches (MB) of all patients was considered as the cut-off of "normal" post-PCI FFR.

Table 3. Baseline lesion characteristics.

| | Baseline |
|---------------------------------------------------|-------------|
| Site of bifurcation lesion, n (%) | |
| • LAD | 9 (90) |
| • LCx | 1 (10) |
| Lesion Type (Medina classification), n (%) | |
| • 1.1.1 | 7 (70) |
| • 0.1.1 | 3 (30) |
| Lesion quantification - baseline 2D-QCA | |
| Main Branch | |
| • RVD proximal (mm) | 3.54 ± 0.74 |
| • MLD proximal (mm) | 2.01 ± 0.65 |
| • DS proximal (%) | 51.4 ± 18.9 |
| • RVD distal (mm) | 2.09 ± 0.43 |
| • MLD distal (mm) | 0.96 ± 0.37 |
| • DS distal (%) | 52.9 ± 20.4 |
| • Lesion length (mm) | 6.9 ± 1.4 |
| Side Branch | |
| • RVD (mm) | 1.58 ± 0.41 |
| • MLD (mm) | 0.91 ± 0.33 |
| • DS (%) | 41.8 ± 17.0 |
| • Lesion length (mm) | 1.9 ± 0.9 |

DS: diameter stenosis; MLD: minimal luminal diameter; LAD: left anterior descending coronary artery; LCx: left circumflex coronary artery; QCA: quantitative coronary angiography; RCA: right coronary artery; RVD: reference vessel diameter.

with final FFR < 0.92; $p=0.031$). Overall, FKBI was associated additional 25.4 ± 8.2 minutes procedure time ($p<0.001$). No fractures, nor other adverse consequences, were noted in the central transition zone from the kissing balloon dilation.

DISCUSSION

In the setting of bifurcation-PCI with the dedicated Tryton-SBS, our findings demonstrate the following: (i) FKBI significantly increases the ostial SB dimensions and has little impact on the MB metrics; (ii) after FKBI, the increase in ostial SB dimensions is accompanied by a significant increase in FFR value in the SB, while the MB FFR remains unchanged.

The optimal percutaneous treatment strategy for coronary bifurcation lesions remains a controversial issue. With smaller, minimally diseased side branches, provisional stenting with single DES placement in the MB is currently the dominant treatment strategy. Unless required by reduced flow or severe ostial SB stenosis, kissing balloon inflation is not recommended

Table 4. Anatomical and functional metrics before and after final kissing balloon inflation.

| | Before FKBI | After FKBI | p |
|------------------------------------|---------------------------|---------------------------|--------|
| 2D-QCA | | | |
| Proximal MB MLD (mm) | 3.33 ± 0.44 | 3.47 ± 0.67 | 0.394 |
| Proximal MB RVD (mm) | 3.94 ± 0.64 | 4.15 ± 0.96 | 0.442 |
| Proximal MB DS (%) | 16.7 ± 14.8 | 15.1 ± 8.5 | 0.644 |
| Distal MB MLD (mm) | 2.62 ± 0.45 | 2.48 ± 0.44 | 0.323 |
| Distal MB RVD (mm) | 3.00 ± 0.56 | 2.91 ± 0.51 | 0.680 |
| Distal MB DS (%) | 13.9 ± 8.7 | 14.7 ± 8.6 | 0.799 |
| SB MLD (mm) | 1.54 ± 0.44 | 1.88 ± 0.34 | 0.054 |
| SB RVD (mm) | 2.14 ± 0.45 | 2.20 ± 0.25 | 0.655 |
| SB DS (%) | 27.6 ± 15.6 | 15.4 ± 10.5 | 0.045 |
| Bifurcation angle (°) | 51.7 ± 15.2 | 55.3 ± 11.2 | 0.462 |
| 3D-QCA | | | |
| Proximal MB MLD (mm) | 2.72 ± 0.22 | 2.75 ± 0.29 | 0.841 |
| Proximal MB RVD (mm) | 3.73 ± 0.36 | 3.85 ± 0.24 | 0.189 |
| Proximal MB DS (%) | 17 ± 10 | 17 ± 7 | 0.970 |
| Distal MB MLD (mm) | 2.43 ± 0.35 | 2.61 ± 0.31 | 0.120 |
| Distal MB RVD (mm) | 3.25 ± 0.34 | 3.33 ± 0.30 | 0.369 |
| Distal MB DS (%) | 25 ± 10 | 21 ± 6 | 0.382 |
| SB MLD (mm) | 1.59 ± 0.29 | 1.89 ± 0.32 | 0.149 |
| SB RVD (mm) | 2.60 ± 0.22 | 2.69 ± 0.23 | 0.133 |
| SB DS (%) | 36 ± 14 | 29 ± 10 | 0.296 |
| Bifurcation angle (°) | 47 ± 4 | 47 ± 10 | 0.860 |
| OCT | | | |
| MB MLD (mm) | 2.24 ± 0.34 | 2.21 ± 0.41 | 0.788 |
| MB MLA (mm ²) | 5.02 ± 1.77 | 5.14 ± 1.88 | 0.434 |
| SB ostial area (mm ²)* | 4.93 ± 2.81* | 7.43 ± 2.87* | <0.001 |
| SB ostial minimum diameter (mm) | 1.83 ± 0.61 | 2.21 ± 0.55 | 0.075 |
| SB ostial maximum** diameter (mm) | 3.12 ± 0.98** | 3.82 ± 1.10** | 0.003 |
| FFR | | | |
| MB FFR [#] | 0.91 ± 0.05 [#] | 0.92 ± 0.04 [#] | 0.470 |
| SB FFR ^{##} | 0.90 ± 0.05 ^{##} | 0.94 ± 0.03 ^{##} | 0.011 |

2D: two-dimensional; 3D: three-dimensional; DS: diameter stenosis; FFR: fractional flow reserve; FKBI: final kissing-balloon inflation; LAD: left anterior descending coronary artery; LCx: left circumflex coronary artery; MB: main branch; MLD: minimal luminal diameter; OCT: optical coherence tomography; QCA: quantitative coronary angiography; RCA: right coronary artery; RVD: reference vessel diameter; SB: side branch.

* The mean change in SB ostial area was $2.5 \pm 2.8 \text{ mm}^2$, $p < 0.001$

** The mean change in SB ostial maximum diameter was $+0.7 \pm 0.9 \text{ mm}$, $p = 0.003$

[#] The mean change in MB FFR was $+0.04 \pm 0.13$; $p = 0.011$

^{##} The mean change in SB FFR was $+0.01 \pm 0.04$; $p = 0.470$

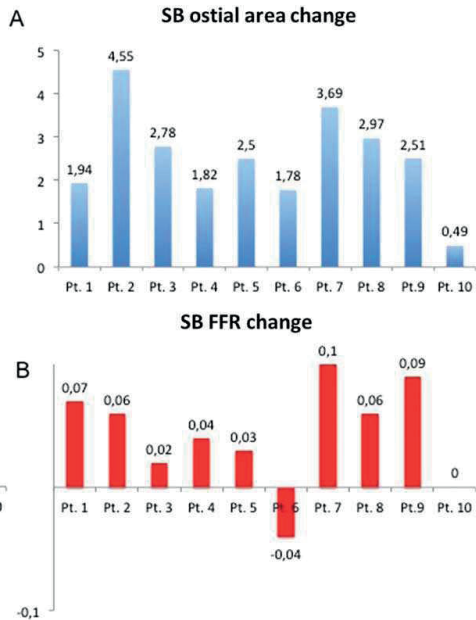
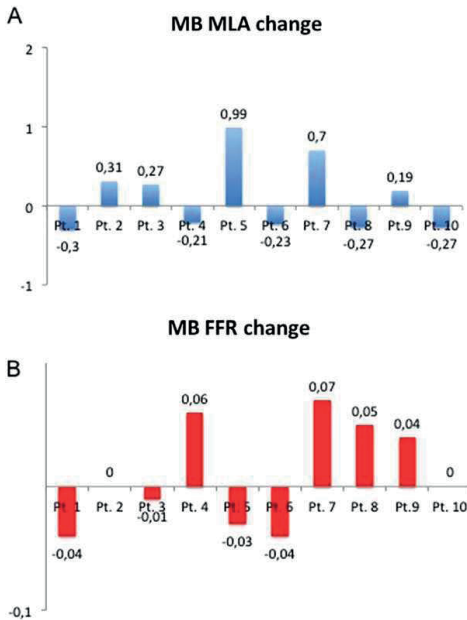


Figure 3. Observed per-single-patient change in main branch minimal luminal area (MLA), as assessed by OCT (panel A) and increase in FFR (panel B). FFR: fractional flow reserve; OCT: optical coherence tomography.

Figure 4. Observed per-single-patient change in side branch ostial area, as assessed by OCT (panel A) and increase in FFR (panel B). FFR: fractional flow reserve; OCT: optical coherence tomography.

(21). Systematic FKBI was not shown to provide clinical benefit, even though bench studies show favourable stent deployment (22, 23). It has been argued that FKBI may facilitate later access to the SB in case of MB restenosis; yet this opportunity has become less relevant with the generalized use of DES and low restenosis rates. It remains that a proportion of

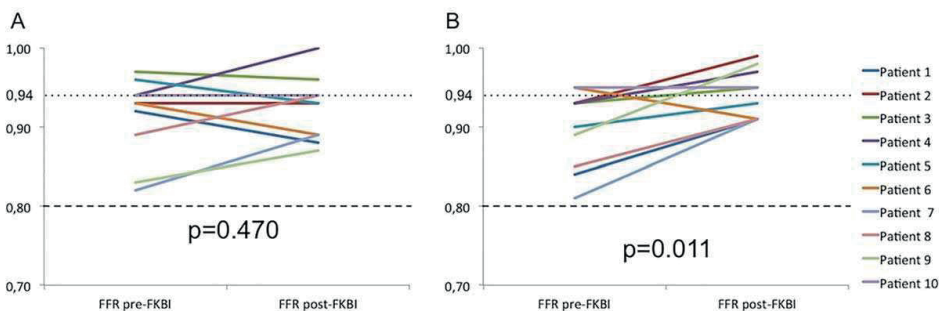


Figure 5. FFR values measured in the main branch before and after FKBI in MB (Panel A) and in SB (Panel B) per single patient. FFR: fractional flow reserve; FKBI: final kissing-balloon inflation; MB: main branch; OCT: optical coherence tomography; SB: side branch.

Table 5. Procedural characteristics.

| | Total n = 10 | Normal final FFR (n = 5) | Abnormal final FFR (n = 5) | p |
|------------------------------------------------------|-------------------------|-----------------------------------------|-------------------------------------------|----------|
| Predilatation | | | | |
| • MB, n (%) | 7 (70) | 3 (60) | 4 (80) | 0.490 |
| • MB, mean inflation pressure (Atm) | 13.7 ± 2.1 | 14.7 ± 1.2 | 13.0 ± 2.6 | 0.352 |
| • MB, mean balloon diameter (mm) | 2.7 ± 0.4 | 2.7 ± 0.3 | 2.7 ± 0.5 | 0.949 |
| • SB, n (%) | 10 (100) | 5 | 5 | - |
| • SB, mean inflation pressure | 10.6 ± 3.3 | 8.8 ± 3.4 | 12.4 ± 2.2 | 0.079 |
| • SB, mean balloon diameter (mm) | 2.4 ± 0.3 | 2.5 ± 0.4 | 2.3 ± 0.3 | 0.347 |
| POT, n (%) | 7 (70) | 3 (60) | 4 (80) | 0.490 |
| • mean inflation pressure (Atm) | 14.6 ± 3.2 | 15.3 ± 1.2 | 14.0 ± 4.3 | 0.632 |
| • mean balloon diameter (mm) | 3.4 ± 0.2 | 3.5 ± 0.0 | 3.4 ± 0.3 | 0.437 |
| Drug-eluting stent type in MB | | | | 0.038 |
| • Everolimus, n (%) | 3 (30) | 0 (0) | 3 (60) | |
| • Zotarolimus, n (%) | 7 (70) | 5 (100) | 2 (40) | |
| Length of MB stent (mm) | 29.4 ± 7.6 | 29.4 ± 8.7 | 29.4 ± 7.4 | 1.000 |
| Additional stenting in MB, n (%) | 1 (10) | * | * | - |
| Additional stenting in SB, n (%) | 1 (10) | * | * | - |
| Additional number of balloons to perform FKBI | 2.3 ± 1.1 | 2.0 ± 1.0 | 2.6 ± 1.1 | 0.402 |
| Total procedure duration (min) | 94.1 ± 18.7 | 85.7 ± 18.7 | 102.4 ± 16.0 | 0.172 |
| Additional time to perform FKBI (min) | 25.4 ± 8.2 | 22.8 ± 6.4 | 27.9 ± 9.5 | 0.342 |

FFR: fractional flow reserve; FKBI: final kissing-balloon inflation; MB: main branch; POT: proximal optimization technique; SB: side branch

complex bifurcation stenoses, especially with larger SB, may require PCI using double stent techniques. With the use of Tryton-SBS, recently published data suggest clinical benefit of FKBI (5). Being observational in nature, these findings may be confounded by differences in baseline risk profiles.

This study was therefore designed to specifically evaluate the impact of FKBI on detailed stenosis geometry and anatomy. Functional relevance was evaluated by changes in FFR measured in both SB and MB pre- and post-FKBI.

Koo et al. used FFR measurement in bifurcation lesions treated with PCI to assess the functional significance of “jailed” SB (i.e. not treated with FKBI) (24). Many “stenosed” SB were found not to be associated with reduced FFR values below the 0.75 threshold.

Using co-registration capabilities, we were able to precisely identify correlates between angiography, OCT and FFR pullback. Geometrical dimensions of bifurcation carina and SB ostia can be measured, as well as the corresponding flow conductance characteristics. We found that the majority of SB ostia had elliptical shape (not circular), which can be misinterpreted as “jailed” or “stenosed” by angiography using single-plane assessment. We

were able to demonstrate that FKBI induced an increase in SB ostia dimensions, alongside with removal of stent struts of the DES previously implanted in the MB from the SB ostium (**Figure 2, panel C**). This finding was associated with a significant increase in SB FFR, which is desirable. We reasoned that any significant increase in final FFR characterizes the efficacy of PCI technique in restoring normal vessel conductance, hence maximal coronary flow increase in the downstream myocardium (25).

In the present study, final kissing balloon inflation was associated with an increase in SB FFR. Previous experience by Pijls et al. and more recently by Johnson et al. showed that sub-optimal FFR values after PCI (i.e. $FFR < 0.96$) were associated with worse patient outcome at follow-up (26,27). Suboptimal post-PCI FFR results can be improved by further stent expansion, increase of ostial dimensions and removal of main branch stent struts covering the side branch orifice, thereby correcting flow pattern alterations and abnormal coronary conductance (28,29). Our findings confirm that optimal PCI results in the case of bifurcation PCI using the Tryton-SBS cannot be reached without FKBI.

Study Limitations

Although the number of studied patients is small, findings are robust because complete anatomical and functional assessment was performed for both MB and SB using 2D-QCA, 3D-QCA, OCT and FFR measurements. Every patient was his/her own control since paired data were obtained before and after FKBI. FFR assessment was not performed at baseline and the decision to perform PCI was driven by clinical data and significant bifurcation stenosis by coronary angiography.

We cannot exclude that angiographically non-significant diffuse disease proximally or distally to the treated bifurcation may have had an impact on final FFR measurements.

Visual estimation of the size of the SB was applied as an inclusion criterion, in keeping with clinical practice. The SB mean RVD was 1.58 ± 0.41 as assessed by QCA (Table 3). A subanalysis of the Tryton randomized trial by Généreux et al. showed that 59% of enrolled patients had a QCA-assessed SB RVD ≤ 2.25 mm (Core Lab QCA) (30). These findings show expected differences between visual estimates of vessel size and QCA and highlight the need for baseline QCA to enhance adequate patient selection.

Lastly, the clinical impact of FKBI could only be evaluated by larger, randomized trials. However, given the findings of the present study and the proven clinical importance of functional measurements using FFR, it may not be desirable to perform bifurcation PCI using the Tryton-SBS without FKBI dilatation.

CONCLUSIONS

In patients with bifurcation lesions undergoing PCI with the Tryton-SBS, FKBI is associated with a significant morphological and functional benefit. Therefore FKBI can be recommended as an integral part of the bifurcation PCI procedural technique with the use of Tryton-SBS.

REFERENCES

1. Hildick-Smith D, de Belder AJ, Cooter N, et al. Randomized Trial of Simple Versus Complex Drug-Eluting Stenting for Bifurcation Lesions The British Bifurcation Coronary Study: Old, New, and Evolving Strategies. *Circulation* 2010;121:1235–1243.
2. Steigen TK, Maeng M, Wiseth R, et al. Randomized Study on Simple Versus Complex Stenting of Coronary Artery Bifurcation Lesions The Nordic Bifurcation Study. *Circulation* 2006;114:1955–1961.
3. Routledge HC, Morice MC, Lefèvre T, et al. 2-year outcome of patients treated for bifurcation coronary disease with provisional side branch T-stenting using drug-eluting stents. *JACC Cardiovasc Interv* 2008;1:358-65.
4. Genereux P, Kumsars I, Lesiak M, et al. A randomized trial of a dedicated bifurcation stent versus provisional stenting in the treatment of coronary bifurcation lesions. *J Am Coll Cardiol* 2015;65:533-43.
5. Grundeken MJ, Lesiak M, Asgedom S, et al. Clinical outcomes after final kissing balloon inflation compared with no final kissing balloon inflation in bifurcation lesions treated with a dedicated coronary bifurcation stent. *Heart* 2014;100: 479-86.
6. Pyxaras SA, Tu S, Barbato E, Reiber JHC, Wijns W. Optimization of Tryton Dedicated Coronary Bifurcation System With Coregistration of Optical Coherence Tomography and Fractional Flow Reserve. *J Am Coll Cardiol Cardiovasc Interv* 2013;6:e39–e40.
7. Tu S, Pyxaras SA, Li Y, Barbato E, Reiber JHC, Wijns W. In Vivo Flow Simulation at Coronary Bifurcation Reconstructed by Fusion of 3-Dimensional X-ray Angiography and Optical Coherence Tomography. *Circ Cardiovasc Interv* 2013;6:e15–e17.
8. Pyxaras SA, Tu S, Barbato E, Wyffels E, Reiber JHC, Wijns W. Co-registration of fractional flow reserve and optical coherence tomography with the use of a three-dimensional angiographic roadmap: an opportunity for optimisation of complex percutaneous coronary interventions. *EuroIntervention* 2013;9:889.
9. Levine GN, Bates ER, Blankenship JC, et al. 2011 ACCF/AHA/SCAI Guideline for Percutaneous Coronary Intervention: Executive Summary: A Report of the American College of Cardiology Foundation/American Heart Association Task Force on Practice Guidelines and the Society for Cardiovascular Angiography and Interventions. *Circulation* 2011;124:2574–2609.
10. Ellis SG, Vandormael MG, Cowley MJ, et al. Coronary morphologic and clinical determinants of procedural outcome with angioplasty for multivessel coronary disease. Implications for patient selection. Multivessel Angioplasty Prognosis Study Group. *Circulation* 1990;82:1193–1202.
11. Grundeken MJ, Génereux P, Wykrzykowska JJ, Leon MB, Serruys PW. The Tryton Side Branch Stent. *EuroIntervention* 2015;11 Suppl V:V145-6.
12. Kaplan AV, Ramcharitar S, Louvard Y, et al. Tryton I, First-In-Man (FIM) Study: acute and 30 day outcome. A preliminary report. *EuroIntervention* 2007;3:54–59.
13. Tu S, Jing J, Holm NR, et al. In vivo assessment of bifurcation optimal viewing angles and bifurcation angles by three-dimensional (3D) quantitative coronary angiography. *Int J Cardiovasc Imaging* 2012;28:1617–1625.
14. Ughi GJ, Van Dyck CJ, Adriaenssens T, et al. Automatic assessment of stent neointimal coverage by intravascular optical coherence tomography. *Eur Heart J Cardiovasc Imaging* 2014;15:195–200.
15. Ughi GJ, Adriaenssens T, Onsea K, et al. Automatic segmentation of in-vivo intra-coronary optical coherence tomography images to assess stent strut apposition and coverage. *Int J Cardiovasc Imaging* 2011;28:229–241.

16. Tu S, Xu L, Ligthart J, et al. In vivo comparison of arterial lumen dimensions assessed by co-registered three-dimensional (3D) quantitative coronary angiography, intravascular ultrasound and optical coherence tomography. *Int J Cardiovasc Imaging* 2012;28:1315–1327.
17. Tu S, Holm NR, Koning G, Huang Z, Reiber JHC. Fusion of 3D QCA and IVUS/OCT. *Int J Cardiovasc Imaging* 2011;27:197–207.
18. Prati F, Guagliumi G, Mintz GS, et al. Expert review document part 2: methodology, terminology and clinical applications of optical coherence tomography for the assessment of interventional procedures. *Eur Heart J* 2012;33:2513–2520.
19. Pijls NH, De Bruyne B, Peels K, et al. Measurement of Fractional Flow Reserve to Assess the Functional Severity of Coronary-Artery Stenoses. *N Engl J Med* 1996;334:1703–1708.
20. Hanekamp CE, Koolen JJ, Pijls NH, Michels HR, Bonnier HJ. Comparison of quantitative coronary angiography, intravascular ultrasound, and coronary pressure measurement to assess optimum stent deployment. *Circulation* 1999;99:1015–1021.
21. Niemelä M, Kervinen K, Erglis A, et al. Randomized Comparison of Final Kissing Balloon Dilatation Versus No Final Kissing Balloon Dilatation in Patients With Coronary Bifurcation Lesions Treated With Main Vessel Stenting: The Nordic-Baltic Bifurcation Study III. *Circulation* 2011;123:79–86.
22. Ormiston JA, Webster MWI, Jack EI S, et al. Drug-eluting stents for coronary bifurcations: Bench testing of provisional side-branch strategies. *Catheter Cardiovasc Interv* 2006;67:49–55.
23. Behan MW, Holm NR, Curzen NP, et al. Simple or Complex Stenting for Bifurcation Coronary Lesions: A Patient-Level Pooled-Analysis of the Nordic Bifurcation Study and the British Bifurcation Coronary Study. *Circ Cardiovasc Interv* 2011;4:57–64.
24. Koo B-K, Kang H-J, Youn T-J, et al. Physiologic Assessment of Jailed Side Branch Lesions Using Fractional Flow Reserve. *J Am Coll Cardiol* 2005;46:633–637.
25. De Bruyne B, Hersbach F, Pijls NH, et al. Abnormal epicardial coronary resistance in patients with diffuse atherosclerosis but “Normal” coronary angiography. *Circulation* 2001;104:2401–2406.
26. Pijls NH, Klauss V, Siebert U et al. Coronary pressure measurement after stenting predicts adverse events at follow-up: a multicenter registry. *Circulation* 2002;105:2950-4.
27. Johnson NP, Tóth GG, Lai D et al. Prognostic value of fractional flow reserve: linking physiologic severity to clinical outcomes. *J Am Coll Cardiol* 2014;64:1641-54.
28. Foin N, Gutierrez-Chico JL, Nakatani S et al. Incomplete stent apposition causes high shear flow disturbances and delay in neointimal coverage as a function of strut to wall detachment distance: implications for the management of incomplete stent apposition. *Circ Cardiovasc Interv* 2014;7:180-9.
29. Matthys K, Carlier S, Segers P et al. In vitro study of FFR, QCA, and IVUS for the assessment of optimal stent deployment. *Catheter Cardiovasc Interv* 2001;54:363-75.
30. Généreux P, Kini A, Lesiak M, et al. Outcomes of a dedicated stent in coronary bifurcations with large side branches: A subanalysis of the randomized TRYTON bifurcation study. *Catheter Cardiovasc Interv* 2016;87:1231–1241.