



Universiteit
Leiden
The Netherlands

Best practices in minimally invasive gynecology: making sense of the evidence

Sandberg, E.M.

Citation

Sandberg, E. M. (2018, April 25). *Best practices in minimally invasive gynecology: making sense of the evidence*. Retrieved from <https://hdl.handle.net/1887/61633>

Version: Not Applicable (or Unknown)

License: [Licence agreement concerning inclusion of doctoral thesis in the Institutional Repository of the University of Leiden](#)

Downloaded from: <https://hdl.handle.net/1887/61633>

Note: To cite this publication please use the final published version (if applicable).

Cover Page



Universiteit Leiden



The following handle holds various files of this Leiden University dissertation:
<http://hdl.handle.net/1887/61633>

Author: Sandberg, E.M.

Title: Best practices in minimally invasive gynecology: making sense of the evidence

Issue Date: 2018-04-25

Chapter 8

Disseminated leiomyoma cells can
be identified following conventional
myomectomy

E.M. Sandberg, L. van den Haak, T. Bosse, F.W. Jansen

Abstract

Objective: Uncontained morcellation of leiomyomas during laparoscopic surgery has recently been discouraged, as undetected malignant tumours, namely leiomyosarcomas, could be fragmented which may result in upstaged disease. However, enucleating leiomyomas per se may be inappropriate from an oncological perspective because complete, radical resection of malignant tumours to prevent further tumour growth or recurrence is not achieved. Thus, the aim of this study was to determine whether spillage of leiomyoma cells occurs during laparotomic myomectomy.

Design: Observational study.

Setting: Tertiary academic centre in the Netherlands.

Population: Women undergoing laparotomic myomectomy were included in the study.

Methods: Peritoneal abdominal washings were obtained on two occasions during the myomectomy procedure; the first one immediately after opening the abdomen and the second one after resection of the leiomyoma(s). Cytological evaluation of the fluids was performed.

Main outcome measures: The presence of leiomyoma cells in any of the washings.

Results: Five patients were included in this pilot study. All first washings were negative for leiomyoma cells. However, cytology positive for the presence of leiomyoma cells was found in three of the five second, post-myomectomy washings.

Conclusion: Tissue spillage from leiomyoma(s) occurs during conventional open myomectomy. The clinical relevance of tissue dissemination after myomectomy is unclear but it cannot be excluded that this may negatively affect the patient's outcome if there is malignant change within the enucleated leiomyoma(s). Therefore, it is questionable whether morcellation in specially designed containment bags after laparoscopic myomectomy, guarantees any additional oncological safety.

Introduction

The introduction of power morcellation in the field of gynaecology has contributed to the wider implementation of minimally invasive surgery by enabling laparoscopic extraction of large specimens. Although warnings regarding its oncological safety were published more than a decade ago,^{1,2} it was only in 2014 that the Food and Drug Administration (FDA) issued a press release discouraging the use of morcellation during laparoscopic gynaecologic surgery, namely hysterectomy and myomectomy, in the presence of leiomyomas.³ This FDA statement was issued in response to reports of cases of morcellation of presumed benign tumours that subsequently turned out to be leiomyosarcoma(s). This in turn led to concerns that tissue dissemination of occult malignancy after morcellation could lead to an upstage of the disease.⁴ Furthermore, preoperative prediction of malignant change within leiomyomas is unreliable in the absence of prognostic patient characteristics or discriminatory diagnostic tests.

One of the basic principles of surgical oncology is that malignant tumours should always be resected radically and in toto to prevent further tumour growth and/or recurrence. If all malignant tissue spillage is considered potentially harmful, as many authors advocate,^{4,6} it can be questioned whether, from an oncological point of view, myomectomy for presumed leiomyomas is safe altogether. Indeed, the cleavage plane is almost never radical during myomectomy, regardless of the type of approach. Furthermore, leiomyosarcomas are heterogeneous tumours, meaning that malignant cells could be located anywhere inside the growth.

In light of these considerations we hypothesised that dissemination of leiomyomatous tissue occurs during resection of leiomyomas and not just as a result of subsequent morcellation of extracted tissue. Therefore, the aim of the current study was to detect the presence of leiomyoma spillage during laparotomic myomectomy by performing peritoneal washings.

Methods

During the study period, all patients undergoing abdominal myomectomy at the Leiden University Medical Centre (Leiden, the Netherlands) were asked to participate. The study was exempted from Institutional Review Board approval, but patients were informed about the study procedure and gave oral consent. Inclusion criteria were women of 18 years or older, diagnosed with symptomatic leiomyomas and eligible to undergo abdominal myomectomy as per the judgment of the surgeon. Exclusion criteria were suspected malignancy and inability to give consent.

The abdominal myomectomy procedure was performed according to standard techniques. As part of the study, the entire abdomen was washed two times with 500 ml of normal saline during the procedure: the first washing was performed as a control, immediately after opening the abdomen, and the second washing after resection of the leiomyoma(s). After every washing, the abdominal fluid was completely aspirated and collected in two separate bags for cytological evaluation. The main outcome of the study was to evaluate the presence of leiomyoma cells in any of the washings.

Before embedding the cells collected from the washings in paraffin, an erythrocyte lysis buffer (155 mM NH_4Cl , 10 mM KHCO_3 , 1 mM EDTA, pH 7.4) was used to limit the amount of red blood cells which would impair visualisation during analyses. For each patient, two sets of formalin-fixed paraffin-embedded samples were obtained from the first and second washing. These samples were then cut at different levels and the tissue was stained with haematoxylin and eosin (HE stain). Next, the specimen slides were reviewed by an experienced pathologist (T.B.) to detect the presence of leiomyoma cells. In case of doubt, an additional staining with desmin was performed.

Data from the medical record of the patients were also abstracted and included: patient age and body mass index (BMI), indications for myomectomy, the number and weight of removed fibroids, and surgical outcomes such as operative time, intra-operative blood loss and complications. Complications were defined based on the classification of the Dutch Society of Obstetrics and Gynaecology.⁷

Results

Five patients were recruited to the study between April and October 2015. Patients were on average 34.6 years old (29–40), with a BMI of 27.7 (22–34.1). Reasons for the surgery were heavy bleeding ($n=2$) and/or infertility problems ($n=3$) and/or pelvic pressure and pain ($n=2$). On average, 3.8 fibroids (3–6) were removed and the removed specimens weighed 599.4 g (256–1040). All procedures were successfully completed, with an operative time of 108 min (91–134) and intra-operative blood loss of 685 ml (275–1300). Two patients experienced intraoperative haemorrhage of more than 1000 ml. One of them received two packages of red blood cells postoperatively. No other complications occurred and the postoperative course was otherwise uneventful in all cases (Table 8.1). All peritoneal washings obtained directly after opening the abdomen were negative, whereas three of the five peritoneal washings acquired after resection of the leiomyomas were positive for leiomyoma cells (Table 8.1, Figure 8.1). In one case the presence of leiomyoma cells was confirmed after performing an additional staining with desmin.

Table 8.1: Baseline characteristics, surgical outcomes and outcomes of cytology peritoneal washings

	Age (years)	BMI (kg/m ²)	Indication surgery	Operative time (min)	Intra-operative blood loss (mL)	Specimen weight (gram)	Number of fibroids (n)	Complications	First washing	Second washing
Patient 1	38	22.0	Infertility	100	275	256	3	--	Negative	Negative
Patient 2	31	27.8	Blood loss	103	1065	1040	3	>1000 mL blood loss + two RBCs	Negative	Positive*
Patient 3	29	26.1	Pressure + infertility	111	350	811	6	--	Negative	Positive
Patient 4	35	34.1	Blood loss + infertility	91	430	500	4	--	Negative	Positive
Patient 5	40	28.4	Pressure	134	1300	390	3	>1000 mL blood loss	Negative	Negative
Mean	34.6	27.7	--	108	684	599.4	3.8	--	--	--

* Desmin stain conclusive.

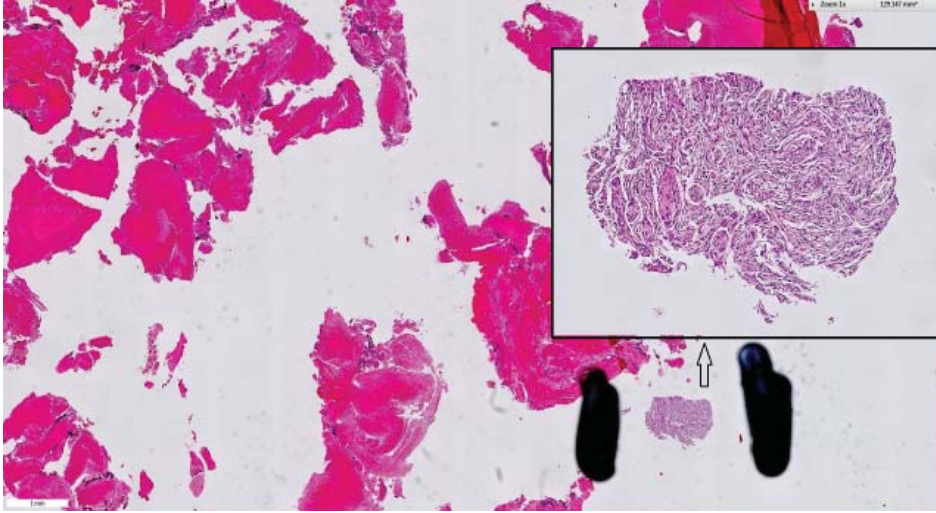


Figure 8.1: Leiomyoma cells (arrow) in the second peritoneal washing of patient 4 (HE stain).

Discussion

Main findings

There is evidence of micro-spillage of leiomyoma cells after conventional, open myomectomy but it is unclear whether these positive cytology results hold any clinical relevance if malignant change within the enucleated leiomyoma(s) is subsequently diagnosed following histological analysis.

Strengths and limitations

One limitation of our study could be the restriction of analysis to a conventional open abdominal myomectomy. However, the process of mechanically enucleating fibroids is similar during laparoscopic surgery and so one would expect the likelihood of tissue dissemination during myomectomy to be the same. The finding that tissue dissemination was not consistent following myomectomy, as no leiomyoma cells were detected in two of the five study cases, could be explained by the known limitations of the peritoneal washings technique⁸ and so does not completely exclude their presence. In any case, even one positive cytology result would have been sufficient to support our hypothesis that dissemination of leiomyomatous tissue can occur during resection of leiomyomas. Our study analysed tumour dissemination of benign leiomyoma cells and not of leiomyosarcomas. Dissemination of leiomyosarcomas might also depend on whether small foci of sarcoma

are at the edges of the excised specimen and/or breaches were made on the surface. Of note, in this study we focused only on myomectomy and so our conclusion can not be extrapolated to hysterectomy in the presence of uterine leiomyomas.

Interpretation

The present study sheds new light on the current morcellation debate. In reaction to the FDA report warning of the use of power morcellation in the presence of uterine leiomyomas, gynaecologists throughout the world have sought to develop techniques to reduce the risk of potential spread, while conserving the less invasive laparoscopic approach. In addition to reducing surgical morbidity, preservation of the laparoscopic route of surgery seems reasonable given the low prevalence of leiomyosarcoma compared with that of leiomyoma.⁹

One of the suggested surgical options is 'contained power morcellation': after resection of the uterus or fibroid, a bag is inserted into the abdomen and the specimen is morcellated in the bag and removed.^{10,11} In many clinics, contained power morcellation has been rapidly adopted and the first studies have shown that, despite a prolonged operative time of approximately 20–30 minutes, the technique is feasible.^{12–14} Even though this technique is in its early phase of development, it can be questioned whether containment after extensive resection without a bag will ever provide any additional safety during myomectomy, as our study showed that during leiomyoma resection, tissue dissemination already occurs. Furthermore, studies evaluating the leakage during contained tissue extraction with power morcellation noted spillage of tissue from the bag in 9.2–33% of cases.^{15,16} However, in all those cases the containment bags were visually intact.

In light of this, it is important to evaluate the impact of intra-abdominal malignant tissue dissemination on patient outcomes. Several studies have suggested that spread of uterine sarcomas leads to an upstaging of the disease and dramatically worsens the five-year survival rate when compared with surgery where no morcellation was performed.^{4–6} Although the assumption that malignant tissue dissemination is associated with poorer outcomes seems instinctively plausible, we should be careful with the concept of upstaging used in the studies. Indeed, it implies that during initial surgery all leiomyosarcomas were stage I and that staging was based on a proper inspection of the abdomen, which seems unlikely when a benign tumour is expected.¹⁷ Other studies have found no differences in survival rates between the morcellated and non-morcellated group, or have stated a lack of reliable evidence regarding the clinical relevance of the spread, especially as generally speaking the overall prognosis of a leiomyosarcoma is poor.^{17,18} Furthermore, it is unknown whether a relation exists between the amount of tissue dissemination and the recurrence

and/or survival rate, especially as advanced research demonstrated already detectable circulating tumour cells in the blood of patients with early-stage localised tumours.¹⁹

The influence of non-radical procedures on the recurrence and survival rate has also been investigated in other malignant tumours. For endometrial carcinoma, similar washing studies have been performed, showing an increased percentage of positive cytology after dissemination of tissue from the endometrial cavity into the peritoneal cavity²⁰ but with inconsistent results regarding the prognosis and recurrence of the disease.^{8,20} Also for ovarian carcinoma, controversy exists regarding the magnitude of harm of tumour leakage.²¹ In a meta-analysis on early-stage ovarian cancer, pre-operative ruptures were associated with poorer outcomes compared with intra-operative ruptures, probably due to the duration and the amount of leakage in the abdomen.²¹⁻²³

From a benign perspective, a condition called parasitic leiomyomas has been reported and although the exact aetiology remains unclear, it is believed to be caused by retained intra-abdominal tissue fragments.²⁴ The overall risk of parasitic leiomyomas after uncontained morcellation has recently been reported as between 0.12 and 0.95%.²⁴ It would be interesting to know whether the prevalence changes with contained morcellation. Assuming that containment keeps macro-spread to a minimum during surgery, it cannot be excluded that micro-spread contributes to this rare condition. One recent published report recommended extensive washings after surgery to minimise the risk of retained tissue.¹⁸

Thus, it is apparent that the impact of tissue dissemination on clinical outcomes is unclear, as is the protective value of contained extraction. Therefore, we believe that the gynaecological community should be cautious in widely adopting the peri-operative use of containment bags, which are most likely used off-label and without a proper systematic evaluation prior to implementation. Otherwise, there is a risk of offering a false sense of security. Furthermore, containment extraction should not distract us from seeking improved diagnosis of leiomyosarcomas and a better understanding of tumour biology including the impact of tissue dissemination on clinical outcomes.²⁵

Conclusion

During open myomectomy, spillage of leiomyoma cells occurs. Although the clinical relevance of tissue dissemination after myomectomy is unclear, it cannot be excluded that it does negatively affect the patient's outcome, especially in the presence of malignancy. As a result, it can be questioned whether contained morcellation, as currently performed after laparoscopic myomectomy, guarantees any additional oncological safety.

References

- (1) Takamizawa S, Minakami H, Usui R, Noguchi S, Ohwada M, Suzuki M et al. Risk of complications and uterine malignancies in women undergoing hysterectomy for presumed benign leiomyomas. *Gynecol Obstet Invest* 1999;48(3):193-196.
- (2) Miller CE. Methods of tissue extraction in advanced laparoscopy. *Curr Opin Obstet Gynecol* 2001; 13(4):399-405.
- (3) Laparoscopic Uterine Power Morcellation in Hysterectomy and Myomectomy: FDA Safety Communication. [www.fda.gov/medicaldevices/safety/alertsandnotices/ucm393576.htm]. Accessed 7 April 2014
- (4) Perri T, Korach J, Sadetzki S, Oberman B, Fridman E, Ben-Baruch G. Uterine leiomyosarcoma: does the primary surgical procedure matter? *Int J Gynecol Cancer* 2009;19(2):257-260.
- (5) Einstein MH, Barakat RR, Chi DS, Sonoda Y, Alektiar KM, Hensley ML et al. Management of uterine malignancy found incidentally after supracervical hysterectomy or uterine morcellation for presumed benign disease. *Int J Gynecol Cancer* 2008;18(5):1065-1070.
- (6) Park JY, Park SK, Kim DY, Kim JH, Kim YM, Kim YT et al. The impact of tumor morcellation during surgery on the prognosis of patients with apparently early uterine leiomyosarcoma. *Gynecol Oncol* 2011;122(2):255-259.
- (7) <http://www.nvog.nl/vakinformatie/Pati%C3%ABntveiligheid/Complicatie/registratie/default.aspx>. Accessed 8 August 2016.
- (8) Krizova A, Clarke BA, Bernardini MQ, James S, Kalloger SE, Boerner SL et al. Histologic artifacts in abdominal, vaginal, laparoscopic, and robotic hysterectomy specimens: a blinded, retrospective review. *Am J Surg Pathol* 2011;35(1):115-126.
- (9) Aarts JW, Nieboer TE, Johnson N, Tavender E, Garry R, Mol BW et al. Surgical approach to hysterectomy for benign gynaecological disease. *Cochrane Database Syst Rev* 2015;8:CD003677.
- (10) Cohen SL, Einarsson JI, Wang KC, Brown D, Boruta D, Scheib SA et al. Contained power morcellation within an insufflated isolation bag. *Obstet Gynecol* 2014;124(3):491-497.
- (11) Einarsson JI, Cohen SL, Fuchs N, Wang KC. In-bag morcellation. *J Minim Invasive Gynecol* 2014;21(5): 951-953.
- (12) Vargas MV, Cohen SL, Fuchs-Weizman N, Wang KC, Manoucheri E, Vitonis AF et al. Open power morcellation versus contained power morcellation within an insufflated isolation bag: comparison of perioperative outcomes. *J Minim Invasive Gynecol* 2015;22(3):433-438.
- (13) Srouji SS, Kaser DJ, Gargiulo AR. Techniques for contained morcellation in gynecologic surgery. *Fertil Steril* 2015;103(4):e34.
- (14) Solima E, Scagnelli G, Austoni V, Natale A, Bertulesi C, Busacca M et al. Vaginal Uterine Morcellation Within a Specimen Containment System: A Study of Bag Integrity. *J Minim Invasive Gynecol* 2015; 22(7):1244-1246.
- (15) Winner B, Porter A, Vellozo S, Biest S. Uncontained Compared With Contained Power Morcellation in Total Laparoscopic Hysterectomy. *Obstet Gynecol* 2015;126(4):834-838.
- (16) Cohen SL, Greenberg JA, Wang KC, Srouji SS, Gargiulo AR, Pozner CN et al. Risk of leakage and tissue dissemination with various contained tissue extraction (CTE) techniques: an in vitro pilot study. *J Minim Invasive Gynecol* 2014;21(5):935-939.
- (17) Pritts EA, Vanness DJ, Berek JS, Parker W, Feinberg R, Feinberg J et al. The prevalence of occult leiomyosarcoma at surgery for presumed uterine fibroids: a meta-analysis. *Gynecol Surg* 2015;12(3):165-177.
- (18) Parker WH, Pritts EA, Olive DL. What is the Future of Open Intraperitoneal Power-Morcellation of Fibroids? *Clin Obstet Gynecol* 2016;59:73-84.
- (19) Lianidou ES, Strati A, Markou A. Circulating tumor cells as promising novel biomarkers in solid cancers. *Crit Rev Clin Lab Sci* 2014;51(3):160-171.

- (20) Lim S, Kim HS, Lee KB, Yoo CW, Park SY, Seo SS. Does the use of a uterine manipulator with an intrauterine balloon in total laparoscopic hysterectomy facilitate tumor cell spillage into the peritoneal cavity in patients with endometrial cancer? *Int J Gynecol Cancer* 2008;18(5):1145-1149.
- (21) Suh DH, Kim TH, Kim JW, Kim SY, Kim HS, Lee TS et al. Improvements to the FIGO staging for ovarian cancer: reconsideration of lymphatic spread and intraoperative tumor rupture. *J Gynecol Oncol* 2013; 24(4):352-358.
- (22) Kim HS, Ahn JH, Chung HH, Kim JW, Park NH, Song YS et al. Impact of intraoperative rupture of the ovarian capsule on prognosis in patients with early-stage epithelial ovarian cancer: a meta-analysis. *Eur J Surg Oncol* 2013;39(3):279-289.
- (23) Trimbos JB, Hacker NF. The case against aspirating ovarian cysts. *Cancer* 1993;72(3):828-831.
- (24) Van der Meulen JF, Pijnenborg J, Boomsma CM, Verberg M, Geomini P, Bongers MY. Parasitic myoma after laparoscopic morcellation: a systematic review of the literature. *BJOG* 2016;123(1):69-75.
- (25) Wright JD, Tergas AI, Cui R, Burke WM, Hou JY, Ananth CV et al. Use of Electric Power Morcellation and Prevalence of Underlying Cancer in Women Who Undergo Myomectomy. *JAMA Oncol* 2015;1(1):69-77.

