



Universiteit
Leiden
The Netherlands

Reconstructive techniques in musculoskeletal tumor surgery : management of pelvic and extremity bone tumors

Bus, M.P.A.

Citation

Bus, M. P. A. (2018, April 12). *Reconstructive techniques in musculoskeletal tumor surgery : management of pelvic and extremity bone tumors*. Retrieved from <https://hdl.handle.net/1887/61174>

Version: Not Applicable (or Unknown)

License: [Licence agreement concerning inclusion of doctoral thesis in the Institutional Repository of the University of Leiden](#)

Downloaded from: <https://hdl.handle.net/1887/61174>

Note: To cite this publication please use the final published version (if applicable).

Cover Page



Universiteit Leiden



The handle <http://hdl.handle.net/1887/61174> holds various files of this Leiden University dissertation.

Author: Bus, M.P.A.

Title: Reconstructive techniques in musculoskeletal tumor surgery : management of pelvic and extremity bone tumors

Issue Date: 2018-04-12

Chapter 9

What Are the Long-term Results of MUTARS® Modular Endoprotheses for Reconstruction of Tumor Resection of the Distal Femur and Proximal Tibia?

M.P.A. Bus¹

M.A.J. van de Sande¹

M. Fiocco^{2,3}

G.R. Schaap⁴

J.A.M. Bramer⁴

P.D.S. Dijkstra¹

¹Orthopaedic Surgery, Leiden University Medical Center, Leiden, the Netherlands

²Medical Statistics and Bioinformatics, Leiden University Medical Center, Leiden, the Netherlands

³Mathematical Institute, Leiden University, Leiden, The Netherlands

⁴Orthopaedic Surgery, Academic Medical Center, Amsterdam, the Netherlands

Clin Orthop Relat Res. 2017 Mar; 475(3): 708–718.

Abstract

Background: Modular endoprostheses are commonly used to reconstruct defects of the distal femur and proximal tibia after bone tumor resection. Because limb salvage surgery for bone sarcomas is relatively new, becoming more frequently used since the 1980s, studies focusing on the long-term results of such prostheses in treatment of primary tumors are scarce.

Questions / purposes: (1) What proportion of patients experience a mechanical complication with the MUTARS modular endoprosthesis when used for tumor reconstruction around the knee, and what factors may be associated with mechanical failure? (2) What are the non-mechanical complications? (3) What are the implant failure rates at five, ten, and 15 years? (4) How often is limb salvage achieved using this prosthesis?

Methods: Between 1995 and 2010, endoprostheses were the preferred method of reconstruction after resection of the knee in adolescents and adults in our centers. During that period, we performed 114 MUTARS knee replacements in 105 patients; no other endoprosthetic systems were used. Four patients (four of 105 [4%]) were lost to follow-up, leaving 110 reconstructions in 101 patients for review. The reverse Kaplan-Meier method was used to calculate median follow-up, which was equal to 8.9 years (95% confidence interval [CI], 8.0 – 9.7). Mean age at surgery was 36 years (range, 13 – 82 years). Predominant diagnoses were osteosarcoma ($n = 56$ [55%]), leiomyosarcoma of bone ($n = 10$ [10%]), and chondrosarcoma ($n = 9$ [9%]). In the early period of our study, we routinely used uncemented uncoated implants for primary reconstructions. Later, hydroxyapatite (HA)-coated implants were the standard. Eighty-nine reconstructions (89 of 110 [81%]) were distal femoral replacements (78 uncemented [78 of 89 {88%}], 42 of which were HA-coated [42 of 78, 54%]) and 21 (21 of 110 [19%]) were proximal tibial replacements. In 26 reconstructions (26 of 110 [24%]), the reconstruction was performed for a failed previous reconstruction. We used a competing risk model to estimate the cumulative incidence of implant failure.

Results: Complications of soft tissue or instability occurred in seven reconstructions (seven of 110 [6%]). With the numbers we had, for uncemented distal femoral replacements, we could not detect a difference in loosening between revision

(five of 17 [29%]) and primary reconstructions (eight of 61 [13%]) (hazard ratio [HR], 1.72; 95% CI, 0.55 – 5.38; $p = 0.354$). Hydroxyapatite-coated uncemented implants had a lower risk of loosening (two of 42 [5%]) than uncoated uncemented implants (11 of 36 [31%]) (HR, 0.23; 95% CI, 0.05 – 1.06; $p = 0.060$). Structural complications occurred in 15 reconstructions (15 of 110 [14%]). Infections occurred in 14 reconstructions (14 of 110 [13%]). Ten patients had a local recurrence (10 of 101 [10%]). With failure for mechanical reasons as the endpoint, the cumulative incidences of implant failure at five, ten, and 15 years were 16.9% (95% CI, 9.6 – 24.2), 20.7% (95% CI, 12.5 – 28.8%), and 37.9% (95% CI, 16.1 – 59.7), respectively. We were able to salvage some of the failures so that at follow-up, 90 patients (90 of 101 [89%]) had a MUTARS *in situ*.

Conclusions: Although no system has yet proved ideal to restore normal function and demonstrate long-term retention of the implant, MUTARS modular endoprotheses represent a reliable long-term option for knee replacement after tumor resection, which seems to be comparable to other modular implants available to surgeons. Although the number of patients is relatively small, we could demonstrate that with this prosthesis, an uncemented HA-coated implant is useful in achieving durable fixation.

Introduction

Various techniques have been described for management of reconstruction of malignant tumors about the knee in adults, including implantation of osteoarticular allografts^{1,2}, allograft-prosthetic composites^{3,4} and custom-made^{5,6} or modular^{7,8} endoprostheses. Endoprosthetic reconstruction likely is the most commonly used approach, in part as a result of the ease of use compared with other options and the difficulty of obtaining allografts in some centers in addition to the reported risks of nonunion, fracture, and infection^{5,6,9}. Potential advantages of endoprostheses include their relative availability, immediate stability, the possibility of rapid recovery, and early weight-bearing⁶. Compared with custom-made implants, modular endoprostheses provide the ability to adjust the proper length at the time of the reconstruction¹⁰.

Nevertheless, revisions of endoprosthetic reconstructions occur frequently. Infection, occurring in 6% to 20% of patients, is the leading cause of failure in the early years after surgery^{5,6,8,11-14}. In the longer term, mechanical complications are the main concern, most notably aseptic loosening, periprosthetic fractures, and wear^{7,15,16}. Because the survival of patients with bone sarcomas has improved, and most patients with primary bone tumors are young and active and place high demands on their implants, improving implant designs and reconstructive techniques are essential to reduce the risk of mechanical complications⁶. The MUTARS system (Modular Universal Tumor And Revision System; implantcast, Buxtehude, Germany; FDA approval pending) was introduced in 1992 and has since been widely used in Europe, Australia, and various Asian countries; results of its use in both orthopaedic oncology and revision surgery have been documented^{7,17,18}. To our knowledge, no studies have evaluated the intermediate- to long-term results of the MUTARS knee replacement system in primary tumor reconstructions and revision procedures.

We therefore asked: (1) What proportion of patients experience a mechanical complication with the MUTARS modular endoprosthesis when used for tumor reconstruction around the knee, and what factors may be associated with mechanical failure? (2) What are the non-mechanical complications? (3) What is the cumulative incidence of implant failure at five, ten, and 15 years? (4) How often is limb salvage achieved using this prosthesis?

Patients and Methods

We present a retrospective case series of all patients with a primary malignant or aggressive benign bone or soft tissue tumor in whom a MUTARS distal femoral or proximal tibial replacement was performed for primary reconstruction or for revision of a failed previous reconstruction. Institutional databases were searched to identify patients who had MUTARS reconstruction between 1995 and 2010 with a minimum follow-up of five years. During the early period under study, we performed a limited number of osteoarticular allograft reconstructions, mainly in young patients. In case it was possible to save adjacent joints, we preferred to perform an intercalary resection and reconstructed the defect with an allograft^{9, 19}. Generally speaking, endoprosthetic reconstruction was the preferred method of reconstruction when resection of the knee was deemed inevitable in adolescents and adults. No other endoprosthetic systems have been used in our centers. We performed a total of 114 MUTARS reconstructions about the knee during the period in question in 105 patients. Four patients (four of 105 [4%]) were lost to follow-up, leaving 110 reconstructions in 101 patients for review; of these, 64 (64 of 101 [63%]) were alive at final review. The reverse Kaplan-Meier method was used to calculate the median follow-up, which was equal to 8.9 years (95% confidence interval [CI], 8.0 – 9.7) (table 1).

Table 1. Study data

Variable	Number	Percent of relevant group
<i>Sex</i>		
Male	55	55
Female	46	45
<i>Diagnosis</i>		
Osteosarcoma	56	55
Leiomyosarcoma of bone	10	10
Chondrosarcoma	9	9
Giant cell tumor of bone	8	8
Pleomorphic undifferentiated sarcoma	7	7
Ewing sarcoma	5	5
Low-grade osteosarcoma	2	2
Sarcoma not otherwise specified	2	2
Synovial sarcoma	1	1
Diffuse-type giant cell tumor	1	1

Table 1. continued

Variable	Number	Percent of relevant group
<i>Reconstruction site</i>		
Distal femur	89	81
Proximal tibia	21	19
<i>Neoadjuvant and adjuvant therapies (around implantation of MUTARS)</i>		
Neoadjuvant chemotherapy	61	60
Adjuvant chemotherapy	64	63
Neoadjuvant radiotherapy	2	2
Adjuvant radiotherapy	4	4
<i>Reconstruction details</i>		
Conventional polyethylene locking mechanism	39	35
PEEK-OPTIMA locking mechanism	71	65
Extensor reconstruction	19	17
MUTARS attachment tube used	16	15
<i>Complications</i>		
Type I (soft tissue, instability)	7	6
Type II (aseptic loosening)	17	16
Type III (structural)	15	14
Type IV (infection)	14	13
Type V (tumor progression)	10	10
<i>Failure</i>		
Any type of revision, including re-fixation	40	36
Major revision / removal entire prosthesis	27	25
<i>Status at final follow-up</i>		
No evidence of disease	64	63
Alive with disease	-	-
Died of disease	34	34
Died of other cause	3	3

All diagnoses were proven histologically before operation. The feasibility of limb-salvaging resection was evaluated on MRI. In the case of suspected joint involvement, an extra-articular resection was performed removing the joint *en bloc* with the patella cut in the coronal plane. Of 84 implants (84 of 110 [76%]) that were implanted for primary reconstruction after tumor resection, 39 (46%) had an extra-articular resection. Twenty-six implants (26 of 110 [24%]) were implanted as a revision of a failed reconstruction, including nine MUTARS and 17 other reconstructions (table 2).

A lateral or medial parapatellar approach was used; this depended on the location of the tumor and biopsy tract, which was excised in continuity with the

tumor. In all cases, we used a rotating hinged MUTARS distal femoral or proximal tibial replacement. A polyethylene locking mechanism connected the femoral and tibial components. Until March 2003, we used the conventional polyethylene lock. From then onward, the PEEK-OPTIMA (Invibio Ltd, Thornton-Cleveleys, UK) lock was used. Extension of the implant was possible in 20-mm increments. All stems and extension pieces were equipped with sawteeth at the junctions to allow rotational adjustment in 5° increments. The hexagonally shaped stems were available for uncemented (TiAl6V4) or cemented (CoCrMo) fixation. Femoral stems were curved to match the natural anterior curvature of the femoral diaphysis. We generally preferred uncemented fixation, unless we were unable to obtain adequate press-fitting or in cases in which bone quality was deemed insufficient for uncemented fixation. In the early period under study, we routinely used uncemented uncoated implants because at that time, the MUTARS system did not come with hydroxyapatite (HA)-coated stems standardly; HA-coated stems were mainly used in cases with a presumed higher risk of loosening such as patients with a failed previous reconstruction. Later, HA-coated implants were the standard for primary reconstruction. The medullary cavity was reamed with a hexagonal rasp to secure optimal contact between the bone and implant. In case of uncemented fixation, the medullary cavity was under-reamed by 1 mm. In case of cemented fixation, we over-reamed the canal for 2 mm and third-generation cementing techniques were used.

Table 2. Procedures performed before implantation of the primary MUTARS, subsequent reconstructions, and reasons for failure.

Procedure	Reconstruction	Number	Reason(s) for reconstruction failure
<i>En bloc</i> resection	Allograft prosthetic composite	6	Allograft collapse (n = 2), allograft fracture (n = 2), nonunion (n = 1), infection (n = 1)
	Kotz prosthesis	4	Prosthetic fracture (n = 2), loosening (n = 1), infection (n = 1)
	Intercalary allograft	3	Nonunion (n = 2), allograft fracture (n = 1)
	Osteoarticular allograft	2	Allograft fracture
	Extracorporeally radiated autograft	1	Resorption
	Inlay allograft	1	Recurrence
Curettage	Cancellous bone grafting	5	Recurrence
	Cement	3	Recurrence
Arthroplasty	TKA	1	-

In cases in which an extensor mechanism reconstruction had to be performed, we ran non-absorbable sutures through the designated holes in the tibial component to fix an attachment tube (implantcast) to the implant; the extensor mechanism was later attached to the tube, again using non-absorbable sutures. After assemblage of the prosthesis, a trial reduction was performed. A final check was performed to assess knee motion and soft tissue tension and subsequently, the implant was locked.

All patients received prophylactic intravenous cephalosporins before surgery; these were continued for one to five days. Drains were removed after a maximum of 48 hours. Based on pain, patients were mobilized under supervision of a physical therapist, usually on the first postoperative day. Antithrombotic prophylaxis was given until 6 weeks postoperatively.

Patients were followed during outpatient visits at two and six weeks after discharge, after three and six months, and every six months thereafter. Radiographic follow-up consisted of conventional radiographs and additional imaging (CT/ MRI) if complications or recurrence were suspected.

Complications and failures were recorded and classified according to Henderson *et al*^{15, 20}. Aseptic loosening was defined as migration of the prosthesis on imaging (periprosthetic lucency on conventional radiographs or CT scan or halo formation on CT) in the absence of infection. We however chose to report on the clinical rather than radiological loosening, i.e., those that required revision, partly because it can be hard to determine which cases are at risk for future failure/ loosening, and it is therefore difficult to reliably comment on the occurrence and significance of these signs. Radiographic signs alone were not observed as a reason for implant failure. Rates of aseptic loosening were compared between primary and revision reconstructions (arthroscopy, curettage, and conventional TKA were not considered as previous reconstructions). Periprosthetic and prosthetic fractures were diagnosed on imaging or intraoperatively. Infection was defined as any deep (periprosthetic) infectious process diagnosed through physical examination, imaging, laboratory tests (including C-reactive protein, erythrocyte sedimentation rate, and synovial fluid leukocyte count) and microbiologic cultures.

Statistical Analysis

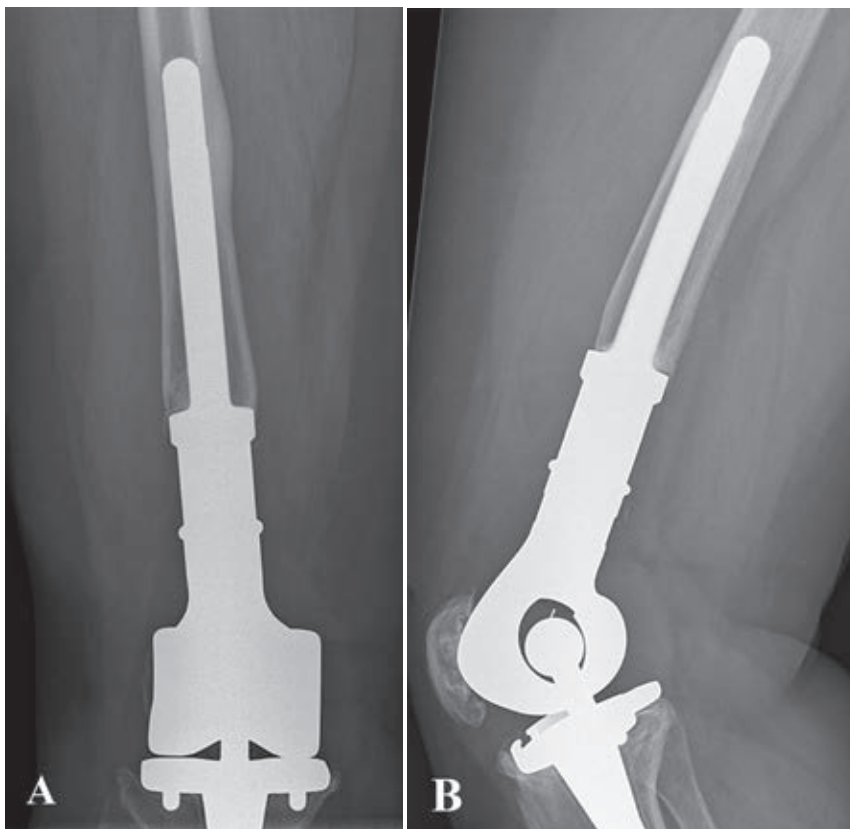
All data were complete. To estimate the cumulative incidence of revision for different types of failure, a competing risks model was used with patient mortality as a competing event^{21, 22}. Failures were defined as removal of part of or all of the

implant, major revision (exchange of the femoral component, tibial component, or the locking mechanism), or cemented re-fixation as the endpoint. Failure did not include isolated revision of the bushing. The influence of potential risk factors on the cumulative incidence of revision was determined with Cox regression analyses. SPSS 21.0 (IBM Corp, Armonk, NY, USA) was used for statistical analysis (level of significance, $p < 0.050$). All analyses for the competing risk models have been performed with the mstate library²³ in the R software package²⁴.

Mean age at surgery was 36 years (range, 13 – 82 years). Predominant diagnoses were osteosarcoma ($n = 56$ [55%]), leiomyosarcoma of bone ($n = 10$ [10%]), chondrosarcoma ($n = 9$ [9%]), giant cell tumor of bone ($n = 8$ [8%]), and pleomorphic undifferentiated sarcoma ($n = 7$ [7%]). Sixty-four patients (64 of 101 [63%]) were treated with chemotherapy (according to appropriate protocols) around the period of MUTARS implantation and four (four of 101 [4%]) underwent radiotherapy.

Eighty-nine reconstructions (81%) were distal femoral replacements and 21 (19%) were proximal tibial replacements. Eleven distal femoral replacements (11 of 89 [12%]) had a cemented femoral stem. Of 78 uncemented distal femoral replacements (78 of 89 [88%]), 42 were HA-coated (42 of 78 [54%]). All proximal tibial replacements had an uncemented tibial stem, 12 of which were HA-coated (12 of 19 [57%]) (figures 1A–B); one (one of 21 [5%]) had a cemented femoral stem. Patellar components were used in 37 distal femoral replacements (37 of 89 [42%]) and in three proximal tibial replacements (three of 21 [14%]). Median total resection length was 16 cm (range, 12 – 30 cm) for distal femoral replacements and 14 cm (range, 12 – 26 cm) for proximal tibial replacements. Attachment tubes were used in 14 proximal tibial replacements (14 of 21 [67%]) and in two distal femoral replacements (two of 89 [2%]). An extensor reconstruction was performed in 11 proximal tibial replacements (11 of 21 [58%]) and six distal femoral replacements (six of 89 [7%]). Rotation of a gastrocnemius muscle flap was performed in four proximal tibial replacements (four of 21 [19%], in one case combined with a split skin graft). Allogeneic fascia lata were used in six distal femoral replacements (six of 89 [7%]) and in two proximal tibial replacements (two of 21 [10%]). Three implants (three of 110 [3%]) were silver-coated.

During tumor resection, clear surgical margins were obtained in 95 patients (95 of 101 [94%]). Two patients (two of 101 [2%]) with giant cell tumors had intentional intralesional surgery. Four patients (four of 101 [5%]) had contaminated margins.



Figures 1A-B. Conventional AP (A) and lateral (B) radiographs taken 6 years after extra-articular resection for an osteosarcoma of the distal femur in a 46-year-old female patient. The defect was reconstructed with an uncemented HA-coated MUTARS distal femoral replacement with a PEEK-OPTIMA locking mechanism. The postoperative course was uncomplicated and no further procedures were undertaken.

Results

Mechanical Complications

Complications of soft tissue or instability (Henderson type 1) occurred in seven reconstructions (seven of 110 [6%], six distal femoral replacements, one proximal tibial replacement) after a median of five months (range, 0 – 46 months). These complications included skin necrosis ($n = 2$ [two of 110, 2%]), flexion contracture ($n = 2$ [two of 110, 2%]), and patellar dislocation ($n = 1$ [one of 110, 1%]).

One patient underwent surgery for extensor mechanism insufficiency ($n = 1$ [one of 110, 1%]). We could not identify factors associated with the occurrence of

type 1 complications. No type 1 complication resulted in removal or revision of the prosthesis.

Aseptic loosening (Henderson type 2) occurred in 15 distal femoral replacements (15 of 89 [17%]) and two proximal tibial replacements (two of 21 [10%]) after a median of 1.2 years (range, 0.5 – 15 years). Both proximal tibial replacements had loosening of the femoral component (both uncemented, one HA-coated), for which cemented re-fixation was undertaken. Of the 15 distal femoral replacements, nine had loosening of the femoral component, three of the tibial component, and three of both components. Treatment consisted of cemented re-fixation ($n = 6$), uncemented revision of the femoral component ($n = 4$), cemented revision ($n = 4$), and a total femoral replacement (as a result of poor remnant host bone) ($n = 1$). With the numbers we had, for uncemented distal femoral replacements, we could not detect an association between reconstruction length and the rate of loosening (hazard ratio [HR], 1.06; 95% CI, 0.93 – 1.21; $p = 0.393$) nor a difference in loosening between revision (five of 17 [29%]) and primary reconstructions (eight of 61 [13%]) (HR, 1.72; 95% CI, 0.55 – 5.38; $p = 0.354$). Uncemented HA-coated distal femoral replacements had a lower risk of loosening (two of 42 [5%]) than uncemented uncoated implants (11 of 36 [31%]) (HR, 0.23; 95% CI, 0.05 – 1.06; $p = 0.060$) (figure 2).

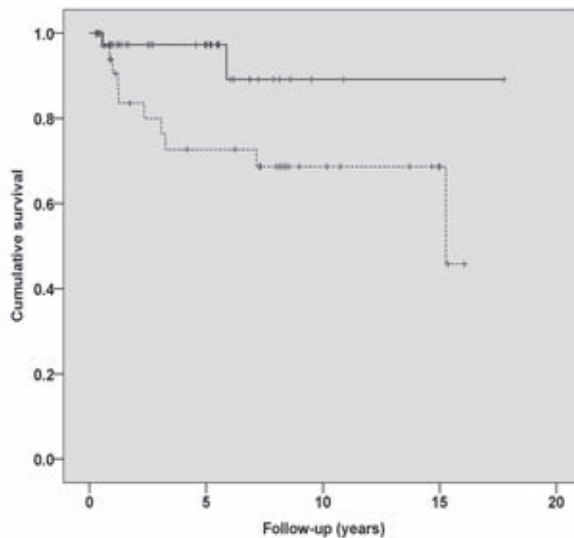


Figure 2. Kaplan-Meier curve showing survival to the occurrence of loosening for uncemented uncoated (blue line, $n = 36$) and uncemented HA-coated (green line, $n = 42$) distal femoral replacements.

Structural complications (Henderson type 3) occurred in 15 reconstructions (15 of 110 [14%]) after a mean of three years (range, 0.0 – 13.5 years). These included six complications of the locking mechanism: three fractures, two instances of wear, and one unlocking of the locking mechanism. Four occurred in PEEK-OPTIMA locks. There were four periprosthetic fractures occurring at three weeks, eight months, 20 months, and six years, respectively. There were three fractures of the femoral component, two with a 12-mm core diameter and a defect of 17.5 and 21.5 cm and one with a 16-mm core diameter stem with a defect of 15.5 cm. These stem fractures occurred two, four, and four years, respectively. There was one fractured insert and one implant rotation deformity.

Two prosthetic fractures and one periprosthetic fracture resulted in revision or removal of the entire implant; others were managed either conservatively or with limited revision procedures such as fixation of the periprosthetic fracture with a small plate, relocking of the locking mechanism, or revision of the locking mechanism. In addition, undisplaced fissure fractures occurred during implantation in 11 reconstructions: nine distal femoral replacements and two proximal tibial replacements. All healed uneventfully. Replacement of the bushings was performed in nine reconstructions (nine of 110 [8%]) after a mean of six years (range, 0.1 – 18 years).

Non-mechanical Complications

Deep infections (Henderson type 4) occurred in 15 reconstructions (15 of 110 [14%]). According to the Henderson classification, nine infections were early (<2 years after implantation [nine of 110, 8%]) and six were late (six of 110 [5%]). Three early-infected implants were retained. Three late infections occurred after operative intervention for another complication; of these, two were retained.

Local recurrences (Henderson type 5) occurred in ten patients (ten of 101 [10%]) after a mean of two years (range, 0.8 – 6 years). All patients who developed a local recurrence had clear surgical margins during the index resection. Two patients had received radiotherapy (one leiomyosarcoma, one high-grade osteosarcoma of an unusual subtype). Treatment consisted of ablative surgery in seven patients and of a second limb-salvaging resection (without removing the implant) in two. In one patient no further treatment was undertaken as a result of a poor prognosis. Focusing on patients without prior resections, local recurrences occurred in five of 39 patients with an extra-articular resection (13%) and in four of 45 patients with an intra-articular resection (9%) ($p = 0.561$).

Implant Failure Rates

With failure for mechanical reasons (types 1 – 3) as the endpoint, the cumulative incidences of implant failure at five, ten, and 15 years were 16.9% (95% CI, 9.6 – 24.2), 20.7% (95% CI, 12.5 – 28.8), and 37.9% (95% CI, 16.1 – 59.7), respectively (figure 3). With failure for infection (type 4) as the endpoint, these were 7.9% (95% CI, 2.7 – 13.2), 10.0% (95% CI, 3.5 – 16.4), and 10.0% (95% CI, 3.5 – 16.4), respectively. With failure from tumor progression (type 5) as the endpoint, these were 5.0% (95% CI, 0.7 – 9.2), 6.2% (95% CI, 1.4 – 11.0), and 6.2% (95% CI, 1.4 – 11.0), respectively. None of the assessed variables (extra-articular resection, HA coating of uncemented implants, reconstruction length of > 16 cm, adjuvant therapy, or having a preceding reconstruction) was found to have been associated with differences in implant survival in univariable Cox regression analyses.

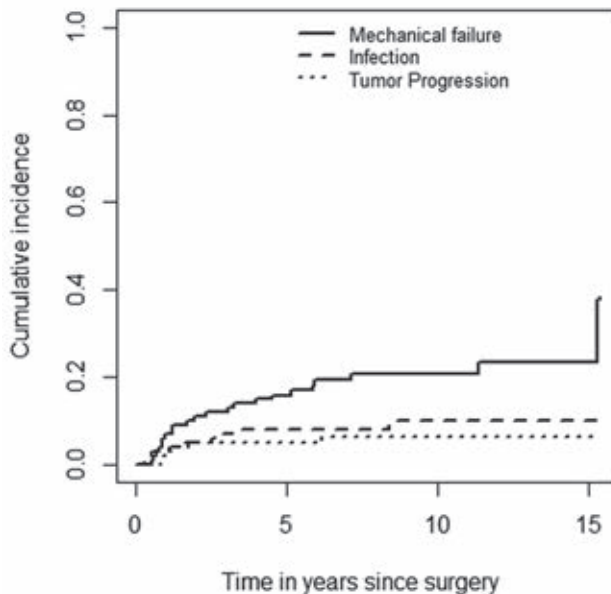


Figure 3. Competing-risk analyses of implant failure. This plot shows the cumulative incidence of mechanical failure (type 1 – 3), infection (type 4), and tumor progression (type 5). Patient mortality was used as a competing event in these analyses.

Limb Salvage

Limb salvage was achieved in 91 patients (90%). In total, 64 of 101 patients had their original MUTARS *in situ* without re-fixation, partial revision, or major revision/removal of the implant. Not all failures required a second MUTARS because

some cases of failure were managed while the same implant was in place (for example the cases of loosening that were managed with cemented re-fixation of the implant or failure of the locking mechanism, which was managed with revision of the polyethylene lock). In all, 55 patients (55 of 101 [55%]) required a total of 141 further surgical procedures: 78 (78 of 141 [55%]) for infection and 42 (42 of 141 [30%]) for mechanical reasons. At review, 90 patients (90 of 101 [89%]) had a MUTARS *in situ*. Above-knee amputations were undertaken in seven patients (seven of 101 [7%]; five as a result of a local recurrence, two resulting from infection), rotationplasty in two (two of 101 [2%]; one as a result of local recurrence, one resulting from infection), total femoral replacement in one (one of 101 [1%], as a result of loosening and poor remnant host bone), and knee disarticulation in one (as a result of a periprosthetic fracture).

Discussion

Modular endoprotheses are frequently used to reconstruct skeletal and knee defects created by resecting a bone neoplasm from the distal femur or proximal tibia. However, they are associated with substantial complication rates on both the short and long term, most notably infection and aseptic loosening^{5, 6, 16}. We sought to evaluate the long-term results of knee arthroplasty with MUTARS modular endoprotheses in the treatment of primary tumors, emphasizing on mechanical complications.

Our study has a number of limitations. Preferably, one would report on proximal tibial and distal femoral replacements separately because they may differ in the types of complications by site. However, we were hampered by a limited number of patients and we therefore chose to report on knee arthroplasty as one group. We grouped patients who had a previous reconstruction together with those reconstructions done for a primary resection and these groups are disparate, which might have influenced our overall risk of loosening. However, we feel that the results as now presented best describe our clinical experiences with this implant system during the period under study. Moreover, as a result of the long retrospective period of our study, we were unable to obtain functional outcome scores and quality of life scores. We had no comparison groups so we are unable to determine if this endoprosthesis offers advantages or disadvantages compared with other prostheses or types of reconstruction.

All complications of soft tissue and instability (Henderson type 1) were managed without implant removal. Few studies specified the incidence of complications of soft tissue and instability; however, our results (6%) are comparable with those recently reported by others (7%–9%)^{8,25}. Pala *et al*⁸ noted that type 1 complications were more frequent in primary than in revision reconstructions (10% versus 4%). Although with the numbers we had we could not demonstrate an association between having a previous reconstruction or an extra-articular resection, it is plausible that soft tissue problems occur more often in previously operated sites and after more extensive resections as a result of scarring and restricted flexibility of surrounding soft tissues. The most common type 1 complication in a large study on KMFTR and HMRS knee replacements (Stryker, Newbury, UK) was patellar tendon rupture with an overall incidence of 5%¹⁴. We did not observe any patellar tendon ruptures. We attribute this to the use of the attachment tube. The tube allows for ingrowth of the extensor apparatus and apparently ensures reliable, long-lasting fixation²⁶.

Aseptic loosening (Henderson type 2) occurred in 12% of the primary reconstructions. This is comparable with most long-term follow-up studies (table 3). The high risk of loosening of megaprotheses around the knee has been ascribed to many factors, including the torque acting on the stems and the long lever arm associated with greater resection length^{25,27}. We could not demonstrate an influence of resection length in the current series. HA coating appeared to decrease the risk of loosening of uncemented distal femoral replacements. Pala *et al* reported a comparable rate (6%) for uncemented HA-coated GMRS prostheses (Stryker, Rutherford, NJ, USA), although their follow-up was substantially shorter (table 3). Satisfactory rates of loosening (0%–8%) have also been reported for cemented custom-made implants with HA collars (Stanmore Implants Worldwide, Elstree, UK)^{5,6,28}. Although loosening may occur as late as 25 years after cemented fixation^{5,6,16}, it is unlikely to occur after bony ingrowth of a HA-coated implant has taken place²⁹. A prerequisite for ingrowth is primary stability; relative motion of more than 150 μm between bone and stem is critical for adequate fixation³⁰. Blunn *et al*²⁹ reported on a series of uncemented tumor implants (Stanmore Implants Worldwide) and noted that subperiosteal cortical bone loss occurred at the mid-stem level. This process, however, stabilized, and none of their implants was revised as a result. We did not observe this as a reason for revision.

Like most modern tumor prostheses, the implants used in our study had a rotating hinge (table 3). Authors postulated that rotating hinges reduce the risk

of bushing wear and of loosening, the latter by reducing torsional stresses at the implant-bone interface^{5,7,8}. Myers *et al*⁶ reported a reduction in loosening rates after the introduction of rotating hinges, although it is unclear whether this reduction should be ascribed to the rotating hinge, the HA-coated collar, or a combination of both⁶. We are of the opinion that uncemented HA-coated implants with a rotating hinge offer the best possibility to achieve stable fixation and therefore durable results, although we cannot definitively support this contention from our results. Loosening appeared to be a particular problem in those implants that were used as a revision of a previously failed reconstruction. Foo *et al*³¹ discussed the difficulties encountered with the use of uncemented MUTARS prostheses after failed allograft reconstructions. We concur with their conclusion that cemented fixation is preferred in case of poor remnant bone quality as may be the case after allograft reconstruction or loosened endoprotheses.

Structural complications (Henderson type 3) occurred in 15%. Introduction of the PEEK-OPTIMA lock has not resulted in a reduction of long-term structural complication rates. Since 2010, we routinely use the MUTARS metal-on-metal locking mechanism because we believe this mechanism should be able to better withstand the high mechanical stresses. Our prosthetic fracture rate (3%) is comparable with the rate reported by Myers *et al* (2%)⁶ and compares favorably with other studies (5% – 7%)^{11, 12, 32}, whereas our follow-up is among the longest reported in the literature (table 3). All three fractured implants had a total resection length of ≥ 15.5 cm and two had 12-mm stems. Previously, Gosheger *et al*⁷ reported stem fractures in four MUTARS reconstructions, all with a stem diameter of 12 mm or less. We believe that careful reaming and implantation of the largest possible stem diameter are advisable to reduce the risk of stem fractures and recommend using stems of at least 12 mm.

Infection (Henderson type 4) occurred in 13% and resulted in removal of the implant in 9%, which is comparable with most previous studies (6% – 20%)^{5, 6, 8, 11, 12, 14}. We could not demonstrate a difference among early and late infections with regard to the possibility of implant retention. However, three late infections occurred after operative intervention for another complication; such infections may be treated as an acute infection as opposed to late-occurring low-grade infections. Currently, we routinely use silver-coated implants, which may reduce the risk of infection and increase the likelihood of being able to retain the implant in case it gets infected^{7, 27}. Others previously reported a reduction in the frequency of infection since the routine use of muscle flaps⁵.

Failure as a result of local recurrence (type 5 complication) occurred in 7%. Other long-term follow-up studies reported comparable rates (5%–6%)^{5, 6, 12, 33}. Kinkel *et al*¹³ noted that the rate of extra-articular resection was substantially higher in their population (40%) compared with other series (0% – 13%; table 3). With the numbers we had, we found no difference in relapse or complication risks between intra- and extra-articular resections. On the other hand, others reported that extra-articular resection is associated with an increased risk of infection and loosening^{7, 18}. One may therefore question whether the high rate of extra-articular resection (46% of the primary reconstructions in our study) is truly justified. Careful evaluation of joint involvement with use of modern imaging techniques (PET-CT, gadolinium-enhanced MRI) may aid to avoid unnecessary extra-articular resections.

As a result of the fact that nearly all studies have used Kaplan-Meier survival analyses to compute implant survival rates, and because different classifications and definitions of failures have been used, it is difficult to adequately compare implant failure rates. Nevertheless, our long-term cumulative incidence rates of failure appear to be comparable to those reported by others^{8, 25, 32} and compare favorably with others^{5, 6, 11, 13} (table 3).

Despite needing more operative procedures for complications, we were able to achieve limb salvage in 90% of our patients. The majority of our patients had a MUTARS (but not necessarily the original MUTARS implant) *in situ* at latest follow-up, indicating that most complications could be adequately managed.

Although no system has yet proved ideal to restore normal function and demonstrate long-term retention of the implant, MUTARS modular endoprostheses represent a reliable long-term option for knee replacement after tumor resection, which seems to be comparable to other modular implants available to surgeons. The cumulative incidence of implant failure was 20.7% at 10 years with mechanical failure as the endpoint. Aseptic loosening was the most important mechanical complication. HA coating of uncemented implants may reduce the risk of loosening, and we currently use uncemented HA-coated implants believing that it is optimal for durable fixation. We conclude that MUTARS represents a reliable system with long-term results comparable to other prostheses and types of reconstructions for tumor resections about the knee.

Note: we thank Prof A.H.M. Taminiau, emeritus professor at the Department of Orthopaedic Surgery of the Leiden University Medical Center, for operating on a substantial number of the patients included in this study.

Table 3. Overview of literature on knee replacement in bone tumor surgery.

Study	Number	Year of surgery	Implant type*	Follow-up (years)	Site (%)	Diagnoses (%)	Hinge type (%)	Fixation method (%)	Extra-articular resection (%)	Aseptic loosening	Implant survival / cumulative incidence of failure
Pala	247	2003-2010	GMRS (Stryker)	4 (2-8)	DF 76; PT 25	Prim. 98 Mets. 2	RH	Unc-HA coated 90; cem 9	-	6%	70 and 58% at 4 and 8 years (survival, all failure modes)
Myers	335	1973-2000	Custom (Stanmore)	Survivors: 12 (5-30) Deceased: N/R	DF	Prim. 94 Mets. 6	FH 48 RH 52	Unc-HA collar 4; cem-HA collar 43; cem 53	Rarely	FH: 35% at 10 years; RH: -	83%, 67%, and 51% at 5, 10, and 15 years, respectively (survival, as a result of aseptic loosening, fracture of the implant, infection, breakage, etc)
Myers	194	1977-2002	Custom (Stanmore)	Survivors: 14.7 (5-29) Deceased: N/R	PT	Prim. 94 Mets. 6%	FH 49 RH 51	Cem/ Cem-HA collar (N/R)	Rarely	FH: 46% at 10 years; RH 3%	79%, 58%, and 45% at 5, 10, and 15 years, respectively (survival, as a result of aseptic loosening, breakage, infection, etc)
Kinkel	77	1995-2005	MUTARS (implantcast)	3.8 (0.3-10.7)	DF 64; PT 36	Prim. 90 Mets. 10	RH	Unc 78; cem 22	40	17	57% at 5 years (survival, reasons N/R)
Griffin	99	1989-2000	KMFTR (Stryker)	Med. 6.1 (0.3-13.2)	DF 75; PT 25	Prim.	FH	Unc	13	2	N/R for overall population
Biau	91	1972-1994	Custom (Stryker)	Med. 5.2 (0.0-28.6)	DF 62; PT 38	Prim. 98 Mets. 2	FH	Cem	3	20	76%, 45%, and 29% at 5, 10, and 15 years, respectively (survival, revision for any reason)
Bickels	110	1990-1998	Modular 66%, custom 25%* (Howmedica)	Med. 7.8 (2-16.5)	DF	Prim. 98 Non-tum. 2	FH 7 RH 93	Cem	2	5	93% and 88% at 5 and 10 years, respectively, overall survival
Morgan	105	1985-2004	Modular (different manufacturers)	Med. 4.8 (0.1-19.6)	DF 72; PT 28	N/R	RH	Cem	-	17	73% and 59% at 5 and 10 years, respectively (survival, failure modes 1-4)

Plotz	60	1976-1996	Custom (different manufacturers)	4.9 (0.1-19.1)	DF 75; PT 25	Prim. 83 Mets. 17	N/R	Hybrid 5; unc-Pc 45; Cem 50	N/R	5	34% and 25% at 5 and 10 years, respectively (survival of the prostheses without revision surgery)
Ruggieri	669	1983-2006	KMFTR/HMRS (Stryker)	1.1 (2-25)	DF 71; PT 24; TF 3; EAK 1	Prim. 97 Mets. 3	FH	Unc 91; cem 9	1	6	80% and 55% at 10 and 20 years, respectively (survival, breakage, aseptic loosening, or infection)
Coathup	61	1992-2001	Custom (Stanmore)	8.5 (2-18)	DF	Prim.	RH	Cem-HA collar	N/R	8	75%, 84%, and 89% at 5, 10, and 15 years, respectively (survival, all failure modes)
Batta	69	1994-2006	Custom (Stanmore)	10.4 (0.3-17.7)	DF	Prim.	RH	Unc-HA collar	N/R	13	73%, 65%, and 55% at 5, 10, and 15 years, respectively (survival, all failure modes)
Schwartz	186	1980-2008	Custom 54%, GMRS 46% (different manufacturers)	8.0 (0.1-28.0)	DF	Prim. 98 Mets. 2	RH	Cem/ Cem-Pc collar (N/R)	N/R	12	77% at 10 years (survival, revision of stemmed components for all failure modes)
Current study	110	1995-2010	MUTARS (implantcast)	Overall: 7.2 (0.4-18.0) Survivors: 9.5 (5.0-18.0) Deceased: 3.1 (0.4-14.1)	DF 81; PT 19	Prim.	RH	Unc- uncoated 41; unc-HA coated 49; cem 10	46**	Primary rec. 12; overall 15	Cumulative incidence of failure for mechanical reasons (Types 1-3): 17%, 21%, and 38% at 5, 10, and 15 years. Further details can be found in results section.

* Implant type: GMRS = Global Modular Replacement System (Stryker, Rutherford, NJ, USA); Custom = custom-made, different manufacturers; MUTARS = Modular Universal Tumor and Revision System (Implantcast, Buxtehude, Germany); KMFTR = Kotz Modular Femur Tibia Reconstruction (Stryker, Rutherford, NJ, USA); Mod. = modular, different manufacturers; HMRS = Howmedica Modular Reconstruction System (Stryker, Rutherford, NJ, USA). Mean followup, unless otherwise stated (med. = median) with the range in parentheses; DF = distal femur, PT = proximal tibia, TF = total femur, EAK = extraarticular knee; prim. = primary tumor, mets. = metastatic disease, non-tum. = nontumorous; RH = rotating hinge, FH = fixed hinge; unc = uncemented, cem = cemented, Pc = porous-coated; ** of the patients in whom the MUTARS was implanted during primary surgery, N/R = not reported.

References

1. Muscolo DL, Ayerza MA, Farfalli G, Aponte-Tinao LA. Proximal tibia osteoarticular allografts in tumor limb salvage surgery. *Clinical orthopaedics and related research*. 2010 May;468(5):1396-404. Epub 2009/12/19.
2. Toy PC, White JR, Scarborough MT, Enneking WF, Gibbs CP. Distal femoral osteoarticular allografts: long-term survival, but frequent complications. *Clinical orthopaedics and related research*. 2010 Nov;468(11):2914-23. Epub 2010/07/21.
3. Donati D, Colangeli M, Colangeli S, Di Bella C, Mercuri M. Allograft-prosthetic composite in the proximal tibia after bone tumor resection. *Clinical orthopaedics and related research*. 2008 Feb;466(2):459-65. Epub 2008/01/16.
4. Mo S, Ding ZQ, Kang LQ, Zhai WL, Liu H. Modified technique using allograft-prosthetic composite in the distal femur after bone tumor resection. *The Journal of surgical research*. 2013 Jun 1;182(1):68-74. Epub 2012/09/11.
5. Myers GJ, Abudu AT, Carter SR, Tillman RM, Grimer RJ. The long-term results of endoprosthetic replacement of the proximal tibia for bone tumours. *The Journal of bone and joint surgery British volume*. 2007 Dec;89(12):1632-7. Epub 2007/12/07.
6. Myers GJ, Abudu AT, Carter SR, Tillman RM, Grimer RJ. Endoprosthetic replacement of the distal femur for bone tumours: long-term results. *The Journal of bone and joint surgery British volume*. 2007 Apr;89(4):521-6. Epub 2007/04/28.
7. Goshager G, Gebert C, Ahrens H, Streitbuerger A, Winkelmann W, Harnes J. Endoprosthetic reconstruction in 250 patients with sarcoma. *Clinical orthopaedics and related research*. 2006 Sep;450:164-71. Epub 2006/05/13.
8. Pala E, Trovarelli G, Calabro T, Angelini A, Abati CN, Ruggieri P. Survival of Modern Knee Tumor Megaprotheses: Failures, Functional Results, and a Comparative Statistical Analysis. *Clinical orthopaedics and related research*. 2014 May 30. Epub 2014/05/31.
9. Bus MP, Dijkstra PD, van de Sande MA, Taminiau AH, Schreuder HW, Jutte PC, et al. Intercalary allograft reconstructions following resection of primary bone tumors: a nationwide multicenter study. *The Journal of bone and joint surgery American volume*. 2014 Feb 19;96(4):e26. Epub 2014/02/21.
10. Chandrasekar CR, Grimer RJ, Carter SR, Tillman RM, Abudu A, Buckley L. Modular endoprosthetic replacement for tumours of the proximal femur. *The Journal of bone and joint surgery British volume*. 2009 Jan;91(1):108-12. Epub 2008/12/19.
11. Biau D, Faure F, Katsahian S, Jeanrot C, Tomeno B, Anract P. Survival of total knee replacement with a megaprosthesis after bone tumor resection. *The Journal of bone and joint surgery American volume*. 2006 Jun;88(6):1285-93. Epub 2006/06/08.
12. Griffin AM, Parsons JA, Davis AM, Bell RS, Wunder JS. Uncemented tumor endoprostheses at the knee: root causes of failure. *Clinical orthopaedics and related research*. 2005 Sep;438:71-9. Epub 2005/09/01.
13. Kinkel S, Lehner B, Kleinhans JA, Jakubowitz E, Ewerbeck V, Heisel C. Medium to long-term results after reconstruction of bone defects at the knee with tumor endoprostheses. *Journal of surgical oncology*. 2010 Feb 1;101(2):166-9. Epub 2009/11/20.
14. Ruggieri P, Mavrogenis AF, Pala E, Abdel-Mota'al M, Mercuri M. Long term results of fixed-hinge megaprotheses in limb salvage for malignancy. *The Knee*. 2012 Oct;19(5):543-9. Epub 2011/09/14.
15. Henderson ER, Groundland JS, Pala E, Dennis JA, Wooten R, Cheong D, et al. Failure mode classification for tumor endoprostheses: retrospective review of five institutions and a literature review. *The Journal of bone and joint surgery American volume*. 2011 Mar 2;93(5):418-29. Epub 2011/03/04.
16. Jeys LM, Kulkarni A, Grimer RJ, Carter SR, Tillman RM, Abudu A. Endoprosthetic reconstruction for the treatment of musculoskeletal tumors of the appendicular skeleton and pelvis. *The Journal of bone and joint surgery American volume*. 2008 Jun;90(6):1265-71. Epub 2008/06/04.
17. Gebert C, Wessling M, Gotze C, Goshager G, Harnes J. The Modular Universal Tumour And Revision System (MUTARS®) in endoprosthetic revision surgery. *International orthopaedics*. 2010 Dec;34(8):1261-5. Epub 2010/04/10.
18. Harnes J, Henrichs MP, Goshager G, Gebert C, Holl S, Dieckmann R, et al. Endoprosthetic replacement after extra-articular resection of bone and soft-tissue tumours around the knee. *The bone & joint journal*. 2013 Oct;95-b(10):1425-31. Epub 2013/10/01.

19. Bus MP, Bramer JA, Schaap GR, Schreuder HW, Jutte PC, van der Geest IC, et al. Hemicortical resection and inlay allograft reconstruction for primary bone tumors: a retrospective evaluation in the Netherlands and review of the literature. *The Journal of bone and joint surgery American volume*. 2015 May 6;97(9):738-50.
20. Henderson ER, O'Connor MI, Ruggieri P, Windhager R, Funovics PT, Gibbons CL, et al. Classification of failure of limb salvage after reconstructive surgery for bone tumours : a modified system Including biological and expandable reconstructions. *The bone & joint journal*. 2014 Nov;96-b(11):1436-40. Epub 2014/11/06.
21. Keurentjes JC, Fiocco M, Schreurs BW, Pijls BG, Nouta KA, Nelissen RG. Revision surgery is overestimated in hip replacement. *Bone & joint research*. 2012 Oct;1(10):258-62. Epub 2013/04/24.
22. Putter H, Fiocco M, Geskus RB. Tutorial in biostatistics: competing risks and multi-state models. *Statistics in medicine*. 2007 May 20;26(11):2389-430. Epub 2006/10/13.
23. de Wreede LC, Fiocco M, Putter H. The mstate package for estimation and prediction in non- and semi-parametric multi-state and competing risks models. *Computer methods and programs in biomedicine*. 2010 Sep;99(3):261-74. Epub 2010/03/17.
24. Team RC. R: A Language and Environment for Statistical Computing. 2008.
25. Batta V, Coathup MJ, Parratt MT, Pollock RC, Aston WJ, Cannon SR, et al. Uncemented, custom-made, hydroxyapatite-coated collared distal femoral endoprotheses: up to 18 years' follow-up. *The bone & joint journal*. 2014 Feb;96-B(2):263-9. Epub 2014/02/05.
26. Gosheger G, Hillmann A, Lindner N, Rodl R, Hoffmann C, Burger H, et al. Soft tissue reconstruction of megaprotheses using a trevira tube. *Clinical orthopaedics and related research*. 2001 Dec(393):264-71. Epub 2002/01/05.
27. Wafa H, Grimer RJ, Reddy K, Jeys L, Abudu A, Carter SR, et al. Retrospective evaluation of the incidence of early periprosthetic infection with silver-treated endoprotheses in high-risk patients: case-control study. *The bone & joint journal*. 2015 Feb;97-B(2):252-7. Epub 2015/01/30.
28. Coathup MJ, Batta V, Pollock RC, Aston WJ, Cannon SR, Skinner JA, et al. Long-term survival of cemented distal femoral endoprotheses with a hydroxyapatite-coated collar: a histological study and a radiographic follow-up. *The Journal of bone and joint surgery American volume*. 2013 Sep 4;95(17):1569-75. Epub 2013/09/06.
29. Blunn GW, Briggs TW, Cannon SR, Walker PS, Unwin PS, Culligan S, et al. Cementless fixation for primary segmental bone tumor endoprotheses. *Clinical orthopaedics and related research*. 2000 Mar(372):223-30. Epub 2000/03/30.
30. Kinkel S, Graage JD, Kretzer JP, Jakubowitz E, Nadorf J. Influence of stem design on the primary stability of megaprotheses of the proximal femur. *International orthopaedics*. 2013 Oct;37(10):1877-83. Epub 2013/08/21.
31. Foo LS, Harges J, Henrichs M, Ahrens H, Gosheger G, Streitburger A. Surgical difficulties encountered with use of modular endoprosthesis for limb preserving salvage of failed allograft reconstruction after malignant tumor resection. *The Journal of arthroplasty*. 2011 Aug;26(5):744-50. Epub 2010/08/10.
32. Morgan HD, Cizik AM, Leopold SS, Hawkins DS, Conrad EU, 3rd. Survival of tumor megaprotheses replacements about the knee. *Clinical orthopaedics and related research*. 2006 Sep;450:39-45. Epub 2006/08/15.
33. Bickels J, Wittig JC, Kollender Y, Henshaw RM, Kellar-Graney KL, Meller I, et al. Distal femur resection with endoprosthetic reconstruction: a long-term followup study. *Clinical orthopaedics and related research*. 2002 Jul(400):225-35. Epub 2002/06/20.

