



Universiteit
Leiden
The Netherlands

Reconstructive techniques in musculoskeletal tumor surgery : management of pelvic and extremity bone tumors

Bus, M.P.A.

Citation

Bus, M. P. A. (2018, April 12). *Reconstructive techniques in musculoskeletal tumor surgery : management of pelvic and extremity bone tumors*. Retrieved from <https://hdl.handle.net/1887/61174>

Version: Not Applicable (or Unknown)

License: [Licence agreement concerning inclusion of doctoral thesis in the Institutional Repository of the University of Leiden](#)

Downloaded from: <https://hdl.handle.net/1887/61174>

Note: To cite this publication please use the final published version (if applicable).

Cover Page



Universiteit Leiden



The handle <http://hdl.handle.net/1887/61174> holds various files of this Leiden University dissertation.

Author: Bus, M.P.A.

Title: Reconstructive techniques in musculoskeletal tumor surgery : management of pelvic and extremity bone tumors

Issue Date: 2018-04-12

Chapter 7

Is there still a role for osteoarticular allograft reconstruction in musculoskeletal tumor surgery?

*A long-term follow-up study of 38 patients and
systematic review of the literature*

M.P.A. Bus¹

M.A.J. van de Sande¹

A.H.M. Taminiau¹

P.D.S. Dijkstra¹

¹Orthopaedic Surgery, Leiden University Medical Center, Leiden, the Netherlands

Bone Joint J 2017;99-B:522–30

Abstract

Aims: To assess complications and failure mechanisms of osteoarticular allograft reconstructions for primary bone tumors.

Patients and Methods: We retrospectively evaluated 38 patients (28 men, 74%) who were treated at our institution with osteoarticular allograft reconstruction between 1989 and 2010. Median age was 19 years (interquartile range 14 to 32). Median follow-up was 19.5 years (95% confidence interval [CI] 13.0 to 26.1) when 26 patients (68%) were alive. In addition, we systematically searched the literature for clinical studies on osteoarticular allografts, finding 31 studies suitable for analysis. Results of papers that reported on one site exclusively were pooled for comparison.

Results: A total of 20 patients (53%) experienced graft failure, including 15 due to mechanical complications (39%) and three (9%) due to infection. In the systematic review, 514 reconstructions were analyzed (distal femur, n = 184, 36%; proximal tibia, n = 136, 26%; distal radius, n = 99, 19%; proximal humerus, n = 95, 18%). Overall rates of failure, fracture and infection were 27%, 20%, and 10% respectively. With the distal femur as the reference, fractures were more common in the humerus (odds ratio [OR] 4.1, 95% CI 2.2 to 7.7) and tibia (OR 2.2, 95% CI 1.3 to 4.4); infections occurred more often in the tibia (OR 2.2, 95% CI 1.3 to 4.4) and less often in the radius (OR 0.1, 95% CI 0.0 to 0.8).

Conclusion: Osteoarticular allograft reconstructions are associated with high rates of mechanical complications. Although comparative studies with alternative techniques are scarce, the risk of mechanical failure in our opinion does not justify routine employment of osteoarticular allografts for reconstruction of large joints after tumor resection.

Introduction

Primary malignant bone tumors commonly grow in close proximity to joints^{1,2}. Resection with clear margins is the mainstay of surgical treatment and therefore, it is often necessary to resect part of a joint^{3,4}. Endoprostheses are generally regarded as the benchmark after such resections^{5,6}. However, endoprosthetic joint arthroplasty requires the sacrifice of the corresponding reciprocal side of the joint. Moreover, recent studies describe considerable rates of failure of endoprosthetic reconstruction due to both mechanical (loosening, implant breakage, periprosthetic fractures) and non-mechanical (predominantly infection) complications⁶⁻⁸.

Osteoarticular allografts provide an alternative method of reconstruction to endoprostheses. Potential advantages of osteoarticular allografts include the possibility to re-attach tendons and to reconstruct unicondylar or hemi-articular defects^{9,10}. On the other hand, allografts have been associated with considerable rates of infection, fracture and nonunion^{3,11-14}. Reported overall complication rates typically range from 40% to 70%^{9,15-25}. Moreover, studies raised concern about the viability of cryopreserved cartilage and noted that osteoarthritis becomes a major problem approximately six years after transplantation^{26,27}. Nevertheless, functional outcome is generally acceptable, with mean Musculoskeletal Tumor Society (MSTS) scoring system scores²⁸ ranging from 70% to 91%^{9,16-18,23-25,29,30}.

To date, there are no studies on large groups of patients with osteoarticular allografts with long-term follow-up. Therefore, there is paucity of solid evidence concerning complications and long-term outcomes. We retrospectively evaluated our experiences with osteoarticular allografts in treatment of primary tumors and systematically reviewed the literature with the aims to assess: long-term complication rates, mechanisms of reconstruction failure, and allograft survival rates.

Patients and Methods

Retrospective study

We searched our institutional database to identify all patients who had an osteoarticular allograft reconstruction for a bone tumor between 1989 and 2012. A total of 38 consecutive patients (28 men, 74%) with a median age of 19 years



(interquartile range [IQR] 14 to 32) at surgery were included (table 1). A total of 33 patients (87%) had a malignant tumor (predominantly osteosarcoma, $n = 20$, 53%), five patients (13%) were treated for a benign but aggressive lesion, mostly giant cell tumors of bone ($n = 4$, 11%). A further 26 patients (68%) were treated with chemotherapy according to appropriate protocols, two (5%) underwent radiotherapy.

Allografts were harvested during post-mortem tissue donation by our national bone bank. Proximal humeral grafts included tendons of the rotator cuff, pectoralis major and latissimus dorsi; allografts of the proximal femur had the tendons of the glutei and iliopsoas attached. Distal femoral and proximal tibial grafts included the knee capsule and all surrounding ligaments. Following retrieval, articular cartilage was covered with gauze soaked in dimethylsulphoxide³¹ and allografts were stored at -80°C ³². Processing of the allografts was performed at either Osteotech (Eatontown, New Jersey) or the Musculoskeletal Transplant Foundation (Edison, New Jersey). Grafts were either not subjected to additional sterilization or irradiated with low-dose gamma radiation (< 25 kGy).

All patients had a biopsy pre-operatively to obtain a histological diagnosis. Resections were planned on conventional radiographs, CT and/or MRI. All patients received prophylactic cephalosporins pre-operatively. During tumor resection, the allograft was thawed in saline with gentamicin and flucloxacillin. Following resection, the graft was cut to fit the resected defect freehand, and appropriate structures were prepared to attach corresponding host structures. All osteotomies were fashioned transversely. Muscle flap rotations ($n = 9$, 23%) were only used where there was poor soft-tissue coverage.

Follow-up routinely included conventional radiographs but if a recurrence was suspected an MRI scan was obtained. Medical files and radiographs of the reconstruction were evaluated to obtain details about patients, tumors, treatment, and reconstructions. Complications and failures were classified into types 1 to 5, according to Henderson *et al*^{33,34} (type 1, soft-tissue failure and instability; type 2, graft-host nonunion; type 3, structural failure; type 4, infection; and type 5, tumor progression). Nonunion was defined as surgical intervention to facilitate union of the allograft-host junction³. Fractures were diagnosed on imaging. If the allograft was removed (partially or completely), or if the reconstruction was converted to an allograft-prosthetic composite or arthrodesis, we considered the reconstruction to be a failure.

Table 1. Study data

Variable	n (%)
<i>Gender</i>	
Male	28 (74)
Female	10 (26)
<i>Diagnosis</i>	
Osteosarcoma (conventional type)	20 (53)
Giant cell tumor of bone	4 (11)
Ewing sarcoma	3 (8)
Chondrosarcoma grade 3	3 (8)
Chondrosarcoma grade 2	2 (5)
Parosteal osteosarcoma	2 (5)
Pleomorphic undifferentiated sarcoma	2 (5)
Low-grade osteosarcoma	1 (3)
Aneurysmal bone cyst	1 (3)
<i>Location</i>	
Proximal tibia	14 (37)
Proximal humerus	12 (32)
Distal femur	10 (26)
Distal radius	2 (5)
<i>Type of graft</i>	
Segmental	32 (84)
Hemicortical/unicondylar	6 (16)
<i>Osteosynthesis</i>	
Plate(s)	28 (74)
Intramedullary nail	8 (21)
Intramedullary nail and plate	1 (3)
Screws	1 (3)
<i>Graft length</i>	
< 10 cm	6 (16)
10 cm to 15 cm	14 (37)
> 15 cm	18 (47)
<i>Adjuvant therapy</i>	
Chemotherapy	26 (68)
Radiotherapy	2 (5)
<i>Failures</i>	
Mechanical reasons	15 (39)
Non-mechanical reasons	5 (13)
<i>Follow-up</i>	
≥ 5 yrs	28 (74)
≥ 10 yrs	24 (63)
≥ 20 yrs	12 (32)



Reconstructions were located in the proximal tibia (n = 14, 37%), proximal humerus (n = 12, 32%), distal femur (n = 10, 26%) and distal radius (n = 2, 5%). A total of 32 patients (84%) had a segmental, and six (16%) a unicondylar reconstruction (four proximal tibial, two distal femoral). Median allograft length was 14 cm (IQR 10 to 17), and was greater for the proximal humerus (16.5 cm, IQR 13 to 19.5) than for other sites (12 cm, IQR 10 to 17). Allografts were fixed to host bone using either one or more plate(s) (n = 28, 74%), an intramedullary nail (n = 8, 21%), screws only, or an intramedullary nail and plate (each; n = 1, 3%). In seven patients (18%), an allogeneic fibular strut was used to reinforce the construct. A gastrocnemius flap was used in nine proximal tibial reconstructions (64%).

Systematic literature review

We performed a systematic search to identify papers on osteoarticular allograft reconstructions for musculoskeletal tumors. All clinical case series that reported on at least five reconstructions, and were written in English, Dutch, German, French or Italian, were included. With search terms which are detailed in the supplementary material, we identified 244 unique titles in PubMed, EMBASE, Web of Science, CINAHL, Academic Search Premier and Science Direct. The leading author screened all titles and abstracts, extracted relevant data and critically appraised the included studies. The critical appraisal data were based on a previous systematic review on reconstructions for tumor resections³⁵. Our review was registered with the international prospective register of systematic reviews (PROSPERO) database³⁶ (identifier CRD42015026027).

Statistical analysis

Continuous variables were compared with Mann-Whitney U tests. Logistic regression analysis was used to assess the influence of factors on the occurrence of complications in the retrospective study, and to compare the incidence of complications in the systematic review. Allograft survival was estimated with Kaplan-Meier curves with 95% confidence intervals (CI). We used SPSS v.21 software (IBM Corp., Armonk, New York), with the level of significance at a p-value < 0.05.

Results

Retrospective study

At review, 26 patients (68%) had no evidence of disease and 12 patients (32%) had died. Median follow-up was 19.5 years (95% CI 13.0 to 26.1). A total of 39 patients (79%) experienced one or more complications. Two patients (5%) required further surgery for joint instability (Henderson type 1 complication); both reconstructions of the distal radius were converted to an arthrodesis. Of 24 patients with a reconstruction around the knee, 15 (63%) had worn a brace for at least one year, or until failure of their graft, because of instability of the reconstructed joint.

Nonunion (Henderson type 2 complication) occurred in six reconstructions (16%). Re-operations took place after a median of 13 months (IQR 9 to 18), in two proximal tibial (14%), two distal femoral (20%) and two proximal humeral reconstructions (17%). One allograft (3%) was removed because of nonunion.

Fractures (Henderson type 3 complication) occurred in ten patients (26%), after a median of 49 months (IQR 27 to 74). Fractures occurred in reconstructions of the proximal tibia (n = 5, 36%), proximal humerus (n = 3, 25%) and distal femur (n = 2, 20%). All fractures occurred in reconstructions ≥ 10 cm.

Infections (Henderson type 4 complication) occurred in five patients (13%), after two, 14, 17, 37 and 40 months. Two patients had a primary infection (5%), others occurred after operative intervention for other complications. Four infections occurred in the proximal tibia (29%) and one in the distal femur (10%). Allografts involving the tibia were associated with an increased risk of infection (OR 9.2, 95% CI 0.9 to 93.0, $p = 0.06$). Tibial grafts with a muscle flap appeared to have a lower infection risk (two of nine, 22%) than those without (two of five, 40%).

Local recurrences (Henderson type 5 complication) occurred in two patients (5%, one osteosarcoma with wide margins and one parosteal osteosarcoma with an intralesional excision), after six and 13 months, respectively. Metastases developed in eight patients (21%).

In total, 20 reconstructions failed (53%): eight proximal tibial (57%), five distal femoral (50%) and two distal radial (100%) allografts. Reasons for failure were fracture (n = 7, 18%), degenerative changes or subchondral collapse (n = 5, 13%, figure 1), infection (n = 3, 9%), instability (n = 2, 6%), tumor recurrence (n = 2, 6%, figure 2) and nonunion (n = 1, 3%) (table 2).



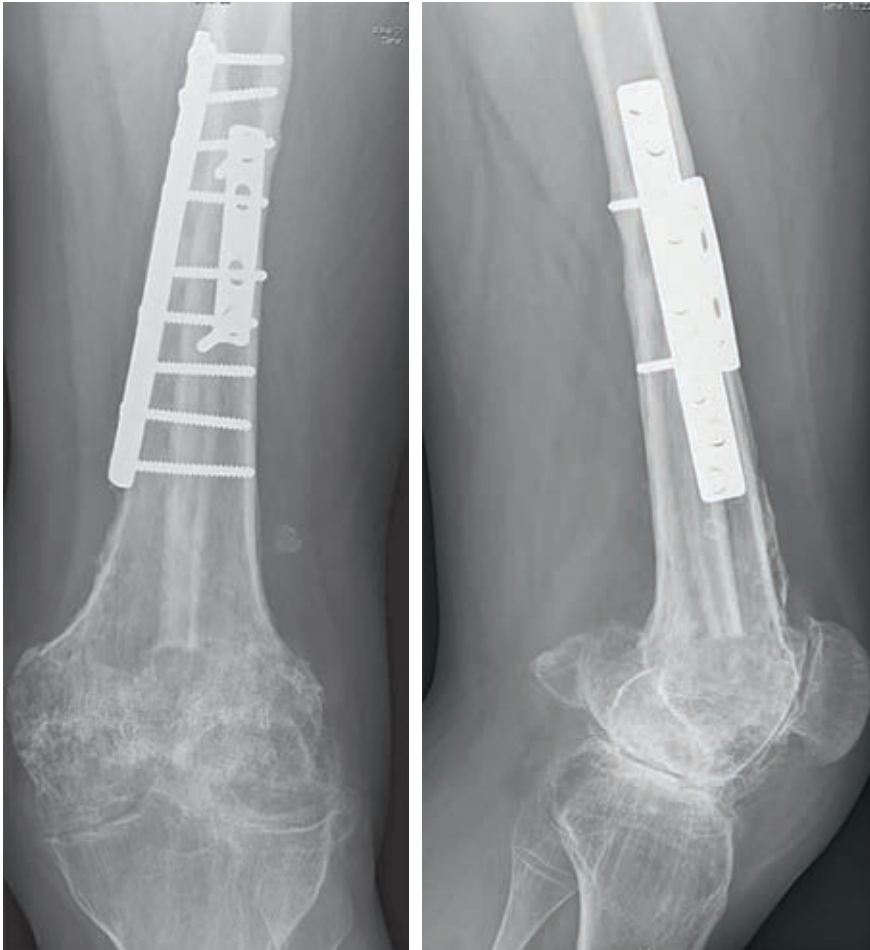

Figure 1. Conventional anteroposterior and lateral radiographs, taken 18 years after a transarticular distal femoral resection for an osteosarcoma in a 14-year-old male patient. The allograft was fixed to host bone using two plates. There is sound incorporation of the allograft. Signs of severe secondary osteoarthritis can easily be identified in the tibiofemoral and patellofemoral joints. The patient was free of pain.

Table 2. Overview of failure mechanisms

Location (n)	Failure type (Henderson classification)					Total n (%)
	Instability	Nonunion	Structural	Infection	Tumor progression	
Proximal tibia (14)	-	1	4	3	-	8 (57)
Distal femur (10)	-	-	4	-	1	5 (50)
Proximal humerus (12)	-	-	4	-	1	5 (42)
Distal radius (2)	2	-	-	-	-	2 (100)
All (38)	2	1	12	3	2	20 (53)

Of the 15 allografts that were followed for more than five years (39%), five (33%) failed after more than five years post-operatively. Failures were salvaged with endoprostheses in 12 patients (32%; eight knee and three shoulder arthroplasties) and with an arthrodesis in two (5%; both at the wrist). Ablative procedures were undertaken in six patients (16%).

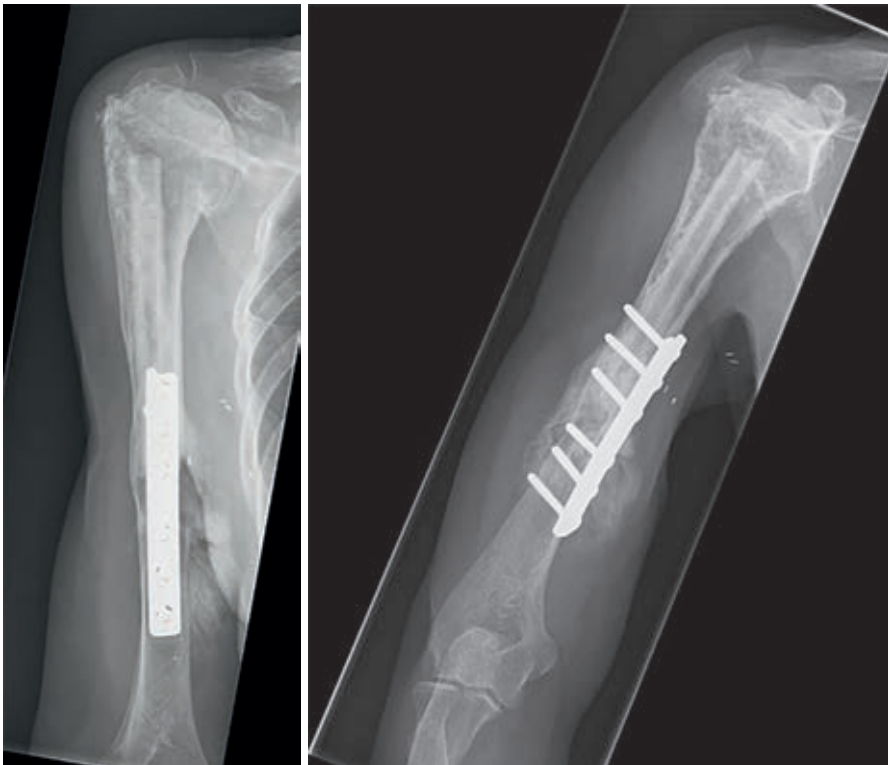

Figure 2. Conventional anteroposterior and lateral radiographs, taken 15 years after resection of the proximal humerus for a low-grade osteosarcoma in a 46-year-old female patient. The allograft was fixed to host bone using a plate. A fibular strut graft can be identified in the intramedullary canal. Later, a transhumeral amputation was performed for a soft-tissue recurrence.

Estimated median allograft survival was 5.7 years (95% CI 0.4 to 11.1), when 22 patients were at risk for failure. With failure for any reason as the endpoint, survival rates at two, five and ten years were 89% (95% CI 79 to 99, 30 patients at risk), 52% (95% CI 34 to 70, 15 patients at risk) and 41% (95% CI 23 to 59, ten patients at risk). With failure for mechanical reasons as the endpoint, these were 97% (95% CI 91 to

100, 31 patients at risk), 59% (95% CI 41 to 78, 15 patients at risk) and 46% (95% CI 26 to 66, ten patients at risk), respectively (figure 3).

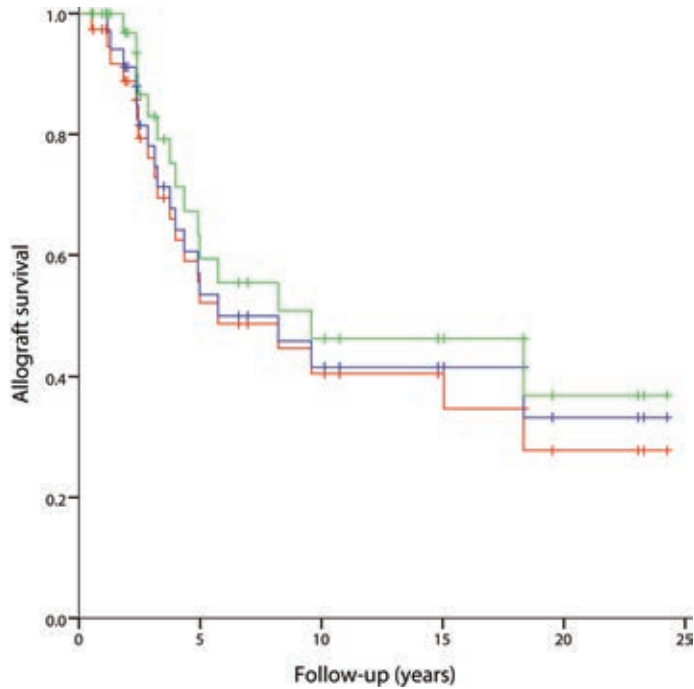


Figure 3. Kaplan-Meier curve for survival of the reconstruction, with failure for all reasons as the endpoint (red line), failure for non-oncological reasons (mechanical reasons and infection) as the endpoint (blue line) and failure for mechanical reasons as the endpoint (green line).

Systematic literature review

After review of 244 titles, 110 abstracts were screened, of which 82 full-text articles were subsequently assessed. This resulted in further exclusion of 51 papers, leaving 31 studies available for review (figure 4)^{9, 14-19, 21-25, 37-55}. Only five studies (16%) were level III evidence; the remainder (26/31, 84%) were level IV (supplementary material). Critical appraisal demonstrated that only nine (30%) of studies properly reported on eligibility criteria and sources and methods of patient selection (figure 5). The 31 included studies reported on a total of 781 reconstructions in 769 patients.

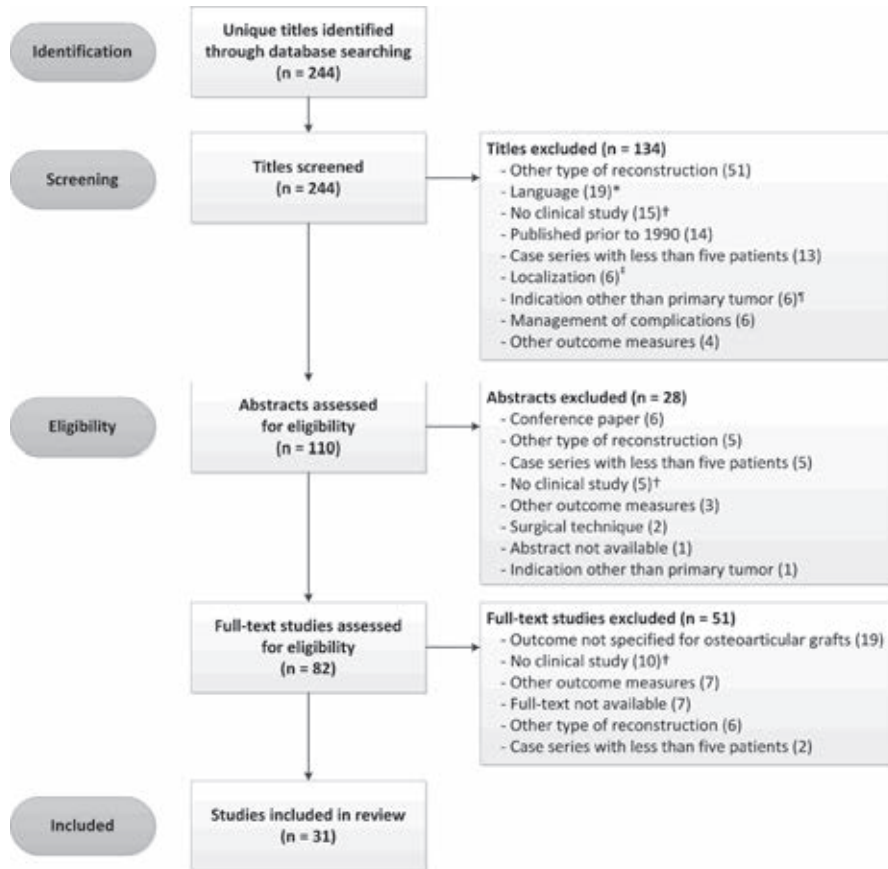


Figure 4. Flowchart of the systematic literature search (*excluded languages were Chinese, Spanish, Russian and Norwegian; †including (but not limited to) basic science studies, animal studies, reviews without new cases, radiological studies, immunological studies and biomechanical studies; ‡excluded sites involving the pelvis, hand and elbow; †excluded indications were traumatic skeletal defects and failed arthroplasty).

Predominant reconstruction sites were the distal femur (n = 333, 43%), proximal tibia (n = 228, 29%), proximal humerus (n = 111, 14%) and distal radius (n = 100, 13%). To ensure that complications could be linked to the site at which they occurred, we selected only those papers that reported on one reconstruction site exclusively. We identified three papers focusing on the distal femur (n = 184)^{14, 16, 19}, five on the proximal tibia (n = 136)^{15, 17, 43, 47, 53}, seven on the distal radius (n = 99)^{22, 38, 40, 41, 48-50} and five on the proximal humerus (n = 95)^{21, 23, 24, 45, 46}, leaving 514 reconstructions for analysis. Apart from one study that included 18% unicondylar distal femoral reconstructions¹⁴, all reconstructions were segmental.

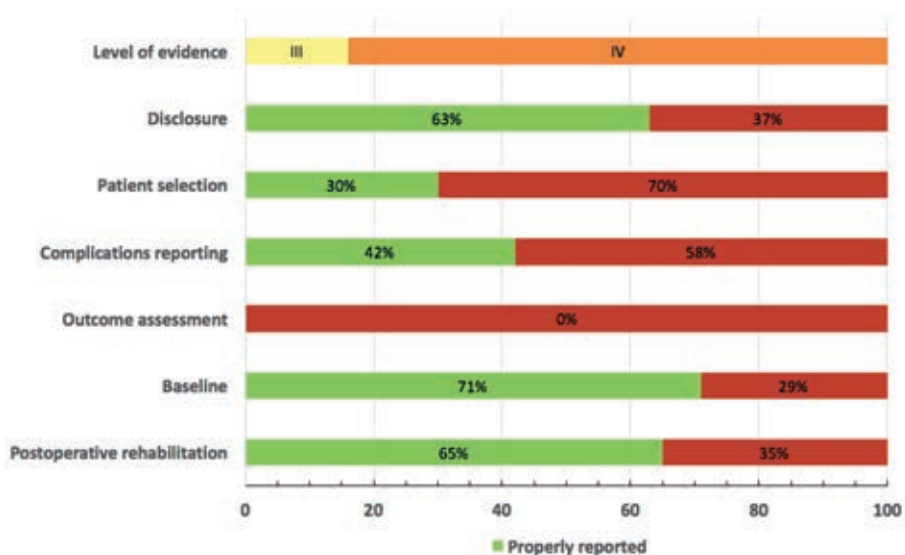


Figure 5. Result of the critical appraisal of studies included in the systematic review. Low reporting of selected criteria increases the risk of bias.

Overall reported rates of failure, fracture and infection were 27% (141/514), 20% (100/514) and 10% (52/514), respectively. Mean follow-up ranged from 24 months to 16 years. With the distal femur as the reference, we compared complication rates between different reconstruction sites. The risk of failure was lowest for the distal radius (OR 0.3, 95% CI 0.1 to 0.6). While the risk of fracture was significantly higher for the proximal humerus (OR 4.1, 95% CI 2.2 to 7.7) and proximal tibia (OR 2.2, 95% CI 1.3 to 4.4), the risk of infection was significantly higher for the proximal tibia (OR 2.2, 95% CI 1.1 to 4.3) and significantly lower for the distal radius (OR 0.1, 95% CI 0.0 to 0.8) (table 3). Results of studies that reported on at least 20 reconstructions are detailed in the supplementary material; many studies did not report the length of the graft. As a result of a lack of detailed description, we were not able to comment on an association between the type of osteosynthesis and the occurrence of complications.

Discussion

Osteoarticular allografts represent an alternative to endoprosthetic reconstruction in musculoskeletal tumor surgery. However, solid evidence on the incidence of complications, failure mechanisms, and survival of the reconstruction is lacking. We therefore systematically reviewed the literature and retrospectively evaluated our single-centre experiences, with the aims to assess long-term rates of complications, mechanisms of failure, and rates of survival of the allograft.

Table III. Analysis of reported complication rates by odds ratios (OR) with 95% confidence intervals (CI)

Location (n)	Failure			Infection			Fracture		
	n (%)	OR (95% CI)	p-value	n (%)	OR (95% CI)	p-value	n (%)	OR (95% CI)	p-value
Distal femur (184)	55 (30)	Ref (-)	-	17 (9)	Ref (-)	-	21 (11)	Ref (-)	-
Proximal tibia (104)	47 (35)	1.2 (0.8 – 2.0)	0.38	25 (18)	2.2 (1.1 – 4.3)	0.02	32 (24)	2.2 (1.3 – 4.4)	0.005
Distal radius (99)	11 (11)	0.3 (0.1 – 0.6)	0.001	1 (1)	0.1 (0.0 – 0.8)	0.03	14 (14)	1.3 (0.6 – 2.6)	0.51
Proximal humerus (95)	28 (30)	1.0 (0.6 – 1.7)	0.94	9 (10)	1.0 (0.4 – 2.4)	0.95	33 (35)	4.1 (2.2 – 7.7)	<0.00001

Data in this table are based on results reported in papers focusing on one reconstruction site exclusively. Results are derived from three papers focusing on the distal femur^{14, 16, 19}, five on the proximal tibia^{15, 17, 43, 47, 53}, seven on the distal radius^{22, 38, 40, 41, 48-50} and five on the proximal humerus^{21, 23, 24, 45, 46}.

* logistic regression analysis. Ref, reference value.

The reconstruction failed in 53% of our patients, mostly due to mechanical complications. Previous studies reported failures in 22% to 60% of segmental osteoarticular allografts; however, follow-up varied greatly (see supplementary material). Previous authors have stated that if an intercalary allograft survives the critical three to four years, it is likely to last for many years¹². It appears that this does not apply to osteoarticular grafts. Of the grafts that were followed for more than five years, 33% failed at a later point in time. One explanation might be that creeping substitution, the process through which the allograft is gradually replaced by living bone²⁹, cannot take place at the articular side of the osteoarticular graft and as a result, there is a risk of subchondral collapse⁴². If technically feasible, performing a unicondylar or hemicortical resection may prove useful in reducing this risk; by preserving host subchondral bone and increasing the contact surface between allogenic and host bone, the risk of collapse and nonunion may be reduced. In the

only study focusing on unicondylar osteoarticular allografts to date, Muscolo *et al*⁹ reported promising results with an allograft rate of survival of 85% at ten years in 40 reconstructions (38 patients).

Severe instability occurred in two reconstructions of the distal radius, and 63% of our patients with a reconstruction around the knee had to wear a brace for a prolonged period. Previously reported rates of instability range from 5% to 20%. Due to the subjectivity of the outcome, it is difficult to assess adequately the occurrence of joint instability in a retrospective study.

From our review, it appeared that fracture is the most common complication after osteoarticular allograft reconstruction (up to 52%). A total of ten of our patients (26%) sustained a fracture. The risk of fracture was higher after nail fixation; in accordance with previous studies, we recommend plate fixation^{3, 11, 56}. One of the problems in osteoarticular reconstructions, however, is the fact that it is not possible to apply bridging osteosynthesis, while it has been noted that this reduces the risk of complications^{3, 57}. An explanation for the high risk of fracture might be that considerable torsional forces act on the plate (especially in case of instability of surrounding joints) and the hardware is therefore prone to break at some point in time. We demonstrated that the proximal humerus and tibia have the highest risk of fracturing. The high risk for proximal humeral grafts might be explained by the greater length of these reconstructions. Although we could not demonstrate an association between graft length and the risk of complications, previous studies reported unfavorable results for larger reconstructions^{3, 13, 58}. Filling the graft with cement may reduce the fracture rate in high-risk reconstructions²⁴. Another strategy is to apply double-plate fixation, thereby increasing the torsional and bending stiffness of the construct⁵⁹. However, this may necessitate additional soft-tissue dissection and thus increase the risk of infection⁵⁸.

A total of three of our patients (8%) underwent revision for symptomatic degenerative joint changes. Previous authors reported degenerative changes in 13% to 31% of reconstructed joints^{17, 19, 25}, while others concluded that osteoarthritis occurs in practically all patients^{20, 40, 41}. However, follow-up periods differed and authors often either did not provide a clear definition of degeneration^{14, 19, 25, 54} or sufficed with a radiographic diagnosis^{9, 16, 17, 44}.

The use of massive allografts is presumed to be associated with a high risk of infection⁶⁰. However, through our literature review, we found an overall infection rate of 10% (52/514), which is identical to the rate found by Racano *et al*⁶¹ in their systematic review on endoprosthetic reconstruction in long-bone tumor surgery

(pooled overall infection rate that included 48 studies on a total of 4838 patients). Albergo *et al*⁶² on the other hand, reported that the risk of failure due to infection is higher for osteoarticular allografts than for endoprostheses in a direct comparative study of 88 patients with an endoprosthesis and 45 patients with an osteoarticular allograft, although their study was retrospective and compared data from two different units. Both in the literature, and in our series, the risk of infection was highest in the proximal tibia. While the patients who were considered to be at high risk for infection due to poor soft-tissue coverage⁶³ were the ones who received a muscle flap, the infection rate was lower in reconstructions with a muscle flap. Concurring with previous authors we believe that muscle flaps should be used routinely in these high-risk cases⁶⁴.

Our study has a number of limitations. First, we were hampered by a limited number of patients in our retrospective study, and it was therefore not possible to assess fully the risk factors for complications. Secondly, different definitions of complications have been used in the literature, and this may have affected the results from our pooled analysis. Furthermore, several studies did not clearly describe how they determined whether a complication had occurred, or how they defined nonunion. Thirdly, studies included in the systematic review have inherent heterogeneity with regards to included diagnoses, treatment protocols, use of additional struts and flaps, osteosynthesis and cement. We were unable to adjust for these factors and this may have introduced bias. However, we aimed to provide an overview of current knowledge on osteoarticular allograft reconstructions in musculoskeletal tumor surgery, and this could only be achieved by combining different studies and definitions. Lastly, it should be noted that all studies included in the systematic review were retrospective and observational, and may therefore be graded as a low level of evidence.

An advantage of using an osteoarticular allograft for primary reconstruction is that, in case of degenerative changes, it may be converted to an allograft-prosthetic composite with relative ease. Therefore, an osteoarticular allograft may be used to delay the time for endoprosthetic reconstruction in young patients. Few series have compared the results of allografts with endoprostheses, and most focused on reconstruction of the proximal humerus^{30, 39, 45, 53, 65}. The majority of the comparative studies concluded that allografts are associated with unacceptably high complication rates and unpredictable outcomes; reconstruction with either allograft-prosthetic composites or endoprostheses was therefore advocated as the method of choice^{39, 45, 53}.



The use of osteoarticular allografts for reconstruction of large joints may have been justifiable in the past, when endoprostheses were associated with high rates of mechanical failure. Due to marked advances in endoprosthetic design, it appears that metallic implants have largely replaced biological implants as the technique of choice for reconstruction of articular defects. Possibly, osteoarticular allografts are a reasonable solution for patients in whom only a small part of the articulating structure has to be resected or, given the unpredictable results of expanding prostheses⁶⁶, joint reconstruction in the growing child or teenagers. Although comparative studies with alternative techniques are scarce, the risk of mechanical failure in our opinion does not justify routine employment of osteoarticular allografts for reconstruction of large joints after tumor resection.

Appendices

Appendix 1. Search strategy for the systematic literature review

PubMed: ("osteoarticular allograft"[tw] OR "osteoarticular allografting"[tw] OR "osteoarticularallografts"[tw]OR"osteoarticularallograft"[tw]OR"osteoarticularknee allografts"[tw] OR (("osteoarticular"[tw] OR osteoartic*[tw] OR "osteo articular"[tw]) AND ("allograft"[tw] OR allograft*[tw] OR "allo graft"[tw] OR allo graft*[tw] OR "Transplantation, Homologous"[Mesh] OR Homograft*[tw] OR Homologous Transplant*[tw] OR Allogeneic Transplant*[tw] OR Homologous graft*[tw] OR Allogeneic graft*[tw])) OR "osteo articular bone grafts"[tw] OR "osteoarticular graft"[tw] OR "osteoarticular grafts"[tw]) AND ("Bone Neoplasms"[Mesh] OR Bone Neoplasm OR Bone Neoplasms OR Bone Cancer OR Cancer of the Bone OR Cancer of Bone OR bone tumor OR bone tumors OR bone tumour OR bone tumours OR bone sarcoma OR bone sarcomas OR Adamantinoma OR Femoral Neoplasms OR "Neoplasms, Bone Tissue"[Mesh] OR Ossifying Fibroma OR Osteoblastoma OR Osteochondroma OR Osteochondromatosis OR Osteoma OR Osteoid Osteoma OR Osteosarcoma OR Osteosarcoma* OR Ewing Sarcoma OR Multiple Hereditary Exostoses OR Ossifying Fibroma* OR Osteoblastoma* OR Osteochondroma* OR Osteoma* OR Ewing Sarcoma*)

Archivalia: OR (("osteoarticular"[tw] OR osteoartic*[tw] OR "osteo articular"[tw]) AND ("graft"[tw] OR graft*[tw]))

Embase: ("osteoarticular allograft".mp OR "osteoarticular allografting".mp OR "osteoarticular allografts".mp OR "osteoarticular allograft".mp OR "osteoarticular knee allografts".mp OR (("osteoarticular".mp OR osteoartic*.mp OR "osteo articular".mp) AND ("bone allograft"/ OR "allograft".mp OR allograft*.mp OR "allo graft".mp OR allograft*.mp OR "allotransplantation"/ OR Homograft*.mp OR Homologous Transplant*.mp OR Allogeneic Transplant*.mp OR Homologous graft*.mp OR Allogeneic graft*.mp)) OR "osteo articular bone grafts".mp OR "osteoarticular graft".mp OR "osteoarticular grafts".mp) AND (exp "Bone Tumor"/ OR (Bone Neoplasm OR Bone Neoplasms OR Bone Cancer OR Cancer of the Bone OR Cancer of Bone OR bone tumor OR bone tumors OR bone tumour OR bone tumours OR bone sarcoma OR bone sarcomas OR Adamantinoma OR Femoral Neoplasms OR Ossifying Fibroma OR Osteoblastoma OR Osteochondroma OR Osteochondromatosis OR Osteoma OR Osteoid Osteoma OR Osteosarcoma OR Osteosarcoma* OR Ewing Sarcoma OR Multiple Hereditary Exostoses OR Ossifying Fibroma* OR Osteoblastoma* OR Osteochondroma* OR Osteoma* OR Ewing Sarcoma*).mp OR ((Bone* AND

Neoplasm) OR (Bone* AND Neoplasms) OR (Bone* AND Cancer) OR (bone* AND tumor*) OR (bone* AND tumour*) OR (bone* AND sarcoma*).mp)

Web of Science: TS=((("osteoarticular allograft" OR "osteoarticular allografting" OR "osteoarticular allografts" OR "osteo articular allograft" OR "osteoarticular knee allografts" OR (("osteoarticular" OR osteoartic* OR "osteo articular") AND ("bone allograft" OR "allograft" OR allograft* OR "allo graft" OR allo graft* OR "allotransplantation" OR Homograft* OR Homologous Transplant* OR Allogeneic Transplant* OR Homologous graft* OR Allogeneic graft*)) OR "osteo articular bone grafts" OR "osteoarticular graft" OR "osteoarticular grafts") AND ("Bone Tumor" OR (Bone Neoplasm OR Bone Neoplasms OR Bone Cancer OR Cancer of the Bone OR Cancer of Bone OR bone tumor OR bone tumors OR bone tumour OR bone tumours OR bone sarcoma OR bone sarcomas OR Adamantinoma OR Femoral Neoplasms OR Ossifying Fibroma OR Osteoblastoma OR Osteochondroma OR Osteochondromatosis OR Osteoma OR Osteoid Osteoma OR Osteosarcoma OR Osteosarcoma* OR Ewing Sarcoma OR Multiple Hereditary Exostoses OR Ossifying Fibroma* OR Osteoblastoma* OR Osteochondroma* OR Osteoma* OR Ewing Sarcoma*) OR ((Bone* AND Neoplasm) OR (Bone* AND Neoplasms) OR (Bone* AND Cancer) OR (bone* AND tumor*) OR (bone* AND tumour*) OR (bone* AND sarcoma*))))))

Cochrane: ((("osteoarticular allograft" OR "osteoarticular allografting" OR "osteoarticular allografts" OR "osteo articular allograft" OR "osteoarticular knee allografts" OR (("osteoarticular" OR osteoartic* OR "osteo articular") AND ("bone allograft" OR "allograft" OR allograft* OR "allo graft" OR allo graft* OR "allotransplantation" OR Homograft* OR Homologous Transplant* OR Allogeneic Transplant* OR Homologous graft* OR Allogeneic graft*)) OR "osteo articular bone grafts" OR "osteoarticular graft" OR "osteoarticular grafts") AND ("Bone Tumor" OR (Bone Neoplasm OR Bone Neoplasms OR Bone Cancer OR Cancer of the Bone OR Cancer of Bone OR bone tumor OR bone tumors OR bone tumour OR bone tumours OR bone sarcoma OR bone sarcomas OR Adamantinoma OR Femoral Neoplasms OR Ossifying Fibroma OR Osteoblastoma OR Osteochondroma OR Osteochondromatosis OR Osteoma OR Osteoid Osteoma OR Osteosarcoma OR Osteosarcoma* OR Ewing Sarcoma OR Multiple Hereditary Exostoses OR Ossifying Fibroma* OR Osteoblastoma* OR Osteochondroma* OR Osteoma* OR Ewing Sarcoma*) OR ((Bone* AND Neoplasm) OR (Bone* AND Neoplasms) OR (Bone* AND Cancer) OR (bone* AND tumor*) OR (bone* AND tumour*) OR (bone* AND sarcoma*))))))

CINAHL: (("osteoarticular allograft" OR "osteoarticular allografting" OR "osteoarticular allografts" OR "osteo articular allograft" OR "osteoarticular knee allografts" OR ("osteoarticular" OR osteoartic* OR "osteo articular") AND ("bone allograft" OR "allograft" OR allograft* OR "allo graft" OR allo graft* OR "allotransplantation" OR Homograft* OR Homologous Transplant* OR Allogeneic Transplant* OR Homologous graft* OR Allogeneic graft*)) OR "osteo articular bone grafts" OR "osteoarticular graft" OR "osteoarticular grafts") AND ("Bone Tumor" OR (Bone Neoplasm OR Bone Neoplasms OR Bone Cancer OR Cancer of the Bone OR Cancer of Bone OR bone tumor OR bone tumors OR bone tumour OR bone tumours OR bone sarcoma OR bone sarcomas OR Adamantinoma OR Femoral Neoplasms OR Ossifying Fibroma OR Osteoblastoma OR Osteochondroma OR Osteochondromatosis OR Osteoma OR Osteoid Osteoma OR Osteosarcoma OR Osteosarcoma* OR Ewing Sarcoma OR Multiple Hereditary Exostoses OR Ossifying Fibroma* OR Osteoblastoma* OR Osteochondroma* OR Osteoma* OR Ewing Sarcoma*) OR ((Bone* AND Neoplasm) OR (Bone* AND Neoplasms) OR (Bone* AND Cancer) OR (bone* AND tumor*) OR (bone* AND tumour*) OR (bone* AND sarcoma*))))

Academic Search Premier [fulltext]: ti/su/ab/kw (("osteoarticular allograft" OR "osteoarticular allografting" OR "osteoarticular allografts" OR "osteo articular allograft" OR "osteoarticular knee allografts" OR ("osteoarticular" OR osteoartic* OR "osteo articular") AND ("bone allograft" OR "allograft" OR allograft* OR "allo graft" OR allo graft* OR "allotransplantation" OR Homograft* OR Homologous Transplant* OR Allogeneic Transplant* OR Homologous graft* OR Allogeneic graft*)) OR "osteo articular bone grafts" OR "osteoarticular graft" OR "osteoarticular grafts") AND ("Bone Tumor" OR (Bone Neoplasm OR Bone Neoplasms OR Bone Cancer OR Cancer of the Bone OR Cancer of Bone OR bone tumor OR bone tumors OR bone tumour OR bone tumours OR bone sarcoma OR bone sarcomas OR Adamantinoma OR Femoral Neoplasms OR Ossifying Fibroma OR Osteoblastoma OR Osteochondroma OR Osteochondromatosis OR Osteoma OR Osteoid Osteoma OR Osteosarcoma OR Osteosarcoma* OR Ewing Sarcoma OR Multiple Hereditary Exostoses OR Ossifying Fibroma* OR Osteoblastoma* OR Osteochondroma* OR Osteoma* OR Ewing Sarcoma*) OR ((Bone* AND Neoplasm) OR (Bone* AND Neoplasms) OR (Bone* AND Cancer) OR (bone* AND tumor*) OR (bone* AND tumour*) OR (bone* AND sarcoma*))))

ScienceDirect: TITLE-ABSTR-KEY(("osteoarticular allograft" OR "osteoarticular allografting" OR "osteoarticular allografts" OR "osteo articular allograft" OR



"osteoarticular knee allografts" OR (("osteoarticular" OR osteoartic* OR "osteo articular") AND ("bone allograft" OR "allograft" OR allograft* OR "allo graft" OR allo graft* OR "allograft" OR Homograft* OR Homologous Transplant* OR Allogeneic Transplant* OR Homologous graft* OR Allogeneic graft*)) OR "osteo articular bone grafts" OR "osteoarticular graft" OR "osteoarticular grafts") AND ("Bone Tumor" OR (Bone Neoplasm OR Bone Neoplasms OR Bone Cancer OR Cancer of the Bone OR Cancer of Bone OR bone tumor OR bone tumors OR bone tumour OR bone tumours OR bone sarcoma OR bone sarcomas OR Adamantinoma OR Femoral Neoplasms OR Ossifying Fibroma OR Osteoblastoma OR Osteochondroma OR Osteochondromatosis OR Osteoma OR Osteoid Osteoma OR Osteosarcoma OR Osteosarcoma* OR Ewing Sarcoma OR Multiple Hereditary Exostoses OR Ossifying Fibroma* OR Osteoblastoma* OR Osteochondroma* OR Osteoma* OR Ewing Sarcoma*) OR ((Bone* AND Neoplasm) OR (Bone* AND Neoplasms) OR (Bone* AND Cancer) OR (bone* AND tumor*) OR (bone* AND tumour*) OR (bone* AND sarcoma*))))))

Appendix 2. Overview of literature on osteoarticular allograft reconstruction

Data	Gebhardt	Mnaymneh	Kocher	Hornicek	Musco	DeGroot	Musco	Buecker	Musco	Ogilvie	Musco	Toy	Campanacci	Current study
Year	1990	1994	1998	1998	2000	2004	2005	2006	2007	2009	2010	2010	2010	2015
Patients (n)	20	83	24	38	108	31	71	24	38	20	52	26	25	38
Localisations (%)	PH 100	DF 100	DR 100	PT 100	DF 63 PT 37	PH 100	DF 100	DF 42 PT 25 PH 31	DF 73 PT 28	DF 40 PT 30 PH 20 DR 5 PU 5	PT 100	DF 100	DF 52 PT 48	DF 26 PT 37 PH 32 DR 5
Unicondylar reconstructions (%)	-	19	-	-	-	-	-	-	100	-	-	-	-	16
Mean follow-up in months (range)	64 (15 – 138)	N/R (min. 2 yrs)	131 (25 – 268)	72 (24 – 96)	66 (range N/R, min. 2 yrs)	65 (7 – 148)	82 (1 – 368)	36 (12 – 74)	127 (6 – 250)	192 (120 – 252)	123 (10 – 250)	156 (15 – 283)	124 (6 – 226)	150 (7 – 280)
Fixation method (%)	PLT 100	N/R	N/R	PLT 100	PLT 80 IMN 20	PLT 97 IMN+PLT 3	PLT 80 IMN 20	PLT 100	PLT 70 SCR 30	N/R	PLT 86 IMN 14	IMN 96 IMN+PLT 4	PLT 96 IMN 4	PLT 74 IMN 21 SCR 3 IMN+PLT 3
Mean graft length, cm (range)	N/R	N/R (8 – 37)	N/R	N/R	N/R	12 (7 – 20)	N/R	N/R	N/R	N/R	N/R	19 (13.5 – 28)	15.5 (8.5 – 25)	14.5 (8 – 26)
Complications (%)														
Infection	15	6	-	23	11	3	8	17	5	10	22	23	-	13
Fracture	25	14	25	42	2	37	5	13	3	45	5	19	52	26
Nonunion	5	12	-	12	-	20	-	50	-	20	-	19	12	18
Joint instability	5	7	8	17	-	7	-	-	11	-	-	8	20	-
Overall complication rate (%)	65	-	58	-	-	56	-	79	-	70	-	62	68	79
Failure rate	30	24	33	32	46	22	23	29	15	60	34	58	60	53
Mean MSTs score (range)	-	-	-	-	-	75 (57 – 90)	87 (50 – 100)	-	91 (67 – 100)	77 (40 – 93)	87 (range N/R)	-	85 (65 – 97)	-

MSTS, Musculoskeletal Tumor Society; N/R, not reported; DF, distal femur; PT, proximal tibia; DT, distal tibia; PH, proximal humerus; DH, distal humerus; DR, distal radius; PU, proximal ulna; PLT, plate(s); IMN, intramedullary nail; SCR, screw(s). Table only includes studies that reported on ≥ 20 osteoarticular allograft reconstructions.



References

1. Bielack SS, Kempf-Bielack B, Delling G, Exner GU, Flege S, Helmke K, et al. Prognostic factors in high-grade osteosarcoma of the extremities or trunk: an analysis of 1,702 patients treated on neoadjuvant cooperative osteosarcoma study group protocols. *Journal of clinical oncology : official journal of the American Society of Clinical Oncology*. 2002 Feb 1;20(3):776-90. Epub 2002/02/01.
2. Arndt CA, Crist WM. Common musculoskeletal tumors of childhood and adolescence. *The New England journal of medicine*. 1999 Jul 29;341(5):342-52. Epub 1999/07/29.
3. Bus MP, Dijkstra PD, van de Sande MA, Taminiau AH, Schreuder HW, Jutte PC, et al. Intercalary allograft reconstructions following resection of primary bone tumors: a nationwide multicenter study. *The Journal of bone and joint surgery American volume*. 2014 Feb 19;96(4):e26. Epub 2014/02/21.
4. Quan GM, Slavin JL, Schlicht SM, Smith PJ, Powell GJ, Choong PF. Osteosarcoma near joints: assessment and implications. *Journal of surgical oncology*. 2005 Sep 1;91(3):159-66. Epub 2005/08/25.
5. Pala E, Trovarelli G, Calabro T, Angelini A, Abati CN, Ruggieri P. Survival of Modern Knee Tumor Megaprotheses: Failures, Functional Results, and a Comparative Statistical Analysis. *Clinical orthopaedics and related research*. 2014 May 30. Epub 2014/05/31.
6. Jeys LM, Kulkarni A, Grimer RJ, Carter SR, Tillman RM, Abudu A. Endoprosthetic reconstruction for the treatment of musculoskeletal tumors of the appendicular skeleton and pelvis. *The Journal of bone and joint surgery American volume*. 2008 Jun;90(6):1265-71. Epub 2008/06/04.
7. Gosheger G, Gebert C, Ahrens H, Streitburger A, Winkelmann W, Harges J. Endoprosthetic reconstruction in 250 patients with sarcoma. *Clinical orthopaedics and related research*. 2006 Sep;450:164-71. Epub 2006/05/13.
8. Bus MP, van de Sande MA, Fiocco M, Schaap GR, Bramer JA, Dijkstra PD. What Are the Long-term Results of MUTARS® Modular Endoprostheses for Reconstruction of Tumor Resection of the Distal Femur and Proximal Tibia? *Clinical orthopaedics and related research*. 2015 Dec 9.
9. Muscolo DL, Ayerza MA, Aponte-Tinao LA, Abalo E, Farfalli G. Unicondylar osteoarticular allografts of the knee. *The Journal of bone and joint surgery American volume*. 2007 Oct;89(10):2137-42. Epub 2007/10/03.
10. Delloye C, Cornu O, Druetz V, Barbier O. Bone allografts: What they can offer and what they cannot. *The Journal of bone and joint surgery British volume*. 2007 May;89(5):574-9. Epub 2007/06/02.
11. Aponte-Tinao L, Farfalli GL, Ritacco LE, Ayerza MA, Muscolo DL. Intercalary femur allografts are an acceptable alternative after tumor resection. *Clinical orthopaedics and related research*. 2012 Mar;470(3):728-34. Epub 2011/06/22.
12. Ortiz-Cruz E, Gebhardt MC, Jennings LC, Springfield DS, Mankin HJ. The results of transplantation of intercalary allografts after resection of tumors. A long-term follow-up study. *The Journal of bone and joint surgery American volume*. 1997 Jan;79(1):97-106. Epub 1997/01/01.
13. Frisoni T, Cevalani L, Giorgini A, Dozza B, Donati DM. Factors affecting outcome of massive intercalary bone allografts in the treatment of tumours of the femur. *The Journal of bone and joint surgery British volume*. 2012 Jun;94(6):836-41. Epub 2012/05/26.
14. Mnaymneh W, Malinin TI, Lackman RD, Hornicek FJ, Ghandur-Mnaymneh L. Massive distal femoral osteoarticular allografts after resection of bone tumors. *Clinical orthopaedics and related research*. 1994 Jun(303):103-15. Epub 1994/06/01.
15. Clohisy DR, Mankin HJ. Osteoarticular allografts for reconstruction after resection of a musculoskeletal tumor in the proximal end of the tibia. *The Journal of bone and joint surgery American volume*. 1994 Apr;76(4):549-54. Epub 1994/04/01.
16. Muscolo DL, Ayerza MA, Aponte-Tinao LA, Ranalletta M. Use of distal femoral osteoarticular allografts in limb salvage surgery. *The Journal of bone and joint surgery American volume*. 2005 Nov;87(11):2449-55. Epub 2005/11/03.
17. Muscolo DL, Ayerza MA, Farfalli G, Aponte-Tinao LA. Proximal tibia osteoarticular allografts in tumor limb salvage surgery. *Clinical orthopaedics and related research*. 2010 May;468(5):1396-404. Epub 2009/12/19.
18. Rodl RW, Ozaki T, Hoffmann C, Bottner F, Lindner N, Winkelmann W. Osteoarticular allograft in surgery for high-grade malignant tumours of bone. *The Journal of bone and joint surgery British volume*. 2000 Sep;82(7):1006-10. Epub 2000/10/21.

19. Toy PC, White JR, Scarborough MT, Enneking WF, Gibbs CP. Distal femoral osteoarticular allografts: long-term survival, but frequent complications. *Clinical orthopaedics and related research*. 2010 Nov;468(11):2914-23. Epub 2010/07/21.
20. de Santos LA, Murray JA, Parrish FF, Wallace S, Finkelstein B, Spjut HJ, et al. Radiographic aspects of massive bone osteoarticular allograft transplantation. *Radiology*. 1978 Sep;128(3):635-41. Epub 1978/09/01.
21. Gebhardt MC, Roth YF, Mankin HJ. Osteoarticular allografts for reconstruction in the proximal part of the humerus after excision of a musculoskeletal tumor. *The Journal of bone and joint surgery American volume*. 1990 Mar;72(3):334-45. Epub 1990/03/01.
22. Kocher MS, Gebhardt MC, Mankin HJ. Reconstruction of the distal aspect of the radius with use of an osteoarticular allograft after excision of a skeletal tumor. *The Journal of bone and joint surgery American volume*. 1998 Mar;80(3):407-19. Epub 1998/04/08.
23. Getty PJ, Peabody TD. Complications and functional outcomes of reconstruction with an osteoarticular allograft after intra-articular resection of the proximal aspect of the humerus. *The Journal of bone and joint surgery American volume*. 1999 Aug;81(8):1138-46. Epub 1999/08/31.
24. DeGroot H, Donati D, Di Liddo M, Gozzi E, Mercuri M. The use of cement in osteoarticular allografts for proximal humeral bone tumors. *Clinical orthopaedics and related research*. 2004 Oct(427):190-7. Epub 2004/11/24.
25. Ogilvie CM, Crawford EA, Hosalkar HS, King JJ, Lackman RD. Long-term results for limb salvage with osteoarticular allograft reconstruction. *Clinical orthopaedics and related research*. 2009 Oct;467(10):2685-90. Epub 2009/02/14.
26. Mankin HJ, Gebhardt MC, Jennings LC, Springfield DS, Tomford WW. Long-term results of allograft replacement in the management of bone tumors. *Clinical orthopaedics and related research*. 1996 Mar(324):86-97. Epub 1996/03/01.
27. Enneking WF, Campanacci DA. Retrieved human allografts : a clinicopathological study. *The Journal of bone and joint surgery American volume*. 2001 Jul;83-a(7):971-86. Epub 2001/07/14.
28. Enneking WF, Dunham W, Gebhardt MC, Malawar M, Pritchard DJ. A system for the functional evaluation of reconstructive procedures after surgical treatment of tumors of the musculoskeletal system. *Clinical orthopaedics and related research*. 1993 Jan(286):241-6. Epub 1993/01/01.
29. Aho AJ, Ekfors T, Dean PB, Aro HT, Ahonen A, Nikkanen V. Incorporation and clinical results of large allografts of the extremities and pelvis. *Clinical orthopaedics and related research*. 1994 Oct(307):200-13. Epub 1994/10/01.
30. O'Connor MI, Sim FH, Chao EY. Limb salvage for neoplasms of the shoulder girdle. Intermediate reconstructive and functional results. *The Journal of bone and joint surgery American volume*. 1996 Dec;78(12):1872-88. Epub 1996/12/01.
31. Judas F, Rosa S, Teixeira L, Lopes C, Ferreira Mendes A. Chondrocyte viability in fresh and frozen large human osteochondral allografts: effect of cryoprotective agents. *Transplantation proceedings*. 2007 Oct;39(8):2531-4. Epub 2007/10/24.
32. Deijkers RL, Bloem RM, Petit PL, Brand R, Vehmeyer SB, Veen MR. Contamination of bone allografts: analysis of incidence and predisposing factors. *The Journal of bone and joint surgery British volume*. 1997 Jan;79(1):161-6. Epub 1997/01/01.
33. Henderson ER, Groundland JS, Pala E, Dennis JA, Wooten R, Cheong D, et al. Failure mode classification for tumor endoprostheses: retrospective review of five institutions and a literature review. *The Journal of bone and joint surgery American volume*. 2011 Mar 2;93(5):418-29. Epub 2011/03/04.
34. Henderson ER, O'Connor MI, Ruggieri P, Windhager R, Funovics PT, Gibbons CL, et al. Classification of failure of limb salvage after reconstructive surgery for bone tumours : a modified system Including biological and expandable reconstructions. *The bone & joint journal*. 2014 Nov;96-b(11):1436-40. Epub 2014/11/06.
35. Teunis T, Nota SP, Hornicek FJ, Schwab JH, Lozano-Calderon SA. Outcome after reconstruction of the proximal humerus for tumor resection: a systematic review. *Clinical orthopaedics and related research*. 2014 Jul;472(7):2245-53.
36. Booth A. PROSPERO's progress and activities 2012/13. *Syst Rev*. 2013 Dec 11;2:111.
37. Gebhardt MC, Flugstad DI, Springfield DS, Mankin HJ. The use of bone allografts for limb salvage in high-grade extremity osteosarcoma. *Clinical orthopaedics and related research*. 1991 Sep(270):181-96. Epub 1991/09/01.



38. Bianchi G, Donati D, Staals EL, Mercuri M. Osteoarticular allograft reconstruction of the distal radius after bone tumour resection. *Journal of hand surgery (Edinburgh, Scotland)*. 2005 Aug;30(4):369-73. Epub 2005/06/14.
39. van de Sande MA, Dijkstra PD, Taminiau AH. Proximal humerus reconstruction after tumour resection: biological versus endoprosthetic reconstruction. *International orthopaedics*. 2011 Sep;35(9):1375-80. Epub 2010/11/19.
40. Szabo RM, Anderson KA, Chen JL. Functional outcome of en bloc excision and osteoarticular allograft replacement with the Sauve-Kapandji procedure for Campanacci grade 3 giant-cell tumor of the distal radius. *The Journal of hand surgery*. 2006 Oct;31(8):1340-8. Epub 2006/10/10.
41. Scoccianti G, Campanacci DA, Beltrami G, Caldora P, Capanna R. The use of osteo-articular allografts for reconstruction after resection of the distal radius for tumour. *The Journal of bone and joint surgery British volume*. 2010 Dec;92(12):1690-4. Epub 2010/12/02.
42. Campanacci L, Manfrini M, Colangeli M, Ali N, Mercuri M. Long-term results in children with massive bone osteoarticular allografts of the knee for high-grade osteosarcoma. *Journal of pediatric orthopaedics*. 2010 Dec;30(8):919-27. Epub 2010/11/26.
43. Hornicek FJ, Jr., Mnaymneh W, Lackman RD, Exner GU, Malinin TI. Limb salvage with osteoarticular allografts after resection of proximal tibia bone tumors. *Clinical orthopaedics and related research*. 1998 Jul(352):179-86. Epub 1998/07/25.
44. Muscolo DL, Ayerza MA, Aponte-Tinao LA. Survivorship and radiographic analysis of knee osteoarticular allografts. *Clinical orthopaedics and related research*. 2000 Apr(373):73-9. Epub 2000/05/16.
45. Potter BK, Adams SC, Pitcher JD, Jr., Malinin TI, Temple HT. Proximal humerus reconstructions for tumors. *Clinical orthopaedics and related research*. 2009 Apr;467(4):1035-41. Epub 2008/09/30.
46. Probyn LJ, Wunder JS, Bell RS, Griffin AM, Davis AM. A comparison of outcome of osteoarticular allograft reconstruction and shoulder arthrodesis following resection of primary tumours of the proximal humerus. *Sarcoma*. 1998;2(3-4):163-70. Epub 2008/06/04.
47. Ramseier LE, Malinin TI, Temple HT, Mnaymneh WA, Exner GU. Allograft reconstruction for bone sarcoma of the tibia in the growing child. *The Journal of bone and joint surgery British volume*. 2006 Jan;88(1):95-9. Epub 2005/12/21.
48. Li J, Jiao Y, Guo Z, Ji C, Wang Z. Comparison of osteoarticular allograft reconstruction with and without the Sauve-Kapandji procedure following tumour resection in distal radius. *Journal of plastic, reconstructive & aesthetic surgery : JPRAS*. 2015 Apr 20. Epub 2015/05/16.
49. Duan H, Zhang B, Yang HS, Liu YH, Zhang WL, Min L, et al. Functional outcome of en bloc resection and osteoarticular allograft reconstruction with locking compression plate for giant cell tumor of the distal radius. *Journal of orthopaedic science : official journal of the Japanese Orthopaedic Association*. 2013 Jul;18(4):599-604. Epub 2013/05/11.
50. Rabitsch K, Maurer-Ertl W, Pirker-Fruhauf U, Lovse T, Windhager R, Leithner A. Reconstruction of the Distal Radius following Tumour Resection Using an Osteoarticular Allograft. *Sarcoma*. 2013;2013:318767. Epub 2013/05/22.
51. San-Julian M, Dolz R, Garcia-Barrecheguren E, Noain E, Sierrasesumaga L, Canadell J. Limb salvage in bone sarcomas in patients younger than age 10: a 20-year experience. *Journal of pediatric orthopaedics*. 2003 Nov-Dec;23(6):753-62. Epub 2003/10/29.
52. Muscolo DL, Ayerza MA, Aponte-Tinao L, Farfalli G. Allograft reconstruction after sarcoma resection in children younger than 10 years old. *Clinical orthopaedics and related research*. 2008 Aug;466(8):1856-62. Epub 2008/05/29.
53. Brien EW, Terek RM, Healey JH, Lane JM. Allograft reconstruction after proximal tibial resection for bone tumors. An analysis of function and outcome comparing allograft and prosthetic reconstructions. *Clinical orthopaedics and related research*. 1994 Jun(303):116-27. Epub 1994/06/01.
54. Buecker PJ, Berenstein M, Gebhardt MC, Hornicek FJ, Mankin HJ. Locking versus standard plates for allograft fixation after tumor resection in children and adolescents. *Journal of pediatric orthopaedics*. 2006 Sep-Oct;26(5):680-5. Epub 2006/08/26.
55. Asavamongkolkul A, Waikakul S, Phimolsarnti R, Kiatisevi P. Functional outcome following excision of a tumour and reconstruction of the distal radius. *International orthopaedics*. 2009 Feb;33(1):203-9. Epub 2007/08/29.
56. Vander Griend RA. The effect of internal fixation on the healing of large allografts. *The Journal of bone and joint surgery American volume*. 1994 May;76(5):657-63. Epub 1994/05/01.

57. Deijkers RL, Bloem RM, Kroon HM, Van Lent JB, Brand R, Taminiou AH. Epidiaphyseal versus other intercalary allografts for tumors of the lower limb. *Clinical orthopaedics and related research*. 2005 Oct;439:151-60. Epub 2005/10/06.
58. Bus MP, Bramer JA, Schaap GR, Schreuder HW, Jutte PC, van der Geest IC, et al. Hemicortical resection and inlay allograft reconstruction for primary bone tumors: a retrospective evaluation in the Netherlands and review of the literature. *The Journal of bone and joint surgery American volume*. 2015 May 6;97(9):738-50.
59. Saunders MM. *Mechanical Testing for the Biomechanics Engineer: A Practical Guide*: Morgan & Claypool Publishers; 2014.
60. Aponte-Tinao LA, Ayerza MA, Muscolo DL, Farfalli GL. What Are the Risk Factors and Management Options for Infection After Reconstruction With Massive Bone Allografts? *Clinical orthopaedics and related research*. 2015 May 20. Epub 2015/05/21.
61. Racano A, Pazonis T, Farrokhyar F, Deheshi B, Ghert M. High infection rate outcomes in long-bone tumor surgery with endoprosthetic reconstruction in adults: a systematic review. *Clinical orthopaedics and related research*. 2013 Jun;471(6):2017-27. Epub 2013/02/14.
62. Albergo JI, Gaston CL, Aponte-Tinao LA, Ayerza MA, Muscolo DL, Farfalli GL, et al. Proximal Tibia Reconstruction After Bone Tumor Resection: Are Survivorship and Outcomes of Endoprosthetic Replacement and Osteoarticular Allograft Similar? *Clinical orthopaedics and related research*. 2016 Apr 21.
63. Farfalli GL, Aponte-Tinao L, Lopez-Millan L, Ayerza MA, Muscolo DL. Clinical and functional outcomes of tibial intercalary allografts after tumor resection. *Orthopedics*. 2012 Mar;35(3):e391-6. Epub 2012/03/06.
64. Myers GJ, Abudu AT, Carter SR, Tillman RM, Grimer RJ. The long-term results of endoprosthetic replacement of the proximal tibia for bone tumours. *The Journal of bone and joint surgery British volume*. 2007 Dec;89(12):1632-7. Epub 2007/12/07.
65. Wang Z, Guo Z, Li J, Li XD, Sang HX. Functional outcomes and complications of reconstruction of the proximal humerus after intra-articular tumor resection. *Orthopaedic surgery*. 2010 Feb;2(1):19-26. Epub 2010/02/01.
66. Staals EL, Colangeli M, Ali N, Casanova JM, Donati DM, Manfrini M. Are Complications Associated With the Repiphysis Expandable Distal Femoral Prosthesis Acceptable for Its Continued Use? *Clinical orthopaedics and related research*. 2015 May 21. Epub 2015/05/23.

