



Universiteit  
Leiden  
The Netherlands

## **Reconstructive techniques in musculoskeletal tumor surgery : management of pelvic and extremity bone tumors**

Bus, M.P.A.

### **Citation**

Bus, M. P. A. (2018, April 12). *Reconstructive techniques in musculoskeletal tumor surgery : management of pelvic and extremity bone tumors*. Retrieved from <https://hdl.handle.net/1887/61174>

Version: Not Applicable (or Unknown)

License: [Licence agreement concerning inclusion of doctoral thesis in the Institutional Repository of the University of Leiden](#)

Downloaded from: <https://hdl.handle.net/1887/61174>

**Note:** To cite this publication please use the final published version (if applicable).

Cover Page



Universiteit Leiden



The handle <http://hdl.handle.net/1887/61174> holds various files of this Leiden University dissertation.


**Author:** Bus, M.P.A.

**Title:** Reconstructive techniques in musculoskeletal tumor surgery : management of pelvic and extremity bone tumors

**Issue Date:** 2018-04-12

# Part I

# Management of Pelvic Bone Tumors





# Chapter 2

## Conventional Primary Central Chondrosarcoma of the Pelvis:

*Prognostic factors and outcome of surgical  
treatment in 162 patients*

M.P.A. Bus<sup>1</sup>

D.A. Campannaci<sup>2</sup>

J.I. Albergo<sup>3</sup>

A. Leithner<sup>4</sup>

M.A.J. van de Sande<sup>1</sup>

C.L. Gaston<sup>3</sup>

G. Caff<sup>2</sup>

J. Mettelsiefen<sup>5</sup>

R. Capanna<sup>2</sup>

P.U. Tunn<sup>5</sup>

L.M. Jeys<sup>3</sup>

P.D.S. Dijkstra<sup>1</sup>

<sup>1</sup> Leiden University Medical Center, Leiden, the Netherlands;

<sup>2</sup> Azienda Ospedaliera Universitaria Careggi, Florence, Italy;

<sup>3</sup> Royal Orthopaedic Hospital, Birmingham, United Kingdom;

<sup>4</sup> Medizinische Universität Graz, Graz, Austria;

<sup>5</sup> Helios Klinikum Berlin-Buch, Berlin, Germany

## Abstract

**Background:** Studies focusing on the oncological outcome after treatment of conventional primary central chondrosarcoma of pelvic bone are lacking. We conducted this retrospective study at five referral centers to gain insight in the outcome of treatment for this tumor type and to identify risk factors for impaired oncological outcome.

**Patients and Methods:** 162 consecutive patients (118 males, 73%) who underwent resection of a conventional primary central chondrosarcoma of pelvic bone from 1985-2013 were evaluated. The median age was 51 years (15-78). The median follow-up was 12.6 years (95% confidence interval [CI], 8.4 - 16.9). There were 30 grade 1 lesions (19%), 93 grade 2 lesions (57%), and 39 grade 3 lesions (24%).

**Results:** Sixty-two patients (38%) experienced local recurrence: nine grade 1 lesions (30%), 31 grade 2 lesions (33%) and 22 grade 3 lesions (56%). Forty-eight patients (30%) developed metastases. The risk of disease-related death was 3% for grade 1 tumors (1 of 30; this patient had a grade 2 recurrence and died of metastases), 33% (31 of 93) for grade 2 tumors, and 54% (21 of 39) for grade 3 tumors. Identified risk factors for impaired disease-specific survival were tumor grade (grade 2, hazard ratio [HR] 20.18,  $p=0.003$ ; grade 3, HR 58.93,  $p<0.001$ ), resection margins (marginal, HR 3.21,  $p=0.001$ ; intralesional, HR 3.56,  $p<0.001$ ) and maximal tumor size (HR 1.08 per cm,  $p=0.026$ ). Deep infection ( $n=31$ , 19%) was the predominant complication.

**Conclusions:** This study offers a standard for survival rates for conventional primary central chondrosarcoma of the pelvis. The survival for grade 1 tumors was excellent. Wide resection margins were associated with a significant survival advantage for higher-grade tumors. Because of the inability to reliably distinguish low- and high-grade tumors preoperatively, we conclude that any central pelvic chondrosarcoma should be treated with aggressive primary resection with the aim of obtaining wide resection margins. There may be aggressive biologic features in some tumors for which a surgical procedure alone may not be adequate to improve outcomes.

## Introduction

Chondrosarcomas are among the most frequent primary tumors of bone. They represent a heterogeneous group of lesions, of which the conventional primary central subtype is the most common (~75-80%)<sup>1-3</sup>. Conventional chondrosarcomas are histologically classified into grades 1 to 3. Chondrosarcoma is relatively resistant to radiation and chemotherapy, and a surgical procedure therefore remains the mainstay of treatment<sup>1-3</sup>. Although curettage with local adjuvants is generally considered a good treatment option for low-grade chondrosarcoma of long bones, most authors recommend resection with clear margins for pelvic chondrosarcoma of any grade<sup>1,4-8</sup>.

Traditionally, pelvic bone tumors were treated with hindquarter amputation (also known as external hemipelvectomy), a procedure associated with unfavorable functional and cosmetic outcomes<sup>9-12</sup>. Nowadays, most pelvic neoplasms are treated with a limb-salvaging *en bloc* resection<sup>13,14</sup>. These internal hemipelvectomies are some of the most challenging procedures in orthopaedic oncology because of the complex pelvic anatomy, the proximity of major neurovascular structures, the fact that pelvic tumors are often large by the time of diagnosis, and challenges associated with reconstruction<sup>13-17</sup>. As a result, pelvic tumors resections are associated with a substantial risk of contaminated margins<sup>18</sup>.

Previous studies on pelvic chondrosarcoma combined different subtypes, although central chondrosarcomas are more often high-grade and appear to have a worse prognosis than secondary peripheral lesions<sup>4,16,19-22</sup>. The aim of this multicenter study was to assess disease-specific and progression-free survival, risk factors for impaired survival, and complications after a surgical procedure in patients treated for a conventional primary central chondrosarcoma of pelvic bone.

## Patients and Methods

A total of 170 patients who underwent surgery for a conventional (grades 1 to 3) primary central chondrosarcoma of the pelvis from 1985 to 2013 were identified through our institutional tumor databases. Eight patients (5%) underwent curettage: four grade 1 intracompartmental tumors (all continuously no evidence of disease at the time of follow-up), one grade 1 tumor with a higher-grade





recurrence that was resected (no evidence of disease at follow-up), one grade 3 tumor for which secondary resection was performed (no evidence of disease at the time of latest follow-up), and two grade 1 tumors that recurred and eventually resulted in disease-related death. To minimize bias, patients who underwent curettage were excluded from further analysis. This left 162 patients (118 male patients, 73%) with a median age of 51 years (range, 15 to 78 years) (table 1). All were followed for a minimum of two years or until death. The median follow-up was 12.6 years (95% CI, 8.4 to 16.9). Seventeen of our patients (10%) were included in previous publications: nine (6%) in a study by Fiorenza *et al*<sup>23</sup>, and eight (5%) in a study by Andreou *et al*<sup>24</sup>. Institutional review board approval was not required for this study.

Tumor grade and size, as well as infiltration of surrounding soft tissues and the hip joint, were assessed on pathology reports of the resected specimen. General criteria used to grade the lesions were cellularity, nuclear size, and the presence of abundant hyaline cartilage matrix (indicating low grade) or mucomyxoid matrix and mitoses (higher grade)<sup>1, 25</sup>. The tumor was classified as grade 1 in 30 patients (19%), grade 2 in 93 (57%) and grade 3 in 39 (24%). The median maximal tumor size was 11 cm (range, 2.5 to 25.0 cm) (data available for 151 patients [93%]). Five patients (3%) had presented with a pathological fracture. Hip (n=57, 35%) and sacroiliac joint (n=14, 9%) infiltration was defined as any form of joint involvement, either gross or focal. Soft-tissue infiltration was present in 119 patients (73%).

Tumor resections were planned on an array of conventional radiographs, computed tomography (CT) and magnetic resonance imaging (MRI). All patients received prophylactic antibiotics preoperatively, and these were continued for at least one day. The surgical approach, technique, and type of reconstruction depended on tumor location and surgeon preferences (figures 1 to 3). Primary treatment consisted of internal hemipelvectomy in 135 patients (83%) and of hindquarter amputation in 27 patients (17%). Hindquarter amputation was only performed if it was deemed impossible to obtain clear margins with a limb-salvaging resection, or if two or three of the following structures had to be sacrificed: hip joint, sciatic nerve, and femoral nerve. The most common types of internal hemipelvectomy were P2-3 (n=46, 34%), P1 (n=24, 18%), P3 (n=17, 13%) and P2 (n=14, 10%); 89 (66%) comprised the periacetabulum, 40 of which (45%) were extra-articular resections of the hip. Of 135 hemipelvectomies, 104 (77%) were reconstructed, including 60 with metallic implants (58%), 14 with allograft-

prosthetic composites (13%), and 10 with allograft reconstructions (10%). The median duration of the surgical procedures was 4.8 hours (range, 1.5 to 10.5) (data were available for 101 patients [62%]).

Surgical margins were classified as wide (resection outside the reactive zone) in 83 patients (51%), marginal (resection through the reactive zone, no tumor cells at the margins) in 42 patients (26%) and intralesional (tumor cells present at the margins) in 37 patients (23%) (table 2)<sup>26</sup>. Contaminated resections (i.e. those resections in which tumor spill occurred) were considered to be intralesional, regardless of the margins eventually achieved. Eight patients (5%) received chemotherapy, and seven patients (4%) had adjuvant radiotherapy for inadequate margins or local recurrence. The occurrence of local recurrence was assessed on imaging (usually MRI) and on histopathology in case a further surgical procedure was performed.

Kaplan-Meier curves were used to estimate disease-specific survival and progression-free survival. Disease-specific survival was defined as the time from the surgical procedure to disease-related death and was censored at the date of latest follow-up or death due to other causes. Progression-free survival was defined as the time from the surgical procedure to local recurrence or metastasis and was censored at the date of latest follow-up or death due to other causes. Prognostic factors were assessed using multivariable Cox proportional hazards models. Categorical variables were compared between groups using chi-square tests; numerical variables were compared using Mann-Whitney U tests. Outcomes are expressed in odds ratios (ORs), hazard ratios (HRs), 95% confidence intervals (CIs) and p-values. Statistical analysis was performed using SPSS version 21 (IBM), with the level of significance at  $p < 0.05$ .



**Table 1.** Study data.

	n	% of relevant group
<b>Sex</b>		
Male	118	73
Female	44	27
<b>Tumor grade and type of treatment</b>		
<b>Grade 1</b>	30	19
Internal hemipelvectomy	28	93
Hindquarter amputation	2	7
<b>Grade 2</b>	93	57
Internal hemipelvectomy	79	85
Hindquarter amputation	14	15
<b>Grade 3</b>	39	24
Internal hemipelvectomy	28	72
Hindquarter amputation	11	28
<b>Details at presentation</b>		
<b>Pathological fracture</b>	5	3
<b>Infiltration of the hip joint</b>	57	35
Grade 1	3	10
Grade 2	36	39
Grade 3	18	47
<b>Infiltration of the sacroiliac joint</b>	14	9
Grade 1	5	17
Grade 2	4	4
Grade 3	5	13
<b>Infiltration of surrounding soft-tissues</b>	119	75
Grade 1	24	83
Grade 2	62	67
Grade 3	33	87
<b>Internal hemipelvectomy types and reconstructions</b>		
<b>Type 1</b>	24	
None	17	71
Allograft	4	17
Other (minor) reconstruction	2	8
Extra-corporally irradiated autograft	1	4
<b>Type 1-2</b>	12	
Endoprosthesis	6	50
Allograft-prosthetic composite	3	25
None	1	8
Extra-corporally irradiated autograft	1	8
Transposition of the hip / iliofemoral arthrodesis	1	8
<b>Type 1-2-3</b>	8	
Endoprosthesis	5	63
None	1	13
Other (minor) reconstruction	2	25

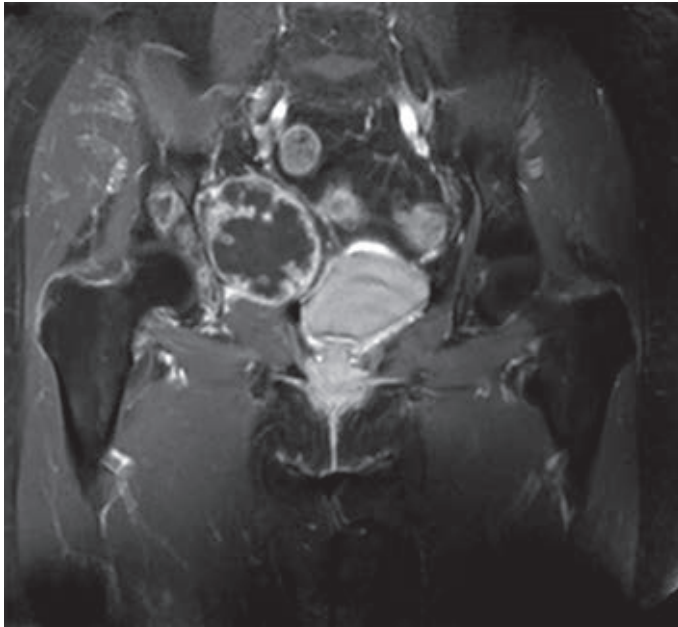
Table 1. continued

	n	% of relevant group
<b>Type 1-2-3-4</b>	4	
Endoprosthesis	2	50
Transposition of the hip / iliofemoral arthrodesis	2	50
<b>Type 1-2-4</b>	5	
Transposition of the hip / iliofemoral arthrodesis	2	40
Allograft-prosthetic composite	2	40
Endoprosthesis	1	20
<b>Type 1-4</b>	5	
None	3	60
Allograft	2	40
<b>Type 2</b>	14	
Endoprosthesis	11	79
Allograft-prosthetic composite	3	21
<b>Type 2-3</b>	46	
Endoprosthesis	35	76
Allograft-prosthetic composite	5	11
Other (minor) reconstruction	3	7
Transposition of the hip / iliofemoral arthrodesis	2	4
Extra-corporally irradiated autograft	1	2
<b>Type 3</b>	17	
None	9	53
Allograft	4	24
Other (minor) reconstruction	4	24
<b>Resection margins*</b>		
Wide	83	51
Marginal	42	26
Intralesional	37	23
<b>Progression of disease</b>		
Locally residual or recurrent tumors	62	38
Metastases	48	30
<b>Status at final follow-up*</b>		
<b>cNED</b>	71	44
Grade 1	19	63
Grade 2	43	46
Grade 3	9	23
<b>NED</b>	20	12
Grade 1	5	17
Grade 2	10	11
Grade 3	4	20
<b>AWD</b>	5	3
Grade 1	2	7
Grade 2	3	3
Grade 3	1	3

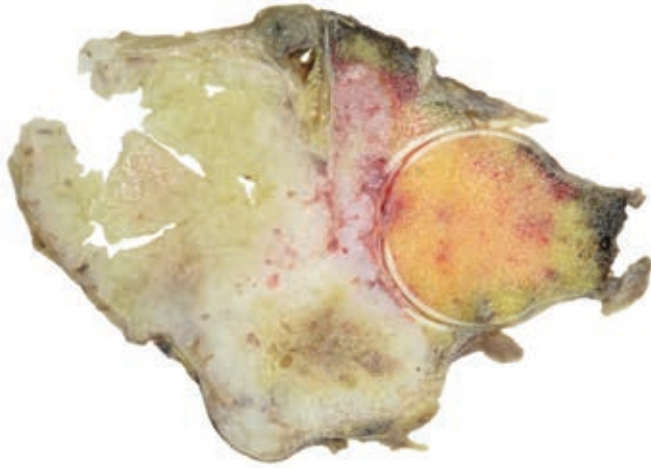
Table 1. continued

	n	% of relevant group
<i>DOD</i>	55	34
Grade 1	1	3
Grade 2	31	33
Grade 3	23	59
<i>DOC</i>	11	7
Grade 1	3	10
Grade 2	6	7
Grade 3	2	5

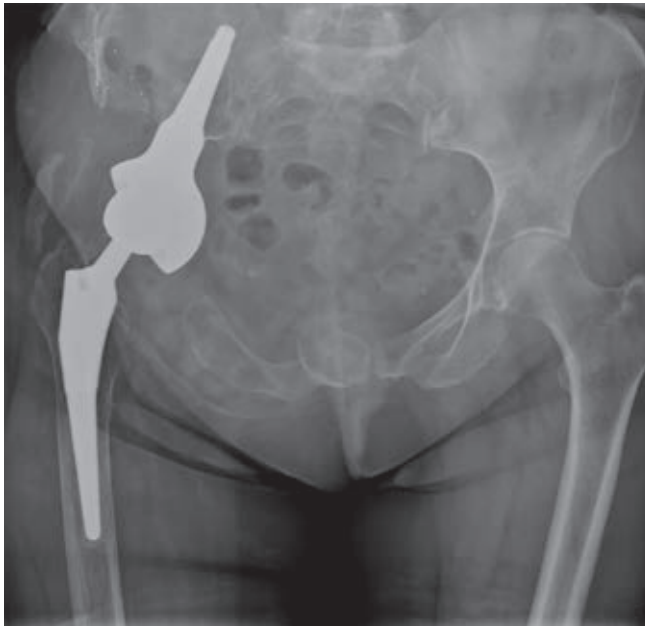
\*cNED, continuously no evidence of disease; NED, no evidence of disease following treatment of local or distant relapse; AWD, alive with disease; DOD, dead of disease; DOC, dead of other cause.



**Figure 1.** Preoperative T1 weighted MR imaging (with fat suppression) of a 67-year-old female patient, showing a chondroid tumor of the right acetabulum.



**Figure 2.** Photograph of the resected specimen after type 2-3 internal hemipelvectomy. In the periacetabulum, a grade 3 chondrosarcoma can be identified. The tumor invades the hip joint and has a maximum diameter of 11 cm. All margins were free of tumor.



**Figure 3.** Anteroposterior radiograph, taken 52 months after tumor resection and reconstruction with an uncemented LUMIC® acetabular prosthesis (implantcast, Buxtehude, Germany) and an uncemented Taperloc femoral stem (Biomet, Warsaw, IN, USA). Tantalum markers, intended for follow-up of implant fixation, can be identified in the right iliac wing. The patient continuously had no evidence of disease at final follow-up.

**Table 2.** Surgical margins in relation to tumor grade. There was no significant association between tumor grade and resection margins (chi squared test,  $p=0.110$ ).

	Wide	Marginal	Intralesional	Total
Grade 1	9 (30)	12 (40)	9 (30)	30
Grade 2	51 (55)	23 (25)	19 (20)	93
Grade 3	23 (59)	7 (18)	9 (23)	39

## Results

### Oncological outcome and risk factors for impaired outcome

At the time of latest follow-up, 96 patients (59%) were alive: 71 (44%) continuously had no evidence of disease, 19 (12%) had no evidence of disease following treatment of local relapse or metastasis and six (4%) were alive with disease. Sixty-six patients (41%) died during follow-up: 55 patients (34%) died from disease and 11 patients (7%) died from other causes.

The median disease-specific survival could not be determined because the survival curve did not cross 0.5; estimated mean disease-specific survival was 17.6 years (95% CI, 15.5 to 19.6 years) (figure 4). The estimated median progression-free survival was 9.3 years (95% CI, 3.3 to 15.3 years). Sixty-two patients (38%) experienced local recurrence: nine grade 1 lesions (30%), 31 grade 2 lesions (33%) and 22 grade 3 lesions (56%) ( $p=0.027$ ) (table 3). Four recurrent tumors (6% of 62) were of higher grade than the original tumor. Recurrent lesions were diagnosed after a median of 1.7 years (range, 0.1 to 27.3); 36 (58%) within two and 59 (95%) within five years.

The risk of disease-related death was 3% (1 of 30) for grade 1, 33% (31 of 93) for grade 2, and 54% (21 of 39) for grade 3 tumors. The patient with a grade 1 lesion who died of disease had a grade 2 recurrence that metastasized. Overall, metastases were diagnosed in 48 patients (30%), after a median of 1.9 years (range, 0.1 to 10.6). Of these, 42 (88%) died of disease, four (8%) were alive with disease at the time of latest follow-up, and two (4%) had no evidence of disease following pulmonary metastasectomy. The risk of metastasis was 32% (30 of 93) for grade 2 and 44% (17 of 39) for grade 3 tumors.

Patients with a local recurrence had a higher risk of metastases (32 of 62 [52%] versus 18 of 100 [18%]; OR 4.3, 95% CI 2.1 to 8.7,  $p < 0.001$ ) and disease-related death (39 of 62 [63%] versus 16 of 100 [16%]; OR 8.9, 95% CI 4.2 to 18.7,  $p < 0.001$ ).

Measured from the diagnosis of local recurrence, median disease-specific survival was 2.4 years (95% CI, 1.4 to 3.4 years) for patients with a grade 2 tumor, and 1.3 years (95% CI, 0.9 to 1.7 years) for patients with a grade 3 lesion (figure 5). Of 62 patients with local recurrence, 30 (48%) developed metastases, compared with 18 of 100 (18%) patients without local recurrence (OR 4.27, 95% CI 2.09 to 8.71,  $p < 0.001$ ).

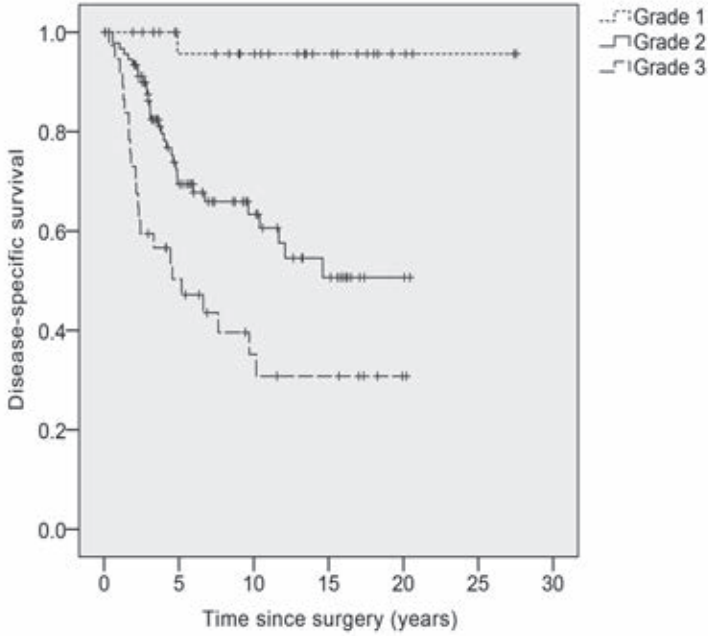
In our multivariable Cox proportional hazards model, we found that higher tumor grade, poorer resection margins, larger tumor size, and soft-tissue infiltration significantly impaired disease-specific and progression-free survival (table 4). Patient sex did not significantly influence survival. The risk of intralesional margins was lower for patients with a maximal tumor diameter of less than 10 cm (6 of 58 [10%]) than for those with a maximal tumor diameter of 10 cm or more (28 of 93 [30%]) ( $p = 0.005$ ). Although the risk of contaminated margins was higher after internal hemipelvectomy (35 of 135 [26%]) than after hindquarter amputation (2 of 27 [7%]), hemipelvectomy type did not significantly influence outcome.

### Complications after surgery

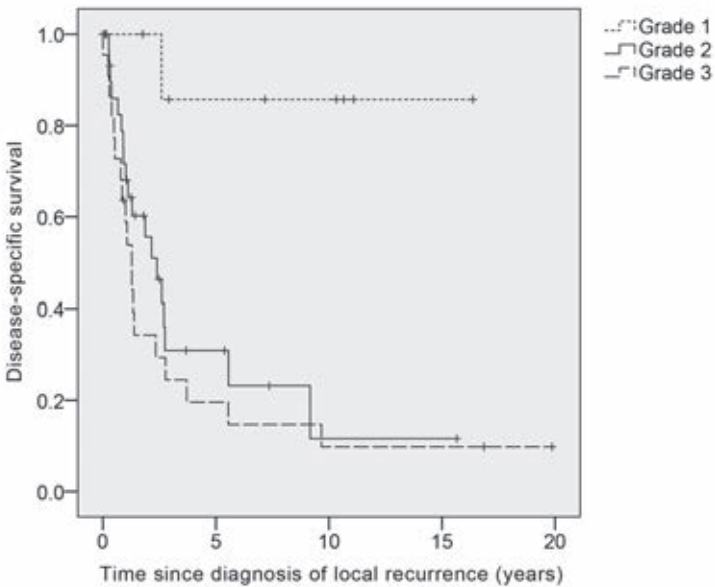
Ninety-five patients (59%) required further operations. The main indications for reoperations were deep infection ( $n=31$  [19%]), wound problems ( $n=20$  [12%]), reconstruction-related complications ( $n=29$  [17%]) and reoperations for local recurrences ( $n=40$ , 25%). There was no significant difference in infection rates between internal hemipelvectomies (27 of 135 [20%]) and hindquarter amputations (4 of 27 [15%]) ( $p = 0.532$ ). Infection was more common in patients with an endoprosthetic reconstruction (18 of 60 [30%]), compared with patients with other types of reconstruction (8 of 45 [18%]) or no reconstruction at all (5 of 57 [9%]) ( $p = 0.014$ ).

Thirteen patients (8%) underwent secondary hindquarter amputation: 10 (6%) for locally residual or recurrent tumors, and three (2%) for infection. One patient (1%) underwent a type BII rotationplasty<sup>27</sup> because of infection. Limb-salvage was achieved in 121 patients (75%).





**Figure 4.** Kaplan-Meier curve demonstrating disease-specific survival stratified according to tumor grade (grade 1, dotted line; grade 2, solid line; grade 3, dashed line).



**Figure 5.** Kaplan-Meier curve demonstrating disease-specific survival measured for patients with a recurrence, measured from the diagnosis of recurrence (grade 1, dotted line; grade 2, solid line; grade 3, dashed line).

**Table 3.** The risk of local recurrence and metastasis in relation to tumor grade and resection margins.

	Total	Recurrence		Metastases	
	N	N	%	N	%
Grade 1					
Wide	9	2	22	0	-
Marginal	12	3	25	0	-
Intralesional	9	4	44	1	11
Grade 2					
Wide	51	9	18	12	24
Marginal	23	10	44	7	30
Intralesional	19	12	63	11	58
Grade 3					
Wide	23	11	48	4	17
Marginal	7	6	86	6	86
Intralesional	9	5	56	7	78

## Discussion

In this multicenter study, we evaluated oncological outcome, risk factors for impaired survival, and postoperative complications in 162 patients who underwent resection of a pelvic conventional primary central chondrosarcoma. Pelvic chondrosarcomas are notoriously difficult to treat and are more often of high grade, and treatment has been associated with worse outcomes than those of extremity chondrosarcoma<sup>16,24,28</sup>. Thirty-four percent of our patients died of disease. Others series on pelvic chondrosarcoma have shown that 20% to 36% of patients died of disease<sup>4,16,20,21</sup>, but these included different subtypes and primary central lesions appear to have a worse prognosis than secondary peripheral tumors<sup>4,19,21,22</sup>.

In concordance with previous studies, tumor grade was the most important prognostic factor for patient survival<sup>4,16,19,21,22,29</sup> (table 5). Of the patients with a grade 1 lesion on the resection specimen, only one (3%) died of disease. Limited surgery may seem attractive for these low-grade pelvic chondrosarcomas, given the excellent survival rates and the favorable clinical outcome reported for curettage of low-grade extremity chondrosarcoma<sup>7</sup>. However, several problems remain to be solved. First, recurrent tumors can be of higher grade than the initial lesion, and recurrence may be regarded as a declaration of a more aggressive subtype<sup>4,5,30,31</sup>. In the current series, four recurrences (6% of 62) were of higher grade than the initial tumor. Second, some lesions appear to be grade I on the biopsy specimen, but they sometimes have a higher grade when later examined on the resected specimen<sup>32,33</sup>. Third,

curettage has been associated with unacceptably high recurrence rates in previous series on pelvic chondrosarcoma<sup>5,31</sup>. Many authors therefore have recommended resection with clear margins for pelvic chondrosarcoma of any grade<sup>1,4-6</sup>. As long as it is not possible to reliably distinguish between grade 1 and higher-grade lesions preoperatively, we concur with previous authors stating that *en bloc* resection is the preferable treatment option for pelvic chondrosarcoma<sup>5,31</sup>.

Tumor grade was also found to be associated with the risk of tumor recurrence. Previous studies showed conflicting results with regard to chondrosarcoma grade and recurrence rates<sup>19,23</sup>. Ninety-five percent of the recurrences occurred within in the first five years after the surgical procedure. Therefore, we recommend close follow-up with an annual MRI scan during the first postoperative years (figure 6), although the utility and accuracy of MRI scans may be hampered by the presence of metallic implants. Alternatively, a CT-scan or fluorine-18 fluorodeoxyglucose positron emission tomography (FDG PET) imaging can be obtained, although less aggressive lesions may not be avid on PET<sup>34</sup>.

Although survival rates after marginal and intralesional resection were nearly identical, wide resection margins were associated with a significant survival advantage. Although wide margins do not eliminate the possibility of recurrent disease<sup>19, 25, 28</sup>, margins were the only treatment-related prognostic factor. After diagnosis of local relapse, the median survival was 2.4 years for grade 2 tumors, and 1.3 years for grade 3 tumors. These poor survival rates, combined with the association between margins and the risk of recurrence and disease-related death, underline the importance of obtaining wide margins during primary resection.

Tumor size was the third most important prognostic factor in our multivariable model; for each centimeter of increase in maximal tumor size, the risk of disease-related death increased by 8%. Others also found an influence of chondrosarcoma size or volume on oncological outcome, but only performed univariable analyses<sup>24, 35, 36</sup>. One study identified a weak influence only on the risk of local recurrence, not survival or metastasis, in multivariable analyses<sup>23</sup>. The presence of soft-tissue infiltration significantly influenced progression-free survival, but failed to reach significance in our analyses on disease-related death. In contrast to our results, Fiorenza *et al* previously reported an influence of soft-tissue infiltration on survival, but not local recurrence, for chondrosarcomas of the axial and appendicular skeleton<sup>23</sup>. In contrast with an earlier study<sup>24</sup>, the prognostic significance of soft tissue infiltration and tumor size in our study suggest that both the Enneking system and the AJCC classification appear to be reasonable

classification systems for pelvic chondrosarcoma<sup>26, 37</sup>. However, neither contain all significant variables that were identified in our study, suggesting a need for a new staging system, although such a system would need to be validated.

**Table 4.** Results of Cox proportional hazards models for disease-specific and progression-free survival

	Univariable analysis		Multivariable analysis	
	p-value	HR	95% CI	p-value
<b>Disease-specific survival (DSS), variables:</b>				
<i>Tumor grade</i>				
Grade 1	-	Ref	-	-
Grade 2	0.009	20.18	2.71 – 150.17	0.003
Grade 3	0.001	58.94	7.67 – 452.89	<0.001
<i>Resection margins</i>				
Wide	-	Ref	-	-
Marginal	0.029	3.21	1.57 – 6.53	0.001
Intralesional	0.008	3.56	1.80 – 7.02	<0.001
<i>Maximal tumor size</i>	0.072	1.08	1.01 – 1.16	0.026
<i>Soft-tissue infiltration (yes vs. no)</i>	0.088	2.37	0.99 – 5.68	0.052
<i>Hemipelvectomy type (internal vs. external)</i>	0.608	1.38	0.64 – 2.97	0.409
<b>Progression-free survival (PFS), variables:</b>				
<i>Tumor grade</i>				
Grade 1	-	Ref	-	-
Grade 2	0.035	2.73	1.26 – 5.90	0.011
Grade 3	<0.001	8.50	3.58 – 20.14	<0.001
<i>Resection margins</i>				
Wide	-	Ref	-	-
Marginal	0.061	2.32	1.29 – 4.16	0.005
Intralesional	0.005	2.36	1.31 – 4.26	0.004
<i>Maximal tumor size</i>	0.062	1.08	1.02 – 1.15	0.013
<i>Soft-tissue infiltration (yes vs. no)</i>	0.005	2.41	1.12 – 5.20	0.024
<i>Hemipelvectomy type (internal vs. external)</i>	0.957	1.88	0.91 – 3.90	0.091

Pelvic resections and reconstructions are notorious for the high risk of postoperative complications, of which infection is the most common. Infected pelvic reconstructions may require aggressive surgical treatment, including removal of reconstruction materials or even, although rarely, hindquarter amputation<sup>38</sup>. Our infection rate (19%) is comparable to previously reported incidences (18% to 32%)<sup>18, 38-42</sup>. The risk of infection was higher for patients after endoprosthetic reconstruction, although this increased risk may have been caused by the fact that these surgical procedures were the most extensive and complicated ones.

Our study had a number of limitations. We included patients who were treated in five different centers between 1985 and 2013. Over the years, available imaging techniques and treatment modalities have changed and have likely influenced our results. Moreover, different pathologists have assessed tumor grades and margins and these were not re-evaluated, although the grading system for chondrosarcoma is inherently subjective and it has been shown that the interobserver reliability of this classification is poor<sup>32,33</sup>. However, we only included patients from referral centers with specialized pathologists and, because of the rarity of this disease, multicenter cooperation is necessary to gain sufficient power. Further research is needed to develop techniques to reliably determine tumor grade and clinical behavior preoperatively, potentially using molecular markers<sup>1</sup>. Also, further study should be directed at the role of limited surgical procedures for low-grade chondrosarcoma of the pelvis. Moreover, the exact margin needed to adequately treat pelvic chondrosarcoma, especially grade 1 lesions, will have to be determined in a prospective study.

In conclusion, this study offers a standard for survival rates for conventional primary central chondrosarcoma of the pelvis. Survival is excellent for patients with a grade 1 tumor and a limited surgical procedure may therefore seem attractive, although we cannot draw conclusions in that regard. However, higher-grade tumors have a substantial risk of disease-related death. We demonstrated that wide resection margins offer a significant survival advantage over marginal and intralesional margins for grade 2 and 3 tumors. Because of the inability to reliably distinguish low-grade and high-grade tumors preoperatively, we conclude that any central pelvic chondrosarcoma should be treated with aggressive primary resection with the aim of obtaining wide resection margins, understanding that there may be aggressive biologic features in some tumors for which a surgical procedure alone may not be adequate to improve outcomes.

Table 5. Overview of literature on pelvic chondrosarcoma.

Reference	Years of surgery	Patients	Chondrosarcoma subtypes	Follow-up	Primary hindquarter amputation	Clear margins	Recurrence	Metastasis	Infection	Limb salvage at time of follow-up	Risk factors for impaired survival	Notes
Donati	1971 - 1999	124	Conventional central (51%) and peripheral (49%)	N/R	24%	Wide margins: 73% of central and 57% of peripheral tumors	18%	8%	N/R	N/R	Tumor grade, internal hemipelvectomy	Curetteage in 1%. No relationship between grade and LR rate (but higher rate of ablative surgery for grade 3 lesions). Central lesions had worse long-term survival (73% at follow-up).
Guo	1997 - 2006	45	Conventional (71%), dedifferentiated (20%), mesenchymal (9%); all involving the periacetabulum	Survivors: mean 3.1 (1.5-9.9) Deceased: mean 3.6 (0.6-5.9)	13%	84%	22%	22%	11%	N/R	-	29% of the patients were initially treated elsewhere. No association between obtained margins and the occurrence of metastases.
Mavrogenis	1975 - 2008	215	Primary or secondary conventional central (55%), peripheral (40%), not specified (4%), periosteal (1%)	Mean 8.6 (2-31)	19%	84%	30%	14% (of the patients without metastases at diagnosis)	N/R	N/R	Tumor grade	Curetteage in 3%. Tumor grade was the most important prognostic factor. Patients with a periacetabular lesion had worse survival.
Mochizuki	1989 - 1998	135	N/R	Mean 3.9 (0.3-10.0)	10%	79%	24%	19%	19%	N/R	Tumor stage, site, size and achieved margins	Patients included from 58 institutions.
Sheth	1970 - 1992	67	Primary or secondary conventional (81%) and dedifferentiated (19%)	Survivors: median 9.6 (2.0-24.0) Deceased: median 0.9 (0.0-10.3)	52%	57%	28%	36%	N/R	N/R	Tumor grade	Inadequate margins, tumor epicenter in the pubis, and tumor grade were associated with an increased risk of local recurrence.

Table 5. continued

Reference	Years of surgery	Patients	Chondrosarcoma subtypes	Follow-up	Primary hindquarter amputation	Clear margins	Recurrence	Metastasis	Infection	Limb salvage at time of follow-up	Risk factors for impaired survival	Notes
Deloin	1968 - 2003	59	Primary (n=47), secondary (n=9) and multiple (n=3)	Survivors: mean 10.3 (4.0-22.7) Deceased: mean 5.6 (0.3-26.0)	19%	81%	31%	20%	10%	75%	Resection margins, tumor grade, acetabular involvement	-
Ozaki	1970 - 1993	31	Primary (n=23) and secondary (n=8)	Median 5.0 years (0.3-22.3)	26%	Wide margins: 26%	45%	6%	16%	61%	Tumor grade	Resection margin correlated with local recurrence rate.
Pring	1975 - 1996	64	Primary (n=49) or secondary (n=15); conventional (n=57) and dedifferentiated (n=7)	Survivors: median 11.7 (3.3-24.6)	20%	83%	19%	17%	13%	80%	Tumor grade, tumor stage and having a primary lesion.	Curettage in 5%. Resection margin correlated with local recurrence rate.
Wirbel	1978 - 1998	51	N/R	Mean 6.1 (0.3-19.1)	25%	84%	20%	35%	20%	69%	Tumor stage, resection margin	Two perioperative deaths.
Current study	1985 - 2013	162	Conventional primary central	Survivors: median 9.2 (2.0-27.5) Deceased: median 3.0 (0.1-15.1)	17%	77%	38%	30%	19%	75%	Tumor grade, resection margins, tumor size, soft-tissue infiltration	-

## References

1. Gelderblom H, Hogendoorn PC, Dijkstra SD, van Rijswijk CS, Krol AD, Taminiau AH, et al. The clinical approach towards chondrosarcoma. *The oncologist*. 2008 Mar;13(3):320-9. Epub 2008/04/02.
2. Bovee JV, Hogendoorn PC, Wunder JS, Alman BA. Cartilage tumours and bone development: molecular pathology and possible therapeutic targets. *Nature reviews Cancer*. 2010 Jul;10(7):481-8. Epub 2010/06/11.
3. Giuffrida AY, Burgueno JE, Koniaris LG, Gutierrez JC, Duncan R, Scully SP. Chondrosarcoma in the United States (1973 to 2003): an analysis of 2890 cases from the SEER database. *The Journal of bone and joint surgery American volume*. 2009 May;91(5):1063-72. Epub 2009/05/05.
4. Mavrogenis AF, Angelini A, Drago G, Merlino B, Ruggieri P. Survival analysis of patients with chondrosarcomas of the pelvis. *Journal of surgical oncology*. 2013 Jul;108(1):19-27. Epub 2013/05/18.
5. Streiburger A, Ahrens H, Balke M, Buerger H, Winkelmann W, Gosheger G, et al. Grade I chondrosarcoma of bone: the Munster experience. *Journal of cancer research and clinical oncology*. 2009 Apr;135(4):543-50. Epub 2008/10/16.
6. Angelini A, Guerra G, Mavrogenis AF, Pala E, Picci P, Ruggieri P. Clinical outcome of central conventional chondrosarcoma. *Journal of surgical oncology*. 2012 Dec;106(8):929-37. Epub 2012/06/01.
7. Verdegaal SH, Brouwers HF, van Zwet EW, Hogendoorn PC, Taminiau AH. Low-grade chondrosarcoma of long bones treated with intralesional curettage followed by application of phenol, ethanol, and bone-grafting. *The Journal of bone and joint surgery American volume*. 2012 Jul 3;94(13):1201-7. Epub 2012/07/05.
8. Meftah M, Schult P, Henshaw RM. Long-term results of intralesional curettage and cryosurgery for treatment of low-grade chondrosarcoma. *The Journal of bone and joint surgery American volume*. 2013 Aug 7;95(15):1358-64. Epub 2013/08/09.
9. Grimer RJ, Chandrasekar CR, Carter SR, Abudu A, Tillman RM, Jeys L. Hindquarter amputation: is it still needed and what are the outcomes? *The bone & joint journal*. 2013 Jan;95-b(1):127-31. Epub 2013/01/12.
10. Carter SR, Eastwood DM, Grimer RJ, Sneath RS. Hindquarter amputation for tumours of the musculoskeletal system. *The Journal of bone and joint surgery British volume*. 1990 May;72(3):490-3. Epub 1990/05/01.
11. Griesser MJ, Gillette B, Crist M, Pan X, Muscarella P, Scharschmidt T, et al. Internal and external hemipelvectomy or flail hip in patients with sarcomas: quality-of-life and functional outcomes. *American journal of physical medicine & rehabilitation / Association of Academic Physiatrists*. 2012 Jan;91(1):24-32. Epub 2011/11/02.
12. Masterson EL, Davis AM, Wunder JS, Bell RS. Hindquarter amputation for pelvic tumors. The importance of patient selection. *Clinical orthopaedics and related research*. 1998 May(350):187-94. Epub 1998/05/29.
13. Bus MP, Boerhout EJ, Bramer JA, Dijkstra PD. Clinical outcome of pedestal cup endoprosthetic reconstruction after resection of a peri-acetabular tumour. *The bone & joint journal*. 2014 Dec;96-b(12):1706-12. Epub 2014/12/03.
14. Bus MP, Szafranski A, Sellevold S, Goryn T, Jutte PC, Bramer JA, et al. LUMiC® Endoprosthetic Reconstruction After Periacetabular Tumor Resection: Short-term Results. *Clinical orthopaedics and related research*. 2016 Mar 28.
15. Weber KL, Pring ME, Sim FH. Treatment and outcome of recurrent pelvic chondrosarcoma. *Clinical orthopaedics and related research*. 2002 Apr(397):19-28. Epub 2002/04/16.
16. Pring ME, Weber KL, Unni KK, Sim FH. Chondrosarcoma of the pelvis. A review of sixty-four cases. *The Journal of bone and joint surgery American volume*. 2001 Nov;83-a(11):1630-42. Epub 2001/11/10.
17. Kawai A, Healey JH, Boland PJ, Lin PP, Huvos AG, Meyers PA. Prognostic factors for patients with sarcomas of the pelvic bones. *Cancer*. 1998 Mar 1;82(5):851-9. Epub 1998/03/05.
18. Angelini A, Calabro T, Pala E, Trovarelli G, Maraldi M, Ruggieri P. Resection and reconstruction of pelvic bone tumors. *Orthopedics*. 2015 Feb 1;38(2):87-93. Epub 2015/02/11.
19. Donati D, El Ghoneimy A, Bertoni F, Di Bella C, Mercuri M. Surgical treatment and outcome of conventional pelvic chondrosarcoma. *The Journal of bone and joint surgery British volume*. 2005 Nov;87(11):1527-30. Epub 2005/11/02.



20. Guo W, Li D, Tang X, Ji T. Surgical treatment of pelvic chondrosarcoma involving periacetabulum. *Journal of surgical oncology*. 2010 Feb 1;101(2):160-5. Epub 2009/12/05.
21. Sheth DS, Yasko AW, Johnson ME, Ayala AG, Murray JA, Romsdahl MM. Chondrosarcoma of the pelvis. Prognostic factors for 67 patients treated with definitive surgery. *Cancer*. 1996 Aug 15;78(4):745-50. Epub 1996/08/15.
22. Ozaki T, Hillmann A, Lindner N, Blasius S, Winkelmann W. Chondrosarcoma of the pelvis. *Clinical orthopaedics and related research*. 1997 Apr(337):226-39. Epub 1997/04/01.
23. Fiorenza F, Abudu A, Grimer RJ, Carter SR, Tillman RM, Ayoub K, et al. Risk factors for survival and local control in chondrosarcoma of bone. *The Journal of bone and joint surgery British volume*. 2002 Jan;84(1):93-9. Epub 2002/02/12.
24. Andreou D, Ruppin S, Fehlberg S, Pink D, Werner M, Tunn PU. Survival and prognostic factors in chondrosarcoma: results in 115 patients with long-term follow-up. *Acta orthopaedica*. 2011 Dec;82(6):749-55. Epub 2011/11/10.
25. Evans HL, Ayala AG, Romsdahl MM. Prognostic factors in chondrosarcoma of bone: a clinicopathologic analysis with emphasis on histologic grading. *Cancer*. 1977 Aug;40(2):818-31. Epub 1977/08/01.
26. Enneking WF, Spanier SS, Goodman MA. A system for the surgical staging of musculoskeletal sarcoma. *Clinical orthopaedics and related research*. 1980 Nov-Dec(153):106-20. Epub 1980/11/01.
27. Winkelmann WW. Rotationplasty. *The Orthopedic clinics of North America*. 1996 Jul;27(3):503-23. Epub 1996/07/01.
28. Bjornsson J, McLeod RA, Unni KK, Ilstrup DM, Pritchard DJ. Primary chondrosarcoma of long bones and limb girdles. *Cancer*. 1998 Nov 15;83(10):2105-19. Epub 1998/11/25.
29. Wirbel RJ, Schulte M, Maier B, Koschnik M, Mutschler WE. Chondrosarcoma of the pelvis: oncologic and functional outcome. *Sarcoma*. 2000;4(4):161-8. Epub 2008/06/04.
30. Schwab JH, Wenger D, Unni K, Sim FH. Does local recurrence impact survival in low-grade chondrosarcoma of the long bones? *Clinical orthopaedics and related research*. 2007 Sep;462:175-80. Epub 2007/05/22.
31. Normand AN, Cannon CP, Lewis VO, Lin PP, Yasko AW. Curettage of biopsy-diagnosed grade 1 periacetabular chondrosarcoma. *Clinical orthopaedics and related research*. 2007 Jun;459:146-9. Epub 2007/04/25.
32. SLICED Study Group. Reliability of histopathologic and radiologic grading of cartilaginous neoplasms in long bones. *The Journal of bone and joint surgery American volume*. 2007 Oct;89(10):2113-23. Epub 2007/10/03.
33. Eefting D, Schrage YM, Geirnaerd MJ, Le Cessie S, Taminiau AH, Bovee JV, et al. Assessment of interobserver variability and histologic parameters to improve reliability in classification and grading of central cartilaginous tumors. *The American journal of surgical pathology*. 2009 Jan;33(1):50-7. Epub 2008/10/15.
34. Brenner W, Conrad EU, Eary JF. FDG PET imaging for grading and prediction of outcome in chondrosarcoma patients. *Eur J Nucl Med Mol Imaging*. 2004 Feb;31(2):189-95.
35. Lee FY, Mankin HJ, Fondren G, Gebhardt MC, Springfield DS, Rosenberg AE, et al. Chondrosarcoma of bone: an assessment of outcome. *The Journal of bone and joint surgery American volume*. 1999 Mar;81(3):326-38. Epub 1999/04/13.
36. Mochizuki K, Yamaguchi H, Umeda T. The management of pelvic chondrosarcoma in Japan. *Japanese Musculo-Skeletal Oncology Group. International orthopaedics*. 2000;24(2):65-70. Epub 2000/07/14.
37. Greene F, Page D, Fleming I. *AJCC manual of staging of cancer*. New York, NY: SpringerVerlag. 2002.
38. Angelini A, Drago G, Trovarelli G, Calabro T, Ruggieri P. Infection after surgical resection for pelvic bone tumors: an analysis of 270 patients from one institution. *Clinical orthopaedics and related research*. 2014 Jan;472(1):349-59. Epub 2013/08/27.
39. Mavrogenis AF, Soultanis H, Patapis P, Guerra G, Fabbri N, Ruggieri P, et al. Pelvic resections K. *Orthopedics*. 2012 Feb;35(2):e232-43. Epub 2012/02/09.
40. Gebert C, Wessling M, Hoffmann C, Roedel R, Winkelmann W, Gosheger G, et al. Hip transposition as a limb salvage procedure following the resection of periacetabular tumors. *Journal of surgical oncology*. 2011 Mar 1;103(3):269-75. Epub 2011/02/22.

41. Jaiswal PK, Aston WJ, Grimer RJ, Abudu A, Carter S, Blunn G, et al. Peri-acetabular resection and endoprosthetic reconstruction for tumours of the acetabulum. *The Journal of bone and joint surgery British volume*. 2008 Sep;90(9):1222-7. Epub 2008/09/02.
42. Hillmann A, Hoffmann C, Gosheger G, Rodl R, Winkelmann W, Ozaki T. Tumors of the pelvis: complications after reconstruction. *Archives of orthopaedic and trauma surgery*. 2003 Sep;123(7):340-4. Epub 2003/07/03.