



Universiteit  
Leiden

The Netherlands

## Multimodality Imaging of Anatomy and Function in Coronary Artery Disease

Schuijf, J.D.

### Citation

Schuijf, J. D. (2007, October 18). *Multimodality Imaging of Anatomy and Function in Coronary Artery Disease*. Retrieved from <https://hdl.handle.net/1887/12423>

Version: Corrected Publisher's Version

License: [Licence agreement concerning inclusion of doctoral thesis in the Institutional Repository of the University of Leiden](#)

Downloaded from: <https://hdl.handle.net/1887/12423>

**Note:** To cite this publication please use the final published version (if applicable).

# Chapter 23

## **Assessment of Left Ventricular Volumes and Ejection Fraction with 16-slice Multi-Slice Computed Tomography; Comparison with 2D-Echocardiography**

Joanne D. Schuijf, Jeroen J. Bax, J. Wouter Jukema, Hildo J. Lamb, Liesbeth P. Salm, Albert de Roos, Ernst E. van der Wall

# Abstract

## Background

In recent years, Multi-Slice Computed Tomography (MSCT) has emerged as a rapidly expanding modality for non-invasive assessment of coronary artery disease. Simultaneously, left ventricular (LV) function can be evaluated although this is not yet a routine component of an MSCT examination. Accordingly, the purpose of the present study was to validate assessment of LV function with MSCT using 2D-echocardiography in a large cohort of patients.

## Methods

In 70 patients (57 male, 13 female), 16-slice MSCT was performed (Toshiba Aquilion 16, Japan) followed by retrospective analysis of global LV function. For these measurements 2D-echocardiography served as the standard of reference.

## Results

For LV volumes, excellent correlations for both end-diastolic volume (EDV) ( $r=0.97$ ) and end-systolic volume (ESV) ( $r=0.98$ ) were obtained by linear regression analysis. At Bland-Altman analysis, mean differences ( $\pm$  standard deviations) of  $-1.4 \text{ ml} \pm 11.3 \text{ ml}$  and  $-3.0 \text{ ml} \pm 7.7 \text{ ml}$  were observed between MSCT and 2D-echocardiography for LV EDV and LV ESV respectively. As a result, LV EF was slightly overestimated with MSCT ( $1.7\% \pm 4.9\%$ ,  $P<0.05$ ). Correlation between the two techniques was excellent ( $r= 0.91$ ).

## Conclusion

In a large cohort of patients, an excellent correlation was observed between 16-slice MSCT and 2D-echocardiography in the evaluation of LV volumes and EF. The addition of LV function analysis to the anatomical MSCT data may potentially enhance the diagnostic value of the technique.

## Introduction

Recently, MSCT has emerged as a rapidly progressing and expanding modality for non-invasive assessment of coronary anatomy. Pooled analysis of recent studies, using 16-slice technology, has shown an average sensitivity and specificity of 88% and 96% in the detection of significant coronary artery stenoses<sup>1</sup>. Accordingly, the expectation is that the technique will become increasingly used as an alternative modality to evaluate the presence of coronary artery disease in patients presenting with chest pain and having risk factors for coronary artery disease. In these patient populations, additional assessment of cardiac function is often desired for prognostic purposes<sup>2</sup>. Generally, this implies an additional examination with Magnetic Resonance Imaging (MRI), or more frequently, echocardiography. MRI is currently the gold standard in the assessment of left ventricular (LV) volumes and ejection fractions (EF), but is a relatively costly and time-consuming technique. As a result, the technique is not widely available for application in larger patient populations. Thus, in daily clinical practice, 2D-echocardiography is routinely performed to assess function as it is more widely available and associated with lower costs.

Functional parameters, however, can also be retrospectively obtained from a MSCT coronary angiography examination since the data are acquired in a helical mode during ECG gating. As a result, a high-resolution 3D volume set is obtained that allows retrospective reconstruction of short-axis images during the entire cardiac cycle. Indeed, the feasibility of additional LV function analysis during MSCT coronary angiography has been demonstrated in previous studies, comparing data to other imaging modalities, including MRI or 2D-echocardiography<sup>3-6</sup>. Thus far, these data have been obtained in relatively small patient populations while using older 4-slice MSCT systems in the majority of studies. Accordingly, the purpose of the present study was to compare 16-slice MSCT to 2D-echocardiography in a relatively large patient population.

## Methods

### Patients and protocol

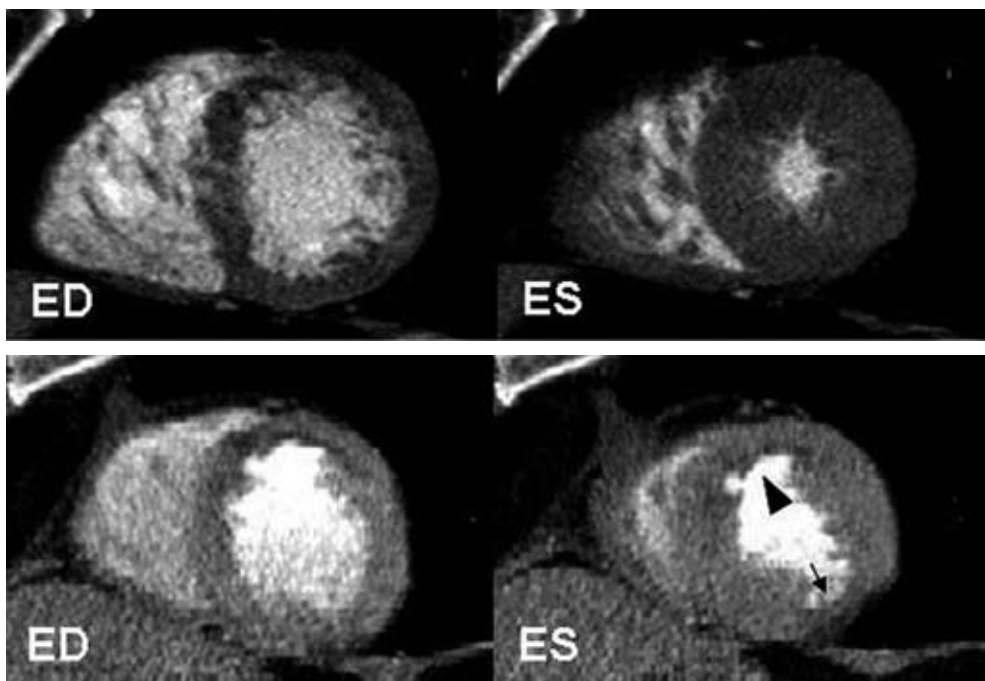
The study group consisted of 70 patients presenting to our outpatient clinic for the evaluation of novel or recurrent chest pain. All patients underwent an MSCT examination as part of ongoing protocols at our institution concerning the evaluation of coronary artery disease with MSCT. For comparison, 2D-echocardiography was performed in all patients. Exclusion criteria were: 1. atrial fibrillation (2 patients excluded), 2. renal insufficiency (serum creatinine >120 mmol/L), 3. known allergy to iodine contrast media (1 patient excluded), 4. severe claustrophobia, and 5. pregnancy. All patients gave written informed consent to the study protocol, which was approved by the local ethics committee.

## MSCT; Data acquisition

MSCT was performed using a Toshiba Multi-Slice Aquilion 16 system (Toshiba Medical Systems, Tokyo, Japan) with a collimation of 16 x 0.5 mm. Rotation time was 0.4s or 0.5s, depending on the heart rate, while the tube current was 250 mA, at 120 kV. Non-ionic contrast material was administered in the antecubital vein with an amount of 120-150 ml, depending on the total scan time and a flow rate of 4.0 ml/sec (Xenetix 300°, Guerbet, Aulnay S. Bois, France). Automated peak enhancement detection in the aortic root was used for timing of the scan. In all patients, the heart was imaged from the aortic root to the cardiac apex during inspiratory breath hold preceded by mild hyperventilation. During the examination, the ECG was recorded simultaneously for retrospective gating of the data.

## MSCT; Data analysis

For the evaluation of LV function, data sets were reconstructed in the short-axis orientation at 20 different time points and subsequently transferred to a dedicated cardiac analysis program



**Figure 1.** Example of 16-slice MSCT short-axis reconstructions in end-diastole and end-systole to assess global LV function.

In Figure 1A, an example is provided of a patient with a normal LV EF of 67%. In all LV wall segments, normal contractility can be observed.

In Figure 1B, a patient with a decreased LV EF of 26% is shown. In both the anterior region (arrowhead) as well as inferolateral (arrow) reduced wall motion and thickening is present.

*Abbreviations: ED: end-diastole, ES: end-systole*

(MR Analytical Software System [MASS], Medis, Leiden, the Netherlands) running on a remote workstation. On the short-axis cine images, endocardial contours were outlined from the base to the apex manually by an independent observer in both end-diastole and end-systole. Papillary muscles were regarded as being part of the ventricular cavity. LV end-systolic (ESV) and end-diastolic volumes (EDV) were calculated using commercially available software (CT-MASS, Medis, Leiden, The Netherlands) by summation of the product (area x slice distance) of all included slices. Finally, the related LV EF was derived by subtracting the end-systolic volume from the volume at end-diastole and dividing the result by the end-diastolic volume.

## 2D-echocardiography

2D-echocardiography was performed in the left lateral decubitus position using a Vingmed System FiVe/Vivid-7 (General Electric-Vingmed, Milwaukee, WI, USA). Images were acquired using a 3.5 MHz transducer at a depth of 16 cm in the parasternal and apical 2-, 4- and 5-chamber views. LV volumes and EFs were calculated by an independent observer without knowledge of the MSCT data from the 2- and 4-chamber images using the biplane Simpson's rule and commercially available software (Echopac 6.1, General Electric-Vingmed)<sup>7-9</sup>.

## Statistical analysis

Continuous data are expressed as mean  $\pm$  standard deviations (SD). Agreement for global LV function (EDV, ESV, EF) was determined by Pearson's correlation coefficient for linear regression and Bland-Altman analysis<sup>10</sup>. The 95% limits of agreement were defined as the range of values  $\pm$  2SD from the mean difference. The statistical significance of the mean difference between the different modalities was tested by Student's *t* test for paired samples. A *p*-value  $<0.05$  was considered to be significant.

# Results

## Patient characteristics

A total of 70 patients (57 male, 13 female) with an average age of  $66 \pm 11$  years was included in the study and underwent MSCT as well as 2D-echocardiography without complications. Average heart rate during the MSCT studies was  $66 \pm 11$  beats per minute, ranging between 41 beats per minute to 98 beats per minute. No additional beta-blocking medication was administered prior to MSCT imaging. Previous percutaneous transluminal coronary angioplasty was performed in 32 (46%) patients, whereas 24 (34%) patients had undergone previous coronary bypass grafting. Previous myocardial infarction was present in 31 (44%) patients (anterior wall infarction;  $n=15$ , inferior wall infarction;  $n=16$ ). Examples of short-axis reconstructions of patients with respectively normal and decreased LV EF are provided in Figure 1.

**Table 1.** Comparison of MSCT to 2D-echocardiography in 70 patients.

Parameter	Mean MSCT	Mean 2D echo	Mean Difference	Pearson (r)	t Test (P-value)
EDV (ml)	151.5 ± 40.1 (70.6, 251.3)	152.9 ± 42.9 (64, 251.0)	1.4 ± 11.3	0.97	>0.05
ESV (ml)	74.8 ± 35.2 (22.9, 172.0)	77.9 ± 35.6 (21.0, 183.0)	3.0 ± 7.7	0.98	<0.05
EF (%)	52.2 ± 11.7 (20.5, 73.5)	50.5 ± 12.0 (19.7, 79.6)	-1.7 ± 4.9	0.91	<0.05

Data are mean values ± standard deviation (minimum value, maximum value).

Abbreviations: EDV: end-diastolic volume, EF: ejection fraction, ESV: end-systolic volume, MSCT: multi-slice computed tomography.

## LV Volumes and EF

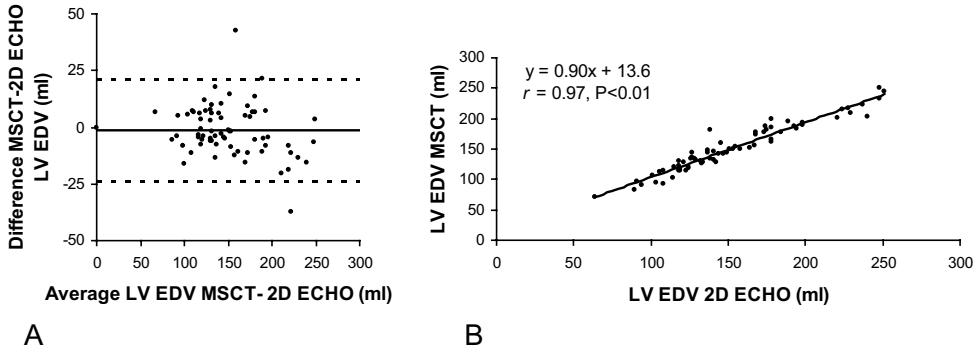
Time to reconstruct the required phases and to calculate LV volumes and EF was approximately 10 to 15 minutes. Mean values of all variables are provided in Table 1. Excellent correlations were demonstrated by linear regression analysis for both LV EDV and ESV, respectively  $r=0.97$  and  $r=0.98$  (Figures 2A and 3A). At Bland-Altman analysis (Figures 2B and 3B) both parameters were shown to be slightly underestimated with MSCT with mean differences (and limits of agreement) of respectively -1.4 ml (-24 ml to 21 ml,  $P>0.05$ ) and -3.0 ml (-18.5 ml to 12.4 ml,  $P<0.05$ ). For LV EF a slightly lower correlation of 0.91 was observed between the two modalities (Figure 4A) with a small but significant overestimation of LV EF by MSCT (1.7% and -8.0% to 11.5%,  $P<0.05$ ) (Figure 4B).

In addition, intra- and interobserver variability were evaluated and resulted in a mean difference of  $-0.13\% \pm 2.4\%$  and  $1.1\% \pm 1.9\%$  for LV EF, respectively. Intraobserver variabilities for LV EDV and LV ESV were respectively  $0.82 \text{ ml} \pm 7.7 \text{ ml}$  and  $-0.53 \text{ ml} \pm 7.6 \text{ ml}$ , whereas mean interobserver differences for LV EDV and LV ESV were  $-1.23 \text{ ml} \pm 6.0 \text{ ml}$  and  $-1.77 \text{ ml} \pm 4.9 \text{ ml}$ , respectively.

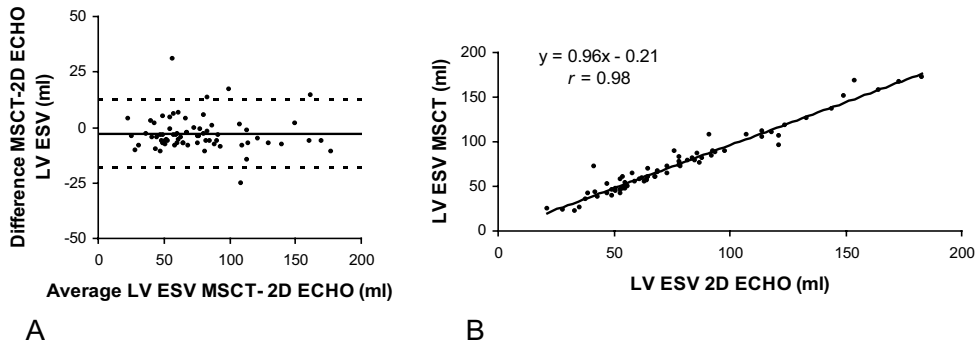
## Discussion

In patients with coronary artery disease, LV chamber volumes and EF are independent and important predictors of morbidity and mortality<sup>2,11</sup>. Accordingly, information of LV function is frequently required in these populations to determine further clinical management. In recent years, MSCT has emerged as a rapidly expanding imaging modality that allows the acquisition of high-resolution, 3D imaging of the entire heart and coronary arteries within a single breath hold<sup>12</sup>. Simultaneously, the technique can also be used to assess cardiac chamber anatomy and function<sup>3-6</sup>. Thus, in a single examination of approximately 15 minutes, information of coronary anatomy and LV function is obtained. However, data thus far have been obtained in limited patient populations and validations in larger populations have not been performed yet.

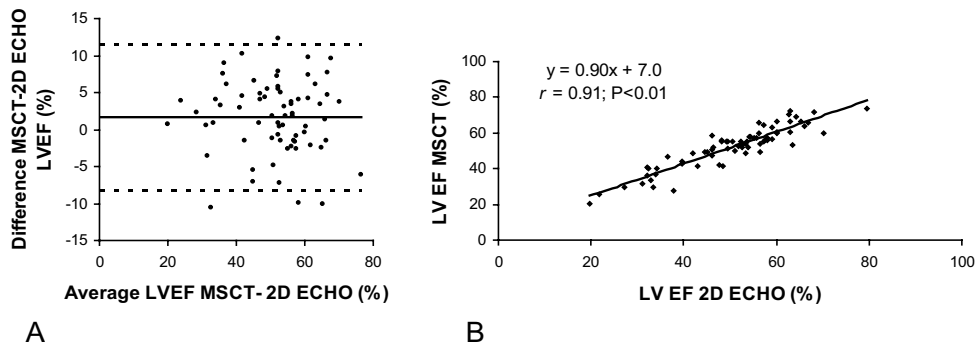
In the present study, global LV function analysis was performed using 16-slice MSCT in 70 patients



**Figure 2.** Linear regression (a) and Bland-Altman (b) plots in the comparison of MSCT and 2D-echocardiography in the assessment of LV EDV. In the Bland-Altman plot, the difference between each pair is plotted against the average value of the same pair (solid line, mean value of differences; dotted lines, mean value of differences  $\pm 2$  SD). Abbreviations: EDV: end-diastolic volume, LV: left ventricular, MSCT: multi-slice computed tomography.



**Figure 3.** Linear regression (a) and Bland-Altman (b) plots in the comparison of MSCT and 2D-echocardiography in the assessment of LV ESV. In the Bland-Altman plot, the difference between each pair is plotted against the average value of the same pair (solid line, mean value of differences; dotted lines, mean value of differences  $\pm 2$  SD). Abbreviations: ESV: end-systolic volume, LV: left ventricular, MSCT: multi-slice computed tomography.



**Figure 4.** Linear regression (a) and Bland-Altman (b) plots in the comparison of MSCT and 2D-echocardiography in the assessment of LV EF. In the Bland-Altman plot, the difference between each pair is plotted against the average value of the same pair (solid line, mean value of differences; dotted lines, mean value of differences  $\pm 2$  SD). Abbreviations: EF: ejection fraction, LV: left ventricular, MSCT: multi-slice computed tomography.



and compared to 2D-echocardiography. Excellent correlations,  $r=0.97$  and  $r=0.98$  respectively, were observed between MSCT and 2D-echocardiography in the assessment of LV EDV and ESV. For both variables a small underestimation ( $<5$  ml) with MSCT as compared to 2D-echocardiography was observed, which was significant for LV ESV. As a result, LV EF was slightly overestimated by MSCT with an average of  $1.7 \pm 4.9\%$ . Correlation between the two modalities in the assessment of LV EF was still excellent with an  $r$ -value of 0.91.

These findings are in line with previous observations obtained in smaller patient populations<sup>3,13</sup>. An initial comparison of LV EF derived from 4-slice MSCT and 2D-echocardiography in 15 patients presenting with unstable angina was described by Dirksen et al, who observed an excellent correlation between both modalities of 0.93 although MSCT underestimated LV EF with an average of  $-1.3 \pm 4.5\%$ <sup>3</sup>. More recently, results of LV functional analysis with 16-slice MSCT and 2D-echocardiography in 19 patients has been published, demonstrating excellent correlations between the two techniques<sup>13</sup>. In line with our study, a small overestimation of LV EF of 2.9% on average was observed. Thus far, two studies have reported on comparisons of LV function parameters between multiple modalities including MSCT (8- and 16-slice)<sup>5,14</sup>. In both studies, performed in 41 and 24 patients respectively, a closer agreement was observed between MSCT and MRI than between 2D-echocardiography and MSCT, suggesting that MSCT may actually be more accurate than 2D-echocardiography. Indeed, particularly in patients with coronary artery disease, the 3D approach of MSCT is likely to provide superior measurements as compared to echocardiography, since the geometrical assumptions that are needed with the latter may frequently result in significant errors in volumetric calculations. On the other hand, the accuracy of MRI is not likely to be surpassed by MSCT in the near future, as temporal resolution of the former remains at present superior.

In addition, reproducibility of the LV measurements was evaluated in the present study, and excellent agreement was observed, with a mean difference of  $-0.13\% \pm 2.4\%$  and  $1.1\% \pm 1.9\%$  for LV EF (intra- and interobserver variability respectively). Accordingly, LV measurements obtained with MSCT appear to be highly reproducible.

## Limitations

Several limitations need to be acknowledged. A disadvantage of MSCT in general is the radiation exposure of 9 to 15 mSv during a single examination. Preferably, functional testing should be repeated during stress conditions to detect early ischemia and thus further enhance risk stratification. However, as such a protocol with MSCT would imply a second radiation dose and contrast material delivery, repeated imaging remains at least at present undesirable. Moreover, with regard to the radiation dose, use of the technique solely for the purpose of functional analysis cannot be not justified. Post-processing time, including the drawing of endocardial contours, is still relatively time-consuming for LV function analysis. Future improvements in image quality, as expected with the recently introduced 64-slice systems, would allow considerable reduction in post-processing time by enabling more accurate and rapid automated endocardial border detection. Another limitation of the present study is the fact that functional parameters were compared to 2D-echocardiography

rather than the current gold standard for volumetric measurement, MRI. In daily clinical practice however, LV function is most commonly assessed by means of 2D-echocardiography as it is a widely available technique associated with relatively low costs. Finally, as the indications for performing MSCT, and thus the precise patient populations that may potentially benefit from this technique, are still under definition, the precise incremental value additional LV EF calculation would provide is also at present unclear.

## **Conclusion**

The present study confirms that reliable assessment of LV volumes and EF is possible with MSCT. As recent years have witnessed a rapid and continuous advancement of the technique, it is anticipated that MSCT will increasingly be used for routine evaluation of CAD in certain subsets of patients prior to more invasive investigations. The addition of LV functional parameters to the angiographic information would entail the addition of a frequently needed prognostic marker to the examination, thereby potentially enhancing the diagnostic value of an MSCT investigation.

## References

1. Schuijf JD, Bax JJ, Shaw LJ, de Roos A, Lamb HJ, van der Wall EE, Wijns W. Meta-analysis of comparative diagnostic performance of magnetic resonance imaging and multislice computed tomography for non-invasive coronary angiography. *Am Heart J*. 2006;151:404-411.
2. White HD, Norris RM, Brown MA, Brandt PW, Whitlock RM, Wild CJ. Left ventricular end-systolic volume as the major determinant of survival after recovery from myocardial infarction. *Circulation*. 1987;76:44-51.
3. Dirksen MS, Bax JJ, de Roos A, Jukema JW, van der Geest RJ, Geleijns K, Boersma E, van der Wall EE, Lamb HJ. Usefulness of dynamic multislice computed tomography of left ventricular function in unstable angina pectoris and comparison with echocardiography. *Am J Cardiol*. 2002;90:1157-1160.
4. Grude M, Juergens KU, Wichter T, Paul M, Fallenberg EM, Muller JG, Heindel W, Breithardt G, Fischbach R. Evaluation of global left ventricular myocardial function with electrocardiogram-gated multidetector computed tomography: comparison with magnetic resonance imaging. *Invest Radiol*. 2003;38:653-661.
5. Heuschmid M, Rothfuss JK, Schroeder S, Fenchel M, Stauder N, Burgstahler C, Franow A, Kuzo RS, Kuettnner A, Miller S, Claussen CD, Kopp AF. Assessment of left ventricular myocardial function using 16-slice multidetector-row computed tomography: comparison with magnetic resonance imaging and echocardiography. *Eur Radiol*. 2005;1-9.
6. Juergens KU, Grude M, Maintz D, Fallenberg EM, Wichter T, Heindel W, Fischbach R. Multi-detector row CT of left ventricular function with dedicated analysis software versus MR imaging: initial experience. *Radiology*. 2004;230:403-410.
7. Schiller NB, Acquatella H, Ports TA, Drew D, Goerke J, Ringertz H, Silverman NH, Brundage B, Botvinick EH, Boswell R, Carlsson E, Parmley WW. Left ventricular volume from paired biplane two-dimensional echocardiography. *Circulation*. 1979;60:547-555.
8. Gordon EP, Schnittger I, Fitzgerald PJ, Williams P, Popp RL. Reproducibility of left ventricular volumes by two-dimensional echocardiography. *J Am Coll Cardiol*. 1983;2:506-513.
9. Otterstad JE, Froeland G, St John SM, Holme I. Accuracy and reproducibility of biplane two-dimensional echocardiographic measurements of left ventricular dimensions and function. *Eur Heart J*. 1997;18:507-513.
10. Bland JM, Altman DG. Statistical methods for assessing agreement between two methods of clinical measurement. *Lancet*. 1986;1:307-310.
11. White HD, Norris RM, Brown MA, Takayama M, Maslowski A, Bass NM, Ormiston JA, Whitlock T. Effect of intravenous streptokinase on left ventricular function and early survival after acute myocardial infarction. *N Engl J Med*. 1987;317:850-855.
12. Mollet NR, Cademartiri F, Krestin GP, McFadden EP, Arampatzis CA, Serruys PW, de Feyter PJ. Improved diagnostic accuracy with 16-row multi-slice computed tomography coronary angiography. *J Am Coll Cardiol*. 2005;45:128-132.
13. Kim TH, Hur J, Kim SJ, Kim HS, Choi BW, Choe KO, Yoon YW, Kwon HM. Two-phase reconstruction for the assessment of left ventricular volume and function using retrospective ECG-gated MDCT: comparison with echocardiography. *AJR Am J Roentgenol*. 2005;185:319-325.
14. Yamamuro M, Tadamura E, Kubo S, Toyoda H, Nishina T, Ohba M, Hosokawa R, Kimura T, Tamaki N, Kameda M, Kita T, Konishi J. Cardiac functional analysis with multi-detector row CT and segmental reconstruction algorithm: comparison with echocardiography, SPECT, and MR imaging. *Radiology*. 2005;234:381-390.