



Universiteit
Leiden
The Netherlands

Tailoring therapy in endometrial and cervical cancer

Gent, M.D.J.M. van

Citation

Gent, M. D. J. M. van. (2017, June 20). *Tailoring therapy in endometrial and cervical cancer*. Retrieved from <https://hdl.handle.net/1887/51101>

Version: Not Applicable (or Unknown)

License: [Licence agreement concerning inclusion of doctoral thesis in the Institutional Repository of the University of Leiden](#)

Downloaded from: <https://hdl.handle.net/1887/51101>

Note: To cite this publication please use the final published version (if applicable).

Cover Page



Universiteit Leiden



The handle <http://hdl.handle.net/1887/51101> holds various files of this Leiden University dissertation

Author: Gent, M.D.J.M. van

Title: Tailoring therapy in endometrial and cervical cancer

Issue Date: 2017-06-20

BIBLIOGRAPHY

M.D.J.M. van Gent, M. Rademaker, J.C.B. van der Veer, MIE van Poelgeest, KN Gaarenstroom, JB Trimbos en CD de Kroon. Long term oncological outcome after conventional radical hysterectomy versus two nerve-sparing modalities for early stage cervical cancer 2017. Accepted

M.D.J.M. van Gent, H. Trum, F. Amant. Treatment of Advanced and Recurrent Endometrial Cancers. 2017. IGCS website.

M.D.J.M van Gent, L. Romijn, K. van Santen, C.D. de Kroon. Nerve-sparing radical hysterectomy versus conventional radical hysterectomy in early stage cervical cancer. A systematic review and meta-analysis of survival and quality of life. *Maturitas*. 2016 Dec.

M.D.J.M. van Gent, A. Nicolae-Cristina, C.D. de Kroon, J.B.M.Z. Trimbos, M.J. Kagie, H.M. Hazelbag, T. Bosse, V.T.H.B.M. Smit. Exploring morphologic and molecular aspects of endometrial cancer under progesterone treatment in the context of fertility preservation. *Int J Gynecol Cancer*. 2016 Mar; 26(3):483-90

M.D.J.M van Gent, L. W. van den Haak, K.N. Gaarenstroom, A.A.W. Peters, M.I.E. van Poelgeest, J.B.M.Z. Trimbos, C.D. de Kroon. Nerve sparing radical abdominal trachelectomy versus nerve sparing radical hysterectomy in early stage (FIGO IA2 - IB) cervical cancer. A comparative study on feasibility and outcome. *Int J Gynecol Cancer*. 2014 May; 24(4): 735-43

M.D.J.M van Gent. Dokter in Australië. *NTOG*, dec 2013; vol. 127: 506-508

M.D.J.M van Gent, M.J.Kagie, J.B. Trimbos. No Surgery for Low-Grade Endometrial Cancer in Women with a Desire to Preserve Fertility. *Journal of gynecol surg*, 2012 Oct; volume 28 (issue 6): 389-398

M.D.J.MvanGent, M.J.Kagie, J.B.Trimbos. Conservatieve behandeling van endometriumcarcinoom bij patiënten met kinderwens. *NTOG*. Vol 122, maart 2009: 33-6

M.D.J.M. van Gent, A. Clement, F.C.M. Twaalfhoven. Een verzuimde dwarsligging. *NTOG*. 2007 Sep; 120(07):24-5

M.D.J.M. van Gent, H.M. Oosterkamp, M.J. Kagie. Manifest carcinoma of the glandula vestibularis major (Bartholin's gland), detected one year after an inguinal lymph-node metastasis *Ned Tijdschr Geneesk*. 2007 Jul 28; 151 (30): 1686-9

A

REFERENCES

- Abu-Rustum NR**, Sonoda Y, Black D, et al. Fertility-sparing radical abdominal trachelectomy for cervical carcinoma: technique and review of the literature. *Gynecologic oncology*. 2006;103(3):807-13.
- Amant F**, Leunen K, Neven P, Berteloot P, Vergote I. Endometrial cancer: predictors of response and preferred endocrine therapy. *Int J Gynecol Cancer*. 2006;16 Suppl 2:527-8.
- Amant F**, Moerman P, Neven P, Timmerman D, Van Limbergen E, Vergote I. Endometrial cancer. *Lancet*. 2005;366(9484):491-505.
- Amezcuca CA**, Lu JJ, Felix JC, Stanczyk FZ, Zheng W. Apoptosis may be an early event of progestin therapy for endometrial hyperplasia. *Gynecol Oncol*. 2000;79(2):169-76.
- Angioli R**, Plotti F, Aloisi A, Scaletta G, Capriglione S, Luvero D, et al. A randomized controlled trial comparing four versus six courses of adjuvant platinum-based chemotherapy in locally advanced cervical cancer patients previously treated with neo-adjuvant chemotherapy plus radical surgery. *Gynecol Oncol*. 2015;139(3):433-8.
- Arbyn M**, Castellsague X, de SS, Bruni L, Saraiya M, Bray F, et al. Worldwide burden of cervical cancer in 2008. *AnnOncol*. 2011;22(12):2675-86.
- Asmussen M**, Andresen A. [Immediate disorders of urination following radical hysterectomy in cervix cancer]. *ZentralblGynakol*. 1987;109(4):222-7.
- Axelsen SM**, Petersen LK. Urogynaecological dysfunction after radical hysterectomy. *Eur J Surg Oncol*. 2006;32(4):445-9.
- Bafaloukos D**, Aravantinos G, Samonis G, Katsifis G, Bakoyiannis C, Skarlos D, et al. Carboplatin, methotrexate and 5-fluorouracil in combination with medroxyprogesterone acetate (JMF-M) in the treatment of advanced or recurrent endometrial carcinoma: A Hellenic cooperative oncology group study. *Oncology*. 1999;56(3):198-201.
- Bakker RM**, Pieterse QD, van Lonkhuijzen LRCW, Trimbos JBMZ, Creutzberg CL, Kenter GG, et al., editors. An observational controlled study on vaginal blood flow and sexual functioning after early stage cervical cancer treatment. 18th International Psycho Oncology Society Congress; 2016; Dublin.
- Basaran D**, Dusek L, Majek O, Cibula D. Oncological outcomes of nerve-sparing radical hysterectomy for cervical cancer: a systematic review. *Ann Surg Oncol*. 2015;22(9):3033-40.
- Basch E**, Torda P, Adams K. Standards for patient-reported outcome-based performance measures. *Jama*. 2013;310(2):139-40.

Beiner ME, Covens A. Surgery insight: radical vaginal trachelectomy as a method of fertility preservation for cervical cancer. *Nature clinical practice*. 2007;4(6):353-61.

Beiner ME, Hauspy J, Rosen B, et al. Radical vaginal trachelectomy vs. radical hysterectomy for small early stage cervical cancer: a matched case-control study. *Gynecologic oncology*. 2008;110(2):168-71.

Ben-Shachar I, Vitellas KM, Cohn DE. The role of MRI in the conservative management of endometrial cancer. *Gynecologic oncology*. 2004;93(1):233-7.

Benedetti-Panici P, Greggi S, Colombo A, et al. Neoadjuvant chemotherapy and radical surgery versus exclusive radiotherapy in locally advanced squamous cell cervical cancer: results from the Italian multicenter randomized study. *J Clin Oncol*. 2002;20(1):179-88.

Bentivegna E, Maulard A, Pautier P, Chargari C, Gouy S, Morice P. Fertility results and pregnancy outcomes after conservative treatment of cervical cancer: a systematic review of the literature. *Fertil Steril*. 2016;106(5):1195-211 e5.

Bergmark K, Avall-Lundqvist E, Dickman PW, Henningsohn L, Steineck G. Lymphedema and bladder-emptying difficulties after radical hysterectomy for early cervical cancer and among population controls. *Int J Gynecol Cancer*. 2006;16(3):1130-9.

Bergmark K, Avall-Lundqvist E, Dickman PW, Henningsohn L, Steineck G. Vaginal changes and sexuality in women with a history of cervical cancer. *The New England journal of medicine*. 1999;340(18):1383-9.

Bernardini M, Barrett J, Seaward G, et al. Pregnancy outcomes in patients after radical trachelectomy. *American journal of obstetrics and gynecology*. 2003;189(5):1378-82.

Bogani G, Cromi A, Uccella S, Serati M, Casarin J, Pinelli C, et al. Nerve-sparing versus conventional laparoscopic radical hysterectomy: a minimum 12 months' follow-up study. *Int J Gynecol Cancer*. 2014;24(4):787-93.

Bogani G, Serati M, Nappi R, Cromi A, di NE, Ghezzi F. Nerve-Sparing Approach Reduces Sexual Dysfunction in Patients Undergoing Laparoscopic Radical Hysterectomy. *J Sex Med*. 2014.

Boing C, Kimmig R. Fertility-preserving treatment in young women with endometrial cancer. *Gynakologisch-geburtshilfliche Rundschau*. 2006;46(1-2):25-33.

Bokhman JV, Chepick OF, Volkova AT, Vishnevsky AS. Can primary endometrial carcinoma stage I be cured without surgery and radiation therapy? *Gynecol Oncol*. 1985;20(2):139-55.

Bokhman JV. Two pathogenetic types of endometrial carcinoma. *Gynecol Oncol*. 1983;15(1):10-7.



Boronow RC, Morrow CP, Creasman WT, Disaia PJ, Silverberg SG, Miller A, et al. Surgical staging in endometrial cancer: clinical-pathologic findings of a prospective study. *Obstetrics and gynecology*. 1984;63(6):825-32.

Burnett AF, Bahador A, Amezcua C. Anastrozole, an aromatase inhibitor, and medroxyprogesterone acetate therapy in premenopausal obese women with endometrial cancer: a report of two cases successfully treated without hysterectomy. *Gynecol Oncol*. 2004;94(3):832-4.

Cancer Genome Atlas Research N, Kandoth C, Schultz N, Cherniack AD, Akbani R, Liu Y, et al. Integrated genomic characterization of endometrial carcinoma. *Nature*. 2013;497(7447):67-73.

Ceccaroni M, Roviglione G, Spagnolo E, Casadio P, Clarizia R, Peiretti M, et al. Pelvic dysfunctions and quality of life after nerve-sparing radical hysterectomy: a multicenter comparative study. *Anticancer Res*. 2012;32(2):581-8.

Cella DF, Tulsky DS, Gray G, Sarafian B, Linn E, Bonomi A, et al. The Functional Assessment of Cancer Therapy scale: development and validation of the general measure. *Journal of clinical oncology : official journal of the American Society of Clinical Oncology*. 1993;11(3):570-9.

Chang WH, Chen CH, Yu MH. Conservative therapy of stage I endometrial adenocarcinoma and atypical endometrial hyperplasia for the preservation of fertility. *Int J Gynaecol Obstet*. 2006;92(2):137-8.

Chang Y-Y, Hwang T-L, Lin W-C. Follow-up of clinical outcome of laparoscopic radical hysterectomy and laparoscopy nerve-sparing radical hysterectomy. *Journal of Minimally Invasive Gynecology*. 2013;Conference: 42nd Global Congress of Minimally Invasive Gynecology:November-December 2013.

Chen C, Li W, Li F, Liu P, Zhou J, Lu L, et al. Classical and nerve-sparing radical hysterectomy: an evaluation of the nerve trauma in cardinal ligament. *Gynecol Oncol*. 2012;125(1):245-51.

Chen L, Zhang WN, Zhang SM, Yang ZH, Zhang P. Effect of laparoscopic nerve-sparing radical hysterectomy on bladder function, intestinal function recovery and quality of sexual life in patients with cervical carcinoma. *Asian Pac J Cancer Prev*. 2014;15(24):10971-5.

Chen Y, Li Y, Xu HC, Li JN, Li YY, Liang ZQ. Laparoscopic anatomical nerve sparing radical hysterectomy for cervical cancer: a clinical analysis of 37 cases. *Zhonghua Fu Chan KeZa Zhi*. 2009;44(5):359-63.

Chiva L, Lapuente F, Gonzalez-Cortijo L, et al. Sparing fertility in young patients with endometrial cancer. *Gynecol Oncol* 2008; 111 (2 Suppl): S101-4.

Church DN, Stelloo E, Nout RA, Valtcheva N, Depreeuw J, ter Haar N, et al. Prognostic significance of POLE proofreading mutations in endometrial cancer. *Journal of the National Cancer Institute*. 2015;107(1):402.

Cibula D, Abu-Rustum NR, Benedetti-Panici P, Kohler C, Raspagliesi F, Querleu D, et al. New classification system of radical hysterectomy: emphasis on a three-dimensional anatomic template for parametrial resection. *Gynecol Oncol*. 2011;122(2):264-8.

Cibula D, Velechovska P, Slama J, et al. Late morbidity following nerve-sparing radical hysterectomy. *Gynecologic oncology*. 2010;116(3):506-11.

Neoadjuvant Chemotherapy for Cervical Cancer Meta-analysis Collaboration. Neoadjuvant chemotherapy for locally advanced cervical cancer: a systematic review and meta-analysis of individual patient data from 21 randomised trials. *Eur J Cancer*. 2003;39(17):2470-86.

Collaboration TC. *Cochrane Handbook for Systematic Reviews of Interventions Version 5.0.1* 2008 [updated September 2008. Available from: www.cochrane-handbook.org.

Colombo N, Carinelli S, Colombo A, Marini C, Rollo D, Sessa C, et al. Cervical cancer: ESMO Clinical Practice Guidelines for diagnosis, treatment and follow-up. *Ann Oncol*. 2012;23 Suppl 7:vii27-32.

Colombo N, Creutzberg C, Amant F, Bosse T, Gonzalez-Martin A, Ledermann J, et al. ESMO-ESGO-ESTRO Consensus Conference on Endometrial Cancer: Diagnosis, Treatment and Follow-up. *Int J Gynecol Cancer*. 2016;26(1):2-30.

Cormio G, Martino R, Loizzi V, Resta L, Selvaggi L. A rare case of choroidal metastasis presented after conservative management of endometrial cancer. *International Journal of Gynecological Cancer*. 2006;16(6):2044-8.

Covens A, Rosen B, Murphy J, et al. How important is removal of the parametrium at surgery for carcinoma of the cervix? *Gynecologic oncology*. 2002;84(1):145-9.

Creasman WT, Morrow CP, Bundy BN, Homesley HD, Graham JE, Heller PB. Surgical pathologic spread patterns of endometrial cancer. A Gynecologic Oncology Group Study. *Cancer*. 1987;60(8 Suppl):2035-41.

de Jongh FE, de Wit R, Verweij J, et al. Dose-dense cisplatin/paclitaxel. a well-tolerated and highly effective chemotherapeutic regimen in patients with advanced ovarian cancer. *Eur J Cancer*. 2002;38(15):2005-13.

de Kroon CD, Gaarenstroom KN, van Poelgeest MI, Peters AA, Trimbos JB. Nerve sparing in radical surgery for early-stage cervical cancer: yes we should! *Int J Gynecol Cancer*. 2010;20(11 Suppl 2):S39-S41.

Delgado G, Bundy B, Zaino R, et al. Prospective surgical-pathological study of disease-free interval in patients with stage IB squamous cell carcinoma of the cervix: a Gynecologic Oncology Group study. *Gynecologic oncology*. 1990;38(3):352-7.

Derks M, van der Velden J, Frijstein MM, Vermeer WM, Stiggelbout AM, Roovers JP, et al. Long-term Pelvic Floor Function and Quality of Life After Radical Surgery for Cervical Cancer: A Multicenter Comparison Between Different Techniques for Radical Hysterectomy With Pelvic Lymphadenectomy. *Int J Gynecol Cancer*. 2016.

Dermenzhy T, Svintitskiy V, Yatsina A. Functioning of urinary and reproductive systems in patients with infiltrative cervical after nerve-sparing radical hysterectomy. *International Journal of Gynecological Cancer*. 2014;Conference(var.pagings):533.

Dermenzhy T, Svintitskiy V, Stakhovskiy E, Yatsyna O. Evaluation of some indexes of urinary system function in patients with infiltrative cervical cancer and effect of nerve-sparing radical hysterectomy (RHE-C1), *Ann. Oncol*. 25 (suppl. 4) (2014) iv319.

Diaz JP, Sonoda Y, Leitao MM, et al. Oncologic outcome of fertility-sparing radical trachelectomy versus radical hysterectomy for stage IB1 cervical carcinoma. *Gynecologic oncology*. 2008;111(2):255-60.

Ditto A, Martinelli F, Mattana F, Reato C, Solima E, Carcangiu M, et al. Class III Nerve-sparing Radical Hysterectomy Versus Standard Class III Radical Hysterectomy: An Observational Study. *Ann Surg Oncol*. 2011.

Dowaji J, Jaenicke F. The outcome of nerve sparing radical hysterectomy in patients with cervical cancer (IB2-IIIa). *International Journal of Gynecological Cancer*. 2011;Conference(var.pagings):S141.

Duska LR, Garrett A, Rueda BR, Haas J, Chang Y, Fuller AF. Endometrial cancer in women 40 years old or younger. *Gynecol Oncol*. 2001;83(2):388-93.

Eddy WA. Endometrial carcinoma in Stein-Leventhal syndrome treated with hydroxyprogesterone caproate. *Am J Obstet Gynecol*. 1978;131(5):581-2.

Espino-Strebel EE, Luna JT, Domingo EJ. A comparison of the feasibility and safety of nerve-sparing radical hysterectomy with the conventional radical hysterectomy. *Int J Gynecol Cancer*. 2010;20(7):1274-83.

Evans-Metcalf ER, Brooks SE, Reale FR, Baker SP. Profile of women 45 years of age and younger with endometrial cancer. *Obstetrics and gynecology*. 1998;91(3):349-54.

Fagotti A, Gagliardi ML, Moruzzi C, et al. Excisional cone as fertility-sparing treatment in early-stage cervical cancer. *Fertility and sterility*. 2011;95(3):1109-12.

- Farhi DC**, Nosanchuk J, Silverberg SG. Endometrial adenocarcinoma in women under 25 years of age. *Obstet Gynecol.* 1986;68(6):741-5.
- Ferrandina G**, Zannoni GF, Gallotta V, Foti E, Mancuso S, Scambia G. Progression of conservatively treated endometrial carcinoma after full term pregnancy: a case report. *Gynecol Oncol.* 2005;99(1):215-7.
- Fujii S**, Takakura K, Matsumura N, Higuchi T, Yura S, Mandai M, et al. Anatomic identification and functional outcomes of the nerve sparing Okabayashi radical hysterectomy. *Gynecol Oncol.* 2007;107(1):4-13.
- Gallos ID**, Yap J, Rajkhowa M, Luesley DM, Coomarasamy A, Gupta JK. Regression, relapse, and live birth rates with fertility-sparing therapy for endometrial cancer and atypical complex endometrial hyperplasia: a systematic review and metaanalysis. *Am J Obstet Gynecol.* 2012;207(4):266-12.
- Garg K**, Broaddus RR, Soslow RA, Urbauer DL, Levine DA, Djordjevic B. Pathologic scoring of PTEN immunohistochemistry in endometrial carcinoma is highly reproducible. *Int J Gynecol Pathol.* 2012;31(1):48-56.
- Gotlieb WH**, Beiner ME, Shalmon B, Korach Y, Segal Y, Zmira N, et al. Outcome of fertility-sparing treatment with progestins in young patients with endometrial cancer. *Obstet Gynecol.* 2003;102(4):718-25.
- Greenblatt RB**, Gambrell RD, Jr., Stoddard LD. The protective role of progesterone in the prevention of endometrial cancer. *Pathology, research and practice.* 1982;174(3):297-318.
- Gurgan T**, Bozdogan G, Demiroglu A, Ayhan A. Preserving fertility before assisted reproduction in women with endometrial carcinoma: case report and literature review. *Reproductive biomedicine online.* 2007;15(5):561-5.
- Hahn HS**, Yoon SG, Hong JS, et al. Conservative treatment with progestin and pregnancy outcomes in endometrial cancer. *Int J Gynecol Cancer* 2009;19:1068.
- Hockel M**, Horn LC, Hentschel B, Hockel S, Naumann G. Total mesometrial resection: high resolution nerve-sparing radical hysterectomy based on developmentally defined surgical anatomy. *Int J Gynecol Cancer.* 2003;13(6):791-803.
- Hockel M**, Horn LC, Manthey N, Braumann UD, Wolf U, Teichmann G, et al. Resection of the embryologically defined uterovaginal (Mullerian) compartment and pelvic control in patients with cervical cancer: a prospective analysis. *Lancet Oncology.* 2009;10(7):683-92.
- Hockel M**, Konerding MA, Heussel CP. Liposuction-assisted nerve-sparing extended radical hysterectomy: oncologic rationale, surgical anatomy, and feasibility study. *Am J Obstet Gynecol.* 1998;178(5):971-6.



Hockel M, Naumann G, Alexander H, Horn LC, Fischer U, Schmidt F, et al. Nerve-sparing radical hysterectomy: II. Results after three years. [German]. *Geburtshilfe und Frauenheilkunde*. 2000;60(6):320-5.

Hong DG, Lee YS, Park NY, et al. Robotic uterine artery preservation and nerve-sparing radical trachelectomy with bilateral pelvic lymphadenectomy in early-stage cervical cancer. *Int J Gynecol Cancer*. 2011;21(2):391-6.

Hozo SP, Djulbegovic B, Hozo I. Estimating the mean and variance from the median, range, and the size of a sample. *BMC Med Res Methodol*. 2005;5:13.

Huang SY, Jung SM, Ng KK, Chang YC, Lai CH. Ovarian metastasis in a nulliparous woman with endometrial adenocarcinoma failing conservative hormonal treatment. *Gynecol Oncol*. 2005;97(2):652-5.

Hug V, Kau S, Hortobagyi GN, Jones L. Adrenal failure in patients with breast carcinoma after long-term treatment of cyclic alternating oestrogen progesterone. *Br J Cancer*. 1991;63(3):454-6.

Hurst SA, Hartzfeld KM, Del Priore G. Occult myometrial recurrence after progesterone therapy to preserve fertility in a young patient with endometrial cancer. *Fertil Steril*. 2008;89(3):724 e1-3.

Imai M, Jobo T, Sato R, Kawaguchi M, Kuramoto H. Medroxyprogesterone acetate therapy for patients with adenocarcinoma of the endometrium who wish to preserve the uterus-usefulness and limitations. *Eur J Gynaecol Oncol*. 2001;22(3):217-20.

Jadoul P, Donnez J. Conservative treatment may be beneficial for young women with atypical endometrial hyperplasia or endometrial adenocarcinoma. *Fertil Steril*. 2003;80(6):1315-24.

Jobo T, Imai M, Kawaguchi M, Kenmochi M, Kuramoto H. Successful conservative treatment of endometrial carcinoma permitting subsequent pregnancy: report of two cases. *Eur J Gynaecol Oncol*. 2000;21(2):119-22.

Jones A, Teschendorff AE, Li Q, Hayward JD, Kannan A, Mould T, et al. Role of DNA methylation and epigenetic silencing of HAND2 in endometrial cancer development. *PLoS Med*. 2013;10(11):e1001551.

Ju XZ, Li ZT, Yang HJ, Wu XH. Nerve-sparing radical hysterectomy and radical hysterectomy: a retrospective study. *Zhonghua Fu Chan KeZa Zhi*. 2009;44(8):605-9.

Kaku T, Yoshikawa H, Tsuda H, Sakamoto A, Fukunaga M, Kuwabara Y, et al. Conservative therapy for adenocarcinoma and atypical endometrial hyperplasia of the endometrium in young women: central pathologic review and treatment outcome. *Cancer Lett*. 2001;167(1):39-48.

- Kamoi S**, Ohaki Y, Mori O, Kurose K, Fukunaga M, Takeshita T. Serial histologic observation of endometrial adenocarcinoma treated with high-dose progestin until complete disappearance of carcinomatous foci--review of more than 25 biopsies from five patients. *Int J Gynecol Cancer*. 2008;18(6):1305-14.
- Kanao H**, Fujiwara K, Ebisawa K, Hada T, Ota Y, Andou M. Various types of total laparoscopic nerve-sparing radical hysterectomies and their effects on bladder function. *J Gynecol Oncol*. 2014;25(3):198-205.
- Kaupilla A**. Oestrogen and progestin receptors as prognostic indicators in endometrial cancer. A review of the literature. *Acta Oncol*. 1989;28(4):561-6.
- Kempson RL**, Pokorny GE. Adenocarcinoma of the endometrium in women aged forty and younger. *Cancer*. 1968;21(4):650-62.
- Kim MK**, Seong SJ, Lee TS, Kim JW, Nam BH, Hong SR, et al. Treatment with medroxyprogesterone acetate plus levonorgestrel-releasing intrauterine system for early-stage endometrial cancer in young women: single-arm, prospective multicenter study: Korean gynecologic oncology group study (KGOG2009). *Japanese journal of clinical oncology*. 2012;42(12):1215-8.
- Kim YB**, Holschneider CH, Ghosh K, Nieberg RK, Montz FJ. Progestin alone as primary treatment of endometrial carcinoma in premenopausal women. Report of seven cases and review of the literature. *Cancer*. 1997;79(2):320-7.
- Kimmig R**, Strowitzki T, Muller-Hocker J, Kurzl R, Korell M, Hepp H. Conservative treatment of endometrial cancer permitting subsequent triplet pregnancy. *Gynecol Oncol*. 1995;58(2):255-7.
- Kinkel K**, Kaji Y, Yu KK, Segal MR, Lu Y, Powell CB, et al. Radiologic staging in patients with endometrial cancer: a meta-analysis. *Radiology*. 1999;212(3):711-8.
- Koskas M**, Uzan J, Luton D, Rouzier R, Darai E. Prognostic factors of oncologic and reproductive outcomes in fertility-sparing management of endometrial atypical hyperplasia and adenocarcinoma: systematic review and meta-analysis. *Fertil Steril*. 2014;101(3):785-94.
- Kowalczyk CL**, Malone J, Jr., Peterson EP, Jacques SM, Leach RE. Well-differentiated endometrial adenocarcinoma in an infertility patient with later conception. A case report. *J Reprod Med*. 1999;44(1):57-60.
- Kung FT**, Chen WJ, Chou HH, Ko SF, Chang SY. Conservative management of early endometrial adenocarcinoma with repeat curettage and hormone therapy under assistance of hysteroscopy and laparoscopy. *Hum Reprod*. 1997;12(8):1649-53.
- Kurman RJ**, Carcangiu, M.L., Herrington, C.S., Young, R.H. WHO Classification of Tumours of Female Reproductive Organs. Fourth Edition 2014 2014.



Kuwabara Y, Suzuki M, Hashimoto M, Furugen Y, Yoshida K, Mitsuhashi N. New method to prevent bladder dysfunction after radical hysterectomy for uterine cervical cancer. *J Obstet Gynaecol Res.* 2000;26(1):1-8.

Lai CH, Hsueh S, Chao AS, Soong YK. Successful pregnancy after tamoxifen and megestrol acetate therapy for endometrial carcinoma. *Br J Obstet Gynaecol.* 1994;101(6):547-9.

Lanowska M, Morawietz L, Sikora A, et al. Prevalence of lymph nodes in the parametrium of radical vaginal trachelectomy (RVT) specimen. *Gynecologic oncology.* 2011;121(2):298-302.

Larson DM, Johnson KK, Broste SK, Krawisz BR, Kresl JJ. Comparison of D&C and office endometrial biopsy in predicting final histopathologic grade in endometrial cancer. *Obstet Gynecol.* 1995;86(1):38-42.

Laurelli G, Falcone F, Gallo MS, Scala F, Losito S, Granata V, et al. Long-Term Oncologic and Reproductive Outcomes in Young Women With Early Endometrial Cancer Conservatively Treated: A Prospective Study and Literature Update. *Int J Gynecol Cancer.* 2016.

Lee II, Kim JJ. Influence of AKT on Progesterone Action in Endometrial Diseases. *Biol Reprod.* 2014;91(3):63.

Lee KR, Scully RE. Complex endometrial hyperplasia and carcinoma in adolescents and young women 15 to 20 years of age. A report of 10 cases. *Int J Gynecol Pathol.* 1989;8(3):201-13.

Lee NK, Cheung MK, Shin JY, Husain A, Teng NN, Berek JS, et al. Prognostic factors for uterine cancer in reproductive-aged women. *Obstet Gynecol.* 2007;109(3):655-62.

Lee TS, Seong SJ, Kim JW, Ryu HS, Song ES, Nam BH. Management of endometrial hyperplasia with a levonorgestrel-releasing intrauterine system: single arm, prospective multicenter study: Korean gynecologic oncology group study (KGOG2006). *Japanese journal of clinical oncology.* 2011;41(6):817-9.

Li J, Wang LJ, Zhang BZ, et al. Neoadjuvant chemotherapy with paclitaxel plus platinum for invasive cervical cancer in pregnancy: two case report and literature review. *Archives of gynecology and obstetrics.* 2011;284(3):779-83.

Liang Z, Chen Y, Xu H, Li Y, Wang D. Laparoscopic nerve-sparing radical hysterectomy with fascia space dissection technique for cervical cancer: description of technique and outcomes. *Gynecol Oncol.* 2010;119(2):202-7.

Long Y, Yao DS, Pan XW, Ou TY. Clinical efficacy and safety of nerve-sparing radical hysterectomy for cervical cancer: a systematic review and meta-analysis. *PLoS One.* 2014;9(4):e94116.

- Lowe MP**, Cooper BC, Sood AK, Davis WA, Syrop CH, Sorosky JI. Implementation of assisted reproductive technologies following conservative management of FIGO grade I endometrial adenocarcinoma and/or complex hyperplasia with atypia. *Gynecol Oncol*. 2003;91(3):569-72.
- Maas CP**, Kenter GG, Trimbos JB, Deruiter MC. Anatomical basis for nerve-sparing radical hysterectomy: immunohistochemical study of the pelvic autonomic nerves. *Acta Obstet Gynecol Scand*. 2005;84(9):868-74.
- Maas CP**, Ter Kuile MM, Laan E, Tuijnman CC, Weijnenborg PT, Trimbos JB, et al. Objective assessment of sexual arousal in women with a history of hysterectomy. *BJOG*. 2004;111(5):456-62.
- Maas CP**, Trimbos JB, Deruiter MC, van de Velde CJ, Kenter GG. Nerve sparing radical hysterectomy: latest developments and historical perspective. *Crit Rev Oncol Hematol*. 2003;48(3):271-9.
- Makino H**, Kato H, Furui T, Hayasaki Y, Morishige K, Kanematsu M. Assessment of uterine enhancement rate after abdominal radical trachelectomy using dynamic contrast-enhanced magnetic resonance imaging. *Arch Gynecol Obstet*. 2016;293(3):625-32.
- Makowski M**, Nowak M, Szpakowski M, Władziński J, Serwach-Nowińska A, Janas Ł, et al. Classical radical hysterectomy and nerve-sparing radical hysterectomy in the treatment of cervical cancer. *Menopausal Review / Przegląd Menopauzalny*. 2014;13(3):180-5.
- Maneo A**, Sideri M, Scambia G, et al. Simple conization and lymphadenectomy for the conservative treatment of stage IB1 cervical cancer. An Italian experience. *Gynecologic oncology*.
- Martin A**, Torrent A. Laparoscopic nerve-sparing radical trachelectomy: surgical technique and outcome. *Journal of minimally invasive gynecology*. 2010;17(1):37-41.
- Mazzon I**, Corrado G, Morricone D, Scambia G. Reproductive preservation for treatment of stage IA endometrial cancer in a young woman: hysteroscopic resection. *Int J Gynecol Cancer*. 2005;15(5):974-8.
- McCulloch P**, Altman DG, Campbell WB, Flum DR, Glasziou P, Marshall JC, et al. No surgical innovation without evaluation: the IDEAL recommendations. *Lancet*. 2009;374(9695):1105-12.
- Merlot B**, Narducci F, Lambaudie E, Phalippou J, Taieb S, Houvenaeghel G, et al. Robotic nerve-sparing versus laparoscopic without nerve-sparing radical hysterectomy in early cervical cancer: Urinary diseases. *International Journal of Gynecological Cancer*. 2011;Conference(var. pagings):S105.
- Minaguchi T**, Nakagawa S, Takazawa Y, Nei T, Horie K, Fujiwara T, et al. Combined phospho-Akt and PTEN expressions associated with post-treatment hysterectomy after conservative progestin therapy in complex atypical hyperplasia and stage Ia, G1 adenocarcinoma of the endometrium. *Cancer Lett*. 2007;248(1):112-22.



Minig L, Franchi D, Boveri S, Casadio C, Bocciolone L, Sideri M. Progestin intrauterine device and GnRH analogue for uterus-sparing treatment of endometrial precancers and well-differentiated early endometrial carcinoma in young women. *Ann Oncol*. 2011;22(3):643-9.

Mitsushita J, Toki T, Kato K, Fujii S, Konishi I. Endometrial carcinoma remaining after term pregnancy following conservative treatment with medroxyprogesterone acetate. *Gynecol Oncol*. 2000;79(1):129-32.

Moyer DL, Felix JC. The effects of progesterone and progestins on endometrial proliferation. *Contraception*. 1998;57(6):399-403.

Muechler EK, Bonfiglio T, Choate J, Huang KE. Pregnancy induced with menotropins in a woman with polycystic ovaries, endometrial hyperplasia, and adenocarcinoma. *Fertil Steril*. 1986;46(5):973-5.

Mukhtarulina S, Ushakov I, Poliakova S. Systematic Nerve-Sparing Radical Hysterectomy (NSRG) in cervical cancer: Urodynamic study on postsurgical bladder function. *International Journal of Gynecological Cancer*. 2011;Conference(var.pagings):S140.

Mutter GL, Ince TA, Baak JP, Kust GA, Zhou XP, Eng C. Molecular identification of latent precancers in histologically normal endometrium. *Cancer Res*. 2001;61(11):4311-4.

Mutter GL, Lin MC, Fitzgerald JT, Kum JB, Baak JP, Lees JA, et al. Altered PTEN expression as a diagnostic marker for the earliest endometrial precancers. *J Natl Cancer Inst*. 2000;92(11):924-30.

Mutter GL, Lin MC, Fitzgerald JT, Kum JB, Eng C. Changes in endometrial PTEN expression throughout the human menstrual cycle. *J Clin Endocrinol Metab*. 2000;85(6):2334-8.

Nakao Y, Nomiyama M, Kojima K, Matsumoto Y, Yamasaki F, Iwasaka T. Successful pregnancies in 2 infertile patients with endometrial adenocarcinoma. *Gynecol Obstet Invest*. 2004;58(2):68-71.

Nishio H, Fujii T, Kameyama K, et al. Abdominal radical trachelectomy as a fertility-sparing procedure in women with early-stage cervical cancer in a series of 61 women. *Gynecologic oncology*. 2009;115(1):51-5.

Niwa K, Tagami K, Lian Z, Onogi K, Mori H, Tamaya T. Outcome of fertility-preserving treatment in young women with endometrial carcinomas. *BJOG*. 2005;112(3):317-20.

Nout RA, Bosse T, Creutzberg CL, Jurgenliemk-Schulz IM, Jobsen JJ, Lutgens LC, et al. Improved risk assessment of endometrial cancer by combined analysis of MSI, PI3K-AKT, Wnt/beta-catenin and P53 pathway activation. *Gynecol Oncol*. 2012;126(3):466-73.

Nyholm HC, Nielsen AL, Lyndrup J, Dreisler A, Thorpe SM. Estrogen and progesterone receptors in endometrial carcinoma: comparison of immunohistochemical and biochemical analysis. *Int J Gynecol Pathol*. 1993;12(3):246-52.

- O'Neill RT.** Pregnancy following hormonal therapy for adenocarcinoma of the endometrium. *Am J Obstet Gynecol.* 1970;108(2):318-21.
- Ogawa S,** Koike T, Shibahara H, Ohwada M, Suzuki M, Araki S, et al. Assisted reproductive technologies in conjunction with conservatively treated endometrial adenocarcinoma. A case report. *Gynecol Obstet Invest.* 2001;51(3):214-6.
- Ota T,** Yoshida M, Kimura M, Kinoshita K. Clinicopathologic study of uterine endometrial carcinoma in young women aged 40 years and younger. *Int J Gynecol Cancer.* 2005;15(4):657-62.
- Ozdegirmenci O,** Kayikcioglu F, Bozkurt U, Akgul MA, Haberal A. Comparison of the efficacy of three progestins in the treatment of simple endometrial hyperplasia without atypia. *Gynecol Obstet Invest.* 2011;72(1):10-4.
- Pareja R,** Rendon GJ, Sanz-Lomana CM, Monzon O, Ramirez PT. Surgical, oncological, and obstetrical outcomes after abdominal radical trachelectomy - a systematic literature review. *Gynecol Oncol.* 2013;131(1):77-82.
- Park JC,** Cho CH, Rhee JH. A successful live birth through in vitro fertilization program after conservative treatment of FIGO grade I endometrial cancer. *Journal of Korean medical science.* 2006;21(3):567-71.
- Park JY,** Kim DY, Kim JH, Kim YM, Kim KR, Kim YT, et al. Long-term oncologic outcomes after fertility-sparing management using oral progestin for young women with endometrial cancer (KGOG 2002). *Eur J Cancer.* 2013;49(4):868-74.
- Park JY,** Lee SH, Seong SJ, Kim DY, Kim TJ, Kim JW, et al. Progestin re-treatment in patients with recurrent endometrial adenocarcinoma after successful fertility-sparing management using progestin. *Gynecol Oncol.* 2013;129(1):7-11.
- Parkin DM,** Bray F, Ferlay J, Pisani P. Global cancer statistics, 2002. *CA Cancer J Clin.* 2005;55(2):74-108.
- Paulson RJ,** Sauer MV, Lobo RA. Pregnancy after in vitro fertilization in a patient with stage I endometrial carcinoma treated with progestins. *Fertil Steril.* 1990
- Penner KR,** Dorigo O, Aoyama C, Ostrzega N, Balzer BL, Rao J, et al. Predictors of resolution of complex atypical hyperplasia or grade 1 endometrial adenocarcinoma in premenopausal women treated with progestin therapy. *Gynecol Oncol.* 2012;124(3):542-8.
- Perri T,** Korach J, Gotlieb WH, Beiner M, Meirou D, Friedman E, et al. Prolonged conservative treatment of endometrial cancer patients: more than 1 pregnancy can be achieved. *Int J Gynecol Cancer.* 2011;21(1):72-8.

Peters WA, 3rd, Liu PY, Barrett RJ, 2nd, Stock RJ, Monk BJ, Berek JS, et al. Concurrent chemotherapy and pelvic radiation therapy compared with pelvic radiation therapy alone as adjuvant therapy after radical surgery in high-risk early-stage cancer of the cervix. *Journal of clinical oncology : official journal of the American Society of Clinical Oncology*. 2000;18(8):1606-13.

Pieterse QD, Kenter GG, Maas CP, de Kroon CD, Creutzberg CL, Trimbos JB, et al. Self-reported sexual, bowel and bladder function in cervical cancer patients following different treatment modalities: longitudinal prospective cohort study. *Int J Gynecol Cancer*. 2013;23(9):1717-25.

Pieterse QD, Maas CP, Ter Kuile MM, Lowik M, van Eijkeren MA, Trimbos JB, et al. An observational longitudinal study to evaluate miction, defecation, and sexual function after radical hysterectomy with pelvic lymphadenectomy for early-stage cervical cancer. *IntJGynecolCancer*. 2006;16(3):1119-29.

Pieterse QD, Ter Kuile MM, Deruiter MC, Trimbos JB, Kenter GG, Maas CP. Vaginal blood flow after radical hysterectomy with and without nerve sparing. A preliminary report. *Int J Gynecol Cancer*. 2008;18(3):576-83.

Pieterse QD, Ter Kuile MM, Maas CP, Kenter GG. The Gynaecologic Leiden Questionnaire: psychometric properties of a self-report questionnaire of sexual function and vaginal changes for gynaecological cancer patients. *Psychooncology*. 2008;17(7):681-9.

Pinto AB, Gopal M, Herzog TJ, Pfeifer JD, Williams DB. Successful in vitro fertilization pregnancy after conservative management of endometrial cancer. *Fertil Steril*. 2001;76(4):826-9.

Piver MS, Rutledge F, Smith JP. Five classes of extended hysterectomy for women with cervical cancer. *Obstet Gynecol*. 1974;44(2):265-72.

Plante M, Gregoire J, Renaud MC, et al. The vaginal radical trachelectomy: an update of a series of 125 cases and 106 pregnancies. *Gynecologic oncology*. 2011;121(2):290-7.

Plante M. [updated 14 April 2016. Available from: <http://www.gcig.igcs.org/ClinicalTrials.html>.

Plante M. Bulky Early-Stage Cervical Cancer (2-4 cm Lesions): Upfront Radical Trachelectomy or Neoadjuvant Chemotherapy Followed by Fertility-Preserving Surgery: Which Is the Best Option? *Int J Gynecol Cancer*. 2015;25(4):722-8.

Plante M. NCT01658930 Shape trial [Available from: <https://clinicaltrials.gov/>.

Porter ME. What is value in health care? *The New England journal of medicine*. 2010;363(26):2477-81.

Possover M, Stober S, Plaul K, Schneider A. Identification and preservation of the motoric innervation of the bladder in radical hysterectomy type III. *Gynecol Oncol*. 2000;79(2):154-7.

Prajwala R, Tsang J, Thangavelu A, Abu JI. Feasibility of laparoscopic nerve sparing radical hysterectomy in the management of early cervical cancer. *International Journal of Gynecological Cancer*. 2013;Conference: 18th International Meeting of the European Society of Gynaecological Oncology:October 2013.

Prat J, Ribe A, Gallardo A. Hereditary ovarian cancer. *Human pathology*. 2005;36(8):861-70.

Querleu D, Morrow CP. Classification of radical hysterectomy. *Lancet Oncol*. 2008;9:297-303.

Rackow BW, Arici A. Endometrial cancer and fertility. *Curr Opin Obstet Gynecol*. 2006;18(3):245-52.

Rademaker M, van den Tillaart SA, van Poelgeest MI, Beltman JJ, Gaarenstroom KN, Peters AAW, et al. Long-term follow-up after nerve sparing radical hysterectomy in patients with stage IA-IIA cervical cancer. *International Journal of Gynecological Cancer*. 2014;Conference(var.pagings):3.

Radlovic P, Cetkovic A, Djakovic M, Rulic B. Comparative study of postoperative morbidity after nerve-sparing radical hysterectomy and traditional radical hysterectomy. *International Journal of Gynecological Cancer*. 2011;Conference(var.pagings):S177.

Ramirez PT, Frumovitz M, Bodurka DC, Sun CC, Levenback C. Hormonal therapy for the management of grade 1 endometrial adenocarcinoma: a literature review. *Gynecol Oncol*. 2004;95(1):133-8.

Randall TC, Kurman RJ. Progesterone treatment of atypical hyperplasia and well-differentiated carcinoma of the endometrium in women under age 40. *Obstetrics and gynecology*. 1997;90(3):434-40.

Raspagliesi F, Ditto A, Fontanelli R, et al. Nerve-sparing radical hysterectomy: a surgical technique for preserving the autonomic hypogastric nerve. *Gynecologic oncology*. 2004;93(2):307-14.

Reid-Nicholson M, Iyengar P, Hummer AJ, Linkov I, Asher M, Soslow RA. Immunophenotypic diversity of endometrial adenocarcinomas: implications for differential diagnosis. *Mod Pathol*. 2006;19(8):1091-100.

Rehman AG, Soerjomataram I, Leitzmann MF. Interpreting the epidemiological evidence linking obesity and cancer: A framework for population-attributable risk estimations in Europe. *Eur J Cancer*. 2010;46(14):2581-92.

Rob L, Halaska M, Robova H. Nerve-sparing and individually tailored surgery for cervical cancer. *Lancet Oncol*. 2010;11(3):292-301.

Rob L, Pluta M, Skapa P, Robova H. Advances in fertility-sparing surgery for cervical cancer. *Expert Rev Anticancer Ther*. 2010;10(7):1101-14.



Rodolakis A, Biliatis I, Morice P, Reed N, Mangler M, Kesic V, et al. European Society of Gynecological Oncology Task Force for Fertility Preservation: Clinical Recommendations for Fertility-Sparing Management in Young Endometrial Cancer Patients. *Int J Gynecol Cancer*. 2015;25(7):1258-65.

Rodolakis A, Mantzaris G, Thomakos N, Vlachos G, Bakos D, Antsaklis A. Rectal dysfunction in loupes assisted nerve-sparing and radical hysterectomies types II and III: A manometric evaluation. *Gynecologic Oncology*. 2008;108(3):339.

Roh J-W, Lee D-O, Chung J, Lim MC, Seo SS, Park S-Y. A prospective randomized trial for evaluation of therapeutic efficacy and safety of nerve-sparing radical hysterectomy in cervical cancer. *International Journal of Gynecological Cancer*. 2014;Conference: 14th Biennial Meeting of the International Gynecologic Cancer Society:October 2012.

Roh JW, Lee DO, Suh DH, Lim MC, Seo SS, Chung J, et al. Efficacy and oncologic safety of nerve-sparing radical hysterectomy for cervical cancer: a randomized controlled trial. *J Gynecol Oncol*. 2015;26(2):90-9.

Rotman M, Sedlis A, Piedmonte MR, Bundy B, Lentz SS, Mudderspach LI, et al. A phase III randomized trial of postoperative pelvic irradiation in Stage IB cervical carcinoma with poor prognostic features: follow-up of a gynecologic oncology group study. *Int J Radiat Oncol Biol Phys*. 2006;65(1):169-76.

Runnebaum IB, Camara O, Diebolder H. Nerve-sparing Vaginal Assisted Laparoscopic Radical Hysterectomy (VALRH): Evaluation of type C1 radicality for low and high-risk early cervical cancer. *Archives of Gynecology and Obstetrics*. 2010;Conference(Deutsche Gesellschaft fur Gynakologie und Geburtshilfe: :*var.pagings*):S170.

Rydzewska L, Tierney J, Vale CL, et al. Neoadjuvant chemotherapy plus surgery versus surgery for cervical cancer. *Cochrane database of systematic reviews (Online)*. 2010(1):CD007406.

Saegusa M, Hashimura M, Yoshida T, Okayasu I. beta- Catenin mutations and aberrant nuclear expression during endometrial tumorigenesis. *Br J Cancer*. 2001;84(2):209-17.

Saegusa M, Okayasu I. Frequent nuclear beta-catenin accumulation and associated mutations in endometrioid-type endometrial and ovarian carcinomas with squamous differentiation. *J Pathol*. 2001;194(1):59-67.

Sakamoto S, Takizawa K. An improved radical hysterectomy with fewer urological complications and with no loss of therapeutic results for invasive cervical cancer. *Baillieres Clin Obstet Gynaecol*. 1988;2(4):953-62.

Sakuragi N, Todo Y, Kudo M, Yamamoto R, Sato T. A systematic nerve-sparing radical hysterectomy technique in invasive cervical cancer for preserving postsurgical bladder function. *Int J Gynecol Cancer*. 2005;15(2):389-97.

- Salha O**, Martin-Hirsch P, Lane G, Sharma V. Endometrial carcinoma in a young patient with polycystic ovarian syndrome: first suspected at time of embryo transfer. *Hum Reprod.* 1997;12(5):959-62.
- Sandadi S**, Tanner EJ, Khoury-Collado F, Kostolias A, Makker V, Chi DS, et al. Radical surgery with individualized postoperative radiation for stage IB cervical cancer: oncologic outcomes and severe complications. *Int J Gynecol Cancer.* 2013;23(3):553-8.
- Sardi J**, Anchezar Henry JP, Panicer G, Gomez Rueda N, Vighi S. Primary hormonal treatment for early endometrial carcinoma. *Eur J Gynaecol Oncol.* 1998;19(6):565-8.
- Satyaswaroop PG**. Development of a preclinical model for hormonal therapy of human endometrial carcinomas. *Annals of medicine.* 1993;25(2):105-11.
- Schain WS**. Patients' rights in decision making: the case for personalism versus paternalism in health care. *Cancer.* 1980;46(4 Suppl):1035-41.
- Schammel DP**, Mittal KR, Kaplan K, Deligdisch L, Tavassoli FA. Endometrial adenocarcinoma associated with intrauterine pregnancy. A report of five cases and a review of the literature. *Int J Gynecol Pathol.* 1998;17(4):327-35.
- Scholten AN**, Creutzberg CL, van den Broek LJ, Noordijk EM, Smit VT. Nuclear beta-catenin is a molecular feature of type I endometrial carcinoma. *J Pathol.* 2003;201(3):460-5.
- Scholten RJPM** OM, Assendelft WJJ. Inleiding in Evidence-Based Medicine. *Klinisch handelen gebaseerd op bewijsmateriaal.* Houten: Bohn, Stafleu, Van Loghum; 2013. 285 p.
- Schouten LJ**, Goldbohm RA, van den Brandt PA. Anthropometry, physical activity, and endometrial cancer risk: results from the Netherlands cohort study. *Int J Gynecol Cancer.* 2006;16 Suppl 2:492.
- Sedlis A**, Bundy BN, Rotman MZ, Lentz SS, Muderspach LI, Zaino RJ. A randomized trial of pelvic radiation therapy versus no further therapy in selected patients with stage IB carcinoma of the cervix after radical hysterectomy and pelvic lymphadenectomy: A Gynecologic Oncology Group Study. *Gynecol Oncol.* 1999;73(2):177-83.
- Sedraky A**, Campbell B, Graves S, Cronenwett JL. Surgical registries for advancing quality and device surveillance. *Lancet.* 2016;388(10052):1358-60.
- Shamshirsaz AA**, Withiam-Leitch M, Odunsi K, Baker T, Frederick PJ, Lele S. Young patients with endometrial carcinoma selected for conservative treatment: a need for vigilance for synchronous ovarian carcinomas, case report and literature review. *Gynecol Oncol.* 2007;104(3):757-60.
- Shi R**, Wei W, Jiang P. Laparoscopic Nerve-Sparing Radical Hysterectomy for Cervical Carcinoma: Emphasis on Nerve Content in Removed Cardinal Ligaments. *Int J Gynecol Cancer.* 2015.

Shibahara H, Shigeta M, Toji H, Wakimoto E, Adachi S, Ogasawara T, et al. Successful pregnancy in an infertile patient with conservatively treated endometrial adenocarcinoma after transfer of embryos obtained by intracytoplasmic sperm injection. *Hum Reprod.* 1999;14(7):1908-11.

Siegel R, Ma J, Zou Z, Jemal A. Cancer statistics, 2014. *CA Cancer J Clin.* 2014;64(1):9-29.

Simpson AN, Feigenberg T, Clarke BA, Gien LT, Ismiil N, Laframboise S, et al. Fertility sparing treatment of complex atypical hyperplasia and low-grade endometrial cancer using oral progestin. *Gynecol Oncol.* 2014;133(2):229-33.

Skret-Magierlo J, Narog M, Kruczek A, Kluza R, Kluz T, Magon T, et al. Radical hysterectomy during the transition period from traditional to nerve-sparing technique. *Gynecol Oncol.* 2010;116(3):502-5.

Snijders-Keilholz A, Hellebrekers BW, Zwinderman AH, van de Vijver MJ, Trimbos JB. Adjuvant radiotherapy following radical hysterectomy for patients with early-stage cervical carcinoma (1984-1996). *Radiotherapy and oncology : journal of the European Society for Therapeutic Radiology and Oncology.* 1999;51(2):161-7.

Sobin L. TNM Classification of malignant tumours. Geneva2002 [updated 2002. UICC International Union against Cancer:[155-7].

Soderini A. Is the nerve sparing (NS) a new standard in radical hysterectomy (NSRH) for cervical cancer (CC)? International Gynecological Cancer Society 12th Biennial Meeting, Bangkok, Thailand; 25 October 2008.

Song T, Seong SJ, Bae DS, Suh DH, Kim DY, Lee KH, et al. Synchronous primary cancers of the endometrium and ovary in young women: a Korean Gynecologic Oncology Group Study. *Gynecol Oncol.* 2013;131(3):624-8.

Sorosky JI. Endometrial cancer. *Obstetrics and gynecology.* 2008;111(2 Pt 1):436-47.

Sowa E, Kuhnt S, Hinz A, Schroder C, Deutsch T, Geue K. Postoperative Health-Related Quality of Life of Cervical Cancer Patients - A Comparison between the Wertheim-Meigs Operation and Total Mesometrial Resection (TMMR). *Geburtshilfe Frauenheilkd.* 2014;74(7):670-6.

Spaans VM, Trietsch MD, Crobach S, Stelloo E, Kremer D, Osse EM, et al. Designing a high-throughput somatic mutation profiling panel specifically for gynaecological cancers. *PLoS One.* 2014;9(3):e93451.

Sparac V, Ujevic B, Ujevic M, Pagon-Belina Z, Marton U. Successful pregnancy after hysteroscopic removal of grade I endometrial carcinoma in a young woman with Lynch syndrome. *Int J Gynecol Cancer.* 2006;16 Suppl 1:442-5.

Speiser D, Mangler M, Kohler C, et al. Fertility Outcome After Radical Vaginal Trachelectomy: A Prospective Study of 212 Patients. *Int J Gynecol Cancer*. 2011.

Stein PD, Beemath A, Olson RE. Obesity as a risk factor in venous thromboembolism. *Am J Med*. 2005;118(9):978-80.

Stelloo E, Bosse T, Nout RA, MacKay HJ, Church DN, Nijman HW, et al. Refining prognosis and identifying targetable pathways for high-risk endometrial cancer; a TransPORTEC initiative. *Modern pathology : an official journal of the United States and Canadian Academy of Pathology, Inc*. 2015;28(6):836-44.

Sun L, Wu LY, Zhang WH, Li XG, Song Y, Zhang X. Preliminary study of nerve sparing radical hysterectomy in patients with cervical cancer. *Zhonghua Zhong Liu Za Zhi*. 2009;31(8):607-11.

Takahashi N, Hirashima Y, Harashima S, Takekuma M, Kawaguchi R, Yamada Y, et al. A patient with stage 1a endometrial carcinoma in whom a solitary recurrent lesion was detected in the external iliac lymph node after MPA therapy. *Arch Gynecol Obstet*. 2008;278(4):365-7.

Tang J, Li J, Wang S, Zhang D, Wu X. On what scale does it benefit the patients if uterine arteries were preserved during ART? *Gynecol Oncol*. 2014;134(1):154-9.

The World Health Organization Quality of Life assessment (WHOQOL): position paper from the World Health Organization. *Social science & medicine*. 1995;41(10):1403-9.

Thigpen JT, Brady MF, Alvarez RD, Adelson MD, Homesley HD, Manetta A, et al. Oral medroxyprogesterone acetate in the treatment of advanced or recurrent endometrial carcinoma: a dose-response study by the **Gynecologic Oncology Group**. *Journal of clinical oncology : official journal of the American Society of Clinical Oncology*. 1999;17(6):1736-44.

Thornton JG, Brown LA, Wells M, Scott JS. Primary treatment of endometrial cancer with progestagen alone. *Lancet*. 1985;2(8448):207-8.

Todo Y, Kuwabara M, Watari H, Ebina Y, Takeda M, Kudo M, et al. Urodynamic study on postsurgical bladder function in cervical cancer treated with systematic nerve-sparing radical hysterectomy. *Int J Gynecol Cancer*. 2006;16(1):369-75.

Tran BN, Connell PP, Waggoner S, Rotmensch J, Mundt AJ. Characteristics and outcome of endometrial carcinoma patients age 45 years and younger. *American journal of clinical oncology*. 2000;23(5):476-80.

Treffers. *Obstetrie en gynaecologie*. 2e herziene druk ed1995. p. 672.

Trimbos JB, Maas CP, Deruiter MC, Kenter GG. [Nerve sparing radical hysterectomy in the case of cervical cancer]. *Ned Tijdschr Geneesk*. 2003;147(28):1344-7.

Trimbos JB, Maas CP, Deruiter MC, Peters AA, Kenter GG. A nerve-sparing radical hysterectomy: guidelines and feasibility in Western patients. *Int J Gynecol Cancer*. 2001;11(3):180-6.

Trimbos JB, Van Den Tillaart SAHM, Maas CP, Peters AAW, Gaarenstroom KN, Deruiter MC, et al. The Swift operation: A modification of the Leiden nerve-sparing radical hysterectomy. *Gynecological Surgery*. 2008;5(3):193-8.

Tseng CJ, Shen HP, Lin YH, Lee CY, Wei-Cheng CW. A prospective study of nerve-sparing radical hysterectomy for uterine cervical carcinoma in Taiwan. *Taiwan J Obstet Gynecol*. 2012;51(1):55-9.

Twijnstra AR, Blikkendaal MD, van Zwet EW, van Kesteren PJ, de Kroon CD, Jansen FW. Predictors of successful surgical outcome in laparoscopic hysterectomy. *Obstetrics and gynecology*. 2012;119(4):700-8.

Ulbright TM, Roth LM. Metastatic and independent cancers of the endometrium and ovary: a clinicopathologic study of 34 cases. *Human pathology*. 1985;16(1):28-34.

Ushijima K, Yahata H, Yoshikawa H, Konishi I, Yasugi T, Saito T, et al. Multicenter phase II study of fertility-sparing treatment with medroxyprogesterone acetate for endometrial carcinoma and atypical hyperplasia in young women. *Journal of clinical oncology : official journal of the American Society of Clinical Oncology*. 2007;25(19):2798-803.

van den Tillaart SA, Kenter GG, Peters AA, Dekker FW, Gaarenstroom KN, Fleuren GJ, et al. Nerve-sparing radical hysterectomy: local recurrence rate, feasibility, and safety in cervical cancer patients stage IA to IIA. *Int J Gynecol Cancer*. 2009;19(1):39-45.

van der Zee M, Jia Y, Wang Y, Heijmans-Antonissen C, Ewing PC, Franken P, et al. Alterations in Wnt-beta-catenin and Pten signalling play distinct roles in endometrial cancer initiation and progression. *J Pathol*. 2013;230(1):48-58.

van Eijk R, Licht J, Schrupf M, Talebian YM, Ruano D, Forte GI, et al. Rapid KRAS, EGFR, BRAF and PIK3CA mutation analysis of fine needle aspirates from non-small-cell lung cancer using allele-specific qPCR. *PLoS One*. 2011;6(3):e17791.

van Gent MD, van den Haak LW, Gaarenstroom KN, Peters AA, van Poelgeest MI, Trimbos JB, et al. Nerve-sparing radical abdominal trachelectomy versus nerve-sparing radical hysterectomy in early-stage (FIGO IA2-IB) cervical cancer: a comparative study on feasibility and outcome. *Int J Gynecol Cancer*. 2014;24(4):735-43.

van Gent MDJM, Kagie MJ, Trimbos JB. No surgery for Low-Grade Endometrial Cancer in Women with a Desire to Preserve Fertility. *Journal of gynecologic Surgery*. 2012;28(6):389-98.

van Gent MDJM, Kagie MJ, Trimbos JBMZ. Conservatieve behandeling van endometriumcarcinoom bij patiënten met kinderwens. *Nederlands Tijdschrift voor Obstetrie en Gynaecologie*. 2009;122:33-6.

van Gent MDJM, Romijn LM, van Santen KE, Trimbos JBMZ, De Kroon CD. Nerve-sparing radical hysterectomy versus conventional radical hysterectomy in early stage cervical cancer. A systematic review and meta analysis of survival and quality of life. *Maturitas*. 2016;94.

Vasen HF, Wijnen JT, Menko FH, et al. Cancer risk in families with hereditary nonpolyposis colorectal cancer diagnosed by mutation analysis. *Gastroenterology* 1996;110:1020.

Vereide AB, Kaino T, Sager G, Orbo A. Bcl-2, BAX, and apoptosis in endometrial hyperplasia after high dose gestagen therapy: a comparison of responses in patients treated with intrauterine levonorgestrel and systemic medroxyprogesterone. *Gynecol Oncol*. 2005;97(3):740-50.

Vinker S, Shani A, Open M, Fenig E, Dgani R. Conservative treatment of adenocarcinoma of the endometrium in young patients. Is it appropriate? *Eur J Obstet Gynecol Reprod Biol*. 1999;83(1):63-5.

Wan YL, Beverley-Stevenson R, Carlisle D, Clarke S, Edmondson RJ, Glover S, et al. Working together to shape the endometrial cancer research agenda: The top ten unanswered research questions. *Gynecol Oncol*. 2016;143(2):287-93.

Wang CB, Wang CJ, Huang HJ, Hsueh S, Chou HH, Soong YK, et al. Fertility-preserving treatment in young patients with endometrial adenocarcinoma. *Cancer*. 2002;94(8):2192-8.

Wang S, Pudney J, Song J, Mor G, Schwartz PE, Zheng W. Mechanisms involved in the evolution of progesterin resistance in human endometrial hyperplasia--precursor of endometrial cancer. *Gynecol Oncol*. 2003;88(2):108-17

Wang W, Li B, Zuo J, Zhang G, Yang Y, Zeng H, et al. Evaluation of pelvic visceral functions after modified nerve-sparing radical hysterectomy. *Chin Med J (Engl)*. 2014;127(4):696-701.

Wang Y, Hanifi-Moghaddam P, Hanekamp EE, Kloosterboer HJ, Franken P, Veldscholte J, et al. Progesterone inhibition of Wnt/beta-catenin signaling in normal endometrium and endometrial cancer. *Clin Cancer Res*. 2009;15(18):5784-93.

Wang Y, van der Zee M, Fodde R, Blok LJ. Wnt/Beta-catenin and sex hormone signaling in endometrial homeostasis and cancer. *Oncotarget*. 2010;1(7):674-84.

Wenwen W, Bin L, Jing Z, Gongyi Z, Yeduo Y, Hongmei Z, et al. [Evaluation of postoperative bladder function and prognosis after modified nerve sparing radical hysterectomy]. *Zhonghua Fu Chan Ke Za Zhi*. 2014;49(5):341-7.

A

Wheeler DT, Bristow RE, Kurman RJ. Histologic alterations in endometrial hyperplasia and well-differentiated carcinoma treated with progestins. *Am J Surg Pathol.* 2007;31(7):988-98.

Wirawan JP, Hakim S, Prihartono J, Rohim AA. The efficacy of nerve sparing technique during radical hysterectomy in reducing post operative urinary retention: Experience in Jakarta, Indonesia. *International Journal of Gynecological Cancer.* 2014;Conference: 14th Biennial Meeting of the International Gynecologic Cancer Society:October 2012.

Wu HM, Lai CH, Huang HY, Wang HS, Soong YK. A successful live twin birth by in vitro fertilization after conservative treatment of recurrent endometrial cancer. *Chang Gung medical journal.* 2008;31(1):102-6.A229

Wu J, Liu X, Hua K, Hu C, Chen X, Lu X. Effect of nerve-sparing radical hysterectomy on bladder function recovery and quality of life in patients with cervical carcinoma. *Int J Gynecol Cancer.* 2010;20(5):905-9.

Xie BG, Lu WY, Huang YH, Zhu WJ. Quality of life in cervical cancer treated with systematic nerve-sparing and modified radical hysterectomies. *J Obstet Gynaecol.* 2015;35(8):839-43.

Yahata T, Fujita K, Aoki Y, Tanaka K. Long-term conservative therapy for endometrial adenocarcinoma in young women. *Hum Reprod.* 2006;21(4):1070-5.

Yamazawa K, Hirai M, Fujito A, Nishi H, Terauchi F, Ishikura H, et al. Fertility-preserving treatment with progestin, and pathological criteria to predict responses, in young women with endometrial cancer. *Human reproduction (Oxford, England).* 2007;22(7):1953-8.

Yan H, Liu Z, Fu X, Li Y, Che H, Mo R, et al. Long-term outcomes of radical vaginal trachelectomy and laparoscopic pelvic lymphadenectomy after neoadjuvant chemotherapy for the IB1 cervical cancer: A series of 60 cases. *International journal of surgery.* 2016;29:38-42.

Yang YC, Wu CC, Chen CP, Chang CL, Wang KL. Reevaluating the safety of fertility-sparing hormonal therapy for early endometrial cancer. *Gynecologic oncology.* 2005;99(2):287-93.

Yang S, Thiel KW, Leslie KK. Progesterone: the ultimate endometrial tumor suppressor. *Trends Endocrinol Metab.* 2011;22(4):145-52.

Yao YY, Wang Y, Wang JL, Zhao C, Wei LH. Outcomes of fertility and pregnancy in patients with early-stage cervical cancer after undergoing neoadjuvant chemotherapy. *European journal of gynaecological oncology.* 2016;37(1):109-12.

Yarali H, Bozdag G, Aksu T, Ayhan A. A successful pregnancy after intracytoplasmic sperm injection and embryo transfer in a patient with endometrial cancer who was treated conservatively. *Fertil Steril.* 2004;81(1):214-6.

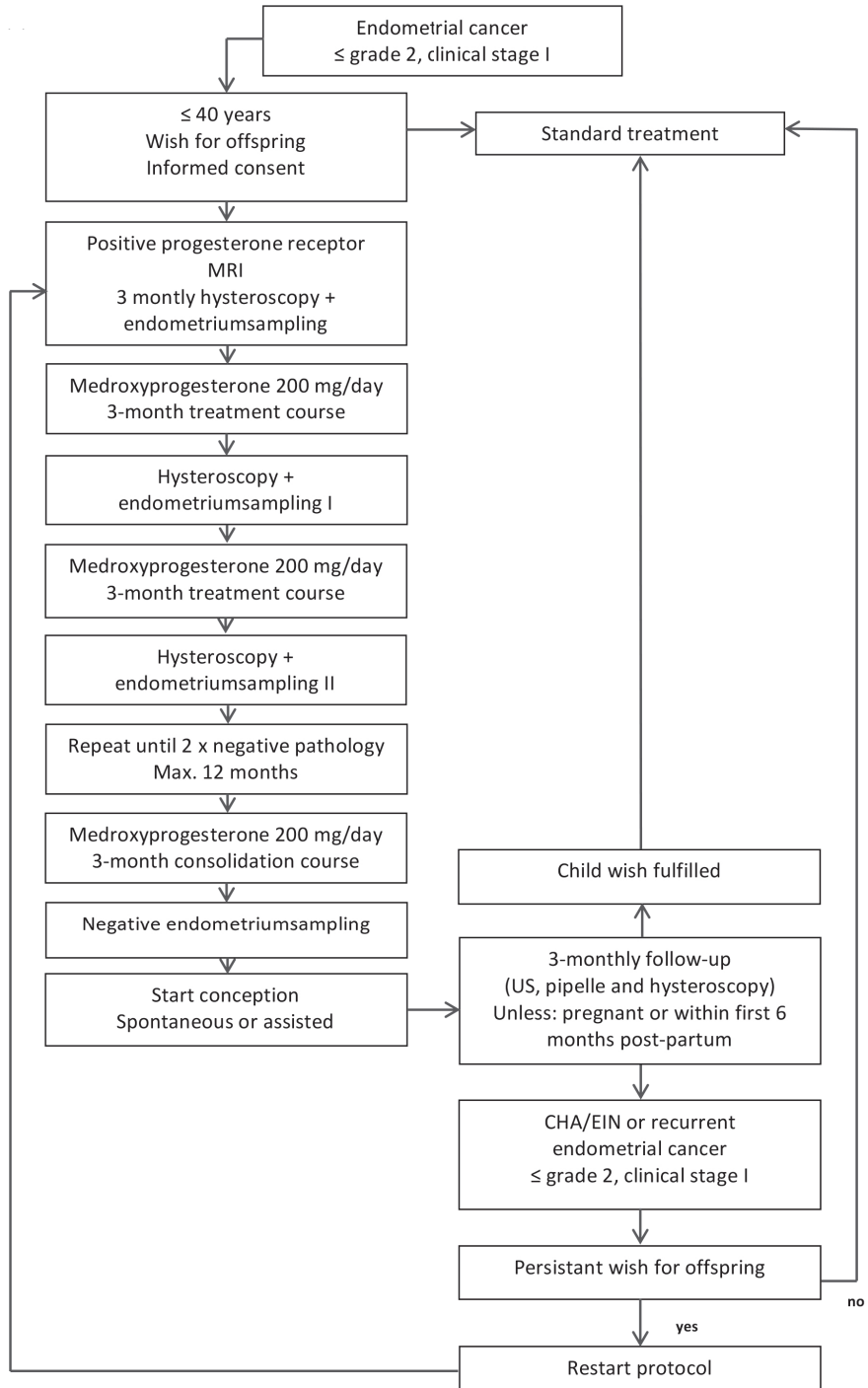
References

Zanetta G GA, Losa G, Cappellini A, Mangioni C. conservative management of endometrial carcinoma with prolonged preservation of the uterus in a young patient. *Int J Gynecol Cancer*. 1997;7:332-4.

Zuckerman B LO, Neumann M, et al. Endometrial carcinoma Stage I-Grade II. Conservative treatment followed by a healthy twin pregnancy. *Int J Gynecol Cancer*. 2002;8(2):172-4.



APPENDIX 1. FLOWCHART





APPENDIX 2.

Part 1a. Results of 33 patients with EIN or LG EEC treated with progesterones in order to preserve fertility

Treated according to protocol	Pts (n = 33)	Age at Dx	BMI	Reason for analysis	GxPx pre-Tx	MRI	PA	PR	ER	Tx
NO	a	33	28.7	F	G1P0	-	LG EEC	+	+	MPA other
NO	b	21	38.8	P	G0	Normal	LG EEC	+	uk	MPA other (12 mo) + LNG-IUD
NO	c	33	26.0	F	G0	<50 % MI	LG EEC	+	+	MPA other
NO	d	29	28.0	F & P	G.P1	Normal	LG EEC	+	+	MPA 200mg/d + LNG-IUD
NO	e	30	38.2	F & P	G0	0 % MI	LG EEC	uk	uk	MPA other
NO	f	37	30.0	P	G0	Normal	LG EEC	+	uk	MPA 200mg/d
NO	g	36	33.2	F & P	G0	-	LG EEC	uk	uk	MPA other + LNG-IUD
NO	h	40	24.0	P	G0	> 50% MI	LG EEC	+	+	MPA 200mg/d
NO	i	32	23.7	P	G0	<50 % MI	LG EEC	+	+	MPA 200mg/d
NO	j	27	31.1	F	G1P1	Normal	LG EEC	+	+	MPA 200mg/d
NO	k	38	23.2	F	G3P0	0 % MI	LG EEC	+	+	Prog. other
NO	l	28	32.9	F & P	G.P1	-	EIN	uk	uk	MPA other
YES	m	33	-	P	G0	-	EIN	+	+	MPA 200mg/d
YES	n	37	28.0	P	G1P0	-	EIN	+	+	Endometrium resection + MPA 200mg/d

Appendix 2. Clinical data and follow-up of Dutch cohort

Duration Course 1	FR after	CR after	Time to recurrence after end Tx	No of Hx	Fertility after course 1	Duration Course 2	FR after	CR after	Time to recurrence after end Tx	No of Hx
11 mo	5 mo	11 mo	-	9	1 x term, 1 x MC	-	-	-	-	-
24 mo	10 mo	24 mo	-	8	0	-	-	-	-	-
8 mo	4 mo	8 mo	16 mo	3	0 (2 x IVF/ ICSI)	4 mo	1 mo	4 mo	-	6
12 mo +	?	?	-	5 +	1	-	-	-	-	-
10 mo	9 mo	-	21 mo	3	1 x MC	4 mo	3 mo	-	-	2
19 mo	16 mo	19 mo	7 mo	8	0	-	-	-	-	-
17 mo	17 mo	-	5 mo	7	0	-	-	-	-	-
25 mo	17 mo	-	-	6	0	-	-	-	-	-
3 mo	-	-	-	3	0	-	-	-	-	-
12 mo	5 mo	8 mo	3 mo	4	0	22 mo ?	19 mo	22 mo	43 mo	6
10 mo	6 mo	-	-	5	0	-	-	-	-	-
8 mo	5 mo	8 mo	20 mo	6	0	14 mo	5 mo	22 mo	15 mo	7
11 mo	4 mo	7 mo	-	6	1 x AD 25 wk	-	-	-	-	-
8 mo	3 mo	8 mo	-	-	-	-	-	-	-	-

A

Part 1 a. Continued

Treated according to protocol	Pts (n = 33)	Age at Dx	BMI	Reason for analysis	GxPx pre-Tx	MRI	PA	PR	ER	Tx
YES	o	35	20.8	F	G0	Normal	LG EEC	+	+	MPA 200mg/d
YES	p	37	23.0	F	G0	Normal	LG EEC	+	+	MPA 200mg/d
YES	q	39	-	P	G0	Normal	LG EEC	+		MPA 200mg/d + LNG-IUD
YES	r	31	20.2	P	G0	0 % MI	LG EEC	+	+	MPA 200mg/d
YES	s	36	23.0	F	G0	-	EIN	-	+	MPA 200mg/d
YES	t	36	36.9	F	G1P0	-	EIN	+	+	MPA 200mg/d
YES	u	29	22.0	F	G0	0 % MI	LG EEC	+	+	MPA other
YES	v	34	27.7	P	G0	-	LG EEC	+	+	Prog. other
YES	w	37	48.0	uk	G0	-	LG EEC	+	+	MPA 200mg/d
YES	x	32	30.1	F & P	G0	Normal	LG EEC	+	+	MPA 200mg/d + LNG-IUD
YES	y	37	25.6	P	G0	0 % MI	LG EEC	+	+	MPA 200mg/d
YES	z	27	35.0	P	G0	<50 % MI	LG EEC	+	uk	MPA 200mg/d
YES	aa	35	20.0	F	G0	0 % MI	LG EEC	+	uk	MPA 200mg/d
YES	bb	31	23.9	P	G0	0 % MI	LG EEC	+	+	MPA 200mg/d
YES	cc	25	29.0	P	G0	-	LG EEC	+		MPA 200mg/d + LNG-IUD
YES	dd	28	23.9	P	G0	Normal	LG EEC	+	+	MPA 200mg/d

Duration Course 1	FR after	CR after	Time to recurrence after end Tx	No of Hx	Fertility after course 1	Duration Course 2	FR after	CR after	Time to recurrence after end Tx	No of Hx
9 mo	6 mo	9 mo	23 mo	6	0	6 mo	3 mo	6 mo	-	3+
6 mo	3 mo	6 mo	-	9	2 (1 x IUFD AD 16 wk, 1 x term)	-	-	-	-	-
11 mo	7 mo	11 mo	-	5	0	-	-	-	-	-
10 mo	4 mo	7 mo	-	6	-	-	-	-	-	-
7 mo	2 mo	6 mo	-	-	-	-	-	-	-	-
10 mo	7 mo	10 mo	-	-	-	-	-	-	-	-
10 mo	5 mo	8 mo	-	-	1 x term	-	-	-	-	-
11 mo	3 mo	-	-	5	0	-	-	-	-	-
6 mo	3 mo	6 mo	-	3	0	-	-	-	-	-
4 mo	-	-	-	2	0	-	-	-	-	-
11 mo	-	-	-	5	0	-	-	-	-	-
6 mo	3 mo	6 mo	13 mo	6	0	-	-	-	-	-
14 mo	10 mo	14 mo	8 mo	6	0	6 mo	3 mo	6 mo	12 mo	3
11 mo	4 mo	7 mo	11 mo	7	0	-	-	-	-	-
34 mo	5 mo	8 mo	5 mo	7	0	3 mo +	-	-	-	-
6 mo	3 mo	6 mo	6 mo	4	0	12 mo	4 mo	-	-	-

A

Part 1a. Continued

Treated according to protocol	Pts (n = 33)	Age at Dx	BMI	Reason for analysis	GxPx pre-Tx	MRI	PA	PR	ER	Tx
YES	ee	27	27.4	F	G0	Normal	LG EEC	+	+	MPA 200mg/d
YES/no [‡]	ff	38	22.8	F	G0	0 % MI	LG EEC	+	+	MPA other
YES/no [¶]	gg	31	22.0	P	G0	0 % MI	LG EEC			MPA 200mg/d

Legend: Dx: diagnosis, Tx: therapy, FR: first response, CR: complete response, Hx: hysteroscopy, FU: follow-up, LNG-IUD: levonogestrel releasing IUD, MPA: medroxyprogesterone, mo: months, F: fertility issues, P: period issues, ER: Estrogen receptor, PR: progesterone receptor, MI: myometrial involvement, MC: miscarriage, LG ECC: low-grade endometrial cancer, EIN: endometrioid intra-epithelial neoplasia, Hyst: hysterectomy, BSO: bilateral salpingo-oophorectomy, USO: unilateral salpingo-oophorectomy, NED: no evidence of disease, IUFD: intra-uterine fetal death, term: term delivery, GTD: Gestational Trophoblastic Disease, LTFU: lost to follow up.

Duration Course 1	FR after	CR after	Time to recurrence after end Tx	No of Hx	Fertility after course 1	Duration Course 2	FR after	CR after	Time to recurrence after end Tx	No of Hx
11 mo	3 mo	6 mo	36 mo	9	1 x term 1 x MC	6 mo	3 mo	6 mo	-	3
9 mo	9 mo	12 mo	-	5	0	-	-	-	-	-
9 mo	4 mo	7 mo	- 3 mo ^{##}	5	1 x MC	-	-	-	-	-

Definitions: Negative pathology result: no abnormalities/hyperplasia without atypia/progesterone effect; Responder: 2 x negative pathology result

- * Recurrence in remaining ovary. Laparoscopic resection, no other signs of disease, abdominal fluid negative. Adjuvant pelvic irradiation. Stage 3 EC.
- ** Advice: hysterectomy since no response after 12 months. Second opinion abroad: continued medication and resulted in response and pregnancy, therefore temporarily LTFU.
- *** Temporarily refusal for definitive therapy
- **** Progression after first 3 mo. Advice: hysterectomy, temporarily refusal by patient, 4 month delay until surgery.
- # Last therapy before Hysterectomy was endometrium resection
- ## 3 Months before stop progesterone: EIN
- ¥ Mostly but no because therapy was stopped after only one negative pathology report
- ¥¥ Mostly but no because therapy was stopped even though 3 months before pathology was reported as EIN

A

Appendices

Part 1b. Results of 33 patients with EIN or LG EEC treated with progesterones in order to preserve fertility

Treated according to protocol	Pts (n = 33)	Fertility after course 2	Total FU	Status at last FU	Final treatment	PA final
NO	a	-	124 mo	NED	FU	-
NO	b	-	24 mo	NED	FU	-
NO	c	0 (IVF-ICSI attempt)	87 mo	NED	FU	-
NO	d	-	34 mo	NED	FU	-
NO	e	1 x MC 2 x Term	129 mo	NED	Hysterectomy	no cancer
NO	f	-	75 mo	NED	Hysterectomy	LG EEC
NO	g	-	33 mo	NED	Hysterectomy + BSO	LG EEC
NO	h	-	38 mo	NED	Hysterectomy + BSO	LG EEC
NO	i	-	23 mo	NED	Hysterectomy + BSO	LG EEC
NO	j	2 x MC	89 mo	NED	Hysterectomy + tubectomy	no cancer
NO	k	-	16 mo	LG EEC	Hysterectomy + tubectomy	no cancer #
NO	l	0	59 mo	EIN	Ongoing treatment	-
YES	m	-	19 mo	Pregnant AD 25	FU	-
YES	n	-	15 mo	NED	FU	-

Stage	Reason Hysterectomy	GxPx post-Tx	Fertility tx	Pregnancy outcome	Recurrence after hysterectomy	Other
-	-	G3P1	IVF	1 x term, 1 x MC	-	Temp. LTFU
-	-	G0	-	UK	-	FU elsewhere
-	-	G0	IVF/ICSI	-	-	LTFU gyn, GP: NED
-	-	-	-	Pre-term delivery AD 36.5	-	SO abroad**
-	Completed family	G4P2	IUI	2 x Term 2 x MC	no	2 Extra periods of LNG-IUD
1A	Inadequate response + recurrent disease	G0	IVF	-	no	-
1A	Recurrence	G0	none	-	-	After 10 mo + LNG-IUD
1A	Persistent disease	G0	-	-	no	Patient delay ***
3	Progressive disease	G0	-	-	no	Patient delay ****
-	doubt on IVF chances	G3P1	IVF	2 x MC	no	Course 3: CR after 6 months, 7 hysteroscopies
-	no response	G3P0	-	-	no	
-	-	-	-	-	-	-
-	-	G1 AD 25 wk	none	AD 25 wk	-	-
-	-	-	-	-	-	-



Part 1b. Continued

Treated according to protocol	Pts (n = 33)	Fertility after course 2	Total FU	Status at last FU	Final treatment	PA final
YES	o	-	89 mo	NED	FU	-
YES	p	-	49 mo	NED	FU	-
YES	q	-	26 mo	NED	FU	-
YES	r	-	14 mo	NED	FU	-
YES	s	-	9 mo	NED	FU	-
YES	t	-	10 mo	NED	FU	-
YES	u	-	21 mo	post partum	FU	-
YES	v	-	46 mo	NED	Hysterectomy	no cancer
YES	w	-	33 mo	NED	Hysterectomy	LG EEC
YES	x	-	23 mo	NED	Hysterectomy + BSO	LG EEC
YES	y	-	23 mo	NED	Hysterectomy + BSO	LG EEC
YES	z	-	20 mo	NED	Hysterectomy + tubectomy	LG EEC
YES	aa	0	75 mo	NED	Hysterectomy + tubectomy	no cancer
YES	bb	-	62 mo	NED	Hysterectomy + USO	LG EEC
YES	cc	-	40 mo	EIN	Ongoing treatment	-
YES	dd	-	25 mo	NED	Ongoing treatment	-
YES	ee	1 x AD 32	67 mo	Pregnant AD 32	-	-

Stage	Reason Hysterectomy	GxPx post-Tx	Fertility tx	Pregnancy outcome	Recurrence after hysterectomy	Other
-	-	G0	IUI	-	-	-
-	-	G2P2-1	IVF	1 x IUFD 1 x term	-	-
-	-	-	-	-	-	-
-	-	-	-	-	-	-
-	-	-	IUI	-	-	-
-	-	-	-	-	-	-
-	-	G1 P1	IVF	1 x term	-	-
1A	no response	0	-	-	no	-
1A	no more wish to preserve fertility	0	-	-	no	-
1A	no more wish to preserve fertility	G0	-	-	no	-
1A	no response	G0	-	-	no	-
1A	recurrence	G0	clomid	-	no	-
-	recurrence	G0	none	-	no	Extra periods of LNG-IUD
1A	recurrence	G0	none	0	yes *	-
-	-	-	-	-	-	Repeated dislocation LNG-IUD
-	-	-	-	-	-	-
-	-	G3P1	IUI	1 x term, 1 x MC, 1 x AD 32 wkn	-	-



Part 1b. Continued

Treated according to protocol	Pts (n = 33)	Fertility after course 2	Total FU	Status at last FU	Final treatment	PA final
YES/no [¥]	ff	-	53 mo	NED	Hysterectomy	LG EEC
YES/no ^{¥¥}	gg	-	16 mo	GTD	-	-

Legend: Dx: diagnosis, Tx: therapy, FR: first response, CR: complete response, Hx: hysteroscopy, FU: follow-up, LNG-IUD: levonogestrel releasing IUD, MPA: medroxyprogesterone, mo: months, F: fertility issues, P: period issues, ER: Estrogen receptor, PR: progesterone receptor, MI: myometrial involvement, MC: miscarriage, LG ECC: low-grade endometrial cancer, EIN: endometrioid intra-epithelial neoplasia, Hyst: hysterectomy, BSO: bilateral salpingo-oophorectomy, USO: unilateral salpingo-oophorectomy, NED: no evidence of disease, IUFD: intra-uterine fetal death, term: term delivery, GTD: Gestational Trophoblastic Disease, LTFU: lost to follow up.

Stage	Reason Hysterectomy	GxPx post-Tx	Fertility tx	Pregnancy outcome	Recurrence after hysterectomy	Other
1A	Hyperplasia, no atypia, worries with doctor/pt	G0	none	-	no	-
-	-	1	-	1 x MC	-	-

Definitions: Negative pathology result: no abnormalities/hyperplasia without atypia/progesterone effect; Responder: 2 x negative pathology result

- * Recurrence in remaining ovary. Laparoscopic resection, no other signs of disease, abdominal fluid negative. Adjuvant pelvic irradiation. Stage 3 EC.
- ** Advice: hysterectomy since no response after 12 months. Second opinion abroad: continued medication and resulted in response and pregnancy, therefore temporarily LTFU.
- *** Temporarily refusal for definitive therapy
- **** Progression after first 3 mo. Advice: hysterectomy, temporarily refusal by patient, 4 month delay until surgery.
- # Last therapy before Hysterectomy was endometrium resection
- ## 3 Months before stop progesterone: EIN
- ¥ Mostly but no because therapy was stopped after only one negative pathology report
- ¥¥ Mostly but no because therapy was stopped even though 3 months before pathology was reported as EIN

A

Part 2. Results of 33 patients with EIN or LG EEC treated with progesterones in order to preserve fertility

Age	mean/median	33
BMI	mean	28
	median	27.4
Follow-up (months)	mean	44.4
	median	33
CR course 1 (n)		61% (20/33)
Time to CR course 1 (months)	mean	8
	median	7.5
Recurrence after CR course 1 (n)		65% (13/20)
Time to recurrence after stop Tx course 1 (months)	mean	13.4
	median	11
CR course 2 after recurrence (9 attempts)		67% (6/9)
Time to CR course 2 (months)	mean	11
	median	6
Recurrence after CR course 2 (n)		50% (3/6)
Time to recurrence after stop Tx course 2 (months)	mean	23.3
	median	15
Pregnancies		17
Term delivery		6
Pre-term delivery (AD 36.5 wk)		1
Pregnant (AD 25 + 32 wk)		2
IUFD (16 wks)		1
Miscarriage		7
Hysterectomies		15
No malignancy		5
Grade 1		10
	Stage 1A	9
	Stage 3	1
Recurrence after hysterectomy + USO	Ovarian met.	1

A

CURRICULUM VITAE

The author of this thesis was born in Veghel, the Netherlands, on September 14, 1980. She attended the public elementary school "De Uilenbrink" in Veghel and went subsequently to the pre-university school "Gymnasium Bernrode".

She started medical school at the University of Leiden in September 1998 and obtained her bachelor's degree in 1999. From 1999 until 2005 she studied medicine. During this time, she spent a month in Messina, Sicily, learning under Professor Maggazu' (paediatrics). After receiving a grant from the Dutch and the American Heart association, she worked during half a year, under Associate Professor Mary Etta King (paediatrics), as a researcher on extra corporeal membrane oxygenation (ECMO) at the department of paediatric cardiology of Harvard affiliated Massachusetts General Hospital, Boston, USA. Directly after finishing medical school she started working as a junior obstetrics and gynaecology resident at Haaglanden Medical Center (HMC), The Hague, previously known as Medical Center Haaglanden (MCH). She continued working there as a registrar from 2008 onwards (Prof. Dr. P.J. Dörr †, Dr. M.J. Kagie). The academic part of the training was performed at the Leiden University Medical Center (Prof. Dr. H.H.H. Kanhai, later Prof. Dr. J.M.M. van Lith), Leiden. She went to Perth, Australia to do her fourth year of training at the King Edward Memorial Hospital (Dr. Anne Karczub).

During her junior residency, she started the research on conservative management of endometrial cancer for women with the desire to preserve fertility. This developed into a PhD project including fertility-sparing and nerve-sparing surgery for cervical cancer. In 2014 she finished her training and became a consultant gynaecologist. She started her career as a gynaecologist at the HMC. In order to realize her future goal of becoming a gynaecologic oncologist, she started at the Antoni van Leeuwenhoek Hospital - Netherlands Cancer Institute in Amsterdam as a consultant. In 2016, she started her fellowship gynaecologic oncology at the Center of Gynaecologic Oncology Amsterdam.

Mignon is married to Sjoerd Meijer and they have 3 sons: Mats (2011), Joep (2013) and Wiebe (2014).



ACKNOWLEDGEMENTS/DANKWOORD

Dankzij de steun van velen is dit proefschrift tot stand gekomen. Het is onmogelijk iedereen te noemen maar ik wil een aantal in het bijzonder bedanken.

De patiënten - Gynaecologen die patiënten hebben aangeleverd voor het onderzoek - Secretariaten gynaecologie van het HMC, LUMC en AVL - Landsteiner Instituut/wetenschapscommissie (HMC) - Maatschap gynaecologie HMC - Mijn oud-opleiders Joep Dörr †, Marjolein Kagie, Cas Holleboom, Humphrey Kanhai, Anne Karczub en Jan van Lith - Afdelingen pathologie en medische statistiek en ethiek (LUMC) - Mijn opleidingsgenoten en in het bijzonder Muriel, Jessica, Heleen en Wietske - Jan Schoones (Walaeus bibliotheek), Thomas Vissers (bibliotheek HMC) - Ellen, Inge (x2), Mandy, Dacia, Evelien, Loes en Karin en Linda; jullie kennis, loyaliteit en doorzettingsvermogen zijn van grote waarde - Mijn collega's uit het AVL: Marc, Hans, Willemien, Christianne, Henry, Nienke, Frédéric, Lotte, Samantha, Regillio en de rest van het CGOA. Frédéric, het eerste kopje koffie op de stoep voor onze introductiecursus bleek goud waard - Marijke, dank voor je snelle acties op mijn duizenden verzoeken (en je koffie en zelfgemaakte taart) - Mijn vrienden - Mijn co-autheurs - Mijn (schoon) familie - aanhang - Saskia Sedney, zonder jou waren we nergens - Lobke, Kaak en Moniek, old friends en natuurlijk mijn paranimfen Wietske, Naomi en Eveliene.

-
Baptist, ik heb veel respect voor jouw chirurgische kunsten en ben vereerd nog "in het staartje" je promovendus te mogen zijn.

-
Cor, dank voor je positieve energie en je flexibiliteit, wat was het een project! Heel fijn hoe je me altijd weer wist te motiveren om door te gaan.

-
Marjolein, vanaf dag één dat ik in het Westeinde binnenstapte was het goed en heb je me gestimuleerd onderzoek te doen en werk te maken van mijn carrière. Je hebt meermaals een cruciale rol gespeeld in deze, ik kan je daar niet genoeg voor bedanken.

-
Gemma "G", jij hebt het stokje van Marjolein overgenomen. De sandwich op de IGCS was hilarisch, gelukkig hadden we publiek.

-
Ko, dank voor je eis dat mijn proefschrift af moest zijn voor de start van mijn fellowship. Dat gaf de boost om er een flinke slinger aan te geven. In ieder geval is het af voordat ik naar het AMC kom.

Lieve Naomi en Eveliene, jullie zijn vanaf de eerste studiedag van geneeskunde mijn dikke vriendinnen en daar is nooit verandering in gekomen. We hebben zo veel life events met elkaar doorgemaakt en elkaar zien groeien in het vak en in het leven. Dit zetten we voort tot we 134 zijn. Lieve Caro, jij vlocht hier mooi bij in, en dank voor het prachtige kunstwerk op de kaft.

-

Lieve Wiets, we hebben ieder duidelijk een andere weg gekozen maar blijven ongelofelijk veel overeenkomsten creëren. Ik vind dat mooi.

-

Lieve opa en oma van Gent, dank voor alles, u mag weer naar het academiegebouw!

-

Lieve opa en oma van Well, vreselijk zonde dat ik dit proefschrift niet meer aan u kan sturen, maar ik voel me nog altijd door jullie gesteund.

-

Lieve ouders, dank voor jullie onvoorwaardelijke steun vanaf het moment dat ik dokter wilde worden op de basisschool. Jullie hebben nooit getwijfeld aan mijn kunnen en hebben altijd overal kansen in gezien. Jullie hebben mij geleerd dat doelen bereikbaar zijn.

-

Lieve broertjes en zusje (Harry, Sébastiaan en Nathalie), ik ben trots op alles wat jullie doen, trots op jullie als persoon en trots dat ik jullie zus ben.

-

Lieve mannen, Sjoerd, Mats, Joep en Wiebe, jullie zijn mijn liefsten. Doordat jullie zo onvermoeibaar, energiek, positief, ondersteunend, komisch, fysiek, puur, onvoorwaardelijk en lief zijn, kan ik de wereld aan.



