



Universiteit
Leiden
The Netherlands

Recent innovations in minimally invasive anterior and posterior lamellar keratoplasty

Parker, J.

Citation

Parker, J. (2017, July 4). *Recent innovations in minimally invasive anterior and posterior lamellar keratoplasty*. Retrieved from <https://hdl.handle.net/1887/50484>

Version: Not Applicable (or Unknown)

License: [Licence agreement concerning inclusion of doctoral thesis in the Institutional Repository of the University of Leiden](#)

Downloaded from: <https://hdl.handle.net/1887/50484>

Note: To cite this publication please use the final published version (if applicable).

Cover Page



Universiteit Leiden



The handle <http://hdl.handle.net/1887/50484> holds various files of this Leiden University dissertation

Author: Parker, Jack

Title: Recent innovations in minimally invasive anterior and posterior lamellar keratoplasty

Issue Date: 2017-07-04

Chapter 4

Bowman Layer Transplantation for Advanced Keratoconus: The First American Case

Jack S. Parker, MD^{1,2,3}; John S. Parker, MD³; Korine van Dijk, BSc^{1,2}; Vasilis Liarakos, MD PhD^{1,2}; Salvatore Luceri, MD^{1,2}; Isabel Dapena, MD PhD^{1,2} and Gerrit R.J. Melles MD PhD^{1,2,4}

¹Netherlands Institute for Innovative Ocular Surgery, Rotterdam, The Netherlands; ²Melles Cornea Clinic Rotterdam, The Netherlands, ³UAB Callahan Eye Hospital, Birmingham, Alabama ⁴Amnitrans EyeBank Rotterdam, The Netherlands.

ABSTRACT

Purpose: To describe the results of the first Bowman Layer (BL) Transplant performed in the United States

Methods: One eye of one patient with advanced, progressive keratoconus was treated by BL transplantation, in which an isolated donor BL was implanted within the mid-stroma of a recipient cornea. At one day, week, month, and three months postoperatively; visual acuity and corneal clarity, density, thickness, and topographic measurements were recorded and compared to their preoperative values.

Results: The day after surgery, best spectacle corrected vision was 20/40. One week postoperatively, the cornea was thin and clear with the profile of the BL graft only barely visible by slit-lamp examination. By three months, whereas both corneal density and thickness were unchanged, maximum keratometry values had fallen from 62.9 diopters (D) to 58.3 D. With a rigid contact lens the preoperative visual acuity of 20/30 was restored. No intra- or postoperative complications were observed.

Conclusion: Early evidence suggests BL transplantation to be a safe and effective means of flattening and stabilizing corneas with advanced keratoconus.

KEYWORDS

Bowman Layer Transplantation, Keratoconus, Corneal Transplantation, Lamellar keratoplasty

The past decade has seen a reversal in the dominant philosophy regarding the management of patients with keratoconus (KC). Whereas previously, a conservative approach prevailed (aiming at avoiding or delaying surgery for as long as possible), now a policy of early intervention predominates, in which preventative action to arrest the course of the disease is regarded as the soundest strategy. To this end, new therapies such as ultraviolet corneal crosslinking (UVCXL) and intracorneal ring segments (ICRS) have been developed. But some eyes remain poor candidates for either procedure, and may continue to progress.¹

Recently, however, a new procedure has emerged for patients with advanced KC known as Bowman Layer (BL) Transplantation. In this operation, a graft consisting exclusively of an isolated donor BL is transplanted into the midstroma of a keratoconic cornea. The healing response around the graft functions to both flatten the cornea into a more normal configuration and also halt further ectasia. As a result, contact lens tolerance may be preserved or restored and both penetrating and deep anterior lamellar keratoplasty (PK and DALK, respectively) avoided.^{2,3}

To date, however, all reported cases of BL transplantation have been confined to a cohort of mostly Dutch patients, all with extremely advanced disease (maximum kera-

tometry values >70 diopters), operated at a single facility, and using tissue prepared by a single eye bank (Amnitrans EyeBank Rotterdam).^{2,3} Here, we describe the results of what is, to our knowledge, the first BL transplantation performed in the United States, involving an American patient and surgeon, advanced (though not extreme) KC, and locally prepared tissue. Moreover, our patient's contralateral eye had previously been treated with ICRS, and we compare the effects of the two operations.

CASE REPORT

A 24 year old black male with a history of advanced, progressive KC was treated with BL transplantation in his left eye. His original diagnosis came five years previously. At the time, he appeared to have moderate disease (Amsler-Krumeich Stage 2) bilaterally. Rigid gas permeable contact lenses were prescribed, but secondary to intolerance in the right eye, symmetrical superior and inferior INTACs (Addition Technology, Inc., Sunnyvale, CA, USA) were placed. Three months postoperatively, in the right eye, best spectacle corrected visual acuity (BSCVA) had improved from 20/40 (0.5) to 20/25 (0.8), and the mean keratometry (Kmean) declined by almost 2.5 diopters (D) from 44.3 to 41.9D (although, the maximum keratometry (Kmax) actually increased from 53.2 to 56.0 D), measured by corneal topography (Carl Zeiss Meditec Atlas, Version 2.0.0.34, Germany).

Two years later, whereas the right eye appeared stable (Kmean 40.9D; Kmax 53.6D), the left eye seemed to be progressing: Kmean had increased from 43.6 to 45.2D, and Kmax from 47.0 to 53.0 D. Therefore, we recommended the left eye receive UVCXL. But because the procedure was not FDA approved in the United States, and because treatment would therefore require that he travel internationally, the patient declined and opted instead for a course of watchful waiting.

Eighteen months later, he returned for examination. Both corneas had progressed. Measured by Scheimpflug-based corneal tomography (Pentacam HR; Oculus, Wetzlar, Germany), the right eye only slightly (Kmean 42.2D; Kmax 52.1D). The left, however, more substantially (Kmean 45.5D; Kmax 57.1D). After six more months, further progression was evident: mild in the right eye (Kmean 43.1D; Kmax 52.9D) and severe in the left (Kmean 47.3D; Kmax 62.9D). Although the vision remained relatively good in both eyes (BSCVA of 20/40 in the right and 20/30 in the left), the relentless progression of disease - particularly in the left eye - prompted us to proceed with BL transplantation.

The graft was prepared as previously described (in the Alabama Eye Bank, one week before transplantation).⁴ From a whole globe obtained less than 36 hours post-mortem, a corneoscleral button was excised and stored in optisol until the time of preparation. At which time, it was removed from solution, mounted endothelial side down in an artificial anterior chamber (Moria, Antony, France), and the epithelium was removed.

Trypan blue (VisionBlue; DORC International) was dripped over the anterior surface, and the BL was lightly scored 360 degrees just inside the limbus using the tip of a 30-gauge needle. Then, it was gradually and delicately peeled free using McPherson forceps. Once separated, the BL spontaneously curled into a roll (Figure 1). It was rinsed in 70% ethanol to remove any lingering epithelial cells and stored in optisol until the time of transplantation.




Figure 1. Isolated Bowman Layer graft (green arrow) floating in a drop of balanced salt solution next to the isolated Descemet membrane (yellow arrow) from the same donor cornea.

The surgery itself likewise proceeded according to prior description: using a 15 degree blade and a crescent knife, a 5mm long partial thickness scleral incision was created, 2mm posterior to the limbus, then tunneled up into the peripheral clear cornea. The anterior chamber was filled with air and DALK spatulas (Melles spatula set; DORC International) were maneuvered into the tunnel and advanced through the cornea to dissect a pocket in the mid- stroma, stretching from limbus-to-limbus, 360 degrees around.^{5,6} A glide (BD Visitec Surgical Glide [Fichman]; Beaver-Visitec International, Waltham, MA) was inserted into the mouth of the tunnel, the BL roll was removed from optisol, dipped again in 70% ethanol, rinsed with balanced salt solution (BSS; Bausch & Lomb, Rochester, NY), stained with trypan blue, and placed on top. The donor tissue was then advanced along the glide and into the cornea by pushing with the tip of a 30-gauge cannula. Inside the pocket, the graft was unfolded with gentle strokes of the cannula and jets of

BSS (Figure 2). Postoperatively, dexamethasone 0.1%/tobramycin 0.3% (Tobradex; Alcon Laboratories) eye drops were applied four times daily for the first month and tapered by one drop per month thereafter.

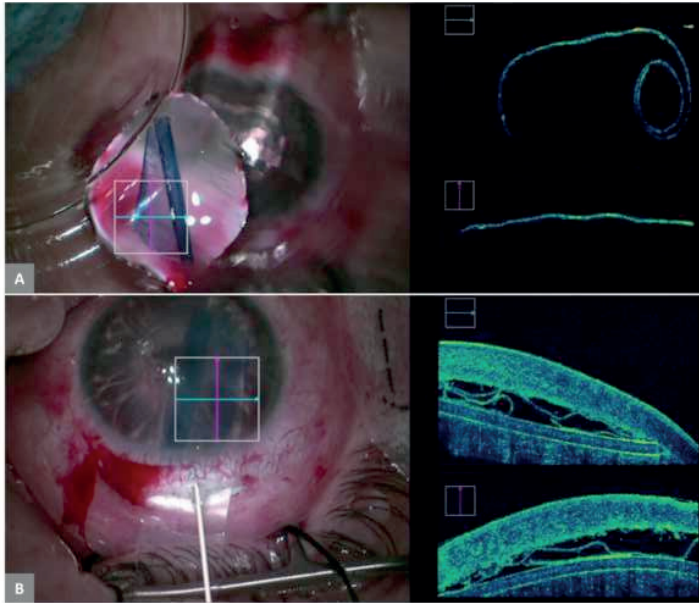


Figure 2. Bowman layer graft immediately before implantation, seen from above with the operating microscope and in profile using intra-operative optical coherence tomography (A). Subsequently, the graft is placed atop the surgical glide, pushed into the stromal pocket, and unfolded (B).

No intra- or postoperative complications were experienced. The day after surgery, a BSCVA of 20/40 was reached, where it remained stable at the one week, one month, and three month visits (preoperative 20/30). (At the three month visit, refraction with a rigid, gas-permeable contact lens (CTL) was also performed, resulting in a best CTL corrected visual acuity of 20/30). Likewise, by 3 months postoperatively, Kmean had declined by 1.2D (from 47.1 to 45.9D) and Kmax by nearly 5D (from 62.9 to 58.3D). Compared to their preoperative values, the central and thinnest point corneal thicknesses were hardly affected, changing from 465 μ m to 482 μ m and from 459 μ m to 464 μ m, respectively. Over this same time period, the average total corneal densitometry measurements (a unitless metric indicating the amount of light backscattered by the cornea) increased slightly, from 15.3 to 18.2. By Scheimpflug imaging and slit-lamp biomicroscopy, the edges of the graft have remained only barely visible as a thin line without any accompanying inflammation (Figure 3). Meanwhile, the cornea of the right eye has continued to show progression (Kmean 43.1D; Kmax 55.5D).

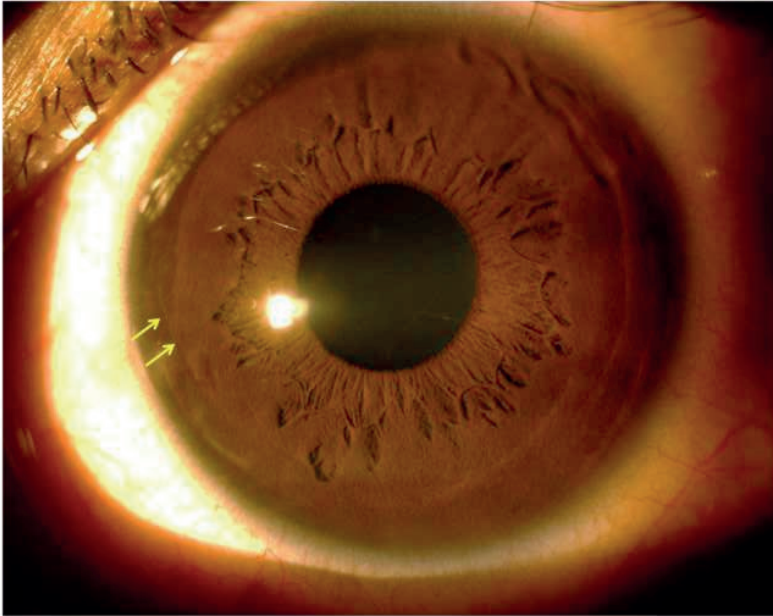


Figure 3. Postoperatively, the edges of the graft have remained faintly visible as a thin white line (yellow arrows) without any accompanying inflammation

DISCUSSION

Prior to BL transplantation, the vision in our patient's operated eye was relatively good, but his ectasia appeared to be rapidly progressing, necessitating some intervention. ICRS placement was not thought to be a viable option, considering the cornea's severe ectasia, and the underwhelming performance in the contralateral eye. Likewise, UVCXL was not regarded as practical, since our patient was unable to travel internationally to receive it. Therefore, our only recourse was to attempt BL transplantation.

Our case is noteworthy because it demonstrates that the prior Dutch results are replicable. That is, even with different surgeons, tissue preparations, and patients, the same basic outcomes are observed. Specifically: a substantial amount of corneal flattening, an interruption in the progression of ectasia, and no intra- or postoperative complications.

Furthermore, because our patient had much less advanced disease than those in the Dutch studies, our results suggest the procedure may also be feasible in eyes with less than "extreme" KC. If true, then this could be an important discovery, since many patients with mild to moderate KC are presently not eligible for either ICRS or UVCXL (especially in the United States) and therefore, have no alternative to prevent the eventual onset of late stage disease.

These advantages notwithstanding, our study may also confirm some of the potential limitations of BL transplantation. First, the procedure does not appear to much improve the recipient's Snellen acuity (although our patient did report a subjective increase in the quality of his vision, perhaps as a result of normalizing his ocular surface). Therefore, BL transplantation may not be ideal for patients with extremely poor vision. Second, much about the surgery remains unknown, including the operation's long term results. This applies, also, to our own case report, which only provides follow-up data through the first 3 postoperative months.

Our results corroborate earlier findings: that BL transplantation may be a useful means of arresting and reversing keratoconic ectasia. Undoubtedly, further investigation will be necessary, hopefully by a diversity of doctors in a variety of locales.

CONFLICT OF INTEREST

Dr Melles is a consultant for DORC International/ Dutch Ophthalmic USA and SurgiCube International. Dr. Dapena is consultant for DORC International. For the remaining authors none were declared.

REFERENCES

1. Parker JS, van Dijk K, Melles GR. Treatment options for advanced keratoconus: A review. *Surv Ophthalmol* 2015;60:459-480.
2. van Dijk K, Parker J, Tong CM, et al. Midstromal isolated Bowman layer graft for reduction of advanced keratoconus: a technique to postpone penetrating or deep anterior lamellar keratoplasty. *JAMA Ophthalmol* 2014;132:495-501.
3. van Dijk K, Liarakos V, Parker J, et al. Bowman layer transplantation to reduce and stabilize progressive, end stage, keratoconus. *Ophthalmology* 2015;122:909-917.
4. Lie J, Droutsas K, Ham L, et al. Isolated Bowman layer transplantation to manage persistent subepithelial haze after excimer laser surface ablation. *J Cataract Refract Surg* 2010;36:1036-1041.
5. Melles GR, Rietveld FJ, Beekhuis WH, et al. A technique to visualize corneal incision and lamellar dissection depth during surgery. *Cornea* 1999;18:80-86.
6. Melles GRJ, Lander F, Rietveld FJR, et al. A new surgical technique for deep, anterior lamellar keratoplasty. *Br J Ophthalmol* 1999;83:327-333.

