Universiteit Leiden
The Netherlands

Recent innovations in minimally invasive anterior and posterior lamellar keratoplasty

Parker, J.

Citation
Parker, J. (2017, July 4). *Recent innovations in minimally invasive anterior and posterior lamellar keratoplasty*. Retrieved from https://hdl.handle.net/1887/50484

Version:	Not Applicable (or Unknown)
License:	Licence agreement concerning inclusion of doctoral thesis in the Institutional Repository of the University of Leiden
Downloaded from:	https://hdl.handle.net/1887/50484

Note: To cite this publication please use the final published version (if applicable).

Cover Page

Universiteit Leiden

Leiden University Repository

The handle http://hdl.handle.net/1887/50484 holds various files of this Leiden University dissertation

Author: Parker, Jack
Title: Recent innovations in minimally invasive anterior and posterior lamellar keratoplasty
Issue Date: 2017-07-04

Chapter 3

Mid-stromal isolated Bowman layer graft to reduce advanced keratoconus to postpone penetrating or deep anterior lamellar keratoplasty

Korine van Dijk, BSc;[1,2] Jack Parker, MD;[1-3] C. Maya Tong, BSc;[1,4] Lisanne Ham, PhD;[1,2,4] Jessica T. Lie, PhD;[1,4] Esther A. Groeneveld-van Beek, MSc;[1,4] and Gerrit R.J. Melles, MD, PhD[1,2,4]

[1]Netherlands Institute for Innovative Ocular Surgery, Rotterdam, The Netherlands; [2]Melles Cornea Clinic Rotterdam, The Netherlands; [3]UAB Callahan Eye Hospital, Birmingham, Alabama; [4]Amnitrans EyeBank Rotterdam, The Netherlands.

ABSTRACT

We describe a new approach to reduce ectasia in eyes with advanced keratoconus in order to postpone penetrating keratoplasty or deep anterior lamellar keratoplasty, by mid-stromal implantation of an isolated Bowman layer graft.

The surgery was performed in 10 eyes of nine patients with progressive, advanced keratoconus and contact lens intolerance. All surgeries were uneventful. Throughout the study period, no complications related to stromal dissection and/or Bowman layer implantation were observed. Maximum corneal power decreased on average from 74.5D (±7.1D) before to 68.3D (±5.6D) after surgery (P=0.00). Hence, isolated Bowman layer implantation may be a safe and effective new technique to reduce ectasia in eyes with advanced KC, potentially allowing continued long term contact lens wear. The low risk of complications may render the procedure suitable as a treatment to postpone penetrating or deep anterior lamellar keratoplasty in cases with impending contact intolerance and/or corneal scarring.

Keratoconus (KC) is regarded as a non-inflammatory disorder characterized by progressive ectasia, associated with a compromised optical performance of the cornea.[1,2] Until recently, early KC stages were managed by hard contact lens fitting to obtain a regular anterior 'optical' surface, until contact lens intolerance in advanced stages required penetrating keratoplasty (PK) or deep anterior lamellar keratoplasty (DALK). Since 2003, UV-crosslinking became an alternative treatment option for keratoconic corneas of at least 400 microns in thickness and preoperative maximum keratometry of ≤58D,[3] with further developments on the way for thinner and steeper corneas.[4] Nevertheless, in more advanced KC cases, treatment options may eventually be limited to PK or DALK, the results of which may frequently be complicated in this patient group, by suture-related problems, epithelial wound healing abnormalities, and/or corneal curvature changes due to progression of KC in the peripheral host cornea, resulting in a cascade of secondary complications, and disappointing visual outcomes.[5-8]

Since fragmentation of Bowman layer is a pathognomic feature in advanced KC,[2,9] we hypothesized that a partial restoration of the corneal anatomy might be obtained through a mid-stromal implantation of an isolated Bowman layer graft, to re-model, ie flatten the corneal curvature. At the same time, stabilization of the ectasia may be obtained by the Bowman layer 'splint', as well as through the wound healing reaction between the host stroma and the Bowman layer graft.[10,11]

In this article, we describe a new surgical approach using mid-stromal implantation of a donor isolated Bowman layer, to reduce ectasia (K ≥70D) in eyes with advanced KC, to enable continued contact lens wear, while avoiding most short and long term complications.

KEYWORDS: Keratoconus, corneal crosslinking, deep anterior lamellar keratoplasty, progressive ectasia, Bowman layer, pachymetry, corneal transplantation, surgical technique

METHODS

Mid-stromal dissection with implantation of an isolated donor Bowman layer in the stromal pocket, was performed in ten eyes of nine patients (3 male and 6 female; 17 to 71 years of age) with (relative) contact lens intolerance due to progressive, end-stage KC, defined as mean K ≥58D and steepest K ≥70D (**Table 1**). In all eyes, an unsuccessful attempt was made to fit a scleral supported rigid contact lens. All patients signed an IRB approved informed consent; the study was conducted according to the Declaration of Helsinki and was registered at www.clinicaltrials.gov (study identifier NCT01686906).

Donor tissue

Donor corneas released for transplantation were mounted on an artificial anterior chamber (Katena, Rockmed, Oirschot, The Netherlands). Subsequently, the epithelial layer was carefully removed using surgical spears. Over 360 degrees a superficial incision was made using a 30-gauge needle in the clear part of the corneal periphery. With a custom-made stripper (DORC International, Zuidland, The Netherlands), the Bowman layer was carefully isolated from the anterior stroma, over the full 360 degrees towards the central part of the cornea. After complete detachment, subsequent trephination resulted in a 9.0 to 11.0 mm diameter Bowman-flap. Due to the elastic properties of the Bowman membrane, a 'Bowman-roll' formed spontaneously, which was submerged in ethanol 70% to remove all epithelial cells. After rinsing the roll with BSS, it was stored in modified minimum essential medium (CorneaMax, Eurobio, Cedex, France) at 31° C, until the time of transplantation (**Figure 1**).

Figure 1. Isolated Bowman layer graft (arrows) in organ culture medium. Note that the thin tissue layer has curled up into a 'Bowman-roll'.

Surgical technique

Manual dissection of a stromal pocket was performed using a technique previously described to create a lamellar dissection plane in deep anterior lamellar keratoplasty.[13,14] Under local anesthesia, a side port was made at the 3 or 9 o'clock limbus, to aspirate the aqueous using a blunt cannula, and to completely fill the anterior chamber with air. At the 12 o'clock limbus, the conjunctiva was opened and a superficial scleral frown incision was made, 5.0 mm in length, 1-2 mm outside the limbus. With a dissection spatula (Melles spatula set, DORC International), a lamellar dissection was made to just within the superior cornea. At this point, the tip of the blade was slightly tilted downward to visualize the interface between the air bubble in the anterior chamber and the corneal endothelium; underneath the corneal `dimple', the air-to-endothelium interface was seen as a specular light-reflex localized at the tip of the blade (**Figure 2**).[14] Between the blade tip and the light-reflex, a non-reflective, dark band was seen, representing the non-incised corneal tissue between the blade and the air-to-endothelium interface. Because the dark band became thinner with advancement of the blade into the deeper stromal layers, the corneal depth of the blade could be judged from the thickness of the dark band, to avoid perforation (**Figure 2**).[13,14]

After a stromal pocket was created up to the limbus over 360°, a glide (BD Visitec™ Surgical Glide (Fichman), Beaver-Visitec International, Waltham, USA) was inserted into the pocket, and the air was removed from the anterior chamber. The Bowman-roll was again immersed in 70% ethanol for 30 seconds to remove remnant cellular material, thoroughly rinsed with balanced salt solution (BSS; B&L, Rochester, USA), and stained with trypan blue (VisionBlue™, DORC International). Then, the Bowman-roll was carefully inserted into the stromal pocket, unfolded and centered, using BSS to manipulate the tissue (**Figure 2**). The eye was then pressurized by filling the anterior chamber with balanced salt solution. Postoperative medication included chloramphenicol 0.5% six times daily and dexamethason 0.1% four times daily.

All surgical procedures were recorded on DVD (Pioneer DVR-RT601H-S, Tokyo, Japan). At standardized time intervals, before surgery, and at 1 day, 1 week, and at 1, 3, 6, 12, 18 and 24 months after surgery, best spectacle corrected visual acuity (BSCVA) and best contact lens visual acuity (BCLVA) were measured, and slit-lamp biomicroscopy, Pentacam (Pentacam HR, Oculus, Wetzlar, Germany) and optical coherence tomography (OCT; Slit-lamp OCT, Heidelberg Engineering GmbH, Heidelberg, Germany) images were made. The endothelium was photographed and evaluated *in vivo* using a Topcon SP3000p non-contact autofocus specular microscope (Topcon Medical Europe, Capelle a/d IJssel, The Netherlands). Images were analyzed and manually corrected and multiple measurements of endothelial cell density were averaged.

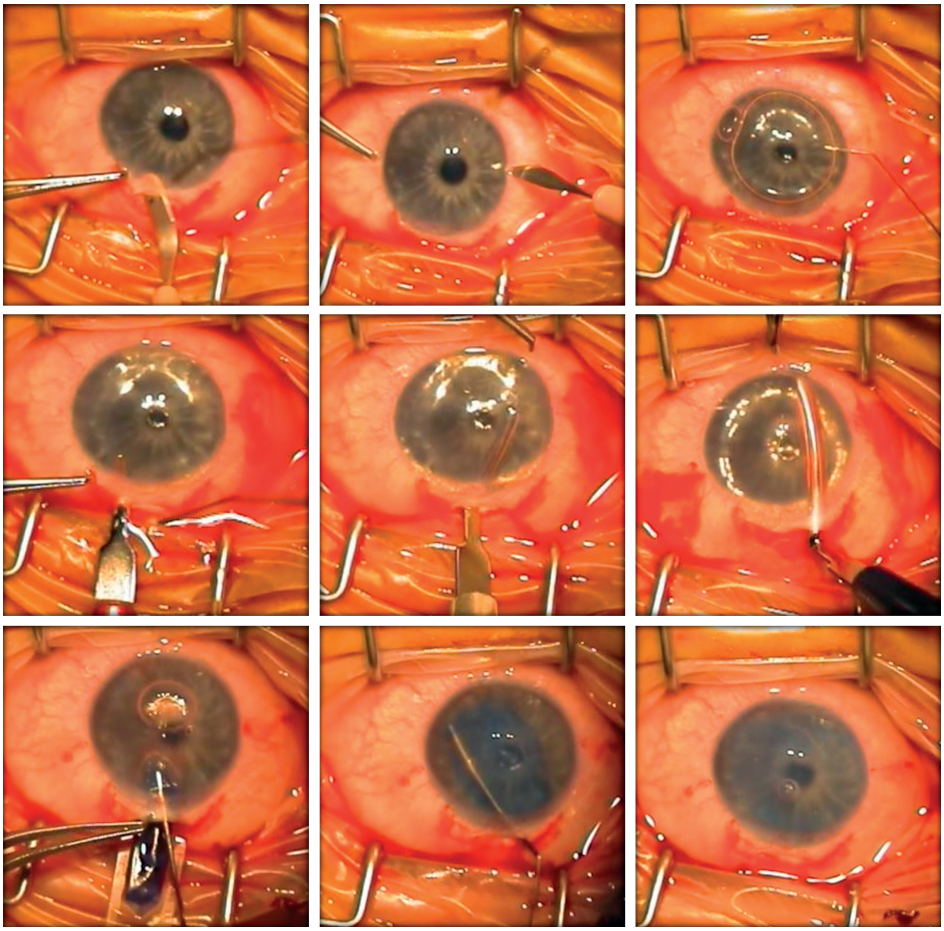

Figure 2. Intraoperative video-stills of an isolated Bowman layer implantation (Case 10). (A) After making a scleral tunnel incision, and (B) a side port, (C) the anterior chamber is filled with air, and (D-F) a mid-stromal dissection is made with spatulas. (F) Note the 'thin black line' alongside the spatula, as an indication for dissection depth. (G) After removal of the larger part of the air-bubble and the insertion a glide into the stromal pocket, a 'burrito-folded' Bowman layer graft is inserted into the pocket and (H) carefully unfolded and centered with an 30G air-cannula. (I) At the end of the surgery, the Bowman layer graft is sandwiched between the anterior and posterior stromal layers, and no sutures are required to fixate the graft of to close the tunnel incision.

RESULTS

All surgeries were uneventful, and throughout the study period no complications related to stromal dissection and/or Bowman layer implantation were observed. Because the donor Bowman layer was intentionally stretched toward the corneal limbus, an intrastromal cavity was seen in some eyes within the first days after surgery (**Figure 3**).

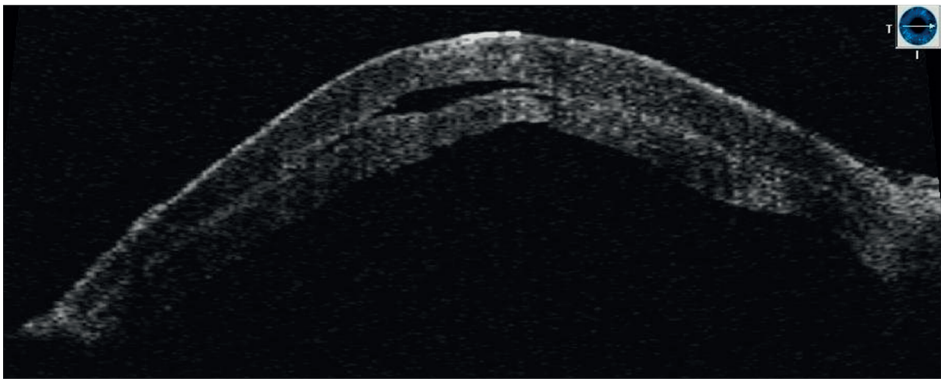

Figure 3. OCT image of a cornea immediately after isolated Bowman layer (arrows) implantation into the recipient corneal stroma. Note the intrastromal cavity directly above the implanted Bowman layer, owing to intraoperative stretching of the donor tissue towards the recipient corneal limbus, to obtain a maximum in flattening effect.

At longer time intervals, the implant could be visualized within the recipient corneal stroma, with biomicroscopy in all transplanted corneas (**Figure 4**).

Compared to preoperative measurements, all keratometry values decreased after surgery in all eyes: mean anterior sim K-values decreased from 65.9D (±5.4D) before surgery, to 59.5D (±4.6D) at 1 month (P=0.00); mean K-max values from 78.5D (±6.3D) to 69.9D (±3.8D) (P=0.00); mean posterior K-values from -10.2D (±0.8D) to -9.0D (±0.5D) (P=0.01); and mean maximum corneal power from 74.5D (±7.1D) to 67.2D (±3.0D) (P=0.00) (**Figure 5**; **Table 1**). From 1 to 12 months, the flattened curvature values remained stable (P>0.1) (**Table 1**).

Compared to preoperative measurements, central corneal thickness (CCT) increased from 396 (±42) mm to 417 (±37) µm and 423 (±38) µm at 6 months and at the most recent follow-up, respectively, and thinnest point thickness (TPT) changed from 334 (±61) µm to 360 (±31) µm and 363 (±49) µm at the six months and the most recent follow-up, respectively. None of the changes reached statistical significance (P>0.05).

Mean LogMar BSCVA and BCLVA showed no significant change from preoperative to six months postoperative (P=0.07 and P=0.77, respectively).

Before surgery, most of the eyes (Cases 1, 2, 3, 4, 6, 8 and 9) could only tolerate very limited contact lens wear for a few hours during the day (due to excessive corneal steepness with an impending "touch" between the cone and the contact lens). After surgery, however, all eyes could be fitted with a sclera-supported rigid contact lens ((R.Visser and Procornea rigid lens laboratory, Nijmegen, The Netherlands);[15] manufactured from Boston Equa 2 material with an oxygen permeability of 85×10^{-11} (cm^3O_2 cm)/(s·cm^2 mm Hg) at 35° C, ISO/Fatt method (Cases 1 and 6) or Boston XO with an oxygen permeability of 100×10^{-11} (cm^3O_2 cm)/(s·cm^2 mm Hg) at 35° C, ISO/Fatt method (Cases 2-5, and 7-10)

Table 1. Pre- and postoperative corneal curvature data

				Anterior K-values (D)					K max (D)					Posterior K-values (D)					Power Max (D)				
Case #	Age/ Gender	OD/OS	FU time (months)	Pre-op	1m	6m	Latest FU	Δ Pre-op to latest FU	Pre-op	1m	6m	Latest FU	Δ Pre-op to latest FU	Pre-op	1m	6m	Latest FU	Δ Pre-op to latest FU	Pre-op	1m	6m	Latest FU	Δ Pre-op to latest FU
1	37F	OS	24	62.8	59.4	59.4	58.4	-4.4	73.2	66.2	67.5	69.8	-3.4	-11.2	-8.3	-8.6	-9.8	1.4	65.9	64.7	65.8	62.7	-3.2
2	22F	OS	24	64.0	61.5	56.9	57.0	-7.0	72.7	67.9	67.9	69.8	-2.9	-9.5	-9.1	-8.1	-8.3	1.2	71.2	65.9	69.5	69.7	-1.5
3	71F	OS	18	61.7	n.a.	60.2	60.5	-1.2	70.3	n.a.	70.2	71.0	0.7	-9.9	n.a.	-9.9	-10.1	-0.2	64.7	n.a.	64.8	65.4	0.7
4	17F	OD	18	62.8	60.4	60.1	59.6	-3.2	77.8	77.9	73.8	69.4	-8.4	-9.6	-9.5	-9.7	-9.3	0.3	72.5	72.9	69.3	64.6	-7.9
5	25M	OD	18	75.4	66.0	69.1	69.4	-6.0	84.7	71.2	73.7	73.8	-10.9	-11.4	-9.6	-10.2	-10.1	1.3	81	68.8	72.5	72.8	-8.2
6	27M	OD	12	67.0	60.5	60.8	62.4	-4.6	76.2	65.3	66.9	68.6	-7.6	-11.1	-9	-9.8	-9.7	1.4	71.3	63.4	63.6	65.5	-5.8
7	29F	OD	12	61.9	57.1	56.6	55.3	-6.6	80.1	68.3	68.3	68.6	-11.5	-9.2	-8.8	-8.9	-9.3	-0.1	75.1	64.8	64.1	64.4	-10.7
8	20F	OS	12	74.1	61.1	64.6	69.0	-5.1	92	72.3	78.3	83.7	-8.3	-10.9	-8.9	-9.7	-9.9	1.0	86.9	70	75.1	81.0	-5.9
9	30M	OD	12	69.3	60.1	64.2	65.0	-4.3	77.8	68.6	73.1	73.7	-4.1	-10.3	-9.6	-9.9	-9.7	0.6	82.6	65.9	70.1	71.8	-10.8
10	29F	OS	12	59.6	49.0	55.8	53.6	-6.0	79.8	71.4	67.6	67.5	-12.3	-9.3	-8.4	-8.5	-8.4	0.9	73.7	68.3	63.5	65.0	-8.7
Average			16	65.9	59.5	60.8	61.0	-4.8	78.5	69.9	70.7	71.6	-6.9	-10.2	-9	-9.3	-9.5	0.8	74.5	67.2	67.8	68.3	-6.2
SD			(±5)	(±5.4)	(±4.6)	(±4.2)	(±5.4)	(±1.7)	(±6.3)	(±3.8)	(±3.8)	(±4.7)	(±4.3)	(±0.8)	(±0.5)	(±0.7)	(±0.7)	(±0.6)	(±7.1)	(±3.0)	(±4.1)	(±5.6)	(±3.9)
P-value (pre-op to FU)					**0.00**	**0.00**	**0.00**			**0.00**	**0.00**	**0.00**			**0.00**	**0.00**	**0.00**			**0.00**	**0.00**	**0.00**	
P-value (1m to latest FU)							0.25					0.37					0.15					0.47	

Yellow = Post-operative values changed <5% from pre-operative values
Green = Post-operative values improved (≥5% decrease from pre-operative values)
SD = Standard deviation
FU = Follow-up
'Bold' = Significant change

from the Polymer Technology Corporation, Bausch & Lomb), which was tolerated well during full daily wear.

Mean endothelial cell density showed no significant change from preoperative (2571 (±497) cells/mm^2) to 12 months postoperative (2552 (±263) cells/mm^2) (P= 0.31).

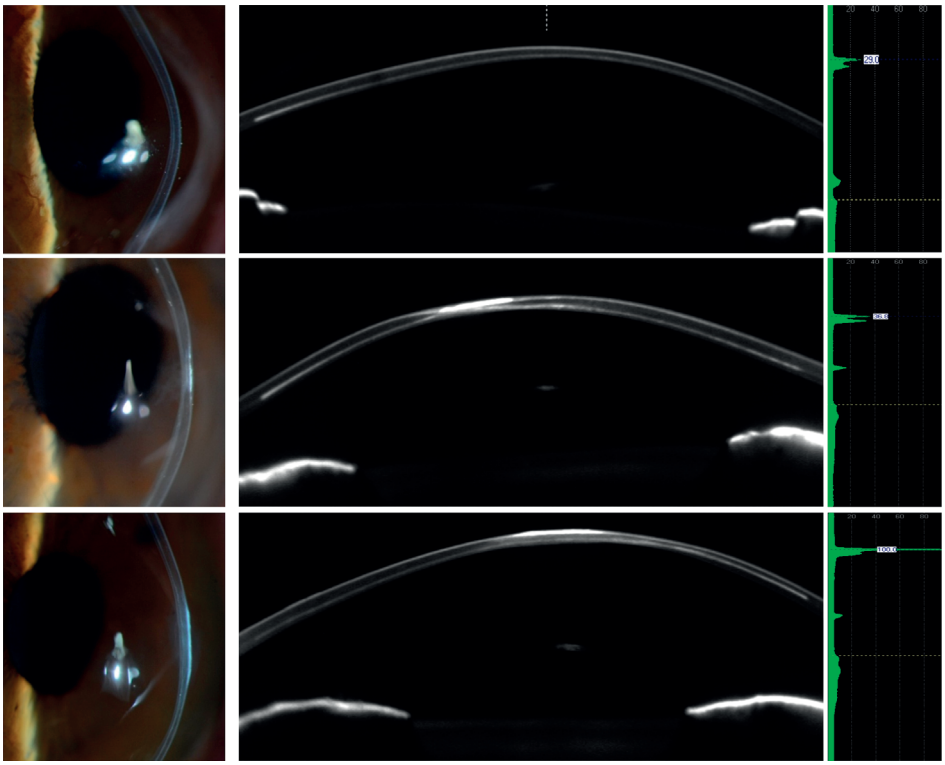

Figure 4. Slit-lamp and Scheimpflug images of three eyes (Cases 4, 6, and 9) at 9-12 months after isolated Bowman layer implantation. (A-F) The Bowman layer transplant (white arrows) is visible within the recipient stroma, without any interface haze or stromal reaction. Note the different types of pre-existing superficial scarring and surface irregularity (yellow arrow).

DISCUSSION

In the past years, the preferred treatment method for progressive KC may have shifted from contact lens fitting for as long as tolerated followed by PK or DALK, to UV-cross-linking in order to stabilize corneal ectasia for the long term.[2,3] Although techniques are being developed to treat thinner or steeper corneas as well,[4] corneas thinner than 400 µm or steeper than 58D may be less eligible for UV-crosslinking, whereas this group of patients would similarly benefit from stabilizing the cone, to enable continued contact lens wear. In fact, particularly in advanced KC cases managed by PK or DALK,

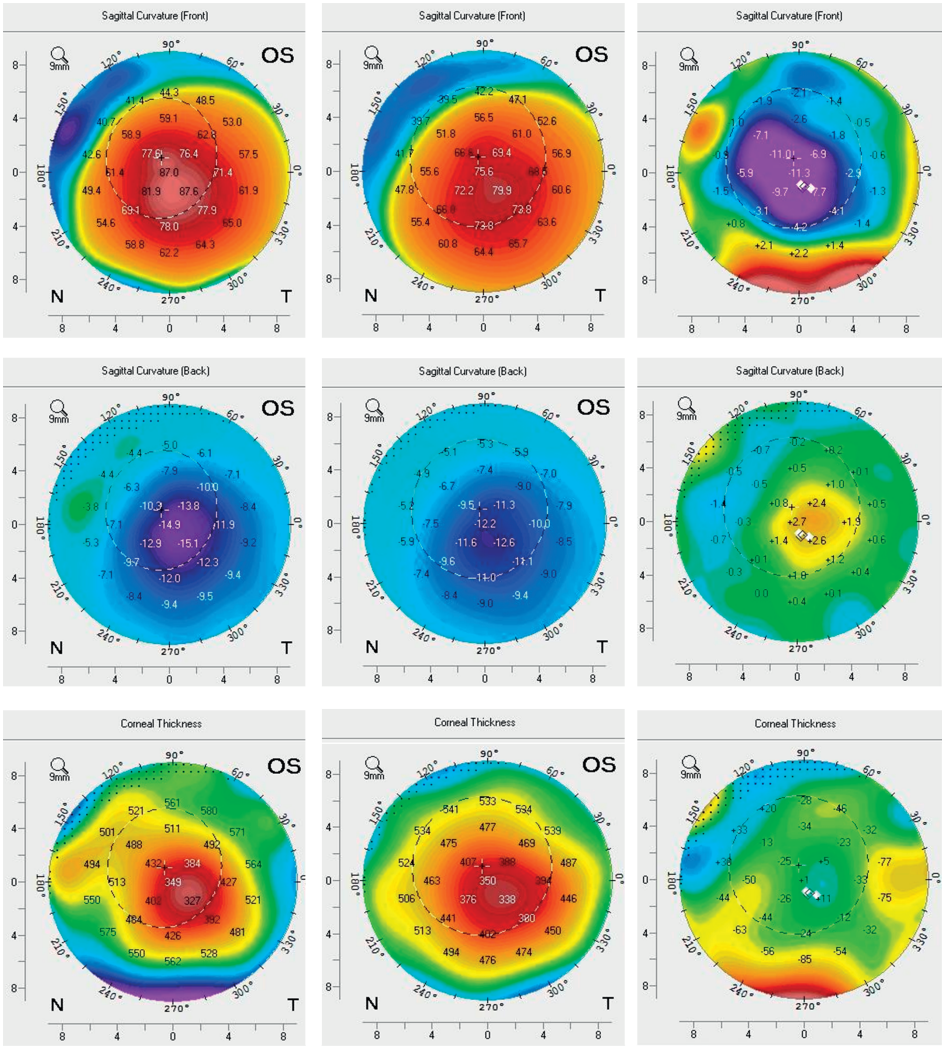

Figure 5. Topography and pachymetry maps of a cornea (Case 8) before and at 12 months after isolated Bowman layer implantation. Note that (A and B) the anterior and posterior keratometric values show significant corneal flattening, while (C) the pachymetry remains unchanged.

the long term clinical outcome of these procedures may frequently be complicated by a sequence of side-effects and complications, through which the final visual outcome may eventually be reduced.[5-8,16-8]Clinical observation suggests that especially eyes with advanced KC are prone to show various 'inflammatory' reactions after surgery, possibly relating to a stronger atopic constitution,[1,2,19,20] rendering any keratoplasty procedure to a 'high-risk' procedure due to the risk of long term complications.

Therefore, our aim was to design a surgical procedure that would solve most of the clinical challenges in advanced KC. Because fragmentation of the recipient's own Bowman layer is one of the pathognomic features in pathology sections of KC corneas,[2,9] it should theoretically be effective to manage KC with an isolated Bowman layer transplant to restore its shape and tensile strength. If the donor Bowman layer would be positioned inside the recipient cornea, the implant would be sandwiched between the stromal layers above and below, and no anterior corneal incisions or fixation means would be necessary. When fixed in this position, the donor Bowman layer would 'pull' the anterior corneal surface flatter, creating a more homogeneous surface topography and possibly long term corneal stability, through better tensile strength of the donor tissue. At the same time, and unlike corneal ring segments,[21] a donor Bowman layer may show similar rigidity as the surrounding recipient corneal stroma, so that the risk of interface reaction and/or migration of the implant may be negligible.

Our surgical approach of positioning an isolated donor Bowman layer in a recipient mid-stromal pocket, proved effective in all cases. The maximum corneal power showed on average a 6 to 7D reduction, which was found to remain stable up to at least one year. Although pachymetry measurements did not show a significant difference, flattening of the cone was clearly associated with stromal compression with biomicroscopy, ie a reduction of the overall arc length. Hence, important parameters used in grading a KC cornea showed improvement, indicating that the procedure may have potential for KC cases ineligible for UV-crosslinking **(Figure 6)**.[22]

An important finding was the complete absence of intra- and/or postoperative complications. None of the eyes showed any ocular surface problems or pressure elevations, while the risk of allograft rejection may be eliminated since no cellular material is transplanted. Therefore, the complete lack of commonly seen complications after PK or DALK indicates that isolated Bowman layer implantation may have important benefits over these procedures. Although the aim of the procedure is not visual improvement, mid-stromal isolated Bowman layer transplantation may allow patients to continue wearing contact lenses in the long term, with a minimal risk of complications, since both the anterior and posterior corneal surfaces are left intact. Hence, mid-stromal Bowman layer transplantation could become an alternative treatment option in the management of advanced KC, to postpone PK or DALK.

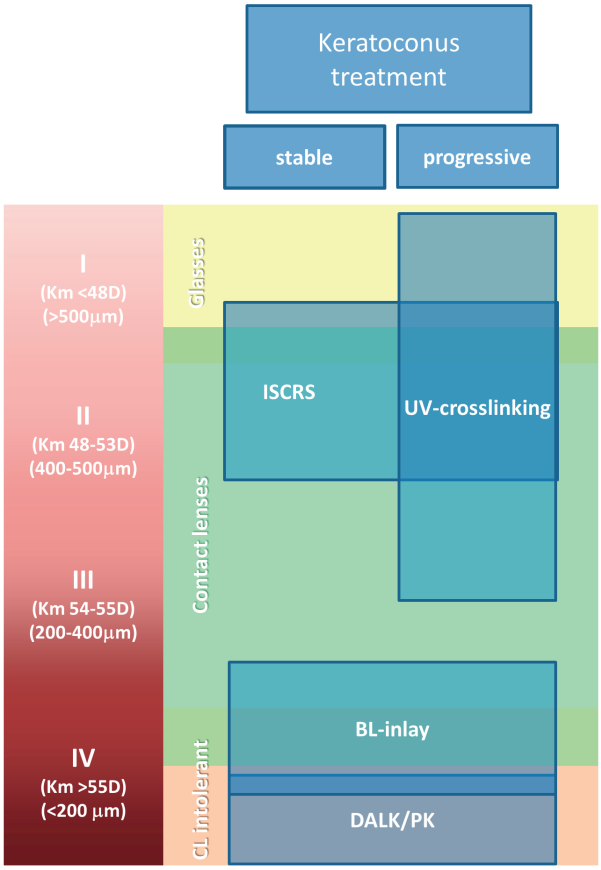

Figure 6. Diagram displaying the different treatment options in the various stages of keratoconus (classification according to Krumeich).

ACKNOWLEDGEMENTS/DISCLOSURE

Conflicts of Interest

GRJ Melles is a consultant for D.O.R.C. International/ Dutch Ophthalmic USA. All other authors (KvD, JP, CMT, LH, JTL, EAGvB) have no conflict of interest to disclose.

Data access and responsibility

GRJ Melles had full access to all data in the study and takes responsibility for the integrity of the data and the accuracy of the data analysis.

Funding

No funding source to disclose.

REFERENCES

1. Rabinowitz YS. Keratoconus. ***Surv Ophthalmol***. 1998;42(4):297-319.
2. Romero-Jiménez M, Santodomingo-Rubido J, Wolffsohn JS. Keratoconus: a review. ***Cont Lens Anterior Eye***. 2010;33(4):157-66.
3. Wollensak G, Spoerl E, Seiler T. Riboflavin/ultraviolet-a-induced collagen crosslinking for the treatment of keratoconus. ***Am J Ophthalmol***. 2003;135(5):620-627.
4. Raiskup F, Spoerl E. Corneal cross-linking with hypo-osmolar riboflavin solution in thin keratoconic corneas. ***Am J Ophthalmol***. 2011;152(1):28–32.
5. Williams KA, Muehlberg SM, Lewis RF, Coster DJ. How successful is corneal transplantation? A report from the Australian Corneal Graft Register. ***Eye***. 1995;9(2):219-227.
6. De Toledo JA, de la Paz MF, Barraquer RI, Barraquer J. Long-term progression of astigmatism after penetrating keratoplasty for keratoconus: evidence of late recurrence. ***Cornea***. 2003;22(4): 317-323.
7. Elder MJ, Stack RR. Globe rupture following penetrating keratoplasty. How often, why, and what can we do to prevent it? ***Cornea***. 2004;23(8):776–780.
8. Nagra PK, Hammersmith KM, Rapuano CJ, Laibson PR, Cohen EJ. Wound dehiscence after penetrating keratoplasty. ***Cornea***. 2006;25(2):132–135.
9. Ambekar R, Toussaint Jr. KC, Johnson AW. The effect of keratoconus on the structural, mechanical, and optical properties of the cornea. ***J Mech Behav Biomed Mater***. 2011;4(3):223-236.
10. Melles GRJ, Binder PS.A comparison of wound healing in sutured and unsutured corneal wounds. ***Arch Ophthalmol***. 1990;108(10):1460-1469.
11. Melles GRJ, Binder PS, Anderson JA. Variation in healing throughout the depth of long-term, unsutured, corneal wounds in human autopsy specimens and monkeys. ***Arch Ophthalmol.*** 1994; 112(1):100–109.
12. Lie JT, Droutsas K, Ham L, et al. Isolated Bowman layer transplantation to manage persistent subepithelial haze after excimer laser surface ablation. ***J Cataract Refract Surg***. 2010;36(6):1036-1041.
13. Melles GRJ, Lander F, Rietveld FJR, Remeijer L, Houdijn Beekhuis R, Binder PS. A new surgical technique for deep stromal, anterior lamellar keratoplasty. ***Br J Ophthalmol***. 1999;83(3):327-333.
14. Melles GRJ, Rietveld FJR, Beekhuis WH, Binder PS: A technique to visualize corneal incision and lamellar dissection depth during surgery. ***Cornea***. 1999;18(1):80-86.
15. Visser E-S, Visser R, van Lier HJJ, Otten HM. Modern scleral lenses part I: clinical features. ***Eye Contact Lens***. 2007;33(1):13–20.
16. Williams KA, Lowe MT, Bartlett CM, Kelly L, Coster DJ. **The Australian Corneal Graft Registry. 2007 report**. Adelaide, Flinders University Press, 2007.
17. Watson SL, Ramsay A, Dart JKG, Bunce C, Craig E. Comparison of deep lamellar keratoplasty and penetrating keratoplasty in patients with keratoconus. ***Ophthalmology.*** 2004;111(9):1676–1682.
18. Jonas JB, Rank RM, Budde WM. Immunologic graft reactions after allogenic penetrating keratoplasty. ***Am J Ophthalmol***. 2002;133(4):437–443.
19. Kok YO, Tan GFL, Loon SC. Review: Keratoconus in Asia. ***Cornea***. 2012;31(5):581-593.
20. Yildiz EH, Erdurmus M, Hammersmith KM, Rapuano CJ, Laibson PR, Cohen EJ. Comparative study of graft rejection in keratoconus patients with and without self-reported atopy. ***Cornea.*** 2009; 28(8):846-850.

21. Coskunseven E, Kymionis GD, Tsiklis NS, et al. Complications of intrastromal corneal ring segment implantation using a femtosecond laser for channel creation: a survey of 850 eyes with keratoconus. ***Acta Ophthalmol***. 2011;89(1):54-57.
22. Sinjab MM. **Quick guide to the management of keratoconus: A systematic step-by-step approach.** New York, Heidelberg, Springer, 2012.