



Universiteit
Leiden
The Netherlands

Recent innovations in minimally invasive anterior and posterior lamellar keratoplasty

Parker, J.

Citation

Parker, J. (2017, July 4). *Recent innovations in minimally invasive anterior and posterior lamellar keratoplasty*. Retrieved from <https://hdl.handle.net/1887/50484>

Version: Not Applicable (or Unknown)

License: [Licence agreement concerning inclusion of doctoral thesis in the Institutional Repository of the University of Leiden](#)

Downloaded from: <https://hdl.handle.net/1887/50484>

Note: To cite this publication please use the final published version (if applicable).

Cover Page



Universiteit Leiden



The handle <http://hdl.handle.net/1887/50484> holds various files of this Leiden University dissertation

Author: Parker, Jack

Title: Recent innovations in minimally invasive anterior and posterior lamellar keratoplasty

Issue Date: 2017-07-04

Chapter 2

Treatment Options for Advanced Keratoconus: A Review

Jack S. Parker¹⁻³, Korine van Dijk¹⁻², Gerrit Melles^{1-2,4}

¹Netherlands Institute for Innovative Ocular Surgery, Rotterdam, The Netherlands; ²Melles Cornea Clinic Rotterdam, The Netherlands; ³UAB Callahan Eye Hospital, Birmingham, Alabama; ⁴Amnitrans EyeBank Rotterdam, The Netherlands.

ABSTRACT

Traditionally, the mainstay of treatment for advanced keratoconus (KC) has been either penetrating or deep anterior lamellar keratoplasty (PK or DALK, respectively). The success of both operations, however, has been somewhat tempered by a well-known litany of potential difficulties and complications, both intra- and postoperatively. These include suture and wound healing problems, progression of disease in the recipient rim, allograft reaction, and persistent irregular astigmatism. Taken together, these constitute a formidable array and have been the inspiration for an ongoing search for less troublesome therapeutic alternatives. To that end, a handful of alternative techniques have been tried against severely ectatic corneas with variable degrees of success. These include ultra-violet cross-linking (UV-CXL) and intracorneal ring segments (ICRS), both which were originally constrained in their indication exclusively to eyes with mild to moderate disease. More recently, Bowman Layer (BL) Transplantation has been introduced for reversing corneal ectasia in eyes with advanced KC, re-enabling comfortable contact lens wear and permitting PK and DALK to be postponed or avoided entirely. This article offers a summary of the current and emerging treatment options for advanced KC, aiming to provide the thoughtful corneal specialist useful information in selecting the optimal therapy for his individual patients.

KEYWORDS: Advanced keratoconus, Bowman layer transplantation, UV cross-linking, DALK, intracorneal ring segments, review

I. INTRODUCTION

Though the precise definition of “advanced” KC remains somewhat unsettled in the ophthalmic community, most specialists would agree that the disease has assumed a fairly late stage when spectacle correction is insufficient, continued contact lens (CL) wear is intolerable, and visual acuity has fallen to unacceptable levels. The traditional recourse at this point has been to reluctantly proceed with either a PK or DALK. While visual acuity not infrequently improves – at least initially – this commonly comes at a cost. Namely, the obligation to manage a litany of potential complications including allograft reaction, suture and wound healing problems, progression of the disease in the recipient rim, and persistent irregular astigmatism. None of these may be regarded as insignificant, and together, they are the reason why transplantation has traditionally been reserved as a last resort for desperate eyes. To combat these issues, a number of innovations have been introduced at the level of surgical technique, instrumentation, and tissue preparation. Moreover, there has been a strong push, as of late, to extend some of the technologies originally devised to treat early to intermediate stage KC and to apply them to cases of advanced disease. Specifically, UV-CXL and ICRS have been evaluated for this purpose, with some demonstrated success. Still, many severely diseased corneas remain unsuitable candidates for either of these two new techniques and are therefore typically relegated to the usual transplantation tactics. Recently, however, Bowman Layer (BL) Transplantation has been introduced as an alternative to PK/ DALK in eyes with advanced KC, unsuitable for either UV-CXL or ICRS. By supplying a physical splint to mechanically bolster the cornea, ectasia may be stabilized and reduced, re-enabling comfortable CL wear and sparing the patient a more drastic transplantation operation with all its potential complications. This article offers a summary of the current and emerging treatment options for advanced KC: their indications and contraindications, expected outcomes and limitations. We conclude with a few remarks about what we have observed in applying these treatments and what they may allow us to speculate about future therapeutic options.

II. TERMINOLOGY AND STAGING

Typically, KC is described as a bilateral, non-inflammatory condition of ongoing corneal ectasia.^{190,275} That consensus definition notwithstanding, considerable controversy exists regarding how best to grade disease severity. While the Amsler-Krumiech scale is still the most widely used for that purpose, two obstacles stand in the way of its universal acceptance. First, it is increasingly being viewed as antiquated or outdated, since it relies on relatively “old” indices (corneal steepness, refractive change, the presence of scar-

ring) whereas newer grading schemes employ a variety of detailed metrics of corneal structure provided by anterior segment optical coherence tomography (AS-OCT) and Pentacam imaging.^{1,156,170,233} Second, Amsler-Krumeich grades do not always correlate well with disease impact. Not uncommonly, eyes with “low” scores (indicating milder disease) may develop CL intolerance resulting in poor functional vision and significant disability. On the other hand, some eyes with “high” scores (indicating severe disease) may nevertheless remain CL tolerant, and thereby continue to enjoy relatively good functional vision with few complaints.²⁸⁶ These two factors combined – first, the growing number of alternate, competing grading schemes; and second, the Amsler-Krumeich’s uncertain ability to predict the actual burden of disease – have made objective scoring of disease severity (especially moderate versus advanced) a controversial matter.

For practical purposes, however, the term “advanced” KC may properly apply to any case with unacceptably poor spectacle distance vision and contact lens intolerance. It describes, then, a category of “surgical eyes”, regardless of their measured corneal parameters. The advantages of this conventional definition are, primarily, that it is reasonable and useful. It does not depend on any specialized imaging device, nor does it require that any particular grading scheme be endorsed. And, with the discussion narrowed to “eyes having failed non-operative management,” the relative advantages and disadvantages of the various surgical options may come to the front of the conversation, facilitating direct comparison.

III. OPERATIONS AND THEIR INDICATIONS

For most of the surgical history of the disease, advanced KC has been treated with PK. Increasingly, however, DALK is becoming the preferred surgical option (largely thanks to improvements in operative technique), now representing 10-20% of all transplants for KC and 30% when eyes with previous hydrops are excluded.^{36,280,350} Meanwhile, UV-CXL and ICRS have likewise seen their roles expanded: whereas both were once regarded as suitable only for mild to moderate cases, there is now growing support for their use in advanced disease as well.^{62,235,268,273} Finally, in 2014, BL transplantation was introduced for advanced KC with extreme thinning / steepening.³³⁹

These five operations (PK, DALK, UV-CXL, ICRS, and BL transplantation) currently represent the available treatment options for advanced KC. Although, historically, other procedures have been tried, most have enjoyed only short runs of popularity. Examples include epikeratophakia and conductive keratoplasty, neither of which is currently regarded as effective in the long term, particularly when compared to the above five alternatives.^{30,172,257,316}

A. Special Considerations:

1. Corneal Thickness

Corneal thickness (or more accurately, corneal thinness) rarely poses an insuperable problem in the performance of a successful PK for advanced KC. An exception exists for eyes with significant peripheral thinning: if an oversized graft is required, complications including allograft reaction and glaucoma become more likely.^{202,315} In these eyes, DALK or a modified procedure (“Tuck-in lamellar keratoplasty” to be described later) may be preferred.

For DALK, thin corneas pose a separate difficulty. Because corneal thinning is associated with concomitant Descemet membrane (DM) weakness and fragility, severely affected eyes carry an elevated risk for perforation. This is especially true if the operation is performed using the Anwar “Big-bubble” technique which may result in inadvertent DM “blowout” with bubble expansion.²³⁹ Therefore, in cases of severe thinning, the preferred technique for DALK may be Melles manual dissection in which the overlying stroma is carefully cut free (instead of pneumatically separated) from the underlying DM, using an air bubble in the anterior chamber as a reference plane to judge depth of dissection.

The debate is robust over the suitability of UV-CXL in thin corneas. The original studies proscribed application in eyes with central corneal thicknesses (CCTs) less than 400 μ m due to known risks of endothelial damage.^{131,352,353} Even in corneas well above this thickness threshold however, there are a number of well documented reports of endothelial failure after treatment.^{26,123,139,298,341} Nevertheless, recently there has been a push to expand the use of UV-CXL into eyes with very thin corneas (<400 μ m) by way of a variety of ingenious modifications to the originally described (Dresden) protocol. Broadly, these consist of attempts to artificially or temporarily thicken the cornea before treatment. To this end, some practitioners leave the epithelium-on (rather than debriding it) to confer extra thickness.^{88,115,178,219,287,314} The primary objection to this tactic is that it may substantially reduce the procedure’s effectiveness.^{56,174,184} A more common solution is to substitute a hypotonic riboflavin solution for the usual isotonic one, thereby swelling the cornea just prior to UV irradiation.^{142,278} The success of such a strategy is somewhat difficult to evaluate owing to the large heterogeneity in protocols in published reports used to achieve this end.^{15,123,341} Moreover, the vast majority of such studies concern corneas just barely thinner than the recommended floor-value of 400 μ m, with relatively few including cases of severe thinning (<350 μ m). The totality of evidence seems to suggest that with the currently popular thickening regimes, pre-operative treatment with hypotonic riboflavin results in a significant increase in central corneal thickness (CCT), but a much smaller increase in thinnest point thickness (TPT).²⁹¹ In addition, the process of crosslinking itself – the actual application of energy – may result in an intraoperative thinning, exposing the endothelium to a higher level of radiation

despite “adequate” pre-procedural thickness (especially if an eye speculum is used for a prolonged period during the procedure, which tends to promote stromal dehydration and thinning).^{153,175,198,229,291,308} There are also theoretical objections that in transiently hydrating the cornea, the density and proximity of collagen fibers are reduced, thereby lowering the potential efficacy of their crosslinking.^{3,143,246} For all of these reasons, there is currently little to recommend UV-CXL in corneas thinner than 400µm.

Although ICRS themselves come in a variety of designs, all require a minimum corneal thickness at the site of their insertion and along the length of their path of 400µm.³⁴² Therefore, eyes with severe thinning are often ineligible. Even when eligible, those with TPTs <400µm seem to experience worse visual outcomes and more complications; especially if the area of greatest thinning is situated inferiorly, a location which tends to promote the creation of unintentionally shallow segment channels. The shallower a segment is placed, the greater the likelihood of subsequent ocular surface problems including epithelial breakdown, infectious keratitis, and subsequent extrusion because the mechanical stress of the ring segment is borne by a thinner layer of overlying stroma.^{200,300,363}

Especially thin corneas do not seem to pose any special difficulty in the performance of BL transplantation, except to make manual stromal dissection a slightly more difficult prospect by raising the chances of inadvertent DM perforation, just as with a Melles manual DALK procedure.

2. *Maximal Corneal Steepness*

Preoperative corneal steepness is not currently believed to be an independent risk factor for poor performance after PK. There is evidence, however, that eyes with advanced KC and central curvatures >60 diopters (D) may regularly experience worse outcomes after DALK owing to the high incidence of DM folds developing over the visual axis after surgery.²⁴¹ These appear to arise from size mismatch between donor and recipient tissues: the stretched recipient DM is invariably of a greater surface area than the posterior surface of the donor in direct proportion to the pre-op degree of corneal ectasia. When the two tissues are placed in apposition, necessarily, DM folds must develop and these tend to undermine the optical performance of the eye (though these folds may spontaneously resolve, usually one year after surgery. Additionally, it may be possible to displace these folds into the corneal periphery, out of the visual axis, by slight modification of the operative technique).³⁰¹

Steeper corneas are more likely to undergo flattening after UV-CXL (although, only rarely does the magnitude of this flattening exceed 2D).^{135,305,326,351} However, there may be an elevated risk of failure – that is, continued progression – in corneas steeper than 58D (particularly if the cone is eccentrically located) and an increased risk of losing vision

after the procedure with a steepness >55D, possibly because the topographic outcomes may be more variable and less predictable.^{21,134,157,187,192}

Traditionally, the use of ICRS has been constrained to eyes with maximum Ks <58D, since values much exceeding these are associated with poorer visual outcomes and more complications including segment migration, extrusion, and stromal melting. Although newer segments designs have mitigated some of these issues, still, use in corneas steeper than 58D is often discouraged.^{6,8,210}

BL transplantation was devised specifically for use in steep corneas. In 2014, van Dijk et al. published the results of BL transplantation in eyes with max K values >70D, finding that – in 90% of eyes – disease progression was successfully arrested.^{338,339}

3. *Preoperative best corrected Visual Acuity*

For patients with extremely poor vision – even with a contact lens in place – either PK or DALK may be preferred, since rarely do the visual gains of UV-CXL, ICRS, or BL transplantation exceed one or two lines. Rather, the primary purposes of these latter operations are 1) to arrest disease progression; and 2) to restore or support contact lens tolerance by making wear more comfortable.

4. *Endothelial Health*

It is not completely unusual for KC to be found alongside co-existing endothelial dysfunction. Fuchs Endothelial Dystrophy (FED) is the most common of such accompanying disorders but also represented are posterior polymorphous dystrophy (PPMD) and a peculiar condition of endothelial depletion and guttae excrescences that may be the product of the KC itself rather than distinct entity.^{97,201,317} The actual prevalence of such “dual-disorders” may be underestimated, since the stromal thinning of KC may mask the corneal edema that would otherwise signify an endothelial decompensation and because stromal irregularities may interfere with confocal microscopy and thereby obstruct the diagnosis of endothelial depopulation.²³⁴

For advanced KC and a failed endothelium, PK is obviously preferred. But in eyes with merely the suggestion of endothelial disease or an endothelial dystrophy not highly advanced, a relatively non-invasive procedure such as ICRS or BL transplantation may be chosen, since neither operation appears to significantly affect recipient endothelial cell density.^{24,210,285,339} To a lesser extent, DALK may be a viable option as well, as the best data suggests an early, modest decline in endothelial cell density (ECD) followed by a relatively quick return to normal, physiologic rates of cell loss thereafter.^{288,302,340} (However, intra-operative perforation – DALK’s most common complication – does appear to result in substantially lowered cell counts.^{90,204}) If any of these alternatives to PK were selected, and then later endothelial decompensation occurred, a secondary Descemet stripping

(automated) endothelial keratoplasty (DS(A)EK) or Descemet Membrane Endothelial Keratoplasty (DMEK) may be prudent.

5. *Lens Status*

Because advanced KC tends to manifest early in life, many of those treated are phakic. Owing to a greater post-operative steroid requirement, keratoconic eyes undergoing PK are significantly more likely to develop cataracts requiring extraction than are eyes receiving DALK.^{33,92,93,217,223} Specifically, Zhang et al found that ten years after PK, 19.2% of eyes operated for advanced KC developed a cataract requiring phacoemulsification compared to 0% following DALK.³⁶⁴ Therefore – and because none of ICRS, UV-CXL, or BL transplantation promote cataractogenesis – PK may be the least desirable option for phakic eyes.^{344,268} This is especially true given that cataract extraction: 1) increases the risk of allograft reaction after PK, and 2) threatens severe pressure spikes in young, myopic eyes.^{63,250}

6. *Patient Age and Ability to Cooperate*

A patient's age and ability to cooperate with examination, medication, and follow-up requirements may critically determine an operation's outcome. These are particularly relevant concerns for the treatment of KC which disproportionately manifests in childhood or adolescence and in patients with co-existing cognitive impairment (e.g. Down, Tourette, Costello, Williams-Beuren, and other syndromes) or personality defects such as hypomania and paranoia.^{83,127,137,167,222,224,269}

i. Age

Although the onset of KC is typically around puberty, it is not totally uncommon to arise earlier and may be responsible for a small percentage of worldwide amblyopia, as the development of visual function often proceeds until a child is eight to eleven years old. In general, the younger the patient at the time of diagnosis, the more severe the condition and the greater its chances for progression. Consequently, many children present with already very advanced disease.^{70,94,140,209,260} Until recently, the usual treatment for these eyes has been PK, with advanced KC now the second most common indication for pediatric corneal transplant behind only congenital corneal opacity.²⁰⁹

Adolescents (age 13-19) operated with PK for advanced KC have long term visual results and levels of graft survival that approximate those of adults.²¹⁵ For children (age 5-12), outcomes are slightly worse, principally attributable to higher rates of graft failure (approaching 30% at 15 years.)²³¹ Intra-operatively, PK may be more challenging in children and adolescents. Their smaller, more hyperopic eyes conduce to shallower anterior chambers, scleral "crimping," and forward displacement of the lens-iris diaphragm during surgery. These eyes are also more likely to have narrow or under-developed iridocorneal

angles, predisposing to the formation of peripheral anterior synechiae and elevated intraocular pressures. Both of these latter occurrences are strong risk factors for graft rejection besides also threatening the eye with the separate problem of glaucoma.^{120,214}

Little has been written about DALK in the eyes of children and adolescents, although the available literature suggests results that parallel the adult population.^{51,52,86,145}

UV-CXL is still a new therapy in many parts of the world, and consequently there are few studies regarding its use in children. From the available data, pediatric UV-CXL seems to confer a modest corneal flattening effect and a mild visual benefit without any additional complications.^{25,55,219,309,310,345} Compared to adults, however, these gains may be smaller and less durable.^{54,64,171}

In the United States, ICRS are not approved for patients younger than 21. Worldwide, use has generally been constrained to individuals older than 18. As a result, little is known about their suitability in pediatric cases. Although, one comparative report does exist, analyzing the efficacy of ICRS for three different age groups: patients 13-19 years old, 20-35 years old, and >35 years old. Ultimately, no difference in visual outcome or corneal topography was found.¹⁰⁵

For BL transplantation no data currently exists for children. Still, for very young patients, BL transplantation may eventually be regarded as one of the safest options: as a largely "extra-ocular" procedure, most of the intraoperative challenges of PK in pediatric eyes are avoided. Moreover, because the postoperative burden is lower (related to the absence of corneal sutures and the extreme improbability of graft rejection), suboptimal patient cooperation may be less consequential.³³⁹

ii. Mental Disability

Patients with mental retardation are well known to have worse outcomes following PK for advanced KC, mostly as a result of a higher incidence of postoperative complications. In particular, there are more occurrences of globe rupture, corneal ulceration, and graft rejection, especially in patients with greater amounts of cognitive disability.^{35,121,186,232,297,354} In part, this is thought to stem from a stronger tendency toward both eye rubbing and ocular self-trauma. Volker- Dieben et al report a 67% five-year survival rate for penetrating grafts in eyes of patients with Down Syndrome, substantially less than the >90% survival rate in "normal" populations.³⁴⁶

DALK may be preferred over PK in these patients, since the eye is not as structurally weakened by the surgery and because faster healing may permit earlier suture removal, reducing the risk of infection.^{76,148}

Surprisingly, all reports of UV-CXL in patients with Down Syndrome are negative (although, it is possible that this represents something of a "publication bias" with the good results going unpublished). These include one patient with severe corneal melting requiring bilateral PKs;¹⁰⁹ another developed an intractable corneal ulcer. (In this lat-

ter case, resolution required admission to the intensive care unit, inducing an artificial coma, supplying mechanical ventilation for weeks, and two separate tarsorrhaphies.)¹⁸⁸ Extrapolating from these examples, the authors conclude that only patients capable of reliable cooperation, with good family support, are acceptable candidates for UV-CXL.

There are no reports of the use of ICRS or BL transplantation in patients with Down Syndrome or other forms of mental disability. Both operations impose fewer postoperative requirements than PK, DALK, or UV-CXL, however and therefore may be less “risky.” The caveat, however, is that most of the postoperative problems of ICRS stem from migration / superficialization of the ring segments themselves. These events occur more frequently if the patient continues to rub the operated eye after surgery.^{71,80,169} And because patients with cognitive impairment tend to display more eye rubbing postoperatively, some caution may be exercised before ICRS placement.

7. *Pre-existing Corneal Scarring*

With advanced KC, corneal scars may arise from previous hydrops and therefore, a section of DM is often incorporated into the area of fibrosis. Surprisingly however, eyes with prior hydrops do not demonstrate lower ECDs compared to those without.¹² As a result, endothelial replacement (with PK) should not be considered mandatory for these patients. This is especially true given that – in eyes with prior hydrops – PK outcomes tend to be worse, principally because the risk of graft rejection is much higher.^{29,220} This extra risk arises because: 1) Corresponding to the size of the original area of hydrops and its proximity to the limbus, corneal neovascularization often develops,^{227,284} and 2) Eyes with hydrops are more likely to have allergic or other ocular surface disease, resulting in more inflammation and more eye rubbing.⁵

For these reasons, DALK – with its lower risk of allograft reaction – may be preferred. However, the Anwar Big Bubble technique is contraindicated for these patients, owing to the large risk of perforation secondary to the patient’s underlying, weakened DM.^{106,158} Therefore, these surgeries could proceed by other maneuvers such as Melles manual dissection.^{17,66,86,251,279}

The effect of hydrops on UV-CXL for advanced KC has not been evaluated. Although, in a study of UV-CXL for pseudophakic bullous keratopathy (PBK), significantly less cross-linking effect was found when stromal scars were present. Therefore (speculatively), the procedure may be less successful given prior hydrops.³⁹ Moreover, UV-CXL would not be expected to reduce the opacity of the scars themselves so their presence in the visual axis may be a relative contraindication.

Likewise, central scarring is generally believed to contraindicate the use of ICRS, as the devices are not believed efficacious as refractive instruments in the presence of a significant central opacity. BL transplantation experiences the same limitation. However – provided that the scarring is only “light” and not severely visually disabling – both

ICRS and BL transplantation may be worthwhile to arrest disease progression and permit continued CL wear (**Figure 1**).^{42,339}

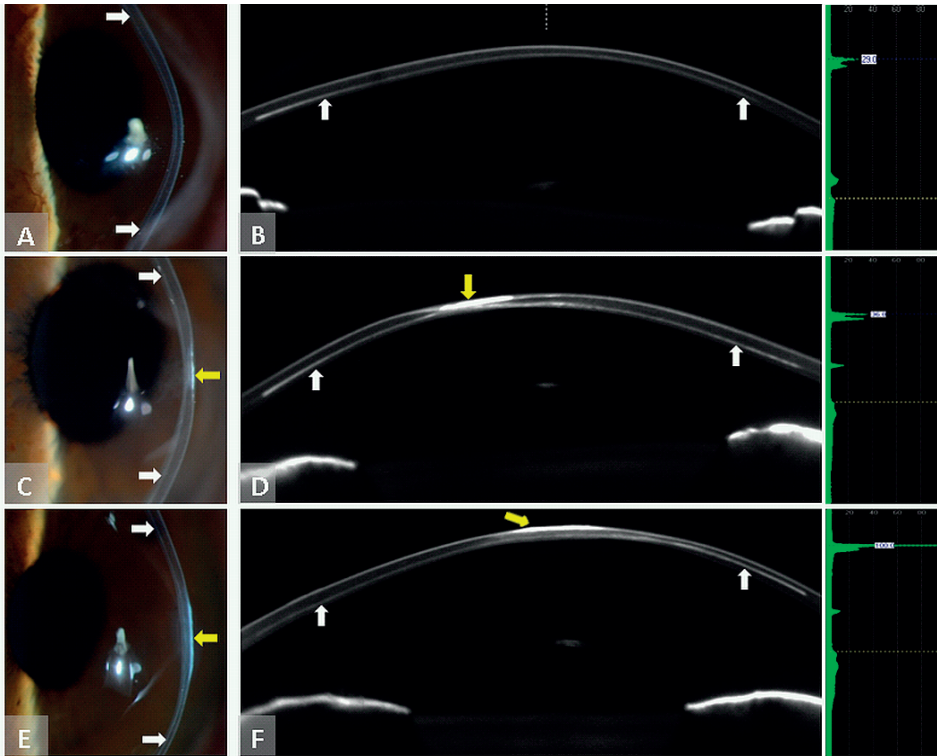


Figure 1. The Bowman layer graft (white arrowheads) is visible within the recipient stroma (though perhaps positioned somewhat deeper than the intended 50% stromal depth), without any interface haze or stromal reaction. Different types of preexisting superficial scarring and surface irregularity (yellow arrowheads) are visible (**A-F**). *Reprinted with permission from JAMA Ophthalmology*

8. International Availability

In the US, UV-CXL is not yet FDA approved for the treatment of KC. And while clinical trials are ongoing, generally these are limited to patients with mild to moderate disease only, leaving those with advanced KC ineligible.

Globally, ICRS are available in numerous designs. In the US, however, the only approved variant is INTACS, which come in “R” and “SK” subtypes. “R” (regular) segments have a large internal diameter (6.7mm), a hexagonal cross-sectional shape, and thicknesses from 0.25mm to 0.5mm in 0.05mm increments. Meanwhile, the “SK” (steep keratometry) segments – designed specifically for advanced KC – have a smaller internal diameter (6.0mm), an oval cross-sectional shape, and a narrower range of thicknesses (0.21mm,

0.40mm, 0.45mm, and 0.50mm). Outside of the US, other types of ICRS are available which include Ferrara rings, Kerarings, the Myoring, and Bisanti Segments.^{101,235}

Aside from the Amnitrans Eye Bank in Rotterdam, there are no commercial eye banks currently preparing BL transplantation tissue for transplant. As a result, surgeons may need to either import the tissue from abroad or prepare it themselves using previously described techniques.³³⁹

IV. SURGICAL TECHNIQUES

A. PK

The biggest recent advance in PK has been the introduction of the femtosecond laser to trephine the recipient and donor tissues, theoretically providing better apposition and faster healing. Suturing techniques and graft sizing practices vary, with results to be discussed later.

B. DALK

Most currently practiced DALK techniques exist as variations or modifications of two basic strategies: the Anwar big-bubble and the Melles manual dissection. The big-bubble method is rooted in Anwar's 1998 discovery that an intrastromal injection of balanced salt solution (BSS) was often effective at establishing a cleavage plane just above DM.¹³ In 2003, he refined the technique to use air instead of BSS and the "big bubble" procedure was born.¹⁹ (Viscoelastic may also be used for this purpose, an observation made independently in 2000.)²³⁶ In contrast, Melles manual dissection is a bit more meticulous. First, the anterior chamber is filled with air. Then, using a series of curved spatulas, the anterior stroma is carefully dissected away from the underlying DM. The precise depth of dissection can be determined by using the "air-endothelium interface:" when the anterior chamber is full of air, a reflected image of the tip of the dissecting spatula appears. The distance of this reflection from the actual spatula itself represents the depth of the ongoing dissection, such that the deeper the dissection is carried out, the closer the reflection appears to the tip of the instrument. Guided in this way, a controlled dissection down to the level of DM is possible (**Figure 2**).^{237,238}

The literature is replete with amendments to both "core" surgical techniques. These include: staining the stroma with Trypan blue to facilitate viewing;²⁸ Parthasarathy et al.'s "small bubble" technique for confirming the presence of the big bubble;²⁶² employing ultrasound pachymetry to guide big-bubble creation;¹²⁵ suture style modifications;^{2,216} and using a diamond knife / nylon wire / microkeratome / excimer or femtosecond laser for lamellar dissection.^{34,113,165,311,312,337,362} For corneas with extreme peripheral thinning, a modified procedure has been proposed dubbed TILK (Tuck-in lamellar keratoplasty)

in which the recipient peripheral corneal rim is undermined and the edges of a large anterior lamellar graft are “tucked in” below to add extra thickness.^{173,336}

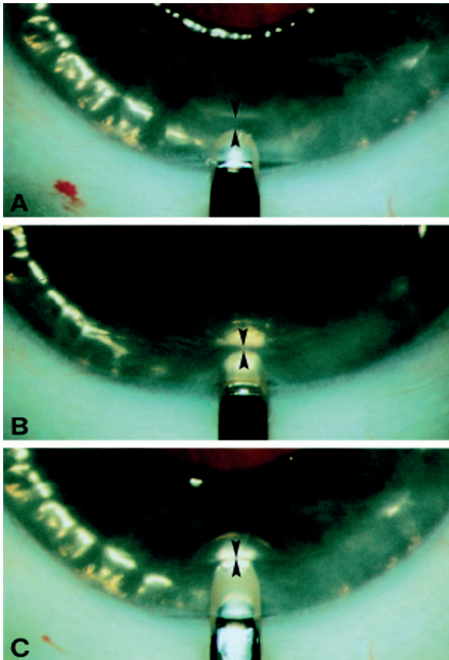


Figure 2. Demonstration of the Melle's manual DALK surgical technique in a human eye bank eye. **(A)** The anterior chamber has been filled with air. In between the blade tip and the air to endothelial interface light reflex, a dark band (arrowheads) is visible. **(B)** Because the dark band reflects unincised posterior corneal tissue, the dark band decreases in width when the blade is advanced into the deeper stromal layers. **(C)** When the blade appears to touch the air to endothelium interface, a stromal dissection level just anterior to the posterior corneal surface is reached. *Reprinted with permission from British Journal of Ophthalmology*

C. UV-CXL

The original UV-CXL procedure – dubbed the “Dresden Protocol” – entailed debriding the cornea entirely of its epithelium, then dripping a riboflavin solution onto the anterior stroma. Subsequent application of UV light generates free radicals which “cross-link” adjacent collagen molecules and stiffen the cornea against further ectasia.³⁵² Since the Dresden protocol was introduced, several alternatives have emerged. These include “accelerated” crosslinking (in which the intensity of energy is increased, in exchange for reduced exposure time),³²⁵ “epi-on” techniques,^{56,105,115,184,219,287,310,314} and the “Athens Protocol” which combines accelerated UV-CXL with same-day photorefractive keratectomy.¹⁶⁸ With the possible exception of “epi-on” crosslinking (which may be less effective, as previously discussed) none of these modified techniques have yet distinguished themselves as clearly more effective than any other, in terms of topographic or visual results.

D. ICRS

ICRS are segments of PMMA plastic available in numerous arc-lengths, thicknesses, and designs. The devices themselves are inserted into stromal tunnels which may be fash-

ioned manually using a handheld corkscrew blade or automatically using a femtosecond laser with no difference in results (except that channels tend to be slightly shallower when created manually, and more often decentered when created by laser).^{79,102,174} For greater effect, two hemi-spherical segments may be placed instead of one. These segments may be implanted “symmetrically” if the keratoconic cone is located centrally, or “asymmetrically” if the cone is decentered, as is typical.²³⁵ With asymmetrical placement, a thicker segment is implanted in the axis of greatest steepening, and a thinner segment is inserted 180 degrees away. Because keratoconic steepening tends to be located in the inferior cornea, the practical recommendation is to place the thicker segment inferiorly and the thinner superiorly.^{9,61} To a large extent, the depth at which the segments lie determines their effect: Maximal flattening occurs with segments at 60-79% corneal thickness. Shallower than 60%, the effect may be lessened and the likelihood of a variety of ocular surface complications increased. Deeper than 80%, there may be no topographic effect at all.¹⁴⁷ Compared to the surgeon’s own depth estimates, most segments lie much more superficially (up to 25%), judged by AS-OCT.^{200,249}

A significant advantage of ICRS is the procedure’s reversibility. Following explantation, the rings may be re-inserted again at a later time, or alternatively PK or DALK may be tried.^{7,116,324,328} Before re-operating, it is necessary to wait at least three months after segment removal for the cornea to revert back to its original shape.⁷⁵

Increasingly, there are reports of combining ICRS with UV-CXL. The sequencing is critical: to achieve maximal flattening, ICRS should be implanted before or simultaneously with UV-CXL. To do the opposite (UV-CXL, then later ICRS) limits the flattening effect of the segments since the cornea has been already “fixed” into a sub-optimal configuration.^{74,78,98,205}

E. BL Transplantation

The most sensitive and specific indicator of KC is the fragmentation of Bowman layer – an insult that critically destabilizes the surrounding cornea, predisposing it to ongoing ectasia.¹ In 2014, van Dijk et al introduced the idea an isolated Bowman Layer “inlay” for eyes with advanced KC. Delivered into a manually dissected mid-stromal pocket, the graft was intended to (partially) restore the corneal anatomy, stabilize the corneal structure, flatten the surface, and arrest progression.³³⁹ Since van Dijk et al’s original report in 2014 (featuring the outcomes of the first 10 operated eyes) a larger study has been published, describing the surgical results of the first 22 cases, with a mean follow up time of 21 ± 7 months. It is from these two studies that the bulk of the data about BL transplantation derives.

The graft is prepared by manually peeling the BL from the anterior stroma of a donor corneo-scleral rim. The process begins by securing a corneo-scleral button atop an artificial anterior chamber, debriding the epithelium using surgical spears, then drip-

ping trypan blue over the anterior corneal surface. After lightly scoring a circular area, 9.0-11.0mm in diameter with a 30G needle, McPherson forceps are used to delicately peel the BL away from the underlying stroma using small circular movements. Because the layer is acellular, it is physically robust and amenable to gentle handling despite being only 10-15µm thick. Once detachment is complete, a “Bowman roll” forms spontaneously, owing to the inherent elastic properties of the tissue itself. The graft is then submerged in 70% ethanol to remove any lingering epithelial cells, rinsed with BSS, and then stored in organ culture before transplantation.^{211,339}

The initial stages of the operation resemble Melles manual DALK: after creating a side port at either the 3 or 9-o’clock position, the anterior chamber is filled with air. A 5mm frown-shaped scleral incision is fashioned at 12-o’clock, 1-2mm outside the limbus, and tunneled just inside the clear cornea. Lamellar dissection then follows, using the same set of curved spatulas employed in the Melles manual DALK technique. Again, the air-endothelium interface is used to judge depth in the stroma, except – for BL transplantation – the intended depth is 50%, rather than the 99% DALK aims for. The reason for this discrepancy is that BL transplantation is commonly performed in extremely thin corneas, and – by aiming at a mid-stromal dissection – the chances of inadvertent anterior or posterior corneal perforation may be minimized. Once completed, this manual mid-stromal dissection results in a stromal “pocket” extending from limbus-to-limbus, 360 degrees, within the cornea. Air is then removed from the anterior chamber, a surgical glide is inserted into the mouth of the scleral tunnel, and the Bowman layer graft (rinsed with BSS and stained with Trypan blue) is placed on top. A blunt cannula is used to gently push the graft along the glide, through the scleral tunnel, and into the stromal pocket. Once in place, the tissue is unfolded by a combination of rinsing with BSS and light cannula touches. After unfolding, the anterior chamber is re-pressurized with BSS.³³⁹

Although the operation is positioned as an alternative to DALK, it retains some of the latter’s salient features. Namely, the status of a technically “extra-ocular” surgery (as the eye is never completely entered), and tissue economy, because the corneal tissue left over from creating the inlay may be re-used for endothelial (DSEK or DMEK) grafts.³³⁹

V. VISUAL OUTCOMES

A. PK

After PK for advanced KC, final uncorrected visual acuity (UCVA) ranges from 20/50 to 20/100, with just over 40% of patients reading 20/40.^{65,50,117,129,161,162,319} Spectacle correction gives better results with a mean acuity (BSCVA) of 20/30-20/40.^{27,45,59,65,164} These gains may recede over time, however, due to mounting irregular astigmatism in the graft that spectacles cannot correct. On this point, Praminik et al found that 15

years after PK for advanced KC, although 66% of eyes retained a BSCVA $\geq 20/40$, 18.9% had fallen to $<20/200$.²⁷¹ For some patients (5-60%), CLs may be required postoperatively.^{44,124,212,272,294,304,307,319,331,348} Compared to glasses alone, CLs usually confer an extra 1-2 lines with a mean acuity (BCVA) of 20/25 one year postoperatively and with 67-96% of patients seeing at least 20/40.^{11,44,50,67,129,161,182,212,256,272,294,304,319} However, because vision doesn't "stabilize" until at least 12 months after surgery, a primary limitation to PK's visual results is the delay in achieving them.^{43,44,162,183,319}

No study has shown that the style or pattern of graft suturing influences ultimate BCVA.¹⁶¹ The effect of graft sizing is controversial but probably modest with various studies reporting slightly better (or worse) results with oversized vs. same-sized grafts.^{67,129,150,304} The type of mechanical trephine used has also not been shown to influence ultimate BCVA, although, the use of a femtosecond laser for cutting the recipient and donor tissue may slightly speed-up visual rehabilitation by permitting earlier suture removal.^{27,45,59,122,161}

B. DALK

DALK, properly performed, probably provides equivalent visual results to PK. The totality of evidence shows that, provided stromal dissection reaches the level of DM, all visual outcomes (UCVA, BSCVA, BCVA, and percent requiring contact lenses) are the same.^{117,119,144,161,166,182,306} In studies where the visual results of DALK are inferior to PK, usually, this discrepancy is attributed to an incomplete stromal dissection such that DM is not fully bared. In these "pre-descemetic" DALKs, visual performance tends to be worse overall. The problem seems to be related to the *depth* of the un-dissected stromal bed, not its "regularity" or "smoothness," since pre-descemetic DALKs performed by laser ablation do not outperform those performed by manual dissection.^{20,48} Large DM perforations sustained intra-operatively lower the chances of excellent visual results.^{90,204} Compared to PK, visual rehabilitation may be somewhat quicker, owing to the possibility of earlier suture removal.²⁷ Post-operative contrast sensitivity is equal for the two surgeries, although there are conflicting reports as to which yields fewer higher order aberrations.^{4,161,185,225,289}

C. UV-CXL

For most patients treated with UV-CXL, visual acuity either remains unchanged or improves mildly, by 1-2 lines.^{56,134,135,326} Eyes with pre-procedural BCVAs $<20/40$ are significantly more likely to achieve substantial flattening with UV-CXL, and correspondingly, greater visual improvements.^{135,326} The steeper the cornea, however, the more variable the response to treatment and the greater the likelihood of vision loss.^{22,136,192,355} In the sole dedicated study of UV-CXL on corneas steeper than 58D, Sloot et al found no benefit in UCVA or BCVA at one year postoperatively, although a slight trend toward the latter.³⁰⁵

D. ICRS

Similarly, ICRS confer a modest visual benefit: on average, 1-2 lines of BSCVA and BCVA^{10,57,72,197,199,210,259,283} In particular, for Amsler-Krumeich Stage III or IV eyes, most studies show no (or markedly reduced) gains, along with more disappointed patients and elective explantation.^{6,8,32,103,169,180,300,330,343,363} The relevant study with the longest follow-up was performed by Torquetti et al, which tracked the outcomes of ICRS placement in keratoconic eyes through ten years. On average, eyes gained one line of UCVA and two lines of BCVA. Ten percent, however, lost at least one line of UCVA, and 20% lost at least one line of BCVA. All eyes losing vision were Amsler-Krumeich Stage III or IV.³²⁹

Whereas newer segment designs such as INTACS SK and the Kerarings may be better than previous versions in flattening corneas with severe ectasia, the visual gains still rarely exceed 1-2 lines. Moreover, these alternate models have been associated with an increased amount of visual aberrations, owing to the small diameter of the segments, bringing them into closer proximity to the visual axis.^{126,141,159,189,195,196,290,296,303}

Visual rehabilitation is typically completed within three to six months after surgery, but may require up to one year. Pairing the procedure with UV-CXL may enhance the flattening effect, or make it more durable, but has not been shown to improve visual results.^{53,96}

E. BL Transplantation

Following BL transplantation, BSCVA typically improves by 1-2 lines, although BCVA usually remains unchanged. The primary visual benefits, then, of BL transplantation may be: 1) to enable more comfortable CL wear by flattening the cornea into a more tolerable configuration; and 2) to permit continued CL wear into the future, by halting disease progression.^{338,339}

VI. REFRACTIVE OUTCOMES

The bulk of the myopia in keratoconic eyes arises – not from the cornea – but from the axial length of the eye, which is significantly larger than in normal individuals. Therefore, regardless of the planned corneal intervention, some amount of myopia is likely to remain.³³² The amount of postoperative myopia tends to be slightly greater following DALK than PK because the resultant cornea tends to be slightly steeper. Otherwise, however, the refractive outcomes are the same.^{14,37,181}

Following PK, large amounts of astigmatism are common; the average amount is 3-5D, but may exceed 10D, and as a consequence, approximately 20% of patients may require refractive surgery post-operatively for their best visual results.^{60,164,183,212} No known preoperative features of the recipient cornea predict the likely amount of postoperative

astigmatism, nor is there an association with age, gender, the type of trephine used, or the size of the graft.²¹² Per several studies by Krumeich et al, postoperative astigmatism may be reduced in eyes with advanced KC by – at the time of surgery – suturing into place a permanent steel alloy “intrastromal corneal ring” which may protect the graft from tractional distortion during subsequent healing.^{193,194} For most conventional suturing styles there is also no astigmatic difference, although, Busin et al have shown that – at least in the short term – a possible benefit may apply to a double running, 16-point technique.^{47,108} Suture removal tends to result in large unpredictable swings in the amount of astigmatism present regardless of the type of suture employed and even when many years have passed since the original surgery.^{46,87,218,248,361} Once all sutures have been removed, however, the measured astigmatism tends to remain relatively stable. In most cases however this stability is only a temporary condition. Eventually, progressive donor-recipient misalignment or recurrence of the original disease results in late rising levels of astigmatism.^{203,213,255,276} De Toledo et al found that this transition – from a period of refractive stability to one of gradual worsening – began approximately ten years after first suture removal.⁸⁹

Typically, UV-CXL yields only a modest reduction in astigmatism, almost always less than 0.5D.^{21,69} While often a “step in the right direction,” the overall effect is succinctly expressed by Pinero et al: “crosslinking is able to induce a corneal astigmatic change, but it is variable, not predictable, and insufficient to provide an effective astigmatic correction.”²⁶⁷

In contrast, ICRS provide a sizable, reduction in corneal astigmatism ranging from 1-3D, regardless of the type of segment employed or the Amsler-Krumeich stage of disease, although the greater the preoperative amount of astigmatism, the less predictable the corrective result of the ICRS may be. The full refractive effect is generally not seen before one year postoperatively (with significant changes occurring between six and twelve months) but thereafter appears stable, at least through ten years of follow-up.^{6,114,266,329,330}

The refractive impact of BL transplantation has not yet been fully elucidated. All available evidence, however, suggests a slight hyperopic shift (consistent with corneal flattening) with no significant effect on corneal astigmatism.^{338,339}

VII. TOPOGRAPHIC OUTCOMES

After PK, the primary determinant of corneal curvature is the size disparity between the graft and the recipient.⁹⁵ When the donor button is oversized by 0.5mm, the mean K usually settles around 45.5D. When the button is same-sized, that value is nearer to 42.5D. The presence of corneal neovascularization, however, skews these figures in unpredictable ways owing to the frequent onset of distortionary scarring postop-

eratively.^{41,59,60,95,150,161,212} While suture placement (the style and material) is unrelated to ultimate corneal curvature, removal can have dramatic (usually homogenizing) effects. In oversized grafts, the effect is a slight steepening of the cornea. For same-sized grafts, however, suture removal may instead produce a small amount of overall flattening.^{87,226,293,332} Regardless of graft size, the donor and recipient tissues tend to become progressively misaligned at the interface over time, grossly evident in >50% of eyes 20 years postoperatively.^{37,164}

As previously mentioned, following DALK, corneas are routinely 2D steeper than if they had received a similarly-sized PK. This disparity may be the product of some degree of intraoperative anterior chamber collapse (and subsequent scarring) seen with PK that DALK avoids.^{14,37,181}

The primary topographical result of UV-CXL is an “evening out” of corneal parameters and a decline in overall surface variability.³²⁷ The probability (although, not the magnitude) of this effect relates to the degree of pre-procedural ectasia, such that eyes with advanced KC may demonstrate changes more frequently than those with mild disease.^{135,187,205,326} Following UV-CXL, central cones flatten modestly (with mean and max Ks falling by 1-2D). Paradoxically, eyes with eccentrically located cones may actually display central steepening after treatment as the corneal parameters become more alike.¹³⁴ Shortly after therapy, CCT may decline (likely the result of keratocytes apoptosis in the anterior stroma) but rebounds to baseline at one year.^{56,287,305}

Standard INTACS reduce mean Ks by 3-5D.^{32,103,169,180,329} This effect may be slightly enhanced (by a diopter or so) by combining the procedure with UV-CXL, and furthermore, the results may be more durable as well.^{60,343} Yeung et al found that, following combined treatment, flattening occurred which was persevered even if the ring segments were later explanted.³⁵⁸ Alternative segment designs include INTACS SK, Kerarings, the Ferrara ring, and the Myoring; all of which have smaller internal diameters and are placed closer to the corneal center, thereby effectuating greater mechanical flattening. Large (although highly variable) reductions in mean Ks have been published, ranging from 2-9D, with most studies reporting results at the higher end of that range. No segment design has proven substantially more effective than any other in this regard, although direct head-to-head trials are rare.^{126,141,159,160,189,195,196,290,303}

The primary effect of BL transplantation is to flatten the operated cornea: by unfolding the transplanted tissue within the stromal pocket and tucking the edges of the graft into the far periphery of the dissected cavity, the natural healing response of the eye generates a tractional force that “pulls” the ectatic cornea into a more normal configuration. The two reports on the magnitude of these effects suggests a 5D reduction in mean anterior simulated Ks, 5-7D reduction in max corneal power, and a 8-9D reduction in max K. These topographic changes occur within the first postoperative month and appear stable through at least two years of follow-up. Both CCT and TPT appear very slightly

greater after surgery, although it is questionable whether either change is statistically significant.^{338,339}

VIII. POSTOPERATIVE DISEASE PROGRESSION

Both DALK and PK replace only the central cornea leaving a peripheral rim of tissue behind. (With DALK, some variable amount of host posterior stroma often remains as well.) There exists now considerable evidence that many eyes receiving either of these two operations continue to progress. Posited explanations include continued ectatic deterioration of the unoperated corneal rim, ongoing graft-host interface misalignment, recurrent disease in the donor button, and transplantation with keratoconic tissue.^{31,85,118,149,213,253,254,264,356} A relevant study was performed by Bourges et al which examined eyes with advanced KC treated with PK. In the years after surgery, in all eyes requiring a repeat PK for any reason, histopathologic study of the removed donor buttons revealed structural changes consistent with KC including Bowman layer disruption and stromal deposits. This suggests infiltration or repopulation of the transplanted tissues with pathologic recipient keratocytes (or possibly even recipient epithelial cells).⁴⁰ “Recurrent” KC has likewise been demonstrated after DALK and in fact may be more likely and quicker in onset, since more of the diseased recipient cornea is left unremoved.^{112,263} Interestingly, reports exist of non-keratoconic eyes receiving PK and later experiencing progressive ectasia requiring re-operation.^{58,191} It is uncertain whether these instances stem from using donor tissue with undiagnosed KC or whether this ectatic degeneration is simply the product of ongoing misalignment of the graft-host junction. Nevertheless, it is probably true that neither DALK nor PK truly abolish ongoing ectasia so much as “de-bulk” the recipient cornea of some pathological cells and furnish tissue that may remain, temporarily, “normal.” Per most studies, approximately 10% of eyes will display “recurrent KC” 20 years after PK, with the earliest pathological changes often becoming evident 10 years after final suture removal.^{118,254,264}

Because UV-CXL was introduced in 2006 (now, only eight years ago), true long-term follow up data are still lacking. However, the best available evidence shows a >90% success rate in arresting progression.^{82,157,305} (Interestingly, UV-CXL has also been used effectively to halt progression in a small number of eyes with recurrent KC after PK).²⁸² Risk factors for failure – i.e. ongoing ectasia – include, as previously mentioned, the application of isotonic riboflavin solution to “thicken” a thin cornea prior to treatment, very steep corneal curvature (greater than 55 to 58D), and age >35 years.^{135,130,143,187,305}

After ICRS, the central cornea continues to thin, though this is usually explained as the result of mechanical stretching of the ring segments themselves and not as evidence of advancing disease.⁷³ On the contrary, most evidence shows that – for mild to moderate

KC – ICRS are as effective as UV-CXL in halting progression, with a greater than 90% success rate at 5 and 10 years.^{32,103,169,180,197,329} But as with UV-CXL, the steeper the cornea, the more likely progression is to continue despite treatment.¹⁰ Kymionis et al, studying the five year success rate of ICRS in keratoconic eyes, found that topographic stability was only achieved in eyes with Kmax values <47D.¹⁹⁹ Placement of ICRS may also be combined with UV-CXL, which theoretically might further defend against progression. Studies on the subject do reflect an additive effect with superior normalization of topographic parameters compared to ICRS alone.^{60,343} However, there are no published data currently available which support the claim that disease progression is less likely with this form of “double treatment” compared to either procedure alone.

From early results of BL transplantation, two years postoperatively, 90% of eyes with previously documented progression had stabilized, despite all eyes having pre-operative Kmax's >70D.^{338,339}

IX. CONTACT LENS TOLERANCE

Even after surgery, many patients with advanced KC have far better vision with a rigid lens in place. Whether a patient is able to (comfortably) wear CLs, postoperatively, is therefore a crucial consideration. Nevertheless, lens tolerance is difficult to objectively assess, being directly proportional to the skill and diligence of the prescribing physician, disposition of the patient, and the type of lenses available for use. For example, one study by Smiddy et al of a large cohort of keratoconic eyes referred to the Wilmer Eye Hospital for PK secondary to CL intolerance found that, with assiduous effort and careful lens selection, 87% could be made comfortable and spared surgery.³⁰⁷ As a result, some caution may be applied to all postoperative CL tolerance reports, since they may reflect (at least in part) greater effort rather than true improvement. This is especially true given that there is no universally agreed upon length of time that a patient must be able to withstand CL wear to be deemed “tolerant”. For example, studies exist which count patients as tolerant although the lens can only be comfortably worn for 2-6 hours per day. Finally, it appears that CL tolerance depends chiefly – not on central corneal steepness – but on peripheral clearance, and on the interaction of the upper edge of the lens with the patient’s upper lid. This explains why, all things being equal, an inferiorly decentered cone is more likely to produce CL intolerance; why operations to “center” the cone may increase tolerance; and why an eye may remain CL intolerant even if central steepness is reduced.^{124,307}

After PK for advanced KC, approximately 90% of patients may be tolerant of rigid lenses, with a mean reported comfortable wear time of 9-12 hours daily.³⁰⁷ Scleral lens tolerance, however, frequently decreases secondary to greater peripheral touching.²⁵⁸

Likewise, same-sizing the graft to the recipient produces more corneal flattening, more peripheral touch, and lower tolerance.³⁰⁴

Presently, there are no dedicated studies of CL tolerance after DALK for advanced KC. Conceivably though, comfortable wear may be more likely than after PK, as corneas operated with DALK tend to be modestly steeper postoperatively, thereby reducing peripheral touch.^{14,37,181}

In the long term, CL tolerance may be slightly improved after UV-CXL, although it is unclear whether this stems from surface flattening or, instead, sub-epithelial nerve plexus fibrosis and diminished corneal sensation. In the short term, rigid lenses are relatively contraindicated since they predispose to epithelial hypoxia and anterior keratocyte apoptosis with subsequent haze formation.²⁹⁵

Reports of rigid lens tolerance after ICRS for advanced KC range considerably, from 60-100%. Documented difficulties include a tendency for CLs to center over the segments themselves (rather than the corneal center), inadequate lens movement and tear exchange, and other troubles that – while potentially correctable with the “proper” lens style and fit – are complex, time consuming, and require considerable expertise to remedy.^{57,84,151,180,244,252,300}

To date, all eyes receiving BL transplantation for advanced KC have been scleral lens tolerant postoperatively.^{338,339}

X. POSTOPERATIVE CARE AND PATIENT PERSPECTIVE

Patient satisfaction with surgery for advanced KC relates to: 1) whether the operated eye becomes the better seeing eye, and 2) the size of the burden entailed by surgical follow-up.

Of all patients receiving a PK, young keratoconics tend to be the most pleased.^{334,349} Happiness peaks 5-15 years after surgery (before which, the requirements of postoperative care tend to be more onerous; and after which, mounting irregular astigmatism in the graft may result in frustratingly frequent refractive changes). Nevertheless, it may be prudent to avoid performing PK in patients with only one “bad” eye. Unless the operated eye becomes the “better seeing” of the two, patients are unlikely to achieve functional benefits sufficient to compensate for the hassle and expense of the surgery itself.^{334,349}

Because DALK imposes fewer postoperative obligations than PK, greater patient satisfaction may be expected. Surprisingly however, in the only comparative study on the matter, patients operated with both techniques – PK in one eye, DALK in the other – expressed a preference for their PK eye.³⁵⁷ A potential explanation for this discrepancy is that the study’s PK eyes had significantly better vision than their DALK counterparts,

and it is uncertain whether these preferences would exist had the visual outcomes been equivalent, as they frequently are.

Most of the impositions of UV-CXL seem to be concentrated in the short term. Shortly after surgery, the epithelial defect may be painful and require the wear of soft CLs. Meanwhile, hard CLs are contraindicated during this period as they may contribute to the development of stromal haze.²⁹⁵

The best indicator of severe patient dissatisfaction with ICRS may be the explantation rate, which ranges from 1-35%, usually stemming from prior segment migration, extrusion, or poor visual results – all of which are more likely in eyes with advanced KC.^{8,32,169,180,196}

Following BL transplantation, the operated eye is typically comfortable. Virtually all patients report enhanced “functional” vision with increased ability to perform activities of their daily life, although only modest Snellen improvements may occur. Although the risk of graft rejection is thought to be extremely low, many patients are continued on light topical steroids for one year after surgery, after which they may be stopped completely.^{338,339}

XI. COMPLICATIONS

A. Ocular Surface Effects [PK, DALK, UV-CXL, ICRS, BL Transplantation]

All by itself, KC reduces corneal sensitivity, related to nerve fiber disruption from progressive ectasia as well as prolonged CL wear.^{242,313} Besides having a “relatively neurotrophic” cornea, many patients with advanced KC have other ocular surface problems as well. These include vernal keratoconjunctivitis, atopic eye disease, and floppy eyelid syndrome.^{179,275,277,333} In fact, most keratoconic eyes display disorders in tear quality and conjunctival cellular composition (squamous metaplasia and goblet cell dropout) that mirror the extent of their corneal ectasia.⁹¹ Interestingly, although KC is usually regarded as a non-inflammatory disease, a litany of inflammatory molecules has been found in superabundance in the tears of affected eyes – in quantities corresponding to the severity of their ectasia – raising the possibility that the pathological mechanism is actually a longstanding chronic inflammation.²⁰⁶⁻²⁰⁸ For these reasons, ocular surface issues are likely to be a significant consideration in eyes with advanced KC.

PK and DALK tend to worsen any existing ocular surface problems, as both involve surface incisions, severing of corneal nerves, and placement of long-lasting sutures. These difficulties are evidenced by chronic, punctate epithelial erosions which may persist indefinitely in 10-20% of eyes after PK.²⁵⁶ In eyes with co-existing vernal keratoconjunctivitis, Waggoner et al showed that nearly 7% may have late-onset, persistent epithelial defects after surgery.³⁴⁷ Eyes with advanced KC are also at especially high risk for suture

related problems – especially cheese wiring – owing to the weak Bowman layer in the recipient corneal rim which provides an ineffective anchor point/ resistance barrier to suture pull-through.⁶⁸ In one study of 947 consecutive eyes operated for advanced KC, 10% required re-suturing at some time, secondary to either graft dehiscence or loosened/ broken sutures.¹⁶³ With ongoing surface problems, both PK and DALK grafts are also more likely to fail, and “recurrence” may be more likely secondary to ongoing eye rubbing.^{29,166,321,356,359}

The initial, most commonly performed, and likely optimal protocol for UV-CXL requires complete epithelial debridement. Subsequent UV radiation damages the underlying sub-epithelial nerve plexus. Consequently, any existing neurotrophic tendencies may be worsened until nerve regeneration occurs and sensation is restored, a process that can require up to a year.^{230,313} This combined with post-op soft contact lens wear dramatically raises the risk for infectious keratitis and stromal melting, particularly when concomitant ocular surface disease impairs normal corneal re-epithelialization.^{16,265,270,292} UV-CXL also appears to carry a theoretical risk to limbal stem cells, since some in-vitro studies demonstrate decreased regenerative capacity and increased apoptosis following treatment.^{243,323} Apoptosis of anterior keratocytes also appears to be the mechanism for UV-CXL's most commonly reported complication – the development of anterior stromal haze – which may be seen in 7 to 100 % of eyes following the procedure, and may be particularly severe in patients with advanced KC. Usually, this haze gradually dissipates over the course of a year, but may be permanent in a small percentage of those affected.^{133,228}

As previously mentioned, ICRS endanger the ocular surface according to how superficially they lie. Shallow segments may result in overlying tissue hypoxia (secondary to anterior stromal compression), and subsequent corneal neovascularization, recurrent erosion, corneal melting, and ring segment exposure / extrusion.^{77,200,300,363} Manually dissected segment channels tend to be shallower and more irregular than those created by femtosecond laser and may predispose to more of these problems (although, femtosecond created channels are more often decentered, jeopardizing the predictability and success of the corrective effect).^{79,102,104,274} Compared to INTACS, Ferrara segments—because of their triangular/ wedged cross-sectional shape – may conduce to gradual segment superficialization.¹⁵²

Unless stitched closed, wound gape may occur at the mouth of the channels. Infectious keratitis is relatively uncommon after ICRS, occurring in 2% of operated eyes.^{146,155,240} Although gram positive organisms are the most common offenders, corneal cultures are usually negative, since many patients are still using post-operative antibiotics at the time of diagnosis. Treatment consists of topical antibiotics and does not always require segment explantation. Usually, no long term visual consequences are experienced, though occasionally extensive scarring requiring subsequent PK occurs.²⁴⁵

BL transplantation may be the least dangerous option in eyes with surface problems, since the operation leaves the corneal surface intact. It makes no surface incisions, uses no sutures, and instills no artificial materials (**Figure 3**).^{338,339}

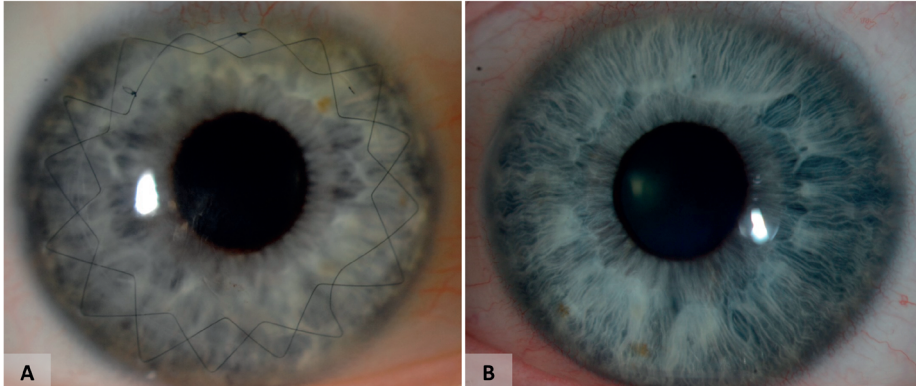


Figure 3. Two images of a single patient (A) Right eye, six months after DALK; (B) Left eye, six months after BL transplantation, with a regular ocular surface.

B. Graft rejection and failure [PK, DALK, BL Transplantation]

Although primary graft failure following PK has become rare, episodes of allograft reaction remain relatively common, affecting 13-31% of eyes in the first three years after surgery, with a mean time to onset of 8-15 months.^{289,324,346-351} The most important risk factors are the size of the graft, the number of previous corneal transplants, and the presence of peripheral corneal neovascularization, though other factors have been implicated as well including the lingering presence of interrupted sutures (especially if loose), an atopic constitution, glaucoma, and having previously received a PK in the contralateral eye (especially if within the past 12 months).^{49,92,99,110,221,254,256,322} Most instances of allograft reaction can be successfully halted by the timely application of steroid treatment, such that graft failure may occur in less than 10% of such events.¹²⁸

For the first PK an eye receives for advanced KC, long term survival is usually good, averaging 97% at 5 years, 90% at 10 years, and 80% at 20-25 years postoperatively.^{67,164,177,271,322} These figures are substantially better than those reported following PK for other indications such as FED or PBK.³²² A potential explanation for this discrepancy is that eyes operated for advanced KC may have a relatively “healthy” pool of normal endothelial cells remaining within the peripheral (unoperated) corneal rim, which may migrate in to bolster and support the endothelial population of the graft over time (which may not occur if PK is performed for endothelial failure).^{177,281}

After the first, all subsequent PKs that a single eye receives experience substantially lower survival rates. With second grafts, survival at 1 year may be only 88%, 69% at 5

years, and 46% at 15 years postoperatively. For third grafts, these figures are worse still, with only 65% surviving 1 year, 49% surviving 5 years, and 33% surviving 15 years (median survival of 4 years).^{177,360} Time to first failure is an important independent risk factor for future failures, with transplants having failed within the first decade more than four times as likely to fail again. Recipient age greater than 60 is another risk factor for subsequent grafts (after the first) to fail.^{177,281,360} Because many patients with advanced KC are transplanted early in life, it may be more likely than not that, ultimately, more than one graft may be required over their lifetime. Therefore, these dramatically worsened survival figures for subsequent grafts may be important long term consequences even for eyes with very good, initial, surgical results.

Further, recall that even some “surviving” grafts (i.e. with a healthy population of endothelial cells) may require replacement if progressive or recurrent corneal ectasia becomes severe – a condition which affects an estimated 11% of eyes at 20 years postoperatively.^{118,254}

DALK may present risks for milder versions of many of these same complications. Allograft reactions may be less frequent and less likely to result in graft failure.²⁹⁹ Graft survival is projected to be longer, with Borderie et al calculating an average lifespan for PK grafts of 17.9 years, compared to 49.0 years with DALK.³⁸ Probably, this disparity exists because, after DALK, ECDs are consistently higher than after PK (unless an intraoperative DM perforation occurs, in which case they are equal).^{38,65,335} Occasionally, an eye will require a re-operation after DALK secondary to poor visual acuity, usually because of interface haze stemming from incomplete or pre-descemetic stromal dissection. While some studies label these “underperforming” DALKs as “failed grafts,” it is important to note that the mechanism is fundamentally different than graft failures following PK.⁸¹

With BL transplantation, the transplanted tissue is acellular, and therefore would be theoretically unlikely to provoke a strong immune reaction. To date, no episodes of allograft reaction, or graft failure, have been observed.^{338,339}

C. DM perforation [DALK, ICRS, BL Transplantation]

DALK’s most significant complication is intraoperative DM perforation, which may occur in 0-50 % of eyes.^{19^{90,111,176,204,236}} Depending on the size of the perforation, conversion to PK (or suturing/ gluing of the ruptured DM) may be necessary to avoid the formation of a double anterior chamber and persistent corneal edema.^{18,318} If using Melles manual dissection (rather than the Anwar big-bubble), if perforation occurs the operation can be aborted and reattempted at a later date, since no surface incisions have been made.

ICRS placement may cause DM perforation in approximately 5% of eyes with advanced KC, being especially likely in extremely thin and steep corneas. Although the DM rupture is usually sustained intra-operatively, late perforations have also been reported attributed to segment migration stemming from eye rubbing.^{138,169,261}

BL transplantation may also result in inadvertent DM perforation – reported in 4-9% of eyes – particularly in especially thin and steep corneas. As with Melles manual DALK, if rupture occurs, the operation may be aborted and rescheduled or converted to PK.^{338,339}

D. Glaucoma [PK, DALK, BL Transplantation]

Although severe intraocular pressure (IOP) increases are less common when the indication for PK is advanced KC (compared to herpetic disease, intractable ulcer, FED, PBK, or corneal perforation), still, most eyes – approximately 75% - experience a pressure rise.^{23,107,132} According to a report by Erdurmus et al, these IOP elevations are >5mmHg from baseline in 72% of patients, and >10mmHg in 24%. Although usually resolving with steroid tapering, persistently high IOP (requiring treatment) may ensue in 6-15% of operated eyes.^{100,154} In aphakic eyes, there is a smaller incidence of glaucoma one year after surgery if an oversized (versus a same-sized) graft is used, although this result has been frequently extrapolated to argue for oversizing grafts in phakic and pseudophakic eyes as well.^{41,365}

Likely because of their lower steroid requirement (owing to the smaller risk of rejection), eyes receiving DALK may be less prone to IOP problems.^{144,247,335} For eyes with advanced KC, Zhang et al described an increase in IOP following DALK in only 1.3% of operated eyes, compared to 42% of eyes after PK.³⁶⁴ Actual glaucoma may also be less common (by up to 40%) per a study by Tan et al.³²⁰

Presently, it is standard to use the same postoperative steroid regimen following BL transplantation as with DALK (though, after a year, it may be possible to discontinue topical steroids entirely). Consequently, BL transplantation may embody some, though probably lower, risk for glaucoma than either DALK or PK. Presently, however, there is only a single case reported of glaucoma diagnosed after BL transplantation, though it is unclear whether the operation itself was responsible.^{338,339}

XII. FUTURE DIRECTIONS

Treatment for advanced KC has trended away from PK (and to some extent, even DALK) largely because of the problems these surgeries entail: ocular surface and wound healing difficulties, suture related issues, allograft reactions, glaucoma, and others. UV-CXL, ICRS, and – most recently, BL transplantation – represent the “second wave” of therapeutic options for advanced KC, notable especially for being much less invasive, and therefore, potentially safer. All three of these latter operations require more study, particularly BL transplantation, whose first patients are now only four years removed from surgery. But if substantial, permanent corneal flattening can be achieved without

surface incisions, sutures, or the requirement for long term steroids, then these surgeries may represent the future of advanced KC treatment.

XIII. METHODS OF LITERATURE SEARCH

The Pubmed and Cochrane library was searched electronically for peer-reviewed literature in November 2013 and October 2014 without date restrictions. Key words employed in the search included keratoconus, penetrating keratoplasty, deep anterior lamellar keratoplasty, intracorneal ring segments, and corneal crosslinking, Articles were included according to their relevance to the subject and excluded to avoid redundancy.

XIV. DISCLOSURE

No author has a financial or proprietary interest in any material or method mentioned. Dr Melles is a consultant for D.O.R.C. International/ Dutch Ophthalmic USA and Surgi-Cube International.

REFERENCES

1. Abou Shousha M, Perez VL, Fraga Santini Canto AP, et al. The use of Bowman's layer vertical topographic thickness map in the diagnosis of keratoconus. *Ophthalmology*. 2014;121(5):988-93
2. Acar BT, Vural ET, Acar S. Does the type of suturing technique used affect astigmatism after deep anterior lamellar keratoplasty in keratoconus patients? *Clin Ophthalmol*. 2011;5:425-8
3. Ahearne M, Yang Y, Then KY, Liu KK. Non-destructive mechanical characterisation of UVA/riboflavin crosslinked collagen hydrogels. *Br J Ophthalmol*. 2008;92(2):268-71
4. Akdemir MO, Kandemir B, Sayman IB, et al. Comparison of contrast sensitivity and visual acuity between deep anterior lamellar keratoplasty and penetrating keratoplasty in patients with keratoconus. *Int J Ophthalmol*. 2012;5(6):737-41
5. Akova YA, Dabil H, Kavalcioglu O, Duman S. Clinical features and keratoplasty results in keratoconus complicated by acute hydrops. *Ocul Immunol Inflamm*. 2000;8(2):101-9
6. Alfonso JF, Lisa C, Fernández-Vega L, et al. Intrastromal corneal ring segment implantation in 219 keratoconic eyes at different stages. *Graefes Arch Clin Exp Ophthalmol*. 2011;249(11):1705-12
7. Alió JL, Artola A, Ruiz-Moreno JM, et al. Changes in keratoconic corneas after intracorneal ring segment explantation and reimplantation. *Ophthalmology*. 2004;111(4):747-51
8. Alió JL, Shabayek MH, Belda JI, et al. Analysis of results related to good and bad outcomes of Intacs implantation for keratoconus correction. *J Cataract Refract Surg*. 2006;32(5):756-61
9. Alió JL, Shabayek MH. Intracorneal asymmetrical rings for keratoconus: where should the thicker segment be implanted? *J Refract Surg*. 2006;22(3):307-9
10. Alió JL, Vega-Estrada A, Esperanza S, et al. Intrastromal corneal ring segments: how successful is the surgical treatment of keratoconus? *Middle East Afr J Ophthalmol*. 2014;21(1):3-9
11. Al-Mohaimeed MM. Penetrating keratoplasty for keratoconus: visual and graft survival outcomes. *Int J Health Sci (Qassim)*. 2013;7(1):67-74
12. Alsuhaibani AH, Al-Rajhi AA, Al-Motowa SM, Wagoner MD. Corneal endothelial cell density and morphology after acute hydrops in keratoconus. *Cornea*. 2008;27(5):535-8
13. Amayem AF, Anwar M. Fluid lamellar keratoplasty in keratoconus. *Ophthalmology*. 2000;107(1):76-9
14. Amayem AF, Hamdi IM, Hamdi MM. Refractive and visual outcomes of penetrating keratoplasty versus deep anterior lamellar keratoplasty with hydrodissection for treatment of keratoconus. *Cornea*. 2013;32(4):e2-5
15. Amigo A, Bonaque S. Safety of extended use of hypoosmolar riboflavin in crosslinking. *J Cataract Refract Surg*. 2014;40(1):171-2
16. Angunawela RI, Arnalich-Montiel F, Allan BD. Peripheral sterile corneal infiltrates and melting after collagen crosslinking for keratoconus. *J Cataract Refract Surg*. 2009;35(3):606-7
17. Anwar HM, Anwar M. Predescemet dissection for healed hydrops—judicious use of air and fluid. *Cornea*. 2011;30(12):1502-9
18. Anwar HM, El-Danasoury A, Hashem AN. The use of fibrin glue to seal Descemet membrane microperforations occurring during deep anterior lamellar keratoplasty. *Cornea*. 2012;31(10):1193-6
19. Anwar M, Teichmann KD. Big-bubble technique to bare Descemet's membrane in anterior lamellar keratoplasty. *J Cataract Refract Surg*. 2002;28(3):398-403
20. Ardjomand N, Hau S, McAlister JC, et al. Quality of vision and graft thickness in deep anterior lamellar and penetrating corneal allografts. *Am J Ophthalmol*. 2007;143(2):228-35

21. Arora R, Jain P, Goyal JL, Gupta D. Comparative analysis of refractive and topographic changes in early and advanced keratoconic eyes undergoing corneal collagen crosslinking. *Cornea*. 2013; Aug 22 [Epub ahead of print]
22. Asri D, Touboul D, Fournié P, et al. Corneal collagen crosslinking in progressive keratoconus: multi-center results from the French National Reference Center for Keratoconus. *J Cataract Refract Surg*. 2011;37(12):2137-43
23. Ayyala RS. Penetrating keratoplasty and glaucoma. *Surv Ophthalmol*. 2000;45(2):91-105
24. Azar RG, Holdbrook MJ, Lemp M, et al. Two-year corneal endothelial cell assessment following INTACS implantation. *J Refract Surg*. 2001;17(5):542-8
25. Baenninger PB, Bachmann LM, Wienecke L, et al. Effects and adverse events after CXL for keratoconus are independent of age: a 1-year follow-up study. *Eye (Lond)*. 2014;28(6):691-5
26. Bagga B, Pahuja S, Murthy S, Sangwan VS. Endothelial failure after collagen cross-linking with riboflavin and UV-A: case report with literature review. *Cornea*. 2012; 31(10):1197-200
27. Bahar I, Kaiserman I, Srinivasan S, et al. Comparison of three different techniques of corneal transplantation for keratoconus. *Am J Ophthalmol*. 2008;146(6):905-12
28. Balestrazzi E, Balestrazzi A, Mosca L, Balestrazzi A. Deep lamellar keratoplasty with trypan blue intrastromal staining. *J Cataract Refract Surg*. 2002;28(6):929-31
29. Basu S, Reddy JC, Vaddavalli PK, et al. Long-term outcomes of penetrating keratoplasty for keratoconus with resolved corneal hydrops. *Cornea*. 2012;31(6):615-20
30. Basu S, Sangwan VS. Efficacy and safety of conductive keratoplasty in keratoconus. *Am J Ophthalmol*. 2011;151(4):735;author reply 735-6
31. Bechrakis N, Blom ML, Stark WJ, Green WR. Recurrent keratoconus. *Cornea*. 1994;13(1):73-7
32. Bedi R, Touboul D, Pinsard L, Colin J. Refractive and topographic stability of Intacs in eyes with progressive keratoconus: five-year follow-up. *J Refract Surg*. 2012;28(6):392-6
33. Behrens A, Seitz B, Langenbucher A, et al. Lens opacities after nonmechanical versus mechanical corneal trephination for keratoplasty in keratoconus. *J Cataract Refract Surg*. 2000;26(11):1605-11
34. Bilgihan K, Ozdek SC, Sari A, Hasanreisoglu B. Microkeratome-assisted lamellar keratoplasty for keratoconus: stromal sandwich. *J Cataract Refract Surg*. 2003;29(7):1267-72
35. Bodenmueller M, Goldblum D, Frueh BE. Penetrating keratoplasty in Down's syndrome. *Klin Monbl Augenheilkd*. 2003;220(3):99-102
36. Boimer C, Lee K, Sharpen L, et al. Evolving surgical techniques of and indications for corneal transplantation in Ontario from 2000 to 2009. *Can J Ophthalmol*. 2011;46(4):360-6
37. Borderie VM, Georgeon C, Borderie M, et al. Corneal radius of curvature after anterior lamellar versus penetrating keratoplasty. *Graefes Arch Clin Exp Ophthalmol*. 2014;252(3):449-56
38. Borderie VM, Sandali O, Bullet J, et al. Long-term results of deep anterior lamellar versus penetrating keratoplasty. *Ophthalmology*. 2012;119(2):249-55
39. Bottós KM, Hofling-Lima AL, Barbosa MC, et al. Effect of collagen cross-linking in stromal fibril organization in edematous human corneas. *Cornea*. 2010;29(7):789-93
40. Bourges JL, Savoldelli M, Dighiero P, et al. Recurrence of keratoconus characteristics: a clinical and histologic follow-up analysis of donor grafts. *Ophthalmology*. 2003;110(10):1920-5
41. Bourne WM, Davison JA, O'Fallon WM. The effects of oversize donor buttons on postoperative intraocular pressure and corneal curvature in aphakic penetrating keratoplasty. *Ophthalmology*. 1982;89(3):242-6
42. Boxer Wachler BS, Christie JP, Chandra NS, et al. Intacs for keratoconus. *Ophthalmology*. 2003; 110(5):1031-40

43. Brahma A, Ennis F, Harper R, et al. Visual function after penetrating keratoplasty for keratoconus: a prospective longitudinal evaluation. *Br J Ophthalmol.* 2000;84(1):60-6
44. Brierly SC, Izquierdo L Jr, Mannis MJ. Penetrating keratoplasty for keratoconus. *Cornea.* 2000; 19(3):329-32
45. Buratto L, Böhm E. The use of the femtosecond laser in penetrating keratoplasty. *Am J Ophthalmol.* 2007;143(5):737-742
46. Burk LL, Waring GO 3rd, Radjee B, Stulting RD. The effect of selective suture removal on astigmatism following penetrating keratoplasty. *Ophthalmic Surg.* 1988;19(12):849-54
47. Busin M, Mönks T, al-Nawaiseh I. Different suturing techniques variously affect the regularity of postkeratoplasty astigmatism. *Ophthalmology.* 1998;105(7):1200-5
48. Busin M, Zambianchi L, Arffa RC. Microkeratome-assisted lamellar keratoplasty for the surgical treatment of keratoconus. *Ophthalmology.* 2005;112(6):987-97
49. Buxton JN, Schuman M, Pecego J. Graft reactions after unilateral and bilateral keratoplasty for keratoconus. *Ophthalmology.* 1981;88(8):771-3
50. Buzard KA, Fundingsland BR. Corneal transplant for keratoconus: results in early and late disease. *J Cataract Refract Surg.* 1997;23(3):398-406
51. Buzzonetti L, Petrocelli G, Laborante A. Anterior lamellar keratoplasty assisted by IntraLase™ femtosecond laser in a pediatric patient. *J Pediatr Ophthalmol Strabismus.* 2010;47:e1-4
52. Buzzonetti L, Petrocelli G, Valente P. Big-bubble deep anterior lamellar keratoplasty assisted by femtosecond laser in children. *Cornea.* 2012;31(9):1083-6
53. Cakir H, Pekel G, Perente I, Genç S. Comparison of intrastromal corneal ring segment implantation only and in combination with collagen crosslinking for keratoconus. *Eur J Ophthalmol.* 2013; 23(5):629-34
54. Caporossi A, Mazzotta C, Baiocchi S, et al. Age-related long-term functional results after riboflavin UV A corneal cross-linking. *J Ophthalmol.* 2011;2011:608041
55. Caporossi A, Mazzotta C, Baiocchi S, et al. Riboflavin-UVA-induced corneal collagen cross-linking in pediatric patients. *Cornea.* 2012;31(3):227-31
56. Caporossi A, Mazzotta C, Paradiso AL, et al. Transepithelial corneal collagen crosslinking for progressive keratoconus: 24-month clinical results. *J Cataract Refract Surg.* 2013;39(8):1157-63
57. Carrasquillo KG, Rand J, Talamo JH. Intacs for keratoconus and post-LASIK ectasia: mechanical versus femtosecond laser-assisted channel creation. *Cornea.* 2007;26(8):956-62
58. Cason JB, Yiu SC. Acute hydrops in the donor cornea graft in non-keratoconus patients. *Middle East Afr J Ophthalmol.* 2013;20(3):265-7
59. Chamberlain WD, Rush SW, Mathers WD, et al. Comparison of femtosecond laser-assisted keratoplasty versus conventional penetrating keratoplasty. *Ophthalmology.* 2011;118(3):486-91
60. Chan CC, Sharma M, Wachler BS. Effect of inferior-segment Intacs with and without C3-R on keratoconus. *J Cataract Refract Surg.* 2007;33(1):75-80
61. Chan CC, Wachler BS. Reduced best spectacle-corrected visual acuity from inserting a thicker Intacs above and thinner Intacs below in keratoconus. *J Refract Surg.* 2007;23(1):93-5
62. Chan E, Snibson GR. Current status of corneal collagen cross-linking for keratoconus: a review. *Clin Exp Optom.* 2013;96(2):155-64
63. Chang DF, Tan JJ, Tripodis Y. Risk factors for steroid response among cataract patients. *J Cataract Refract Surg.* 2011;37(4):675-81
64. Chatzis N, Hafezi F. Progression of keratoconus and efficacy of pediatric [corrected] corneal collagen cross-linking in children and adolescents. *J Refract Surg.* 2012;28(11):753-8

65. Cheng YY, Visser N, Schouten JS, et al. Endothelial cell loss and visual outcome of deep anterior lamellar keratoplasty versus penetrating keratoplasty: a randomized multicenter clinical trial. *Ophthalmology*. 2011;118(2):302-9
66. Chew AC, Mehta JS, Tan DT. Deep lamellar keratoplasty after resolution of hydrops in keratoconus. *Cornea*. 2011;30(4):454-9
67. Choi JA, Lee MA, Kim MS. Long-term outcomes of penetrating keratoplasty in keratoconus: analysis of the factors associated with final visual acuities. *Int J Ophthalmol*. 2014;7(3):517-21
68. Christo CG, van Rooij J, Geerards AJ, et al. Suture-related complications following keratoplasty: a 5-year retrospective study. *Cornea*. 2001;20(8):816-9
69. Chunyu T, Xiujun P, Zhengjun F, et al. Corneal collagen cross-linking in keratoconus: a systematic review and meta-analysis. *Sci Rep*. 2014;4:5652
70. Ciftci S, Ciftci L, Dogan E, Simsek A. Sensory exotropia associated with keratoconus and review of literature: strabismus and keratoconus. *Eye Sci*. 2013;28(2):88-91
71. Colin J, Buestel C, Touboul D. Unusual secondary displacement of Intacs segments--superimposition of distal ends. *J Refract Surg*. 2010;26(12):924-5
72. Colin J, Cochener B, Savary G, et al. INTACS inserts for treating keratoconus: one-year results. *Ophthalmology*. 2001;108(8):1409-14
73. Colin J, Malet FJ. Intacs for the correction of keratoconus: two-year follow-up. *J Cataract Refract Surg*. 2007;33(1):69-74
74. Colin J, Touboul D, Bedi R. Refractive and keratometric outcomes of intacs continue to improve until 6 months. *Cornea*. 2011;30(9):1068; author reply 1068-9
75. Colin J, Velou S. Current surgical options for keratoconus. *Cataract Refract Surg*. 2003;29(2):379-86
76. Coombes AG, Kirwan JF, Rostron CK. Deep lamellar keratoplasty with lyophilised tissue in the management of keratoconus. *Br J Ophthalmol*. 2001;85(7):788-91
77. Cosar CB, Sridhar MS, Sener B. Late onset of deep corneal vascularization: a rare complication of intrastromal corneal ring segments for keratoconus. *Eur J Ophthalmol*. 2009;19(2):298-300
78. Coskunseven E, Jankov MR 2nd, Hafezi F, et al. Effect of treatment sequence in combined intrastromal corneal rings and corneal collagen crosslinking for keratoconus. *J Cataract Refract Surg*. 2009;35(12):2084-91
79. Coskunseven E, Kymionis GD, Tsiklis NS, et al. Complications of intrastromal corneal ring segment implantation using a femtosecond laser for channel creation: a survey of 850 eyes with keratoconus. *Acta Ophthalmol*. 2011;89(1):54-7
80. Coskunseven E, Kymionis GD, Tsiklis NS, et al. One-year results of intrastromal corneal ring segment implantation (KeraRing) using femtosecond laser in patients with keratoconus. *Am J Ophthalmol*. 2008;145(5):775-9
81. Coster DJ, Lowe MT, Keane MC, et al. A comparison of lamellar and penetrating keratoplasty outcomes: a registry study. *Ophthalmology*. 2014;121(5):979-87
82. Craig JA, Mahon J, Yellowlees A, et al. Epithelium-off photochemical corneal collagen cross-linkage using riboflavin and ultraviolet a for keratoconus and keratectasia: a systematic review and meta-analysis. *Ocul Surf*. 2014;12(3):202-14
83. Cullen J, Butler H. Mongolism (down's syndrome) and keratoconus. *Br J Ophthalmol*. 1963;47:321-30
84. Dalton K, Sorbara L. Fitting an MSD (mini scleral design) rigid contact lens in advanced keratoconus with INTACS. *Cont Lens Anterior Eye*. 2011;34(6):274-81
85. Dang TQ, Molchan RP, Taylor KR, et al. Novel approach for the treatment of corneal ectasia in a graft. *Cornea*. 2014;33(3):310-2

86. Das S, Dua N, Ramamurthy B. Deep lamellar keratoplasty in keratoconus with healed hydrops. *Cornea*. 2007;26(9):1156-7
87. Davis EA, Azar DT, Jakobs FM, Stark WJ. Refractive and keratometric results after the triple procedure: experience with early and late suture removal. *Ophthalmology*. 1998;105(4):624-30
88. De Bernardo M, Capasso L, Tortori A, et al. Trans epithelial corneal collagen crosslinking for progressive keratoconus: 6 months follow up. *Cont Lens Anterior Eye*. 2014; Aug 26 [Epub ahead of print]
89. de Toledo JA, de la Paz MF, Barraquer RI, Barraquer J. Long-term progression of astigmatism after penetrating keratoplasty for keratoconus: evidence of late recurrence. *Cornea*. 2003;22(4):317-23
90. Den S, Shimmura S, Tsubota K, Shimazaki J. Impact of the descemet membrane perforation on surgical outcomes after deep lamellar keratoplasty. *Am J Ophthalmol*. 2007;143(5):750-4
91. Dogru M, Karakaya H, Ozçetin H, et al. Tear function and ocular surface changes in keratoconus. *Ophthalmology*. 2003;110(6):1110-8
92. Donshik PC, Cavanagh HD, Boruchoff SA, Dohlman CH. Effect of bilateral and unilateral grafts on the incidence of rejections in keratoconus. *Am J Ophthalmol*. 1979;87(6):823-6
93. Donshik PC, Cavanaugh HD, Boruchoff SA, Dohlman CH. Posterior subcapsular cataracts induced by topical corticosteroids following keratoplasty for keratoconus. *Ann Ophthalmol*. 1981;13(1):29-32
94. Downie LE. The necessity for ocular assessment in atopic children: bilateral corneal hydrops in an 8 year old. *Pediatrics*. 2014;134(2):e596-601
95. Duran JA, Malvar A, Diez E. Corneal dioptric power after penetrating keratoplasty. *Br J Ophthalmol*. 1989;73(8):657-60
96. El Awady H, Shawky M, Ghanem AA. Evaluation of collagen crosslinking in keratoconus eyes with Kera intracorneal ring implantation. *Eur J Ophthalmol*. 2012;22(Suppl 7):S62-
97. El-Agha MS, El Sayed YM, Harhara RM, Essam HM. Correlation of corneal endothelial changes with different stages of keratoconus. *Cornea*. 2014;33(7):707-11
98. El-Raggal TM. Effect of corneal collagen crosslinking on femtosecond laser channel creation for intrastromal corneal ring segment implantation in keratoconus. *J Cataract Refract Surg*. 2011;37(4):701-5
99. Epstein AJ, de Castro TN, Laibson PR, et al. Risk factors for the first episode of corneal graft rejection in keratoconus. *Cornea*. 2006;25(9):1005-11
100. Erdurmus M, Cohen EJ, Yildiz EH, et al. Steroid-induced intraocular pressure elevation or glaucoma after penetrating keratoplasty in patients with keratoconus or Fuchs dystrophy. *Cornea*. 2009;28(7):759-64
101. Ertan A, Colin J. Intracorneal rings for keratoconus and keratectasia. *J Cataract Refract Surg*. 2007;33(7):1303-14
102. Ertan A, Kamburoğlu G. Analysis of centration of Intacs segments implanted with a femtosecond laser. *J Cataract Refract Surg*. 2007;33(3):484-7
103. Ertan A, Kamburoğlu G. Intacs implantation using a femtosecond laser for management of keratoconus: Comparison of 306 cases in different stages. *J Cataract Refract Surg*. 2008;34(9):1521-6
104. Ertan A, Karacal H. Factors influencing flap and INTACS decentration after femtosecond laser application in normal and keratoconic eyes. *J Refract Surg*. 2008;24(8):797-801
105. Ertan A, Ozkilic E. Effect of age on outcomes in patients with keratoconus treated by Intacs using a femtosecond laser. *J Refract Surg*. 2008;24(7):690-5
106. Fan Gaskin JC, Patel DV, McGhee CN. Acute corneal hydrops in keratoconus - new perspectives. *Am J Ophthalmol*. 2014;157(5):921-8

107. Fan JC, Chow K, Patel DV, McGhee CN. Corticosteroid-induced intraocular pressure elevation in keratoconus is common following uncomplicated penetrating keratoplasty. *Eye (Lond)*. 2009;23(11):2056-62
108. Fares U, Sarhan AR, Dua HS. Management of post-keratoplasty astigmatism. *J Cataract Refract Surg*. 2012;38(11):2029-39
109. Faschinger C, Kleinert R, Wedrich A. [Corneal melting in both eyes after simultaneous corneal cross-linking in a patient with keratoconus and Down syndrome]. *Ophthalmologe*. 2010;107(10):951-2,954-5
110. Fasolo A, Capuzzo C, Fornea M, et al. Risk factors for graft failure after penetrating keratoplasty: 5-year follow-up from the corneal transplant epidemiological study. *Cornea*. 2011;30(12):1328-35
111. Feizi S, Javadi MA, Jamali H, Mirbabae F. Deep anterior lamellar keratoplasty in patients with keratoconus: big-bubble technique. *Cornea*. 2010;29(2):177-82
112. Feizi S, Javadi MA, Rezaei Kanavi M. Recurrent keratoconus in a corneal graft after deep anterior lamellar keratoplasty. *J Ophthalmic Vis Res*. 2012;7(4):328-31
113. Ferrara P, Ferrara G, Torquetti L. Ferrara technique of deep anterior lamellar keratoplasty for keratoconus treatment. *Int J Keratoconus Ectatic Corneal Diseases*. 2013;2(2):51-5
114. Ferreira TB, Güell JL, Manero F. Combined intracorneal ring segments and iris-fixated phakic intraocular lens for keratoconus refractive and visual improvement. *J Refract Surg*. 2014;30(5):336-41
115. Filippello M, Stagni E, O'Brart D. Transepithelial corneal collagen crosslinking: bilateral study. *J Cataract Refract Surg*. 2012;38(2):283-91
116. Fontana L, Parente G, Sincich A, Tassinari G. Deep anterior lamellar keratoplasty after Intacs implantation in patients with keratoconus. *Cornea*. 2009;28(1):32-5
117. Fontana L, Parente G, Sincich A, Tassinari G. Influence of graft-host interface on the quality of vision after deep anterior lamellar keratoplasty in patients with keratoconus. *Cornea*. 2011;30(5):497-502
118. Fukuoka S, Honda N, Ono K, et al. Extended long-term results of penetrating keratoplasty for keratoconus. *Cornea*. 2010;29(5):528-30
119. Funnell CL, Ball J, Noble BA. Comparative cohort study of the outcomes of deep lamellar keratoplasty and penetrating keratoplasty for keratoconus. *Eye (Lond)*. 2006;20(5):527-32
120. Ganekal S, Gangangouda C, Dorairaj S, Jhanji V. Early outcomes of primary pediatric keratoplasty in patients with acquired, atraumatic corneal pathology. *J AAPOS*. 2011;15(4):353-5
121. García García GP, Martínez JB. Outcomes of penetrating keratoplasty in mentally retarded patients with keratoconus. *Cornea*. 2008;27(9):980-7
122. Gaster RN, Dumitrascu O, Rabinowitz YS. Penetrating keratoplasty using femtosecond laser-enabled keratoplasty with zig-zag incisions versus a mechanical trephine in patients with keratoconus. *Br J Ophthalmol*. 2012;96(9):1195-9
123. Gatziofas Z, Richoz O, Spoerl E, Hafezi F. Persistent corneal edema after collagen cross-linking for keratoconus. *Am J Ophthalmol*. 2013; 155(3): 610-1
124. Geerards AJ, Vreugdenhil W, Khazen A. Incidence of rigid gas-permeable contact lens wear after keratoplasty for keratoconus. *Eye Contact Lens*. 2006;32(4):207-10
125. Ghanem RC, Ghanem MA. Pachymetry-guided intrastromal air injection ("pachy-bubble") for deep anterior lamellar keratoplasty. *Cornea*. 2012;31(9):1087-91
126. Gharaibeh AM, Muhsen SM, AbuKhader IB, et al. KeraRing intrastromal corneal ring segments for correction of keratoconus. *Cornea*. 2012;31(2):115-20

127. Giedd KK, Mannis MJ, Mitchell GL, Zadnik K. Personality in keratoconus in a sample of patients derived from the internet. *Cornea*. 2005;24(3):301-7
128. Girard LJ, Esnaola N, Rao R, et al R. Allograft rejection after penetrating keratoplasty for keratoconus. *Ophthalmic Surg*. 1993;24(1):40-3
129. Goble RR, Hardman Lea SJ, Falcon MG. The use of the same size host and donor trephine in penetrating keratoplasty for keratoconus. *Eye (Lond)*. 1994;8(Pt 3):311-4
130. Goldich Y, Barkana Y, Wussuku Lior O, et al. Corneal collagen cross-linking for the treatment of progressive keratoconus: 3-year prospective outcome. *Can J Ophthalmol*. 2014;49(1):54-9
131. Goldich Y, Marcovich AL, Barkana Y, et al. Safety of corneal collagen cross-linking with UV-A and riboflavin in progressive keratoconus. *Cornea*. 2010;29(4):409-11
132. Greenlee EC, Kwon YH. Graft failure: III. Glaucoma escalation after penetrating keratoplasty. *Int Ophthalmol*. 2008;28(3):191-207
133. Greenstein SA, Fry KL, Bhatt J, Hersh PS. Natural history of corneal haze after collagen crosslinking for keratoconus and corneal ectasia: Scheimpflug and biomicroscopic analysis. *J Cataract Refract Surg*. 2010;36(12):2105-14
134. Greenstein SA, Fry KL, Hersh PS. Effect of topographic cone location on outcomes of corneal collagen cross-linking for keratoconus and corneal ectasia. *J Refract Surg*. 2012;28(6):397-405
135. Greenstein, SA, Hersh PS.Characteristics influencing outcomes of corneal collagen crosslinking for keratoconus and ectasia: implications for patient selection. *J Cataract Refract Surg* 2013;39(8): 1133-40
136. Grewal DS, Brar GS, Jain R, et al. Corneal collagen crosslinking using riboflavin and ultraviolet-A light for keratoconus: one-year analysis using Scheimpflug imaging. *J Cataract Refract Surg*. 2009; 35(3):425-32
137. Gripp KW, Demmer LA. Keratoconus in Costello syndrome. *Am J Med Genet A*. 2013;161A(5): 1132-6
138. Güell JL, Verdaguer P, Elies D, et al. Acute corneal hydrops after intrastromal corneal ring segment implantation for keratoconus. *J Cataract Refract Surg*. 2012;38(12):2192-5
139. Gumus K. Acute idiopathic endotheliitis early after corneal cross-linking with riboflavin and ultraviolet-A. *Cornea*. 2014;33(6):630-3
140. Gunes A, Tok L, Tok O, Seyrek L. The youngest patient with bilateral keratoconus eecondary to chronic persistent eye rubbing. *Semin Ophthalmol*. 2014 Feb 7. [Epub ahead of print]
141. Haddad W, Fadlallah A, Dirani A, et al. Comparison of 2 types of intrastromal corneal ring segments for keratoconus. *J Cataract Refract Surg*. 2012;38(7):1214-21
142. Hafezi F, Mrochen M, Iseli HP, Seiler T. Collagen crosslinking with ultraviolet-A and hypoosmolar riboflavin solution in thin corneas. *J Cataract Refract Surg*. 2009;35(4):621-4
143. Hafezi F. Limitation of collagen cross-linking with hypoosmolar riboflavin solution: failure in an extremely thin cornea. *Cornea*. 2011;30(8):917-9
144. Han DC, Mehta JS, Por YM, et al. Comparison of outcomes of lamellar keratoplasty and penetrating keratoplasty in keratoconus. *Am J Ophthalmol*. 2009;148(5):744-51
145. Harding SA, Nischal KK, Upponi-Patil A, Fowler DJ. Indications and outcomes of deep anterior lamellar keratoplasty in children. *Ophthalmology*. 2010;117(11):2191-5
146. Hashemi H, Ghaffari R, Mohammadi M, et al. Microbial keratitis after INTACS implantation with loose suture. *J Refract Surg*. 2008;24(5):551-2
147. Hashemi H, Yazdani-Abyaneh A, Beheshtnejad A, et al. Efficacy of intacs intrastromal corneal ring segment relative to depth of insertion evaluated with anterior segment optical coherence tomography. *Middle East Afr J Ophthalmol*. 2013;20(3):234-8

148. Haugen OH, Høvdning G, Eide GE, Bertelsen T. Corneal grafting for keratoconus in mentally retarded patients. *Acta Ophthalmol Scand.* 2001;79(6):609-15
149. Hayes S, Young R, Boote C, et al. A structural investigation of corneal graft failure in suspected recurrent keratoconus. *Eye (Lond).* 2010;24(4):728-34
150. Heidemann DG, Sugar A, Meyer RF, Musch DC. Oversized donor grafts in penetrating keratoplasty. A randomized trial. *Arch Ophthalmol.* 1985;103(12):1807-11
151. Hladun L, Harris M. Contact lens fitting over intrastromal corneal rings in a keratoconic patient. *Optometry.* 2004;75(1):48-54
152. Hofling-Lima AL, Branco BC, Romano AC, et al. Corneal infections after implantation of intracorneal ring segments. *Cornea.* 2004;23(6):547-9
153. Holopainen JM, Krootila K. Transient corneal thinning in eyes undergoing corneal cross-linking. *Am J Ophthalmol.* 2011;152(4):533-6
154. Huber KK, Maier AK, Klamann MK, et al. Glaucoma in penetrating keratoplasty: risk factors, management and outcome. *Graefes Arch Clin Exp Ophthalmol.* 2013;251(1):105-16
155. Ibáñez-Alperte J, Pérez-García D, Cristóbal JA, et al. Keratitis after implantation of intrastromal corneal rings with spontaneous extrusion of the segment. *Case Rep Ophthalmol.* 2010;1(2):42-6
156. Ishii R, Kamiya K, Igarashi A, et al. Correlation of corneal elevation with severity of keratoconus by means of anterior and posterior topographic analysis. *Cornea.* 2012;31(3):253-8
157. Ivarsen A, Hjortdal J. Collagen cross-linking for advanced progressive keratoconus. *Cornea.* 2013;32(7):903-6
158. Jabbarvand M, Mohammadpour M. Deep lamellar keratoplasty in keratoconus with healed hydrops. *Cornea.* 2008;27(9):1100;author reply 1100
159. Jabbarvand M, Salamatrad A, Hashemian H, Khodaparast M. Continuous corneal intrastromal ring implantation for treatment of keratoconus in an Iranian population. *Am J Ophthalmol.* 2013;155(5):837-42
160. Jabbarvand M, Salamatrad A, Hashemian H, et al. Continuous intracorneal ring implantation for keratoconus using a femtosecond laser. *J Cataract Refract Surg.* 2013;39(7):1081-7
161. Javadi MA, Motlagh BF, Jafarinasab MR, et al. Outcomes of penetrating keratoplasty in keratoconus. *Cornea.* 2005;24(8):941-6
162. Jaycock PD, Jones MN, Males J, et al. UK Transplant Ocular Tissue Advisory Group and Contributing Ophthalmologists. Outcomes of same-sizing versus oversizing donor trephines in keratoconic patients undergoing first penetrating keratoplasty. *Ophthalmology.* 2008;115(2):268-75
163. Jeganathan SV, Ghosh S, Jhanji V, et al. Resuturing following penetrating keratoplasty: a retrospective analysis. *Br J Ophthalmol.* 2008;92(7):893-5
164. Jensen LB, Hjortdal J, Ehlers N. Longterm follow-up of penetrating keratoplasty for keratoconus. *Acta Ophthalmol.* 2010;88(3):347-51
165. Jiménez-Alfaro I, Pérez-Santonja JJ, Gómez Tellería G, et al. Therapeutic lamellar keratoplasty with an automated microkeratome. *J Cataract Refract Surg.* 2001;27(8):1161-5
166. Jones MN, Armitage WJ, Ayliffe W, et al. Penetrating and deep anterior lamellar keratoplasty for keratoconus: a comparison of graft outcomes in the United kingdom. *Invest Ophthalmol Vis Sci.* 2009;50(12):5625-9
167. Kandarakis A, Karampelas M, Soumplis V, et al. A case of bilateral self-induced keratoconus in a patient with tourette syndrome associated with compulsive eye rubbing: case report. *BMC Ophthalmol.* 2011;11:28

168. Kanellopoulos AJ, Asimellis G. Epithelial remodeling after partial topography-guided normalization and high-fluence short-duration crosslinking (Athens protocol): Results up to 1 year. *J Cataract Refract Surg.* 2014;40(10):1597-602
169. Kanellopoulos AJ, Pe LH, Perry HD, Donnenfeld ED. Modified intracorneal ring segment implantations (INTACS) for the management of moderate to advanced keratoconus: efficacy and complications. *Cornea.* 2006;25(1):29-33
170. Kanellopoulos AJ, Asimellis G. Revisiting keratoconus diagnosis and progression classification based on evaluation of corneal asymmetry indices, derived from Scheimpflug imaging in keratoconic and suspect cases. *Clin Ophthalmol.* 2013;7:1539-1548
171. Kankariya VP, Kymionis GD, Diakonis VF, Yoo SH. Management of pediatric keratoconus - evolving role of corneal collagen cross-linking: an update. *Indian J Ophthalmol.* 2013;61(8):435-40
172. Kato N, Toda I, Kawakita T, et al. Topography-guided conductive keratoplasty: treatment for advanced keratoconus. *Am J Ophthalmol.* 2010;150(4):481-9
173. Kaushal S, Jhanji V, Sharma N, et al. "Tuck in" lamellar keratoplasty (TILK) for corneal ectasias involving corneal periphery. *Br J Ophthalmol.* 2008;92:286-90
174. Kaya V, Utine CA, Yilmaz OF. Efficacy of corneal collagen cross-linking using a custom epithelial debridement technique in thin corneas: a confocal microscopy study. *J Refract Surg* 2011;27(6): 444-50
175. Kaya V, Utine CA, Yilmaz ÖF. Intraoperative corneal thickness measurements during corneal collagen cross-linking with hypoosmolar riboflavin solution in thin corneas. *Cornea.* 2012;31(5): 486-90
176. Keane M, Coster D, Ziaei M, Williams K. Deep anterior lamellar keratoplasty versus penetrating keratoplasty for treating keratoconus. *Cochrane Database Syst Rev.* 2014;7:CD009700
177. Kelly TL, Coster DJ, Williams KA. Repeat penetrating corneal transplantation in patients with keratoconus. *Ophthalmology.* 2011;118(8):1538-42
178. Khairy HA, Marey HM, Ellakwa AF. Epithelium-on corneal cross-linking treatment of progressive keratoconus: a prospective, consecutive study. *Clin Ophthalmol.* 2014;8:19-23
179. Khan MD, Kundi N, Saeed N, et al. Incidence of keratoconus in spring catarrh. *Br J Ophthalmol.* 1988;72(1):41-3
180. Khan MI, Injarie A, Muhtaseb M. Intrastromal corneal ring segments for advanced keratoconus and cases with high keratometric asymmetry. *J Cataract Refract Surg.* 2012;38(1):129-36
181. Kim KH, Choi SH, Ahn K, et al. Comparison of refractive changes after deep anterior lamellar keratoplasty and penetrating keratoplasty for keratoconus. *Jpn J Ophthalmol.* 2011;55(2):93-7
182. Kim MH, Chung TY, Chung ES. A retrospective contralateral study comparing deep anterior lamellar keratoplasty with penetrating keratoplasty. *Cornea.* 2013;32(4):385-9
183. Kirkness CM, Ficker LA, Steele AD, Rice NS. Refractive surgery for graft-induced astigmatism after penetrating keratoplasty for keratoconus. *Ophthalmology.* 1991;98(12):1786-92
184. Kocak I, Aydin A, Kaya F, Koc H. Comparison of transepithelial corneal collagen crosslinking with epithelium-off crosslinking in progressive keratoconus. *J Fr Ophtalmol.* 2014;37(5):371-6
185. Koh S, Maeda N, Nakagawa T, et al. Characteristic higher-order aberrations of the anterior and posterior corneal surfaces in 3 corneal transplantation techniques. *Am J Ophthalmol.* 2012; 153(2):284-90
186. Koller B, Neuhann TF, Neuhann IM. Keratoplasty in patients with intellectual disability. *Cornea.* 2014;33(1):10-3
187. Koller T, Mrochen M, Seiler T. Complication and failure rates after corneal crosslinking. *J Cataract Refract Surg.* 2009;35(8):1358-62

188. Koppen C, Leysen I, Tassignon MJ. Riboflavin/UVA cross-linking for keratoconus in Down syndrome. *J Refract Surg.* 2010;26(9):623-4
189. Kotb AM, Hantera M. Efficacy and safety of Intacs SK in moderate to severe keratoconus. *Middle East Afr J Ophthalmol.* 2013;20(1):46-50
190. Krachmer JH, Feder RS, Belin MW. Keratoconus and related noninflammatory corneal thinning disorders. *Surv Ophthalmol.* 1984; 28(4):293-322
191. Krivoy D, McCormick S, Zaidman GW. Postkeratoplasty keratoconus in a nonkeratoconus patient. *Am J Ophthalmol.* 2001;131(5):653-4
192. Krumeich JH, Brand-Saberi B, Chankiewitz V, et al. Induction of neoplasia after deep anterior lamellar keratoplasty in a CXL-treated cornea. *Cornea.* 2014;33(3):313-6
193. Krumeich JH, Daniel J. Perforating keratoplasty with an intracorneal ring. *Cornea.* 1999;18(3): 277-81
194. Krumeich JH, Duncker G. Intrastromal corneal ring in penetrating keratoplasty: evidence-based update 4 years after implantation. *J Cataract Refract Surg.* 2006;32(6):993-8
195. Kubaloglu A, Cinar Y, Sari ES, et al. Comparison of 2 intrastromal corneal ring segment models in the management of keratoconus. *J Cataract Refract Surg.* 2010;36(6):978-85
196. Kwitko S, Severo NS. Ferrara intracorneal ring segments for keratoconus. *J Cataract Refract Surg.* 2004;30(4):812-20
197. Kymionis GD, Grentzelos MA, Diakonis VF, et al. Nine-year follow-up of intacs implantation for keratoconus. *Open Ophthalmol J.* 2009;3:77-81
198. Kymionis GD, Kounis GA, Portaliou DM. Intraoperative pachymetric measurements during corneal collagen cross-linking with riboflavin and ultraviolet A irradiation. *Ophthalmology.* 2009; 116(12): 2336-9
199. Kymionis GD, Siganos CS, Tsiklis NS, et al. Long-term follow-up of Intacs in keratoconus. *Am J Ophthalmol.* 2007;143(2):236-44
200. Lai MM, Tang M, Andrade EM, et al. Optical coherence tomography to assess intrastromal corneal ring segment depth in keratoconic eyes. *J Cataract Refract Surg.* 2006;32(11):1860-5
201. Laing RA, Sandstrom MM, Berrospi AR, Leibowitz HM. The human corneal endothelium in keratoconus: A specular microscopic study. *Arch Ophthalmol.* 1979;97(10):1867-9
202. Lake D, Hamada S, Khan S, Daya SM. Deep anterior lamellar keratoplasty over penetrating keratoplasty for host rim thinning and ectasia. *Cornea.* 2009;28(5):489-92
203. Langenbucher A, Naumann GO, Seitz B. Spontaneous long-term changes of corneal power and astigmatism after suture removal after penetrating keratoplasty using a regression model. *Am J Ophthalmol.* 2005;140(1):29-34
204. Leccisotti A. Descemet's membrane perforation during deep anterior lamellar keratoplasty: prognosis. *J Cataract Refract Surg.* 2007;33(5):825-9
205. Legare ME, Iovieno A, Yeung SN, et al. Intacs with or without same-day corneal collagen cross-linking to treat corneal ectasia. *Can J Ophthalmol.* 2013;48(3):173-8
206. Lema I, Durán JA, Ruiz C, et al. Inflammatory response to contact lenses in patients with keratoconus compared with myopic subjects. *Cornea.* 2008;27(7):758-63
207. Lema I, Durán JA. Inflammatory molecules in the tears of patients with keratoconus. *Ophthalmology.* 2005;112(4):654-9
208. Lema I, Sobrino T, Durán JA, et al. Subclinical keratoconus and inflammatory molecules from tears. *Br J Ophthalmol.* 2009;93(6):820-4
209. Léoni-Mesplé S, Mortemousque B, Touboul D, et al. Scalability and severity of keratoconus in children. *Am J Ophthalmol.* 2012;154(1):56-62

210. Levinger S, Pokroy R. Keratoconus managed with intacs: one-year results. *Arch Ophthalmol*. 2005; 123(10):1308-14
211. Lie J, Droutsas K, Ham L, et al. Isolated Bowman layer transplantation to manage persistent sub-epithelial haze after excimer laser surface ablation. *J Cataract Refract Surg*. 2010;36(6):1036-41
212. Lim L, Pesudovs K, Coster DJ. Penetrating keratoplasty for keratoconus: visual outcome and success. *Ophthalmology*. 2000;107(6):1125-31
213. Lim L, Pesudovs K, Goggin M, Coster DJ. Late onset post-keratoplasty astigmatism in patients with keratoconus. *Br J Ophthalmol*. 2004;88(3):371-6
214. Limaieim R, Chebil A, Baba A, et al. Pediatric penetrating keratoplasty: indications and outcomes. *Transplant Proc*. 2011;43(2):649-51
215. Lowe MT, Keane MC, Coster DJ, Williams KA. The outcome of corneal transplantation in infants, children, and adolescents. *Ophthalmology*. 2011;118(3):492-7
216. Luengo-Gimeno F, Tan DT, Mehta JS. Evolution of deep anterior lamellar keratoplasty (DALK). *Ocul Surf*. 2011;9(2):98-110
217. MacIntyre R, Chow SP, Chan E, Poon A. Long-term outcomes of deep anterior lamellar keratoplasty versus penetrating keratoplasty in Australian keratoconus patients. *Cornea*. 2014;33(1):6-9
218. Mader TH, Yuan R, Lynn MJ, et al. Changes in keratometric astigmatism after suture removal more than one year after penetrating keratoplasty. *Ophthalmology*. 1993;100(1):119-26; discussion 127
219. Magli A, Forte R, Tortori A, et al. Epithelium-off corneal collagen cross-linking versus transepithelial cross-linking for pediatric keratoconus. *Cornea*. 2013;32(5):597-601
220. Maharana PK, Sharma N, Vajpayee RB. Acute corneal hydrops in keratoconus. *Indian J Ophthalmol*. 2013;61(8):461-4
221. Malbran ES, Fernández-Meijide RE. Bilateral versus unilateral penetrating graft in keratoconus. *Ophthalmology*. 1982;89(1):38-40
222. Mannis MJ, Morrison TL, Zadnik K, et al. Personality trends in keratoconus. An analysis. *Arch Ophthalmol*. 1987;105(6):798-800
223. Martin TP, Reed JW, Legault C, et al. Cataract formation and cataract extraction after penetrating keratoplasty. *Ophthalmology*. 1994;101(1):113-9
224. Mashor RS, Kumar NL, Ritenour RJ, Rootman DS. Keratoconus caused by eye rubbing in patients with Tourette Syndrome. *Can J Ophthalmol*. 2011;46(1):83-6
225. Mashor RS, Rootman DB, Bahar I, et al. Outcomes of deep anterior lamellar keratoplasty versus intralase enabled penetrating keratoplasty in keratoconus. *Can J Ophthalmol*. 2011;46(5):403-7
226. Mathers WD, Gold JB, Kattan H, Lemp MA. Corneal steepening with final suture removal after penetrating keratoplasty. *Cornea*. 1991;10(3):221-3
227. Maurice DM, Zauberman H, Michaelson IC. The stimulus to neovascularization in the cornea. *Exp Eye Res*. 1966;5(3):168-84
228. Mazzotta C, Balestrazzi A, Baiocchi S, et al. Stromal haze after combined riboflavin-UVA corneal collagen cross-linking in keratoconus: in vivo confocal microscopic evaluation. *Clin Experiment Ophthalmol*. 2007;35(6):580-2
229. Mazzotta C, Caragiuli S. Intraoperative corneal thickness measurement by optical coherence tomography in keratoconic patients undergoing corneal collagen cross-linking. *Am J Ophthalmol*. 2014;157(6):1156-62
230. Mazzotta C, Traversi C, Baiocchi S, et al. Corneal healing after riboflavin ultraviolet-A collagen cross-linking determined by confocal laser scanning microscopy in vivo: early and late modifications. *Am J Ophthalmol*. 2008;146(4):527-33

231. McClellan K, Lai T, Grigg J, Billson F. Penetrating keratoplasty in children: visual and graft outcome. *Br J Ophthalmol*. 2003;87(10):1212-4
232. McElvanney AM, Adhikary HP. Penetrating keratoplasty in the mentally retarded. *Eye (Lond)*. 1997;11(Pt 6):786-9
233. McMahon TT, Szczołka-Flynn L., Barr JT, et al. A New Method for Grading the Severity of Keratoconus The Keratoconus Severity Score (KSS). *Cornea*. 2006;25(7):794-800
234. McMonnies CW. Corneal endothelial assessment with special references to keratoconus. *Optom Vis Sci*. 2014;91(6):e124-34
235. Medical Advisory Secretariat. Intrastromal corneal ring implants for corneal thinning disorders: an evidence-based analysis. Ontario Health Technology Assessment Series 2009;9(1)
236. Melles GR, Remeijer L, Geerards AJ, Beekhuis WH. A quick surgical technique for deep, anterior lamellar keratoplasty using visco-dissection. *Cornea*. 2000;19(4):427-32
237. Melles GR, Rietveld FJ, Beekhuis WH, Binder PS. A technique to visualize corneal incision and lamellar dissection depth during surgery. *Cornea*. 1999;18(1):80-6
238. Melles GRJ, Lander F, Rietveld FJR, et al. A new surgical technique for deep, anterior lamellar keratoplasty. *Br J Ophthalmol*. 1999;83:327-33
239. Michieletto P, Balestrazzi A, Balestrazzi A, et al. Factors predicting unsuccessful big bubble deep lamellar anterior keratoplasty. *Ophthalmologica*. 2006;220(6):379-82
240. Mitchell BM, Kanellopoulos AJ, Font RL. Post intrastromal corneal ring segments insertion complicated by *Candida parapsilosis* keratitis. *Clin Ophthalmol*. 2013;7:443-8
241. Mohamed SR, Manna A, Amisshah-Arthur K, McDonnell PJ. Non-resolving Descemet folds 2 years following deep anterior lamellar keratoplasty: the impact on visual outcome. *Cont Lens Anterior Eye*. 2009;32(6):300-2
242. Moon JW, Shin KC, Lee HJ, et al. The effect of contact lens wear on the ocular surface changes in keratoconus. *Eye Contact Lens*. 2006;32(2):96-101
243. Moore JE, Atkinson SD, Azar DT, et al. Protection of corneal epithelial stem cells prevents ultraviolet A damage during corneal collagen cross-linking treatment for keratoconus. *Br J Ophthalmol*. 2014;98(2):270-4
244. Moreira LB, Bardal RA, Crisigiovanni LR. Contact lenses fitting after intracorneal ring segments implantation in keratoconus. *Arq Bras Oftalmol*. 2013;76(4):215-7
245. Mulet ME, Pérez-Santonja JJ, Ferrer C, Alió JL. Microbial keratitis after intrastromal corneal ring segment implantation. *J Refract Surg*. 2010;26(5):364-9
246. Müller LJ, Pels E, Vrensen GF. The effects of organ-culture on the density of keratocytes and collagen fibers in human corneas. *Cornea*. 2001;20(1):86-95
247. Musa FU, Patil S, Rafiq O, et al. Long-term risk of intraocular pressure elevation and glaucoma escalation after deep anterior lamellar keratoplasty. *Clin Experiment Ophthalmol*. 2012;40(8):780-5
248. Musch DC, Meyer RF, Sugar A. The effect of removing running sutures on astigmatism after penetrating keratoplasty *Arch Ophthalmol*. 1988;106(4):488-92
249. Naftali M, Jabaly-Habib H. Depth of intrastromal corneal ring segments by OCT. *Eur J Ophthalmol*. 2013;23(2):171-6
250. Nagra PK, Rapuano CJ, Laibson PL, et al. Cataract extraction following penetrating keratoplasty. *Cornea*. 2004;23(4):377-9
251. Nanavaty MA, Daya SM. Outcomes of deep anterior lamellar keratoplasty in keratoconic eyes with previous hydrops. *Br J Ophthalmol*. 2012;96(10):1304-9

252. Nepomuceno RL, Boxer Wachler BS, Weissman BA. Feasibility of contact lens fitting on keratoconus patients with INTACS inserts. *Cont Lens Anterior Eye*. 2003;26(4):175-80
253. Nirankari VS, Karesh J, Bastion F, et al. Recurrence of keratoconus in donor cornea 22 years after successful keratoplasty. *Br J Ophthalmol*. 1983;67(1):23-8
254. Niziol LM, Musch DC, Gillespie BW, et al. Long-term outcomes in patients who received a corneal graft for keratoconus between 1980 and 1986. *Am J Ophthalmol*. 2013;155(2):213-9
255. Noble BA, Ball JL. Late onset post-keratoplasty astigmatism in patients with keratoconus. *Br J Ophthalmol*. 2004;88(3):317
256. Olson RJ, Pingree M, Ridges R, et al. Penetrating keratoplasty for keratoconus: a long-term review of results and complications. *J Cataract Refract Surg*. 2000;26(7):987-91
257. Oral D, Kaya V. Topography-guided conductive keratoplasty for keratoconus. *Am J Ophthalmol*. 2011;151(6):1102-3;author reply 1103
258. Ortenberg I, Behrman S, Geraisy W, Barequet IS. Wearing time as a measure of success of scleral lenses for patients with irregular astigmatism. *Eye Contact Lens*. 2013;39(6):381-4
259. Ozertürk Y, Sari ES, Kubaloglu A, et al. Comparison of deep anterior lamellar keratoplasty and intrastromal corneal ring segment implantation in advanced keratoconus. *J Cataract Refract Surg*. 2012;38(2):324-32
260. Panahi-Bazaz MR, Sharifpour F, Moghaddasi A. Bilateral keratoconus and corneal hydrops associated with eye rubbing in a 7-year-old girl. *J Ophthalmic Vis Res*. 2014;9(1):101-5
261. Park S, Ramamurthi S, Ramaesh K. Late dislocation of intrastromal corneal ring segment into the anterior chamber. *J Cataract Refract Surg*. 2010;36(11):2003-5
262. Parthasarathy A, Por YM, Tan DT. Use of a "small-bubble technique" to increase the success of Anwar's "big-bubble technique" for deep lamellar keratoplasty with complete baring of Descemet's membrane. *Br J Ophthalmol*. 2007;91(10):1369-73
263. Patel N, Mearza A, Rostron CK, Chow J. Corneal ectasia following deep lamellar keratoplasty. *Br J Ophthalmol*. 2003;87(6):799-800
264. Patel SV, Malta JB, Banitt MR, et al. Recurrent ectasia in corneal grafts and outcomes of repeat keratoplasty for keratoconus. *Br J Ophthalmol*. 2009;93(2):191-7
265. Pérez-Santonja JJ, Artola A, Javaloy J, et al. Microbial keratitis after corneal collagen crosslinking. *J Cataract Refract Surg*. 2009;35(6):1138-40
266. Piñero DP, Alio JL, El Kady B, et al. Refractive and aberrometric outcomes of intracorneal ring segments for keratoconus: mechanical versus femtosecond-assisted procedures. *Ophthalmology*. 2009;116(9):1675-87
267. Piñero DP, Alio JL, Klonowski P, Toffaha B. Vectorial astigmatic changes after corneal collagen crosslinking in keratoconic corneas previously treated with intracorneal ring segments: a preliminary study. *Eur J Ophthalmol*. 2012;22(Suppl 7):S69-80
268. Piñero DP, Alio JL. Intracorneal ring segments in ectatic corneal disease - a review. *Clin Experiment Ophthalmol*. 2010;38(2):154-67
269. Pinsard L, Touboul D, Vu Y, et al. Keratoconus associated with Williams-Beuren syndrome: first case reports. *Ophthalmic Genet*. 2010;31(4):252-6
270. Pollhammer M, Cursiefen C. Bacterial keratitis early after corneal crosslinking with riboflavin and ultraviolet-A. *J Cataract Refract Surg*. 2009;35(3):588-9
271. Pramanik S, Musch DC, Sutphin JE, Farjo AA. Extended long-term outcomes of penetrating keratoplasty for keratoconus. *Ophthalmology*. 2006;113(9):1633-8
272. Price FW Jr, Whitson WE, Marks RG. Progression of visual acuity after penetrating keratoplasty. *Ophthalmology*. 1991;98(8):1177-85

273. Pron G, Ieraci I, Kaulback K, Medical Advisory Secretariat (Health Quality Ontario). Collagen crosslinking using riboflavin and ultraviolet-A for corneal thinning disorders: an evidence-based analysis. *Ont Health Technol Assess Ser.* 2011;11(5):1-89
274. Rabinowitz YS. Intacs for keratoconus. *Curr Opin Ophthalmol.* 2007;18(4):279-83
275. Rabinowitz YS. Keratoconus. *Surv Ophthalmol.* 1998 42(4):23
276. Raecker ME, Erie JC, Patel SV, et al. Long-term keratometric changes after penetrating keratoplasty for keratoconus and Fuchs endothelial dystrophy. *Am J Ophthalmol.* 2009;147(2):227-33
277. Rahi A, Davies P, Ruben M, et al. Keratoconus and coexisting atopic disease. *Br J Ophthalmol.* 1977;61(12):761-4
278. Raiskup F, Spoerl E. Corneal cross-linking with hypo-osmolar riboflavin solution in thin keratoconic corneas. *Am J Ophthalmol.* 2011;152(1):28-32
279. Ramamurthi S, Ramaesh K. Surgical management of healed hydrops: a novel modification of deep anterior lamellar keratoplasty. *Cornea.* 2011;30(2):180-3
280. Reddy JC, Hammersmith K., Nagra PK, Rapuano CJ. The role of penetrating keratoplasty in the era of selective lamellar keratoplasty. *Int Ophthalmol Clin.* 2013;53(2):12
281. Regis-Pacheco LF, Binder PS. What happens to the corneal transplant endothelium after penetrating keratoplasty? *Cornea.* 2014;33(6):587-96
282. Richoz O, Schutz JS, Pajic B, et al. Crosslinking for recurrent keratoconus. *Ophthalmology.* 2012; 119(4):878
283. Rodríguez LA, Guillén PB, Benavides MA, et al. Penetrating keratoplasty versus intrastromal corneal ring segments to correct bilateral corneal ectasia: preliminary study. *J Cataract Refract Surg.* 2007;33(3):488-96
284. Rowson NJ, Dart JK, Buckley RJ. Corneal neovascularisation in acute hydrops. *Eye (Lond).* 1992;6 (Pt 4):404-6
285. Ruckhofer J, Böhne M, Alzner E, Grabner G. Confocal microscopy after implantation of intrastromal corneal ring segments. *Ophthalmology.* 2000;107(12):2144-51
286. Sahebjada S, Fenwick EK, Xie J, et al. Impact of keratoconus in the better eye and the worse eye on vision-related quality of life. *Invest Ophthalmol Vis Sci.* 2014;21;55(1):412-6
287. Salman, AG. Transepithelial corneal collagen crosslinking for progressive keratoconus in a pediatric age group. *J Cataract Refract Surg.* 2013;39(8):1164-70
288. Salouti R, Masoumpour M, Nowroozadeh MH, et al. Changes in corneal endothelial cell profile measurements after deep anterior lamellar keratoplasty for keratoconus. *Cornea.* 2013;32(6): 751-6
289. Salvetat ML, Brusini P, Pedrotti E, et al. Higher order aberrations after keratoplasty for keratoconus. *Optom Vis Sci.* 2013;90(3):293-301
290. Sansanayudh W, Bahar I, Kumar NL, et al. Intrastromal corneal ring segment SK implantation for moderate to severe keratoconus. *J Cataract Refract Surg.* 2010;36(1):110-3
291. Schmidinger G, Pachala M, Prager F. Pachymetry changes during corneal crosslinking: effect of closed eyelids and hypotonic riboflavin solution. *J Cataract Refract Surg.* 2013;39(8):1179-83
292. Sehra SV, Titiyal JS, Sharma N, et al. Change in corneal microstructure with rigid gas permeable contact lens use following collagen cross-linking: an in vivo confocal microscopy study. *Br J Ophthalmol.* 2014;98(4):442-7
293. Seitz B, Langenbucher A, Szentmary N, Naumann GO. Corneal curvature after penetrating keratoplasty before and after suture removal: a comparison between keratoconus and Fuchs' dystrophy. *Ophthalmologica.* 2006;220(5):302-6

294. Severinsky B, Behrman S, Frucht-Pery J, Solomon A. Scleral contact lenses for visual rehabilitation after penetrating keratoplasty: long term outcomes. *Cont Lens Anterior Eye*. 2014;37(3):196-202
295. Severinsky B, Wajnsztajn D, Frucht-Pery J. Silicone hydrogel mini-scleral contact lenses in early stage after corneal collagen cross-linking for keratoconus: a retrospective case series. *Clin Exp Optom*. 2013;96(6):542-6
296. Shabayek MH, Alió JL. Intrastromal corneal ring segment implantation by femtosecond laser for keratoconus correction. *Ophthalmology*. 2007;114(9):1643-52
297. Sharif KW, Casey TA. Penetrating keratoplasty for keratoconus: complications and long-term success. *Br J Ophthalmol*. 1991;75(3):142-6
298. Sharma A, Mirchia K, Mohan K, et al. Persistent corneal edema after collagen cross-linking for keratoconus. *Am J Ophthalmol*. 2012;154(6):922-6
299. Sharma N, Kandar AK, Singh Titiyal J. Stromal rejection after big bubble deep anterior lamellar keratoplasty: case series and review of literature. *Eye Contact Lens*. 2013;39(2):194-8
300. Shetty R, Kurian M, Anand D, et al. Intacs in advanced keratoconus. *Cornea*. 2008;27(9):1022-9
301. Shi W, Li S, Gao H, et al. Modified deep lamellar keratoplasty for the treatment of advanced-stage keratoconus with steep curvature. *Ophthalmology*. 2010; 117(2):226-31
302. Shimazaki J1, Shimmura S, Ishioka M, Tsubota K. Randomized clinical trial of deep lamellar keratoplasty vs penetrating keratoplasty. *Am J Ophthalmol*. 2002;134(2):159-65
303. Siganos D, Ferrara P, Chatzinikolas K, et al. Ferrara intrastromal corneal rings for the correction of keratoconus. *J Cataract Refract Surg*. 2002;28(11):1947-51
304. Silbiger JS, Cohen EJ, Laibson PR. The rate of visual recovery after penetrating keratoplasty for keratoconus. *CLAO J*. 1996;22(4):266-9
305. Sloot F, Soeters N, van der Valk R, Tahzib NG. Effective corneal collagen crosslinking in advanced cases of progressive keratoconus. *J Cataract Refract Surg*. 2013;39(8):1141-5
306. Smadja D, Colin J, Krueger RR, et al. Outcomes of deep anterior lamellar keratoplasty for keratoconus: learning curve and advantages of the big bubble technique. *Cornea*. 2012;31(8):859-63
307. Smiddy WE, Hamburg TR, Kracher GP, Stark WJ. Keratoconus. Contact lens or keratoplasty? *Ophthalmology*. 1988;95(4):487-92
308. Soeters N, van Bussel E, van der Valk R, et al. Effect of the eyelid speculum on pachymetry during corneal collagen crosslinking in keratoconus patients. *J Cataract Refract Surg*. 2014;40(4):575-81
309. Soeters N, van der Valk R, Tahzib NG. Corneal cross-linking for treatment of progressive keratoconus in various age groups. *J Refract Surg*. 2014;30(7):454-60
310. Sorkin N, Varssano D. Corneal collagen crosslinking: a systematic review. *Ophthalmologica*. 2014; 232(1):10-27
311. Spadea L, Giammaria D, Fiasca A, Verrecchia V. Excimer laser-assisted lamellar keratoplasty for the surgical treatment of keratoconus. *J Cataract Refract Surg*. 2009;35(1):105-12
312. Spadea L, Gizzi R, Evangelista Conocchia N, Urbano S. Optical pachymetry-guided custom excimer laser-assisted lamellar keratoplasty for the surgical treatment of keratoconus. *J Cataract Refract Surg*. 2012;38(9):1559-67
313. Spadea L, Salvatore S, Vingolo EM. Corneal sensitivity in keratoconus: a review of the literature. *ScientificWorldJournal*. 2013:683090
314. Spadea L, Mencucci R. Transepithelial corneal collagen cross-linking in ultrathin keratoconic corneas. *Clin Ophthalmol*. 2012;6:1785-92
315. Speaker MG, Arentsen JJ, Laibson PR. Long-term survival of large diameter penetrating keratoplasties for keratoconus and pellucid marginal degeneration. *Acta Ophthalmol Suppl*. 1989;192: 17-9

316. Spitznas M, Eckert J, Frising M, Eter N. Long-term functional and topographic results seven years after epikeratophakia for keratoconus. *Graefes Arch Clin Exp Ophthalmol.* 2002;240(8):639-43
317. Sturbaum CW, Peiffer RL Jr. Pathology of corneal endothelium in keratoconus. *Ophthalmologica.* 1993;206:192-208
318. Sugita J, Kondo J. Deep lamellar keratoplasty with complete removal of pathological stroma for vision improvement. *Br J Ophthalmol.* 1997;81:184-8
319. Sutton G, Hodge C, McGhee CN. Rapid visual recovery after penetrating keratoplasty for keratoconus. *Clin Experiment Ophthalmol.* 2008;36(8):725-30
320. Tan DT, Anshu A, Parthasarathy A, Htoon HM. Visual acuity outcomes after deep anterior lamellar keratoplasty: a case-control study. *Br J Ophthalmol.* 2010;94(10):1295-9
321. Thomas JK, Guel DA, Thomas TS, Cavanagh HD. The role of atopy in corneal graft survival in keratoconus. *Cornea.* 2011;30(10):1088-97
322. Thompson RW Jr, Price MO, Bowers PJ, Price FW Jr. Long-term graft survival after penetrating keratoplasty. *Ophthalmology.* 2003;110(7):1396-402
323. Thorsrud A, Nicolaiassen B, Drolsum L. Corneal collagen crosslinking in vitro: inhibited regeneration of human limbal epithelial cells after riboflavin-ultraviolet-A exposure. *J Cataract Refract Surg.* 2012;38(6):1072-6
324. Titiyal JS, Chawla B, Sharma N. Deep anterior lamellar keratoplasty with Intacs explantation in keratoconus. *Eur J Ophthalmol.* 2010;20(5):874-8
325. Tomita M, Mita M, Huseynova T. Accelerated versus conventional corneal collagen crosslinking. *J Cataract Refract Surg.* 2014;40(6):1013-20
326. Toprak I, Yaylali V, Yildirim C. Factors affecting outcomes of corneal collagen crosslinking treatment. *Eye (Lond).* 2014;28(1):41-6
327. Toprak I, Yildirim C. Effects of corneal collagen crosslinking on corneal topographic indices in patients with keratoconus. *Eye Contact Lens.* 2013;39(6):385-7
328. Torquetti L, Ferrara G, Almeida F, et al. Clinical outcomes after intrastromal corneal ring segments reoperation in keratoconus patients. *Int J Ophthalmol.* 2013;6(6):796-800
329. Torquetti L, Ferrara G, Almeida F, et al. Intrastromal corneal ring segments implantation in patients with keratoconus: 10-year follow-up. *J Refract Surg.* 2014;30(1):22-6
330. Tu KL, Sebastian RT, Owen M, et al. Quantification of the surgically induced refractive effect of intrastromal corneal ring segments in keratoconus with standardized incision site and segment size. *J Cataract Refract Surg.* 2011;37(10):1865-70
331. Tuft SJ, Fitzke FW, an S, Frucht-Pery J, Solomon A. Scleral contact lenses for visual rehabilitation after penetrating 1992;76(11):642-5
332. Tuft SJ, Gregory W. Long-term refraction and keratometry after penetrating keratoplasty for keratoconus. *Cornea.* 1995;14(6):614-7
333. Tuft SJ, Moodaley LC, Gregory WM, et al. Prognostic factors for the progression of keratoconus. *Ophthalmology.* 1994;101(3):439-47
334. Uiters E, van den Borne B, van der Horst FG, Völker-Dieben HJ. Patient satisfaction after corneal transplantation. *Cornea.* 2001;20(7):687-94
335. Vabres B, Bosnjakowski M, Bekri L, et al. Deep lamellar keratoplasty versus penetrating keratoplasty for keratoconus. *J Fr Ophtalmol.* 2006;29(4):361-71
336. Vajpayee RB, Jhanji V, Beltz J, Moorthy S. "Tuck in" lamellar keratoplasty for tectonic management of postkeratoplasty corneal ectasia with peripheral corneal involvement. *Cornea.* 2011;30(2):171-4

337. Vajpayee RB, Maharana PK, Sharma N, et al. Diamond knife-assisted deep anterior lamellar keratoplasty to manage keratoconus. *J Cataract Refract Surg.* 2014;40(2):276-82
338. van Dijk K, Liarakos V, Parker J, et al. Bowman layer transplantation to reduce and stabilize progressive, end stage, keratoconus. *Ophthalmology.* 2015:Epub ahead of print
339. van Dijk K, Parker J, Tong CM, et al. Midstromal isolated Bowman layer graft for reduction of advanced keratoconus: a technique to postpone penetrating or deep anterior lamellar keratoplasty. *JAMA Ophthalmol.* 2014;132(4):495-501
340. van Dooren BT, Mulder PG, Nieuwendaal CP, et al. Endothelial cell density after deep anterior lamellar keratoplasty (Melles technique). *Am J Ophthalmol.* 2004;137(3):397-400
341. Vazirani J, Bagga B, Taneja M. Persistent corneal edema after collagen cross-linking for keratoconus. *Am J Ophthalmol.* 2013;155(4):775
342. Vazirani J, Basu S. Keratoconus: current perspectives. *Clin Ophthalmol.* 2013;7:2019-30
343. Vicente LL, Boxer Wachler BS. Factors that correlate with improvement in vision after combined Intacs and trans-epithelial corneal crosslinking. *Br J Ophthalmol.* 2010;94(12):1597-601
344. Vinciguerra P, Camesasca FI, Romano MR. Corneal crosslinking and lens opacity. *Ophthalmology.* 2011;118(12):2519
345. Viswanathan D, Kumar NL, Males JJ. Outcome of corneal collagen crosslinking for progressive keratoconus in paediatric patients. *Biomed Res Int.* 2014;140461
346. Völker-Dieben HJ, Odenthal MT, D'Amaro J, Kruit PJ. Surgical treatment of corneal pathology in patients with Down's syndrome. *J Intellect Disabil Res.* 1993;37(Pt 2):169-75
347. Wagoner MD, Ba-Abbad R; King Khaled Eye Specialist Hospital Cornea Transplant Study Group. Penetrating keratoplasty for keratoconus with or without vernal keratoconjunctivitis. *Cornea.* 2009;28(1):14-8
348. Wicker D, Sanislo S, Green DG. Effect of contact lens correction of sine wave contrast sensitivity in keratoconus patients after penetrating keratoplasty. *Optom Vis Sci.* 1992;69(5):342-6
349. Williams KA, Ash JK, Pararajasegaram P, et al. Long-term outcome after corneal transplantation. Visual result and patient perception of success. *Ophthalmology.* 1991;98(5):651-7
350. Wisse, RP, van den Hoven CM, Van der Lelij A. Does lamellar surgery for keratoconus experience the popularity it deserves? *Acta Ophthalmol.* 2014;92(5):473-7
351. Wittig-Silva C, Chan E, Islam FM, et al. A randomized, controlled trial of corneal collagen cross-linking in progressive keratoconus: three-year results. *Ophthalmology.* 2014;121(4):812-21
352. Wollensak G, Spoerl E, Seiler T. Riboflavin/ultraviolet-aiduced collagen crosslinking for the treatment of keratoconus. *Am J Ophthalmol.* 2003;135(5):620-7
353. Wollensak G, Spoerl E, Wilsch M, Seiler T. Endothelial cell damage after riboflavin-ultraviolet-A treatment in the rabbit. *J Cataract Refract Surg.* 2003;29(9):1786-90
354. Wroblewski KJ, Mader TH, Torres MF, et al. Long-term graft survival in patients with Down syndrome after penetrating keratoplasty. *Cornea.* 2006;25(9):1026-8
355. Yam JC, Cheng AC. Prognostic factors for visual outcomes after crosslinking for keratoconus and post-LASIK ectasia. *Eur J Ophthalmol.* 2013;23(6):799-806
356. Yeniad B, Alparslan N, Akarcay K. Eye rubbing as an apparent cause of recurrent keratoconus. *Cornea.* 2009;28(4):477-9
357. Yeung SN, Lichtinger A, Kim P, et al. Retrospective contralateral study comparing deep anterior lamellar keratoplasty with penetrating keratoplasty: a patient's perspective. *Can J Ophthalmol.* 2012;47(4):360-4

358. Yeung SN, Lichtinger A, Ku JY, et al. Intracorneal ring segment explantation after intracorneal ring segment implantation combined with same-day corneal collagen crosslinking in keratoconus. *Cornea*. 2013;32(12):1617-20
359. Yildiz EH, Erdurmus M, Hammersmith KM, et al. Comparative study of graft rejection in keratoconus patients with and without self-reported atopy. *Cornea*. 2009;28(8):846-50
360. Yildiz EH, Hoskins E, Fram N, et al. Third or greater penetrating keratoplasties: indications, survival, and visual outcomes. *Cornea*. 2010;29(3):254-9
361. Yilmaz S, Ali Ozdil M, Maden A. Factors affecting changes in astigmatism before and after suture removal following penetrating keratoplasty. *Eur J Ophthalmol*. 2007;17(3):301-6
362. Yoo SH, Kymionis GD, Koreishi A, et al. Femtosecond laser-assisted sutureless anterior lamellar keratoplasty. *Ophthalmology*. 2008;115(8):1303-7
363. Zare MA, Hashemi H, Salari MR. Intracorneal ring segment implantation for the management of keratoconus: safety and efficacy. *J Cataract Refract Surg*. 2007;33(11):1886-91
364. Zhang YM, Wu SQ, Yao YF. Long-term comparison of full-bed deep anterior lamellar keratoplasty and penetrating keratoplasty in treating keratoconus. *J Zhejiang Univ Sci B*. 2013;14(5):438-50
365. Zimmerman T, Olson R, Waltman S, Kaufman H. Transplant size and elevated intraocular pressure. *Postkeratoplasty*. *Arch Ophthalmol*. 1978;96(12):2231-3

