



Universiteit  
Leiden  
The Netherlands

## **Recent innovations in minimally invasive anterior and posterior lamellar keratoplasty**

Parker, J.

### **Citation**

Parker, J. (2017, July 4). *Recent innovations in minimally invasive anterior and posterior lamellar keratoplasty*. Retrieved from <https://hdl.handle.net/1887/50484>

Version: Not Applicable (or Unknown)

License: [Licence agreement concerning inclusion of doctoral thesis in the Institutional Repository of the University of Leiden](#)

Downloaded from: <https://hdl.handle.net/1887/50484>

**Note:** To cite this publication please use the final published version (if applicable).

Cover Page



Universiteit Leiden



The handle <http://hdl.handle.net/1887/50484> holds various files of this Leiden University dissertation

**Author:** Parker, Jack

**Title:** Recent innovations in minimally invasive anterior and posterior lamellar keratoplasty

**Issue Date:** 2017-07-04

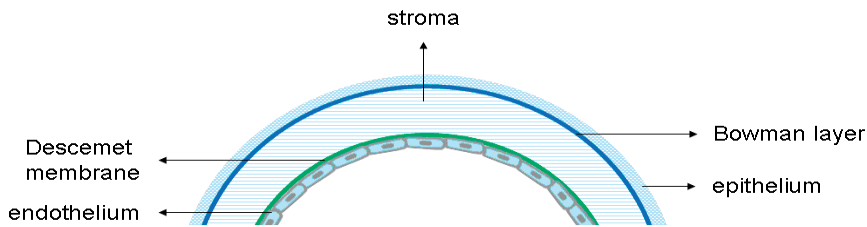
# **Chapter 1**

## **General Introduction**



## CORNEAL ANATOMY

Among the major structures of the human eye are the cornea, iris, lens, retina, choroid, and the optic nerve, although - presently - only the cornea is amenable to transplantation. It consists of 5 anatomic layers (from anterior to posterior): the epithelium, Bowman Layer, stroma, Descemet membrane, and endothelium (**Figure 1**).



**Figure 1.** The anatomical layers of the cornea.

Source: Ham L. Descemet Membrane Endothelial Keratoplasty: Donor Tissue Preparation and Clinical Outcomes. Optima Grafische Communicatie Rotterdam, 2011. p. 29

### The Epithelium

The corneal epithelium is constituted by 5-7 layers of non-keratinized, stratified, squamous epithelial cells admixed with a scattering of sentinel cells of the immune system including macrophages, lymphocytes, melanocytes, and Langerhans cells.<sup>1,2</sup> Its optical quality derives from: the evenness and regularity of its apical surface; the constancy of its thickness (precisely regulated at 50-52 $\mu$ m); the scarcity of organelles; and the presence of the intracytoplasmic enzyme crystalline within corneal epithelial cells.<sup>2-4</sup>

The corneal epithelium's basal layer contains cells linked to each other by desmosomes and tight junctions and to their underlying basement membrane by hemi-desmosomes. These cells migrate into the corneal center from the periphery (horizontally), then up toward the corneal surface (vertically); their origin appears to be a population of stem cells, located at the corneal limbus, the loss of which predisposes the cornea to persistent or non-healing corneal epithelial defects.<sup>5</sup> Above the basal epithelial layer are 2-3 layers of wing cells, linked by zona occludens, followed by the superficial most cells of the cornea, which are connected by tight and adherens junctions that tightly regulate corneal-environmental exchange.<sup>6</sup>

### The Bowman Layer

The cornea's Bowman Layer (BL) consists of a thin swath of modified anterior stroma lying immediately beneath the epithelial basement membrane. Approximately 8-14 $\mu$ m

thick (thinning with age), BL is acellular, physically robust, and tenaciously adherent to the underlying stroma.<sup>7</sup> Like the stroma, it consists mostly of types V and I collagen, although its fibers are smaller and more randomly arranged.<sup>8,9</sup>

Surprisingly, the physiologic purpose of this discrete structure remains, to date, unclear.

Some have speculated that it functions as a strong barrier to the passage of pathogens (especially viruses) through the cornea and into the deeper structures of the eye.<sup>10</sup> And undoubtedly, the focal loss of BL does permit aberrant epithelial-stromal communication, which is evident in the fibrous scars that frequently form at those sites.<sup>11-14</sup> In addition, BL may also have some structural role in maintaining the shape/ tectonic stability of the cornea, since - for corneal ectasias - the earliest and most sensitive indicator of disease is BL degeneration.<sup>15,16</sup> However, because the deliberate and widespread destruction of BL by photorefractive keratoplasty (*PRK*, a common laser refractive procedure) only rarely destabilizes the cornea into severe ectasia, the architectural *raison d'être* of BL must be more complicated and remains poorly understood.<sup>17</sup>

Because BL exists as an independent structure, after debriding the overlying epithelium, it may be peeled as a single sheet from the underlying stroma, after which it reliably scrolls into a single or double roll secondary to the inherent elasticity of the tissue itself.<sup>14,18</sup>

## The Stroma

Stroma represents the bulk of the thickness and weight of the cornea: it is constituted by collagen fibrils (predominantly Types I and V) arranged into 200-250 layered sheets (lamellae) that are oriented obliquely and with interlacing fibers connecting the layers together.<sup>1</sup> The posterior-most layer(s) of the stroma (the so-called "Dua Layer") appear morphologically identical to adjacent stroma, but may exhibit specialized behaviors owing to their location.<sup>19-22</sup> Interspersed among the collagen fibers are glycoproteins, which attract cations and water, and therefore tend to cause the cornea to swell.<sup>1</sup> (This tendency must be counter-acted by the endothelial pump function, to be discussed below.) These glycoproteins, and the collagen structure of the stroma itself, are secreted and maintained by a population of highly metabolically active corneal keratocytes, which are most numerous in the anterior cornea.<sup>1</sup>

## The Pre-Descemet Stroma

The injection of air or viscoelastic into the deep stroma of a human cornea not infrequently produces a cleavage plane between the bulk of the stroma (anterior) and a thin layer of anatomically indistinct stroma of variable thickness which immediately overlies the Descemet layer (posterior).<sup>19-22</sup> This thin band of pre-Descemet stroma is otherwise

known as the Dua layer, and while its existence has been long recognized, its importance may only be recently understood.<sup>23</sup>

Being composed of multiple collagen layers, the pre-Descemet stroma may confer an additional element of strength and support potentially advantageous in certain surgical circumstances. Specifically, during “big-bubble” anterior lamellar procedures, it may protect against inadvertent rupture of the Descemet membrane (itself a structure with very low tensile strength) and perforation into the anterior chamber. The pre-Descemet stroma may also be incorporated into a Descemet Membrane Endothelial Keratoplasty (DMEK) graft; this modification has given rise to the modified transplant type “Pre-Descemet Endothelial Keratoplasty” (PDEK), originally described by Agarwal in 2014.<sup>24</sup> Compared to conventional DMEK, PDEK may provide easier to handle tissue intra-operatively and the ability to use younger human donor tissue.<sup>25</sup> On the other hand, known PDEK disadvantages include smaller graft diameters (carrying fewer endothelial cells) and the possibility of optical interference generated by the additional stromal elements.<sup>26,27</sup>

High tensile strength is among the most notable features of the pre-Descemet stroma; some have speculated that – as a result – it may be ruptures in this tissue, rather than the relatively weak Descemet Membrane, that is responsible for the explosive deterioration seen with corneal hydrops in eyes with Keratoconus; and that, further, previously thought “Descemetoceles” may instead be “Dua-celes.”<sup>28</sup>

## The Descemet Membrane

Descemet Membrane (DM) is the basement membrane of - and secreted by - the cornea's endothelium, and lies sandwiched between the endothelium (below) and the posterior stroma (above). Composed largely of type IV collagen and laminin, it is comprised of three distinct layers: a thin non-banded zone (0.3µm thick) immediately adjacent to the stroma, an anterior banded zone (2-4µm) that thickens with advancing age, and a posterior/amorphous non-banded zone (>4µm) that features an atypical striate pattern of degeneration and wart-like collagenous excrescences known as guttae in patients with Fuchs endothelial dystrophy (FED).<sup>29,30</sup>

As a membrane with only tenuous connections to the overlying stroma, DM is easily stripped free as a single sheet (along with its attendant endothelium), which - like BL - also curls spontaneously into a single or double roll upon separation, owing to its own internal elasticity.<sup>31,32</sup>

## The Endothelium

The endothelium exists as a monolayer of tightly-packed hexagonal cells that comprise the cornea's posterior surface. The number of endothelial cells per unit area is regarded as the endothelial cell density (ECD), which is maximum at birth (around 6000 cells/mm<sup>2</sup>), declines sharply in the first year of life (to approximately 4000 cells/mm<sup>2</sup>), and

then decreases gradually by ~3% per year until adulthood, when the loss rate slows to ~1% per year, so that - by late age - most people have approximately 2000-2500 cells/mm<sup>2</sup>.<sup>33,34</sup>

Aside from aging, other causes of reduced ECD include: prior intraocular surgery, elevated eye pressure, trauma, prolonged contact lens wear, and chronic anterior chamber inflammation.<sup>35</sup>

Polymegathism and pleomorphism are the hallmarks of diseased or damaged endothelium: as cells are lost, neighboring cells expand to fill the vacated space producing a cobblestone pattern of variably sized and irregularly-shaped cells.<sup>35,36</sup> Specular microscopy readily demonstrates these changes *in vivo* in patients with endothelial diseases and may be used to track corneal health over time.<sup>37</sup>

### Endothelial Migration and Proliferation

The prevailing research suggests that, *in vivo*, endothelial cells neither proliferate nor replicate and remain permanently confined to a pre-mitotic, G1-phase.<sup>38</sup> While no definite explanation for this arrest in cell development has been discovered, candidate explanations include: the absence of autocrine/paracrine mitogenic stimulation, negative regulation by transforming growth factor beta (TGF- $\beta$ ; a substance that - when combined with aqueous humor - may inhibit entry into S-phase), and cell contact inhibition (a process mediated by p27kip1, a known G1-phase inhibitor).<sup>38,39</sup> Endothelial depletion from the central cornea prompts the inward migration of cells from the periphery to fill the vacancy. Although, previously, it was believed that these peripheral cells may be qualitatively different from central cells, perhaps possessing some additional proliferative potential, recent studies have failed to corroborate this theory.<sup>40,41</sup>

Nevertheless, *in vitro*, the human endothelium does appear capable of (limited) replication and growth, particularly when treated concurrently with Ethylenediamine-tetraacetic acid (EDTA), viral oncogenes, or when reared in culture media with select additives including epidermal growth factor (EGF), nerve growth factor (NGF), basic fibroblast growth factor (bFGF), and animal-derived extracellular matrix (ECM).<sup>42-51</sup> But even under these conditions, human corneal endothelium cannot be cultured indefinitely or proliferated infinitely: in general, the cells do not survive into the long term and cannot replicate beyond a few generations. This is particularly true for cell lines obtained from older donors (>30 years) which are relatively refractory to mitogenic stimulation and require more and longer exposure before responding.<sup>52,53</sup> Interestingly, however, young and old endothelial cells alike contain telomeres of similar lengths.<sup>45</sup> This suggests both a low natural replication rate, and also, that telomere shortening is an unlikely mechanism for the diminished capacity for replication that older cells display,



which may - instead - be attributed to accumulating stresses, including (potentially) oxidative damage.<sup>52-54</sup>

### **Corneal Transparency and Hydration: The Endothelial Barrier and Pump Function**

The transparency of the cornea derives from the diameter and spacing of the collagen fibers that compose it. Because both are smaller than half a wavelength of light, 90% of the *incident* light passes through, amplified by constructive interference, whereas nearly all *scattered* light is dissipated by destructive interference. As a result, under normal circumstances, the cornea

- although constituted largely of the same material as the adjacent sclera (which is totally opaque)
- remains clear.<sup>55-58</sup> However, if its architecture is disturbed such that the caliber or distance between collagen fibers are affected (for example, by scarring or fluid accumulation), then the delicate interference patterns that selectively transmit incident and rebuff scattered light are ruined, resulting in focal opacities.

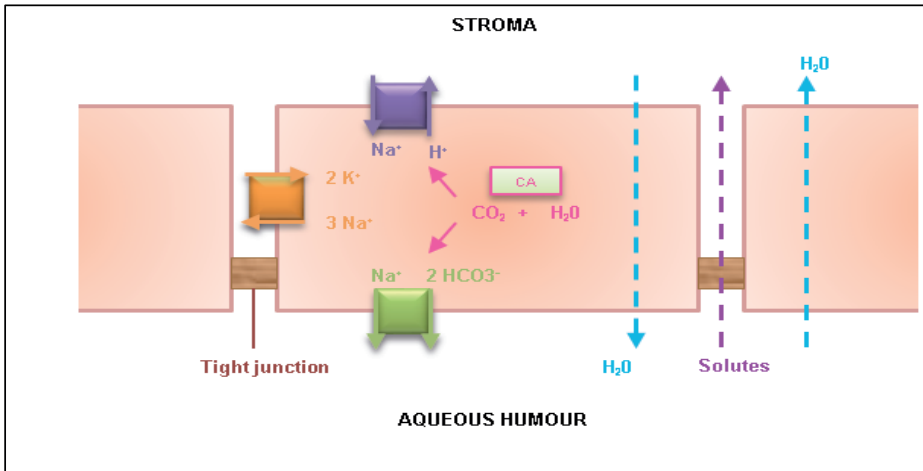
#### *Corneal hydration*

The cornea's water content (78% by weight) is tightly controlled by two principle means: the epithelial barrier and the endothelial pump.<sup>59-61</sup> At the ocular surface, tight junctions between epithelial cells keep fluid out from above. Meanwhile, with eyes open, evaporation from the tear film creates an osmotic gradient that draws water up from the stroma below.

Along the cornea's posterior surface, endothelial cells are likewise bound together by tight junctions, albeit with frequent gaps, permitting some fluid leakage up into the stroma. This constant leak provides the primary supply of glucose, amino acids, and other nutrients to the avascular cornea. Meanwhile, the "endothelial pump" (really, a complex chain of ion transporters) creates a countercurrent, which - by osmotic gradient - directs fluid back out of the stroma and recycles it into the anterior chamber, thereby balancing the passive influx.<sup>59-62</sup>

#### *Endothelial Barrier and Pump Function*

CO<sub>2</sub> passively diffuses into endothelial cells. There, it combines with H<sub>2</sub>O to form carbonic acid (H<sub>2</sub>CO<sub>3</sub>) and is cleaved by carbonic anhydrase into hydrogen ions and bicarbonate (H<sup>+</sup> and HCO<sub>3</sub><sup>-</sup>), both of which are then actively pumped into the stroma (**Figure 2**).<sup>63,64</sup>



**Figure 2.** Ion transport systems and carbonic anhydrase (CA) functions of the corneal endothelium.

Source: Ham L. Descemet Membrane Endothelial Keratoplasty: Donor Tissue Preparation and Clinical Outcomes. Optima Grafische Communicatie Rotterdam, 2011. p.32

The bicarbonate is allowed back into the cell by the cooperative actions of two basolateral channels: the  $\text{Na}^+\text{-K}^+$  ATPase and the  $1\text{Na}^+\text{-2HCO}_3^-$  transporter. The former pumps sodium against its concentration gradient into the stroma and the latter permits the ion's return, along with 2 molecules of bicarbonate. (Sodium also returns to the cell via basolateral  $\text{Na}^+\text{-K}^+\text{-2Cl}^-$  transporters and  $\text{Na}^+\text{-H}^+$  exchangers). Principally, it is the net flux of bicarbonate (and possibly also NaCl) that drives the osmotic gradient which draws water out of the stroma and deturgescs the cornea.<sup>65-70</sup>

## CORNEAL TRANSPLANTATION

Corneal transplantation (or simply, *keratoplasty*) involves the exchange of donor corneal tissue - as a graft - for the patient's own diseased cornea (or a portion of it.) Whereas the operation may also be performed for tectonic and cosmetic reasons, its most common indication is visual restoration.<sup>71</sup>

Originally, the surgery amounted to little more than simple substitution: after excising practically the whole recipient cornea, a donor graft was sewn into position, effectively replacing the entire organ. This type of whole-corneal transplantation is traditionally known as *penetrating keratoplasty (PK)* and is still performed today, although now less commonly, since the advent of modern partial corneal (lamellar) transplantation.<sup>71,72</sup>

## EARLY EFFORTS IN CORNEAL TRANSPLANTATION

Scientific inquiry into the possibility of corneal transplantation began in the late 1700s. By the 1820s, the idea had matured and the term “keratoplasty” arose to designate the surgical procedure (coined independently by Himley and Reisinger).<sup>72</sup> Virtually all initial attempts at the operation were failures, as the early donor tissue came from animals and succumbed invariably to immunological rejection.<sup>73</sup> Consequently, the first successful corneal transplant was delayed until 1905 when a Slovakian ophthalmologist - Dr. Eduard Zirm - performed bilateral corneal replacement for a patient previously blinded by a chemical accident.<sup>74</sup>

With the essential technique established, next came improvements in tissue and tools. The Russian ophthalmologist Vladimir Filatov popularized the use of cadaveric human corneas for donor grafts and thereby established himself as the father of modern eye banking.<sup>75</sup> In Spain, Ramon Castroviejo performed his first successful keratoplasty in 1936 and subsequently devised a litany of useful instruments to facilitate the procedure.<sup>76</sup> Prophylactic antibiotics became stronger and more routine in the 1940s, steroids emerged to temper postoperative inflammation, and better corneal preservation protocols and upgraded technology (in particular, operating microscopes which enabled modern microsurgery) pushed surgical outcomes to new heights.<sup>77</sup>

Meanwhile, eye banks developed in parallel. The first was created in New York in 1944 by Townly Paton.<sup>78</sup> In 1961, the Eye Bank Association of America (EBAA) was founded and established standards for obtaining, processing, storing, and using donor tissue. By incorporating specular microscopy, eye banks learned to scrutinize the endothelial health of their corneas and to offer exclusively high quality tissue.<sup>79</sup> Finally, the development of MK medium by McCarey and Kaufman in 1974 enabled corneal preservation, permitting grafts to be stored and transplants planned and scheduled in advance.<sup>80</sup>

## EVOLVING TECHNIQUES IN CORNEAL TRANSPLANTATION

Despite these revolutions in medication, instrumentation, and tissue preservation, the basic goal of the operation remained the same: total replacement of the recipient cornea with donor tissue. Complete corneal exchange (*penetrating keratoplasty, PK*) therefore represents the overwhelming history of the surgery.<sup>81</sup> It was the first, and - until at least the 1970s - the only form of corneal transplantation commonly available. Nevertheless, the operation was prone to problems, deriving principally from the bulk of the grafts and from the incisions necessary to accommodate them. Such problems include: poor wound healing, suture related difficulties, an unstable ocular surface, the

persistent threat of allograft reaction and graft rejection, and frequently, disappointing visual outcomes.<sup>82</sup>

The first attempts at partial corneal transplantation (*lamellar keratoplasty, LK*) occurred in the 1950s. While Jose Barraquer experimented with replacing the anterior corneal surface, Charles Tillet trialed posterior lamellar exchange.<sup>83,84</sup> Ultimately, however, both efforts failed: Barraquer's because the irregular interface between the donor and recipient tissues degraded the cornea's optical results, and Tillet's because fixating a posterior lamellar graft to the overlying stroma proved impossible with conventional suturing techniques. Sunk by disappointing results like these, LK was mostly forgotten and largely abandoned for decades.<sup>85</sup>

But in the 1980's, interest in anterior lamellar exchange was revived: Eduardo Archila demonstrated that an intrastromal injection of air could facilitate deeper dissection into the recipient cornea, significantly reducing the irregularity at the graft interface.<sup>86</sup> This gave rise to the concept of *deep anterior lamellar keratoplasty (DALK)*. Mohammed Anwar refined the technique by establishing that a single "big bubble" could be generated between the recipient stroma and its Descemet Membrane (DM), and that - by expanding this bubble - the two tissues might be totally separated.<sup>87</sup> Independently, Gerrit Melles showed that a similar feat was possible using visco-elastic instead of air.<sup>88</sup> He also devised a method for manually dissecting the entire host stroma from its DM using a series of curved spatulas and the "air-endothelium reflex" (the location of the reflection produced by the tips of his instruments) to precisely judge the depth of the ongoing dissection.<sup>89</sup>

Meanwhile, Melles also solved the primary problem with posterior lamellar transplantation: fixating the grafts to the recipient's stroma. Whereas prior attempts to suture the donor tissue had failed, Melles discovered that - instead - an air bubble could be left inside the anterior chamber and the force of its buoyancy sufficed to hold the graft in place. As a result, in 1998, *posterior lamellar keratoplasty (PLK)* became feasible.<sup>90</sup> In the States, the operation was rebranded *Deep Lamellar Endothelial Keratoplasty (DLEK)* by Mark Terry.<sup>91</sup> But because DLEK proved too technically challenging for widespread adoption (since it required meticulously dissecting matching stromal/endothelial lenticles from the recipient and the donor corneas, then exchanging them), Melles revised the procedure into a modified version which he dubbed *Descemet Stripping Endothelial Keratoplasty (DSEK)*.<sup>92</sup> Compared to DLEK, DSEK was simpler and easier: while the two operations employed identical donor tissue, DSEK abandoned the stromal dissection that DLEK required in favor of merely stripping the recipient endothelium and DM. This dramatically lessened the technical challenge of the surgery and established DSEK as the global treatment of choice for endothelial disorders, especially after Mark Gorovoy popularized the use of microkeratome-cut DSEK grafts (thus effecting a tweak to the nomenclature: *Descemet Stripping Automated Endothelial Keratoplasty, DSAEK*).<sup>93</sup>

Although an improvement over DLEK, DS(A)EK nevertheless retained some of its predecessor's limitations. In particular, both operations entailed the transplantation of some amount of donor stroma into the recipient eye, and this extra tissue probably compromised the cornea's optical performance.<sup>94</sup> Consequently, Melles further refined the operation to *Descemet Membrane Endothelial Keratoplasty (DMEK)*, which differed from DSEK in that its graft was constituted exclusively of DM and its endothelium, without any attendant stroma.<sup>95</sup> Therefore, with DMEK - and for the first time in the history of posterior lamellar exchange - an exact one- to-one exchange of donor for diseased tissue was achieved, and the natural, physiologic anatomy of the cornea was restored.<sup>96</sup>

*Endothelial keratoplasty (EK)* is the umbrella term that emerged to describe these various formulations of posterior lamellar transplantation (PLK, DLEK, DS(A)EK, and DMEK). Whereas PLK and DLEK have been largely superseded, DS(A)EK and DMEK currently co-exist as the two most common treatments for endothelial dysfunction worldwide.<sup>97</sup> Since their original description, both operations have changed considerably: in general, DS(A)EK grafts have gotten thinner (i.e. they incorporate less donor stroma), promoting better visual outcomes through reduced scarring at the transplant interface.<sup>98</sup> Meanwhile, DMEK grafts have likewise experienced several shape changes. Until recently, all consisted of circular sheets of DM and endothelium cut from the center of donor corneas. But in 2014, it was discovered that - rather than harvesting merely the central, circular, island of DM and endothelium - instead, the entire sheet could be bisected and then stripped to produce two, large, hemi-circular grafts; each of which may be transplanted into separate patients.<sup>99</sup> This new surgical variant has been named Hemi-DMEK, and it appears to offer results comparable to conventional DMEK while doubling the pool of donor tissue available for transplant.<sup>100,101</sup>

Aside from Hemi-DMEK, other modifications to the basic DMEK technique include: *Descemet membrane endothelial transfer (DMET)*, in which a DMEK graft is injected into the recipient eye but not appositioned against the host stroma, and corneal clearance occurs after some delay by endothelial cell migration)<sup>102,103</sup>, *DMEK-S* (a largely abandoned way to prepare DMEK grafts by microkeratome that leaves the tissue with a rim of stroma to facilitate intraoperative handling)<sup>104</sup>, and *Pre-Descemets Endothelial Keratoplasty (PDEK)*, which is similar to conventional DMEK except that the graft is 20µm thicker because it also incorporates a thin layer of posterior stroma).<sup>105</sup>

Alongside these innovations in posterior lamellar transplantation, recently, a new operation has emerged for patients with corneal ectasias: Bowman Layer (BL) transplantation.<sup>106</sup> The procedure entails manually dissecting a pocket within the mid-stroma of a recipient cornea and implanting a graft consisting of an isolated, donor BL. Subsequent healing both flattens and "fixes" the cornea into a more normal configuration that resists further disease progression.<sup>106,107</sup>

Thereby, corneal ectasias may be halted (even partially reversed). And because the operation makes no surface incisions, requires no sutures, and transplants only thin, acellular material (and thus provokes little-to-no immunological reaction), BL transplantation may avoid many of the most common complications of PK and even DALK.<sup>108</sup>

## THESIS OUTLINE

This thesis concerns these modern developments in transplantation tactics: specifically, the recent innovations in minimally invasive anterior and posterior lamellar keratoplasty.

The first section concerns anterior lamellar techniques: Chapter 2 summarizes the current state of evidence regarding the outcomes of the various operations; Chapters 3 provides the results from the first cohort of patients to receive the operation, and the data from the first American patient to receive the transplantation is described in Chapter 4. Chapter 5 concludes the section by describing the most significant controversies that are outstanding in the field of anterior lamellar transplantation today.

The thesis's second section is dedicated to posterior lamellar operations, mostly DMEK. A general review distinguishing DMEK from its predecessors is provided in Chapter 6, and the longevity/ cell density of the grafts over time is the subject of Chapter 7. DMEK's results in phakic (vs. pseudophakic) eyes is discussed in Chapter 8.

Finally, Chapters 9 and 10 provide a survey of all results, along with a general discussion and brief conclusion.

## REFERENCES

1. Sabet S, Adamopoulou A. Basic Structure and Function of the Human Cornea and Adnexal Structures. In: Copeland R and Afshari N (Ed.). *Copeland Afshari's Principles and Practice of Cornea*. Jaypee Brothers Medical Publishers, 2013.
2. Qazi Y, Hamrah P. Corneal Allograft Rejection: Immunopathogenesis to Therapeutics. *J Clin Cell Immunol*. 2013 Nov 20; 2013(Suppl 9): 006.
3. Maurice D. The location of the fluid pump in the cornea. *J Physiol*. 1972; 221: 43–54.
4. Hodson S, Miller F. The bicarbonate ion pump in the endothelium which regulates the hydration of rabbit cornea. *J Physiol*. 1976; 263: 563–577.
5. Daniels JT, Harris AR, Mason C. Corneal epithelial stem cells in health and disease. *Stem Cell Rev*. 2006;2:247–54.
6. Maurice DM. The cornea and sclera, In: Davidson H (Ed.). *The Eye*. New York Academic, 1984.
7. Germundsson J, Karanis G, Fagerholm P, Lagali N. Age-related thinning of Bowman's layer in the human cornea in vivo. *Invest Ophthalmol Vis Sci*. 2013;54:6143–9.
8. Gordon MK, Foley JW, Birk DE, Fitch JM, Linsenmayer TF. Type V collagen and Bowman's membrane. Quantitation of mRNA in corneal epithelium and stroma. *JBiol Chem*. 1994;269:24959–66.
9. Nakayasu K, Tanaka M, Konomi H, Hayashi T. Distribution of types I, II, III, IV and V collagen in normal and keratoconus corneas. *Ophthalmic Res*. 1986;18:1–10.
10. Holmberg K. The fine structure of Bowman's layer and the basement membrane of the corneal epithelium. *Am J Ophthalmol*. 1960;50:1013–21.
11. Netto MV, Mohan RR, Sinha S, Sharma A, Dupps W, Wilson SE. Stromal haze, myofibroblasts, and surface irregularity after PRK. *Exp Eye Res* 2006; 82:788–797
12. Møller-Pedersen T. On the structural origin of refractive instability and corneal haze after excimer laser keratectomy for myopia. *Acta Ophthalmol Scand Suppl* 2003; 237:1–20
13. Lagali N, Germundsson J, Fagerholm P. The role of Bowman's layer in corneal regeneration after phototherapeutic keratectomy: a prospective study using in vivo confocal microscopy. *Invest Ophthalmol Vis Sci*. 2009;50:4192–8.
14. Lie J, Droutsas K, Ham L. Isolated Bowman layer transplantation to manage persistent subepithelial haze after excimer laser surface ablation. *J Cataract Refract Surg*. 2010;36:1036–41.
15. Sykakis E, Carley F, Irion L, Denton J, Hillarby MC. An in depth analysis of histopathological characteristics found in keratoconus. *Pathology*. 2012;44:234–9.
16. Zimmermann DR, Fischer RW, Winterhalter KH, Witmer R, Vaughan L. Comparative studies of collagens in normal and keratoconus corneas. *Exp Eye Res*. 1988;46:431–42.
17. Dawson DG, Grossniklaus HE, McCarey BE, Edelhauser HF. Biomechanical and wound healing characteristics of corneas after excimer laser keratorefractive surgery: is there a difference between advanced surface ablation and sub-Bowman's keratomileusis? *J Refract Surg*. 2008;24: S90–6.
18. Groeneveld-van Beek EA, Parker J, Lie JT. Donor Tissue Preparation for Bowman Layer Transplantation. *Cornea*. 2016 Jun 29. [Epub ahead of print]
19. McKee HD, Irion LC, Carley FM, Jhanji V, Brahma AK. Residual corneal stroma in big- bubble deep anterior lamellar keratoplasty: a histological study in eye-bank corneas. *Br J Ophthalmol*. 2011; 95(10):1463–5
20. Dua HS, Faraj LA, Said DG, Gray T, Lowe J. Human corneal anatomy redefined: a novel pre-Descemet's layer (Dua's layer). *Ophthalmology*. 2013;120(9):1778–85

21. Schlötzer-Schrehardt U, Bachmann BO, Tourtas T, et al. Ultrastructure of the posterior corneal stroma. *Ophthalmology*. 2015;122(4):693-9
22. McKee HD, Irion LC, Carley FM, et al. Re: Dua et al.: Human corneal anatomy redefined: a novel pre-Descemet layer (Dua's layer) 715 (*Ophthalmology* 2013; 120:1778-85). *Ophthalmology*. 2014; 121(5): e24–5.
23. Dua HS, Mastropasqua L, Faraj L, et al. Big bubble deep anterior lamellar keratoplasty: the collagen layer in the wall of the big bubble is unique. *Acta Ophthalmol*. 2015;93(5):427–430.
24. Agarwal A, Dua H, Narang P, et al. Pre-Descemet's endothelial keratoplasty (PDEK). *Br J Ophthalmol*. 2014;98:1181-5.
25. Dua HS, Termote K, Kenawy MB et al. Scrolling Characteristics of Pre-Descemet Endothelial Keratoplasty Tissue: An Ex Vivo Study. *Am J Ophthalmol*. 2016;166:84-90.
26. Agarwal A, Agarwal A, Narang P, Kumar DA, Jacob S. Pre-Descemet Endothelial Keratoplasty With Infant Donor Corneas: A Prospective Analysis. *Cornea*. 2015;34:859- 65.
27. Dua HS, Said DG. Pre-Descemets endothelial keratoplasty: the PDEK clamp for successful PDEK. *Eye (Lond)*. 2017 Feb 17. [Epub ahead of print]
28. Dua HS, Said DG. Clinical evidence of the pre-Descemets layer (Dua's layer) in corneal pathology. *Eye (Lond)*. 2016;30:1144-5.
29. Johnson DH, Bourne WM, Campbell RJ. The ultrastructure of Descemet's membrane. I. Changes with age in normal corneas. *Arch Ophthalmol*. 1982;100:1942-7.
30. Bourne WM, Johnson DH, Campbell RJ. The ultrastructure of Descemet's membrane. III. Fuchs' dystrophy. *Arch Ophthalmol*. 1982;100:1952-5.
31. Lie JT, Birbal R, Ham L, van der Wees J, Melles GR. Donor tissue preparation for Descemet membrane endothelial keratoplasty. *J Cataract Refract Surg*. 2008;34:1578-83.
32. Groeneveld-van Beek EA, Lie JT, van der Wees J, Bruinsma M, Melles GR. Standardized 'no-touch' donor tissue preparation for DALK and DMEK: harvesting undamaged anterior and posterior transplants from the same donor cornea. *Acta Ophthalmol*. 2013;91:145-50.
33. McCarey BE, Edelhauser HF, Lynn MJ. Review of corneal endothelial specular microscopy for FDA clinical trials of refractive procedures, surgical devices, and new intraocular drugs and solutions. *Cornea*. 2008;27:1-16.
34. Laule A, Cable MK, Hoffman CE, Hanna C. Endothelial cell population changes of human cornea during life. *Arch Ophthalmol*. 1978;96:2031-5.
35. Capella JA. Regeneration of endothelium in diseased and injured cornea. *Am J Ophthalmol*. 1972; 74:810-7.
36. Ikebe M, Takamatsu T, Ito M, et al. Changes in nuclear DNA content and cell size of injured human corneal endothelium. *Exp Eye Res*. 1988;47:205-15.
37. Sturrock GD, Sherrard ES, Rice NS. Specular microscopy of the corneal endothelium. *Br J Ophthalmol*. 1978;62:809-14.
38. Joyce NC. Proliferative capacity of the corneal endothelium. *Prog Retin Eye Res*. 2003;22:359-389.
39. Joyce NC, Harris DL, Mello DM. Mechanisms of mitotic inhibition in corneal endothelium: contact inhibition and TGF-beta2. *Invest Ophthalmol Vis Sci*. 2002;43:2152-2159
40. Amann J, Holley GP, Lee SB, Edelhauser HF. Increased endothelial cell density in the paracentral and peripheral regions of the human cornea. *Am J Ophthalmol*. 2003;135:584- 590.
41. Konomi K, Zhu C, Harris D, Joyce NC. Comparison of the proliferative capacity of human corneal endothelial cells from the central and peripheral areas. *Invest Ophthalmol Vis Sci*. 2005;46:4086-4091



42. Baum JL, Niedra R, Davis C, Yue BY. Mass culture of human corneal endothelial cells. *Arch Ophthalmol*. 1979;97:1136-1140.
43. Sumide T, Nishida K, Yamato M, Ide T, Hayashida Y, Watanabe K, Yang J, Kohno C, Kikuchi A, Maeda N, Watanabe H, Okano T, Tano Y. Functional human corneal endothelial cell sheets harvested from temperature-responsive culture surfaces. *FASEB J*. 2006;20:392-394.
44. Slettedal JK, Lyberg T, Røger M, Beraki K, Ramstad H, Nicolaissen B. Regeneration with proliferation of the endothelium of cultured human donor corneas with extended postmortem time. *Cornea*. 2008;27:212-219.
45. Senoo T, Joyce NC. Cell cycle kinetics in corneal endothelium from old and young donors. *Invest Ophthalmol Vis Sci*. 2000;41:660-667.
46. Senoo T, Obara Y, Joyce NC. EDTA promotes proliferation in human corneal endothelium. *Invest Ophthalmol Vis Sci*. 2000;41:2930-2935.
47. Wilson SE, Weng J, Blair S, He YG, Lloyd S. Expression of E6/E7 or SV40 large T antigen-coding oncogenes in human corneal endothelial cells indicates regulated high-proliferative capacity. *Invest Ophthalmol Vis Sci*. 1995;36:32-40.
48. Schonthal AH, Hwang JJ, Stevenson D, Trousdale MD. Expression and activity of cell cycle-regulatory proteins in normal and transformed corneal endothelial cells. *Exp Eye Res*. 1999;68:531-539.
49. Shao Y, Hu D, Chen J. A study on effect of bFGF, EGF and NGF on growth of cultured human corneal endothelial cells. *Yan Ke Xue Bao*. 2008;24:9-12.
50. Blake DA, Yu H, Young DL, Caldwell DR. Matrix stimulates the proliferation of human corneal endothelial cells in culture. *Invest Ophthalmol Vis Sci*. 1997;38:1119-1129.
51. Miyata K, Drake J, Osakabe Y, Hosokawa Y, Hwang D, Soya K, Oshika T, Amano S. Effect of donor age on morphologic variation of cultured human corneal endothelial cells. *Cornea*. 2001;20:59-63.
52. Beckman KB, Ames BN. The free radical theory of aging matures. *Physiol Rev*. 1998;78:547-581.
53. Joyce NC, Navon SE, Roy S, Zieske JD. Expression of cell cycle-associated proteins in human and rabbit corneal endothelium in situ. *Invest Ophthalmol Vis Sci*. 1996;37:1566-1575.
54. Joyce NC. Cell cycle status in human corneal endothelium. *Exp Eye Res*. 2005;81:629-638.
55. Hassell JR, Birk DE. The molecular basis of corneal transparency. *Exp Eye Res*. 2010;91:326-335.
56. Maurice DM. The structure and transparency of the cornea. *J Physiol*. 1957;136:263-286.
57. Hart RW, Farrell RA. Light scattering in the cornea. *J Opt Soc Am*. 1969;59:766-774.
58. Jester JV, Møller-Pedersen T, Huang J et al. The cellular basis of corneal transparency: evidence for 'corneal crystallins'. *J Cell Sci*. 1999;112:613-622.
59. Fischbarg J, Maurice DM. An update on corneal hydration control. *Exp Eye Res*. 2004;78:537-541.
60. Meek KM, Leonard DW, Cannon CJ, Dennis S, Khan S. Transparency, swelling and scarring in the corneal stroma. *Eye (Lond)*. 2003;17:927-936.
61. Hart WM. The Cornea. In: Adler's physiology of the eye. 9th ed. St. Louis: Moby-Year Book. 1992;3:55-58.
62. Noske W, Fromm M, Levarlet B, Kreusel KM, Hirsch M. Tight junctions of the human corneal endothelium: morphological and electrophysiological features. *Ger J Ophthalmol*. 1994;3:253-257.
63. Bonanno JA. Identity and regulation of ion transport mechanisms in the corneal endothelium. *Prog Retin Eye Res*. 2003;22:69-94.
64. Fischbarg J. Active and passive properties of the rabbit corneal endothelium. *Exp Eye Res*. 1973;15:615-638.

65. Huff JW, Green K. Demonstration of active sodium transport across the isolated rabbit corneal endothelium. *Curr Eye Res.* 1981;1:113-114.
66. Lim JJ. Na<sup>+</sup> transport across the rabbit corneal endothelium. *Curr Eye Res.* 1981;1:255-258.
67. Whitehart DR, Soppet DR. Activities of transport enzymes located in the plasma membranes of corneal endothelial cells. *Invest Ophthalmol Vis Sci.* 1981;21:819-825.
68. Jentsch TJ, Keller SK, Wiederholt M. Ion transport mechanisms in cultured bovine corneal endothelial cells. *Curr Eye Res.* 1985;4:361-369.
69. Sun XC, Li J, Cui M, Bonanno JA. Role of carbonic anhydrase IV in corneal endothelial HCO<sub>3</sub><sup>-</sup> transport. *Invest Ophthalmol Vis Sci.* 2008;49:1048-1055.
70. Fischbarg J. Mechanism of fluid transport across corneal endothelium and other epithelial layers: a possible explanation based on cyclic cell volume regulatory changes. *Br J Ophthalmol.* 1997;81:85-89.
71. Williams KA, Muehlberg SM, Lewis RF, Coster DJ. How successful is corneal transplantation? A report from the Australian Corneal Graft Register. *Eye.* 1995;9:219-227.
72. Soong MD H. Corneal Transplantation. In: Spaeth G, ed. *Ophthalmic Surgery: Principles and Practice.* Philadelphia, PA: Elsevier; 2003:139-160
73. Power H: IV international Congress of Ophthalmology. Vol. IV. P.172. London. 1872
74. Zirm EK: Eine erfolgreiche totale keratoplastik. V. Graefes Arch Ophthalmol. 1906;64:580-593
75. Filatov VP. Transplantation of the cornea. *Arch Ophthalmol.* 1935;13,321-347
76. Murube J. Ramon Castroviejo centenary: a life dedicated to corneal transplantation. *Surv Ophthalmol.* 2005;50:215-225.
77. Vajpayee RB. Corneal transplantation. First edition, New Delhi, India, 2002;3-5.
78. Paton D. The founder of the first eye bank: R. Townley Paton, MD. *Refract Corneal Surg.* 1991;7:190-194.
79. Maurice DM. A scanning slit optical microscopy. *Invest Ophthalmol Vis Sci.* 1974;13:1033-1037
80. Lindstrom RL. Advances in corneal preservation. *Trans Am Ophthalmol Soc.* 1990;88:555-648.
81. Terry MA. Endothelial keratoplasty: why aren't we all doing Descemetmembrane endothelial keratoplasty? *Cornea.* 2012;31:469-71
82. Price MO, Price FW Jr. Endothelial keratoplasty - a review. *Clin Experiment Ophthalmol.* 2010;38:128-140.
83. Barraquer JI. Lamellar keratoplasty. (Special techniques). *Ann Ophthalmol.* 1972;4:437-469.
84. Tillett CW. Posterior lamellar keratoplasty. *Am J Ophthalmol.* 1956;41:530-533.
85. Culbertson WW. Endothelial replacement: flap approach. *Ophthalmol Clin North Am.* 2003;16:113-118.
86. Archila EA. Deep lamellar keratoplasty dissection of host tissue with intrastromal air injection. *Cornea.* 1984-1985;3:217-8.
87. Anwar M, Teichmann KD. Big-bubble technique to bare Descemet's membrane in anterior lamellar keratoplasty. *J Cataract Refract Surg.* 2002;28(3):398-403
88. Melles GR, Remeijer L, Geerards AJ, Beekhuis WH. A quick surgical technique for deep, anterior lamellar keratoplasty using visco-dissection. *Cornea.* 2000;19(4):427-32
89. Melles GR, Rietveld FJ, Beekhuis WH, Binder PS. A technique to visualize corneal incision and lamellar dissection depth during surgery. *Cornea.* 1999;18(1):80-6
90. Melles GR, Eggink FA, Lander F, et al. A surgical technique for posterior lamellar keratoplasty. *Cornea.* 1998;17:618-26.
91. Terry MA, Ousley PJ. Deep lamellar endothelial keratoplasty in the first United States patients: early clinical results. *Cornea.* 2001;20:239-43.

92. Melles GR, Lander F, Nieuwendaal C. Sutureless, posterior lamellar keratoplasty: a case report of a modified technique. *Cornea*. 2002;21:325-7.
93. Gorovoy MS. Descemet-stripping automated endothelial keratoplasty. *Cornea*. 2006;25:886-9.
94. Dirisamer M, Parker J, Naveiras M, et al. Identifying causes for poor visual outcome after DSEK/ DSAEK following secondary DMEK in the same eye. *Acta Ophthalmol*. 2013;91:131-9.
95. Melles GR, Ong TS, Ververs B, van der Wees J. Descemet membrane endothelial keratoplasty (DMEK). *Cornea*. 2006;25:987-90.
96. Livny E, Parker JS, van der Kaaij M et al. Postmortem ultrastructural analysis of a cornea transplanted with Descemet membrane endothelial keratoplasty. *Cornea*. 2014;33:790-4
97. Price FW Jr, Price MO. Evolution of endothelial keratoplasty. *Cornea*. 2013;32 Suppl 1:S28-32.
98. Dapena I, Ham L, Melles GR. Endothelial keratoplasty: DSEK/DSAEK or DMEK--the thinner the better? *Curr Opin Ophthalmol*. 2009;20:299-307.
99. Lam FC, Baydoun L, Dirisamer M, Lie J, Dapena I, Melles GR. Hemi-Descemet membrane endothelial keratoplasty transplantation: a potential method for increasing the pool of endothelial graft tissue. *JAMA Ophthalmol*. 2014;132:1469-73.
100. Gerber-Hollbach N, Parker J, Baydoun L, Liarakos V, Ham L, Dapena I, Melles G. "Preliminary outcome of hemi-DMEK for Fuchs Endothelial Dystrophy." *Br J Ophthalmol*. 2016 Feb 2. [Epub ahead of print]
101. Lam FC, Baydoun L, Satué M, et al. One year outcome of hemi-Descemet membrane endothelial keratoplasty. *Graefes Arch Clin Exp Ophthalmol*. 2015;253:1955-8
102. Dirisamer M, Ham L, Dapena I, van Dijk K, Melles GR. Descemet membrane endothelial transfer: "free-floating" donor Descemet implantation as a potential alternative to "keratoplasty". *Cornea*. 2012;31:194-7.
103. Lam FC, Bruinsma M, Melles GR. Descemet membrane endothelial transfer. *Curr Opin Ophthalmol*. 2014;25:353-7.
104. Studeny P, Farkas A, Vokrojova M, Liskova P, Jirsova K. Descemet membrane endothelial keratoplasty with a stromal rim (DMEK-S). *Br J Ophthalmol*. 2010;94:909- 914.
105. Agarwal A, Dua HS, Narang P, et al. Pre-Descemet's endothelial keratoplasty (PDEK). *Br J Ophthalmol*. 2014 Sep;98(9):1181-5.
106. van Dijk K, Parker J, Tong M, Ham L, Lie J, Groeneveld-van Beek E, Melles G. "Mid-stromal isolated Bowman layer graft to reduce and stabilize advanced keratoconus as an alternative to penetrating or deep anterior lamellar keratoplasty." *JAMA Ophthalmol*. 2014;132:495-501.
107. van Dijk K, Liarakos V, Parker J, Ham L, Lie JT, Groeneveld-van Beek EA, Melles GRJ. "Bowman layer transplantation to reduce and stabilize progressive, end stage, keratoconus." *Ophthalmology*. 2015;122(5):909-17.
108. Parker JS, van Dijk K, Melles GR. Treatment options for advanced keratoconus: A review. *Surv Ophthalmol*. 2015;60:459-80

