Universiteit Leiden
The Netherlands

Recent innovations in minimally invasive anterior and posterior lamellar keratoplasty

Parker, J.

Citation
Parker, J. (2017, July 4). *Recent innovations in minimally invasive anterior and posterior lamellar keratoplasty*. Retrieved from https://hdl.handle.net/1887/50484

Version:	Not Applicable (or Unknown)
License:	Licence agreement concerning inclusion of doctoral thesis in the Institutional Repository of the University of Leiden
Downloaded from:	https://hdl.handle.net/1887/50484

Note: To cite this publication please use the final published version (if applicable).

Cover Page

Universiteit Leiden

Leiden University Repository

The handle http://hdl.handle.net/1887/50484 holds various files of this Leiden University dissertation

Author: Parker, Jack
Title: Recent innovations in minimally invasive anterior and posterior lamellar keratoplasty
Issue Date: 2017-07-04



Recent innovations in minimally invasive anterior and posterior lamellar keratoplasty

JACK PARKER

Recent innovations in minimally invasive anterior and posterior lamellar keratoplasty

Jack Parker

Recent innovations in minimally invasive anterior and posterior lamellar keratoplasty

© 2017 Jack Parker
ISBN: 978-94-92683-62-5
Printing and Layout: Optima Grafische Communicatie, Rotterdam, The Netherlands
Cover design: Jack Parker

The research described in this thesis was performed at the Netherlands Institute for Innovative Ocular Surgery.

Recent innovations in minimally invasive anterior and posterior lamellar keratoplasty

Proefschrift

Ter verkrijging van de graad van
Doctor aan de Universiteit Leiden
op gezag van Rector Magnificus prof.dr. CJ.J.M. Stolker,
volgens besluit van het College voor Promoties
te verdedigen op dinsdag 4 juli 2017
te klokke 16.15 uur

door

John Steven Parker Jr
geboren te Birmingham, Alabama, USA
in 1986

Promotoren
Prof.dr. M.J. Jager
Dr. G.R.J. Melles

Leden Promotiecommissie
Prof.dr. M-J. Tassignon, Universiteit van Antwerpen
Prof.dr. C. Cursiefen, Universiteit van Keulen
Dr. Y.Y.Y. Cheng

TABLE OF CONTENTS

Chapter 1	General Introduction	7
Part I	**Bowman Layer Transplantation**	
Chapter 2	Treatment Options for Advanced Keratoconus: A Review. *Surv. Ophth. 2015;60:459-480*	25
Chapter 3	Mid-stromal isolated Bowman layer graft to reduce and stabilizeadvanced keratoconus as an alternative to penetrating or deep anterior lamellar keratoplasty. *JAMA Ophthalmol. 2014;132:495-501*	73
Chapter 4	Bowman Layer Transplantation for Advanced Keratoconus: The First American Case.	87
Chapter 5	Updates in Anterior Lamellar Keratoplasty: The State of the Debates *Expert Rev Ophthalmol. 2016;11:339-346.*	97
Part II	**Descemet membrane endothelial keratoplasty**	
Chapter 6	Descemet membrane endothelial keratoplasty (DMEK): a review. *US Ophthalmic Review, 2013;6:29-32*	117
Chapter 7	Endothelial cell density after Descemet Membrane Endothelial Keratoplasty: 1- to 4-Year Follow-up. *Am J Ophthalmol. 2011;151:1107-1107.e2*	133
Chapter 8	Outcome of Descemet membrane endothelial keratoplasty in phakic eyes. *J Cataract Refract Surg. 2012;38:871-877*	139
Chapter 9	Summary and conclusions *Based on US Ophthalmic Review 2015;8:33-34*	167
Chapter 10	Dutch Summary	155
	List of publications	179
	Acknowledgments	181
	CV	183

Chapter 1

General Introduction

CORNEAL ANATOMY

Among the major structures of the human eye are the cornea, iris, lens, retina, choroid, and the optic nerve, although - presently - only the cornea is amenable to transplantation. It consists of 5 anatomic layers (from anterior to posterior): the epithelium, Bowman Layer, stroma, Descemet membrane, and endothelium (**Figure 1**).

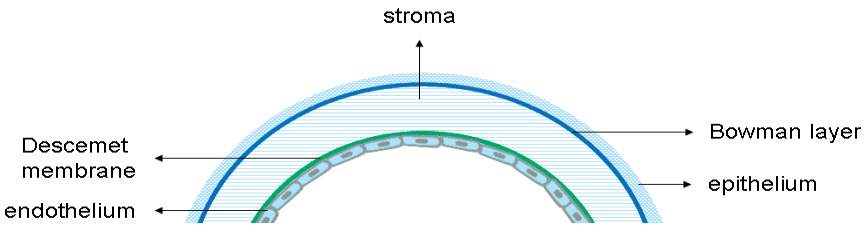

Figure 1. The anatomical layers of the cornea.
Source: Ham L. Descemet Membrane Endothelial Keratoplasty: Donor Tissue Preparation and Clinical Outcomes. Optima Grafische Communicatie Rotterdam, 2011. p. 29

The Epithelium

The corneal epithelium is constituted by 5-7 layers of non-keratinized, stratified, squamous epithelial cells admixed with a scattering of sentinel cells of the immune system including macrophages, lymphocytes, melanocytes, and Langerhans cells.[1,2] Its optical quality derives from: the evenness and regularity of its apical surface; the constancy of its thickness (precisely regulated at 50-52µm); the scarcity of organelles; and the presence of the intracytoplasmic enzyme crystalline within corneal epithelial cells.[2-4]

The corneal epithelium's basal layer contains cells linked to each other by desmosomes and tight junctions and to their underlying basement membrane by hemi-desmosomes. These cells migrate into the corneal center from the periphery (horizontally), then up toward the corneal surface (vertically); their origin appears to be a population of stem cells, located at the corneal limbus, the loss of which predisposes the cornea to persistent or non-healing corneal epithelial defects.[5] Above the basal epithelial layer are 2-3 layers of wing cells, linked by zona occludens, followed by the superficial most cells of the cornea, which are connected by tight and adherens junctions that tightly regulate corneal-environmental exchange.[6]

The Bowman Layer

The cornea's Bowman Layer (BL) consists of a thin swath of modified anterior stroma lying immediately beneath the epithelial basement membrane. Approximately 8-14µm

thick (thinning with age), BL is acellular, physically robust, and tenaciously adherent to the underlying stroma.[7] Like the stroma, it consists mostly of types V and I collagen, although its fibers are smaller and more randomly arranged.[8,9]

Surprisingly, the physiologic purpose of this discrete structure remains, to date, unclear.

Some have speculated that it functions as a strong barrier to the passage of pathogens (especially viruses) through the cornea and into the deeper structures of the eye.[10] And undoubtedly, the focal loss of BL does permit aberrant epithelial-stromal communication, which is evident in the fibrous scars that frequently form at those sites.[11-14] In addition, BL may also have some structural role in maintaining the shape/ tectonic stability of the cornea, since - for corneal ectasias - the earliest and most sensitive indicator of disease is BL degeneration.[15,16] However, because the deliberate and widespread destruction of BL by photorefractive keratoplasty (*PRK*, a common laser refractive procedure) only rarely destabilizes the cornea into severe ectasia, the architectural *raison d'etre* of BL must be more complicated and remains poorly understood.[17]

Because BL exists as an independent structure, after debriding the overlying epithelium, it may be peeled as a single sheet from the underlying stroma, after which it reliably scrolls into a single or double roll secondary to the inherent elasticity of the tissueitself.[14,18]

The Stroma

Stroma represents the bulk of the thickness and weight of the cornea: it is constituted by collagen fibrils (predominantly Types I and V) arranged into 200-250 layered sheets (lamellae) that are oriented obliquely and with interlacing fibers connecting the layers together.[1] The posterior-most layer(s) of the stroma (the so-called "Dua Layer") appear morphologically identical to adjacent stroma, but may exhibit specialized behaviors owing to their location.[19-22] Interspersed among the collagen fibers are glycoproteins, which attract cations and water, and therefore tend to cause the cornea to swell.[1] (This tendency must be counter-acted by the endothelial pump function, to be discussed below.) These glycoproteins, and the collagen structure of the stroma itself, are secreted and maintained by a population of highly metabolically active corneal keratocytes, which are most numerous in the anterior cornea.[1]

The Pre-Descemet Stroma

The injection of air or viscoelastic into the deep stroma of a human cornea not infrequently produces a cleavage plane between the bulk of the stroma (anterior) and a thin layer of anatomically indistinct stroma of variable thickness which immediately overlies the Descemet layer (posterior).[19-22] This thin band of pre-Descemet stroma is otherwise

known as the Dua layer, and while its existence has been long recognized, its importance may only be recently understood.[23]

Being composed of multiple collagen layers, the pre-Descemet stroma may confer an additional element of strength and support potentially advantageous in certain surgical circumstances. Specifically, during "big-bubble" anterior lamellar procedures, it may protect against inadvertent rupture of the Descemet membrane (itself a structure with very low tensile strength) and perforation into the anterior chamber. The pre-Descemet stroma may also be incorporated into a Descemet Membrane Endothelial Keratoplasty (DMEK) graft; this modification has given rise to the modified transplant type "Pre-Descemet Endothelial Keratoplasty" (PDEK), originally described by Agarwal in 2014.[24] Compared to conventional DMEK, PDEK may provide easier to handle tissue intra-operatively and the ability to use younger human donor tissue.[25] On the other hand, known PDEK disadvantages include smaller graft diameters (carrying fewer endothelial cells) and the possibility of optical interference generated by the additional stromal elements.[26,27]

High tensile strength is among the most notable features of the pre-Descemet stroma; some have speculated that – as a result – it may be ruptures in this tissue, rather than the relatively weak Descemet Membrane, that is responsible for the explosive deterioration seen with corneal hydrops in eyes with Keratoconus; and that, further, previously thought "Descemetoceles" may instead be "Dua-celes."[28]

The Descemet Membrane

Descemet Membrane (DM) is the basement membrane of - and secreted by - the cornea's endothelium, and lies sandwiched between the endothelium (below) and the posterior stroma (above). Composed largely of type IV collagen and laminin, it is comprised of three distinct layers: a thin non-banded zone (0.3μm thick) immediately adjacent to the stroma, an anterior banded zone (2-4μm) that thickens with advancing age, and a posterior/amorphous non-banded zone (>4μm) that features an atypical striate pattern of degeneration and wart-like collagenous excrescences known as guttae in patients with Fuchs endothelial dystrophy (FED).[29,30]

As a membrane with only tenuous connections to the overlying stroma, DM is easily stripped free as a single sheet (along with its attendant endothelium), which - like BL - also curls spontaneously into a single or double roll upon separation, owing to its own internal elasticity.[31,32]

The Endothelium

The endothelium exists as a monolayer of tightly-packed hexagonal cells that comprise the cornea's posterior surface. The number of endothelial cells per unit area is regarded as the endothelial cell density (ECD), which is maximum at birth (around 6000 cells/mm^2), declines sharply in the first year of life (to approximately 4000 cells/mm^2), and

then decreases gradually by ~3% per year until adulthood, when the loss rate slows to ~1% per year, so that - by late age - most people have approximately 2000-2500 cells/ mm^2.[33,34]

Aside from aging, other causes of reduced ECD include: prior intraocular surgery, elevated eye pressure, trauma, prolonged contact lens wear, and chronic anterior chamber inflammation.[35]

Polymegathism and pleomorphism are the hallmarks of diseased or damaged endothelium: as cells are lost, neighboring cells expand to fill the vacated space producing a cobblestone pattern of variably sized and irregularly-shaped cells.[35,36]Specular microscopy readily demonstrates these changes *in vivo* in patients with endothelial diseases and may be used to track corneal health over time.[37]

Endothelial Migration and Proliferation

The prevailing research suggests that, *in vivo*, endothelial cells neither proliferate nor replicate and remain permanently confined to a pre-mitotic, G1-phase.[38] While no definite explanation for this arrest in cell development has been discovered, candidate explanations include: the absence of autocrine/paracrine mitogenic stimulation, negative regulation by transforming growth factor beta (TGF-B; a substance that - when combined with aqueous humor - may inhibit entry into S-phase), and cell contact inhibition (a process mediated by p27kip1, a known G1-phase inhibitor).[38,39] Endothelial depletion from the central cornea prompts the inward migration of cells from the periphery to fill the vacancy. Although, previously, it was believed that these peripheral cells may be qualitatively different from central cells, perhaps possessing some additional proliferative potential, recent studies have failed to corroborate this theory.[40,41]

Nevertheless, *in vitro*, the human endothelium does appear capable of (limited) replication and growth, particularly when treated concurrently with Ethylenediaminetetraacetic acid (EDTA), viral oncogenes, or when reared in culture media with select additives including epidermal growth factor (EGF), nerve growth factor (NGF), basic fibroblast growth factor (bFGF), and animal-derived extracellular matrix (ECM).[42-51] But even under these conditions, human corneal endothelium cannot be cultured indefinitely or proliferated infinitely: in general, the cells do not survive into the long term and cannot replicate beyond a few generations. This is particularly true for cell lines obtained from older donors (>30 years) which are relatively refractory to mitogenic stimulation and require more and longer exposure before responding.[52,53]Interestingly, however, young and old endothelial cells alike contain telomeres of similar lengths.[45] This suggests both a low natural replication rate, and also, that telomere shortening is an unlikely mechanism for the diminished capacity for replication that older cells display,

which may - instead - be attributed to accumulating stresses, including (potentially) oxidative damage.[52-54]

Corneal Transparency and Hydration: The Endothelial Barrier and Pump Function

The transparency of the cornea derives from the diameter and spacing of the collagen fibers that compose it. Because both are smaller than half a wavelength of light, 90% of the *incident* light passes through, amplified by constructive interference, whereas nearly all *scattered* light is dissipated by destructive interference. As a result, under normal circumstances, the cornea

- although constituted largely of the same material as the adjacent sclera (which is totally opaque)
- remains clear.[55-58] However, if its architecture is disturbed such that the caliber or distance between collagen fibers are affected (for example, by scarring or fluid accumulation), thenthe delicate interference patterns that selectively transmit incident and rebuff scattered light are ruined, resulting in focal opacities.

Corneal hydration

The cornea's water content (78% by weight) is tightly controlled by two principle means: the epithelial barrier and the endothelial pump.[59-61]At the ocular surface, tight junctions between epithelial cells keep fluid out from above. Meanwhile, with eyes open, evaporation from the tear film creates an osmotic gradient that draws water up from the stroma below.

Along the cornea's posterior surface, endothelial cells are likewise bound together by tight junctions, albeit with frequent gaps, permitting some fluid leakage up into the stroma. This constant leak provides the primary supply of glucose, amino acids, and other nutrients to the avascular cornea. Meanwhile, the "endothelial pump" (really, a complex chain of ion transporters) creates a countercurrent, which - by osmotic gradient - directs fluid back out of the stroma and recycles it into the anterior chamber, thereby balancing the passive influx. [59-62]

Endothelial Barrier and Pump Function

CO_2 passively diffuses into endothelial cells. There, it combines with H_2O to form carbonic acid (H_2CO_3) and is cleaved by carbonic anhydrase into hydrogen ions and bicarbonate (H^+ and HCO_{3-}), both of which are then actively pumped into the stroma (**Figure 2**).[63,64]

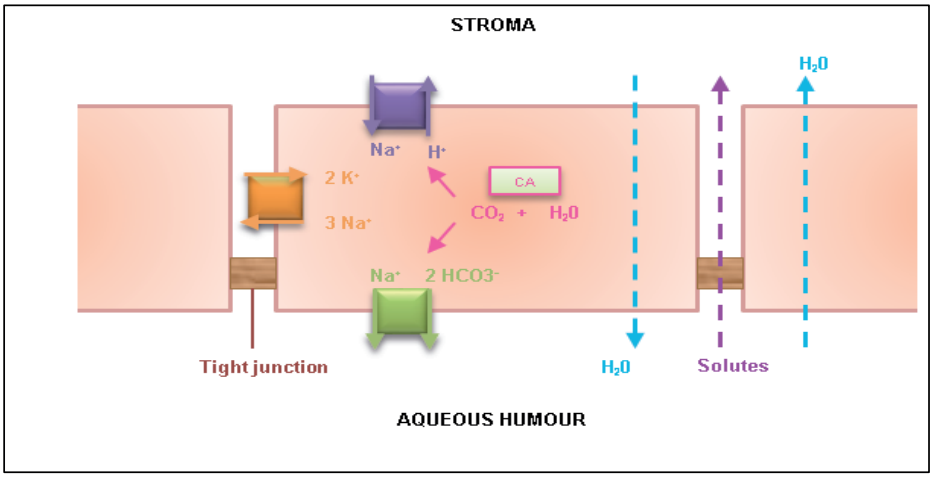

Figure 2. Ion transport systems and carbonic anhydrase (CA) functions of the corneal endothelium. Source: Ham L. Descemet Membrane Endothelial Keratoplasty: Donor Tissue Preparation and Clinical Outcomes. Optima Grafische Communicatie Rotterdam, 2011. p.32

The bicarbonate is allowed back into the cell by the cooperative actions of two basolateral channels: the Na^+-K^+ ATPase and the $1Na^+$-$2HCO_3^-$ transporter. The former pumps sodium against its concentration gradient into the stroma and the latter permits the ion's return, along with 2 molecules of bicarbonate. (Sodium also returns to the cell via basolateral Na^+-K^+-$2Cl^-$ transporters and Na^+-H^+ exchangers). Principally, it is the net flux of bicarbonate (and possibly also NaCl) that drives the osmotic gradient which draws water out of the stroma and deturgesses the cornea. [65-70]

CORNEAL TRANSPLANTATION

Corneal transplantation (or simply, *keratoplasty*) involves the exchange of donor corneal tissue - as a graft - for the patient's own diseased cornea (or a portion of it.) Whereas the operation may also be performed for tectonic and cosmetic reasons, its most common indication is visual restoration.[71]

Originally, the surgery amounted to little more than simple substitution: after excising practically the whole recipient cornea, a donor graft was sewn into position, effectively replacing the entire organ. This type of whole-corneal transplantation is traditionally known as p*enetrating keratoplasty (PK)* and is still performed today, although now less commonly, since the advent of modern partial corneal (lamellar) transplantation.[71,72]

EARLY EFFORTS IN CORNEAL TRANSPLANTATION

Scientific inquiry into the possibility of corneal transplantation began in the late 1700s. By the 1820s, the idea had matured and the term "keratoplasty" arose to designate the surgical procedure (coined independently by Himley and Reisinger).[72] Virtually all initial attempts at the operation were failures, as the early donor tissue came from animals and succumbed invariably to immunological rejection.[73] Consequently, the first successful corneal transplant was delayed until 1905 when a Slovakian ophthalmologist - Dr. Eduard Zirm - performed bilateral corneal replacement for a patient previously blinded by a chemical accident.[74]

With the essential technique established, next came improvements in tissue and tools. The Russian ophthalmologist Vladimir Filatov popularized the use of cadaveric human corneas for donor grafts and thereby established himself as the father of modern eye banking.[75] In Spain, Ramon Castroviejo performed his first successful keratoplasty in 1936 and subsequently devised a litany of useful instruments to facilitate the procedure.[76] Prophylactic antibiotics became stronger and more routine in the 1940s, steroids emerged to temper postoperative inflammation, and better corneal preservation protocols and upgraded technology (in particular, operating microscopes which enabled modern microsurgery) pushed surgical outcomes to new heights.[77]

Meanwhile, eye banks developed in parallel. The first was created in New York in 1944 by Townly Paton.[78] In 1961, the Eye Bank Association of America (EBAA) was founded and established standards for obtaining, processing, storing, and using donor tissue. By incorporating specular microscopy, eye banks learned to scrutinize the endothelial health of their corneas and to offer exclusively high quality tissue.[79] Finally, the development of MK medium by McCarey and Kaufman in 1974 enabled corneal preservation, permitting grafts to be stored and transplants planned and scheduled in advance.[80]

EVOLVING TECHNIQUES IN CORNEAL TRANSPLANTATION

Despite these revolutions in medication, instrumentation, and tissue preservation, the basic goal of the operation remained the same: total replacement of the recipient cornea with donor tissue. Complete corneal exchange (*penetrating keratoplasty*, *PK*) therefore represents the overwhelming history of the surgery.[81] It was the first, and - until at least the 1970s - the only form of corneal transplantation commonly available. Nevertheless, the operation was prone to problems, deriving principally from the bulk of the grafts and from the incisions necessary to accommodate them. Such problems include: poor wound healing, suture related difficulties, an unstable ocular surface, the

persistent threat of allograft reaction and graft rejection, and frequently, disappointing visual outcomes.[82]

The first attempts at partial corneal transplantation (*lamellar keratoplasty*, *LK*) occurred in the 1950s. While Jose Barraquer experimented with replacing the anterior corneal surface, Charles Tillet trialed posterior lamellar exchange.[83,84] Ultimately, however, both efforts failed: Barraquer's because the irregular interface between the donor and recipient tissues degraded the cornea's optical results, and Tillet's because fixating a posterior lamellar graft to the overlying stroma proved impossible with conventional suturing techniques. Sunk by disappointing results like these, LK was mostly forgotten and largely abandoned for decades.[85]

But in the 1980's, interest in anterior lamellar exchange was revived: Eduardo Archila demonstrated that an intrastromal injection of air could facilitate deeper dissection into the recipient cornea, significantly reducing the irregularity at the graft interface.[86] This gave rise to the concept of *deep anterior lamellar keratoplasty (DALK)*. Mohammed Anwar refined the technique by establishing that a single "big bubble" could be generated between the recipient stroma and its Descemet Membrane (DM), and that - by expanding this bubble - the two tissues might be totally separated.[87] Independently, Gerrit Melles showed that a similar feat was possible using visco-elastic instead of air.[88] He also devised a method for manually dissecting the entire host stroma from its DM using a series of curved spatulas and the "air-endothelium reflex" (the location of the reflection produced by the tips of his instruments) to precisely judge the depth of the ongoing dissection.[89]

Meanwhile, Melles also solved the primary problem with posterior lamellar transplantation: fixating the grafts to the recipient's stroma. Whereas prior attempts to suture the donor tissue had failed, Melles discovered that - instead - an air bubble could be left inside the anterior chamber and the force of its buoyancy sufficed to hold the graft in place. As a result, in 1998, *posterior lamellar keratoplasty (PLK)* became feasible.[90] In the States, the operation was rebranded *Deep Lamellar Endothelial Keratoplasty (DLEK)* by Mark Terry.[91] But because DLEK proved too technically challenging for widespread adoption (since it required meticulously dissecting matching stromal/endothelial lenticules from the recipient and the donor corneas, then exchanging them), Melles revised the procedure into a modified version which he dubbed *Descemet Stripping Endothelial Keratoplasty (DSEK)*.[92] Compared to DLEK, DSEK was simpler and easier: while the two operations employed identical donor tissue, DSEK abandoned the stromal dissection that DLEK required in favor of merely stripping the recipient endothelium and DM. This dramatically lessened the technical challenge of the surgery and established DSEK as the global treatment of choice for endothelial disorders, especially after Mark Gorovoy popularized the use of microkeratome-cut DSEK grafts (thus effecting a tweak to the nomenclature: Descemet Stripping *Automated* Endothelial Keratoplasty, DSAEK).[93]

Although an improvement over DLEK, DS(A)EK nevertheless retained some of its predecessor's limitations. In particular, both operations entailed the transplantation of some amount of donor stroma into the recipient eye, and this extra tissue probably compromised the cornea's optical performance.[94] Consequently, Melles further refined the operation to *Descemet Membrane Endothelial Keratoplasty (DMEK),* which differed from DSEK in that its graft was constituted exclusively of DM and its endothelium, without any attendant stroma.[95] Therefore, with DMEK - and for the first time in the history of posterior lamellar exchange - an exact one- to-one exchange of donor for diseased tissue was achieved, and the natural, physiologic anatomy of the cornea was restored.[96]

Endothelial keratoplasty (EK) is the umbrella term has that emerged to describe these various formulations of posterior lamellar transplantation (PLK, DLEK, DS(A)EK, and DMEK). Whereas PLK and DLEK have been largely superseded, DS(A)EK and DMEK currently co-exist as the two most common treatments for endothelial dysfunction worldwide.[97] Since their original description, both operations have changed considerably: in general, DS(A)EK grafts have gotten thinner (i.e. they incorporate less donor stroma), promoting better visual outcomes through reduced scarring at the transplant interface.[98] Meanwhile, DMEK grafts have likewise experienced several shape changes. Until recently, all consisted of circular sheets of DM and endothelium cut from the center of donor corneas. But in 2014, it was discovered that - rather than harvesting merely the central, circular, island of DM and endothelium - instead, the entire sheet could be bisected and then stripped to produce two, large, hemi-circular grafts; each of which may be transplanted into separate patients.[99] This new surgical variant has been named Hemi-DMEK, and it appears to offer results comparable to conventional DMEK while doubling the pool of donor tissue available for transplant.[100,101]

Aside from Hemi-DMEK, other modifications to the basic DMEK technique include: *Descemet membrane endothelial transfer* (*DMET*, in which a DMEK graft is injected into the recipient eye but not appositioned against the host stroma, and corneal clearance occurs after some delay by endothelial cell migration)[102,103], *DMEK-S* (a largely abandoned way to prepare DMEK grafts by microkeratome that leaves the tissue with a rim of stroma to facilitate intraoperative handling)[104], and *Pre-Descemets Endothelial Keratoplasty* (*PDEK*, which is similar to conventional DMEK except that the graft is 20µm thicker because it also incorporates a thin layer of posterior stroma).[105]

Alongside these innovations in posterior lamellar transplantation, recently, a new operation has emerged for patients with corneal ectasias: Bowman Layer (BL) transplantation.[106] The procedure entails manually dissecting a pocket within the mid-stroma of a recipient cornea and implanting a graft consisting of an isolated, donor BL. Subsequent healing both flattens and "fixes" the cornea into a more normal configuration that resists further disease progression.[106,107]

Thereby, corneal ectasias may be halted (even partially reversed). And because the operation makes no surface incisions, requires no sutures, and transplants only thin, acellular material (and thus provokes little-to-no immunological reaction), BL transplantation may avoid many of the most common complications of PK and even DALK.[108]

THESIS OUTLINE

This thesis concerns these modern developments in transplantation tactics: specifically, the recent innovations in minimally invasive anterior and posterior lamellar keratoplasty.

The first section concerns anterior lamellar techniques: Chapter 2 summarizes the current state of evidence regarding the outcomes of the various operations; Chapters 3 provides the results from the first cohort of patients to receive the operation, and the data from the first American patient to receive the transplantation is described in Chapter 4. Chapter 5 concludes the section by describing the most significant controversies that are outstanding in the field of anterior lamellar transplantation today.

The thesis's second section is dedicated to posterior lamellar operations, mostly DMEK. A general review distinguishing DMEK from its predecessors is provided in Chapter 6, and the longevity/ cell density of the grafts over time is the subject of Chapter 7. DMEK's results in phakic (vs. pseudophakic) eyes is discussed in Chapter 8.

Finally, Chapters 9 and 10 provide a survey of all results, along with a general discussion and brief conclusion.

REFERENCES

1. Sabet S, Adamopoulou A. Basic Structure and Function of the Human Cornea and Adnexal Structures. In: Copeland R and Afshari N (Ed.). Copeland Afshari's Principles and Practice of Cornea. Jaypee Brothers Medical Publishers, 2013.
2. Qazi Y, Hamrah P. Corneal Allograft Rejection: Immunopathogenesis to Therapeutics. J Clin Cell Immunol. 2013 Nov 20; 2013(Suppl 9): 006.
3. Maurice D. The location of the fluid pump in the cornea. J Physiol. 1972; 221: 43–54.
4. Hodson S, Miller F. The bicarbonate ion pump in the endothelium which regulates the hydration of rabbit cornea. J Physiol. 1976; 263: 563–577.
5. Daniels JT, Harris AR, Mason C. Corneal epithelial stem cells in health and disease. Stem Cell Rev. 2006;2:247-54.
6. Maurice DM. The cornea and sclera, In: Davidson H (Ed.). The Eye. New York Academic, 1984.
7. Germundsson J, Karanis G, Fagerholm P, Lagali N. Age-related thinning of Bowman's layer in the human cornea in vivo. Invest Ophthalmol Vis Sci. 2013;54:6143-9.
8. Gordon MK, Foley JW, Birk DE, Fitch JM, Linsenmayer TF. Type V collagen and Bowman's membrane. Quantitation of mRNA in corneal epithelium and stroma. JBiol Chem. 1994;269:24959-66.
9. Nakayasu K, Tanaka M, Konomi H, Hayashi T. Distribution of types I, II, III, IV and V collagen in normal and keratoconus corneas. Ophthalmic Res. 1986;18:1-10.
10. Holmberg K. The fine structure of Bowman's layer and the basement membrane of the corneal epithelium. Am J Ophthalmol. 1960;50:1013-21.
11. Netto MV, Mohan RR, Sinha S, Sharma A, Dupps W, Wilson SE. Stromal haze, myofibroblasts, and surface irregularity after PRK. Exp Eye Res 2006; 82:788-797
12. Møller-Pedersen T. On the structural origin of refractive instability and corneal haze after excimer laser keratectomy for myopia. Acta Ophthalmol Scand Suppl 2003; 237:1-20
13. Lagali N, Germundsson J, Fagerholm P. The role of Bowman's layer in corneal regeneration after phototherapeutic keratectomy: a prospective study using in vivo confocal microscopy. Invest Ophthalmol Vis Sci. 2009;50:4192-8.
14. Lie J, Droutsas K, Ham L. Isolated Bowman layer transplantation to manage persistent subepithelial haze after excimer laser surface ablation. J Cataract Refract Surg. 2010;36:1036-41.
15. Sykakis E, Carley F, Irion L, Denton J, Hillarby MC. An in depth analysis of histopathological characteristics found in keratoconus. Pathology. 2012;44:234-9.
16. Zimmermann DR, Fischer RW, Winterhalter KH, Witmer R, Vaughan L. Comparative studies of collagens in normal and keratoconus corneas. Exp Eye Res. 1988;46:431-42.
17. Dawson DG, Grossniklaus HE, McCarey BE, Edelhauser HF. Biomechanical and wound healing characteristics of corneas after excimer laser keratorefractive surgery: is there a difference between advanced surface ablation and sub-Bowman's keratomileusis? J Refract Surg. 2008;24: S90-6.
18. Groeneveld-van Beek EA, Parker J, Lie JT. Donor Tissue Preparation for Bowman Layer Transplantation. Cornea. 2016 Jun 29. [Epub ahead of print]
19. McKee HD, Irion LC, Carley FM, Jhanji V, Brahma AK. Residual corneal stroma in big- bubble deep anterior lamellar keratoplasty: a histological study in eye-bank corneas. Br J Ophthalmol. 2011; 95(10):1463-5
20. Dua HS, Faraj LA, Said DG, Gray T, Lowe J. Human corneal anatomy redefined: a novel pre-Descemet's layer (Dua's layer). Ophthalmology. 2013;120(9):1778-85

21. Schlötzer-Schrehardt U, Bachmann BO, Tourtas T, et al. Ultrastructure of the posterior corneal stroma. Ophthalmology. 2015;122(4):693-9
22. McKee HD, Irion LC, Carley FM, et al. Re: Dua et al.: Human corneal anatomy redefined: a novel pre-Descemet layer (Dua's layer) 715 (Ophthalmology 2013; 120:1778-85). Ophthalmology. 2014; 121(5): e24–5.
23. Dua HS, Mastropasqua L, Faraj L, et al. Big bubble deep anterior lamellar keratoplasty: the collagen layer in the wall of the big bubble is unique. Acta Ophthalmol. 2015;93(5):427–430.
24. Agarwal A, Dua H, Narang P, et al. Pre-Descemet's endothelial keratoplasty (PDEK). Br J Ophthalmol. 2014;98:1181-5.
25. Dua HS, Termote K, Kenawy MB et al. Scrolling Characteristics of Pre-Descemet Endothelial Keratoplasty Tissue: An Ex Vivo Study. Am J Ophthalmol. 2016;166:84-90.
26. Agarwal A, Agarwal A, Narang P, Kumar DA, Jacob S. Pre-Descemet Endothelial Keratoplasty With Infant Donor Corneas: A Prospective Analysis. Cornea. 2015;34:859- 65.
27. Dua HS, Said DG. Pre-Descemets endothelial keratoplasty: the PDEK clamp for successful PDEK. Eye (Lond). 2017 Feb 17. [Epub ahead of print]
28. Dua HS, Said DG. Clinical evidence of the pre-Descemets layer (Dua's layer) in corneal pathology. Eye (Lond). 2016;30:1144-5.
29. Johnson DH, Bourne WM, Campbell RJ. The ultrastructure of Descemet's membrane. I. Changes with age in normal corneas. Arch Ophthalmol. 1982;100:1942-7.
30. Bourne WM, Johnson DH, Campbell RJ. The ultrastructure of Descemet's membrane. III. Fuchs' dystrophy. Arch Ophthalmol. 1982;100:1952-5.
31. Lie JT, Birbal R, Ham L, van der Wees J, Melles GR. Donor tissue preparation for Descemet membrane endothelial keratoplasty. J Cataract Refract Surg. 2008;34:1578-83.
32. Groeneveld-van Beek EA, Lie JT, van der Wees J, Bruinsma M, Melles GR. Standardized 'no-touch' donor tissue preparation for DALK and DMEK: harvesting undamaged anterior and posterior transplants from the same donor cornea. Acta Ophthalmol. 2013;91:145-50.
33. McCarey BE, Edelhauser HF, Lynn MJ. Review of corneal endothelial specular microscopy for FDA clinical trials of refractive procedures, surgical devices, and new intraocular drugs and solutions. Cornea. 2008;27:1-16.
34. Laule A, Cable MK, Hoffman CE, Hanna C. Endothelial cell population changes of human cornea during life. Arch Ophthalmol. 1978;96:2031-5.
35. Capella JA. Regeneration of endothelium in diseased and injured cornea. Am J Ophthalmol. 1972; 74:810-7.
36. Ikebe M, Takamatsu T, Ito M, et al. Changes in nuclear DNA content and cell size of injured human corneal endothelium. Exp Eye Res. 1988;47:205-15.
37. Sturrock GD, Sherrard ES, Rice NS. Specular microscopy of the corneal endothelium. Br J Ophthalmol. 1978;62:809-14.
38. Joyce NC. Proliferative capacity of the corneal endothelium. Prog Retin Eye Res. 2003;22:359-389.
39. Joyce NC, Harris DL, Mello DM. Mechanisms of mitotic inhibition in corneal endothelium: contact inhibition and TGF-beta2. Invest Ophthalmol Vis Sci. 2002;43:2152-2159
40. Amann J, Holley GP, Lee SB, Edelhauser HF. Increased endothelial cell density in the paracentral and peripheral regions of the human cornea. Am J Ophthalmol. 2003;135:584- 590.
41. Konomi K, Zhu C, Harris D, Joyce NC. Comparison of the proliferative capacity of human corneal endothelial cells from the central and peripheral areas. Invest Ophthalmol Vis Sci. 2005;46:4086-4091

42. Baum JL, Niedra R, Davis C, Yue BY. Mass culture of human corneal endothelial cells. Arch Ophthalmol. 1979;97:1136- 1140.
43. Sumide T, Nishida K, Yamato M, Ide T, Hayashida Y, Watanabe K, Yang J, Kohno C, Kikuchi A, Maeda N, Watanabe H, Okano T, Tano Y. Functional human corneal endothelial cell sheets harvested from temperature-responsive culture surfaces. FASEB J. 2006;20:392-394.
44. Slettedal JK, Lyberg T, Røger M, Beraki K, Ramstad H, Nicolaissen B. Regeneration with proliferation of the endothelium of cultured human donor corneas with extended postmortem time. Cornea. 2008;27:212-219
45. Senoo T, Joyce NC. Cell cycle kinetics in corneal endothelium from old and young donors. Invest Ophthalmol Vis Sci. 2000;41:660–667.
46. Senoo T, Obara Y, Joyce NC. EDTA promotes proliferation in human corneal endothelium. Invest Ophthalmol Vis Sci. 2000;41:2930–2935.
47. Wilson SE, Weng J, Blair S, He YG, Lloyd S. Expression of E6/E7 or SV40 large T antigen-coding oncogenes in human corneal endothelial cells indicates regulated high- proliferative capacity. Invest Ophthalmol Vis Sci. 1995;36:32-40.
48. Schonthal AH, Hwang JJ, Stevenson D, Trousdale MD. Expression and activity of cell cycle-regulatory proteins in normal and transformed corneal endothelial cells. Exp Eye Res. 1999;68: 531-539.
49. Shao Y, Hu D, Chen J. A study on effect of bFGF, EGF and NGF on growth of cultured human corneal endothelial cells. Yan Ke Xue Bao. 2008;24:9-12.
50. Blake DA, Yu H, Young DL, Caldwell DR. Matrix stimulates the proliferation of human corneal endothelial cells in culture. Invest Ophthalmol Vis Sci. 1997;38:1119-1129.
51. Miyata K, Drake J, Osakabe Y, Hosokawa Y, Hwang D, Soya K, Oshika T, Amano S. Effect of donor age on morphologic variation of cultured human corneal endothelial cells. Cornea. 2001;20: 59-63.
52. Beckman KB, Ames BN. The free radical theory of aging matures. Physiol Rev. 1998;78:547-581.
53. Joyce NC, Navon SE, Roy S, Zieske JD. Expression of cell cycle-associated proteins in human and rabbit corneal endothelium in situ. Invest Ophthalmol Vis Sci. 1996;37:1566– 1575
54. Joyce NC. Cell cycle status in human corneal endothelium. Exp Eye Res. 2005;81:629- 638.
55. Hassell JR, Birk DE. The molecular basis of corneal transparency. Exp Eye Res. 2010;91:326-335.
56. Maurice DM. The structure and transparency of the cornea. J Physiol. 1957;136:263-286.
57. Hart RW, Farrell RA. Light scattering in the cornea. J Opt Soc Am. 1969;59:766-774.
58. Jester JV, Moller-Pedersen T, Huang J et al. The cellular basis of corneal transparency: evidence for 'corneal crystallins'. J Cell Sci. 1999;112:613-622.49.
59. Fischbarg J, Maurice DM. An update on corneal hydration control. Exp Eye Res. 2004;78:537-541.
60. Meek KM, Leonard DW, Connon CJ, Dennis S, Khan S. Transparency, swelling and scarring in the corneal stroma. Eye (Lond). 2003;17:927-936.
61. Hart WM. The Cornea. In: Adler's physiology of the eye. 9th ed. St. Louis: Moby-Year Book. 1992;3: 55-58.
62. Noske W, Fromm M, Levarlet B, Kreusel KM, Hirsch M. Tight junctions of the human corneal endothelium: morphological and electrophysiological features. Ger JOphthalmol. 1994;3:253-257.
63. Bonanno JA. Identity and regulation of ion transport mechanisms in the corneal endothelium. Prog Retin Eye Res. 2003;22:69-94.
64. Fischbarg J. Active and passive properties of the rabbit corneal endothelium. Exp Eye Res. 1973; 15:615-638. 5

65. Huff JW, Green K. Demonstration of active sodium transport across the isolated rabbit corneal endothelium. Curr Eye Res. 1981;1:113-114.
66. Lim JJ. Na+ transport across the rabbit corneal endothelium. Curr Eye Res. 1981;1:255- 258.
67. Whikehart DR, Soppet DR. Activities of transport enzymes located in the plasma membranes of corneal endothelial cells. Invest Ophthalmol Vis Sci. 1981;21:819-825.
68. Jentsch TJ, Keller SK, Wiederholt M. Ion transport mechanisms in cultured bovine corneal endothelial cells. Curr Eye Res. 1985;4:361-369.
69. Sun XC, Li J, Cui M, Bonanno JA. Role of carbonic anhydrase IV in corneal endothelial HCO3- transport. Invest Ophthalmol Vis Sci. 2008;49:1048-1055.
70. Fischbarg J. Mechanism of fluid transport across corneal endothelium and other epithelial layers: a possible explanation based on cyclic cell volume regulatory changes. Br J Ophthalmol. 1997;81: 85-89.
71. Williams KA, Muehlberg SM, Lewis RF, Coster DJ. How successful is corneal transplantation? A report from the Australian Corneal Graft Register. Eye. 1995;9:219- 227.
72. Soong MD H. Corneal Transplantation. In: Spaeth G, ed. Ophthalmic Surgery: Principles and Practice. Philadelphia, PA: Elsevier; 2003:139-160
73. Power H: IV international Congress of Ophthalmology. Vol. IV. P.172. London. 1872
74. Zirm EK: Eine erfolgreiche totale keratoplastik. V. Graefes Arch Ophthalmol. 1906;64:580-593
75. Filatov VP. Transplantation of the cornea. Arch Ophthalmol. 1935;13,321-347
76. Murube J. Ramon Castroviejo centenary: a life dedicated to corneal transplantation. Surv Ophthalmol. 2005;50:215-225.
77. Vajpayee RB. Corneal transplantation. First edition, New Delhi, India, 2002;3-5.
78. Paton D. The founder of the first eye bank: R. Townley Paton, MD. Refract Corneal Surg. 1991;7: 190-194.
79. Maurice DM. A scanning slit optical microscopy. Invest Ophthalmol Vis Sci. 1974;13:1033-1037
80. Lindstrom RL. Advances in corneal preservation. Trans Am Ophthalmol Soc. 1990;88:555-648.
81. Terry MA. Endothelial keratoplasty: why aren't we all doing Descemetmembrane endothelial keratoplasty? Cornea. 2012;31:469-71
82. Price MO, Price FW Jr. Endothelial keratoplasty - a review. Clin Experiment Ophthalmol. 2010;38: 128-140.
83. Barraquer JI. Lamellar keratoplasty. (Special techniques). Ann Ophthalmol. 1972;4:437- 469.
84. Tillett CW. Posterior lamellar keratoplasty. Am J Ophthalmol. 1956;41:530-533.
85. Culbertson WW. Endothelial replacement: flap approach. Ophthalmol Clin North Am. 2003;16: 113-118.
86. Archila EA. Deep lamellar keratoplasty dissection of host tissue with intrastromal air injection. Cornea. 1984-1985;3:217-8.
87. Anwar M, Teichmann KD. Big-bubble technique to bare Descemet's membrane in anterior lamellar keratoplasty. J Cataract Refract Surg. 2002;28(3):398-403
88. Melles GR, Remeijer L, Geerards AJ, Beekhuis WH. A quick surgical technique for deep, anterior lamellar keratoplasty using visco-dissection. Cornea. 2000;19(4):427-32
89. Melles GR, Rietveld FJ, Beekhuis WH, Binder PS. A technique to visualize corneal incision and lamellar dissection depth during surgery. Cornea. 1999;18(1):80-6
90. Melles GR, Eggink FA, Lander F, et al. A surgical technique for posterior lamellar keratoplasty. Cornea. 1998;17:618-26.
91. Terry MA, Ousley PJ. Deep lamellar endothelial keratoplasty in the first United States patients: early clinical results. Cornea. 2001;20:239-43.

92. Melles GR, Lander F, Nieuwendaal C. Sutureless, posterior lamellar keratoplasty: a case report of a modified technique. Cornea. 2002;21:325-7.
93. Gorovoy MS. Descemet-stripping automated endothelial keratoplasty. Cornea. 2006;25:886-9.
94. Dirisamer M, Parker J, Naveiras M, et al. Identifying causes for poor visual outcome after DSEK/DSAEK following secondary DMEK in the same eye. Acta Ophthalmol. 2013;91:131-9.
95. Melles GR, Ong TS, Ververs B, van der Wees J. Descemet membrane endothelial keratoplasty (DMEK). Cornea. 2006;25:987-90.
96. Livny E, Parker JS, van der Kaaij M et al. Postmortem ultrastructural analysis of a cornea transplanted with Descemet membrane endothelial keratoplasty. Cornea. 2014;33:790-4
97. Price FW Jr, Price MO. Evolution of endothelial keratoplasty. Cornea. 2013;32 Suppl 1:S28-32.
98. Dapena I, Ham L, Melles GR. Endothelial keratoplasty: DSEK/DSAEK or DMEK--the thinner the better? Curr Opin Ophthalmol. 2009;20:299-307.
99. Lam FC, Baydoun L, Dirisamer M, Lie J, Dapena I, Melles GR. Hemi-Descemet membrane endothelial keratoplasty transplantation: a potential method for increasingthe pool of endothelial graft tissue. JAMA Ophthalmol. 2014;132:1469-73.
100. Gerber-Hollbach N, Parker J, Baydoun L, Liarakos V, Ham L, Dapena I, Melles G. "Preliminary outcome of hemi-DMEK for Fuchs Endothelial Dystrophy." Br J Ophthalmol. 2016 Feb 2. [Epub ahead of print]
101. Lam FC, Baydoun L, Satué M, et al. One year outcome of hemi-Descemet membrane endothelial keratoplasty. Graefes Arch Clin Exp Ophthalmol. 2015;253:1955-8
102. Dirisamer M, Ham L, Dapena I, van Dijk K, Melles GR. Descemet membrane endothelial transfer: "free-floating" donor Descemet implantation as a potential alternative to "keratoplasty". Cornea. 2012;31:194-7.
103. Lam FC, Bruinsma M, Melles GR. Descemet membrane endothelial transfer. Curr Opin Ophthalmol. 2014;25:353-7.
104. Studeny P, Farkas A, Vokrojova M, Liskova P, Jirsova K. Descemet membrane endothelial keratoplasty with a stromal rim (DMEK-S). Br J Ophthalmol. 2010;94:909- 914.
105. Agarwal A, Dua HS, Narang P, et al. Pre-Descemet's endothelial keratoplasty (PDEK).Br J Ophthalmol. 2014 Sep;98(9):1181-5.
106. van Dijk K, Parker J, Tong M, Ham L, Lie J, Groeneveld-van Beek E, Melles G. "Mid-stromal isolated Bowman layer graft to reduce and stabilize advanced keratoconus as an alternative to penetrating or deep anterior lamellar keratoplasty." JAMA Ophthalmol. 2014;132:495-501.
107. van Dijk K, Liarakos V, Parker J, Ham L, Lie JT, Groenveld-van Beek EA, Melles GRJ. "Bowman layer transplantation to reduce and stabilize progressive, end stage, keratoconus." Ophthalmology. 2015;122(5):909-17.
108. Parker JS, van Dijk K, Melles GR. Treatment options for advanced keratoconus: A review. Surv Ophthalmol. 2015;60:459-80

Chapter 2

Treatment Options for Advanced Keratoconus: A Review

Jack S. Parker[1-3], Korine van Dijk[1-2], Gerrit Melles[1-2,4]

[1]Netherlands Institute for Innovative Ocular Surgery, Rotterdam, The Netherlands; [2]Melles Cornea Clinic Rotterdam, The Netherlands; [3]UAB Callahan Eye Hospital, Birmingham, Alabama; [4]Amnitrans EyeBank Rotterdam, The Netherlands.

ABSTRACT

Traditionally, the mainstay of treatment for advanced keratoconus (KC) has been either penetrating or deep anterior lamellar keratoplasty (PK or DALK, respectively). The success of both operations, however, has been somewhat tempered by a well-known litany of potential difficulties and complications, both intra- and postoperatively. These include suture and wound healing problems, progression of disease in the recipient rim, allograft reaction, and persistent irregular astigmatism. Taken together, these constitute a formidable array and have been the inspiration for an ongoing search for less troublesome therapeutic alternatives. To that end, a handful of alternative techniques have been tried against severely ectatic corneas with variable degrees of success. These include ultra-violet cross-linking (UV-CXL) and intracorneal ring segments (ICRS), both which were originally constrained in their indication exclusively to eyes with mild to moderate disease. More recently, Bowman Layer (BL) Transplantation has been introduced for reversing corneal ectasia in eyes with advanced KC, re-enabling comfortable contact lens wear and permitting PK and DALK to be postponed or avoided entirely. This article offers a summary of the current and emerging treatment options for advanced KC, aiming to provide the thoughtful corneal specialist useful information in selecting the optimal therapy for his individual patients.

KEYWORDS: Advanced keratoconus, Bowman layer transplantation, UV cross-linking, DALK, intracorneal ring segments, review

I. INTRODUCTION

Though the precise definition of "advanced" KC remains somewhat unsettled in the ophthalmic community, most specialists would agree that the disease has assumed a fairly late stage when spectacle correction is insufficient, continued contact lens (CL) wear is intolerable, and visual acuity has fallen to unacceptable levels. The traditional recourse at this point has been to reluctantly proceed with either a PK or DALK. While visual acuity not infrequently improves – at least initially – this commonly comes at a cost. Namely, the obligation to manage a litany of potential complications including allograft reaction, suture and wound healing problems, progression of the disease in the recipient rim, and persistent irregular astigmatism. None of these may be regarded as insignificant, and together, they are the reason why transplantation has traditionally been reserved as a last resort for desperate eyes. To combat these issues, a number of innovations have been introduced at the level of surgical technique, instrumentation, and tissue preparation. Moreover, there has been a strong push, as of late, to extend some of the technologies originally devised to treat early to intermediate stage KC and to apply them to cases of advanced disease. Specifically, UV-CXL and ICRS have been evaluated for this purpose, with some demonstrated success. Still, many severely diseased corneas remain unsuitable candidates for either of these two new techniques and are therefore typically relegated to the usual transplantation tactics. Recently, however, Bowman Layer (BL) Transplantation has been introduced as an alternative to PK/ DALK in eyes with advanced KC, unsuitable for either UV-CXL or ICRS. By supplying a physical splint to mechanically bolster the cornea, ectasia may be stabilized and reduced, re-enabling comfortable CL wear and sparing the patient a more drastic transplantation operation with all its potential complications. This article offers a summary of the current and emerging treatment options for advanced KC: their indications and contraindications, expected outcomes and limitations. We conclude with a few remarks about what we have observed in applying these treatments and what they may allow us to speculate about future therapeutic options.

II. TERMINOLOGY AND STAGING

Typically, KC is described as a bilateral, non-inflammatory condition of ongoing corneal ectasia.[190,275] That consensus definition notwithstanding, considerable controversy exists regarding how best to grade disease severity. While the Amsler-Krumiech scale is still the most widely used for that purpose, two obstacles stand in the way of its universal acceptance. First, it is increasingly being viewed as antiquated or outdated, since it relies on relatively "old" indices (corneal steepness, refractive change, the presence of scar-

ring) whereas newer grading schemes employ a variety of detailed metrics of corneal structure provided by anterior segment optical coherence tomography (AS-OCT) and Pentacam imaging. [1,156,170,233] Second, Amsler-Krumeich grades do not always correlate well with disease impact. Not uncommonly, eyes with "low" scores (indicating milder disease) may develop CL intolerance resulting in poor functional vision and significant disability. On the other hand, some eyes with "high" scores (indicating severe disease) may nevertheless remain CL tolerant, and thereby continue to enjoy relatively good functional vision with few complaints.[286] These two factors combined – first, the growing number of alternate, competing grading schemes; and second, the Amsler-Krumeich's uncertain ability to predict the actual burden of disease – have made objective scoring of disease severity (especially moderate versus advanced) a controversial matter.

For practical purposes, however, the term "advanced" KC may properly apply to any case with unacceptably poor spectacle distance vision and contact lens intolerance. It describes, then, a category of "surgical eyes", regardless of their measured corneal parameters. The advantages of this conventional definition are, primarily, that it is reasonable and useful. It does not depend on any specialized imaging device, nor does it require that any particular grading scheme be endorsed. And, with the discussion narrowed to "eyes having failed non-operative management," the relative advantages and disadvantages of the various surgical options may come to the front of the conversation, facilitating direct comparison.

III. OPERATIONS AND THEIR INDICATIONS

For most of the surgical history of the disease, advanced KC has been treated with PK. Increasingly, however, DALK is becoming the preferred surgical option (largely thanks to improvements in operative technique), now representing 10-20% of all transplants for KC and 30% when eyes with previous hydrops are excluded.[36,280,350] Meanwhile, UV-CXL and ICRS have likewise seen their roles expanded: whereas both were once regarded as suitable only for mild to moderate cases, there is now growing support for their use in advanced disease as well.[62,235,268,273] Finally, in 2014, BL transplantation was introduced for advanced KC with extreme thinning / steepening.[339]

These five operations (PK, DALK, UV-CXL, ICRS, and BL transplantation) currently represent the available treatment options for advanced KC. Although, historically, other procedures have been tried, most have enjoyed only short runs of popularity. Examples include epikeratophakia and conductive keratoplasty, neither of which is currently regarded as effective in the long term, particularly when compared to the above five alternatives.[30,172,257,316]

A. Special Considerations:

1. *Corneal Thickness*

Corneal thickness (or more accurately, corneal thinness) rarely poses an insuperable problem in the performance of a successful PK for advanced KC. An exception exists for eyes with significant peripheral thinning: if an oversized graft is required, complications including allograft reaction and glaucoma become more likely.[202,315] In these eyes, DALK or a modified procedure ("Tuck-in lamellar keratoplasty" to be described later) may be preferred.

For DALK, thin corneas pose a separate difficulty. Because corneal thinning is associated with concomitant Descemet membrane (DM) weakness and fragility, severely affected eyes carry an elevated risk for perforation. This is especially true if the operation is performed using the Anwar "Big-bubble" technique which may result in inadvertent DM "blowout" with bubble expansion.[239] Therefore, in cases of severe thinning, the preferred technique for DALK may be Melles manual dissection in which the overlying stroma is carefully cut free (instead of pneumatically separated) from the underlying DM, using an air bubble in the anterior chamber as a reference plane to judge depth of dissection.

The debate is robust over the suitability of UV-CXL in thin corneas. The original studies proscribed application in eyes with central corneal thicknesses (CCTs) less than 400µm due to known risks of endothelial damage.[131,352,353] Even in corneas well above this thickness threshold however, there are a number of well documented reports of endothelial failure after treatment.[26,123,139,298,341] Nevertheless, recently there has been a push to expand the use of UV-CXL into eyes with very thin corneas (<400µm) by way of a variety of ingenious modifications to the originally described (Dresden) protocol. Broadly, these consist of attempts to artificially or temporarily thicken the cornea before treatment. To this end, some practitioners leave the epithelium-on (rather than debriding it) to confer extra thickness.[88,115,178,219,287,314] The primary objection to this tactic is that it may substantially reduce the procedure's effectiveness.[56,174,184] A more common solution is to substitute a hypotonic riboflavin solution for the usual isotonic one, thereby swelling the cornea just prior to UV irradiation.[142,278] The success of such a strategy is somewhat difficult to evaluate owing to the large heterogeneity in protocols in published reports used to achieve this end.[15,123,341] Moreover, the vast majority of such studies concern corneas just barely thinner than the recommended floor-value of 400µm, with relatively few including cases of severe thinning (<350µm). The totality of evidence seems to suggest that with the currently popular thickening regimes, pre-operative treatment with hypotonic riboflavin results in a significant increase in central corneal thickness (CCT), but a much smaller increase in thinnest point thickness (TPT).[291] In addition, the process of crosslinking itself – the actual application of energy – may result in an intraoperative thinning, exposing the endothelium to a higher level of radiation

despite "adequate" pre-procedural thickness (especially if an eye speculum is used for a prolonged period during the procedure, which tends to promote stromal dehydration and thinning).[153,175,198,229,291,308] There are also theoretical objections that in transiently hydrating the cornea, the density and proximity of collagen fibers are reduced, thereby lowering the potential efficacy of their crosslinking.[3,143,246] For all of these reasons, there is currently little to recommend UV-CXL in corneas thinner than 400µm.

Although ICRS themselves come in a variety of designs, all require a minimum corneal thickness at the site of their insertion and along the length of their path of 400µm.[342] Therefore, eyes with severe thinning are often ineligible. Even when eligible, those with TPTs <400µm seem to experience worse visual outcomes and more complications; especially if the area of greatest thinning is situated inferiorly, a location which tends to promote the creation of unintentionally shallow segment channels. The shallower a segment is placed, the greater the likelihood of subsequent ocular surface problems including epithelial breakdown, infectious keratitis, and subsequent extrusion because the mechanical stress of the ring segment is borne by a thinner layer of overlying stroma.[200,300,363]

Especially thin corneas do not seem to pose any special difficulty in the performance of BL transplantation, except to make manual stromal dissection a slightly more difficult prospect by raising the chances of inadvertent DM perforation, just as with a Melles manual DALK procedure.

2. Maximal Corneal Steepness

Preoperative corneal steepness is not currently believed to be an independent risk factor for poor performance after PK. There is evidence, however, that eyes with advanced KC and central curvatures >60 diopters (D) may regularly experience worse outcomes after DALK owing to the high incidence of DM folds developing over the visual axis after surgery.[241] These appear to arise from size mismatch between donor and recipient tissues: the stretched recipient DM is invariably of a greater surface area than the posterior surface of the donor in direct proportion to the pre-op degree of corneal ectasia. When the two tissues are placed in apposition, necessarily, DM folds must develop and these tend to undermine the optical performance of the eye (though these folds may spontaneously resolve, usually one year after surgery. Additionally, it may be possible to displace these folds into the corneal periphery, out of the visual axis, by slight modification of the operative technique).[301]

Steeper corneas are more likely to undergo flattening after UV-CXL (although, only rarely does the magnitude of this flattening exceed 2D).[135,305,326,351] However, there may be an elevated risk of failure – that is, continued progression – in corneas steeper than 58D (particularly if the cone is eccentrically located) and an increased risk of losing vision

after the procedure with a steepness >55D, possibly because the topographic outcomes may be more variable and less predictable.[21,134,157,187,192]

Traditionally, the use of ICRS has been constrained to eyes with maximum Ks <58D, since values much exceeding these are associated with poorer visual outcomes and more complications including segment migration, extrusion, and stromal melting. Although newer segments designs have mitigated some of these issues, still, use in corneas steeper than 58D is often discouraged.[6,8,210]

BL transplantation was devised specifically for use in steep corneas. In 2014, van Dijk et al. published the results of BL transplantation in eyes with max K values >70D, finding that – in 90% of eyes – disease progression was successfully arrested.[338,339]

3. Preoperative best corrected Visual Acuity

For patients with extremely poor vision – even with a contact lens in place – either PK or DALK may be preferred, since rarely do the visual gains of UV-CXL, ICRS, or BL transplantation exceed one or two lines. Rather, the primary purposes of these latter operations are 1) to arrest disease progression; and 2) to restore or support contact lens tolerance by making wear more comfortable.

4. Endothelial Health

It is not completely unusual for KC to be found alongside co-existing endothelial dysfunction. Fuchs Endothelial Dystrophy (FED) is the most common of such accompanying disorders but also represented are posterior polymorphous dystrophy (PPMD) and a peculiar condition of endothelial depletion and guttae excrescences that may be the product of the KC itself rather than distinct entity.[97,201,317] The actual prevalence of such "dual-disorders" may be underestimated, since the stromal thinning of KC may mask the corneal edema that would otherwise signify an endothelial decompensation and because stromal irregularities may interfere with confocal microscopy and thereby obstruct the diagnosis of endothelial depopulation.[234]

For advanced KC and a failed endothelium, PK is obviously preferred. But in eyes with merely the suggestion of endothelial disease or an endothelial dystrophy not highly advanced, a relatively non-invasive procedure such as ICRS or BL transplantation may be chosen, since neither operation appears to significantly affect recipient endothelial cell density.[24,210,285,339] To a lesser extent, DALK may be a viable option as well, as the best data suggests an early, modest decline in endothelial cell density (ECD) followed by a relatively quick return to normal, physiologic rates of cell loss thereafter.[288,302,340] (However, intra-operative perforation – DALK's most common complication – does appear to result in substantially lowered cell counts.[90,204]) If any of these alternatives to PK were selected, and then later endothelial decompensation occurred, a secondary Descemet stripping

(automated) endothelial keratoplasty (DS(A)EK) or Descemet Membrane Endothelial Keratoplasty (DMEK) may be prudent.

5. Lens Status

Because advanced KC tends to manifest early in life, many of those treated are phakic. Owing to a greater post-operative steroid requirement, keratoconic eyes undergoing PK are significantly more likely to develop cataracts requiring extraction than are eyes receiving DALK.[33,92,93,217,223] Specifically, Zhang et al found that ten years after PK, 19.2% of eyes operated for advanced KC developed a cataract requiring phacoemulsification compared to 0% following DALK.[364] Therefore – and because none of ICRS, UV-CXL, or BL transplantation promote cataractogenesis – PK may be the least desirable option for phakic eyes.[344,268] This is especially true given that cataract extraction: 1) increases the risk of allograft reaction after PK, and 2) threatens severe pressure spikes in young, myopic eyes.[63,250]

6. Patient Age and Ability to Cooperate

A patient's age and ability to cooperate with examination, medication, and follow-up requirements may critically determine an operation's outcome. These are particularly relevant concerns for the treatment of KC which disproportionately manifests in childhood or adolescence and in patients with co-existing cognitive impairment (e.g. Down, Tourette, Costello, Williams-Beuren, and other syndromes) or personality defects such as hypomania and paranoia.[83,127,137,167,222,224,269]

i. Age

Although the onset of KC is typically around puberty, it is not totally uncommon to arise earlier and may be responsible for a small percentage of worldwide amblyopia, as the development of visual function often proceeds until a child is eight to eleven years old. In general, the younger the patient at the time of diagnosis, the more severe the condition and the greater its chances for progression. Consequently, many children present with already very advanced disease.[70,94,140,209,260] Until recently, the usual treatment for these eyes has been PK, with advanced KC now the second most common indication for pediatric corneal transplant behind only congenital corneal opacity.[209]

Adolescents (age 13-19) operated with PK for advanced KC have long term visual results and levels of graft survival that approximate those of adults.[215] For children (age 5-12), outcomes are slightly worse, principally attributable to higher rates of graft failure (approaching 30% at 15 years.)[231] Intra-operatively, PK may be more challenging in children and adolescents. Their smaller, more hyperopic eyes conduce to shallower anterior chambers, scleral "crimping," and forward displacement of the lens-iris diaphragm during surgery. These eyes are also more likely to have narrow or under-developed iridocorneal

angles, predisposing to the formation of peripheral anterior synechiae and elevated intraocular pressures. Both of these latter occurrences are strong risk factors for graft rejection besides also threatening the eye with the separate problem of glaucoma. [120,214]

Little has been written about DALK in the eyes of children and adolescents, although the available literature suggests results that parallel the adult population.[51,52,86,145]

UV-CXL is still a new therapy in many parts of the world, and consequently there are few studies regarding its use in children. From the available data, pediatric UV-CXL seems to confer a modest corneal flattening effect and a mild visual benefit without any additional complications.[25,55,219,309,310,345] Compared to adults, however, these gains may be smaller and less durable.[54,64,171]

In the United States, ICRS are not approved for patients younger than 21. Worldwide, use has generally been constrained to individuals older than 18. As a result, little is known about their suitability in pediatric cases. Although, one comparative report does exist, analyzing the efficacy of ICRS for three different age groups: patients 13-19 years old, 20-35 years old, and >35 years old. Ultimately, no difference in visual outcome or corneal topography was found.[105]

For BL transplantation no data currently exists for children. Still, for very young patients, BL tranplantation may eventually be regarded as one of the safest options: as a largely "extra-ocular" procedure, most of the intraoperative challenges of PK in pediatric eyes are avoided. Moreover, because the postoperative burden is lower (related to the absence of corneal sutures and the extreme improbability of graft rejection), suboptimal patient cooperation may be less consequential.[339]

ii. Mental Disability

Patients with mental retardation are well known to have worse outcomes following PK for advanced KC, mostly as a result of a higher incidence of postoperative complications. In particular, there are more occurrences of globe rupture, corneal ulceration, and graft rejection, especially in patients with greater amounts of cognitive disability.[35,121,186,232,297,354] In part, this is thought to stem from a stronger tendency toward both eye rubbing and ocular self-trauma. Volker- Dieben et al report a 67% five-year survival rate for penetrating grafts in eyes of patients with Down Syndrome, substantially less than the >90% survival rate in "normal" populations.[346]

DALK may be preferred over PK in these patients, since the eye is not as structurally weakened by the surgery and because faster healing may permit earlier suture removal, reducing the risk of infection.[76,148]

Surprisingly, all reports of UV-CXL in patients with Down Syndrome are negative (although, it is possible that this represents something of a "publication bias" with the good results going unpublished). These include one patient with severe corneal melting requiring bilateral PKs;[109] another developed an intractable corneal ulcer. (In this lat-

ter case, resolution required admission to the intensive care unit, inducing an artificial coma, supplying mechanical ventilation for weeks, and two separate tarrsorhaphies.)[188] Extrapolating from these examples, the authors conclude that only patients capable of reliable cooperation, with good family support, are acceptable candidates for UV-CXL.

There are no reports of the use of ICRS or BL transplantation in patients with Down Syndrome or other forms of mental disability. Both operations impose fewer postoperative requirements than PK, DALK, or UV-CXL, however and therefore may be less "risky." The caveat, however, is that most of the postoperative problems of ICRS stem from migration / superficialization of the ring segments themselves. These events occur more frequently if the patient continues to rub the operated eye after surgery.[71,80,169] And because patients with cognitive impairment tend to display more eye rubbing postoperatively, some caution may be exercised before ICRS placement.

7. Pre-existing Corneal Scarring

With advanced KC, corneal scars may arise from previous hydrops and therefore, a section of DM is often incorporated into the area of fibrosis. Surprisingly however, eyes with prior hydrops do not demonstrate lower ECDs compared to those without.[12] As a result, endothelial replacement (with PK) should not be considered mandatory for these patients. This is especially true given that – in eyes with prior hydrops – PK outcomes tend to be worse, principally because the risk of graft rejection is much higher.[29,220] This extra risk arises because: 1) Corresponding to the size of the original area of hydrops and its proximity to the limbus, corneal neovascularization often develops;[227,284] and 2) Eyes with hydrops are more likely to have allergic or other ocular surface disease, resulting in more inflammation and more eye rubbing.[5]

For these reasons, DALK – with its lower risk of allograft reaction – may be preferred. However, the Anwar Big Bubble technique is contraindicated for these patients, owing to the large risk of perforation secondary to the patient's underlying, weakened DM.[106,158] Therefore, these surgeries could proceed by other maneuvers such Melles manual dissection.[17,66,86,251,279]

The effect of hydrops on UV-CXL for advanced KC has not been evaluated. Although, in a study of UV-CXL for pseudophakic bullous keratopathy (PBK), significantly less crosslinking effect was found when stromal scars were present. Therefore (speculatively), the procedure may be less successful given prior hydrops.[39] Moreover, UV-CXL would not be expected to reduce the opacity of the scars themselves so their presence in the visual axis may be a relative contraindication.

Likewise, central scarring is generally believed to contraindicate the use of ICRS, as the devices are not believed efficacious as refractive instruments in the presence of a significant central opacity. BL transplantation experiences the same limitation. However – provided that the scarring is only "light" and not severely visually disabling – both

ICRS and BL transplantation may be worthwhile to arrest disease progression and permit continued CL wear (**Figure 1**).[42,339]

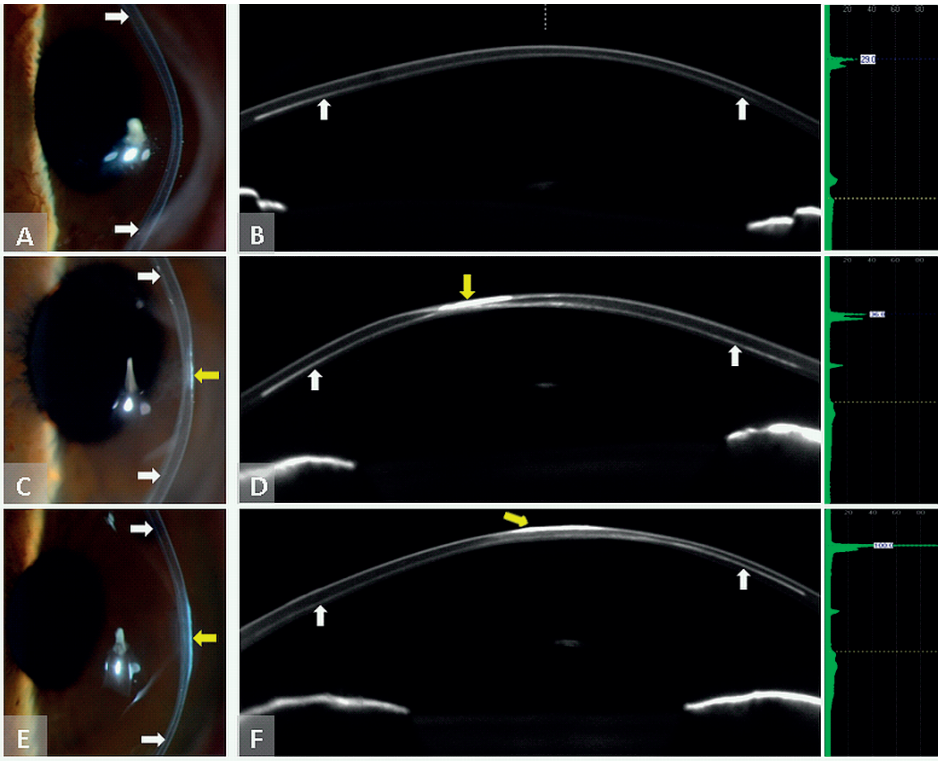

Figure 1. The Bowman layer graft (white arrowheads) is visible within the recipient stroma (though perhaps positioned somewhat deeper than the intended 50% stromal depth), without any interface haze or stromal reaction. Different types of preexisting superficial scarring and surface irregularity (yellow arrowheads) are visible (**A-F**). *Reprinted with permission from JAMA Ophthalmology*

8. International Availability

In the US, UV-CXL is not yet FDA approved for the treatment of KC. And while clinical trials are ongoing, generally these are limited to patients with mild to moderate disease only, leaving those with advanced KC ineligible.

Globally, ICRS are available in numerous designs. In the US, however, the only approved variant is INTACS, which come in "R" and "SK" subtypes. "R" (regular) segments have a large internal diameter (6.7mm), a hexagonal cross-sectional shape, and thicknesses from 0.25mm to 0.5mm in 0.05mm increments. Meanwhile, the "SK" (steep keratometry) segments – designed specifically for advanced KC – have a smaller internal diameter (6.0mm), an oval cross-sectional shape, and a narrower range of thicknesses (0.21mm,

0.40mm, 0.45mm, and 0.50mm). Outside of the US, other types of ICRS are available which include Ferrara rings, Kerarings, the Myoring, and Bisanti Segments.[101,235]

Aside from the Amnitrans Eye Bank in Rotterdam, there are no commercial eye banks currently preparing BL transplantation tissue for transplant. As a result, surgeons may need to either import the tissue from abroad or prepare it themselves using previously described techniques.[339]

IV. SURGICAL TECHNIQUES

A. PK

The biggest recent advance in PK has been the introduction of the femtosecond laser to trephine the recipient and donor tissues, theoretically providing better apposition and faster healing. Suturing techniques and graft sizing practices vary, with results to be discussed later.

B. DALK

Most currently practiced DALK techniques exist as variations or modifications of two basic strategies: the Anwar big-bubble and the Melles manual dissection. The big-bubble method is rooted in Anwar's 1998 discovery that an intrastromal injection of balanced salt solution (BSS) was often effective at establishing a cleavage plane just above DM.[13] In 2003, he refined the technique to use air instead of BSS and the "big bubble" procedure was born.[19] (Viscoelastic may also be used for this purpose, an observation made independently in 2000.)[236] In contrast, Melles manual dissection is a bit more meticulous. First, the anterior chamber is filled with air. Then, using a series of curved spatulas, the anterior stroma is carefully dissected away from the underlying DM. The precise depth of dissection can be determined by using the "air-endothelium interface:" when the anterior chamber is full of air, a reflected image of the tip of the dissecting spatula appears. The distance of this reflection from the actual spatula itself represents the depth of the ongoing dissection, such that the deeper the dissection is carried out, the closer the reflection appears to the tip of the instrument. Guided in this way, a controlled dissection down to the level of DM is possible (**Figure 2**).[237,238]

The literature is replete with amendments to both "core" surgical techniques. These include: staining the stroma with Trypan blue to facilitate viewing;[28] Parthasarathy et al.'s "small bubble" technique for confirming the presence of the big bubble;[262] employing ultrasound pachymetry to guide big-bubble creation;[125] suture style modifications;[2,216] and using a diamond knife / nylon wire / microkeratome / excimer or femtosecond laser for lamellar dissection.[34,113,165,311,312,337,362] For corneas with extreme peripheral thinning, a modified procedure has been proposed dubbed TILK (Tuck-in lamellar keratoplasty)

in which the recipient peripheral corneal rim is undermined and the edges of a large anterior lamellar graft are "tucked in" below to add extra thickness.[173,336]

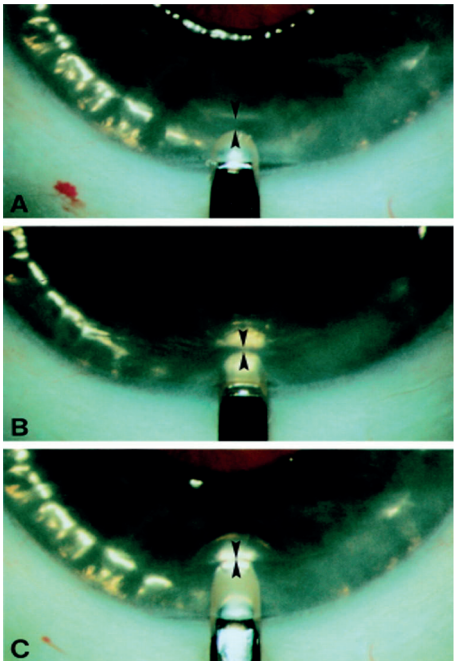

Figure 2. Demonstration of the Melles manual DALK surgical technique in a human eye bank eye. **(A)** The anterior chamber has been filled with air. In between the blade tip and the air to endothelial interface light reflex, a dark band (arrowheads) is visible. **(B)** Because the dark band reflects unincised posterior corneal tissue, the dark band decreases in width when the blade is advanced into the deeper stromal layers. **(C)** When the blade appears to touch the air to endothelium interface, a stromal dissection level just anterior to the posterior corneal surface is reached. *Reprinted with permission from British Journal of Ophthalmology*

C. UV-CXL

The original UV-CXL procedure – dubbed the "Dresden Protocol" – entailed debriding the cornea entirely of its epithelium, then dripping a riboflavin solution onto the anterior stroma. Subsequent application of UV light generates free radicals which "cross-link" adjacent collagen molecules and stiffen the cornea against further ectasia.[352] Since the Dresden protocol was introduced, several alternatives have emerged. These include "accelerated" crosslinking (in which the intensity of energy is increased, in exchange for reduced exposure time),[325] "epi-on" techniques,[56,105,115,184,219,287,310,314] and the "Athens Protocol" which combines accelerated UV-CXL with same-day photorefractive keratectomy.[168] With the possible exception of "epi-on" crosslinking (which may be less effective, as previously discussed) none of these modified techniques have yet distinguished themselves as clearly more effective than any other, in terms of topographic or visual results.

D. ICRS

ICRS are segments of PMMA plastic available in numerous arc-lengths, thicknesses, and designs. The devices themselves are inserted into stromal tunnels which may be fash-

ioned manually using a handheld corkscrew blade or automatically using a femtosecond laser with no difference in results (except that channels tend to be slightly shallower when created manually, and more often decentered when created by laser).[79,102,174] For greater effect, two hemi-spherical segments may be placed instead of one. These segments may be implanted "symmetrically" if the keratoconic cone is located centrally, or "asymmetrically" if the cone is decentered, as is typical.[235] With asymmetrical placement, a thicker segment is implanted in the axis of greatest steepening, and a thinner segment is inserted 180 degrees away. Because keratoconic steepening tends to be located in the inferior cornea, the practical recommendation is to place the thicker segment inferiorly and the thinner superiorly.[9,61] To a large extent, the depth at which the segments lie determines their effect: Maximal flattening occurs with segments at 60-79% corneal thickness. Shallower than 60%, the effect may be lessened and the likelihood of a variety of ocular surface complications increased. Deeper than 80%, there may be no topographic effect at all.[147] Compared to the surgeon's own depth estimates, most segments lie much more superficially (up to 25%), judged by AS-OCT.[200,249]

A significant advantage of ICRS is the procedure's reversibility. Following explantation, the rings may be re-inserted again at a later time, or alternatively PK or DALK may be tried.[7,116,324,328] Before re-operating, it is necessary to wait at least three months after segment removal for the cornea to revert back to its original shape.[75]

Increasingly, there are reports of combining ICRS with UV-CXL. The sequencing is critical: to achieve maximal flattening, ICRS should be implanted before or simultaneously with UV-CXL. To do the opposite (UV-CXL, then later ICRS) limits the flattening effect of the segments since the cornea has been already "fixed" into a sub-optimal configuration.[74,78,98,205]

E. BL Transplantation

The most sensitive and specific indicator of KC is the fragmentation of Bowman layer – an insult that critically destabilizes the surrounding cornea, predisposing it to ongoing ectasia.[1] In 2014, van Dijk et al introduced the idea an isolated Bowman Layer "inlay" for eyes with advanced KC. Delivered into a manually dissected mid-stromal pocket, the graft was intended to (partially) restore the corneal anatomy, stabilize the corneal structure, flatten the surface, and arrest progression.[339]Since van Dijk et al's original report in 2014 (featuring the outcomes of the first 10 operated eyes) a larger study has been published, describing the surgical results of the first 22 cases, with a mean follow up time of 21 ± 7 months. It is from these two studies that the bulk of the data about BL transplantation derives.

The graft is prepared by manually peeling the BL from the anterior stroma of a donor corneo-scleral rim. The process begins by securing a corneo-scleral button atop an artificial anterior chamber, debriding the epithelium using surgical spears, then drip-

ping trypan blue over the anterior corneal surface. After lightly scoring a circular area, 9.0-11.0mm in diameter with a 30G needle, McPherson forceps are used to delicately peel the BL away from the underlying stroma using small circular movements. Because the layer is acellular, it is physically robust and amenable to gentle handling despite being only 10-15µm thick. Once detachment is complete, a "Bowman roll" forms spontaneously, owing to the inherent elastic properties of the tissue itself. The graft is then submerged in 70% ethanol to remove any lingering epithelial cells, rinsed with BSS, and then stored in organ culture before transplantation.[211,339]

The initial stages of the operation resemble Melles manual DALK: after creating a side port at either the 3 or 9-o'clock position, the anterior chamber is filled with air. A 5mm frown-shaped scleral incision is fashioned at 12-o'clock, 1-2mm outside the limbus, and tunneled just inside the clear cornea. Lamellar dissection then follows, using the same set of curved spatulas employed in the Melles manual DALK technique. Again, the air-endothelium interface is used to judge depth in the stroma, except – for BL transplantation – the intended depth is 50%, rather than the 99% DALK aims for. The reason for this discrepancy is that BL transplantation is commonly performed in extremely thin corneas, and – by aiming at a mid-stromal dissection –the chances of inadvertent anterior or posterior corneal perforation may be minimized. Once completed, this manual mid-stromal dissection results in a stromal "pocket" extending from limbus-to-limbus, 360 degrees, within the cornea. Air is then removed from the anterior chamber, a surgical glide is inserted into the mouth of the scleral tunnel, and the Bowman layer graft (rinsed with BSS and stained with Trypan blue) is placed on top. A blunt cannula is used to gently push the graft along the glide, through the scleral tunnel, and into the stromal pocket. Once in place, the tissue is unfolded by a combination of rinsing with BSS and light cannula touches. After unfolding, the anterior chamber is re-pressurized with BSS.[339]

Although the operation is positioned as an alternative to DALK, it retains some of the latter's salient features. Namely, the status of a technically "extra-ocular" surgery (as the eye is never completely entered), and tissue economy, because the corneal tissue left over from creating the inlay may be re-used for endothelial (DSEK or DMEK) grafts.[339]

V. VISUAL OUTCOMES

A. PK

After PK for advanced KC, final uncorrected visual acuity (UCVA) ranges from 20/50 to 20/100, with just over 40% of patients reading 20/40.[65,50,117,129,161,162,319] Spectacle correction gives better results with a mean acuity (BSCVA) of 20/30-20/40.[27,45,59,65,164] These gains may recede over time, however, due to mounting irregular astigmatism in the graft that spectacles cannot correct. On this point, Praminik et al found that 15

years after PK for advanced KC, although 66% of eyes retained a BSCVA ≥20/40, 18.9% had fallen to <20/200.[271] For some patients (5-60%), CLs may be required postoperatively.[44,124,212,272,294,304,307,319,331,348] Compared to glasses alone, CLs usually confer an extra 1-2 lines with a mean acuity (BCVA) of 20/25 one year postoperatively and with 67-96% of patients seeing at least 20/40.[11,44,50,67,129,161,182,212,256,272,294,304,319] However, because vision doesn't "stabilize" until at least 12 months after surgery, a primary limitation to PK's visual results is the delay in achieving them. [43,44,162,183,319]

No study has shown that the style or pattern of graft suturing influences ultimate BCVA.[161] The effect of graft sizing is controversial but probably modest with various studies reporting slightly better (or worse) results with oversized vs. same-sized grafts.[67,129,150,304] The type of mechanical trephine used has also not been shown to influence ultimate BCVA, although, the use of a femtosecond laser for cutting the recipient and donor tissue may slightly speed-up visual rehabilitation by permitting earlier suture removal.[27,45,59,122,161]

B. DALK

DALK, properly performed, probably provides equivalent visual results to PK. The totality of evidence shows that, provided stromal dissection reaches the level of DM, all visual outcomes (UCVA, BSCVA, BCVA, and percent requiring contact lenses) are the same.[117,119,144,161,166,182,306] In studies where the visual results of DALK are inferior to PK, usually, this discrepancy is attributed to an incomplete stromal dissection such that DM is not fully bared. In these "pre-descemetic" DALKs, visual performance tends to be worse overall. The problem seems to be related to the *depth* of the un-dissected stromal bed, not its "regularity" or "smoothness," since pre-descemetic DALKs performed by laser ablation do not outperform those performed by manual dissection.[20,48] Large DM perforations sustained intra-operatively lower the chances of excellent visual results.[90,204] Compared to PK, visual rehabilitation may be somewhat quicker, owing to the possibility of earlier suture removal.[27] Post-operative contrast sensitivity is equal for the two surgeries, although there are conflicting reports as to which yields fewer higher order aberrations.[4,161,185,225,289]

C. UV-CXL

For most patients treated with UV-CXL, visual acuity either remains unchanged or improves mildly, by 1-2 lines.[56,134,135,326] Eyes with pre-procedural BCVAs <20/40 are significantly more likely to achieve substantial flattening with UV-CXL, and correspondingly, greater visual improvements.[135,326] The steeper the cornea, however, the more variable the response to treatment and the greater the likelihood of vision loss.[22,136,192,355] In the sole dedicated study of UV-CXL on corneas steeper than 58D, Sloot et al found no benefit in UCVA or BCVA at one year postoperatively, although a slight trend toward the latter.[305]

D. ICRS

Similarly, ICRS confer a modest visual benefit: on average, 1-2 lines of BSCVA and BCVA .[10,57,72,197,199,210,259,283] In particular, for Amsler-Krumeich Stage III or IV eyes, most studies show no (or markedly reduced) gains, along with more disappointed patients and elective explantation.[6,8,32,103,169,180,300,330,343,363] The relevant study with the longest follow-up was performed by Torquetti et al, which tracked the outcomes of ICRS placement in keratoconic eyes through ten years. On average, eyes gained one line of UCVA and two lines of BCVA. Ten percent, however, lost at least one line of UCVA, and 20% lost at least one line of BCVA. All eyes losing vision were Amsler-Krumeich Stage III or IV.[329]

Whereas newer segment designs such as INTACS SK and the Kerarings may be better than previous versions in flattening corneas with severe ectasia, the visual gains still rarely exceed 1-2 lines. Moreover, these alternate models have been associated with an increased amount of visual aberrations, owing to the small diameter of the segments, bringing them into closer proximity to the visual axis.[126,141,159,189,195,196,290,296,303]

Visual rehabilitation is typically completed within three to six months after surgery, but may require up to one year. Pairing the procedure with UV-CXL may enhance the flattening effect, or make it more durable, but has not been shown to improve visual results.[53,96]

E. BL Transplantation

Following BL transplantation, BSCVA typically improves by 1-2 lines, although BCVA usually remains unchanged. The primary visual benefits, then, of BL transplantation may be: 1) to enable more comfortable CL wear by flattening the cornea into a more tolerable configuration; and 2) to permit continued CL wear into the future, by halting disease progression.[338,339]

VI. REFRACTIVE OUTCOMES

The bulk of the myopia in keratoconic eyes arises – not from the cornea – but from the axial length of the eye, which is significantly larger than in normal individuals. Therefore, regardless of the planned corneal intervention, some amount of myopia is likely to remain.[332] The amount of postoperative myopia tends to be slightly greater following DALK than PK because the resultant cornea tends to be slightly steeper. Otherwise, however, the refractive outcomes are the same.[14,37,181]

Following PK, large amounts of astigmatism are common; the average amount is 3-5D, but may exceed 10D, and as a consequence, approximately 20% of patients may require refractive surgery post-operatively for their best visual results.[60,164,183,212] No known preoperative features of the recipient cornea predict the likely amount of postoperative

astigmatism, nor is there an association with age, gender, the type of trephine used, or the size of the graft.[212] Per several studies by Krumeich et al, postoperative astigmatism may be reduced in eyes with advanced KC by – at the time of surgery – suturing into place a permanent steel alloy "intrastromal corneal ring" which may protect the graft from tractional distortion during subsequent healing.[193,194] For most conventional suturing styles there is also no astigmatic difference, although, Busin et al have shown that – at least in the short term – a possible benefit may apply to a double running, 16-point technique.[47,108] Suture removal tends to result in large unpredictable swings in the amount of astigmatism present regardless of the type of suture employed and even when many years have passed since the original surgery.[46,87,218,248,361] Once all sutures have been removed, however, the measured astigmatism tends to remain relatively stable. In most cases however this stability is only a temporary condition. Eventually, progressive donor-recipient misalignment or recurrence of the original disease results in late rising levels of astigmatism.[203,213,255,276] De Toledo et al found that this transition – from a period of refractive stability to one of gradual worsening – began approximately ten years after first suture removal.[89]

Typically, UV-CXL yields only a modest reduction in astigmatism, almost always less than 0.5D.[21,69] While often a "step in the right direction," the overall effect is succinctly expressed by Pinero et al: "crosslinking is able to induce a corneal astigmatic change, but it is variable, not predictable, and insufficient to provide an effective astigmatic correction."[267]

In contrast, ICRS provide a sizable, reduction in corneal astigmatism ranging from 1-3D, regardless of the type of segment employed or the Amsler-Krumeich stage of disease, although the greater the preoperative amount of astigmatism, the less predictable the corrective result of the ICRS may be. The full refractive effect is generally not seen before one year postoperatively (with significant changes occurring between six and twelve months) but thereafter appears stable, at least through ten years of follow-up.[6,114,266,329,330]

The refractive impact of BL transplantation has not yet been fully elucidated. All available evidence, however, suggests a slight hyperopic shift (consistent with corneal flattening) with no significant effect on corneal astigmatism.[338,339]

VII. TOPOGRAPHIC OUTCOMES

After PK, the primary determinant of corneal curvature is the size disparity between the graft and the recipient.[95] When the donor button is oversized by 0.5mm, the mean K usually settles around 45.5D. When the button is same-sized, that value is nearer to 42.5D. The presence of corneal neovascularization, however, skews these figures in unpredictable ways owing to the frequent onset of distortionary scarring postop-

eratively.[41,59,60,95,150,161,212] While suture placement (the style and material) is unrelated to ultimate corneal curvature, removal can have dramatic (usually homogenizing) effects. In oversized grafts, the effect is a slight steepening of the cornea. For same-sized grafts, however, suture removal may instead produce a small amount of overall flattening.[87,226,293,332] Regardless of graft size, the donor and recipient tissues tend to become progressively misaligned at the interface over time, grossly evident in >50% of eyes 20 years postoperatively.[37,164]

As previously mentioned, following DALK, corneas are routinely 2D steeper than if they had received a similarly-sized PK. This disparity may be the product of some degree of intraoperative anterior chamber collapse (and subsequent scarring) seen with PK that DALK avoids.[14,37,181]

The primary topographical result of UV-CXL is an "evening out" of corneal parameters and a decline in overall surface variability.[327] The probability (although, not the magnitude) of this effect relates to the degree of pre-procedural ectasia, such that eyes with advanced KC may demonstrate changes more frequently than those with mild disease.[135,187,205,326] Following UV-CXL, central cones flatten modestly (with mean and max Ks falling by 1-2D). Paradoxically, eyes with eccentrically located cones may actually display central steepening after treatment as the corneal parameters become more alike.[134] Shortly after therapy, CCT may decline (likely the result of keratocytes apoptosis in the anterior stroma) but rebounds to baseline at one year.[56,287,305]

Standard INTACS reduce mean Ks by 3-5D.[32,103,169,180,329] This effect may be slightly enhanced (by a diopter or so) by combining the procedure with UV-CXL, and furthermore, the results may be more durable as well.[60,343] Yeung et al found that, following combined treatment, flattening occurred which was persevered even if the ring segments were later explanted.[358] Alternative segment designs include INTACS SK, Kerarings, the Ferrara ring, and the Myoring; all of which have smaller internal diameters and are placed closer to the corneal center, thereby effectuating greater mechanical flattening. Large (although highly variable) reductions in mean Ks have been published, ranging from 2-9D, with most studies reporting results at the higher end of that range. No segment design has proven substantially more effective than any other in this regard, although direct head-to-head trials are rare.[126,141,159,160,189,195,196,290,303]

The primary effect of BL transplantation is to flatten the operated cornea: by unfolding the transplanted tissue within the stromal pocket and tucking the edges of the graft into the far periphery of the dissected cavity, the natural healing response of the eye generates a tractional force that "pulls" the ectatic cornea into a more normal configuration. The two reports on the magnitude of these effects suggests a 5D reduction in mean anterior simulated Ks, 5-7D reduction in max corneal power, and a 8-9D reduction in max K. These topographic changes occur within the first postoperative month and appear stable through at least two years of follow-up. Both CCT and TPT appear very slightly

greater after surgery, although it is questionable whether either change is statistically significant.[338,339]

VIII. POSTOPERATIVE DISEASE PROGRESSION

Both DALK and PK replace only the central cornea leaving a peripheral rim of tissue behind. (With DALK, some variable amount of host posterior stroma often remains as well.) There exists now considerable evidence that many eyes receiving either of these two operations continue to progress. Posited explanations include continued ectatic deterioration of the unoperated corneal rim, ongoing graft-host interface misalignment, recurrent disease in the donor button, and transplantation with keratoconic tissue.[31,85,118,149,213,253,254,264,356] A relevant study was performed by Bourges et al which examined eyes with advanced KC treated with PK. In the years after surgery, in all eyes requiring a repeat PK for any reason, histopathologic study of the removed donor buttons revealed structural changes consistent with KC including Bowman layer disruption and stromal deposits. This suggests infiltration or repopulation of the transplanted tissues with pathologic recipient keratocytes (or possibly even recipient epithelial cells).[40] "Recurrent" KC has likewise been demonstrated after DALK and in fact may be more likely and quicker in onset, since more of the diseased recipient cornea is left unremoved.[112,263] Interestingly, reports exist of non-keratoconic eyes receiving PK and later experiencing progressive ectasia requiring re-operation.[58,191] It is uncertain whether these instances stem from using donor tissue with undiagnosed KC or whether this ectatic degeneration is simply the product of ongoing misalignment of the graft-host junction. Nevertheless, it is probably true that neither DALK nor PK truly abolish ongoing ectasia so much as "de-bulk" the recipient cornea of some pathological cells and furnish tissue that may remain, temporarily, "normal." Per most studies, approximately 10% of eyes will display "recurrent KC" 20 years after PK, with the earliest pathological changes often becoming evident 10 years after final suture removal.[118,254,264]

Because UV-CXL was introduced in 2006 (now, only eight years ago), true long-term follow up data are still lacking. However, the best available evidence shows a >90% success rate in arresting progression.[82,157,305] (Interestingly, UV-CXL has also been used effectively to halt progression in a small number of eyes with recurrent KC after PK).[282] Risk factors for failure – i.e. ongoing ectasia – include, as previously mentioned, the application of isotonic riboflavin solution to "thicken" a thin cornea prior to treatment, very steep corneal curvature (greater than 55 to 58D), and age >35 years.[135,130,143,187,305]

After ICRS, the central cornea continues to thin, though this is usually explained as the result of mechanical stretching of the ring segments themselves and not as evidence of advancing disease.[73] On the contrary, most evidence shows that – for mild to moderate

KC – ICRS are as effective as UV-CXL in halting progression, with a greater than 90% success rate at 5 and 10 years.[32,103,169,180,197,329] But as with UV-CXL, the steeper the cornea, the more likely progression is to continue despite treatment.[10] Kymionis et al, studying the five year success rate of ICRS in keratoconic eyes, found that topographic stability was only achieved in eyes with Kmax values <47D.[199] Placement of ICRS may also be combined with UV-CXL, which theoretically might further defend against progression. Studies on the subject do reflect an additive effect with superior normalization of topographic parameters compared to ICRS alone.[60,343] However, there are no published data currently available which support the claim that disease progression is less likely with this form of "double treatment" compared to either procedure alone.

From early results of BL transplantation, two years postoperatively, 90% of eyes with previously documented progression had stabilized, despite all eyes having pre-operative Kmax's >70D.[338,339]

IX. CONTACT LENS TOLERANCE

Even after surgery, many patients with advanced KC have far better vision with a rigid lens in place. Whether a patient is able to (comfortably) wear CLs, postoperatively, is therefore a crucial consideration. Nevertheless, lens tolerance is difficult to objectively assess, being directly proportional to the skill and diligence of the prescribing physician, disposition of the patient, and the type of lenses available for use. For example, one study by Smiddy et al of a large cohort of keratoconic eyes referred to the Wilmer Eye Hospital for PK secondary to CL intolerance found that, with assiduous effort and careful lens selection, 87% could be made comfortable and spared surgery.[307] As a result, some caution may be applied to all postoperative CL tolerance reports, since they may reflect (at least in part) greater effort rather than true improvement. This is especially true given that there is no universally agreed upon length of time that a patient must be able to withstand CL wear to be deemed "tolerant". For example, studies exist which count patients as tolerant although the lens can only be comfortably worn for 2-6 hours per day. Finally, it appears that CL tolerance depends chiefly – not on central corneal steepness – but on peripheral clearance, and on the interaction of the upper edge of the lens with the patient's upper lid. This explains why, all things being equal, an inferiorly decentered cone is more likely to produce CL intolerance; why operations to "center" the cone may increase tolerance; and why an eye may remain CL intolerant even if central steepness is reduced.[124,307]

After PK for advanced KC, approximately 90% of patients may be tolerant of rigid lenses, with a mean reported comfortable wear time of 9-12 hours daily.[307] Scleral lens tolerance, however, frequently decreases secondary to greater peripheral touching.[258]

Likewise, same-sizing the graft to the recipient produces more corneal flattening, more peripheral touch, and lower tolerance.[304]

Presently, there are no dedicated studies of CL tolerance after DALK for advanced KC. Conceivably though, comfortable wear may be more likely than after PK, as corneas operated with DALK tend to be modestly steeper postoperatively, thereby reducing peripheral touch.[14,37,181]

In the long term, CL tolerance may be slightly improved after UV-CXL, although it is unclear whether this stems from surface flattening or, instead, sub-epithelial nerve plexus fibrosis and diminished corneal sensation. In the short term, rigid lenses are relatively contraindicated since they predispose to epithelial hypoxia and anterior keratocyte apoptosis with subsequent haze formation.[295]

Reports of rigid lens tolerance after ICRS for advanced KC range considerably, from 60-100%. Documented difficulties include a tendency for CLs to center over the segments themselves (rather than the corneal center), inadequate lens movement and tear exchange, and other troubles that – while potentially correctable with the "proper" lens style and fit – are complex, time consuming, and require considerable expertise to remedy.[57,84,151,180,244,252,300]

To date, all eyes receiving BL transplantation for advanced KC have been scleral lens tolerant postoperatively.[338,339]

X. POSTOPERATIVE CARE AND PATIENT PERSPECTIVE

Patient satisfaction with surgery for advanced KC relates to: 1) whether the operated eye becomes the better seeing eye, and 2) the size of the burden entailed by surgical follow-up.

Of all patients receiving a PK, young keratoconics tend to be the most pleased.[334,349] Happiness peaks 5-15 years after surgery (before which, the requirements of postoperative care tend to be more onerous; and after which, mounting irregular astigmatism in the graft may result in frustratingly frequent refractive changes). Nevertheless, it may be prudent to avoid performing PK in patients with only one "bad" eye. Unless the operated eye becomes the "better seeing" of the two, patients are unlikely to achieve functional benefits sufficient to compensate for the hassle and expense of the surgery itself.[334,349]

Because DALK imposes fewer postoperative obligations than PK, greater patient satisfaction may be expected. Surprisingly however, in the only comparative study on the matter, patients operated with both techniques – PK in one eye, DALK in the other – expressed a preference for their PK eye.[357] A potential explanation for this discrepancy is that the study's PK eyes had significantly better vision than their DALK counterparts,

and it is uncertain whether these preferences would exist had the visual outcomes been equivalent, as they frequently are.

Most of the impositions of UV-CXL seem to be concentrated in the short term. Shortly after surgery, the epithelial defect may be painful and require the wear of soft CLs. Meanwhile, hard CLs are contraindicated during this period as they may contribute to the development of stromal haze.[295]

The best indicator of severe patient dissatisfaction with ICRS may be the explantation rate, which ranges from 1-35%, usually stemming from prior segment migration, extrusion, or poor visual results – all of which are more likely in eyes with advanced KC.[8,32,169,180,196]

Following BL transplantation, the operated eye is typically comfortable. Virtually all patients report enhanced "functional" vision with increased ability to perform activities of their daily life, although only modest Snellen improvements may occur. Although the risk of graft rejection is thought to be extremely low, many patients are continued on light topical steroids for one year after surgery, after which they may be stopped completely.[338,339]

XI. COMPLICATIONS

A. Ocular Surface Effects [PK, DALK, UV-CXL, ICRS, BL Transplantation]

All by itself, KC reduces corneal sensitivity, related to nerve fiber disruption from progressive ectasia as well as prolonged CL wear.[242,313] Besides having a "relatively neurotrophic" cornea, many patients with advanced KC have other ocular surface problems as well. These include vernal keratoconjunctivitis, atopic eye disease, and floppy eyelid syndrome.[179,275,277,333] In fact, most keratoconic eyes display disorders in tear quality and conjunctival cellular composition (squamous metaplasia and goblet cell dropout) that mirror the extent of their corneal ectasia.[91] Interestingly, although KC is usually regarded as a non-inflammatory disease, a litany of inflammatory molecules has been found in superabundance in the tears of affected eyes – in quantities corresponding to the severity of their ectasia – raising the possibility that the pathological mechanism is actually a longstanding chronic inflammation.[206-208] For these reasons, ocular surface issues are likely to be a significant consideration in eyes with advanced KC.

PK and DALK tend to worsen any existing ocular surface problems, as both involve surface incisions, severing of corneal nerves, and placement of long-lasting sutures. These difficulties are evidenced by chronic, punctate epithelial erosions which may persist indefinitely in 10-20% of eyes after PK.[256] In eyes with co-existing vernal keratoconjunctivitis, Waggoner et al showed that nearly 7% may have late-onset, persistent epithelial defects after surgery.[347] Eyes with advanced KC are also at especially high risk for suture

related problems – especially cheese wiring – owing to the weak Bowman layer in the recipient corneal rim which provides an ineffective anchor point/ resistance barrier to suture pull-through.[68] In one study of 947 consecutive eyes operated for advanced KC, 10% required re-suturing at some time, secondary to either graft dehiscence or loosened/ broken sutures.[163] With ongoing surface problems, both PK and DALK grafts are also more likely to fail, and "recurrence" may be more likely secondary to ongoing eye rubbing.[29,166,321,356,359]

The initial, most commonly performed, and likely optimal protocol for UV-CXL requires complete epithelial debridement. Subsequent UV radiation damages the underlying sub-epithelial nerve plexus. Consequently, any existing neurotrophic tendencies may be worsened until nerve regeneration occurs and sensation is restored, a process that can require up to a year.[230,313] This combined with post-op soft contact lens wear dramatically raises the risk for infectious keratitis and stromal melting, particularly when concomitant ocular surface disease impairs normal corneal re-epithelialization.[16,265,270,292] UV-CXL also appears to carry a theoretical risk to limbal stem cells, since some in-vitro studies demonstrate decreased regenerative capacity and increased apoptosis following treatment.[243,323] Apoptosis of anterior keratocytes also appears to be the mechanism for UV-CXL's most commonly reported complication – the development of anterior stromal haze – which may be seen in 7 to 100 % of eyes following the procedure, and may be particularly severe in patients with advanced KC. Usually, this haze gradually dissipates over the course of a year, but may be permanent in a small percentage of those affected.[133,228]

As previously mentioned, ICRS endanger the ocular surface according to how superficially they lie. Shallow segments may result in overlying tissue hypoxia (secondary to anterior stromal compression), and subsequent corneal neovascularization, recurrent erosion, corneal melting, and ring segment exposure / extrusion.[77,200,300,363] Manually dissected segment channels tend to be shallower and more irregular than those created by femtosecond laser and may predispose to more of these problems (although, femtosecond created channels are more often decentered, jeopardizing the predictability and success of the corrective effect).[79,102,104,274] Compared to INTACS, Ferrara segments– because of their triangular/ wedged cross-sectional shape – may conduce to gradual segment superficialization.[152]

Unless stitched closed, wound gape may occur at the mouth of the channels. Infectious keratitis is relatively uncommon after ICRS, occurring in 2% of operated eyes.[146,155,240] Although gram positive organisms are the most common offenders, corneal cultures are usually negative, since many patients are still using post-operative antibiotics at the time of diagnosis. Treatment consists of topical antibiotics and does not always require segment explantation. Usually, no long term visual consequences are experienced, though occasionally extensive scarring requiring subsequent PK occurs.[245]

BL transplantation may be the least dangerous option in eyes with surface problems, since the operation leaves the corneal surface intact. It makes no surface incisions, uses no sutures, and instils no artificial materials **(Figure 3)**.[338,339]

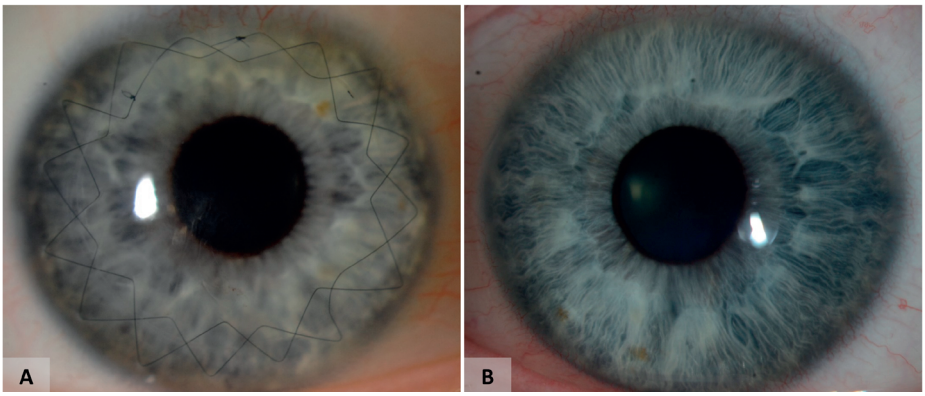

Figure 3. Two images of a single patient **(A)** Right eye, six months after DALK; **(B)** Left eye, six months after BL transplantation, with a regular ocular surface.

B. Graft rejection and failure [PK, DALK, BL Transplantation]

Although primary graft failure following PK has become rare, episodes of allograft reaction remain relatively common, affecting 13-31% of eyes in the first three years after surgery, with a mean time to onset of 8-15 months.[289,324,346-351] The most important risk factors are the size of the graft, the number of previous corneal transplants, and the presence of peripheral corneal neovascularization, though other factors have been implicated as well including the lingering presence of interrupted sutures (especially if loose), an atopic constitution, glaucoma, and having previously received a PK in the contralateral eye (especially if within the past 12 months.)[49,92,99,110,221,254,256,322] Most instances of allograft reaction can be successfully halted by the timely application of steroid treatment, such that graft failure may occur in less than 10% of such events.[128]

For the first PK an eye receives for advanced KC, long term survival is usually good, averaging 97% at 5 years, 90% at 10 years, and 80% at 20-25 years postoperatively.[67,164,177,271,322] These figures are substantially better than those reported following PK for other indications such as FED or PBK.[322] A potential explanation for this discrepancy is that eyes operated for advanced KC may have a relatively "healthy" pool of normal endothelial cells remaining within the peripheral (unoperated) corneal rim, which may migrate in to bolster and support the endothelial population of the graft over time (which may not occur if PK is performed for endothelial failure).[177,281]

After the first, all subsequent PKs that a single eye receives experience substantially lower survival rates. With second grafts, survival at 1 year may be only 88%, 69% at 5

years, and 46% at 15 years postoperatively. For third grafts, these figures are worse still, with only 65% surviving 1 year, 49% surviving 5 years, and 33% surviving 15 years (median survival of 4 years).[177,360] Time to first failure is an important independent risk factor for future failures, with transplants having failed within the first decade more than four times as likely to fail again. Recipient age greater than 60 is another risk factor for subsequent grafts (after the first) to fail.[177,281,360] Because many patients with advanced KC are transplanted early in life, it may be more likely than not that, ultimately, more than one graft may be required over their lifetime. Therefore, these dramatically worsened survival figures for subsequent grafts may be important long term consequences even for eyes with very good, initial, surgical results.

Further, recall that even some "surviving" grafts (i.e. with a healthy population of endothelial cells) may require replacement if progressive or recurrent corneal ectasia becomes severe – a condition which affects an estimated 11% of eyes at 20 years postoperatively.[118,254]

DALK may present risks for milder versions of many of these same complications. Allograft reactions may be less frequent and less likely to result in graft failure.[299] Graft survival is projected to be longer, with Borderie et al calculating an average lifespan for PK grafts of 17.9 years, compared to 49.0 years with DALK.[38] Probably, this disparity exists because, after DALK, ECDs are consistently higher than after PK (unless an intraoperative DM perforation occurs, in which case they are equal).[38,65,335] Occasionally, an eye will require a re-operation after DALK secondary to poor visual acuity, usually because of interface haze stemming from incomplete or pre-descemetic stromal dissection. While some studies label these "underperforming" DALKs as "failed grafts," it is important to note that the mechanism is fundamentally different than graft failures following PK.[81]

With BL transplantation, the transplanted tissue is acellular, and therefore would be theoretically unlikely to provoke a strong immune reaction. To date, no episodes of allograft reaction, or graft failure, have been observed.[338,339]

C. DM perforation [DALK, ICRS, BL Transplantation]

DALK's most significant complication is intraoperative DM perforation, which may occur in 0-50 % of eyes.19[90,111,176,204,236] Depending on the size of the perforation, conversion to PK (or suturing/ gluing of the ruptured DM) may be necessary to avoid the formation of a double anterior chamber and persistent corneal edema.[18,318] If using Melles manual dissection (rather than the Anwar big-bubble), if perforation occurs the operation can be aborted and reattempted at a later date, since no surface incisions have been made.

ICRS placement may cause DM perforation in approximately 5% of eyes with advanced KC, being especially likely in extremely thin and steep corneas. Although the DM rupture is usually sustained intra-operatively, late perforations have also been reported attributed to segment migration stemming from eye rubbing.[138,169,261]

BL transplantation may also result in inadvertent DM perforation – reported in 4-9% of eyes – particularly in especially thin and steep corneas. As with Melles manual DALK, if rupture occurs, the operation may be aborted and rescheduled or converted to PK.[338,339]

D. Glaucoma [PK, DALK, BL Transplantation]

Although severe intraocular pressure (IOP) increases are less common when the indication for PK is advanced KC (compared to herpetic disease, intractable ulcer, FED, PBK, or corneal perforation), still, most eyes – approximately 75% - experience a pressure rise.[23,107,132] According to a report by Erdurmus et al, these IOP elevations are >5mmHg from baseline in 72% of patients, and >10mmHg in 24%. Although usually resolving with steroid tapering, persistently high IOP (requiring treatment) may ensue in 6-15% of operated eyes.[100,154] In aphakic eyes, there is a smaller incidence of glaucoma one year after surgery if an oversized (versus a same-sized) graft is used, although this result has been frequently extrapolated to argue for oversizing grafts in phakic and pseudophakic eyes as well.[41,365]

Likely because of their lower steroid requirement (owing to the smaller risk of rejection), eyes receiving DALK may be less prone to IOP problems.[144,247,335] For eyes with advanced KC, Zhang et al described an increase in IOP following DALK in only 1.3% of operated eyes, compared to 42% of eyes after PK.[364] Actual glaucoma may also be less common (by up to 40%) per a study by Tan et al.[320]

Presently, it is standard to use the same postoperative steroid regimen following BL transplantation as with DALK (though, after a year, it may be possible to discontinue topical steroids entirely). Consequently, BL transplantation may embody some, though probably lower, risk for glaucoma than either DALK or PK. Presently, however, there is only a single case reported of glaucoma diagnosed after BL transplantation, though it is unclear whether the operation itself was responsible. [338,339]

XII. FUTURE DIRECTIONS

Treatment for advanced KC has trended away from PK (and to some extent, even DALK) largely because of the problems these surgeries entail: ocular surface and wound healing difficulties, suture related issues, allograft reactions, glaucoma, and others. UV-CXL, ICRS, and – most recently, BL transplantation – represent the "second wave" of therapeutic options for advanced KC, notable especially for being much less invasive, and therefore, potentially safer. All three of these latter operations require more study, particularly BL transplantation, whose first patients are now only four years removed from surgery. But if substantial, permanent corneal flattening can be achieved without

surface incisions, sutures, or the requirement for long term steroids, then these surgeries may represent the future of advanced KC treatment.

XIII. METHODS OF LITERATURE SEARCH

The Pubmed and Cochrane library was searched electronically for peer-reviewed literature in November 2013 and October 2014 without date restrictions. Key words employed in the search included keratoconus, penetrating keratoplasty, deep anterior lamellar keratoplasty, intracorneal ring segments, and corneal crosslinking, Articles were included according to their relevance to the subject and excluded to avoid redundancy.

XIV. DISCLOSURE

No author has a financial or proprietary interest in any material or method mentioned. Dr Melles is a consultant for D.O.R.C. International/ Dutch Ophthalmic USA and Surgi-Cube International.

REFERENCES

1. Abou Shousha M, Perez VL, Fraga Santini Canto AP, et al. The use of Bowman's layer vertical topographic thickness map in the diagnosis of keratoconus. Ophthalmology. 2014;121(5):988-93
2. Acar BT, Vural ET, Acar S. Does the type of suturing technique used affect astigmatism after deep anterior lamellar keratoplasty in keratoconus patients? Clin Ophthalmol. 2011;5:425-8
3. Ahearne M, Yang Y, Then KY, Liu KK. Non-destructive mechanical characterisation of UVA/riboflavin crosslinked collagen hydrogels. Br J Ophthalmol. 2008;92(2):268-71
4. Akdemir MO, Kandemir B, Sayman IB, et al.Comparison of contrast sensitivity and visual acuity between deep anterior lamellar keratoplasty and penetrating keratoplasty in patients with keratoconus. Int J Ophthalmol. 2012;5(6):737-41
5. Akova YA, Dabil H, Kavalcioglu O, Duman S. Clinical features and keratoplasty results in keratoconus complicated by acute hydrops. Ocul Immunol Inflamm. 2000;8(2):101-9
6. Alfonso JF, Lisa C, Fernández-Vega L, et al. Intrastromal corneal ring segment implantation in 219 keratoconic eyes at different stages. Graefes Arch Clin Exp Ophthalmol. 2011;249(11):1705-12
7. Alió JL, Artola A, Ruiz-Moreno JM, et al. Changes in keratoconic corneas after intracorneal ring segment explantation and reimplantation. Ophthalmology. 2004;111(4):747-51
8. Alió JL, Shabayek MH, Belda JI, et al. Analysis of results related to good and bad outcomes of Intacs implantation for keratoconus correction. J Cataract Refract Surg. 2006;32(5):756-61
9. Alió JL, Shabayek MH. Intracorneal asymmetrical rings for keratoconus: where should the thicker segment be implanted? J Refract Surg. 2006;22(3):307-9
10. Alió JL, Vega-Estrada A, Esperanza S, et al. Intrastromal corneal ring segments: how successful is the surgical treatment of keratoconus? Middle East Afr J Ophthalmol. 2014;21(1):3-9
11. Al-Mohaimeed MM. Penetrating keratoplasty for keratoconus: visual and graft survival outcomes. Int J Health Sci (Qassim). 2013;7(1):67-74
12. Alsuhaibani AH, Al-Rajhi AA, Al-Motowa SM, Wagoner MD. Corneal endothelial cell density and morphology after acute hydrops in keratoconus. Cornea. 2008;27(5):535-8
13. Amayem AF, Anwar M. Fluid lamellar keratoplasty in keratoconus. Ophthalmology. 2000;107(1):76-9
14. Amayem AF, Hamdi IM, Hamdi MM. Refractive and visual outcomes of penetrating keratoplasty versus deep anterior lamellar keratoplasty with hydrodissection for treatment of keratoconus. Cornea. 2013;32(4):e2-5
15. Amigo A, Bonaque S. Safety of extended use of hypoosmolar riboflavin in crosslinking. J Cataract Refract Surg. 2014;40(1):171-2
16. Angunawela RI, Arnalich-Montiel F, Allan BD. Peripheral sterile corneal infiltrates and melting after collagen crosslinking for keratoconus. J Cataract Refract Surg. 2009;35(3):606-7
17. Anwar HM, Anwar M. Predescemetic dissection for healed hydrops--judicious use of air and fluid. Cornea. 2011;30(12):1502-9
18. Anwar HM, El-Danasoury A, Hashem AN. The use of fibrin glue to seal Descemet membrane microperforations occurring during deep anterior lamellar keratoplasty. Cornea. 2012;31(10):1193-6
19. Anwar M, Teichmann KD. Big-bubble technique to bare Descemet's membrane in anterior lamellar keratoplasty. J Cataract Refract Surg. 2002;28(3):398-403
20. Ardjomand N, Hau S, McAlister JC, et al. Quality of vision and graft thickness in deep anterior lamellar and penetrating corneal allografts. Am J Ophthalmol. 2007;143(2):228-35

21. Arora R, Jain P, Goyal JL, Gupta D. Comparative analysis of refractive and topographic changes in early and advanced keratoconic eyes undergoing corneal collagen crosslinking. Cornea. 2013; Aug 22 [Epub ahead of print]
22. Asri D, Touboul D, Fournié P, et al.Corneal collagen crosslinking in progressive keratoconus: multicenter results from the French National Reference Center for Keratoconus. J Cataract Refract Surg. 2011;37(12):2137-43
23. Ayyala RS. Penetrating keratoplasty and glaucoma. Surv Ophthalmol. 2000;45(2):91-105
24. Azar RG, Holdbrook MJ, Lemp M, et al. Two-year corneal endothelial cell assessment following INTACS implantation. J Refract Surg. 2001;17(5):542-8
25. Baenninger PB, Bachmann LM, Wienecke L, et al. Effects and adverse events after CXL for keratoconus are independent of age: a 1-year follow-up study. Eye (Lond). 2014;28(6):691-5
26. Bagga B, Pahuja S, Murthy S, Sangwan VS. Endothelial failure after collagen cross-linking with riboflavin and UV-A: case report with literature review. Cornea. 2012; 31(10):1197-200
27. Bahar I, Kaiserman I, Srinivasan S, et al. Comparison of three different techniques of corneal transplantation for keratoconus. Am J Ophthalmol. 2008;146(6):905-12
28. Balestrazzi E, Balestrazzi A, Mosca L, Balestrazzi A. Deep lamellar keratoplasty with trypan blue intrastromal staining. J Cataract Refract Surg. 2002;28(6):929-31
29. Basu S, Reddy JC, Vaddavalli PK, et al. Long-term outcomes of penetrating keratoplasty for keratoconus with resolved corneal hydrops. Cornea. 2012;31(6):615-20
30. Basu S, Sangwan VS. Efficacy and safety of conductive keratoplasty in keratoconus. Am J Ophthalmol. 2011;151(4):735;author reply 735-6
31. Bechrakis N, Blom ML, Stark WJ, Green WR. Recurrent keratoconus. Cornea. 1994;13(1):73-7
32. Bedi R, Touboul D, Pinsard L, Colin J. Refractive and topographic stability of Intacs in eyes with progressive keratoconus: five-year follow-up. J Refract Surg. 2012;28(6):392-6
33. Behrens A, Seitz B, Langenbucher A, et al. Lens opacities after nonmechanical versus mechanical corneal trephination for keratoplasty in keratoconus. J Cataract Refract Surg. 2000;26(11):1605-11
34. Bilgihan K, Ozdek SC, Sari A, Hasanreisoglu B. Microkeratome-assisted lamellar keratoplasty for keratoconus: stromal sandwich. J Cataract Refract Surg. 2003;29(7):1267-72
35. Bodenmueller M, Goldblum D, Frueh BE. Penetrating keratoplasty in Down's syndrome. Klin Monbl Augenheilkd. 2003;220(3):99-102
36. Boimer C, Lee K, Sharpen L, et al. Evolving surgical techniques of and indications for corneal transplantation in Ontario from 2000 to 2009. Can J Ophthalmol. 2011;46(4):360-6
37. Borderie VM, Georgeon C, Borderie M, et al. Corneal radius of curvature after anterior lamellar versus penetrating keratoplasty. Graefes Arch Clin Exp Ophthalmol. 2014;252(3):449-56
38. Borderie VM, Sandali O, Bullet J, et al. Long-term results of deep anterior lamellar versus penetrating keratoplasty.Ophthalmology. 2012;119(2):249-55
39. Bottós KM, Hofling-Lima AL, Barbosa MC, et al. Effect of collagen cross-linking in stromal fibril organization in edematous human corneas. Cornea. 2010;29(7):789-93
40. Bourges JL, Savoldelli M, Dighiero P, et al. Recurrence of keratoconus characteristics: a clinical and histologic follow-up analysis of donor grafts. Ophthalmology. 2003;110(10):1920–5
41. Bourne WM, Davison JA, O'Fallon WM. The effects of oversize donor buttons on postoperative intraocular pressure and corneal curvature in aphakic penetrating keratoplasty. Ophthalmology. 1982;89(3):242-6
42. Boxer Wachler BS, Christie JP, Chandra NS, et al. Intacs for keratoconus. Ophthalmology. 2003; 110(5):1031-40

43. Brahma A, Ennis F, Harper R, et al. Visual function after penetrating keratoplasty for keratoconus: a prospective longitudinal evaluation. Br J Ophthalmol. 2000;84(1):60-6
44. Brierly SC, Izquierdo L Jr, Mannis MJ. Penetrating keratoplasty for keratoconus. Cornea. 2000; 19(3):329-32
45. Buratto L, Böhm E. The use of the femtosecond laser in penetrating keratoplasty. Am J Ophthalmol. 2007;143(5):737-742
46. Burk LL, Waring GO 3rd, Radjee B, Stulting RD. The effect of selective suture removal on astigmatism following penetrating keratoplasty. Ophthalmic Surg. 1988;19(12):849-54
47. Busin M, Mönks T, al-Nawaiseh I. Different suturing techniques variously affect the regularity of postkeratoplasty astigmatism. Ophthalmology. 1998;105(7):1200-5
48. Busin M, Zambianchi L, Arffa RC. Microkeratome-assisted lamellar keratoplasty for the surgical treatment of keratoconus. Ophthalmology. 2005;112(6):987-97
49. Buxton JN, Schuman M, Pecego J. Graft reactions after unilateral and bilateral keratoplasty for keratoconus. Ophthalmology. 1981;88(8):771-3
50. Buzard KA, Fundingsland BR. Corneal transplant for keratoconus: results in early and late disease. J Cataract Refract Surg. 1997;23(3):398-406
51. Buzzonetti L, Petrocelli G, Laborante A. Anterior lamellar keratoplasty assisted by IntraLase™ femtosecond laser in a pediatric patient. J Pediatr Ophthalmol Strabismus. 2010;47:e1-4
52. Buzzonetti L, Petrocelli G, Valente P. Big-bubble deep anterior lamellar keratoplasty assisted by femtosecond laser in children. Cornea. 2012;31(9):1083-6
53. Cakir H, Pekel G, Perente I, Genç S. Comparison of intrastromal corneal ring segment implantation only and in combination with collagen crosslinking for keratoconus. Eur J Ophthalmol. 2013; 23(5):629-34
54. Caporossi A, Mazzotta C, Baiocchi S, et al. Age-related long-term functional results after riboflavin UV A corneal cross-linking. J Ophthalmol. 2011;2011:608041
55. Caporossi A, Mazzotta C, Baiocchi S, et al. Riboflavin-UVA-induced corneal collagen cross-linking in pediatric patients. Cornea. 2012;31(3):227-31
56. Caporossi A, Mazzotta C, Paradiso AL, et al. Transepithelial corneal collagen crosslinking for progressive keratoconus: 24-month clinical results. J Cataract Refract Surg. 2013;39(8):1157-63
57. Carrasquillo KG, Rand J, Talamo JH. Intacs for keratoconus and post-LASIK ectasia: mechanical versus femtosecond laser-assisted channel creation. Cornea. 2007;26(8):956-62
58. Cason JB, Yiu SC. Acute hydrops in the donor cornea graft in non-keratoconus patients. Middle East Afr J Ophthalmol. 2013;20(3):265-7
59. Chamberlain WD, Rush SW, Mathers WD, et al. Comparison of femtosecond laser-assisted keratoplasty versus conventional penetrating keratoplasty. Ophthalmology. 2011;118(3):486-91
60. Chan CC, Sharma M, Wachler BS. Effect of inferior-segment Intacs with and without C3-R on keratoconus. J Cataract Refract Surg. 2007;33(1):75-80
61. Chan CC, Wachler BS. Reduced best spectacle-corrected visual acuity from inserting a thicker Intacs above and thinner Intacs below in keratoconus. J Refract Surg. 2007;23(1):93-5
62. Chan E, Snibson GR. Current status of corneal collagen cross-linking for keratoconus: a review. Clin Exp Optom. 2013;96(2):155-64
63. Chang DF, Tan JJ, Tripodis Y. Risk factors for steroid response among cataract patients. J Cataract Refract Surg. 2011;37(4):675-81
64. Chatzis N, Hafezi F. Progression of keratoconus and efficacy of pediatric [corrected] corneal collagen cross-linking in children and adolescents. J Refract Surg. 2012;28(11):753-8

65. Cheng YY, Visser N, Schouten JS, et al. Endothelial cell loss and visual outcome of deep anterior lamellar keratoplasty versus penetrating keratoplasty: a randomized multicenter clinical trial. Ophthalmology. 2011;118(2):302-9
66. Chew AC, Mehta JS, Tan DT. Deep lamellar keratoplasty after resolution of hydrops in keratoconus. Cornea. 2011;30(4):454-9
67. Choi JA, Lee MA, Kim MS. Long-term outcomes of penetrating keratoplasty in keratoconus: analysis of the factors associated with final visual acuities. Int J Ophthalmol. 2014;7(3):517-21
68. Christo CG, van Rooij J, Geerards AJ, et al. Suture-related complications following keratoplasty: a 5-year retrospective study. Cornea. 2001;20(8):816-9
69. Chunyu T, Xiujun P, Zhengjun F, et al. Corneal collagen cross-linking in keratoconus: a systematic review and meta-analysis. Sci Rep. 2014;4:5652
70. Ciftci S, Ciftci L, Dogan E, Simsek A. Sensory exotropia associated with keratoconus and review of literature: strabismus and keratoconus. Eye Sci. 2013;28(2):88-91
71. Colin J, Buestel C, Touboul D. Unusual secondary displacement of Intacs segments--superimposition of distal ends. J Refract Surg. 2010;26(12):924-5
72. Colin J, Cochener B, Savary G, et al. INTACS inserts for treating keratoconus: one-year results. Ophthalmology. 2001;108(8):1409-14
73. Colin J, Malet FJ.Intacs for the correction of keratoconus: two-year follow-up. J Cataract Refract Surg. 2007;33(1):69-74
74. Colin J, Touboul D, Bedi R. Refractive and keratometric outcomes of intacs continue to improve until 6 months. Cornea. 2011;30(9):1068; author reply 1068-9
75. Colin J, Velou S. Current surgical options for keratoconus. Cataract Refract Surg. 2003;29(2):379-86
76. Coombes AG, Kirwan JF, Rostron CK. Deep lamellar keratoplasty with lyophilised tissue in the management of keratoconus. Br J Ophthalmol. 2001;85(7):788-91
77. Cosar CB, Sridhar MS, Sener B. Late onset of deep corneal vascularization: a rare complication of intrastromal corneal ring segments for keratoconus. Eur J Ophthalmol. 2009;19(2):298-300
78. Coskunseven E, Jankov MR 2nd, Hafezi F, et al. Effect of treatment sequence in combined intrastromal corneal rings and corneal collagen crosslinking for keratoconus. J Cataract Refract Surg. 2009;35(12):2084-91
79. Coskunseven E, Kymionis GD, Tsiklis NS, et al. Complications of intrastromal corneal ring segment implantation using a femtosecond laser for channel creation: a survey of 850 eyes with keratoconus. Acta Ophthalmol. 2011;89(1):54-7
80. Coskunseven E, Kymionis GD, Tsiklis NS, et al. One-year results of intrastromal corneal ring segment implantation (KeraRing) using femtosecond laser in patients with keratoconus. Am J Ophthalmol. 2008;145(5):775-9
81. Coster DJ, Lowe MT, Keane MC, et al. A comparison of lamellar and penetrating keratoplasty outcomes: a registry study. Ophthalmology. 2014;121(5):979-87
82. Craig JA, Mahon J, Yellowlees A, et al. Epithelium-off photochemical corneal collagen cross-linkage using riboflavin and ultraviolet a for keratoconus and keratectasia: a systematic review and meta-analysis. Ocul Surf. 2014;12(3):202-14
83. Cullen J, Butler H. Mongolism (down's syndrome) and keratoconus.Br J Ophthalmol. 1963;47: 321-30
84. Dalton K, Sorbara L. Fitting an MSD (mini scleral design) rigid contact lens in advanced keratoconus with INTACS. Cont Lens Anterior Eye. 2011;34(6):274-81
85. Dang TQ, Molchan RP, Taylor KR, et al. Novel approach for the treatment of corneal ectasia in a graft. Cornea. 2014;33(3):310-2

86. Das S, Dua N, Ramamurthy B. Deep lamellar keratoplasty in keratoconus with healed hydrops. Cornea. 2007;26(9):1156-7
87. Davis EA, Azar DT, Jakobs FM, Stark WJ. Refractive and keratometric results after the triple procedure: experience with early and late suture removal. Ophthalmology. 1998;105(4):624-30
88. De Bernardo M, Capasso L, Tortori A, et al. Trans epithelial corneal collagen crosslinking for progressive keratoconus: 6 months follow up. Cont Lens Anterior Eye. 2014; Aug 26 [Epub ahead of print]
89. de Toledo JA, de la Paz MF, Barraquer RI, Barraquer J. Long-term progression of astigmatism after penetrating keratoplasty for keratoconus: evidence of late recurrence. Cornea. 2003;22(4):317-23
90. Den S, Shimmura S, Tsubota K, Shimazaki J. Impact of the descemet membrane perforation on surgical outcomes after deep lamellar keratoplasty. Am J Ophthalmol. 2007;143(5):750-4
91. Dogru M, Karakaya H, Ozçetin H, et al. Tear function and ocular surface changes in keratoconus. Ophthalmology. 2003;110(6):1110-8
92. Donshik PC, Cavanagh HD, Boruchoff SA, Dohlman CH. Effect of bilateral and unilateral grafts on the incidence of rejections in keratoconus. Am J Ophthalmol. 1979;87(6):823-6
93. Donshik PC, Cavanaugh HD, Boruchoff SA, Dohlman CH. Posterior subcapsular cataracts induced by topical corticosteroids following keratoplasty for keratoconus. Ann Ophthalmol. 1981;13(1): 29-32
94. Downie LE. The necessity for ocular assessment in atopic children: bilateral corneal hydrops in an 8 year old. Pediatrics. 2014;134(2):e596-601
95. Duran JA, Malvar A, Diez E. Corneal dioptric power after penetrating keratoplasty. Br J Ophthalmol. 1989;73(8):657-60
96. El Awady H, Shawky M, Ghanem AA. Evaluation of collagen crosslinking in keratoconus eyes with Kera intracorneal ring implantation. Eur J Ophthalmol. 2012;22(Suppl 7):S62-.
97. El-Agha MS, El Sayed YM, Harhara RM, Essam HM. Correlation of corneal endothelial changes with different stages of keratoconus. Cornea. 2014;33(7):707-11
98. El-Raggal TM. Effect of corneal collagen crosslinking on femtosecond laser channel creation for intrastromal corneal ring segment implantation in keratoconus. J Cataract Refract Surg. 2011; 37(4):701-5
99. Epstein AJ, de Castro TN, Laibson PR, et al. Risk factors for the first episode of corneal graft rejection in keratoconus. Cornea. 2006;25(9):1005-11
100. Erdurmus M, Cohen EJ, Yildiz EH, et al. Steroid-induced intraocular pressure elevation or glaucoma after penetrating keratoplasty in patients with keratoconus or Fuchs dystrophy. Cornea. 2009;28(7):759-64
101. Ertan A, Colin J. Intracorneal rings for keratoconus and keratectasia. J Cataract Refract Surg. 2007; 33(7):1303-14
102. Ertan A, Kamburoğlu G. Analysis of centration of Intacs segments implanted with a femtosecond laser. J Cataract Refract Surg. 2007;33(3):484-7
103. Ertan A, Kamburoğlu G. Intacs implantation using a femtosecond laser for management of keratoconus: Comparison of 306 cases in different stages. J Cataract Refract Surg. 2008;34(9):1521-6
104. Ertan A, Karacal H. Factors influencing flap and INTACS decentration after femtosecond laser application in normal and keratoconic eyes. J Refract Surg. 2008;24(8):797-801
105. Ertan A, Ozkilic E. Effect of age on outcomes in patients with keratoconus treated by Intacs using a femtosecond laser. J Refract Surg. 2008;24(7):690-5
106. Fan Gaskin JC, Patel DV, McGhee CN. Acute corneal hydrops in keratoconus - new perspectives. Am J Ophthalmol. 2014;157(5):921-8

107. Fan JC, Chow K, Patel DV, McGhee CN. Corticosteroid-induced intraocular pressure elevation in keratoconus is common following uncomplicated penetrating keratoplasty. Eye (Lond). 2009; 23(11):2056-62
108. Fares U, Sarhan AR, Dua HS. Management of post-keratoplasty astigmatism. J Cataract Refract Surg. 2012;38(11):2029-39
109. Faschinger C, Kleinert R, Wedrich A. [Corneal melting in both eyes after simultaneous corneal cross-linking in a patient with keratoconus and Down syndrome]. Ophthalmologe. 2010;107(10): 951-2,954-5
110. Fasolo A, Capuzzo C, Fornea M, et al. Risk factors for graft failure after penetrating keratoplasty: 5-year follow-up from the corneal transplant epidemiological study. Cornea. 2011;30(12):1328-35
111. Feizi S, Javadi MA, Jamali H, Mirbabaee F. Deep anterior lamellar keratoplasty in patients with keratoconus: big-bubble technique. Cornea. 2010;29(2):177-82
112. Feizi S, Javadi MA, Rezaei Kanavi M. Recurrent keratoconus in a corneal graft after deep anterior lamellar keratoplasty. J Ophthalmic Vis Res. 2012;7(4):328-31
113. Ferrara P, Ferrara G, Torquetti L. Ferrara technique of deep anterior lamellar keratoplasty for keratoconus treatment. Int J Keratoconus Ectatic Corneal Diseases. 2013;2(2):51-5
114. Ferreira TB, Güell JL, Manero F. Combined intracorneal ring segments and iris-fixated phakic intraocular lens for keratoconus refractive and visual improvement. J Refract Surg. 2014;30(5): 336-41
115. Filippello M, Stagni E, O'Brart D. Transepithelial corneal collagen crosslinking: bilateral study. J Cataract Refract Surg. 2012;38(2):283-91
116. Fontana L, Parente G, Sincich A, Tassinari G. Deep anterior lamellar keratoplasty after Intacs implantation in patients with keratoconus. Cornea. 2009;28(1):32-5
117. Fontana L, Parente G, Sincich A, Tassinari G. Influence of graft-host interface on the quality of vision after deep anterior lamellar keratoplasty in patients with keratoconus. Cornea. 2011;30(5): 497-502
118. Fukuoka S, Honda N, Ono K, et al. Extended long-term results of penetrating keratoplasty for keratoconus.Cornea. 2010;29(5):528-30
119. Funnell CL, Ball J, Noble BA. Comparative cohort study of the outcomes of deep lamellar keratoplasty and penetrating keratoplasty for keratoconus. Eye (Lond). 2006;20(5):527-32
120. Ganekal S, Gangangouda C, Dorairaj S, Jhanji V. Early outcomes of primary pediatric keratoplasty in patients with acquired, atraumatic corneal pathology. J AAPOS. 2011;15(4):353-5
121. García García GP, Martínez JB. Outcomes of penetrating keratoplasty in mentally retarded patients with keratoconus. Cornea. 2008;27(9):980-7
122. Gaster RN, Dumitrascu O, Rabinowitz YS. Penetrating keratoplasty using femtosecond laser-enabled keratoplasty with zig-zag incisions versus a mechanical trephine in patients with keratoconus. Br J Ophthalmol. 2012;96(9):1195-9
123. Gatzioufas Z, Richoz O, Spoerl E, Hafezi F. Persistent corneal edema after collagen cross-linking for keratoconus. Am J Ophthalmol. 2013; 155(3): 610-1
124. Geerards AJ, Vreugdenhil W, Khazen A. Incidence of rigid gas-permeable contact lens wear after keratoplasty for keratoconus. Eye Contact Lens. 2006;32(4):207-10
125. Ghanem RC, Ghanem MA. Pachymetry-guided intrastromal air injection ("pachy-bubble") for deep anterior lamellar keratoplasty. Cornea. 2012;31(9):1087-91
126. Gharaibeh AM, Muhsen SM, AbuKhader IB, et al. KeraRing intrastromal corneal ring segments for correction of keratoconus. Cornea. 2012;31(2):115-20

127. Giedd KK, Mannis MJ, Mitchell GL, Zadnik K. Personality in keratoconus in a sample of patients derived from the internet. Cornea. 2005;24(3):301-7
128. Girard LJ, Esnaola N, Rao R, et al R. Allograft rejection after penetrating keratoplasty for keratoconus. Ophthalmic Surg. 1993;24(1):40-3
129. Goble RR, Hardman Lea SJ, Falcon MG. The use of the same size host and donor trephine in penetrating keratoplasty for keratoconus. Eye (Lond). 1994;8(Pt 3):311-4
130. Goldich Y, Barkana Y, Wussuku Lior O, et al. Corneal collagen cross-linking for the treatment of progressive keratoconus: 3-year prospective outcome. Can J Ophthalmol. 2014;49(1):54-9
131. Goldich Y, Marcovich AL, Barkana Y, et al. Safety of corneal collagen cross-linking with UV-A and riboflavin in progressive keratoconus. Cornea. 2010;29(4):409–11
132. Greenlee EC, Kwon YH. Graft failure: III. Glaucoma escalation after penetrating keratoplasty. Int Ophthalmol. 2008;28(3):191-207
133. Greenstein SA, Fry KL, Bhatt J, Hersh PS. Natural history of corneal haze after collagen crosslinking for keratoconus and corneal ectasia: Scheimpflug and biomicroscopic analysis. J Cataract Refract Surg. 2010;36(12):2105-14
134. Greenstein SA, Fry KL, Hersh PS. Effect of topographic cone location on outcomes of corneal collagen cross-linking for keratoconus and corneal ectasia. J Refract Surg. 2012;28(6):397-405
135. Greenstein, SA, Hersh PS.Characteristics influencing outcomes of corneal collagen crosslinking for keratoconus and ectasia: implications for patient selection. J Cataract Refract Surg 2013;39(8): 1133-40
136. Grewal DS, Brar GS, Jain R, et al. Corneal collagen crosslinking using riboflavin and ultraviolet-A light for keratoconus: one-year analysis using Scheimpflug imaging. J Cataract Refract Surg. 2009; 35(3):425-32
137. Gripp KW, Demmer LA. Keratoconus in Costello syndrome. Am J Med Genet A. 2013;161A(5): 1132-6
138. Güell JL, Verdaguer P, Elies D, et al. Acute corneal hydrops after intrastromal corneal ring segment implantation for keratoconus. J Cataract Refract Surg. 2012;38(12):2192-5
139. Gumus K. Acute idiopathic endotheliitis early after corneal cross-linking with riboflavin and ultraviolet-A. Cornea. 2014;33(6):630-3
140. Gunes A, Tok L, Tok O, Seyrek L. The youngest patient with bilateral keratoconus eecondary to chronic persistent eye rubbing. Semin Ophthalmol. 2014 Feb 7. [Epub ahead of print]
141. Haddad W, Fadlallah A, Dirani A, et al. Comparison of 2 types of intrastromal corneal ring segments for keratoconus. J Cataract Refract Surg. 2012;38(7):1214-21
142. Hafezi F, Mrochen M, Iseli HP, Seiler T. Collagen crosslinking with ultraviolet-A and hypoosmolar riboflavin solution in thin corneas. J Cataract Refract Surg. 2009;35(4):621-4
143. Hafezi F. Limitation of collagen cross-linking with hypoosmolar riboflavin solution: failure in an extremely thin cornea. Cornea. 2011;30(8):917-9
144. Han DC, Mehta JS, Por YM, et al. Comparison of outcomes of lamellar keratoplasty and penetrating keratoplasty in keratoconus. Am J Ophthalmol. 2009;148(5):744-51
145. Harding SA, Nischal KK, Upponi-Patil A, Fowler DJ. Indications and outcomes of deep anterior lamellar keratoplasty in children. Ophthalmology. 2010;117(11):2191-5
146. Hashemi H, Ghaffari R, Mohammadi M, et al. Microbial keratitis after INTACS implantation with loose suture. J Refract Surg. 2008;24(5):551-2
147. Hashemi H, Yazdani-Abyaneh A, Beheshtnejad A, et al. Efficacy of intacs intrastromal corneal ring segment relative to depth of insertion evaluated with anterior segment optical coherence tomography. Middle East Afr J Ophthalmol. 2013;20(3):234-8

148. Haugen OH, Høvding G, Eide GE, Bertelsen T. Corneal grafting for keratoconus in mentally retarded patients. Acta Ophthalmol Scand. 2001;79(6):609-15
149. Hayes S, Young R, Boote C, et al. A structural investigation of corneal graft failure in suspected recurrent keratoconus. Eye (Lond). 2010;24(4):728-34
150. Heidemann DG, Sugar A, Meyer RF, Musch DC. Oversized donor grafts in penetrating keratoplasty. A randomized trial. Arch Ophthalmol. 1985;103(12):1807-11
151. Hladun L, Harris M. Contact lens fitting over intrastromal corneal rings in a keratoconic patient. Optometry. 2004;75(1):48-54
152. Hofling-Lima AL, Branco BC, Romano AC, et al. Corneal infections after implantation of intracorneal ring segments. Cornea. 2004;23(6):547-9
153. Holopainen JM,.Krootila K. Transient corneal thinning in eyes undergoing corneal cross-linking. Am J Ophthalmol. 2011;152(4):533-6
154. Huber KK, Maier AK, Klamann MK, et al. Glaucoma in penetrating keratoplasty: risk factors, management and outcome. Graefes Arch Clin Exp Ophthalmol. 2013;251(1):105-16
155. Ibáñez-Alperte J, Pérez-García D, Cristóbal JA, et al. Keratitis after implantation of intrastromal corneal rings with spontaneous extrusion of the segment. Case Rep Ophthalmol. 2010;1(2):42-6
156. Ishii R, Kamiya K, Igarashi A, et al. Correlation of corneal elevation with severity of keratoconus by means of anterior and posterior topographic analysis. Cornea. 2012;31(3):253-8
157. Ivarsen A, Hjortdal J. Collagen cross-linking for advanced progressive keratoconus. Cornea. 2013; 32(7):903-6
158. Jabbarvand M, Mohammadpour M. Deep lamellar keratoplasty in keratoconus with healed hydrops. Cornea. 2008;27(9):1100;author reply 1100
159. Jabbarvand M, Salamatrad A, Hashemian H, Khodaparast M. Continuous corneal intrastromal ring implantation for treatment of keratoconus in an Iranian population. Am J Ophthalmol. 2013; 155(5):837-42
160. Jabbarvand M, Salamatrad A, Hashemian H, et al. Continuous intracorneal ring implantation for keratoconus using a femtosecond laser.J Cataract Refract Surg. 2013;39(7):1081-7
161. Javadi MA, Motlagh BF, Jafarinasab MR, et al. Outcomes of penetrating keratoplasty in keratoconus. Cornea. 2005;24(8):941-6
162. Jaycock PD, Jones MN, Males J, et al. UK Transplant Ocular Tissue Advisory Group and Contributing Ophthalmologists. Outcomes of same-sizing versus oversizing donor trephines in keratoconic patients undergoing first penetrating keratoplasty. Ophthalmology. 2008;115(2):268-75
163. Jeganathan SV, Ghosh S, Jhanji V, et al. Resuturing following penetrating keratoplasty: a retrospective analysis. Br J Ophthalmol. 2008;92(7):893-5
164. Jensen LB, Hjortdal J, Ehlers N. Longterm follow-up of penetrating keratoplasty for keratoconus. Acta Ophthalmol. 2010;88(3):347-51
165. Jiménez-Alfaro I, Pérez-Santonja JJ, Gómez Tellería G, et al. Therapeutic lamellar keratoplasty with an automated microkeratome. J Cataract Refract Surg. 2001;27(8):1161-5
166. Jones MN, Armitage WJ, Ayliffe W, et al. Penetrating and deep anterior lamellar keratoplasty for keratoconus: a comparison of graft outcomes in the United kingdom. Invest Ophthalmol Vis Sci. 2009;50(12):5625-9
167. Kandarakis A, Karampelas M, Soumplis V, et al. A case of bilateral self-induced keratoconus in a patient with tourette syndrome associated with compulsive eye rubbing: case report. BMC Ophthalmol. 2011;11:28

168. Kanellopoulos AJ, Asimellis G. Epithelial remodeling after partial topography-guided normalization and high-fluence short-duration crosslinking (Athens protocol): Results up to 1 year. J Cataract Refract Surg. 2014;40(10):1597-602
169. Kanellopoulos AJ, Pe LH, Perry HD, Donnenfeld ED. Modified intracorneal ring segment implantations (INTACS) for the management of moderate to advanced keratoconus: efficacy and complications. Cornea. 2006;25(1):29-33
170. Kanellopoulos AJ, Asimellis G. Revisiting keratoconus diagnosis and progression classification based on evaluation of corneal asymmetry indices, derived from Scheimpflug imaging in keratoconic and suspect cases. Clin Ophthalmol. 2013;7:1539-1548
171. Kankariya VP, Kymionis GD, Diakonis VF, Yoo SH. Management of pediatric keratoconus - evolving role of corneal collagen cross-linking: an update. Indian J Ophthalmol. 2013;61(8):435-40
172. Kato N, Toda I, Kawakita T, et al. Topography-guided conductive keratoplasty: treatment for advanced keratoconus. Am J Ophthalmol. 2010;150(4):481-9
173. Kaushal S, Jhanji V, Sharma N, et al. "Tuck in" lamellar keratoplasty (TILK) for corneal ectasias involving corneal periphery. Br J Ophthalmol. 2008;92:286–90
174. Kaya V, Utine CA, Yilmaz OF. Efficacy of corneal collagen cross-linking using a custom epithelial debridement technique in thin corneas: a confocal microscopy study. J Refract Surg 2011;27(6): 444-50
175. Kaya V, Utine CA, Yılmaz ÖF. Intraoperative corneal thickness measurements during corneal collagen cross-linking with hypoosmolar riboflavin solution in thin corneas. Cornea. 2012;31(5): 486-90
176. Keane M, Coster D, Ziaei M, Williams K. Deep anterior lamellar keratoplasty versus penetrating keratoplasty for treating keratoconus. Cochrane Database Syst Rev. 2014;7:CD009700
177. Kelly TL, Coster DJ, Williams KA. Repeat penetrating corneal transplantation in patients with keratoconus. Ophthalmology. 2011;118(8):1538-42
178. Khairy HA, Marey HM, Ellakwa AF. Epithelium-on corneal cross-linking treatment of progressive keratoconus: a prospective, consecutive study. Clin Ophthalmol. 2014;8:819-23
179. Khan MD, Kundi N, Saeed N, et al. Incidence of keratoconus in spring catarrh. Br J Ophthalmol. 1988;72(1):41-3
180. Khan MI, Injarie A, Muhtaseb M. Intrastromal corneal ring segments for advanced keratoconus and cases with high keratometric asymmetry. J Cataract Refract Surg. 2012;38(1):129-36
181. Kim KH, Choi SH, Ahn K, et al. Comparison of refractive changes after deep anterior lamellar keratoplasty and penetrating keratoplasty for keratoconus. Jpn J Ophthalmol. 2011;55(2):93-7
182. Kim MH, Chung TY, Chung ES. A retrospective contralateral study comparing deep anterior lamellar keratoplasty with penetrating keratoplasty. Cornea. 2013;32(4):385-9
183. Kirkness CM, Ficker LA, Steele AD, Rice NS. Refractive surgery for graft-induced astigmatism after penetrating keratoplasty for keratoconus. Ophthalmology. 1991;98(12):1786-92
184. Kocak I, Aydin A, Kaya F, Koc H. Comparison of transepithelial corneal collagen crosslinking with epithelium-off crosslinking in progressive keratoconus. J Fr Ophtalmol. 2014;37(5):371-6
185. Koh S, Maeda N, Nakagawa T, et al. Characteristic higher-order aberrations of the anterior and posterior corneal surfaces in 3 corneal transplantation techniques. Am J Ophthalmol. 2012; 153(2):284-90
186. Koller B, Neuhann TF, Neuhann IM. Keratoplasty in patients with intellectual disability.Cornea. 2014;33(1):10-3
187. Koller T, Mrochen M, Seiler T. Complication and failure rates after corneal crosslinking. J Cataract Refract Surg. 2009;35(8):1358-62

188. Koppen C, Leysen I, Tassignon MJ. Riboflavin/UVA cross-linking for keratoconus in Down syndrome. J Refract Surg. 2010;26(9):623-4
189. Kotb AM, Hantera M. Efficacy and safety of Intacs SK in moderate to severe keratoconus. Middle East Afr J Ophthalmol. 2013;20(1):46-50
190. Krachmer JH, Feder RS, Belin MW. Keratoconus and related noninflammatory corneal thinning disorders. Surv Ophthalmol. 1984; 28(4):293–322
191. Krivoy D, McCormick S, Zaidman GW. Postkeratoplasty keratoconus in a nonkeratoconus patient. Am J Ophthalmol. 2001;131(5):653-4
192. Krumeich JH, Brand-Saberi B, Chankiewitz V, et al. Induction of neoplasia after deep anterior lamellar keratoplasty in a CXL-treated cornea. Cornea. 2014;33(3):313-6
193. Krumeich JH, Daniel J. Perforating keratoplasty with an intracorneal ring. Cornea. 1999;18(3): 277-81
194. Krumeich JH, Duncker G. Intrastromal corneal ring in penetrating keratoplasty: evidence-based update 4 years after implantation. J Cataract Refract Surg. 2006;32(6):993-8
195. Kubaloglu A, Cinar Y, Sari ES, et al. Comparison of 2 intrastromal corneal ring segment models in the management of keratoconus. J Cataract Refract Surg. 2010;36(6):978-85
196. Kwitko S, Severo NS. Ferrara intracorneal ring segments for keratoconus. J Cataract Refract Surg. 2004;30(4):812-20
197. Kymionis GD, Grentzelos MA, Diakonis VF, et al. Nine-year follow-up of intacs implantation for keratoconus. Open Ophthalmol J. 2009;3:77-81
198. Kymionis GD, Kounis GA, Portaliou DM. Intraoperative pachymetric measurements during corneal collagen cross-linking with riboflavin and ultraviolet A irradiation. Ophthalmology. 2009; 116(12): 2336-9
199. Kymionis GD, Siganos CS, Tsiklis NS, et al. Long-term follow-up of Intacs in keratoconus. Am J Ophthalmol. 2007;143(2):236-44
200. Lai MM, Tang M, Andrade EM, et al. Optical coherence tomography to assess intrastromal corneal ring segment depth in keratoconic eyes. J Cataract Refract Surg. 2006;32(11):1860-5
201. Laing RA, Sandstrom MM, Berrospi AR, Leibowitz HM. The human corneal endothelium in keratoconus: A specular microscopic study. Arch Ophthalmol. 1979;97(10):1867-9
202. Lake D, Hamada S, Khan S, Daya SM. Deep anterior lamellar keratoplasty over penetrating keratoplasty for host rim thinning and ectasia. Cornea. 2009;28(5):489-92
203. Langenbucher A, Naumann GO, Seitz B. Spontaneous long-term changes of corneal power and astigmatism after suture removal after penetrating keratoplasty using a regression model. Am J Ophthalmol. 2005;140(1):29-34
204. Leccisotti A. Descemet's membrane perforation during deep anterior lamellar keratoplasty: prognosis. J Cataract Refract Surg. 2007;33(5):825-9
205. Legare ME, Iovieno A, Yeung SN, et al. Intacs with or without same-day corneal collagen cross-linking to treat corneal ectasia. Can J Ophthalmol. 2013;48(3):173-8
206. Lema I, Durán JA, Ruiz C, et al. Inflammatory response to contact lenses in patients with keratoconus compared with myopic subjects. Cornea. 2008;27(7):758-63
207. Lema I, Durán JA. Inflammatory molecules in the tears of patients with keratoconus.Ophthalmology. 2005;112(4):654-9
208. Lema I, Sobrino T, Durán JA, et al. Subclinical keratoconus and inflammatory molecules from tears. Br J Ophthalmol. 2009;93(6):820-4
209. Léoni-Mesplié S, Mortemousque B, Touboul D, et al. Scalability and severity of keratoconus in children. Am J Ophthalmol. 2012;154(1):56-62

210. Levinger S, Pokroy R. Keratoconus managed with intacs: one-year results.Arch Ophthalmol. 2005; 123(10):1308-14
211. Lie J, Droutsas K, Ham L, et al. Isolated Bowman layer transplantation to manage persistent subepithelial haze after excimer laser surface ablation. J Cataract Refract Surg. 2010;36(6):1036-41
212. Lim L, Pesudovs K, Coster DJ. Penetrating keratoplasty for keratoconus: visual outcome and success. Ophthalmology. 2000;107(6):1125-31
213. Lim L, Pesudovs K, Goggin M, Coster DJ. Late onset post-keratoplasty astigmatism in patients with keratoconus. Br J Ophthalmol. 2004;88(3):371-6
214. Limaiem R, Chebil A, Baba A, et al. Pediatric penetrating keratoplasty: indications and outcomes. Transplant Proc. 2011;43(2):649-51
215. Lowe MT, Keane MC, Coster DJ, Williams KA. The outcome of corneal transplantation in infants, children, and adolescents. Ophthalmology. 2011;118(3):492-7
216. Luengo-Gimeno F, Tan DT, Mehta JS. Evolution of deep anterior lamellar keratoplasty (DALK). Ocul Surf. 2011;9(2):98-110
217. MacIntyre R, Chow SP, Chan E, Poon A. Long-term outcomes of deep anterior lamellar keratoplasty versus penetrating keratoplasty in Australian keratoconus patients. Cornea. 2014;33(1):6-9
218. Mader TH, Yuan R, Lynn MJ, et al. Changes in keratometric astigmatism after suture removal more than one year after penetrating keratoplasty. Ophthalmology. 1993;100(1):119-26; discussion 127
219. Magli A, Forte R, Tortori A, et al. Epithelium-off corneal collagen cross-linking versus transepithelial cross-linking for pediatric keratoconus. Cornea. 2013;32(5):597-601
220. Maharana PK, Sharma N, Vajpayee RB. Acute corneal hydrops in keratoconus. Indian J Ophthalmol. 2013;61(8):461-4
221. Malbran ES, Fernández-Meijide RE. Bilateral versus unilateral penetrating graft in keratoconus. Ophthalmology. 1982;89(1):38-40
222. Mannis MJ, Morrison TL, Zadnik K, et al. Personality trends in keratoconus. An analysis. Arch Ophthalmol. 1987;105(6):798-800
223. Martin TP, Reed JW, Legault C, et al. Cataract formation and cataract extraction after penetrating keratoplasty. Ophthalmology. 1994;101(1):113-9
224. Mashor RS, Kumar NL, Ritenour RJ, Rootman DS. Keratoconus caused by eye rubbing in patients with Tourette Syndrome. Can J Ophthalmol. 2011;46(1):83-6
225. Mashor RS, Rootman DB, Bahar I, et al. Outcomes of deep anterior lamellar keratoplasty versus intralase enabled penetrating keratoplasty in keratoconus. Can J Ophthalmol. 2011;46(5):403-7
226. Mathers WD, Gold JB, Kattan H, Lemp MA. Corneal steepening with final suture removal after penetrating keratoplasty. Cornea. 1991;10(3):221-3
227. Maurice DM, Zauberman H, Michaelson IC. The stimulus to neovascularization in the cornea. Exp Eye Res. 1966;5(3):168-84
228. Mazzotta C, Balestrazzi A, Baiocchi S, et al. Stromal haze after combined riboflavin-UVA corneal collagen cross-linking in keratoconus: in vivo confocal microscopic evaluation. Clin Experiment Ophthalmol. 2007;35(6):580-2
229. Mazzotta C, Caragiuli S. Intraoperative corneal thickness measurement by optical coherence tomography in keratoconic patients undergoing corneal collagen cross-linking. Am J Ophthalmol. 2014;157(6):1156-62
230. Mazzotta C, Traversi C, Baiocchi S, et al. Corneal healing after riboflavin ultraviolet-A collagen cross-linking determined by confocal laser scanning microscopy in vivo: early and late modifications. Am J Ophthalmol. 2008;146(4):527-33

231. McClellan K, Lai T, Grigg J, Billson F. Penetrating keratoplasty in children: visual and graft outcome. Br J Ophthalmol. 2003;87(10):1212-4
232. McElvanney AM, Adhikary HP. Penetrating keratoplasty in the mentally retarded. Eye (Lond). 1997;11(Pt 6):786-9
233. McMahon TT, Szczotka-Flynn L., Barr JT, et al. A New Method for Grading the Severity of Keratoconus The Keratoconus Severity Score (KSS). Cornea. 2006;25(7):794-800
234. McMonnies CW. Corneal endothelial assessment with special references to keratoconus. Optom Vis Sci. 2014;91(6):e124-34
235. Medical Advisory Secretariat. Intrastromal corneal ring implants for corneal thinning disorders: an evidence-based analysis. Ontario Health Technology Assessment Series 2009;9(1)
236. Melles GR, Remeijer L, Geerards AJ, Beekhuis WH. A quick surgical technique for deep, anterior lamellar keratoplasty using visco-dissection. Cornea. 2000;19(4):427-32
237. Melles GR, Rietveld FJ, Beekhuis WH, Binder PS. A technique to visualize corneal incision and lamellar dissection depth during surgery. Cornea. 1999;18(1):80-6
238. Melles GRJ, Lander F, Rietveld FJR, et al. A new surgical technique for deep, anterior lamellar keratoplasty. Br J Ophthalmol. 1999;83:327–33
239. Michieletto P, Balestrazzi A, Balestrazzi A, et al. Factors predicting unsuccessful big bubble deep lamellar anterior keratoplasty. Ophthalmologica. 2006;220(6):379-82
240. Mitchell BM, Kanellopoulos AJ, Font RL. Post intrastromal corneal ring segments insertion complicated by Candida parapsilosis keratitis. Clin Ophthalmol. 2013;7:443-8
241. Mohamed SR, Manna A, Amissah-Arthur K, McDonnell PJ. Non-resolving Descemet folds 2 years following deep anterior lamellar keratoplasty: the impact on visual outcome. Cont Lens Anterior Eye. 2009;32(6):300-2
242. Moon JW, Shin KC, Lee HJ, et al. The effect of contact lens wear on the ocular surface changes in keratoconus. Eye Contact Lens. 2006;32(2):96-101
243. Moore JE, Atkinson SD, Azar DT, et al. Protection of corneal epithelial stem cells prevents ultraviolet A damage during corneal collagen cross-linking treatment for keratoconus. Br J Ophthalmol. 2014;98(2):270-4
244. Moreira LB, Bardal RA, Crisigiovanni LR. Contact lenses fitting after intracorneal ring segments implantation in keratoconus. Arq Bras Oftalmol. 2013;76(4):215-7
245. Mulet ME, Pérez-Santonja JJ, Ferrer C, Alió JL. Microbial keratitis after intrastromal corneal ring segment implantation. J Refract Surg. 2010;26(5):364-9
246. Müller LJ, Pels E, Vrensen GF. The effects of organ-culture on the density of keratocytes and collagen fibers in human corneas. Cornea. 2001;20(1):86-95
247. Musa FU, Patil S, Rafiq O, et al. Long-term risk of intraocular pressure elevation and glaucoma escalation after deep anterior lamellar keratoplasty. Clin Experiment Ophthalmol. 2012;40(8): 780-5
248. Musch DC, Meyer RF, Sugar A. The effect of removing running sutures on astigmatism after penetrating keratoplasty Arch Ophthalmol. 1988;106(4):488-92
249. Naftali M, Jabaly-Habib H. Depth of intrastromal corneal ring segments by OCT. Eur J Ophthalmol. 2013;23(2):171-6
250. Nagra PK, Rapuano CJ, Laibson PL, et al. Cataract extraction following penetrating keratoplasty. Cornea. 2004;23(4):377-9
251. Nanavaty MA, Daya SM. Outcomes of deep anterior lamellar keratoplasty in keratoconic eyes with previous hydrops. Br J Ophthalmol. 2012;96(10):1304-9

252. Nepomuceno RL, Boxer Wachler BS, Weissman BA. Feasibility of contact lens fitting on keratoconus patients with INTACS inserts. Cont Lens Anterior Eye. 2003;26(4):175-80
253. Nirankari VS, Karesh J, Bastion F, et al. Recurrence of keratoconus in donor cornea 22 years after successful keratoplasty. Br J Ophthalmol. 1983;67(1):23-8
254. Niziol LM, Musch DC, Gillespie BW, et al. Long-term outcomes in patients who received a corneal graft for keratoconus between 1980 and 1986. Am J Ophthalmol. 2013;155(2):213-9
255. Noble BA, Ball JL. Late onset post-keratoplasty astigmatism in patients with keratoconus. Br J Ophthalmol. 2004;88(3):317
256. Olson RJ, Pingree M, Ridges R, et al. Penetrating keratoplasty for keratoconus: a long-term review of results and complications. J Cataract Refract Surg. 2000;26(7):987-91
257. Oral D, Kaya V. Topography-guided conductive keratoplasty for keratoconus. Am J Ophthalmol. 2011;151(6):1102-3;author reply 1103
258. Ortenberg I, Behrman S, Geraisy W, Barequet IS. Wearing time as a measure of success of scleral lenses for patients with irregular astigmatism. Eye Contact Lens. 2013;39(6):381-4
259. Ozertürk Y, Sari ES, Kubaloglu A, et al. Comparison of deep anterior lamellar keratoplasty and intrastromal corneal ring segment implantation in advanced keratoconus. J Cataract Refract Surg. 2012;38(2):324-32
260. Panahi-Bazaz MR, Sharifipour F, Moghaddasi A. Bilateral keratoconus and corneal hydrops associated with eye rubbing in a 7-year-old girl. J Ophthalmic Vis Res. 2014;9(1):101-5
261. Park S, Ramamurthi S, Ramaesh K. Late dislocation of intrastromal corneal ring segment into the anterior chamber. J Cataract Refract Surg. 2010;36(11):2003-5
262. Parthasarathy A, Por YM, Tan DT. Use of a "small-bubble technique" to increase the success of Anwar's "big-bubble technique" for deep lamellar keratoplasty with complete baring of Descemet's membrane. Br J Ophthalmol. 2007;91(10):1369-73
263. Patel N, Mearza A, Rostron CK, Chow J. Corneal ectasia following deep lamellar keratoplasty. Br J Ophthalmol. 2003;87(6):799-800
264. Patel SV, Malta JB, Banitt MR, et al. Recurrent ectasia in corneal grafts and outcomes of repeat keratoplasty for keratoconus. Br J Ophthalmol. 2009;93(2):191-7
265. Pérez-Santonja JJ, Artola A, Javaloy J, et al. Microbial keratitis after corneal collagen crosslinking. J Cataract Refract Surg. 2009;35(6):1138-40
266. Piñero DP, Alio JL, El Kady B, et al. Refractive and aberrometric outcomes of intracorneal ring segments for keratoconus: mechanical versus femtosecond-assisted procedures. Ophthalmology. 2009;116(9):1675-87
267. Piñero DP, Alio JL, Klonowski P, Toffaha B. Vectorial astigmatic changes after corneal collagen crosslinking in keratoconic corneas previously treated with intracorneal ring segments: a preliminary study. Eur J Ophthalmol. 2012;22(Suppl 7):S69-80
268. Piñero DP, Alio JL. Intracorneal ring segments in ectatic corneal disease - a review. Clin Experiment Ophthalmol. 2010;38(2):154-67
269. Pinsard L, Touboul D, Vu Y, et al. Keratoconus associated with Williams-Beuren syndrome: first case reports. Ophthalmic Genet. 2010;31(4):252-6
270. Pollhammer M, Cursiefen C. Bacterial keratitis early after corneal crosslinking with riboflavin and ultraviolet-A. J Cataract Refract Surg. 2009;35(3):588-9
271. Pramanik S, Musch DC, Sutphin JE, Farjo AA. Extended long-term outcomes of penetrating keratoplasty for keratoconus. Ophthalmology. 2006;113(9):1633-8
272. Price FW Jr, Whitson WE, Marks RG. Progression of visual acuity after penetrating keratoplasty. Ophthalmology. 1991;98(8):1177-85

273. Pron G, Ieraci I, Kaulback K, Medical Advisory Secretariat (Health Quality Ontario). Collagen crosslinking using riboflavin and ultraviolet-A for corneal thinning disorders: an evidence-based analysis. Ont Health Technol Assess Ser. 2011;11(5):1-89
274. Rabinowitz YS. Intacs for keratoconus. Curr Opin Ophthalmol. 2007;18(4):279-83
275. Rabinowitz YS. Keratoconus. Surv Ophthalmol. 1998 42(4):23
276. Raecker ME, Erie JC, Patel SV, et al. Long-term keratometric changes after penetrating keratoplasty for keratoconus and Fuchs endothelial dystrophy. Am J Ophthalmol. 2009;147(2):227-33
277. Rahi A, Davies P, Ruben M, et al. Keratoconus and coexisting atopic disease. Br J Ophthalmol. 1977;61(12):761-4
278. Raiskup F, Spoerl E. Corneal cross-linking with hypo-osmolar riboflavin solution in thin keratoconic corneas. Am J Ophthalmol. 2011;152(1):28-32
279. Ramamurthi S, Ramaesh K. Surgical management of healed hydrops: a novel modification of deep anterior lamellar keratoplasty. Cornea. 2011;30(2):180-3
280. Reddy JC, Hammersmith. K., Nagra PK, Rapuano CJ. The role of penetrating keratoplasty in the era of selective lamellar keratoplasty. Int Ophthalmol Clin. 2013;53(2):12
281. Regis-Pacheco LF, Binder PS. What happens to the corneal transplant endothelium after penetrating keratoplasty? Cornea. 2014;33(6):587-96
282. Richoz O, Schutz JS, Pajic B, et al. Crosslinking for recurrent keratoconus. Ophthalmology. 2012; 119(4):878
283. Rodríguez LA, Guillén PB, Benavides MA, et al. Penetrating keratoplasty versus intrastromal corneal ring segments to correct bilateral corneal ectasia: preliminary study. J Cataract Refract Surg. 2007;33(3):488-96
284. Rowson NJ, Dart JK, Buckley RJ. Corneal neovascularisation in acute hydrops. Eye (Lond). 1992;6 (Pt 4):404-6
285. Ruckhofer J, Böhnke M, Alzner E, Grabner G. Confocal microscopy after implantation of intrastromal corneal ring segments. Ophthalmology. 2000;107(12):2144-51
286. Sahebjada S, Fenwick EK, Xie J, et al. Impact of keratoconus in the better eye and the worse eye on vision-related quality of life. Invest Ophthalmol Vis Sci. 2014;21;55(1):412-6
287. Salman, AG. Transepithelial corneal collagen crosslinking for progressive keratoconus in a pediatric age group. J Cataract Refract Surg. 2013;39(8):1164-70
288. Salouti R, Masoumpour M, Nowroozzadeh MH, et al. Changes in corneal endothelial cell profile measurements after deep anterior lamellar keratoplasty for keratoconus. Cornea. 2013;32(6): 751-6
289. Salvetat ML, Brusini P, Pedrotti E, et al. Higher order aberrations after keratoplasty for keratoconus. Optom Vis Sci. 2013;90(3):293-301
290. Sansanayudh W, Bahar I, Kumar NL, et al. Intrastromal corneal ring segment SK implantation for moderate to severe keratoconus. J Cataract Refract Surg. 2010;36(1):110-3
291. Schmidinger G, Pachala M, Prager F. Pachymetry changes during corneal crosslinking: effect of closed eyelids and hypotonic riboflavin solution. J Cataract Refract Surg. 2013;39(8):1179-83
292. Sehra SV, Titiyal JS, Sharma N, et al. Change in corneal microstructure with rigid gas permeable contact lens use following collagen cross-linking: an in vivo confocal microscopy study. Br J Ophthalmol. 2014;98(4):442-7
293. Seitz B, Langenbucher A, Szentmary N, Naumann GO. Corneal curvature after penetrating keratoplasty before and after suture removal: a comparison between keratoconus and Fuchs' dystrophy. Ophthalmologica. 2006;220(5):302-6

294. Severinsky B, Behrman S, Frucht-Pery J, Solomon A. Scleral contact lenses for visual rehabilitation after penetrating keratoplasty: long term outcomes. Cont Lens Anterior Eye. 2014;37(3):196-202
295. Severinsky B, Wajnsztajn D, Frucht-Pery J. Silicone hydrogel mini-scleral contact lenses in early stage after corneal collagen cross-linking for keratoconus: a retrospective case series. Clin Exp Optom. 2013;96(6):542-6
296. Shabayek MH, Alió JL. Intrastromal corneal ring segment implantation by femtosecond laser for keratoconus correction. Ophthalmology. 2007;114(9):1643-52
297. Sharif KW, Casey TA. Penetrating keratoplasty for keratoconus: complications and long-term success. Br J Ophthalmol. 1991;75(3):142-6
298. Sharma A, Mirchia K, Mohan K, et al. Persistent corneal edema after collagen cross-linking for keratoconus. Am J Ophthalmol. 2012;154(6):922-6
299. Sharma N, Kandar AK, Singh Titiyal J. Stromal rejection after big bubble deep anterior lamellar keratoplasty: case series and review of literature. Eye Contact Lens. 2013;39(2):194-8
300. Shetty R, Kurian M, Anand D, et al. Intacs in advanced keratoconus. Cornea. 2008;27(9):1022-9
301. Shi W, Li S, Gao H, et al. Modified deep lamellar keratoplasty for the treatment of advanced-stage keratoconus with steep curvature. Ophthalmology. 2010; 117(2):226-31
302. Shimazaki J1, Shimmura S, Ishioka M, Tsubota K. Randomized clinical trial of deep lamellar keratoplasty vs penetrating keratoplasty. Am J Ophthalmol. 2002;134(2):159-65
303. Siganos D, Ferrara P, Chatzinikolas K, et al. Ferrara intrastromal corneal rings for the correction of keratoconus. J Cataract Refract Surg. 2002;28(11):1947-51
304. Silbiger JS, Cohen EJ, Laibson PR. The rate of visual recovery after penetrating keratoplasty for keratoconus. CLAO J. 1996;22(4):266-9
305. Sloot F, Soeters N, van der Valk R, Tahzib NG. Effective corneal collagen crosslinking in advanced cases of progressive keratoconus. J Cataract Refract Surg. 2013;39(8):1141-5
306. Smadja D, Colin J, Krueger RR, et al. Outcomes of deep anterior lamellar keratoplasty for keratoconus: learning curve and advantages of the big bubble technique. Cornea. 2012;31(8):859-63
307. Smiddy WE, Hamburg TR, Kracher GP, Stark WJ. Keratoconus. Contact lens or keratoplasty? Ophthalmology. 1988;95(4):487-92
308. Soeters N, van Bussel E, van der Valk R, et al. Effect of the eyelid speculum on pachymetry during corneal collagen crosslinking in keratoconus patients. J Cataract Refract Surg. 2014;40(4):575-81
309. Soeters N, van der Valk R, Tahzib NG. Corneal cross-linking for treatment of progressive keratoconus in various age groups. J Refract Surg. 2014;30(7):454-60
310. Sorkin N, Varssano D. Corneal collagen crosslinking: a systematic review. Ophthalmologica. 2014; 232(1):10-27
311. Spadea L, Giammaria D, Fiasca A, Verrecchia V. Excimer laser-assisted lamellar keratoplasty for the surgical treatment of keratoconus. J Cataract Refract Surg. 2009;35(1):105-12
312. Spadea L, Gizzi R, Evangelista Conocchia N, Urbano S. Optical pachymetry-guided custom excimer laser-assisted lamellar keratoplasty for the surgical treatment of keratoconus. J Cataract Refract Surg. 2012;38(9):1559-67
313. Spadea L, Salvatore S, Vingolo EM. Corneal sensitivity in keratoconus: a review of the literature. ScientificWorldJournal. 2013:683090
314. Spadea L,Mencucci R. Transepithelial corneal collagen cross-linking in ultrathin keratoconic corneas. Clin Ophthalmol. 2012;6:1785-92
315. Speaker MG, Arentsen JJ, Laibson PR. Long-term survival of large diameter penetrating keratoplasties for keratoconus and pellucid marginal degeneration. Acta Ophthalmol Suppl. 1989;192: 17–9

316. Spitznas M, Eckert J, Frising M, Eter N. Long-term functional and topographic results seven years after epikeratophakia for keratoconus. Graefes Arch Clin Exp Ophthalmol. 2002;240(8):639-43
317. Sturbaum CW, Peiffer RL Jr. Pathology of corneal endothelium in keratoconus. Ophthalmologica. 1993;206:192–208
318. Sugita J, Kondo J. Deep lamellar keratoplasty with complete removal of pathological stroma for vision improvement. Br J Ophthalmol. 1997;81:184-8
319. Sutton G, Hodge C, McGhee CN. Rapid visual recovery after penetrating keratoplasty for keratoconus. Clin Experiment Ophthalmol. 2008;36(8):725-30
320. Tan DT, Anshu A, Parthasarathy A, Htoon HM. Visual acuity outcomes after deep anterior lamellar keratoplasty: a case-control study. Br J Ophthalmol. 2010;94(10):1295-9
321. Thomas JK, Guel DA, Thomas TS, Cavanagh HD. The role of atopy in corneal graft survival in keratoconus. Cornea. 2011;30(10):1088-97
322. Thompson RW Jr, Price MO, Bowers PJ, Price FW Jr. Long-term graft survival after penetrating keratoplasty. Ophthalmology. 2003;110(7):1396-402
323. Thorsrud A, Nicolaissen B, Drolsum L. Corneal collagen crosslinking in vitro: inhibited regeneration of human limbal epithelial cells after riboflavin-ultraviolet-A exposure. J Cataract Refract Surg. 2012;38(6):1072-6
324. Titiyal JS, Chawla B, Sharma N. Deep anterior lamellar keratoplasty with Intacs explantation in keratoconus. Eur J Ophthalmol. 2010;20(5):874-8
325. Tomita M, Mita M, Huseynova T. Accelerated versus conventional corneal collagen crosslinking. J Cataract Refract Surg. 2014;40(6):1013-20
326. Toprak I, Yaylalı V, Yildirim C. Factors affecting outcomes of corneal collagen crosslinking treatment. Eye (Lond).2014;28(1):41-6
327. Toprak I, Yildirim C. Effects of corneal collagen crosslinking on corneal topographic indices in patients with keratoconus. Eye Contact Lens. 2013;39(6):385-7
328. Torquetti L, Ferrara G, Almeida F, et al. Clinical outcomes after intrastromal corneal ring segments reoperation in keratoconus patients. Int J Ophthalmol. 2013;6(6):796-800
329. Torquetti L, Ferrara G, Almeida F, et al. Intrastromal corneal ring segments implantation in patients with keratoconus: 10-year follow-up. J Refract Surg. 2014;30(1):22-6
330. Tu KL, Sebastian RT, Owen M, et al. Quantification of the surgically induced refractive effect of intrastromal corneal ring segments in keratoconus with standardized incision site and segment size. J Cataract Refract Surg. 2011;37(10):1865-70
331. Tuft SJ, Fitzke FW, an S, Frucht-Pery J, Solomon A. Scleral contact lenses for visual rehabilitation after penetrating 1992;76(11):642-5
332. Tuft SJ, Gregory W. Long-term refraction and keratometry after penetrating keratoplasty for keratoconus. Cornea. 1995;14(6):614-7
333. Tuft SJ, Moodaley LC, Gregory WM, et al. Prognostic factors for the progression of keratoconus. Ophthalmology. 1994;101(3):439-47
334. Uiters E, van den Borne B, van der Horst FG, Völker-Dieben HJ. Patient satisfaction after corneal transplantation. Cornea. 2001;20(7):687-94
335. Vabres B, Bosnjakowski M, Bekri L, et al. Deep lamellar keratoplasty versus penetrating keratoplasty for keratoconus. J Fr Ophtalmol. 2006;29(4):361-71
336. Vajpayee RB, Jhanji V, Beltz J, Moorthy S. "Tuck in" lamellar keratoplasty for tectonic management of postkeratoplasty corneal ectasia with peripheral corneal involvement. Cornea. 2011;30(2): 171-4

337. Vajpayee RB, Maharana PK, Sharma N, et al. Diamond knife-assisted deep anterior lamellar keratoplasty to manage keratoconus. J Cataract Refract Surg. 2014;40(2):276-82
338. van Dijk K, Liarakos V, Parker J, et al. Bowman layer transplantationto reduce and stabilize progressive, end stage, keratoconus. Ophthalmology. 2015:Epub ahead of print
339. van Dijk K, Parker J, Tong CM, et al. Midstromal isolated Bowman layer graft for reduction of advanced keratoconus: a technique to postpone penetrating or deep anterior lamellar keratoplasty. JAMA Ophthalmol. 2014;132(4):495-501
340. van Dooren BT, Mulder PG, Nieuwendaal CP, et al. Endothelial cell density after deep anterior lamellar keratoplasty (Melles technique). Am J Ophthalmol. 2004;137(3):397-400
341. Vazirani J, Bagga B, Taneja M. Persistent corneal edema after collagen cross-linking for keratoconus. Am J Ophthalmol. 2013;155(4):775
342. Vazirani J, Basu S. Keratoconus: current perspectives. Clin Ophthalmol. 2013;7:2019-30
343. Vicente LL, Boxer Wachler BS. Factors that correlate with improvement in vision after combined Intacs and trans-epithelial corneal crosslinking. Br J Ophthalmol. 2010;94(12):1597-601
344. Vinciguerra P, Camesasca FI, Romano MR. Corneal crosslinking and lens opacity. Ophthalmology. 2011;118(12):2519
345. Viswanathan D, Kumar NL, Males JJ. Outcome of corneal collagen crosslinking for progressive keratoconus in paediatric patients. Biomed Res Int. 2014:140461
346. Völker-Dieben HJ, Odenthal MT, D'Amaro J, Kruit PJ. Surgical treatment of corneal pathology in patients with Down's syndrome. J Intellect Disabil Res. 1993;37(Pt 2):169-75
347. Wagoner MD, Ba-Abbad R; King Khaled Eye Specialist Hospital Cornea Transplant Study Group. Penetrating keratoplasty for keratoconus with or without vernal keratoconjunctivitis. Cornea. 2009;28(1):14-8
348. Wicker D, Sanislo S, Green DG. Effect of contact lens correction of sine wave contrast sensitivity in keratoconus patients after penetrating keratoplasty. Optom Vis Sci. 1992;69(5):342-6
349. Williams KA, Ash JK, Pararajasegaram P, et al. Long-term outcome after corneal transplantation. Visual result and patient perception of success. Ophthalmology. 1991;98(5):651-7
350. Wisse, RP., van den Hoven CM, Van der Lelij A. Does lamellar surgery for keratoconus experience the popularity it deserves? Acta Ophthalmol. 2014;92(5):473-7
351. Wittig-Silva C, Chan E, Islam FM, et al. A randomized, controlled trial of corneal collagen cross-linking in progressive keratoconus: three-year results. Ophthalmology. 2014;121(4):812-21
352. Wollensak G, Spoerl E, Seiler T. Riboflavin/ultraviolet-ainduced collagen crosslinking for the treatment of keratoconus. Am J Ophthalmol. 2003;135(5):620–7
353. Wollensak G, Spoerl E, Wilsch M, Seiler T. Endothelial cell damage after riboflavin-ultraviolet-A treatment in the rabbit. J Cataract Refract Surg. 2003;29(9):1786-90
354. Wroblewski KJ, Mader TH, Torres MF, et al. Long-term graft survival in patients with Down syndrome after penetrating keratoplasty. Cornea. 2006;25(9):1026-8
355. Yam JC, Cheng AC. Prognostic factors for visual outcomes after crosslinking for keratoconus and post-LASIK ectasia. Eur J Ophthalmol. 2013;23(6):799-806
356. Yeniad B, Alparslan N, Akarcay K. Eye rubbing as an apparent cause of recurrent keratoconus. Cornea. 2009;28(4):477-9
357. Yeung SN, Lichtinger A, Kim P, et al. Retrospective contralateral study comparing deep anterior lamellar keratoplasty with penetrating keratoplasty: a patient's perspective. Can J Ophthalmol. 2012;47(4):360-4

358. Yeung SN, Lichtinger A, Ku JY, et al. Intracorneal ring segment explantation after intracorneal ring segment implantation combined with same-day corneal collagen crosslinking in keratoconus. Cornea. 2013;32(12):1617-20
359. Yildiz EH, Erdurmus M, Hammersmith KM, et al. Comparative study of graft rejection in keratoconus patients with and without self-reported atopy. Cornea. 2009;28(8):846-50
360. Yildiz EH, Hoskins E, Fram N, et al. Third or greater penetrating keratoplasties: indications, survival, and visual outcomes. Cornea. 2010;29(3):254-9
361. Yilmaz S, Ali Ozdil M, Maden A. Factors affecting changes in astigmatism before and after suture removal following penetrating keratoplasty. Eur J Ophthalmol. 2007;17(3):301-6
362. Yoo SH, Kymionis GD, Koreishi A, et al. Femtosecond laser-assisted sutureless anterior lamellar keratoplasty. Ophthalmology. 2008;115(8):1303-7
363. Zare MA, Hashemi H, Salari MR.Intracorneal ring segment implantation for the management of keratoconus: safety and efficacy. J Cataract Refract Surg. 2007;33(11):1886-91
364. Zhang YM, Wu SQ, Yao YF. Long-term comparison of full-bed deep anterior lamellar keratoplasty and penetrating keratoplasty in treating keratoconus. J Zhejiang Univ Sci B. 2013;14(5):438-50
365. Zimmerman T, Olson R, Waltman S, Kaufman H. Transplant size and elevated intraocular pressure. Postkeratoplasty. Arch Ophthalmol. 1978;96(12):2231-3

Chapter 3

Mid-stromal isolated Bowman layer graft to reduce advanced keratoconus to postpone penetrating or deep anterior lamellar keratoplasty

Korine van Dijk, BSc;[1,2] Jack Parker, MD;[1-3] C. Maya Tong, BSc;[1,4] Lisanne Ham, PhD;[1,2,4] Jessica T. Lie, PhD;[1,4] Esther A. Groeneveld-van Beek, MSc;[1,4] and Gerrit R.J. Melles, MD, PhD[1,2,4]

[1]Netherlands Institute for Innovative Ocular Surgery, Rotterdam, The Netherlands; [2]Melles Cornea Clinic Rotterdam, The Netherlands; [3]UAB Callahan Eye Hospital, Birmingham, Alabama; [4]Amnitrans EyeBank Rotterdam, The Netherlands.

ABSTRACT

We describe a new approach to reduce ectasia in eyes with advanced keratoconus in order to postpone penetrating keratoplasty or deep anterior lamellar keratoplasty, by mid-stromal implantation of an isolated Bowman layer graft.

The surgery was performed in 10 eyes of nine patients with progressive, advanced keratoconus and contact lens intolerance. All surgeries were uneventful. Throughout the study period, no complications related to stromal dissection and/or Bowman layer implantation were observed. Maximum corneal power decreased on average from 74.5D (±7.1D) before to 68.3D (±5.6D) after surgery (P=0.00). Hence, isolated Bowman layer implantation may be a safe and effective new technique to reduce ectasia in eyes with advanced KC, potentially allowing continued long term contact lens wear. The low risk of complications may render the procedure suitable as a treatment to postpone penetrating or deep anterior lamellar keratoplasty in cases with impending contact intolerance and/or corneal scarring.

Keratoconus (KC) is regarded as a non-inflammatory disorder characterized by progressive ectasia, associated with a compromised optical performance of the cornea.[1,2] Until recently, early KC stages were managed by hard contact lens fitting to obtain a regular anterior 'optical' surface, until contact lens intolerance in advanced stages required penetrating keratoplasty (PK) or deep anterior lamellar keratoplasty (DALK). Since 2003, UV-crosslinking became an alternative treatment option for keratoconic corneas of at least 400 microns in thickness and preoperative maximum keratometry of ≤58D,[3] with further developments on the way for thinner and steeper corneas.[4] Nevertheless, in more advanced KC cases, treatment options may eventually be limited to PK or DALK, the results of which may frequently be complicated in this patient group, by suture-related problems, epithelial wound healing abnormalities, and/or corneal curvature changes due to progression of KC in the peripheral host cornea, resulting in a cascade of secondary complications, and disappointing visual outcomes.[5-8]

Since fragmentation of Bowman layer is a pathognomic feature in advanced KC,[2,9] we hypothesized that a partial restoration of the corneal anatomy might be obtained through a mid-stromal implantation of an isolated Bowman layer graft, to re-model, ie flatten the corneal curvature. At the same time, stabilization of the ectasia may be obtained by the Bowman layer 'splint', as well as through the wound healing reaction between the host stroma and the Bowman layer graft.[10,11]

In this article, we describe a new surgical approach using mid-stromal implantation of a donor isolated Bowman layer, to reduce ectasia (K ≥70D) in eyes with advanced KC, to enable continued contact lens wear, while avoiding most short and long term complications.

KEYWORDS: Keratoconus, corneal crosslinking, deep anterior lamellar keratoplasty, progressive ectasia, Bowman layer, pachymetry, corneal transplantation, surgical technique

METHODS

Mid-stromal dissection with implantation of an isolated donor Bowman layer in the stromal pocket, was performed in ten eyes of nine patients (3 male and 6 female; 17 to 71 years of age) with (relative) contact lens intolerance due to progressive, end-stage KC, defined as mean K ≥58D and steepest K ≥70D (**Table 1**). In all eyes, an unsuccessful attempt was made to fit a scleral supported rigid contact lens. All patients signed an IRB approved informed consent; the study was conducted according to the Declaration of Helsinki and was registered at www.clinicaltrials.gov (study identifier NCT01686906).

Donor tissue

Donor corneas released for transplantation were mounted on an artificial anterior chamber (Katena, Rockmed, Oirschot, The Netherlands). Subsequently, the epithelial layer was carefully removed using surgical spears. Over 360 degrees a superficial incision was made using a 30-gauge needle in the clear part of the corneal periphery. With a custom-made stripper (DORC International, Zuidland, The Netherlands), the Bowman layer was carefully isolated from the anterior stroma, over the full 360 degrees towards the central part of the cornea. After complete detachment, subsequent trephination resulted in a 9.0 to 11.0 mm diameter Bowman-flap. Due to the elastic properties of the Bowman membrane, a 'Bowman-roll' formed spontaneously, which was submerged in ethanol 70% to remove all epithelial cells. After rinsing the roll with BSS, it was stored in modified minimum essential medium (CorneaMax, Eurobio, Cedex, France) at 31° C, until the time of transplantation (**Figure 1**).

Figure 1. Isolated Bowman layer graft (arrows) in organ culture medium. Note that the thin tissue layer has curled up into a 'Bowman-roll'.

Surgical technique

Manual dissection of a stromal pocket was performed using a technique previously described to create a lamellar dissection plane in deep anterior lamellar keratoplasty.[13,14] Under local anesthesia, a side port was made at the 3 or 9 o'clock limbus, to aspirate the aqueous using a blunt cannula, and to completely fill the anterior chamber with air. At the 12 o'clock limbus, the conjunctiva was opened and a superficial scleral frown incision was made, 5.0 mm in length, 1-2 mm outside the limbus. With a dissection spatula (Melles spatula set, DORC International), a lamellar dissection was made to just within the superior cornea. At this point, the tip of the blade was slightly tilted downward to visualize the interface between the air bubble in the anterior chamber and the corneal endothelium; underneath the corneal `dimple', the air-to-endothelium interface was seen as a specular light-reflex localized at the tip of the blade (**Figure 2**).[14] Between the blade tip and the light-reflex, a non-reflective, dark band was seen, representing the non-incised corneal tissue between the blade and the air-to-endothelium interface. Because the dark band became thinner with advancement of the blade into the deeper stromal layers, the corneal depth of the blade could be judged from the thickness of the dark band, to avoid perforation (**Figure 2**).[13,14]

After a stromal pocket was created up to the limbus over 360°, a glide (BD Visitec™ Surgical Glide (Fichman), Beaver-Visitec International, Waltham, USA) was inserted into the pocket, and the air was removed from the anterior chamber. The Bowman-roll was again immersed in 70% ethanol for 30 seconds to remove remnant cellular material, thoroughly rinsed with balanced salt solution (BSS; B&L, Rochester, USA), and stained with trypan blue (VisionBlue™, DORC International). Then, the Bowman-roll was carefully inserted into the stromal pocket, unfolded and centered, using BSS to manipulate the tissue (**Figure 2**). The eye was then pressurized by filling the anterior chamber with balanced salt solution. Postoperative medication included chloramphenicol 0.5% six times daily and dexamethason 0.1% four times daily.

All surgical procedures were recorded on DVD (Pioneer DVR-RT601H-S, Tokyo, Japan). At standardized time intervals, before surgery, and at 1 day, 1 week, and at 1, 3, 6, 12, 18 and 24 months after surgery, best spectacle corrected visual acuity (BSCVA) and best contact lens visual acuity (BCLVA) were measured, and slit-lamp biomicroscopy, Pentacam (Pentacam HR, Oculus, Wetzlar, Germany) and optical coherence tomography (OCT; Slit-lamp OCT, Heidelberg Engineering GmbH, Heidelberg, Germany) images were made. The endothelium was photographed and evaluated *in vivo* using a Topcon SP3000p non-contact autofocus specular microscope (Topcon Medical Europe, Capelle a/d IJssel, The Netherlands). Images were analyzed and manually corrected and multiple measurements of endothelial cell density were averaged.

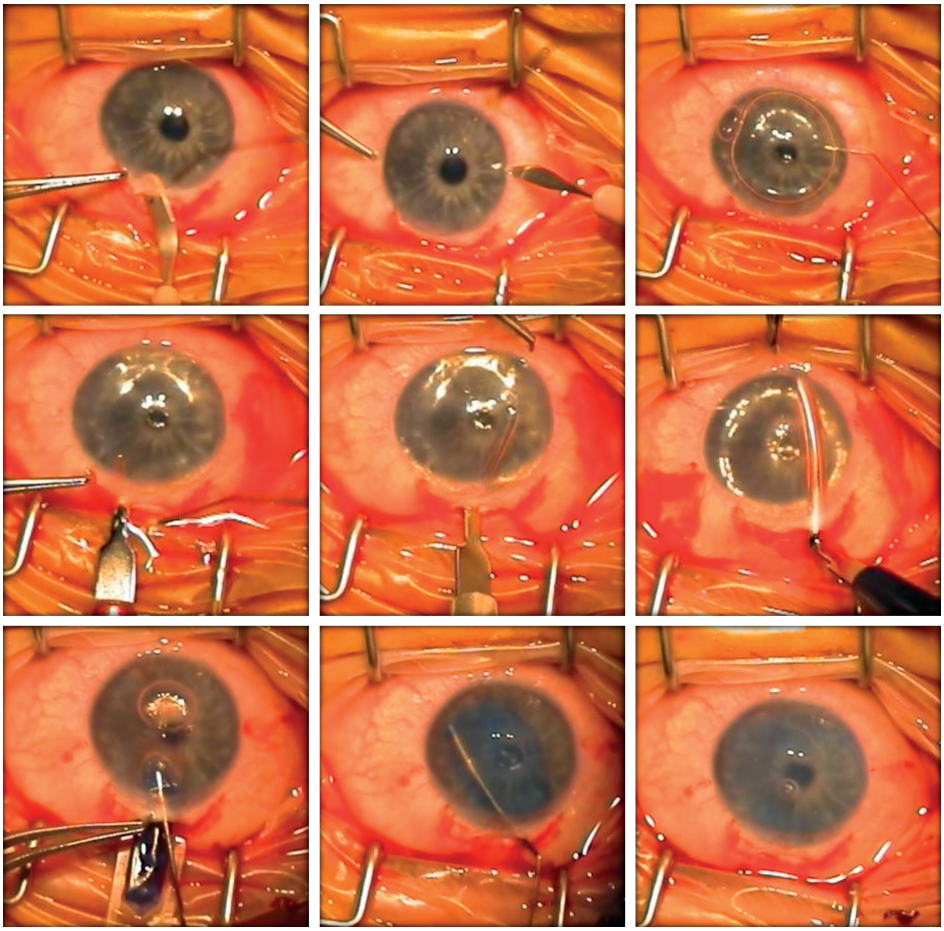

Figure 2. Intraoperative video-stills of an isolated Bowman layer implantation (Case 10). (A) After making a scleral tunnel incision, and (B) a side port, (C) the anterior chamber is filled with air, and (D-F) a mid-stromal dissection is made with spatulas. (F) Note the 'thin black line' alongside the spatula, as an indication for dissection depth. (G) After removal of the larger part of the air-bubble and the insertion a glide into the stromal pocket, a 'burrito-folded' Bowman layer graft is inserted into the pocket and (H) carefully unfolded and centered with an 30G air-cannula. (I) At the end of the surgery, the Bowman layer graft is sandwiched between the anterior and posterior stromal layers, and no sutures are required to fixate the graft of to close the tunnel incision.

RESULTS

All surgeries were uneventful, and throughout the study period no complications related to stromal dissection and/or Bowman layer implantation were observed. Because the donor Bowman layer was intentionally stretched toward the corneal limbus, an intrastromal cavity was seen in some eyes within the first days after surgery (**Figure 3**).

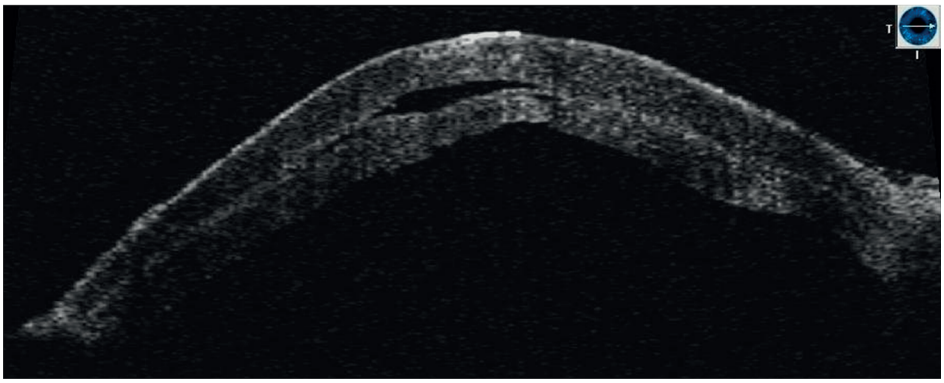

Figure 3. OCT image of a cornea immediately after isolated Bowman layer (arrows) implantation into the recipient corneal stroma. Note the intrastromal cavity directly above the implanted Bowman layer, owing to intraoperative stretching of the donor tissue towards the recipient corneal limbus, to obtain a maximum in flattening effect.

At longer time intervals, the implant could be visualized within the recipient corneal stroma, with biomicroscopy in all transplanted corneas (**Figure 4**).

Compared to preoperative measurements, all keratometry values decreased after surgery in all eyes: mean anterior sim K-values decreased from 65.9D (±5.4D) before surgery, to 59.5D (±4.6D) at 1 month (P=0.00); mean K-max values from 78.5D (±6.3D) to 69.9D (±3.8D) (P=0.00); mean posterior K-values from -10.2D (±0.8D) to -9.0D (±0.5D) (P=0.01); and mean maximum corneal power from 74.5D (±7.1D) to 67.2D (±3.0D) (P=0.00) (**Figure 5**; **Table 1**). From 1 to 12 months, the flattened curvature values remained stable (P>0.1) (**Table 1**).

Compared to preoperative measurements, central corneal thickness (CCT) increased from 396 (±42) mm to 417 (±37) µm and 423 (±38) µm at 6 months and at the most recent follow-up, respectively, and thinnest point thickness (TPT) changed from 334 (±61) µm to 360 (±31) µm and 363 (±49) µm at the six months and the most recent follow-up, respectively. None of the changes reached statistical significance (P>0.05).

Mean LogMar BSCVA and BCLVA showed no significant change from preoperative to six months postoperative (P=0.07 and P=0.77, respectively).

Before surgery, most of the eyes (Cases 1, 2, 3, 4, 6, 8 and 9) could only tolerate very limited contact lens wear for a few hours during the day (due to excessive corneal steepness with an impending "touch" between the cone and the contact lens). After surgery, however, all eyes could be fitted with a sclera-supported rigid contact lens ((R.Visser and Procornea rigid lens laboratory, Nijmegen, The Netherlands);[15] manufactured from Boston Equa 2 material with an oxygen permeability of 85×10^{-11} (cm^3O_2 cm)/(s·cm^2 mm Hg) at 35° C, ISO/Fatt method (Cases 1 and 6) or Boston XO with an oxygen permeability of 100×10^{-11} (cm^3O_2 cm)/(s·cm^2 mm Hg) at 35° C, ISO/Fatt method (Cases 2-5, and 7-10)

Table 1. Pre- and postoperative corneal curvature data

				Anterior K-values (D)					K max (D)					Posterior K-values (D)					Power Max (D)				
Case #	Age/ Gender	OD/OS	FU time (months)	Pre-op	1m	6m	Latest FU	Δ Pre-op to latest FU	Pre-op	1m	6m	Latest FU	Δ Pre-op to latest FU	Pre-op	1m	6m	Latest FU	Δ Pre-op to latest FU	Pre-op	1m	6m	Latest FU	Δ Pre-op to latest FU
1	37F	OS	24	62.8	59.4	59.4	58.4	-4.4	73.2	66.2	67.5	69.8	-3.4	-11.2	-8.3	-8.6	-9.8	1.4	65.9	64.7	65.8	62.7	-3.2
2	22F	OS	24	64.0	61.5	56.9	57.0	-7.0	72.7	67.9	67.9	69.8	-2.9	-9.5	-9.1	-8.1	-8.3	1.2	71.2	65.9	69.5	69.7	-1.5
3	71F	OS	18	61.7	n.a.	60.2	60.5	-1.2	70.3	n.a.	70.2	71.0	0.7	-9.9	n.a.	-9.9	-10.1	-0.2	64.7	n.a.	64.8	65.4	0.7
4	17F	OD	18	62.8	60.4	60.1	59.6	-3.2	77.8	77.9	73.8	69.4	-8.4	-9.6	-9.5	-9.7	-9.3	0.3	72.5	72.9	69.3	64.6	-7.9
5	25M	OD	18	75.4	66.0	69.1	69.4	-6.0	84.7	71.2	73.7	73.8	-10.9	-11.4	-9.6	-10.2	-10.1	1.3	81	68.8	72.5	72.8	-8.2
6	27M	OD	12	67.0	60.5	60.8	62.4	-4.6	76.2	65.3	66.9	68.6	-7.6	-11.1	-9	-9.8	-9.7	1.4	71.3	63.4	63.6	65.5	-5.8
7	29F	OD	12	61.9	57.1	56.6	55.3	-6.6	80.1	68.3	68.3	68.6	-11.5	-9.2	-8.8	-8.9	-9.3	-0.1	75.1	64.8	64.1	64.4	-10.7
8	20F	OS	12	74.1	61.1	64.6	69.0	-5.1	92	72.3	78.3	83.7	-8.3	-10.9	-8.9	-9.7	-9.9	1.0	86.9	70	75.1	81.0	-5.9
9	30M	OD	12	69.3	60.1	64.2	65.0	-4.3	77.8	68.6	73.1	73.7	-4.1	-10.3	-9.6	-9.9	-9.7	0.6	82.6	65.9	70.1	71.8	-10.8
10	29F	OS	12	59.6	49.0	55.8	53.6	-6.0	79.8	71.4	67.6	67.5	-12.3	-9.3	-8.4	-8.5	-8.4	0.9	73.7	68.3	63.5	65.0	-8.7
Average			16	65.9	59.5	60.8	61.0	-4.8	78.5	69.9	70.7	71.6	-6.9	-10.2	-9	-9.3	-9.5	0.8	74.5	67.2	67.8	68.3	-6.2
SD			(±5)	(±5.4)	(±4.6)	(±4.2)	(±5.4)	(±1.7)	(±6.3)	(±3.8)	(±3.8)	(±4.7)	(±4.3)	(±0.8)	(±0.5)	(±0.7)	(±0.7)	(±0.6)	(±7.1)	(±3.0)	(±4.1)	(±5.6)	(±3.9)
P-value (pre-op to FU)					**0.00**	**0.00**	**0.00**			**0.00**	**0.00**	**0.00**			**0.00**	**0.00**	**0.00**			**0.00**	**0.00**	**0.00**	
P-value (1m to latest FU)							0.25					0.37					0.15					0.47	

Yellow = Post-operative values changed <5% from pre-operative values
Green = Post-operative values improved (≥5% decrease from pre-operative values)
SD = Standard deviation
FU = Follow-up
'Bold' = Significant change

from the Polymer Technology Corporation, Bausch & Lomb), which was tolerated well during full daily wear.

Mean endothelial cell density showed no significant change from preoperative (2571 (±497) cells/mm^2) to 12 months postoperative (2552 (±263) cells/mm^2) (P= 0.31).

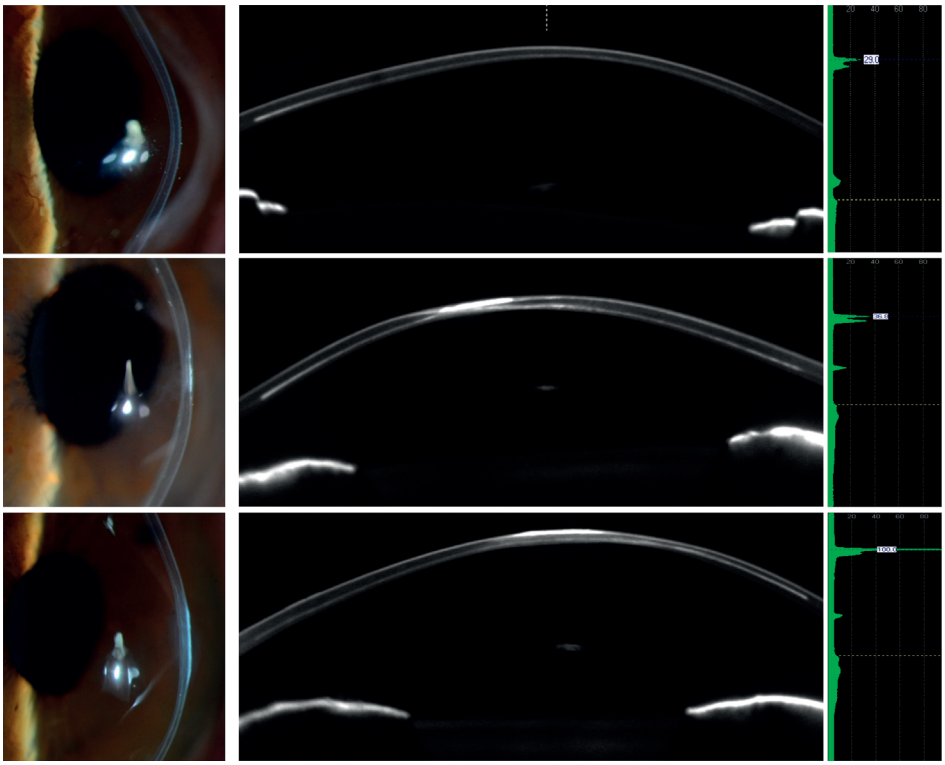

Figure 4. Slit-lamp and Scheimpflug images of three eyes (Cases 4, 6, and 9) at 9-12 months after isolated Bowman layer implantation. (A-F) The Bowman layer transplant (white arrows) is visible within the recipient stroma, without any interface haze or stromal reaction. Note the different types of pre-existing superficial scarring and surface irregularity (yellow arrow).

DISCUSSION

In the past years, the preferred treatment method for progressive KC may have shifted from contact lens fitting for as long as tolerated followed by PK or DALK, to UV-cross-linking in order to stabilize corneal ectasia for the long term.[2,3] Although techniques are being developed to treat thinner or steeper corneas as well,[4] corneas thinner than 400 µm or steeper than 58D may be less eligible for UV-crosslinking, whereas this group of patients would similarly benefit from stabilizing the cone, to enable continued contact lens wear. In fact, particularly in advanced KC cases managed by PK or DALK,

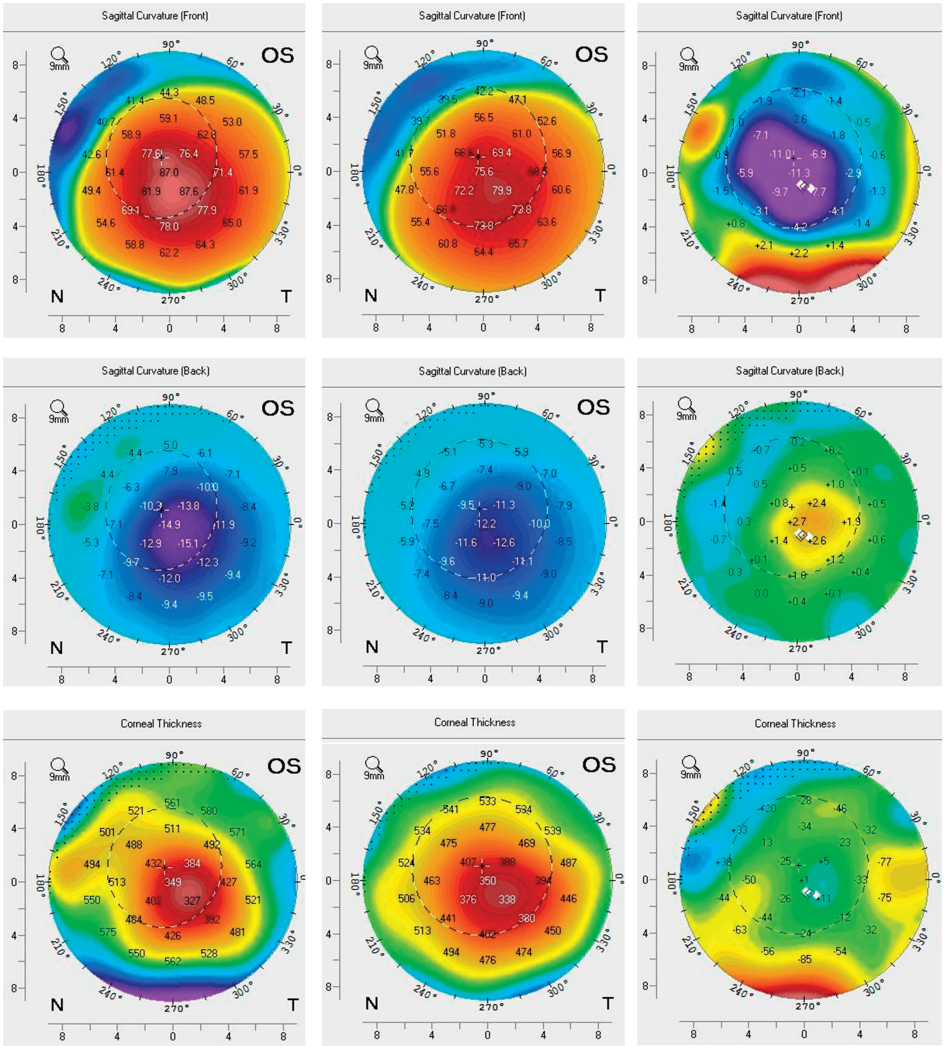

Figure 5. Topography and pachymetry maps of a cornea (Case 8) before and at 12 months after isolated Bowman layer implantation. Note that (A and B) the anterior and posterior keratometric values show significant corneal flattening, while (C) the pachymetry remains unchanged.

the long term clinical outcome of these procedures may frequently be complicated by a sequence of side-effects and complications, through which the final visual outcome may eventually be reduced.[5-8,16-8]Clinical observation suggests that especially eyes with advanced KC are prone to show various 'inflammatory' reactions after surgery, possibly relating to a stronger atopic constitution,[1,2,19,20] rendering any keratoplasty procedure to a 'high-risk' procedure due to the risk of long term complications.

Therefore, our aim was to design a surgical procedure that would solve most of the clinical challenges in advanced KC. Because fragmentation of the recipient's own Bowman layer is one of the pathognomic features in pathology sections of KC corneas,[2,9] it should theoretically be effective to manage KC with an isolated Bowman layer transplant to restore its shape and tensile strength. If the donor Bowman layer would be positioned inside the recipient cornea, the implant would be sandwiched between the stromal layers above and below, and no anterior corneal incisions or fixation means would be necessary. When fixed in this position, the donor Bowman layer would 'pull' the anterior corneal surface flatter, creating a more homogeneous surface topography and possibly long term corneal stability, through better tensile strength of the donor tissue. At the same time, and unlike corneal ring segments,[21] a donor Bowman layer may show similar rigidity as the surrounding recipient corneal stroma, so that the risk of interface reaction and/or migration of the implant may be negligible.

Our surgical approach of positioning an isolated donor Bowman layer in a recipient mid-stromal pocket, proved effective in all cases. The maximum corneal power showed on average a 6 to 7D reduction, which was found to remain stable up to at least one year. Although pachymetry measurements did not show a significant difference, flattening of the cone was clearly associated with stromal compression with biomicroscopy, ie a reduction of the overall arc length. Hence, important parameters used in grading a KC cornea showed improvement, indicating that the procedure may have potential for KC cases ineligible for UV-crosslinking **(Figure 6)**.[22]

An important finding was the complete absence of intra- and/or postoperative complications. None of the eyes showed any ocular surface problems or pressure elevations, while the risk of allograft rejection may be eliminated since no cellular material is transplanted. Therefore, the complete lack of commonly seen complications after PK or DALK indicates that isolated Bowman layer implantation may have important benefits over these procedures. Although the aim of the procedure is not visual improvement, mid-stromal isolated Bowman layer transplantation may allow patients to continue wearing contact lenses in the long term, with a minimal risk of complications, since both the anterior and posterior corneal surfaces are left intact. Hence, mid-stromal Bowman layer transplantation could become an alternative treatment option in the management of advanced KC, to postpone PK or DALK.

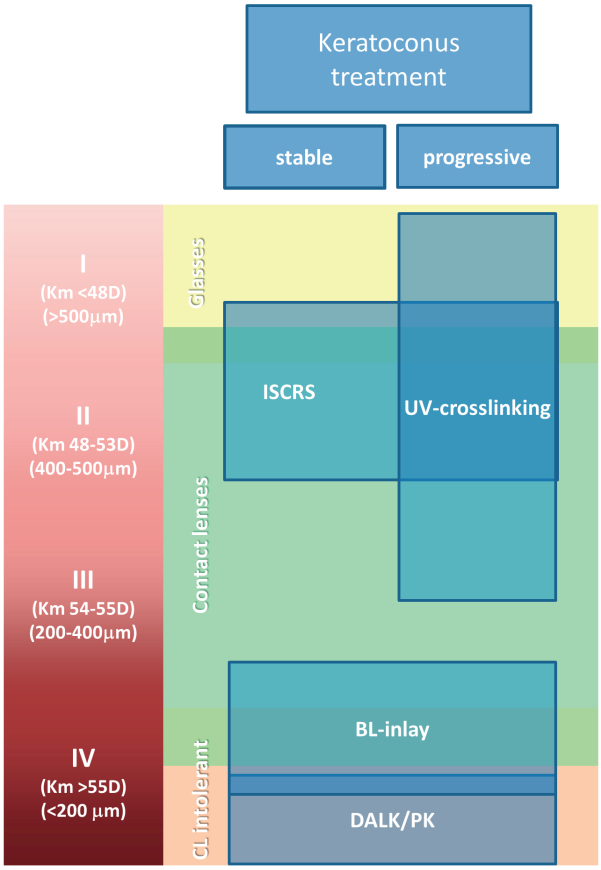

Figure 6. Diagram displaying the different treatment options in the various stages of keratoconus (classification according to Krumeich).

ACKNOWLEDGEMENTS/DISCLOSURE

Conflicts of Interest

GRJ Melles is a consultant for D.O.R.C. International/ Dutch Ophthalmic USA. All other authors (KvD, JP, CMT, LH, JTL, EAGvB) have no conflict of interest to disclose.

Data access and responsibility

GRJ Melles had full access to all data in the study and takes responsibility for the integrity of the data and the accuracy of the data analysis.

Funding

No funding source to disclose.

REFERENCES

1. Rabinowitz YS. Keratoconus. ***Surv Ophthalmol***. 1998;42(4):297-319.
2. Romero-Jiménez M, Santodomingo-Rubido J, Wolffsohn JS. Keratoconus: a review. ***Cont Lens Anterior Eye***. 2010;33(4):157-66.
3. Wollensak G, Spoerl E, Seiler T. Riboflavin/ultraviolet-a-induced collagen crosslinking for the treatment of keratoconus. ***Am J Ophthalmol***. 2003;135(5):620-627.
4. Raiskup F, Spoerl E. Corneal cross-linking with hypo-osmolar riboflavin solution in thin keratoconic corneas. ***Am J Ophthalmol***. 2011;152(1):28–32.
5. Williams KA, Muehlberg SM, Lewis RF, Coster DJ. How successful is corneal transplantation? A report from the Australian Corneal Graft Register. ***Eye***. 1995;9(2):219-227.
6. De Toledo JA, de la Paz MF, Barraquer RI, Barraquer J. Long-term progression of astigmatism after penetrating keratoplasty for keratoconus: evidence of late recurrence. ***Cornea***. 2003;22(4): 317-323.
7. Elder MJ, Stack RR. Globe rupture following penetrating keratoplasty. How often, why, and what can we do to prevent it? ***Cornea***. 2004;23(8):776–780.
8. Nagra PK, Hammersmith KM, Rapuano CJ, Laibson PR, Cohen EJ. Wound dehiscence after penetrating keratoplasty. ***Cornea***. 2006;25(2):132–135.
9. Ambekar R, Toussaint Jr. KC, Johnson AW. The effect of keratoconus on the structural, mechanical, and optical properties of the cornea. ***J Mech Behav Biomed Mater***. 2011;4(3):223-236.
10. Melles GRJ, Binder PS.A comparison of wound healing in sutured and unsutured corneal wounds. ***Arch Ophthalmol***. 1990;108(10):1460-1469.
11. Melles GRJ, Binder PS, Anderson JA. Variation in healing throughout the depth of long-term, unsutured, corneal wounds in human autopsy specimens and monkeys. ***Arch Ophthalmol.*** 1994; 112(1):100–109.
12. Lie JT, Droutsas K, Ham L, et al. Isolated Bowman layer transplantation to manage persistent subepithelial haze after excimer laser surface ablation. ***J Cataract Refract Surg***. 2010;36(6):1036-1041.
13. Melles GRJ, Lander F, Rietveld FJR, Remeijer L, Houdijn Beekhuis R, Binder PS. A new surgical technique for deep stromal, anterior lamellar keratoplasty. ***Br J Ophthalmol***. 1999;83(3):327-333.
14. Melles GRJ, Rietveld FJR, Beekhuis WH, Binder PS: A technique to visualize corneal incision and lamellar dissection depth during surgery. ***Cornea***. 1999;18(1):80-86.
15. Visser E-S, Visser R, van Lier HJJ, Otten HM. Modern scleral lenses part I: clinical features. ***Eye Contact Lens***. 2007;33(1):13–20.
16. Williams KA, Lowe MT, Bartlett CM, Kelly L, Coster DJ. **The Australian Corneal Graft Registry. 2007 report**. Adelaide, Flinders University Press, 2007.
17. Watson SL, Ramsay A, Dart JKG, Bunce C, Craig E. Comparison of deep lamellar keratoplasty and penetrating keratoplasty in patients with keratoconus. ***Ophthalmology.*** 2004;111(9):1676–1682.
18. Jonas JB, Rank RM, Budde WM. Immunologic graft reactions after allogenic penetrating keratoplasty. ***Am J Ophthalmol***. 2002;133(4):437–443.
19. Kok YO, Tan GFL, Loon SC. Review: Keratoconus in Asia. ***Cornea***. 2012;31(5):581-593.
20. Yildiz EH, Erdurmus M, Hammersmith KM, Rapuano CJ, Laibson PR, Cohen EJ. Comparative study of graft rejection in keratoconus patients with and without self-reported atopy. ***Cornea.*** 2009; 28(8):846-850.

21. Coskunseven E, Kymionis GD, Tsiklis NS, et al. Complications of intrastromal corneal ring segment implantation using a femtosecond laser for channel creation: a survey of 850 eyes with keratoconus. ***Acta Ophthalmol***. 2011;89(1):54-57.
22. Sinjab MM. **Quick guide to the management of keratoconus: A systematic step-by-step approach.** New York, Heidelberg, Springer, 2012.

Chapter 4

Bowman Layer Transplantation for Advanced Keratoconus: The First American Case

Jack S. Parker, MD[1,2,3]; John S. Parker, MD[3]; Korine van Dijk, BSc[1,2]; Vasilis Liarakos, MD PhD[1,2]; Salvatore Luceri, MD[1,2]; Isabel Dapena, MD PhD[1,2] and Gerrit R.J. Melles MD PhD[1,2,4]

[1]Netherlands Institute for Innovative Ocular Surgery, Rotterdam, The Netherlands; [2]Melles Cornea Clinic Rotterdam, The Netherlands, [3]UAB Callahan Eye Hospital, Birmingham, Alabama [4]Amnitrans EyeBank Rotterdam, The Netherlands.

ABSTRACT

Purpose: To describe the results of the first Bowman Layer (BL) Transplant performed in the United States

Methods: One eye of one patient with advanced, progressive keratoconus was treated by BL transplantation, in which an isolated donor BL was implanted within the mid-stroma of a recipient cornea. At one day, week, month, and three months postoperatively; visual acuity and corneal clarity, density, thickness, and topographic measurements were recorded and compared to their preoperative values.

Results: The day after surgery, best spectacle corrected vision was 20/40. One week postoperatively, the cornea was thin and clear with the profile of the BL graft only barely visible by slit-lamp examination. By three months, whereas both corneal density and thickness were unchanged, maximum keratometry values had fallen from 62.9 diopters (D) to 58.3 D. With a rigid contact lens the preoperative visual acuity of 20/30 was restored. No intra- or postoperative complications were observed.

Conclusion: Early evidence suggests BL transplantation to be a safe and effective means of flattening and stabilizing corneas with advanced keratoconus.

KEYWORDS

Bowman Layer Transplantation, Keratoconus, Corneal Transplantation, Lamellar keratoplasty

The past decade has seen a reversal in the dominant philosophy regarding the management of patients with keratoconus (KC). Whereas previously, a conservative approach prevailed (aiming at avoiding or delaying surgery for as long as possible), now a policy of early intervention predominates, in which preventative action to arrest the course of the disease is regarded as the soundest strategy. To this end, new therapies such as ultraviolet corneal crosslinking (UVCXL) and intracorneal ring segments (ICRS) have been developed. But some eyes remain poor candidates for either procedure, and may continue to progress.[1]

Recently, however, a new procedure has emerged for patients with advanced KC known as Bowman Layer (BL) Transplantation. In this operation, a graft consisting exclusively of an isolated donor BL is transplanted into the midstroma of a keratoconic cornea. The healing response around the graft functions to both flatten the cornea into a more normal configuration and also halt further ectasia. As a result, contact lens tolerance may be preserved or restored and both penetrating and deep anterior lamellar keratoplasty (PK and DALK, respectively) avoided.[2,3]

To date, however, all reported cases of BL transplantation have been confined to a cohort of mostly Dutch patients, all with extremely advanced disease (maximum kera-

tometry values >70 diopters), operated at a single facility, and using tissue prepared by a single eye bank (Amnitrans EyeBank Rotterdam).[2,3] Here, we describe the results of what is, to our knowledge, the first BL transplantation performed in the United States, involving an American patient and surgeon, advanced (though not extreme) KC, and locally prepared tissue. Moreover, our patient's contralateral eye had previously been treated with ICRS, and we compare the effects of the two operations.

CASE REPORT

A 24 year old black male with a history of advanced, progressive KC was treated with BL transplantation in his left eye. His original diagnosis came five years previously. At the time, he appeared to have moderate disease (Amsler-Krumeich Stage 2) bilaterally. Rigid gas permeable contact lenses were prescribed, but secondary to intolerance in the right eye, symmetrical superior and inferior INTACs (Addition Technology, Inc., Sunnyvale, CA, USA) were placed. Three months postoperatively, in the right eye, best spectacle corrected visual acuity (BSCVA) had improved from 20/40 (0.5) to 20/25 (0.8), and the mean keratometry (Kmean) declined by almost 2.5 diopters (D) from 44.3 to 41.9D (although, the maximum keratometry (Kmax) actually increased from 53.2 to 56.0 D), measured by corneal topography (Carl Zeiss Meditec Atlas, Version 2.0.0.34, Germany).

Two years later, whereas the right eye appeared stable (Kmean 40.9D; Kmax 53.6D), the left eye seemed to be progressing: Kmean had increased from 43.6 to 45.2D, and Kmax from 47.0 to 53.0 D. Therefore, we recommended the left eye receive UVCXL. But because the procedure was not FDA approved in the United States, and because treatment would therefore require that he travel internationally, the patient declined and opted instead for a course of watchful waiting.

Eighteen months later, he returned for examination. Both corneas had progressed. Measured by Scheimpflug-based corneal tomography (Pentacam HR; Oculus, Wetzlar, Germany), the right eye only slightly (Kmean 42.2D; Kmax 52.1D). The left, however, more substantially (Kmean 45.5D; Kmax 57.1D). After six more months, further progression was evident: mild in the right eye (Kmean 43.1D; Kmax 52.9D) and severe in the left (Kmean 47.3D; Kmax 62.9D). Although the vision remained relatively good in both eyes (BSCVA of 20/40 in the right and 20/30 in the left), the relentless progression of disease - particularly in the left eye - prompted us to proceed with BL transplantation.

The graft was prepared as previously described (in the Alabama Eye Bank, one week before transplantation).[4] From a whole globe obtained less than 36 hours post-mortem, a corneoscleral button was excised and stored in optisol until the time of preparation. At which time, it was removed from solution, mounted endothelial side down in an artificial anterior chamber (Moria, Antony, France), and the epithelium was removed.

Trypan blue (VisionBlue; DORC International) was dripped over the anterior surface, and the BL was lightly scored 360 degrees just inside the limbus using the tip of a 30-gauge needle. Then, it was gradually and delicately peeled free using McPherson forceps. Once separated, the BL spontaneously curled into a roll (Figure 1). It was rinsed in 70% ethanol to remove any lingering epithelial cells and stored in optisol until the time of transplantation.



Figure 1. Isolated Bowman Layer graft (green arrow) floating in a drop of balanced salt solution next to the isolated Descemet membrane (yellow arrow) from the same donor cornea.

The surgery itself likewise proceeded according to prior description: using a 15 degree blade and a crescent knife, a 5mm long partial thickness scleral incision was created, 2mm posterior to the limbus, then tunneled up into the peripheral clear cornea. The anterior chamber was filled with air and DALK spatulas (Melles spatula set; DORC International) were maneuvered into the tunnel and advanced through the cornea to dissect a pocket in the mid- stroma, stretching from limbus-to-limbus, 360 degrees around.[5,6] A glide (BD Visitec Surgical Glide [Fichman]; Beaver-Visitec International, Waltham, MA) was inserted into the mouth of the tunnel, the BL roll was removed from optisol, dipped again in 70% ethanol, rinsed with balanced salt solution (BSS; Bausch & Lomb, Rochester, NY), stained with trypan blue, and placed on top. The donor tissue was then advanced along the glide and into the cornea by pushing with the tip of a 30-gauge cannula. Inside the pocket, the graft was unfolded with gentle strokes of the cannula and jets of

BSS (Figure 2). Postoperatively, dexamethasone 0.1%/tobramycin 0.3% (Tobradex; Alcon Laboratories) eye drops were applied four times daily for the first month and tapered by one drop per month thereafter.

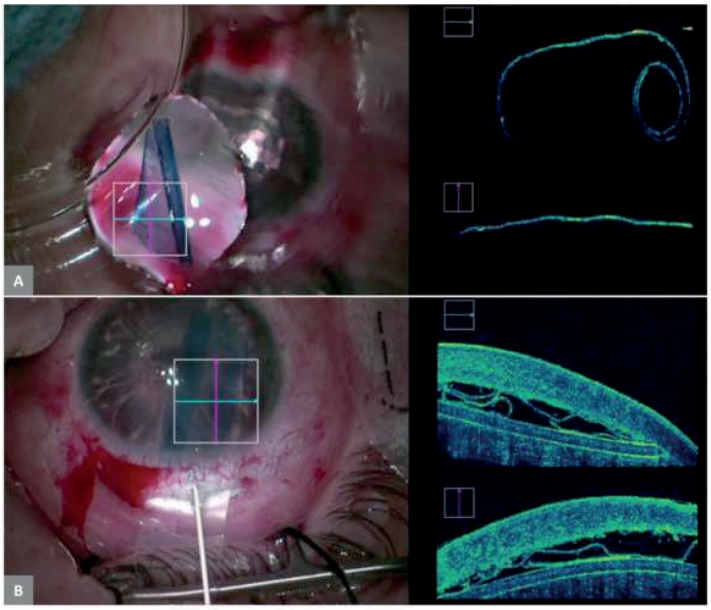

Figure 2. Bowman layer graft immediately before implantation, seen from above with the operating microscope and in profile using intra-operative optical coherence tomography (**A**). Subsequently, the graft is placed atop the surgical glide, pushed into the stromal pocket, and unfolded (**B**).

No intra- or postoperative complications were experienced. The day after surgery, a BSCVA of 20/40 was reached, where it remained stable at the one week, one month, and three month visits (preoperative 20/30). (At the three month visit, refraction with a rigid, gas-permeable contact lens (CTL) was also performed, resulting in a best CTL corrected visual acuity of 20/30). Likewise, by 3 months postoperatively, Kmean had declined by 1.2D (from 47.1 to 45.9D) and Kmax by nearly 5D (from 62.9 to 58.3D) Compared to their preoperative values, the central and thinnest point corneal thicknesses were hardly affected, changing from 465µm to 482µm and from 459µm to 464µm, respectively. Over this same time period, the average total corneal densitometry measurements (a unitless metric indicating the amount of light backscattered by the cornea) increased slightly, from 15.3 to 18.2. By Scheimpflug imaging and slit-lamp biomicroscopy, the edges of the graft have remained only barely visible as a thin line without any accompanying inflammation (Figure 3). Meanwhile, the cornea of the right eye has continued to show progression (Kmean 43.1D; Kmax 55.5D).

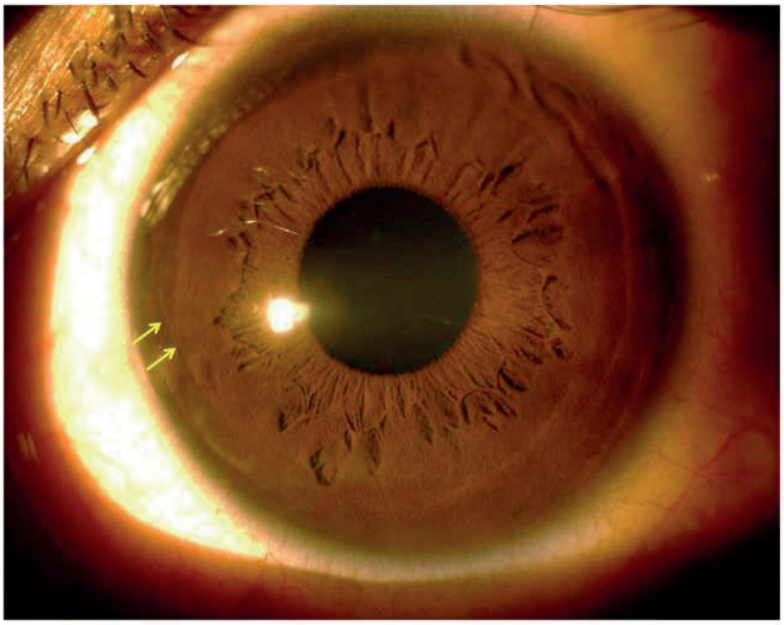

Figure 3. Postoperatively, the edges of the graft have remained faintly visible as a thin white line (yellow arrows) without any accompanying inflammation

DISCUSSION

Prior to BL transplantation, the vision in our patient's operated eye was relatively good, but his ectasia appeared to be rapidly progressing, necessitating some intervention. ICRS placement was not thought to be a viable option, considering the cornea's severe ectasia, and the underwhelming performance in the contralateral eye. Likewise, UVCXL was not regarded as practical, since our patient was unable to travel internationally to receive it. Therefore, our only recourse was to attempt BL transplantation.

Our case is noteworthy because it demonstrates that the prior Dutch results are replicable. That is, even with different surgeons, tissue preparations, and patients, the same basic outcomes are observed. Specifically: a substantial amount of corneal flattening, an interruption in the progression of ectasia, and no intra- or postoperative complications.

Furthermore, because our patient had much less advanced disease than those in the Dutch studies, our results suggest the procedure may also be feasible in eyes with less than "extreme" KC. If true, then this could be an important discovery, since many patients with mild to moderate KC are presently not eligible for either ICRS or UVCXL (especially in the United States) and therefore, have no alternative to prevent the eventual onset of late stage disease.

These advantages notwithstanding, our study may also confirm some of the potential limitations of BL transplantation. First, the procedure does not appear to much improve the recipient's Snellen acuity (although our patient did report a subjective increase in the quality of his vision, perhaps as a result of normalizing his ocular surface). Therefore, BL transplantation may not be ideal for patients with extremely poor vision. Second, much about the surgery remains unknown, including the operation's long term results. This applies, also, to our own case report, which only provides follow-up data through the first 3 postoperative months.

Our results corroborate earlier findings: that BL transplantation may be a useful means of arresting and reversing keratoconic ectasia. Undoubtedly, further investigation will be necessary, hopefully by a diversity of doctors in a variety of locales.

CONFLICT OF INTEREST

Dr Melles is a consultant for DORC International/ Dutch Ophthalmic USA and SurgiCube International. Dr. Dapena is consultant for DORC International. For the remaining authors none were declared.

REFERENCES

1. Parker JS, van Dijk K, Melles GR. Treatment options for advanced keratoconus: A review. *Surv Ophthalmol* 2015;60:459-480.
2. van Dijk K, Parker J, Tong CM, et al. Midstromal isolated Bowman layer graft for reduction of advanced keratoconus: a technique to postpone penetrating or deep anterior lamellar keratoplasty. *JAMA Ophthalmol* 2014;132:495-501.
3. van Dijk K, Liarakos V, Parker J, et al. Bowman layer transplantation to reduce and stabilize progressive, end stage, keratoconus. *Ophthalmology* 2015;122:909-917.
4. Lie J, Droutsas K, Ham L, et al. Isolated Bowman layer transplantation to manage persistent subepithelial haze after excimer laser surface ablation. *J Cataract Refract Surg* 2010;36:1036-1041.
5. Melles GR, Rietveld FJ, Beekhuis WH, et al. A technique to visualize corneal incision and lamellar dissection depth during surgery. *Cornea* 1999;18:80-86.
6. Melles GRJ, Lander F, Rietveld FJR, et al. A new surgical technique for deep, anterior lamellar keratoplasty. *Br J Ophthalmol* 1999;83:327–333.

Chapter 5

Updates in Anterior Lamellar Keratoplasty: The State of the Debates

Jack S. Parker[1-3], Korine van Dijk[1-2], Gerrit Melles[1-2,4]

[1]Netherlands Institute for Innovative Ocular Surgery, Rotterdam, The Netherlands; [2]Melles Cornea Clinic Rotterdam, The Netherlands; [3]UAB Callahan Eye Hospital, Birmingham, Alabama; [4]Amnitrans EyeBank Rotterdam, The Netherlands.

ABSTRACT

Introduction: Deep and Superficial anterior lamellar keratoplasty (DALK and SALK, respectively) are rapidly replacing penetrating keratoplasty (PK) as the treatments of choice for anterior corneal disorders worldwide. Nevertheless, significant disagreements remain which encompass nearly every aspect of both operations and whether there are better alternatives

Areas Covered: Here, we perform a comprehensive literature review of all articles published in the English language, indexed on Pubmed, and within the past 5 years on the subject of "anterior lamellar keratoplasty." From these articles, the most salient disputes are enumerated and presented.

Expert Commentary: Presently, there is no consensus in the areas of graft preparation, instrumentation, or operative technique for DALK/ SALK. As new evidence emerges, these debates may be clarified, or – instead – merely forgotten, as alternative surgical techniques arise to supplant ALK entirely.

KEYWORDS: anterior lamellar keratoplasty, Bowman layer transplantation, DALK, SALK, review

1.0 INTRODUCTION

The past decade has seen a blossoming of anterior lamellar keratoplasty (ALK) as a surgical strategy and a proliferation of studies scrutinizing its various applications. From these myriad investigations, a consensus has emerged that ALK (properly performed) confers the same visual benefits as its predecessor (penetrating keratoplasty, PK), but with fewer potential complications.[1,2] In this article, we put that general agreement aside and focus instead on the remaining controversies. After "staging the debate" by describing the evolving trends in corneal transplantation, we shift to enumerating the five largest contemporary disputes surrounding ALK. As a collection, these span the gamut: from graft selection and preparation, to operative technique, to instrumentation, to surgical anatomy, to potential alternatives. Overall, the intention is not to resolve any of these points of contention, but rather, to provide an overview of the landscape of competing claims. By identifying the various opinions, and by displaying their rationales, we hope to apprise readers of these ongoing disputes and enable them to interpret new research *vis-a-vis* existing debates.

1.1 Modern Trends

Globally, the number of PKs performed each year has been increasing: in 2011, the total number of such procedures (domestically and internationally) using tissue prepared by American eye banks was 36,998.[3] That number has grown steadily and stands in the Eye Bank Association of America's most recent report at a modestly greater 38,919.[4] Nevertheless, as a percentage of all corneal transplants, PK is becoming less preferred, both in the United States and abroad, largely secondary to the introduction of posterior lamellar keratoplasty, particularly Descemet Stripping (Automated) Endothelial Keratoplasty (DSAEK) and Descemet Membrane Endothelial Keratoplasty (DMEK), which have almost totally displaced PK from the treatment of corneal endothelial disorders.[3,4]

The emergence of ALK has also undercut the number of PKs performed, although to a lesser extent. Particularly in the United States, PK still remains the more popular option for anterior corneal pathologies, accounting for 90% of those transplantations.[3,4] This fraction has been tilting steadily in ALK's direction for the past decade, however, and has reached parity in much of Europe and swung decisively into ALK's favor within regions of the Middle East.[5-10] ALK's most common indication - representing >70% of all cases - is advanced keratoconus (KC), followed by stromal dystrophies and postinfectious scarring.[3,4] Overall, the number of transplantations performed for KC appears to be decreasing, potentially owing to modern disease arresting therapies including ultra-violet corneal crosslinking (UV-CXL) and intra-corneal ring segments (ICRS).[10,11]

2.0 CONTROVERSY ONE: GRAFT PREPARATION

The debates here are multifaceted, and center upon the use of fresh vs. preserved human corneas vs. xenografts (deriving primarily from pigs), and upon the proper instrumentation for graft creation.

2.1 Fresh (human) corneal tissue (FCT)

The case for the use of FCT is based on tradition and simplicity. It is also the graft type with the largest literature base, and recently, Russo et al. have reported that with Descemet membrane baring deep anterior lamellar keratoplasty (D-DALK), FCTs provide better visual results and longer longevity than do decellularized grafts.[12] Prolonged death-to-preservation and storage times conduce to epithelial defects in the immediate postoperative phase, but do not impact ultimate visual outcome.[13] Conversely, Borderie et al. published that the use of tissue from donors >80 years old yields significantly worse visual results (with average corrected acuities of 20/55, compared to 20/30 with younger donors).[14] FCT may be commonly stored in Optisol-GS, as in the United States, or in Organ Culture, as in Europe. After a week of storage in organ culture, ALK tissue may be transplanted with good results.[15,16] However, during storage, the donor grafts swell (up to 1200µm) and become opaque. Although these features reverse after surgery, preventing this storage-related transformation may permit a technically easier operation and less postoperative surface change. For this purpose, Lie et al. proposed a new dehydrating solution, buffered with PEG, for soaking donor lenticules stored in organ culture, starting 24-48 hours before surgery.[17] These recent discoveries aside, for those using FCT for DALK, the biggest controversy is whether to leave the donor endothelium on, or strip it off, prior to transplantation.

2.1.A. **DM-on FCT tissue:** Leaving the donor-DM intact may result in less trauma to the graft's posterior surface during stripping (and also, less epithelial disruption). Meanwhile, it shortens the surgery, has no measurable impact on Snellen acuity or higher order aberrations, and has never been proved responsible for a heightened occurrence of graft rejection.[18,19]

2.1.B. DM-off FCT tissue: Opponents counter that DM-on transplants may undermine healing at the lamellar interface, precipitating a double anterior chamber and interface haze which - while not diminishing Snellen acuity (and the stromal haze may tend to resolve over time) - does appear to compromise contrast sensitivity.[19-22] There is also the theoretical risk of an increased antigenic load, which may incite additional allograft reaction.

2.2 Preserved (human) corneal tissue (PCT)

PCTs are decellularized grafts stored in sterile solutions. Compared to FCTs, they carry a significantly longer shelf-life, a lower probability of harboring infection, and a diminished risk of inciting allograft reaction (since they have been purified of antigen presenting cells). For the same reason, these grafts possess a lower density of keratocytes (even years after surgery), and - when combined with D-DALK - may thin and opacify over time.[12,23] The competing strategies for producing PCT include:

2.2.A. Cryopreservation and/ or dehydration: "Lyophilizing" is among the oldest methods for PCT production; it consists of freezing followed by dehydration under high vacuum. Cryopreservation remains popular (and may be performed alone, without a subsequent lyophilizing step, yielding results equivalent to the use of FCT, per Javadi et al.)[24], although today dehydration is more commonly accomplished chemically by osmotic agents (such as glycerol/ glycerin). Stored at -78°C, donor corneas may remain viable for years. In a recent study of DALK in high-risk patients, Li et al. reported that 0/31 (0%) eyes experienced an episode of allograft reaction during the first two years when operated with glycerol cryopreserved corneas compared to 10/33 (21.2%) operated with FCT.[25] Excepting Russo et al.'s previously mentioned report, no study has found worsened visual outcomes with cryopreserved or dehydrated tissue compared to FCT (and, in fact, Farias et al. described improved contrast sensitivity using lyophilized vs. Optisol stored grafts in patients receiving DALK for KC).[12,26,27] The chief reported problem with glycerol storage is swelling and opacification of the donor tissue prior to surgery, which - though resolving spontaneously after surgery - may make the operation itself more technically challenging.[17]

2.2.B. Gamma irradiation: Gamma-irradiated corneas are available commercially under the product name "VisionGraft Sterile Cornea" (VisionGraft, Tissue Banks International Inc., Baltimore, MD, USA). Following irradiation, the tissues are stored in an Albumin solution where they can remain viable at room temperature for one year. Most of the literature describes their use as patch-grafts for corneal perforations. However, the several studies evaluating their role as stand-alone corneal transplants have found equivalent Snellen acuities compared to FCT and reduced risk of allograft reaction, but more stromal haze (and, therefore, the heightened possibility of diminished contrast sensitivity).[28-31]

2.3 Xenotransplantation

Particularly in the population-dense third world, the donor cornea shortage has rendered xenotransplantation and "xenobridging" positions of extreme interest. Porcine corneas perhaps have the greatest potential, since they have approximately the same size, shape, and refractive properties as human corneas, and since porcine-to-human transplantations are already commonplace in other areas of medicine.[32-34] To date, most

studies have been animal based, evaluating various protocols for decellularizing porcine corneas and transplanting them into rabbits and non-human primates.[35-37] However, Zhang et al. recently reported the results of 47 eyes receiving decellularized, porcine DALK grafts for intractable fungal ulcers: 6 months after surgery, all patients were apparently free of infection, and 41/47 (87%) had clear, epithelialized grafts.[38]

2.4 Instrumentation

For DALK, graft preparation consists only of removing the DM and endothelium from a full-thickness donor cornea (and for surgeons who prefer DM-on FCT, even this represents an optional step). But for superficial ALK (intending only partial-thickness stromal replacement), the donor graft must be specially crafted. Formerly, this was accomplished by hand: after mounting a corneoscleral button within an artificial anterior chamber (or some facsimile) a manual lamellar dissection was performed.[39,40] Now, however, three automated alternatives exist: the microkeratome and femtosecond and excimer lasers.

2.4.A. Microkeratome facilitated graft preparation: This is the older strategy, having been originally conceived by Barraquer in 1972.[41] Different cut depths (and thereby graft thicknesses) can be achieved by varying the cutting speed, blade size, and pressure within the artificial chamber holding the donor tissue in position. In general, ALK grafts prepared by microkeratome tend to approximate their intended depth better when the cut is shallower, so thinner grafts are more likely to be accurately prepared than thicker ones.[42,43] For each individual graft, the thickness may also be uneven, with the center thinner than the periphery (by, on average, 25μm).[44] Perhaps the greatest liability for microkeratome graft preparation, however, is that it may oblige the intraoperative use of the microkeratome to likewise fashion the recipient bed, and - of all the strategies for recipient stromal dissection - the microkeratome may yield the worst results.[45-48]

2.4.B. Femtosecond and excimer laser facilitated graft preparation: Compared to the microkeratome, the femtosecond laser is more accurate and more precise.[49,50]It also permits the edges of the donor lenticules to be shaped into one of several configurations, theoretically enabling better tissue apposition. However, the femtosecond laser is considerably more expensive to use and, with deeper cuts (>250μm), produces ridges in the graft's posterior stroma that compromise its optical performance.[44,51]

The excimer laser is an older, alternative technique for graft preparation: it ablates, rather than incises, the donor tissue to the desired depth. Its advantages include precisely perpendicular graft edges, which may reduce horizontal and vertical tilting (and correspondingly, astigmatism) compared to donor grafts trephined by hand.[52-54] However, unlike the femtosecond laser, the excimer laser does not permit the graft edges to be "shaped" into various configurations, making it potentially less suitable for SALK applications. In addition, the excimer laser has conventionally been an expensive

instrument to use, and not widely available. As a result, there is correspondingly little published about its use.

3.0 CONTROVERSY TWO: PRE DESCEMET STROMA AND DALK DISSECTION DEPTH

Pre Descemet Stroma layer (the so-called "Dua layer") remains a hotly contested subject. The referenced tissue no doubt exists, although perhaps not as a discrete structure. Specifically, whereas some stroma does indeed typically remain adherent to the underlying DM during pneumo/visco/manual dissection (an old, if not widely appreciated finding), the amount is not constant, nor is it otherwise endowed with any special features.[55-63] Regardless, Pre Descemet Stroma layer(s) may still be useful as a reference plane: stromal dissections reaching this level might be characterized as "deep" and distinguished from those terminating superficially.[64] On this issue, the modern debate centers around what dissection depth is ideal.

3.1 Maximal

The totality of evidence suggests that deep dissection (to the level of Pre Descemet Stroma/DM) provides visual results that are equivalent to PK and better than those obtained with mid-stromal dissection.[1,2] Compared to sub-maximal dissection (close to, but not quite to the level of Pre Descemet Stroma/DM), the visual recovery is faster, interface reflectivity is lower, and keratocyte activation is lesser, at least through the first 6 postoperative months.[65,66] Thereafter, these disparities diminish (as stromal haze decreases) , but may not totally disappear.

3.2 Sub-maximal

Most studies of sub-maximal dissection are the result of failed "big-bubble" attempts, after which, layer-by-layer manual stromal removal is performed. (This might bias the results against submaximal dissection, since those eyes receiving it may be somehow architecturally /structurally different from those in which big-bubble dissection succeeded). As a result, the stromal layer tends to be not only thicker, but also, more irregular. Although this irregularity may be optically limiting, there may not be a correlation between residual stromal thickness and visual outcome.[67,68] Grafts transplanted onto a thicker stromal bed also have a higher keratocyte density postoperatively, and - if using decellularized donor material - may be less likely to develop progressive thinning / anterior stromal haze, which tends to worsen over time (whereas, with FCT tissue, stromal haze tends to gradually improve over time).[12,66] According to Borderie et al., corneas undergoing manual stromal (vs. big-bubble) dissection additionally pos-

sess higher postoperative endothelial densities, presumably secondary to their more anterior cleavage planes.[48] Therefore, a submaximal dissection depth may be desirable in patients with concomitant endothelial dysfunction. Additional theoretical reasons to prefer a thicker recipient bed include: a technically easier surgery, protection against inadvertent perforation, and added tectonic stability.

4.0 CONTROVERSY THREE: BIG-BUBBLE UPDATES AND DEBATES

DALK with pneumatic dissection was introduced by Anwar in 2002 via his "big-bubble" technique.[68] (Hydrodissection and visco-dissection strategies were previously introduced, but neither achieved a popular following.[69,70]) Since then, a litany of modifications to the original procedure have been described, mostly geared toward increasing the success rate of big-bubble production (varying widely in the literature between 35-95%).[1,2] The most debated factors influencing this success rate include:

4.1 Patient demographics

Feizi et al. reported that female sex predicts against successful big bubble creation (odds ratio of 0.4), but that patient age, personal history of vernal keratoconjunctivitis, and family history of keratoconus do not.[71] Conversely, Goweida published that advanced patient age predisposes toward the formation of type-2 bubbles following intrastromal air injection (with a cleavage plane formed between Pre Descemet stroma and DM), which have a higher-rate of intraoperative rupture compared to type-1 bubbles (formed between posterior stroma and Pre Descemet Stroma.)[72]

4.2 Patient disease severity

KC severity is partially reflected in measured corneal steepness, thickness, and the presence of stromal scarring. Studies analyzing the effects of these features on big-bubble creation have returned conflicting results. Fontana et al. and Huang et al. reported that milder KC results in more frustrated attempts (Fontana: 73% success rate in corneas with central mean keratometry > 62 diopters (D) vs. 55% of patients <62D; and Huang: 80.6% success in corneas with advanced KC vs. 36.4% with moderate KC).[73,74] In contrast, Michieletto et al. published that corneas thinner than 250µm, particularly if accompanied by significant stromal scarring, are more likely to suffer DM perforations during air injection, necessitating conversion to PK.[75] Goweida likewise found thinner corneas more susceptible to inadvertent type-2 bubble formation and intraoperative perforation.[72] Meanwhile, in what may be the largest dedicated study of the subject, Feizi et al. uncovered no association between corneal steepness, thickness, or anterior stromal scarring (not involving DM) and big-bubble creation.[71]

4.3 Surgeon learning curve

Some learning curve certainly exists - Caporossi et al. (in two separate investigations) and Smadja et al. both reported a significant decrease in all complications after their first 10 cases.[76-78] However, because most studies report a success rate of ≤ 80%, it is probable that an inescapable risk of DM perforation is intrinsic the procedure, regardless of the level of surgical experience.

4.4 Location of intrastromal air-injection (central vs. peripheral)

The originally described technique calls for air injection in the corneal center. However, Busin et al. published that peripheral injections (1-2mm inside the corneal trephination) are equally efficacious in big-bubble generation.[79] Moreover, Feizi et al. reported that peripheral air injections (outside the original trephination, into the corneal periphery) achieve the same effect, while avoiding obscuring/whitening the central cornea, thereby preserving intraoperative visibility. Although, a potential downside of this latter procedure is enhanced risk of type-2 bubble creation with subsequent perforation.[80,81]

4.5 Depth of intrastromal air-injection (superficial vs. deep)

Overwhelmingly, big-bubble formation seems to be a function of the stromal depth at which air is injected, with deeper injections more likely to succeed than shallower ones. This consensus finding has generated a litany of competing, ancillary techniques for facilitating deep injection. These include:

4.5.A. Enhanced visualization techniques: Melles et al. reported that inflating the anterior chamber with air prior to injection generated an "air-endothelial" light reflex, providing a guide for advancing a needle into the deep stroma with minimal risk of inadvertent perforation.[56,82,83] Recently, Scorcia et al. described a similar visual cue demonstrated by retro-illumination (therefore, requiring pupillary dilation of the operative eye).[84]

4.5.B. Facilitated visualization techniques: Several have described the intraoperative use of optical coherence tomography (OCT) to guide air injection, but none have demonstrated an improved rate of big-bubble creation.[85,86]

4.5.C. Facilitated injection techniques: Principally, these employ intraoperative pachymetry to guide deep incisions inside the trephination area, into which the intrastromal injection is delivered. In a large trial of the technique, Ghanem et al. reported a 90.5% success rate of big-bubble formation, rising to 95.5% if - after an initial attempt failed - a second injection was delivered using visco-elastic, rather than air.[87-89]

5.0 CONTROVERSY FOUR: MANUAL, MICROKERATOME, EXCIMER, AND FEMTOSECOND ASSISTED ALK

For both SALK and DALK, recipient lamellar dissection may proceed manually, by microkeratome, and by femtosecond or excimer laser. In general, SALK is limited to patients with stromal scarring in the anterior 200µm of the cornea, and as a result, is performed more commonly for post-infectious or traumatic scarring, and less frequently for ectatic disorders such as keratoconus.[90,91] Compared to DALK for the same indications, SALK may offer equivalent visual results and, theoretically, enhanced tectonic stability.[92,93]

5.1 Manual dissection

Manual dissection has been virtually abandoned as a strategy for SALK, since microkeratome and femtosecond cuts have proven faster and smoother. For DALK, however, manual dissection remains a popular strategy. First introduced by Melles in 1998, a controlled manual dissection down to the level of DM is possible using curved spatulas, guided by the air-endothelial light reflex (previously discussed).[82,83] Visual outcomes approximate those achieved by big-bubble dissection, and the chances of inadvertent perforation may be reduced by 50%, although the interface may be less regular, compromising contrast sensitivity.[48,94]

5.2 Microkeratome:

Microkeratomes are rarely used to facilitate DALK: their cut depth is too variable/unreliable to consistently achieve a deep dissection, particularly in severely irregular (especially KC) corneas, where the risk of various complications is also increased.[46-48] Despite Busin et al.'s positive report describing their own results, Borderie et al. found that - compared to femtosecond and manual dissection - microkeratome cuts resulted in the worst visual outcomes among the three strategies.[48,95,96] As a result, the microkeratome is more commonly used to facilitate SALK, since its cut accuracy and precision are better with shallower passes.[42,96] An advantage of using the microkeratome for SALK is that the recipient beds tend to be smoother than when the femtosecond laser is used, instead. The microkeratome may also be preferred in cases of dense corneal opacities, below which the femtosecond laser may have difficulty focusing.[97]

5.3 Femtosecond and excimer laser:

Like the microkeratome, the femtosecond laser is rarely used to perform deep lamellar dissection with DALK, since - the deeper its application - the larger and the more visually significant are the interface ridges produced.[44,51] (Higher frequency laser application and excimer laser ablation of the femtosecond dissected bed somewhat diminish these ridges, but only to a limited extent.[98]) However, the laser nevertheless finds frequent us-

age in DALK surgeries to shape the edges of the recipient and donor tissues: by cutting interlocking profiles in the two tissues, their fit may be enhanced, resulting in better tissue apposition, a stronger wound, and the possibility of earlier suture removal.[93,97,99] Wetlab studies have indeed confirmed an increased resistance to wound gape/ leak using femtosecond cut edges compared to simple, mechanical trephination methods.[49,100] However, there have been no astigmatic improvements noted (which disputes the notion that better tissue apposition is achieved.) Moreover, in the only study to directly assess whether earlier suture removal is possible following femtosecond vs. conventional trephination, Shehadeh-Mashor et al. found that - on the contrary - suture removal was significantly delayed in the femtosecond group compared to the mechanical method.[101] Additional disadvantages to incorporating the femtosecond laser into DALK procedures including substantially increased surgical time and cost. Femtosecond assisted SALK, however, is an operation growing in popularity, and several studies have shown that - with specially cut donor and recipient profiles - the graft may be secured without sutures, thereby alleviating one of the largest potential sources of postoperative complications.[90,91]

As mentioned previously, the excimer laser has likewise been used to shape the recipient and donor surfaces, achieving visual and astigmatic results that compare favorably to the above mentioned alternative modalities.[52-54,102-104] However, their expense entailed, relative scarcity, and the inability to shape the donor edge profile with excimer laser has somewhat undermined their popularity.

6.0 CONTROVERSY FIVE: ALTERNATIVES TO DALK/SALK - BOWMAN LAYER (BL) TRANSPLANTATION

BL transplantation was introduced by van Dijk et al. in 2013 as a procedure for patients with advanced, progressive KC.[105] The operation consists of transplanting an isolated, donor BL into the midstroma of a keratoconic cornea. As the recipient cornea heals around the transplanted tissue, it flattens (with maximum keratometry values decreasing by, on average, approximately 9D).[105,106] The ocular surface likewise experiences a significant reduction of higher order visual aberrations, especially spherical aberration.[107] The effect is to improve best spectacle corrected visual acuity and patient subjective visual satisfaction. Best contact lens acuity frequently remains unchanged, but rigid contact lens tolerance may be increased. Like DALK/SALK, the operation itself is largely "extraocular," taking place entirely within the recipient cornea, but it entails no surface incisions or corneal sutures - only a manual mid-stromal dissection (facilitated by manual DALK dissection spatulas.) Because the graft is acellular, the risk of allograft reaction and graft rejection may be diminished. As a result, some of the most significant complications of PK

and DALK may be avoided, including wound healing, ocular surface, and suture related problems.. As with DALK, the operation's most common complication is intraoperative DM perforation, which may occur in approximately 10% of eyes. Thereafter, the surgery may be converted to PK or aborted: since no surface incisions have been made, the perforation site may be allowed to heal and the operation reattempted at a later date.

Presently, BL grafts are prepared by hand: donor corneas are mounted in artificial anterior chambers, debrided of their epithelium, stained with trypan blue, and then stripped of their BL using fine forceps. Groeneveld-van Beek et al. reported a success rate for BL graft preparation of 70%, indicative of the current technical difficulty of the procedure. Before stripping BL, the donor cornea's endothelium may harvested for Descemet Membrane Endothelium Keratoplasty (DMEK). Thereby, a single donor cornea may be sectioned for use in two separate patients.[108,109]

To date, BL transplantation has been reserved exclusively for patients with extremely advanced KC (maximum keratometry values >70D). Its application to less severely ectatic corneas has not yet been investigated. However, considering that many KC disease arresting therapies are not-yet available in the United States (including ultraviolet corneal cross-linking and a variety of intracorneal ring subtypes), BL transplantation may see an expanded role in the future.

7.0 EXPERT COMMENTARY

In each of the five areas listed above, legitimate controversies exist. None are likely to be resolved soon, although – as new technologies emerge – the list of "most important" controversies is likely to change. It is possible that none of them will be resolved, so much as they will be "forgotten," as have many of the disputes lingering with regard to PK.

8.0 5-YEAR VIEW

Despite continual advances in PK, DALK, and SALK, the future may involve fewer penetrating surgeries of all sorts. With the spread of disease arresting therapies (including ultraviolet crosslinking, intracorneal ring segments, and Bowman layer transplantation), the trend will be toward improved visual outcomes and fewer postoperative complications.

9.0 KEY ISSUES:

- Deep and Superficial anterior lamellar keratoplasty (DALK and SALK, respectively) offer equivalent visual results with fewer complications compared to PK.
- Both operations are increasing in popularity, although significant disagreement remains concerning their application
- For both, donor corneal tissue may be prepared fresh, from decellularized stores, and increasingly from animal sources. Microkeratomes and femtosecond lasers may be useful instruments for sculpting grafts.
- The surgeries themselves may be facilitated by "big bubble" techniques, by manual dissection, or by recourse to microkeratome and femtosecond technology. The propriety of each method may depend on the particular features of the individual patient.
- For superficial stromal scars, SALK may offer an additional advantage over DALK by providing a tectonically stronger eye, and by eliminating the need for sutures.
- Meanwhile, Bowman Layer transplantation is a new operation for patients with advanced keratoconus: it may eventually supersede PK and DALK/SALK as the treatment of choice for patients with corneal ectasias.

REFERENCES

1. *Parker JS, van Dijk K, Melles GR. Treatment options for advanced keratoconus: A review. Surv Ophthalmol. 2015;60(5):459-80
2. Chen G, Tzekov R, Li W, Jiang F, Mao S, Tong Y. Deep Anterior Lamellar Keratoplasty Versus Penetrating Keratoplasty: A Meta-Analysis of Randomized Controlled Trials. Cornea. 2016;35(2): 169-74
3. Eye Bank Association of America. 2012 Eye Banking Statistical Report. 2016
4. *Eye Bank Association of America. 2014 Eye Banking Statistical Report. 2016
5. Wisse RP, van den Hoven CM, Van der Lelij A. Does lamellar surgery for keratoconus experience the popularity it deserves? Acta Ophthalmol. 2014;92(5):473-7.
6. Keenan TD, Jones MN, Rushton S, Carley FM; National Health Service Blood and Transplant Ocular Tissue Advisory Group and Contributing Ophthalmologists (Ocular Tissue Advisory Group Audit Study 8). Trends in the indications for corneal graft surgery in the United Kingdom: 1999 through 2009. Arch Ophthalmol. 2012;130(5):621-8
7. Godefrooij DA, Gans R, Imhof SM, Wisse RP. Trends in penetrating and anterior lamellar corneal grafting techniques for keratoconus: a national registry study. Acta Ophthalmol. 2016 Apr 7 7. doi: 10.1111/aos.13041. [Epub ahead of print]
8. Frigo AC, Fasolo A, Capuzzo C et al. Corneal Transplantation Activity Over 7 Years: Changing Trends for Indications, Patient Demographics and Surgical Techniques From the Corneal Transplant Epidemiological Study (CORTES). Transplant Proc. 2015;47(2):528-35
9. Zare M, Javadi MA, Einollahi B et al. Changing indications and surgical techniques for corneal transplantation between 2004 and 2009 at a tertiary referral center. Middle East Afr J Ophthalmol. 2012;19(3):323-9
10. de Sanctis U, Alovisi C, Bauchiero L, et al. Changing trends in corneal graft surgery: a ten-year review. Int J Ophthalmol. 2016;9(1):48-52
11. Sandvik GF, Thorsrud A, Råen M, et al. Does Corneal Collagen Cross-linking Reduce the Need for Keratoplasties in Patients With Keratoconus? Cornea. 2015;34(9):991-5
12. Russo A, Bonci P, Leonetti P, et al. Long-Term Dehydrated Donor Lamella Survival in Anterior Keratoplasty: Keratocyte Migration and Repopulation of Corneal Stroma. Cornea. 2015;34(9):1044-51
13. Feizi S, Javadi MA, Kanavi MR, Javadi F. Effect of donor graft quality on clinical outcomes after deep anterior lamellar keratoplasty. Cornea. 2014;33(8):795-800
14. Borderie VM, Sandali O, Basli E, Goldschmidt P, Laroche L. Donor tissue selection for anterior lamellar keratoplasty. Cornea. 2013;32(8):1105-9
15. Heindl LM, Riss S, Adler W, et al. Split cornea transplantation: relationship between storage time of split donor tissue and outcome. Ophthalmology. 2013;120(5):899-907
16. Heindl LM, Riss S, Laaser K, et al. Split cornea transplantation for 2 recipients - review of the first 100 consecutive patients. Am J Ophthalmol. 2011;152(4):523-532
17. Lie JT, Monnereau C, Groeneveld-van Beek EA, et al. Dehydration of corneal anterior donor tissue with polyethylene glycol (PEG)-enriched media. Cell Tissue Bank. 2015;16(3):399-409
18. Prazeres TM, Muller RT, Rayes T, Hirai FE, de Sousa LB. Comparison of Descemet-On Versus Descemet-Off Deep Anterior Lamellar Keratoplasty in Keratoconus Patients: A Randomized Trial. Cornea. 2015;34(7):797-801
19. Feizi S, Zare M, Hosseini SB, Kanavi MR, Yazdani S. Donor Descemet-off versus Descemet-on deep anterior lamellar keratoplasty: a confocal scan study. Eur J Ophthalmol. 2015;25(2):90-5

20. Zare M, Feizi S, Hasani H, Silbert D. Comparison of descemet-on versus descemet-off deep anterior lamellar keratoplasty. Cornea. 2013;32(11):1437-40
21. Goyal P, Sureka SP, Das S. Comparison of Descemet-On Versus Descemet-Off Deep Anterior Lamellar Keratoplasty in Keratoconus Patients: A Randomized Trial. Cornea. 2016;35(1):e1. doi: 10.1097/ICO.0000000000000648.
22. Morrison JC, Swan KC. Full-thickness lamellar keratoplasty. A histologic study in human eyes. Ophthalmology. 1982;89(6):715-9.
23. Feilmeier MR, Tabin GC, Williams L, Oliva M. The use of glycerol-preserved corneas in the developing world. Middle East Afr J Ophthalmol. 2010;17(1):38-43
24. Javadi MA, Feizi S, Javadi F, et al. Deep anterior lamellar keratoplasty using fresh versus cryopreserved corneas. Ophthalmol. 2014;121 (2): 610-1.
25. Li J, Yu L, Deng Z, et al. Deep anterior lamellar keratoplasty using acellular corneal tissue for prevention of allograft rejection in high-risk corneas. Am J Ophthalmol. 2011;152(5):762-70.
26. Farias R, Barbosa L, Lima A, et al. Deep anterior lamellar transplant using lyophilized and Optisol corneas in patients with keratoconus. Cornea. 2008;27(9):1030-6
27. Chen W, Lin Y, Zhang X, et al. Comparison of fresh corneal tissue versus glycerin-cryopreserved corneal tissue in deep anterior lamellar keratoplasty. Invest Ophthalmol Vis Sci. 2010;51(2):775-81
28. Daoud YJ, Smith R, Smith T, et al. The intraoperative impression and postoperative outcomes of gamma-irradiated corneas in corneal and glaucoma patch surgery. Cornea. 2011;30(12):1387-91
29. Stevenson W, Cheng S, Emami-Naeini P, et al. Gamma-Irradiation Reduces the Allogenicity of Donor Corneas. Invest Ophthalmol Vis Sci. 2012; 53(11): 7151–7158
30. Utine CA, Tzu JH, Akpek EK. Lamellar keratoplasty using gamma-irradiated corneal lenticules. Am J Ophthalmol. 2011;151(1):170-174
31. Sikder S, McCally RL, Engler C, Ward D, Jun A. Evaluation of irradiated corneas using scatterometry and light and electron microscopy. Cornea. 2011;30:503–7
32. Oh JY, Kim MK, Lee HJ, et al. Processing porcine cornea for biomedical applications. Tissue Eng Part C Methods. 2009;15(4):635-45
33. Lamm V, Hara H, Mammen A, Dhaliwal D, Cooper DK. Corneal blindness and xenotransplantation. Xenotransplantation. 2014 ;21(2):99-11
34. Kim DH, Kim J, Jeong HJ, et al. Biophysico-functional compatibility of Seoul National University (SNU) miniature pig cornea as xenocorneal graft for the use of human clinical trial. Xenotransplantation. 2016;23(3):202-10
35. Hashimoto Y, Funamoto S, Sasaki S, et al. Corneal Regeneration by Deep Anterior Lamellar Keratoplasty (DALK) Using Decellularized Corneal Matrix. PLoS One. 2015;10(7):e0131989.
36. Choi HJ, Lee JJ, Kim MK, et al. Cross-reactivity between decellularized porcine corneal lamellae for corneal xenobridging and subsequent corneal allotransplants. Xenotransplantation. 2014;21(2): 115-23
37. Lee W, Miyagawa Y, Long C, Cooper DK, Hara H. A comparison of three methods of decellularization of pig corneas to reduce immunogenicity. Int J Ophthalmol. 2014 18;7(4):587-93
38. *Zhang MC, Liu X, Jin Y, et al. Lamellar keratoplasty treatment of fungal corneal ulcers with acellular porcine corneal stroma. Am J Transplant. 2015;15(4):1068-75
39. Ward BA, Nesburn AB. An artificial anterior chamber. Am J Ophthalmol 1976;82:796-797
40. Wong DW, Chan WK, Tan DT. Harvesting a lamellar graft from a corneoscleral button: a new technique. Am J Ophthalmol. 1997 May;123(5):688-9
41. Barraquer JI. Lamellar keratoplasty (special techniques).Ann Ophthalmol 1972; 4:437–469

42. Li L, Behrens A, Sweet PM, Osann KE, Chuck RS. Corneal lenticule harvest using a microkeratome and an artificial anterior chamber system at high intrachamber pressure. J Cataract Refract Surg. 2002 May;28(5):860-5
43. Springs CL, Joseph MA, Odom JV, Wiley LA. Predictability of donor lamellar graft diameter and thickness in an artificial anterior chamber system. Cornea. 2002;21(7):696-9
44. Yokogawa H, Tang M, Li Y, et al. Deep Laser-Assisted Lamellar Anterior Keratoplasty With Microkeratome-Cut Grafts. Cornea. 2016;35(5):706-12
45. Coullet J, Fournié P, Malecaze F, Arné JL. Inadequate results for microkeratome-assisted additive stromal keratoplasty for management of keratoconus. J Refract Surg. 2008 Feb;24(2):166-72
46. Yuen LH, Mehta JS, Shilbayeh R, Lim L, Tan DT. Hemi-automated lamellar keratoplasty (HALK). Br J Ophthalmol. 2011;95(11):1513-8
47. Tan DT, Mehta JS. Future directions in lamellar corneal transplantation. Cornea. 2007;26(9 Suppl 1):S21e8. Review.
48. Borderie VM, Werthel AL, Touzeau O, et al. Comparison of techniques used for removing the recipient stroma in anterior lamellar keratoplasty. Arch Ophthalmol. 2008;126(1):31-7
49. Kopani KR, Page MA, Holiman J, et al. Femtosecond laser-assisted keratoplasty: full and partial-thickness cut wound strength and endothelial cell loss across a variety of wound patterns. Br J Ophthalmol. 2014 Jul;98(7):894-9
50. Bahar I, Kaiserman I, McAllum P, Rootman D. Femtosecond laser-assisted penetrating keratoplasty: stability evaluation of different wound configurations. Cornea. 2008;27(2):209-11
51. Zhang C, Bald M, Tang M, Li Y, Huang D. Interface quality of different corneal lamellar-cut depths for femtosecond laser-assisted lamellar anterior keratoplasty. J Cataract Refract Surg. 2015;41(4): 827-35
52. El-Husseiny M, Seitz B, Langenbucher A, et al. Excimer versus Femtosecond Laser Assisted Penetrating Keratoplasty in Keratoconus and Fuchs Dystrophy: Intraoperative Pitfalls. J Ophthalmol. 2015;2015:645830.
53. Resch MD, Zemova E, Marsovszky L, et al. In Vivo Confocal Microscopic Imaging of the Cornea After Femtosecond and Excimer Laser-assisted Penetrating Keratoplasty. J Refract Surg. 2015;31: 620-6.
54. Buratto L, Belloni S, Valeri R. Excimer laser lamellar keratoplasty of augmented thickness for keratoconus. J Refract Surg. 1998;14:517-25.
55. McKee HD, Irion LC, Carley FM, Jhanji V, Brahma AK. Residual corneal stroma in big-bubble deep anterior lamellar keratoplasty: a histological study in eye-bank corneas. Br J Ophthalmol. 2011; 95(10):1463-5
56. Melles GR, Remeijer L, Geerards AJ, et al. A quick surgical technique for deep, anterior lamellar keratoplasty using visco-dissection. Cornea 2000;19:427e32.
57. Hirano K, Sugita J, Kobayashi M. Separation of corneal stroma and Descemet's membrane during deep lamellar keratoplasty. Cornea 2002;21:196e9.
58. Jafarinasab MR, Rahmati-Kamel M, Kanavi MR, Feizi S. Dissection plane in deep anterior lamellar keratoplasty using the big-bubble technique. Cornea. 2010;29(4):388-91
59. Dua HS, Faraj LA, Said DG, Gray T, Lowe J. Human corneal anatomy redefined: a novel pre-Descemet's layer (Dua's layer). Ophthalmology. 2013;120(9):1778-85
60. McKee HD, Irion LC, Carley FM et al. Re: Dua et al.: Human corneal anatomy redefined: a novel pre-Descemet layer (Dua's layer) (Ophthalmology 2013;120:1778-85). Ophthalmology. 2014;121(5): e24-5

61. Dua HS, Mastropasqua L, Faraj L et al. Big bubble deep anterior lamellar keratoplasty: the collagen layer in the wall of the big bubble is unique. Acta Ophthalmol. 2015;93(5):427-30
62. Dua HS, Said DG. Clinical evidence of the pre-Descemets layer (Dua's layer) in corneal pathology. Eye (Lond). 2016 Apr 8. doi: 10.1038/eye.2016.62. [Epub ahead of print]
63. Schlötzer-Schrehardt U, Bachmann BO, Tourtas T, et al. Ultrastructure of the posterior corneal stroma. Ophthalmology. 2015;122(4):693-9
64. Zaki AA, Elalfy MS, Said DG, Dua HS. Deep anterior lamellar keratoplasty--triple procedure: a useful clinical application of the pre-Descemet's layer (Dua's layer). Eye (Lond). 2015;29(3):323-6
65. Schiano-Lomoriello D, Colabelli-Gisoldi RA, Nubile M, et al. Descemetic and predescemetic DALK in keratoconus patients: a clinical and confocal perspective study. Biomed Res Int. 2014;2014: 123156
66. Abdelkader A, Kaufman HE. Descemetic versus pre-descemetic lamellar keratoplasty: clinical and confocal study. Cornea. 2011;30(11):1244-52
67. Marchini G, Mastropasqua L, Pedrotti E, et al. Deep lamellar keratoplasty by intracorneal dissection: a prospective clinical and confocal microscopic study. Ophthalmology. 2006;113(8): 1289-300
68. *Anwar M, Teichmann KD. Big-bubble technique to bare Descemet's membrane in anterior lamellar keratoplasty. J Cataract Refract Surg. 2002;28(3):398-403
69. Anwar HM, Anwar M. Predescemetic dissection for healed hydrops--judicious use of air and fluid. Cornea. 2011;30(12):1502-9
70. Melles GR, Remeijer L, Geerards AJ, Beekhuis WH. A quick surgical technique for deep, anterior lamellar keratoplasty using visco-dissection. Cornea. 2000;19(4):427-32
71. Feizi S, Javadi MA, Daryabari SH.Factors influencing big-bubble formation during deep anterior lamellar keratoplasty in keratoconus. Br J Ophthalmol. 2016;100(5):622-5
72. Goweida MB. Intraoperative review of different bubble types formed during pneumodissection (big-bubble) deep anterior lamellar keratoplasty. Cornea. 2015;34(6):621-4
73. Fontana L, Parente G, Tassinari G. Clinical outcomes after deep anterior lamellar keratoplasty using the big-bubble. Ophthalmol 2007;143:117–24
74. Huang T, Zhang X, Wang Y, et al. Outcomes of deep anterior lamellar keratoplasty using the big-bubble technique in various corneal diseases. Am J Ophthalmol 2012;154:282–9
75. Michieletto P1, Balestrazzi A, Balestrazzi A, et al. Factors predicting unsuccessful big bubble deep lamellar anterior keratoplasty. Ophthalmologica. 2006;220(6):379-82.
76. Caporossi A, Simi C, Licignano R, Traversi C, Balestrazzi A. Air-guided manual deep lamellar keratoplasty. Eur J Ophthalmol. 2004;14(1):55-8
77. Caporossi A, Balestrazzi A, Simi C, Caporossi T, Traversi C. Manual deep lamellar keratoplasty: alternative methods and air-guided technique. Transplant Proc. 2005;37(6):2697-701
78. Smadja D, Colin J, Krueger RR, et al. Outcomes of deep anterior lamellar keratoplasty for keratoconus: learning curve and advantages of the big bubble technique. Cornea. 2012;31(8):859-63
79. Busin M, Scorcia V, Leon P, Nahum Y. Outcomes of Air Injection Within 2 mm Inside a Deep Trephination for Deep Anterior Lamellar Keratoplasty in Eyes With Keratoconus. Am J Ophthalmol. 2016; 164:6-13
80. Feizi S, Faramarzi A, Javadi MA, Jafarinasab MR. Modified big-bubble deep anterior lamellar keratoplasty using peripheral air injection. Br J Ophthalmol. 2014;98(11):1597-600
81. Feizi S, Daryabari SH, Najdi D, Javadi MA, Karimian F. Big-bubble deep anterior lamellar keratoplasty using central vs peripheral air injection: a clinical trial. Eur J Ophthalmol. 2015:0

82. Melles GR, Rietveld FJ, Beekhuis WH, Binder PS. A technique to visualize corneal incision and lamellar dissection depth during surgery. Cornea. 1999;18(1):80-6
83. *Melles GRJ, Lander F, Rietveld FJR, et al. A new surgical technique for deep, anterior lamellar keratoplasty. Br J Ophthalmol. 1999;83:327–33
84. Scorcia V, Lucisano A, Pietropaolo R, et al. Red Reflex-Guided Big-Bubble Deep Anterior Lamellar Keratoplasty: A Simple Technique to Judge Dissection Depth. Cornea. 2015;34(9):1035-8
85. Au J, Goshe J, Dupps WJ Jr, Srivastava SK, Ehlers JP. Intraoperative Optical Coherence Tomography for Enhanced Depth Visualization in Deep Anterior Lamellar Keratoplasty From the PIONEER Study. Cornea. 2015;34(9):1039-43
86. Steven P, Le Blanc C, Lankenau E, et al. Optimising deep anterior lamellar keratoplasty (DALK) using intraoperative online optical coherence tomography (iOCT). Br J Ophthalmol. 2014;98(7): 900-4
87. Ghanem RC, Bogoni A, Ghanem VC. Pachymetry-guided intrastromal air injection ("pachy-bubble") for deep anterior lamellar keratoplasty: results of the first 110 cases. Cornea. 2015;34(6): 625-31
88. Rama P, Knutsson KA, Paganoni G. Response to "Pachymetry-Guided Intrastromal Air Injection ("Pachy-Bubble") for Deep Anterior Lamellar Keratoplasty: Results of the First 110 Cases". Cornea. 2015;34(10):e32
89. Ghanem RC. Pachy-bubble and diamond knife-assisted deep anterior lamellar keratoplasty. J Cataract Refract Surg. 2014;40(8):1398
90. Jabbarvand M, Hashemian H, Khodaparast M, Ghadimi H, Khalilipour E. Femtosecond laser-assisted sutureless anterior lamellar keratoplasty for superficial corneal opacities. J Cataract Refract Surg. 2014;40(11):1805-12
91. Shetty R, Nagaraja H, Veluri H, et al. Sutureless femtosecond anterior lamellar keratoplasty: a 1-year follow-up study. Indian J Ophthalmol. 2014;62(9):923-6
92. Patel AK, Scorcia V, Kadyan A. Microkeratome-assisted superficial anterior lamellar keratoplasty for anterior stromal corneal opacities after penetrating keratoplasty. Cornea. 2012;31(1):101-5
93. Lu Y, Yang L, Ge Y, Chen X, Huang Z. Femtosecond laser-assisted anterior lamellar keratoplasty for the treatment of stromal corneal pathology. BMC Ophthalmol. 2015 Mar 1;15:15
94. Saw VP, Ng T, Crouch R, Maloof AJ. Deep anterior lamellar keratoplasty using the manual dissection technique of Melles: a histopathologic correlation. Cornea. 2006;25(8):882-5
95. Busin M, Zambianchi L, Arffa RC. Microkeratome-assisted lamellar keratoplasty for the surgical treatment of keratoconus. Ophthalmology. 2005;112(6):987-97
96. Busin M, Scorcia V, Zambianchi L, Ponzin D. Outcomes from a modified microkeratome-assisted lamellar keratoplasty for keratoconus. Arch Ophthalmol. 2012;130(6):776-82
97. Fung SS, Aiello F, Maurino V. Outcomes of femtosecond laser-assisted mushroom-configuration keratoplasty in advanced keratoconus. Eye (Lond). 2016;30(4):553-61
98. Monterosso C, Galan A, Böhm E, et al. Effect of 60 kHz and 150 kHz Femtosecond Lasers on Corneal Stromal Bed Surfaces: A Comparative Study. ISRN Ophthalmol. 2013 29;2013:971451
99. Chen Y, Hu DN, Xia Y, et al. Comparison of femtosecond laser-assisted deep anterior lamellar keratoplasty and penetrating keratoplasty for keratoconus. BMC Ophthalmol. 2015;15:144
100. Malta JB, Soong HK, Shtein R, et al. Femtosecond laser-assisted keratoplasty: laboratory studies in eye bank eyes. Curr Eye Res. 2009 Jan;34(1):18-25
101. Shehadeh-Mashor R, Chan CC, Bahar I, et al. Comparison between femtosecond laser mushroom configuration and manual trephine straight-edge configuration deep anterior lamellar keratoplasty. Br J Ophthalmol. 2014;98(1):35-9

102. Bilgihan K, Ozdek SC, Sari A, Hasanreisoğlu B. Excimer laser-assisted anterior lamellar keratoplasty for keratoconus, corneal problems after laser in situ keratomileusis, and corneal stromal opacities. J Cataract Refract Surg. 2006;32:1264-9.
103. Spadea L, Giammaria D, Fiasca A, Verrecchia V. Excimer laser-assisted lamellar keratoplasty for the surgical treatment of keratoconus. J Cataract Refract Surg. 2009;35:105-12.
104. Spadea L, Gizzi R, Evangelista Conocchia N, Urbano S. Optical pachymetry-guided custom excimer laser-assisted lamellar keratoplasty for the surgical treatment of keratoconus. J Cataract Refract Surg. 2012;38:1559-67.
105. *van Dijk K, Parker J, Tong CM, et al. Midstromal isolated Bowman layer graft for reduction of advanced keratoconus: a technique to postpone penetrating or deep anterior lamellar keratoplasty. JAMA Ophthalmol. 2014 1;132(4):495-501
106. van Dijk K, Liarakos VS, Parker J, et al. Bowman layer transplantation to reduce and stabilize progressive, advanced keratoconus. Ophthalmology. 2015;122(5):909-17
107. Luceri S, Parker J, Dapena I, et al. Corneal Densitometry and Higher Order Aberrations After Bowman Layer Transplantation: 1-Year Results. Cornea. 2016;35(7):959-66
108. Lie J, Droutsas K, Ham L, et al. Isolated Bowman layer transplantation to manage persistent subepithelial haze after excimer laser surface ablation. J Cataract Refract Surg. 2010 Jun;36(6): 1036-41
109. Groeneveld van-Beek, Parker J, Lie J, et al. Donor Tissue Preparation for Bowman Layer Transplantation. Cornea. In press

SPECIAL / ANNOTATED REFERENCES

1. Parker JS, van Dijk K, Melles GR. Treatment options for advanced keratoconus: A review. Surv Ophthalmol. 2015;60(5):459-8
This article represents a recent, comprehensive overview of the existing surgical treatments for keratoconus, and compiles nearly all the published data regarding the surgical outcomes of DALK.
3. *Eye Bank Association of America. 2014 Eye Banking Statistical Report. 2016
This report provides the best data regarding recent trends in corneal transplantation
38. *Zhang MC, Liu X, Jin Y, et al. Lamellar keratoplasty treatment of fungal corneal ulcers with acellular porcine corneal stroma. Am J Transplant. 2015;15(4):1068-75
The first large-scale, successful study of the use of acellular porcine corneal tissue for human use.
68. *Anwar M, Teichmann KD. Big-bubble technique to bare Descemet's membrane in anterior lamellar keratoplasty. J Cataract Refract Surg. 2002;28(3):398-403
The original big-bubble technique, described
83. *Melles GRJ, Lander F, Rietveld FJR, et al. A new surgical technique for deep, anterior lamellar keratoplasty. Br J Ophthalmol. 1999;83:327–33
The original Melles manual dissection technique, described
105. *van Dijk K, Parker J, Tong CM, et al. Midstromal isolated Bowman layer graft for reduction of advanced keratoconus: a technique to postpone penetrating or deep anterior lamellar keratoplasty. JAMA Ophthalmol. 2014 1;132(4):495-501
This article reports the first results with BL transplantation.

Chapter 6

Descemet Membrane Endothelial Keratoplasty (DMEK): A Review

Jack Parker[1-3], John S. Parker[3], and Gerrit R.J. Melles[1,2,4]

[1]Netherlands Institute for Innovative Ocular Surgery, Rotterdam, The Netherlands; [2]Melles Cornea Clinic Rotterdam, The Netherlands; [3]UAB Callahan Eye Hospital, Birmingham, Alabama; [4]Amnitrans EyeBank Rotterdam, The Netherlands.

ABSTRACT

Descemet Membrane Endothelial Keratoplasty (DMEK) is the most recent step forward in the evolution of endothelial keratoplasty toward thinner grafts and more natural, anatomic corneal restoration. Offering unprecedented visual results and requiring no special or expensive equipment, DMEK has the potential to become the first line treatment for corneal endothelial disorders. The surgery's perceived shortcomings (primarily technical difficulty) have mostly been addressed by new "no-touch" procedures for both graft preparation and graft unfolding in the recipient eye. And as a result, DMEK has been gaining traction with ophthalmologists the world over. Now, in its most recent formulation, DMEK is ready for the typical corneal surgeon, in any clinical setting, and at low cost.

KEYWORDS: Descemet membrane endothelial keratoplasty, posterior lamellar keratoplasty, corneal transplantation, endothelium, surgical technique

INTRODUCTION

For almost 100 years, Penetrating Keratoplasty (PK) was the mainstay of therapy for patients with corneal endothelial disorders.[1] That changed in 1998 with the introduction of Posterior Lamellar Keratoplasty (PLK),[2-4] later popularized in the United States as Deep Lamellar Endothelial Keratoplasty (DLEK).[5-7] Selectivity was the new technique's primary advantage. By replacing only the inner aspect of the cornea, many of the suture, astigmatism, and wound healing problems of PK disappeared. But while effective, DLEK ultimately proved too technically challenging for widespread adoption. So, the surgery was simplified, giving rise to Descemet Stripping (Automated) Endothelial Keratoplasty (DS(A)EK).[8-11] And within five years, this modified technique became the global treatment of choice for corneal endothelial disorders. Still, few patients after DS(A)EK achieved best corrected visual acuities (BCVAs) exceeding 20/25. Probably, the graft's layer of attached stroma was to blame, which thickened the cornea and seemed to undermine its optical performance.[12-16]

A stroma-less graft was the solution, arriving in 2006 in the form of Descemet Membrane Endothelial Keratoplasty (DMEK).[17-19] With a transplant composed solely of isolated Descemet membrane (and its endothelium), DMEK slashed graft thickness by 75% compared to DS(A)EK, from 80 microns down to 20. The results were dramatic: almost 80% of patients reached ≥20/25 within 6 months after surgery.[12,20,21]

Recently, DMEK has been refined into a standardized "no-touch" procedure, ready for the typical corneal surgeon in any clinical setting and at low cost.[22] Compared to its predecessors (DSEK, DLEK, and their variations), DMEK provides better and faster visual recovery, usually with no additional complications. It is therefore poised to become the first-line option for corneal endothelial disorders worldwide.[23]

PREOPERATIVE PREPARATION OF THE DMEK GRAFT

Ideally, DMEK grafts are prepared in an eye bank, 1-2 weeks before surgery. There, the tissue undergoes several rounds of additional screening. Principally, this consists of evaluating the cell density and morphology of the donor endothelium. Grafts which appear abnormal under the microscope – those with scarce or atypical cells, suspicious for being dysfunctional – are discarded, raising the quality of the pool of tissue for transplant. Preparing the grafts weeks in advance also adds convenience: it saves time and safeguards against unexpected tissue shortage on the day of surgery.[24]

On the other hand, some ophthalmologists may prefer to create the grafts themselves, in the operating room, just before surgery.[25] This is especially true in the United States, where few eye banks currently supply ready-to-use DMEK tissue. Each graft takes 30

minutes to prepare, and all the steps are the same, whether in the operating room or the eye bank.

The initially described DMEK graft harvesting technique consisted of stripping Descemet membrane from a corneo-scleral rim submerged in saline. This method was proven safe and reproducible, with <5% tissue loss due to inadvertent tearing, and – surprisingly – no significant endothelial cell damage.[24-28] Recently, the process was upgraded to a "no-touch" procedure, making the preparation both safer and easier.[29] As a bonus, the anterior portion of the corneas left over from creating the DMEK grafts (with the Descemet membrane stripped off, but otherwise intact) can be used for Deep Anterior Lamellar Keratoplasty (DALK). This added benefit applies only to DMEK, because DS(A)EK preparation – by incorporating some of the posterior stroma into the graft – mangles the corneal remains, leaving them less suitable for transplant.[29-31]

DMEK SURGICAL TECHNIQUE

The standardized no-touch technique for DMEK was published by Dapena et al in 2011.[22] In brief, a 3.0mm clear-cornea tunnel incision is made at the 12 o'clock position with a slit knife, followed by the creation of three side-ports using a surgical knife at 10:30, 1:30, and 7:30 (right eye) or 4:30 (left eye). Under air, the recipient's Descemet membrane is first scored 360 degrees then stripped from the posterior stroma using a reversed Sinskey hook (Catalogue no 50.1971B, D.O.R.C. International, Zuidland, The Netherlands). The DMEK graft is thoroughly rinsed with balanced salt solution (BSS, Alcon Nederland BV, Gorinchem, The Netherlands) and stained twice with trypan blue 0.06% (Catalogue no VBL.10S.USA, Vision blue™; D.O.R.C. International) to enhance its visibility in the recipient anterior chamber. Already curled into a roll due to the inherent elastic properties of the membrane itself, the graft may be nudged into a "double roll" configuration by applying a flow of BSS directly across its surface.[22]

After staining, the DMEK double-roll is sucked into a custom-made glass pipette (D.O.R.C. International), then injected into the recipient anterior chamber through the 12 o'clock incision "hinge down" so that the double roll faces upward. Once the graft has been inserted, its orientation can be checked (and verified as properly "hinge down") through the use of the Moutsouris sign, whereby the tip of a 30G cannula, positioned atop the edge of the graft, will turn blue if it is embraced by an upward facing roll. If the tip does not turn blue, then the roll must be facing down, and therefore the graft is upside down, which can be corrected by gently flushing it within the anterior chamber (**Figure 1**).[22]

With the graft properly oriented, it may be unfolded by injecting a small air bubble in between the double rolls, then stroking the surface of the cornea to move the bubble

and spread out the graft (Dapena technique). Once it has been fully unfolded, the graft is fixed against the recipient posterior stroma by completely filling the anterior chamber with air for a period of one hour. Afterwards, the air fill is reduced to 30-50%, and the patient is instructed to remain supine for 24 hours.[22]

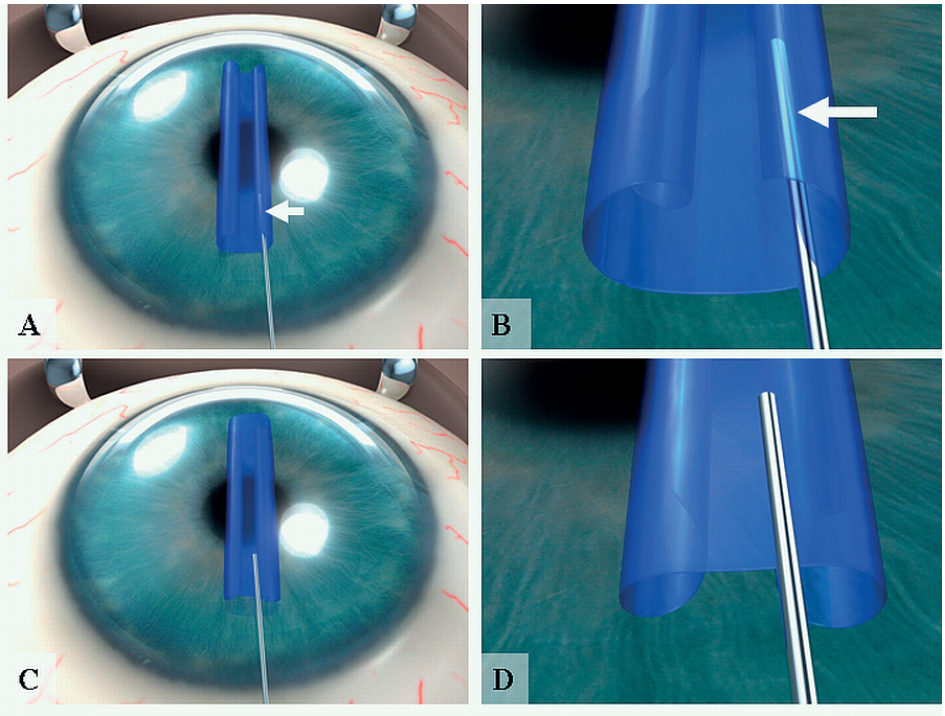

Figure 1. Artist rendering of the *Moutsouris sign*. (A and B) When the DMEK-graft is oriented correctly within the anterior chamber (double roll upward), the tip of the cannula can be positioned 'inside' a peripheral curl, so that the tip appears blue (arrows) because of the overlying blue tinted donor tissue (Moutsouris sign positive). (C and D) When the graft is positioned 'upside-down' (double roll downward), the tip of the cannula does not 'find' the curls, so the tip will not change in color (Moutsouris sign negative). [This figure has been published previously in Dapena et al. Arch Ophthalmol. 2011;129(1):88-94]

Variations on DMEK surgery do exist, however, with DMAEK and DMEK-S being the most prominent examples.[32-35] These differ from regular DMEK in that a stromal rim is left attached to the periphery of the graft during preparation, which allows grasping and a "drag-and-drop" insertion method. Otherwise, the surgery is the same.

RESULTS

Visual Acuity

After DMEK, 77% of eyes may achieve a BCVA ≥20/25 at 6 months, with 50% ≥20/20. Visual rehabilitation is frequently fast, not uncommonly rebounding to 20/20 within the first post-operative week, and with most patients reaching their final BCVA within 1-3 months.[19,22,23,26] (DMAEK and DMEK-S, likewise, seem to offer similarly good results.[35,36])

No other form of corneal transplantation offers comparable outcomes. After PK, less than 50% of patients achieve visions of ≥20/40, and then only at 1 year.[37] Following DS(A)EK, the average vision at 6 months is 20/40, rarely reaching 20/25 or better.[12-16] Tellingly, in those patients with poor vision after DSEK, many dramatically improve with a re-operation to replace their DSEK graft with a DMEK **(Figure 2)**.[38] Moreover, in people with one eye operated with each technique – one eye DSEK, one eye DMEK – overwhelmingly, they prefer the vision in their DMEK eye.[39]

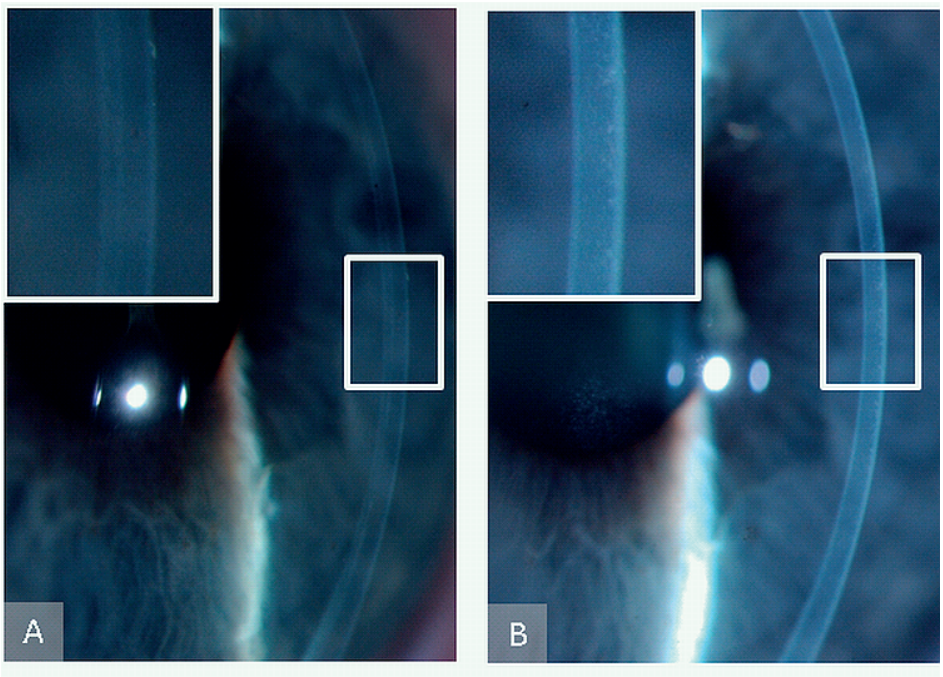

Figure 2. (A) Slit-lamp photograph 1 year after DSEK. Despite complete corneal clearance and minimal interface opacity, the patient's BCVA never improved beyond 20/100. Image (B) shows the same eye following a secondary DMEK for reasons of low visual acuity. After DMEK, vision improved to 20/25 at 1 month post-operatively.

Refractive Change and Stability

After DMEK, both the spherical equivalent (SE) and cylindrical error are frequently within 1.0D of the pre-operative refractive error. Pachymetric and refractive data show that the transplanted cornea stabilizes 3 months after surgery, at which point new glasses may be prescribed. Until then, most patients are able to wear their current prescription.[23]

Endothelial Cell Density

Most DMEK grafts show a ±30% reduction in cell density 6 months after surgery. Thereafter, cell density falls at a steady, predictable rate – at about 10% per year.[26,40-42] Interestingly, the transition to an entirely no-touch technique has had no effect on the measured "cell-loss" after DMEK.[22] The strong implication is that mechanical damage during transplantation cannot be the cause. More likely, the rapid fall in cell density after surgery reflects a decline in cellular concentration – not number – as the endothelial cells migrate out from the graft onto peripheral parts of the patient's posterior stroma.

Cell density measurements after DS(A)EK are almost identical, with a sharp ±30% drop-off in the first 6 months, followed by a regular decline of nearly 10% per year.[43-45]

A much larger decline is evident after PK, however, in which grafts commonly lose upwards of 40-55% within the first post-operative year. In addition, the rate of decline never appears to stabilize at a lower level, as with DS(A)EK and DMEK.[46-48]

COMPLICATIONS

Graft Detachment

Graft detachment is the most common complication following all forms of endothelial keratoplasty. With DS(A)EK, this may occur in 0-82% of surgeries.[11,49-51] Similarly, detachment rates of 20-60% have been reported after DMEK, although many of these cases do not appear to be clinically significant.[22,35,52-54] Frequently, DMEK detachments are small, peripheral, and temporary. And even when the detached areas are both large and central, some patients nevertheless achieve BCVAs ≥20/40. In our own series, clinically significant detachments – those which reduced the patient's vision and/or required re-intervention – occurred in 10% of eyes. Risk factors might include surgical inexperience, failing to completely unfold the donor membrane during surgery, implanting the graft upside down, the use of intra-ocular viscoelastics, use of plastic materials (rather than glass) to inject the tissue into the recipient anterior chamber, insufficient air-bubble support after surgery, and the use of Optisol rather than organ culture medium for graft storage pre-operatively.[52-55]

Management depends on the size of the detachment. Small detachments (less than one-third of the graft area) resolve spontaneously and rarely, if ever, require re-

intervention. Larger detachments, however, have more variable outcomes, complicating the management decision tree. In general, even with large detachments (greater than one-third of the graft area), most corneas eventually clear, although over a longer time period and then only 50% of patients achieve vision ≥20/40. Because a satisfactory visual result may occur half the time after a large detachment without any subsequent intervention, reoperation – either with re-grafting or re-bubbling – ought to be an individualized decision, tailored to the patient's preferences (i.e. for more surgery, in light of the possibility of better vision).[52-55]

Allograft rejection

Two years after DMEK, the allograft rejection rate is ≤1%. This is considerably lower than the reported rate after PK (5-15% in "low-risk" cases), and also lower than after DS(A)EK (10%).[23,37,56-58] Likely, the explanation lies in DMEK's thinner, stroma-less graft, which may be less immunogenic because it presents fewer antigens to the recipient's immune system.[23,57]

Secondary glaucoma

Because runaway pressures threaten both the survival of the graft and the health of the optic nerve, glaucoma is among the most important potential complications of any form of corneal transplantation. Reported rates after PK and DS(A)EK commonly range from 15-35%, but sometimes as high as 60% depending on the patient population and the steroid regimen.[59-62] Because the risk of allograft rejection after DMEK is relatively low, a lighter, less intense, steroid schedule is possible. (Specifically, we use 0.1% topical dexamethasone for just the first postoperative month, then switch to fluoromethalone thereafter.) Perhaps as a consequence, the reported rate of glaucoma is small – just 6.5% at 2 years. Most cases arise in eyes with a pre-existing history of pressure trouble, with relatively few "new" cases after surgery.[63]

Two additional factors may contribute to DMEK's low rate of secondary glaucoma. First, most patients receiving a DMEK for Fuchs Dystrophy are Caucasian, a population thought to be at lower risk. Second, one week prior to surgery, a peripheral iridotomy is made at the 12 o'clock position to prevent the development of a pupillary block glaucoma.[63]

DMEK IN PHAKIC EYES

DMEK is safe for phakic eyes, although several additional protective steps are required. Just prior to transplant, the pupil should be constricted with 2% pilocarpine to protect the lens from accidental damage during surgery, either from air-bubble or instrument

induced trauma. Even so, 25% of phakic eyes may present with mild anterior subcapsular lens opacities or a Vossius ring (iris pigment imprint on the outer lens capsule). Usually, these pigment deposits disappear with time and do not affect final visual acuity. The rate of iatrogenic cataract formation necessitating phacoemulsification is reported at 4% at 2 years.[64,65]

As a precaution, the size of the air bubble left behind in the anterior chamber after DMEK surgery ought to be reduced in phakic eyes, from 50% down to 30%. This may help prevent a mechanical angle closure glaucoma from developing (arising when a large air bubble presses against the lens, causing the lens to tilt forward and compress the angle).[65]

FUTURE DIRECTIONS

Steadily, reports have been accumulating of corneas with detached grafts (after both DMEK and DS(A)EK) that nevertheless clear.[66,67] When these corneas are viewed with specular and confocal microscopy, endothelial cells are clearly visible populating the recipient's posterior stroma **(Figure 3)**. The prevailing speculation is that endothelial migration is responsible for this phenomenon, either by the donor cells, or host cells, or both.[68-70] If widespread cell migration does indeed occur, then a simplified procedure, tentatively named "free-DMEK" or "Descemet Membrane Endothelial Transfer" (DMET) – in which the donor tissue is merely injected into the recipient anterior chamber after descemetorhexis – could be effective in the management of corneal endothelial disease.[71] The advantages of this surgery, even over DMEK, would be enormous: perfect anatomical restoration, complete visual recovery, elimination of virtually all intra- and post-operative complications associated with endothelial keratoplasty, and an enormous reduction in the required surgical skills. Pending further study, DMET has the potential to become the preferred "no-keratoplasty" treatment for corneal endothelial disorders.

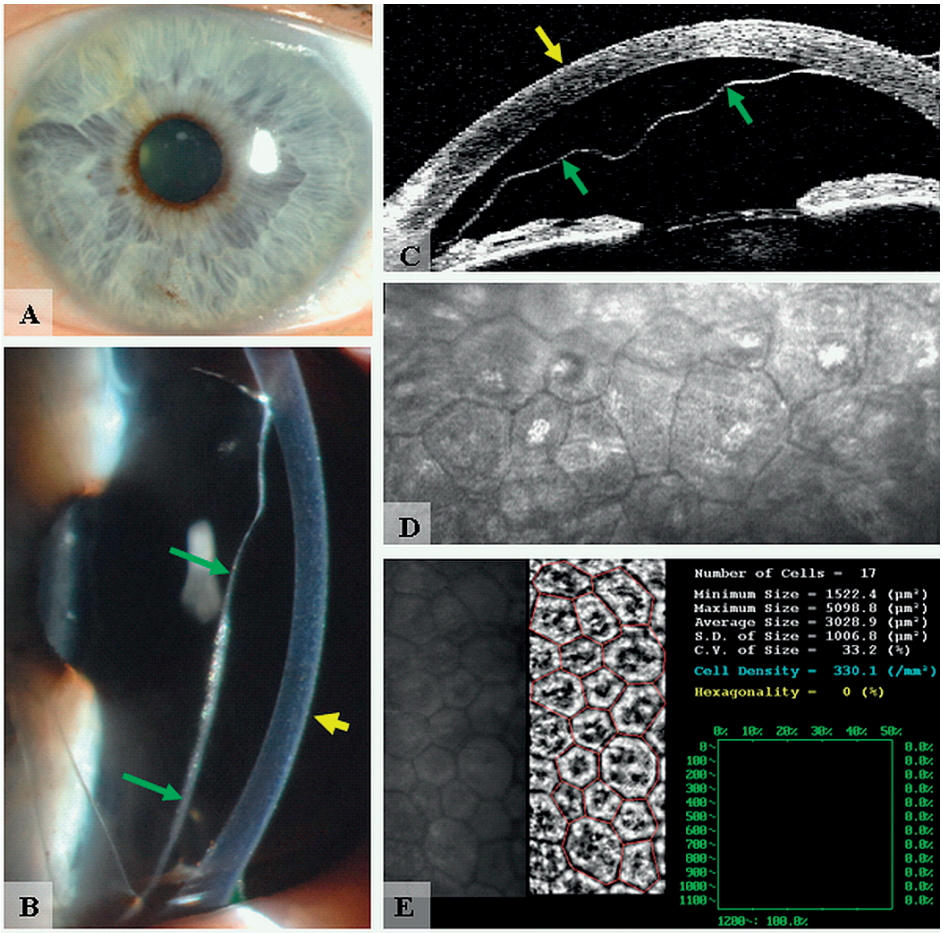

Figure 3. Slit-lamp photographs after DMEK (A, B) showing a clear cornea (yellow arrows) above a large centrally detached graft (green arrows).OCT demonstrates normal corneal thickness above the detachment (C), and confocal (D) and specular microscopy (E) reveal the presence of endothelial cells populating the recipient's posterior stroma in the detached area.

REFERENCES

1. Terry MA, "Endothelial Keratoplasty: Why aren't we all doing Descemet membrane endothelial keratoplasty?" Cornea, 2012 Feb 23. [Epub ahead of print].
2. Melles GRJ, Eggink FAGJ, Lander F, et al, A surgical technique for posterior lamellar keratoplasty, Cornea, 1998;17:618-26.
3. Melles GR, Lander F, Beekhuis WH, et al, Posterior lamellar keratoplasty for a case of pseudophakic bullous keratopathy, Am J Ophthalmol, 1999;127:340-1.
4. Melles GR, Lander F, Nieuwendaal C, Sutureless, posterior lamellar keratoplasty: A case report of a modified technique, Cornea, 2002;21:325-7.
5. Terry MA, Ousley PJ, Deep lamellar endothelial keratoplasty in the first United States patients: early clinical results, Cornea, 2001;20:239-43.
6. Terry MA, Ousley PJ, Deep lamellar endothelial keratoplasty visual acuity, astigmatism, and endothelial survival in a large prospective series, Ophthalmology, 2005;112:1541-8.
7. Ousley PJ, Terry MA, Stability of vision, topography, and endothelial cell density from 1 year to 2 years after deep lamellar endothelial keratoplasty surgery, Ophthalmology, 2005;112:50-7.
8. Melles GR, Wijdh RH, Nieuwendaal CP, A technique to excise the Descemet membrane from a recipient cornea (descemetorhexis), Cornea, 2004;23:286-8.
9. Price FW Jr, Price MO, Descemet's stripping with endothelial keratoplasty in 50 eyes: a refractive neutral corneal transplant, J Refract Surg, 2005;21:339-45.
10. Azar DT, Jain S, Sambursky R, Strauss L, Microkeratome-assisted posterior keratoplasty, J Cataract Refract Surg, 2001;27:353-6.
11. Gorovoy MS, Descemet-stripping automated endothelial keratoplasty, Cornea, 2006;25:886-9.
12. Dapena I, Ham L, Melles GRJ, Endothelial Keratoplasty: DSEK/DSAEK or DMEK – the thinner the better? Curr Opin Ophthalmol, 2009;20:299-307.
13. Bahar I, Kaiserman I, McAllum P, et al, Comparison of posterior lamellar keratoplasty techniques to penetrating keratoplasty, Ophthalmology, 2008;115:1525-33.
14. Chen ES, Terry MA, Shamie N, et al, Descemet-stripping automated endothelial keratoplasty: six month results in a prospective study of 100 eyes, Cornea, 2008;27:514-20.
15. Mearza AA, Qureshi MA, Rostron CK, Experience and 12-month results of Descemet-stripping endothelial keratoplasty (DSEK) with a small-incision technique, Cornea, 2007;26:279-83.
16. Terry MA, Shamie N, Chen ES, et al, Precut tissue for Descemet's stripping automated endothelial keratoplasty: Vision, astigmatism, and endothelial survival, Ophthalmology, 2009;116:248-56.
17. Melles GR, Lander F, Rietveld FJ, Transplantation of Descemet's membrane carrying viable endothelium through a small scleral incision, Cornea, 2002;21:415-8.
18. Melles GR, Ong TS, Ververs B, van der Wees J, Descemet membrane endothelial keratoplasty (DMEK), Cornea, 2006;25:987-90.
19. Melles GR, Ong TS, Ververs B, van der Wees J, Preliminary clinical results of Descemet membrane endothelial keratoplasty, Am J Ophthalmol, 2008;145:222-7.
20. Melles GR, Posterior lamellar keratoplasty: DLEK to DSEK to DMEK, Cornea, 2006;25:879-81.
21. Fernandez MM, Afshari NA, Endothelial Keratoplasty: From DLEK to DMEK, Middle East Afr J Ophthalmol, 2010;17:5-8.
22. Dapena I, Moutsouris K, Droutsas K, et al, Standardized 'no touch' technique for Descemet membrane endothelial keratoplasty (DMEK), Arch Ophthalmol, 2011;129:88-94.

23. Dirisamer M, Ham L, Dapena I, et al, Efficacy of Descemet membrane endothelial keratoplasty (DMEK): Clinical outcome of 200 consecutive cases after a 'learning curve' of 25 cases, Arch Ophthalmol, 2011;129:1435-43.
24. Lie JT, Birbal R, Ham L et al, Donor tissue preparation for Descemet membrane endothelial keratoplasty, J Cataract Refract Surg, 2008;34:1578-83.
25. Kruse FE, Laaser K, Cursiefen C, et al, A stepwise approach to donor preparation and insertion increases safety and outcome of Descemet membrane endothelial keratoplasty, Cornea, 2011;30: 580-7.
26. Price MO, Giebel AW, Fairchild KM, Price FW Jr, Descemet's membrane endothelial keratoplasty: prospective multicenter study of visual and refractive outcomes and endothelial survival, Ophthalmology, 2009; 116:2361-8.
27. Zhu Z, Rife L, Yiu S, et al, Technique for preparation of the corneal endothelium-Descemet membrane complex for transplantation, Cornea, 2006;25:705-8.
28. Ignacio TS, Nguyen TT, Sarayba MA, et al, A technique to harvest Descemet's membrane with viable endothelial cells for selective transplantation, Am J Ophthalmol, 2005;139:325-30.
29. Groeneveld-van Beek E, Lie J, van der Wees J, et al., Standardized 'no-touch' donor tissue preparation for DALK and DMEK: Harvesting undamaged anterior and posterior transplants from the same donor cornea, Acta Ophthalmolo 2012; In press.
30. Heindl LM, Riss S, Laaser K, et al, Split cornea transplantation for 2 recipients - review of the first 100 consecutive patients, Am J Ophthalmol, 2011;152:523-32.
31. Lie JT, Groeneveld-van Beek EA, Ham L, et al, More efficient use of donor corneal tissue with Descemet membrane endothelial keratoplasty (DMEK): two lamellar keratoplasty procedures with one donor cornea, Br J Ophthalmol, 2010;94:1265-6.
32. Kymionis GD, Yoo SH, Diakonis VF, et al, Automated donor tissue preparation for Descemet membrane automated endothelial keratoplasty (DMAEK): An Experimental Study, Ophthalmic Surg Lasers Imaging, 2011;42:158-61.
33. McCauley MB, Price FW, Price MO, Descemet membrane automated endothelial keratoplasty: hybrid technique combining DSAEK stability with DMEK visual results, J Cataract Refract Surg, 2009;35:1659-64.
34. Studeny P, Farkas A, Vokrojova M, et al, Descemet membrane endothelial keratoplasty with a stromal rim (DMEK-S), Br J Ophthalmol, 2010;94:909-14.
35. Guerra FP, Anshu A, Price MO, et al, Descemet's membrane endothelial keratoplasty prospective study of 1-Year visual outcomes, graft survival, and endothelial cell loss, Ophthalmology, 2011; 118:2368-73.
36. McCauley MB, Price MO, Fairchild KM, et al, Prospective study of visual outcomes and endothelial survival with Descemet membrane automated endothelial keratoplasty, Cornea, 2011;30:315-9.
37. Williams KA, Muehlberg SM, Lewis RF, et al, How successful is corneal transplantation? A report from the Australian Corneal Graft Register, Eye, 1995;9:219-27.
38. Ham L, Dapena I, van der Wees J, Melles GR, Secondary DMEK for poor visual outcome after DSEK: donor posterior stroma may limit visual acuity in endothelial keratoplasty, Cornea, 2010;29: 1278-83.
39. Guerra FP, Anshu A, Price MO, Price FW, Endothelial keratoplasty: fellow eyes comparison of Descemet stripping automated endothelial keratoplasty and Descemet membrane endothelial keratoplasty, Cornea, 2011;30:1382-6.
40. Dapena I, Dapena L, Dirisamer M, et al, Visual acuity and endothelial cell density following Descemet membrane endothelial keratoplasty (DMEK), Arch Soc Esp Oftalmol, 2011;86:395-401.

41. Ham L, Dapena I, van der Wees J, Melles GR, Endothelial cell density after Descemet membrane endothelial keratoplasty: 1- to 3-year follow-up, Am J Ophthalmol, 2010;149:1016-7.
42. Parker J, Dirisamer M, Naveiras M, et al, Endothelial cell density after Descemet membrane endothelial keratoplasty: 4-year follow-up, Am J Ophthalmol, 2011;151:1107.
43. Price MO, Fairchild KM, Price DA, et al, Descemet's stripping endothelial keratoplasty five-year graft survival and endothelial cell loss, Ophthalmology, 2011;118:725-9.
44. Price FW Jr, Price MO, Does endothelial cell survival differ between DSEK and standard PK?, Ophthalmology, 2009;116:367-8.
45. Price MO, Price FW Jr, Endothelial cell loss after Descemet stripping with endothelial keratoplasty influencing factors and 2-year trend, Ophthalmology, 2008;115:857-65.
46. Borderie VM, Boëlle PY, Touzeau O, et al, Predicted long-term outcome of corneal transplantation, Ophthalmology, 2009;116:2354-60.
47. Patel SV, David O, Hodge MS, Bourne WM, Corneal endothelium and postoperative outcomes 15 years after penetrating keratoplasty, Am J Ophthalmol, 2005;139:311-9.
48. Ing JJ, Ing HH, Nelson LR, et al, Ten-year postoperative results of penetrating keratoplasty, Ophthalmology,1998;105:1855-65.
49. Busin M, Bhatt PR Scorcia V, A modified technique for Descemet membrane stripping automated endothelial keratoplasty to minimize endothelial cell loss, Arch Ophthalmol, 2008;126:1133-7.
50. Koenig SB, Covert DJ, Early results of small-incision Descemet stripping and automated endothelial keratoplasty, Ophthalmology, 2007;114:221-6.
51. Terry MA, Shamie N, Chen ES, et al, Endothelial keratoplasty a simplified technique to minimize graft dislocation, iatrogenic graft failure, and pupillary block, Ophthalmology, 2008;115:1179-86.
52. Dapena I, Moutsouris K, Ham L, Melles GR, Graft detachment rate, Ophthalmology, 2010;117:847.
53. Dirisamer M, van Dijk K, Dapena I, et al, Prevention and management of graft detachment in Descemet membrane endothelial keratoplasty (DMEK), Arch Ophthalmol, 2012;130:280-91.
54. Dapena I, Ham L, Droutsas K, et al, Learning curve in Descemet's membrane endothelial keratoplasty: First series of 135 consecutive cases, Ophthalmology, 2011;118:2147-54.
55. Laaser K, Bachmann BO, Horn FK, et al, Donor tissue culture conditions and outcome after descemet membrane endothelial keratoplasty, Am J Ophthalmol, 2011;151:1007-18.
56. Anshu A, Price MO, Price FW Jr, Risk of corneal transplant rejection significantly reduced with Descemet's membrane endothelial keratoplasty, Ophthalmology, 2012;119:536-40.
57. Dapena I, Ham L, Netukova M, et al, Incidence of early allograft rejection following Descemet membrane endothelial keratoplasty (DMEK), Cornea, 2011;30:1341-45.
58. Li JY, Terry MA, Goshe J, et al, Graft rejection after Descemet's stripping automated endothelial keratoplasty: graft survival and endothelial cell loss, Ophthalmology, 2012;119:90-4.
59. Vajaranant TS, Price MO, Price FW, Visual acuity and intraocular pressure after Descemet's stripping endothelial keratoplasty in eyes with and without preexisting glaucoma, Ophthalmology, 2009; 116:1644-50.
60. Erdurmus M, Cohen EJ, Yildiz EH, et al, Steroid-induced intraocular pressure elevation or glaucoma after penetrating keratoplasty in patients with keratoconus or Fuchs dystrophy, Cornea, 2009;28:759-64.
61. Greenlee EC, Kwon YH, Graft failure: III. glaucoma escalation after penetrating keratoplasty, Int Ophthalmol, 2008;28:191-207.
62. Allen MB, Lieu P, Mootha VV, et al, Risk factors for intraocular pressure elevation after Descemet stripping automated endothelial keratoplasty, Eye Contact Lens, 2010;36:223-7.

63. Naveiras M, Dirisamer, Parker J, et al, Causes of glaucoma after Descemet membrane endothelial keratoplasty (DMEK), Am J Ophthalmol, 2012, Epub
64. Dapena I, Ham L, Tabak S, et al, Phacoemulsification after Descemet membrane endothelial keratoplasty, J Cataract Refract Surg, 2009;35:1314-5.
65. Parker J, Dirisamer M, Naveiras M, et al,Outcomes of Descemet membrane endothelial keratoplasty in phakic eyes, J Cataract Refract Surg, 2012, in Press.
66. Price FW Jr, Price MO, Comment on 'Spontaneous corneal clearance despite graft detachment after descemet membrane endothelial keratoplasty', Am J Ophthalmol, 2010;149:173-4; author reply 174-5.
67. Zafirakis P, Kymionis GD, Grentzelos MA, Livir-Rallatos G, Corneal graft detachment without corneal edema after Descemet stripping automated endothelial keratoplasty, Cornea, 2010;29: 456-8.
68. Jacobi C, Zhivov A, Korbmacher J, et al, Evidence of endothelial cell migration after Descemet membrane endothelial keratoplasty, Am J Ophthalmol, 2011;152:537-42.
69. Lagali N, Stenevi U, Claesson, M, et al, Donor and recipient endothelial cell population of the transplanted human cornea: a two-dimensional imaging study, Invest Ophthalmol Vis Sci, 2010; 51:1898-1904.
70. Stewart RM, Hiscott PS, Kaye SB, Endothelial migration and new Descemet membrane after endothelial keratoplasty, Am J Ophthalmol, 2010;149:683; author reply 683-4.
71. Dirisamer M, Yeh RY, van Dijk K, et al, First series of Descemet membrane endothelial transfer (DMET) suggests recipient endothelium contributes to corneal clearance, Am J Ophthalmol; In press.

Chapter 7

Endothelial cell density after Descemet membrane endothelial keratoplasty: 1-4 year follow-up

Jack Parker;[1-3] Martin Dirisamer, MD;[1,2,4] Miguel Naveiras, MD;[1,2] Lisanne Ham, MSc;[1,2] Jacqueline van der Wees, PhD;[1,5] Gerrit R.J. Melles, MD; PhD[1,2,5]

[1]Netherlands Institute for Innovative Ocular Surgery, Rotterdam, The Netherlands; [2]Melles Cornea Clinic Rotterdam, The Netherlands; [3]Callahan Eye Foundation Hospital, Birmingham, Alabama; [4]Department of Ophthalmology, AKH Linz, Austria; [5]Amnitrans EyeBank, Rotterdam, The Netherlands.

KEYWORDS: Endothelium, Descemet membrane endothelial keratoplasty, posterior lamellar keratoplasty, corneal transplantation, Descemet membrane, surgical technique

'Descemet membrane endothelial keratoplasty' (DMEK) is one of several surgical options for patients with corneal endothelial disorders.[1] 'Deep lamellar keratoplasty'(DLEK) and 'Descemet stripping (automated) endothelial keratoplasty (DSEK/DSAEK) are alternative therapies, and early follow-up data have shown that endothelial cell densities (ECDs) in grafted tissue may be similar in these patients to those treated with DMEK.[1-3] Previously, we reported the ECDs in 58 patients 1-3 years after DMEK.[2] In the current study, we continued and expanded our analysis on mid-term ECDs after DMEK as a measure of long-term Descemet graft survival.

From a larger group of 225 consecutive patients who underwent DMEK for Fuchs endothelial dystrophy or pseudophakic bullous keratopathy, ECD measurements were available in 186 eyes with 6 months follow-up; 80 also had 12 months follow-up; 49 had 24 months follow-up, 13 had 36 months follow-up, and 6 had 48 months follow-up **(Supplemental Figure ; Supplemental Table; Supplemental Material at AJO.com).**

Our findings support a 34% sharp decrease in ECD in the first 6 months after DMEK, followed by a slower decrease of about 9% per year sustained over 4 years. This result closely resembles previous reports of 34% decrease in ECD within 6 months after DSEK, followed by a 8% decrease between 6 to 24 months.[2,4,5] Our updated data showed that the similarity between ECDs in patients after DMEK and earlier types of endothelial keratoplasty is robust over a larger period of time and with a greater number of patients than has been previously reported.[2,4-6] This, combined with evidence that more than three-fourths of patients achieve visual acuities >20/25 six months after surgery, may indicate that DMEK could become a preferred treatment method in corneal endothelial disease.[1]

ACKNOWLEDGMENTS / DISCLOSURE

1. Funding / Support – None
2. Financial Disclosures – Dr Melles is a consultant for D.O.R.C. International/ Dutch Ophthalmic USA.
3. Contributions of Authors - Design of the study (JvdW, GM); Conduct of the study (JP, MD, MN, LH, JvdW, GM); Data analysis (JP, MD, MN, LH, JvdW, GM).
4. IRB/IC - Study conducted in compliance with the Institutional Review Board and Informed Consent requirements, in adherence to the tenets of the Declaration of Helsinki, at the Netherlands Institute for Innovative Ocular Surgery (Study registration no N.08.11).
5. Other Acknowledgments – None.

REFERENCES

1. Dapena I, Ham L, Melles GRJ. Endothelial keratoplasty: DSEK/DSAEK or DMEK - the thinner the better? Curr Opin Ophthalmol 2009(4);20:299-307.
2. Ham L, Dapena I, Van der Wees J, Melles GRJ. Endothelial cell density after Descemet Membrane Endothelial Keratoplasty: 1- to 3-Year Follow-Up. Am J Ophthalmol. 2010;149(6):1016-1017.
3. Mashor RS, Kaiserman I, Kumar NL, Sansanayudh W, Rootman DS. Deep lamellar endothelial keratoplasty: up to 5-year follow-up. Ophthalmology 2010;117(4):680-686.
4. Price MO, Price FW Jr. Endothelial cell loss after Descemet stripping with endothelial keratoplasty: Influencing factors and 2-year trend. Ophthalmology 2008;115(5):857–865.
5. Terry MA, Chen ES, Shamie N, Hoar KL, Friend DJ. Endothelial cell loss after Descemet's stripping endothelial keratoplasty in a large prospective series. Ophthalmology 2008;115(3):488–496.
6. Borderie VM, Boëlle PY, Touzeau O, Allouch C, Boutboul S, Laroche L. Predicted long-term outcome of corneal transplantation. Ophthalmology 2009;116(12):2354-2360.

SUPPLEMENTAL FIGURES

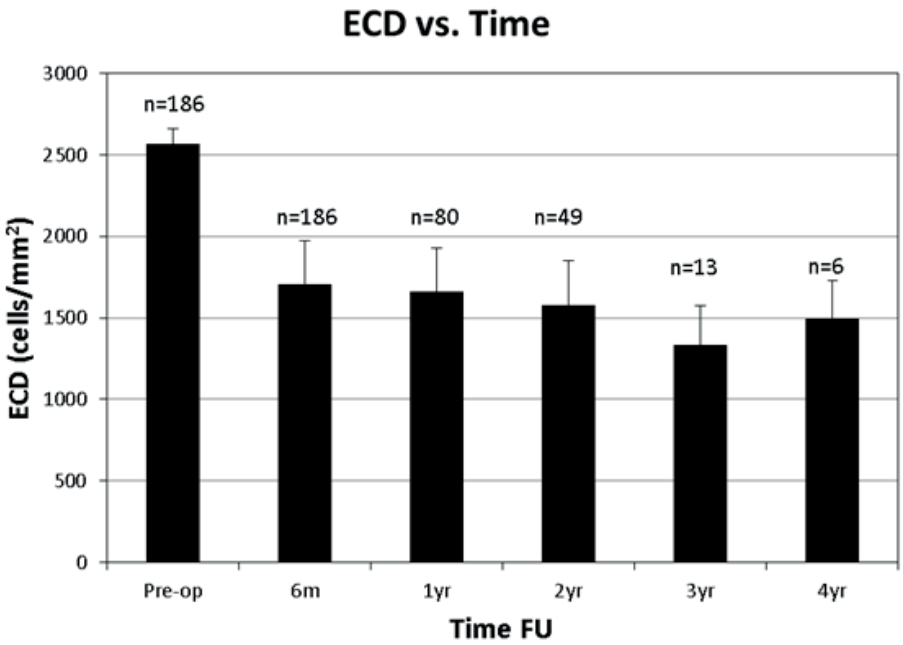

Supplemental Figure. Graph displaying the cross-sectional decrease in central corneal endothelial cell density (ECD) of the Descemet graft in absolute values up to 4 years after Descemet membrane endothelial keratoplasty (DMEK).

Supplemental Table. Cross-sectional central corneal endothelial cell density in absolute values up to 4 years after Descemet membrane endothelial keratoplasty (DMEK)

Groups of DMEK eyes		**Endothelial cell density (cells/mm^2) at follow-up intervals**					
		Preoperative	*6 months*	*1 year*	*2 years*	*3 years*	*4 years*
Eyes with 4 years FU	n=6	2730	2260	2100	1830	1610	1500
Eyes with 3 years FU	n=13	2650	1880	1740	1540	1330	
Eyes with 2 years FU	n=49	2660	1940	1800	1570		
Eyes with 1 year FU	n=80	2620	1780	1660			
Eyes with 6 months FU	n=186	2570	1710				

Chapter 8

Outcome of Descemet membrane endothelial keratoplasty in phakic eyes

Jack Parker[1-3]; Martin Dirisamer, MD[1,2,4]; Miguel Naveiras, MD[1,2]; Win H.W. Tse [1,2]; Korine van Dijk, BSc[1,2]; Laurence E. Frank, PhD[5]; Lisanne Ham, MSc[1,2,6]; and Gerrit R.J. Melles MD, PhD[1,2,6]

[1]Netherlands Institute for Innovative Ocular Surgery, Rotterdam, The Netherlands; [2]Melles Cornea Clinic Rotterdam, The Netherlands; [3]Callahan Eye Foundation Hospital, Birmingham, Alabama; [4]Department of Ophthalmology, AKH Linz, Austria; [5]Department of Methodology and Statistics, Utrecht University, The Netherlands; [6]Amnitrans EyeBank Rotterdam, The Netherlands.

ABSTRACT

Purpose: To determine the clinical outcome of isolated Descemet membrane transplantation, i.e. Descemet membrane endothelial keratoplasty (DMEK), in phakic eyes.

Setting: Non-randomized, prospective clinical study, at a tertiary referral center.

Methods: From a larger group of consecutive 260 DMEK eyes that underwent DMEK for Fuchs endothelial dystrophy, 52 eyes were phakic. For the latter group, the best corrected visual acuity (BCVA), subjective and objective refractive data, endothelial cell density, and intra- and postoperative complications were documented at 1, 3 and 6 months.

Results: A total of 69% of phakic eyes reached a BCVA of ≥20/40 (≥0.5) within one week, and 85% reached ≥20/25 (≥0.8) at six months. Compared to an age-matched control group of pseudophakic eyes, phakic DMEK eyes showed a similar visual rehabilitation rate, final visual outcome, and endothelial cell densities of 1660 (±470) cells/mm^2 at 6 months follow-up, as well as a minor hyperopic shift (+0.74D) and a similar graft detachment rate (4%). Visual outcomes of ≥20/13 (≥1.5) were limited to phakic eyes, suggesting better optical quality with the crystalline lens in-situ. Temporary mechanical angle-closure glaucoma due to air bubble dislocation behind the iris was found to be the main complication (11.5%). Two eyes (4%) required phaco-emulsification after DMEK.

Conclusion: DMEK in phakic eyes may give excellent visual outcomes without an increased risk of complications. Visual acuities of ≥20/13 (≥1.5) may indicate that near normal anatomical repair in DMEK is associated with near perfect optical quality of the transplanted cornea.

KEYWORDS: Crystalline lens, Descemet membrane endothelial keratoplasty, posterior lamellar keratoplasty, corneal transplantation, Descemet membrane, endothelium, surgical technique

INTRODUCTION

Since 1998, we have introduced various techniques for endothelial keratoplasty, later popularized as 'deep lamellar endothelial keratoplasty' (DLEK), and Descemet stripping (automated) endothelial keratoplasty (DSEK/DSAEK).[1,2] More recently we described a technique for the selective transplantation of a donor Descemet membrane, now referred to as Descemet membrane endothelial keratoplasty (DMEK).[3,4]

To perform these various types of endothelial keratoplasty, a sufficiently deep recipient anterior chamber is required to maneuver the graft in position against the recipient posterior stroma.[5] Since removal of the crystalline lens also deepens the anterior chamber, there is a trend to routinely perform a cataract extraction prior or during the transplantation surgery. This is especially true given that the main indication for endothelial keratoplasty is a Fuchs endothelial dystrophy, many of which are accompanied by some degree of cataract that may be aggravated by the corneal surgery or the prolonged postoperative (steroid) medication.[6-8]

Clinical observation, however, suggests that 'phakic eyes do better' after endothelial keratoplasty, i.e. sparing the crystalline lens appears to be associated with higher visual outcomes.[9,10] This finding might be explained by bias due to selection of younger patients who on average have higher visual potential or a lower incidence of co-morbidity. On the other hand, cataract extraction could also induce some degradation of the optical quality of the eye, for example by posterior capsule opacification, loss of accommodation, and/or a change in the optical properties of the lens system.

In the current prospective study, we therefore prospectively evaluated the clinical outcome of 52 phakic DMEK eyes up to 6 months after surgery to determine what (dis) advantages may be associated with sparing the (clear) crystalline lens in DMEK.

MATERIALS AND METHODS

From a larger group of 260 eyes that underwent DMEK to manage Fuchs endothelial dystrophy, 52 eyes were phakic of which 48 consecutive phakic eyes of 43 patients, 24 male and 19 female, were enrolled in our prospective study. The average age was 52 (± 7) years (range 33 to 67) (**Table 1**). Two eyes were excluded from the visual acuity analysis because of graft detachment after DMEK, and two eyes were lost to follow-up.[11-12] From the larger group of 260 eyes that underwent DMEK to manage Fuchs endothelial dystrophy, we selected a group of 47 pseudophakic patients, which constituted the control-group in this study and age-matched the group of 48 phakic patients. The average age in the control group was 60 (± 5) years (range 48 to 66 years). All patients signed an IRB-approved informed consent.

Table 1. Demographics of phakic DMEK patients

Demographics of phakic DMEK patients		
Number of phakic patients	43	-
Number of phakic eyes	48	-
Mean age (yrs)	52.4 (±6.7)	-
Number of men/women	24/19	56/44%

Donor tissue

From donor globes obtained less than 24 hours post mortem, corneo-scleral buttons were excised and stored by organ culture in modified minimum essential medium (EMEM) at 31° C. After one week of culture, endothelial cell morphology and viability were evaluated and the corneo-scleral buttons were mounted endothelial side up on a custom made holder with a suction cup. Descemet's membrane (DM) was stripped from the posterior stroma, so that a 9.5 mm diameter flap of posterior DM with its endothelial monolayer was obtained.[13] Due to the elastic properties of the membrane, a 'Descemet-roll' formed spontaneously, with the endothelium at the outer side. Each Descemet–roll was then stored in organ culture medium until the time of transplantation.

Surgery

Surgeries were performed under retrobulbar anaesthesia, as previously described.[2-4] A 3.0 mm tunnel incision was made at the limbus, entering the anterior chamber approximated 3.0 mm within the clear cornea. With an inverted Sinskey hook (D.O.R.C. International, Zuidland, The Netherlands), a circular portion of DM was scored and stripped from the posterior stroma, so that a 9.0 mm diameter 'descemetorhexis' was created, and the central portion of DM was removed from the eye.[14]

The donor Descemet-roll was stained with a 0.06% trypan blue solution (VisionBlue™, D.O.R.C. International), and sucked into a custom made injector (D.O.R.C International), to transfer the tissue from the culture medium vial to the anterior chamber.[4] Using the injector, the donor Descemet-roll was inserted into the anterior chamber and the graft was oriented endothelial side down (donor DM facing recipient posterior stroma) by careful, indirect manipulation of the tissue with air and fluid. While maintaining the anterior chamber with fluid and air, the graft was gently spread out over the iris. Then, an air bubble was injected underneath the donor DM to position the tissue onto the recipient posterior stroma.[4] The anterior chamber was completely filled with air for 45-60 minutes followed by an air-liquid exchange to pressurize the eye.

Data collection and Statistical analysis

Donor endothelial cell density (ECD) was evaluated in-vitro (Axiovert 40 inverted light microscope, Zeiss, Göttingen, Germany), and photographed (PixeLINK PL-A662, Zeiss,

Göttingen, Germany). In patient eyes, ECD was evaluated in-vivo using a Topcon SP3000p non-contact autofocus specular microscope (Topcon Medical Europe BV, Capelle a/d IJssel, The Netherlands). Images of the central corneal window were manually corrected and three measurements were averaged.

Recipient eyes were examined before and after DMEK at 1, 3 and 6 months with biomicroscopy, Pentacam imaging (Oculus, Wetzlar, Germany), non-contact specular microscopy, and slit-lamp photography (Topcon Medical Europe BV). BCVA, ECD, as well as intraoperative and postoperative complications were recorded in a database.

Both the 'relative' and 'absolute' refractive changes were considered relevant to our study. To detect the presence or absence of a hyperopic shift, the myopic and hyperopic shift in spherical equivalent were averaged to show the relative, overall tendency in refractive change. The absolute change, whether in myopic or hyperopic direction, may illustrate the clinical impact of the refractive change.

For all comparisons, two-sided paired-sample *t*-tests were performed (SPSS 18.0). *P*-values for the Pentacam and refractive data were corrected with the Benjamini&Hochberg correction (multiple tests increase false positives).[15] After correction, all P-values <0.05 represented statistical significance. Repeated measures AN(C)OVA (PASW Statistics 18) were used to test whether the pre- to postoperative decline in ECD and the pre- to postoperative change in logMAR visual acuity differs between the phakic group and the age matched pseudophakic control group.

RESULTS

Best corrected visual acuity (BCVA)

At six months, all eyes (100%) reached a BCVA of ≥20/40 (≥0.5), 85% ≥20/25 (≥0.8), 67% ≥20/20 (≥1.0), and 21% ≥20/17 (≥1.2) (n=48) (**Figure 1**). At one week these percentages were respectively 69%, 35%, 19%, and 0%; at 1 month 98%, 73%, 44%, and 4% and at 3 months 98%, 77%, 58% and 10% (**Figure 1**). The BCVA of the phakic eyes did not differ from that in age-matched pseudophakic eyes (*P*>0.1) (**Figure 1**).

Spherical equivalent of subjective refraction

The manifest spherical equivalent averaged -0.76D (±2.2 D) before surgery, 0.01D (±2.1D) at three months, and -0.02D (±2.1D) at six months after surgery (n=43) (**Table 2a**). Hence, the pre- to postoperative change in spherical equivalent (hyperopic and myopic shifts in corneal power averaged) was +0.77D (±0.8D) at three months (*P*=0.0000) and +0.74D (±0.8D) at six months (*P*=0.0000) (n=43) (**Table 2a**). The pre- to postoperative absolute change in spherical equivalent (absolute change in corneal power) averaged 0.96D (±0.6D) at three months and 0.84D (±0.7D) at six months (n=43) (**Table 2a**).

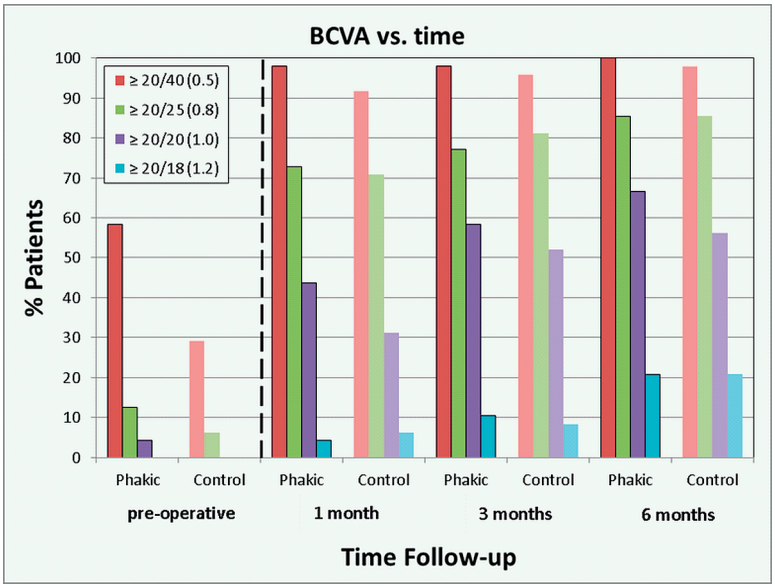

Figure 1. Graph displaying the best corrected visual acuity (BCVA) of all phakic eyes and the age-matched pseudophakic controls before and at 1, 3, and 6 months after DMEK surgery.

Table 2a

Subjective refractive outcome DMEK in phakic eyes (D) *n=43*[a]																		
	Pre-operative			3m postoperative			6m postoperative			ΔSE 3m vs preop	ΔSE 3m vs preop absolute	ΔSE 6m vs preop	ΔSE 6m vs preop absolute	ΔSE 6m vs 3m	Δ Cyl 3m vs preop	Δ Cyl 3m vs preop absolute	Δ Cyl 6m vs preop	Δ Cyl 6m vs preop absolute	ΔCyl 6m vs 3m
	SE	Sp	Cyl	SE	Sp	Cyl	SE	Sp	Cyl										
Average	-0.76	-0.26	-1.02	0.01	0.54	-1.07	-0.02	0.51	-1.05	0.77	0.96	0.74	0.84	-0.03	-0.05	0.87	-0.03	0.81	0.02
SD	2.2	2.2	1.0	2.1	2.3	0.9	2.1	2.1	1.0	0.8	0.6	0.8	0.7	0.7	1.1	0.7	1.0	0.6	0.8

Cylindric error of subjective refraction

The refractive cylinder averaged -1.02D (±1.0D) before surgery, -1.07D (±0.9D) at three months, and -1.05D (±1.0D) at six months after surgery (n=43) (**Table 2a**). Hence, the pre- to postoperative change in refractive cylinder (hyperopic and myopic shifts in cylindric power averaged) was -0.05D (±1.1D) at three months (*P*= 0.7581) and -0.03D (±1.0D) at six months (*P*=0.8214) (n=43) (**Table 2a**). The pre- to postoperative absolute change

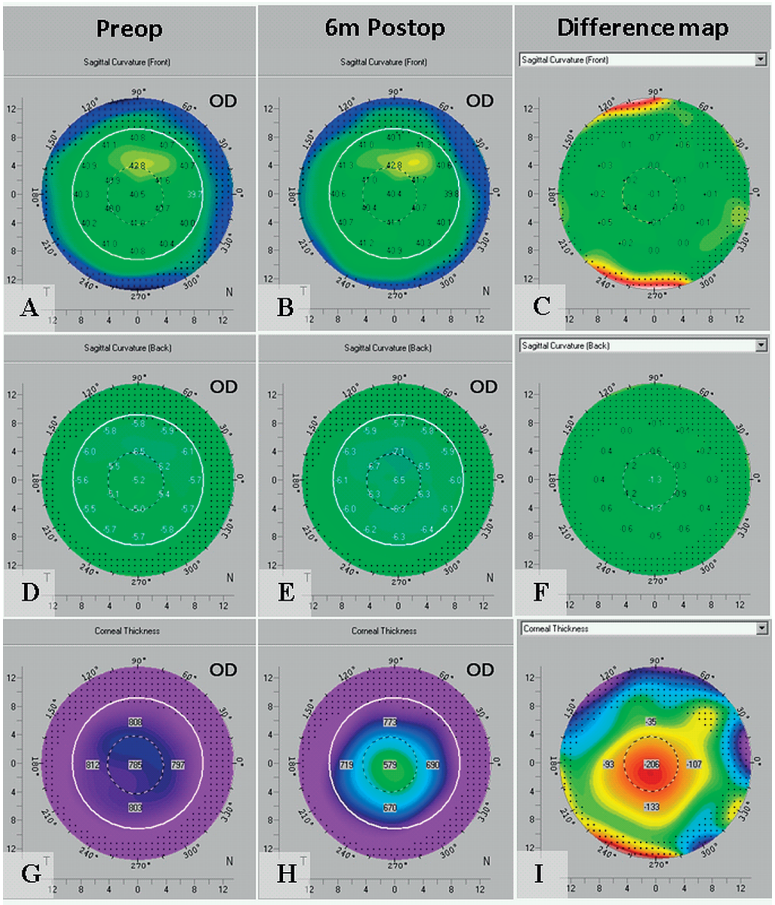

Figure 2. Topographic corneal power maps of the anterior corneal curvature (A-C), the posterior corneal curvature (D-F), and the corneal pachymetry (G-I) before DMEK (A, D and G), 6 months after DMEK (B, E, and H), and the difference maps (C, F and I). Note that the anterior corneal curvature is stable but the posterior curvature change of approximately 1.0D. Compare to Table 3a.

in refractive cylinder (absolute change in cylindric power) averaged 0.87D (±0.7D) at three months and 0.81D (±0.6D) at six months (n=43) (**Table 2a**).

Stability of refraction

The change in spherical equivalent before and at six months after surgery was ≤0.5D in 37% (16/43) of eyes and ≤1.0D in 61% (26/43) (**Table 2b**). The change in cylindric error before and at six months after surgery was ≤1.0D in 67% (29/43) of eyes (**Table 2b**).

From the three to six months postoperative time interval, 74% (32/43) of eyes did not show more than a 0.5D change in spherical equivalent, and 88% (38/43) was ≤1.0D (**Table 2b**).

Table 2b

Stability of refraction after DMEK in phakic eyes (D) *n= 43*[a]				
ΔSE 6m vs pre-op		ΔCyl 6m vs preop	ΔSE 6m vs 3m	
≤0.5D	≤1.0D	≤1.0D	≤0.5D	≤1.0D
37% 16/43	61% 26/43	67% 29/43	74% 32/43	88% 38/43

[a]n=43, because for 5 out of 48 patients no complete refractive dataset was available

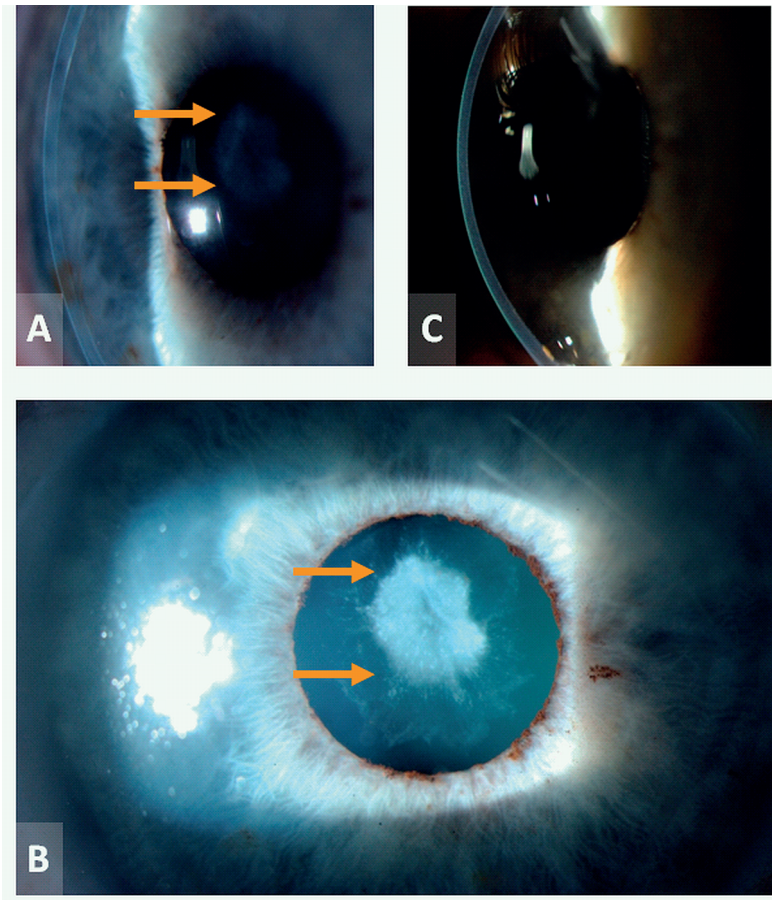

Figure 3. (A and B) Slit-lamp photographs of a cornea 6 months after DMEK complicated by air bubble dislocation behind the iris and air-bubble induced mechanical angle-closure glaucoma in the immediate postoperative phase. Note the anterior subcapsular cataract (orange arrows) for which a secondary phaco-emulsification was performed. (C) Three months after phacoemulsification (9 months after the initial DMEK), the Descemet graft is attached and functional.

Objective corneal power measurements

Using Pentacam topographic corneal power maps, the 'True Net Power' keratometric values were 42.8D (±2.3D) before surgery (n=45), 41.0D (±1.5D) at three months (n=41) (*P*=0.0000), and 41.0D (±1.5D) at six months after surgery (n=45) (*P*=0.0000). Anterior keratometric values changed from 43.2D (±1.7D) before (n=45), to 42.5D (±1.4D) at three months (n=41) (*P*=0.0000) to 42.5D (±1.5D) at six months after surgery (n=45) (*P*=0.0009), but posterior keratometric values increased from 5.4D (±0.7D) before surgery (n=45) to 6.4D (±0.3D) at three months (n=41) to 6.3D (±0.3D) at six months after surgery (n=45) (*P*=0.0000) (**Figure 2; Table 3a**).

Table 3a

Objective refractive outcome DMEK in phakic eyes (D) Pentacam measurements					
	Pre-operative (n=45)[a]	3m postoperative (n=41)[b]	6m postoperative (n=45)[a]	ΔK mean 3m vs preop	ΔK mean 6m vs preop
Average True Net Power	42.8	41.0	41.0	1.75	1.78
SD	2.3	1.5	1.5	0.83	0.76
P=				**0.0000**	**0.0000**
Average Cornea Front	43.2	42.5	42.5	0.75	0.74
SD	1.7	1.4	1.5	0.33	0.25
P=				**0.0000**	**0.0009**
Average Cornea Back	5.4	6.4	6.3	0.93	0.91
SD	0.7	0.3	0.3	0.42	0.37
P=				**0.0000**	**0.0000**

Pachymetry

Pentacam pachymetry measurements decreased from 665µm (±103µm) before surgery (n=45), to 510µm (±39µm) at three months (n=41) (*P*=0.0000), and 520µm (±44µm) at six months (n=45, *P*= 0.0000, **Table 3b**).

Table 3b

Central pachymetry after DMEK (µm) Pentacam measurements					
	Pre-operative (n=45)[a]	3m postoperative (n=41)[b]	6m postoperative (n=45)[a]	Δ pachymetry 3m vs preop	Δ pachymetry 6m vs preop
Pachymetry	665	510	520	155	145
SD	103	39	44	64	59
P=	-	-	-	**0.0000**	**0.0000**

Endothelial cell density

In phakic eyes, endothelial cell density averaged 2560 (±170) cells/mm^2 before surgery (n=46), and 1660 (±470) cells/mm^2 (n=46) at six months postoperative. The decline in ECD at six months was similar to that in the age corrected control group of pseudophakic DMEK eyes (n=47), which showed an average endothelial cell density of 2580 (±190) cells/mm^2 before surgery and 1660 (±500) cells/mm^2 (n=47) at six months postoperative. The ECD and cell loss of the phakic group was similar to the age-matched pseudophakic control group (*P*>0.1) (**Table 3c**).

Table 3c

	Endothelial cell density (cells/ mm^2)	
	Phakic	Pseudophakic
Pre-op	2560 (±170)	2580 (±190)
6 m post-op	1660 (±470)	1660 (±500)
Cell loss (%)	35.4	35.5
N=	46[c]	47

[a]n=45, because for 3 out of 48 patients no preoperative and/or 6m postoperative Pentacam data were available
[b]n=41, because for 7 out of 48 patients no 3m postoperative Pentacam data were available
[c]n=46, because for 2 out of 48 patients no 6m postoperative ECD data were available

Side effects and complications

From a total of 52 phakic DMEK eyes, two eyes (4%) required phaco-emulsification at six months and 2.5 years after the initial DMEK surgery. Both of these eyes had developed anterior subcapsular opacifications within the first month after surgery, attributed to air bubble misdirection behind the iris in the immediate postoperative phase, causing mechanical angle-closure glaucoma in one case (**Figure 3**). Both phaco-emulsification procedures were uneventful and no graft displacements or other graft related problems were encountered.

Five other eyes (10%) showed a faint haze over the anterior lens capsule (similar to Glaukom-flecken) after surgery that may have been induced by air bubble trauma during or at the end of the DMEK procedure. Of these five eyes, all had at least 6 months of follow up, and the BCVA appeared similar to that of the overall group of phakic eyes: 100% reached ≥20/40 (≥0.5), 80% (4/5) ≥20/25 (≥0.8), 60% (3/5) ≥20/20 (≥1.0), and 20% (1/5) ≥20/18 (≥1.2).

Mechanical angle-closure glaucoma due to air bubble misdirection behind the iris in the immediate postoperative phase, was observed in a total of six eyes (11.5%) In all of these eyes, the air had shown a tendency to move underneath the iris during surgery. Another eye with pre-existing open-angle glaucoma presented with intermittent glau-

comatous crises within the first half year after surgery, for which secondary glaucoma surgery was performed.

Graft detachment occurring in two eyes (4%), was managed by a secondary DMEK in one eye, while the other eye showed corneal clearance despite graft attachment.[11-12] Other potential complications, such as primary or secondary graft failure, or allograft rejection did not occur in this series.

DISCUSSION

Clinical impression suggest that "phakic eyes do better" after DMEK surgery, as has also been reported after DSEK/DSAEK.[10] In the current study, however, we were not able to substantiate this observation: for the two main outcome criteria, the six months BCVA and the endothelial cell density, no overall difference could be found between the phakic DMEK eyes and an age-matched pseudophakic control group. In this age group, 85% of eyes reached a BCVA of ≥20/25 (≥0.8) within 6 months post-operative.

If all of the above is taken in consideration, should it be advocated to leave the crystalline lens in situ in the absence of a cataract? In DSEK/DSAEK, many corneal surgeons prefer to routinely perform a phaco-emulsification prior or during transplantation, because a deeper anterior chamber may facilitates tissue handling and in particular unfolding of the graft. After DSEK/DSAEK, cataract formation has been described to occur in about 37% of cases, however, when corrected for age (<50 yrs) the actual incidence reported was 7%.[10] In our series, only two DMEK eyes (4%) developed a clinically significant cataract, and with the standardized surgical technique currently available,[4] there may be little to gain by making the eye pseudophakic prior to DMEK. In addition, while reviewing the patients files, two rather subjective findings could explain our clinical impression that phakic eyes show better outcomes.

First, although statistical analysis did not show a difference in average BCVA between both groups, phakic eyes were frequently found to obtain visual acuities above 20/18 (>1.2), while none of the age-matched pseudophakic eyes reached this level of sight. This finding may suggest that, compared to a phakic eye, the optical system of the pseudophakic DMEK eye is somehow compromised. Furthermore, this finding may indicate that the anatomical restoration of the transplanted cornea after DMEK may allow for a near perfect optical quality of that cornea, because even minor aberrations would quickly limit the final visual acuity, even in virgin eyes. Second, the age-group eligible for sparing the (clear) crystalline lens (30-60 years of age) may still benefit from the accommodative power of the eye. For that reason the overall satisfaction with the DMEK procedure may be higher, i.e. when performed to manage an isolated Fuchs endothelial dystrophy, complete visual rehabilitation is commonly achieved, and also perceived as

such by the patient. It may be important to note that higher visual outcomes are associated with higher visual demands, so that relatively minor optical aberrations will be perceived as more disturbing to a patient.

Clinically, most DMEK patients continue to wear their 'own' glasses in the first months after surgery. This may be explained by the minor change in refractive power associated by the DMEK procedure: in about ⅔ of eyes of both the spherical equivalent and the cylindrical error were within 1.0D from the preoperative refractive error, partially due to a +0.74D refractive shift in hyperopic direction induced by stromal dehydration.[16] Pachymetry and refractive data demonstrated that the transplanted cornea stabilizes approximately three months after DMEK, so new glasses could usually be prescribed at this time point.

Detachment of the Descemet graft from the recipient posterior stroma may be the most common complication after endothelial keratoplasty.[17,18] During the 'learning curve period' in DMEK, graft detachment occurred in 10-20% of cases but declined to 2-5% or less with experience.[19,20] In the current series of phakic DMEK eyes, a similar graft detachment rate was found, i.e. 4% (two eyes). The most striking complication in our study was mechanical angle-closure glaucoma due to air bubble misdirection behind the iris in the immediate postoperative phase, occurring in six eyes (11.5%). In one of these eyes, the air-bubble dislocation seemed to have caused an anterior subcapsular cataract reducing BCVA to 20/40 (0.5) requiring secondary phaco-emulsification. In all of these six eyes, the air had already shown a tendency to move underneath the iris *during* surgery. Hence, to avoid this type of secondary angle-closure glaucoma, it may be advocated to reduce the final air-bubble size to approximately 25% or to remove all intracameral air at the termination of the surgery if the air tends to dislocate underneath the iris during surgery.

A YAG-laser iridotomy routinely made 1-2 weeks before the DMEK surgery may have prevented the occurrence of true pupillary block glaucoma in our series (since mechanical angle closure glaucoma induced by air-bubble misdirection does not result from a blockage of the pupillary outflow). One eye, however, developed clinically significant cystoid macular edema after the YAG-laser iridotomy that subsided over a period of 2 months. In another eye, pre-existing open-angle glaucoma may have been aggravated into intermittent glaucomatous crises by the DMEK surgery,[17] possibly by peripheral anterior synecchiae, perioperative inflammation, or the steroid medication.[21] No other glaucomatous or posterior segment complications were seen in this series, nor any other graft related problems such as primary or secondary graft failure, or allograft rejection. Therefore, because the latter cases may be considered incidental and mechanical angle-closure glaucoma can be avoided, DMEK in phakic eyes may be associated with a relatively low risk of complications.

SUMMARY

What was known before:

- In phakic eyes prior to endothelial transplantation, it is common practice to first remove the patient's crystalline lens, even in the absence of a cataract. This measure, while believed to facilitate DSEK/DSAEK surgery, and/or to reduce subsequent cataract formation, has not been studied in DMEK patients.

What this paper adds:

- In our study, we found that DMEK can be easily performed in phakic eyes, and that leaving the crystalline lens in-situ, rarely results in secondary cataract formation.
- Since better overall optical quality may be achieved in phakic DMEK eyes, while the accommodative functions are spared, it may be considered to leave the (clear) crystalline lens in situ prior to DMEK.

ACKNOWLEDGMENTS / DISCLOSURE

IRB/IC - Study conducted in compliance with the Institutional Review Board and Informed Consent requirements, in adherence to the tenets of the Declaration of Helsinki, at the Netherlands Institute for Innovative Ocular Surgery (Study registration no N.05.14). The study was submitted to http://www.clinicaltrals.gov (Study registration no NCT00521898).

REFERENCES

1. Melles GRJ, Eggink FAGJ, Lander F, Pels E, Rietveld FJ, Beekhuis WH, Binder PS. A surgical technique for posterior lamellar keratoplasty. Cornea 1998; 17:618-626
2. Dapena I, Ham L, Melles GRJ. Endothelial keratoplasty: DSEK/DSAEK or DMEK - the thinner the better? Curr Opin Ophthalmol 2009; 20:299-307
3. Ham L, Dapena I, van Luijk C, van der Wees J, Melles GRJ. Descemet membrane endothelial keratoplasty (DMEK) for Fuchs endothelial dystrophy: review of the first 50 consecutive cases. Eye 2009; 23:1990-1998
4. Dapena I, Moutsouris K, Droutsas K, Ham L, van Dijk K, Melles GR. Standardized "no-touch" technique for descemet membrane endothelial keratoplasty. Arch Ophthalmol 2011;129:88-94
5. Huang T, Wang Y, Ji J, Gao N, Chen J. Deep lamellar endothelial keratoplasty for iridocorneal endothelial syndrome in phakic eyes. Arch Ophthalmol 2009; 127:33-36
6. Payant JA, Gordon LW, VanderZwaag R, Wood TO. Cataract formation following corneal transplanation in eyes with Fuchs' endothelial dystrophy. Cornea 1990; 9:286-289
7. Price MO, Price FW Jr.Cataract progression and treatment following posterior lamellar keratoplasty. J Cataract Refract Surg 2004; 30:1310-1315
8. Price FW Jr, Price DA, Ngakeng V, Price MO. Survey of steroid usage patterns during and after low-risk penetrating keratoplasty. Cornea. 2009; 28:865-870
9. Price MO, Price FW Jr. Endothelial keratoplasty - a review. Clin Experiment Ophthalmol 2010; 38: 128-140
10. Price MO, Price DA, Fairchild KM, Price FW Jr. Rate and risk factors for cataract formation and extraction after Descemet stripping endothelial keratoplasty. Br J Ophthalmol 2010; 94:1468-1471
11. Balachandran C, Ham L, Verschoor CA, Ong TS, van der Wees J, Melles GR. Spontaneous corneal clearance despite graft detachment in descemet membrane endothelial keratoplasty. Am J Ophthalmol 2009; 148:227-234
12. Ham L, van der Wees J, Melles GR. Causes of primary donor failure in descemet membrane endothelial keratoplasty. Am J Ophthalmol 2008; 145:639-644
13. Lie JT, Birbal R, Ham L, van der Wees J, Melles GRJ. Donor tissue preparation for Descemet membrane endothelial keratoplasty (DMEK). J Cataract Refract Surg 2008; 34:1578-1583
14. Melles GRJ, Ong TS, Ververs B, van der Wees J. Descemet membrane endothelial keratoplasty (DMEK). Cornea 2006; 25:987-990
15. Benjamini Y, Hochberg Y. Controlling the false discovery rate: A practical and powerful approach to multiple testing. J R Statist Soc B 1995; 57:289-300
16. Ham L, Dapena I, Moutsouris K, Balachandran C, Frank LE, van Dijk K, Melles GR. Refractive change and stability after Descemet membrane endothelial keratoplasty Effect of corneal dehydration-induced hyperopic shift on intraocular lens power calculation. J Cataract Refract Surg 2011; 37: 1455-1464
17. Dirisamer M, Ham L, Dapena I, Moutsouris K, Droutsas K, van Dijk K, Frank LE, Oellerich S, Melles GR. Efficacy of Descemet Membrane Endothelial Keratoplasty: Clinical Outcome of 200 Consecutive Cases After a Learning Curve of 25 Cases. Arch Ophthalmol 2011 Jul 11. [Epub ahead of print]
18. Dapena, I, Ham L, Droutsas K, van Dijk K, Moutsouris K, Melles GRJ. Learning curve in Descemet membrane endothelial keratoplasty (DMEK). First series of 135 consecutive cases. Ophthalmology 2011 Jul 19. [Epub ahead of print]
19. Price MO, Price FW Jr. Descemet Membrane Endothelial Keratoplasty. Int Ophthalmol Clin 2010; 50:137-147

20. Dapena I, Moutsouris M, Ham L, Melles GRJ. Graft detachment rate. Ophthalmology 2010; 117:847
21. Prasanth B, Dubey S, Mathur U. IOP changes after DSEK. Ophthalmology 2010; 117:1460-1461

Chapter 9

Summary and conclusions

BOWMAN LAYER TRANSPLANTATION

Today, penetrating keratoplasty (PK) and its cousin deep anterior lamellar keratoplasty (DALK) remain the standard of care for eyes with advanced keratoconus (KC) once visual acuity becomes unacceptable and/or contact lens intolerance develops (Chapters 1,2, and 5).[1,2] And while the outcomes of these operations are often described as "good," many unresolved challenges remain.[3,4]

Specifically, many recipients of both surgeries are young at the time of their operations, in some cases extremely so, rendering the procedures more technically challenging and the postoperative care more difficult, especially if there is some coexisting cognitive or behavioral limitation (which is not altogether uncommon).[5–8] Young eyes also tend to be phakic: in the first few years after transplantation, cataracts may develop. As a result, lens extraction may be necessary, potentially risking the graft's health in the process.[9,10] Children already suffer poorer graft survival than adults,[11] but even if the statistics were identical, still it is very likely that young patients will "outlive" their first transplant and therefore require re-operation(s). And because the outcomes of second and third transplants tend to be inferior to the first, many patients who seem—initially—to do well with both surgeries may, ultimately, experience problems.[12] This is especially true given that advanced KC is found in patients with severe ocular surface disorders, many of which are exacerbated by PK/DALK and their large incisions, sutures, and the neurotrophic corneas they produce.[13,14] Beneath the ocular surface, additional wound healing problems may also be found, since the stroma at the junction between the graft and the recipient probably never securely heals, predisposing these eyes to inadvertent traumatic rupture and ongoing ectasia at the tissue interface (and thereby "recurrence" of their disease).[15]

All of these difficulties are fundamental problems intrinsic to DALK and PK themselves and therefore not likely to be cured by refinements to operative technique or instrumentation (Chapter 2). The solution may instead require an entirely new surgical approach, possibly one that abandons the idea of exchanging or replacing the recipient cornea with donor tissue. To this end, recently there has been a strong push to intervene early against eyes with mild KC in the hopes of arresting progression before PK or DALK (and their attendant complications) become necessary. Both ultraviolet-crosslinking (UV-CXL) and intracorneal ring segments (ICRS) have been evaluated for this purpose, each with demonstrated success. Nevertheless, many eyes are not candidates for either operation. Those with corneas steeper than 58 diopters (D) or thinner than 400μm, for example, may be ineligible for both ICRS and UV-CXL according to published safety guidelines.[16,17] Further, in the US, ICRS are not approved in patients younger than 18 years old, and UV-CXL - while recently legalized - is not yet widespread.[16,17]

Other exclusions also apply: corneas with prior herpetic disease are disqualified from UV-CXL, and a history of recurrent erosions excludes ICRS placement.[16,17] Overall, it may

be fair to say that, for various reasons, many patients with "active" or "ongoing" KC are ineligible for these therapies, and therefore may continue to progress.[18] Eventually, contact lens intolerance might develop. Many patients then receive either PK or DALK and be subject to possible complications.

What has been badly needed is an operation to arrest keratoconic progression in eyes poorly suited for UV-CXL or ICRS, before PK or DALK become necessary.[18-20]For this reason, in 2014, we began our investigation into a new operation known as Bowman layer (BL) transplantation (Chapter 3).[21] One of the most sensitive and specific manifestations of KC is the fragmentation of the BL, an insult that critically destabilizes the surrounding cornea, predisposing it to ongoing ectasia. As a result, we reasoned that an isolated BL transplant might flatten the cornea into a more normal architecture and bolster it against further deformation.

For our first surgeries, we chose only patients with extremely advanced KC, all with maximum keratometry values ≥70D. The operation itself was performed by manually dissecting a midstromal pocket, limbus-to-limbus, 360° within the recipient cornea, then implanting an isolated BL graft. All surgeries in this initial series were uneventful with no complications, except in two cases that experienced an intraoperative perforation of Descemet Membrane during the dissection. In the initial 10 eyes operated with this technique, by one year after surgery, neither spectacle nor contact lens corrected visual acuity significantly changed from pre- to postoperative.[21] However, recipient corneas were flattened by an average of 8–9 D, and in all cases, disease progression was arrested and comfortable contact lens wear was preserved or restored.[21]

Since our original study, we have operated on a growing number of additional patients with the same technique both in the Netherlands and also now in the United States (Chapter 4).[22,23] Overall, the surgery seems effective in >90% of eyes at halting ongoing ectasia (now with a mean follow up period of greater than 3 years, and with some patients now 5 years after surgery). Moreover, a slight average improvement in spectacle corrected visual acuity has been observed (from 20/400 to 20/125). Likely, these gains reflect a "normalizing" of the ocular surface since – after BL implantation – the cornea's higher order visual aberrations (especially spherical aberration) significantly diminished.[24] In addition, no known postoperative complications have been observed. Specifically, no ocular surface matters have arisen (likely because the technique employs no surface incisions and no sutures), nor have there been any occurrences of either cataract formation or allograft reaction. In fact, because the BL transplant is acellular,[25] graft rejection may significantly less likely.[19,23] Therefore, much fewer (and possibly no) steroids may be required postoperatively, eliminating a major source of postoperative risk.

So far, our experience with Bowman layer transplantation has led us to believe that the operation may be a promising way to arrest keratoconic progression, even in those

eyes ineligible for other procedures. Longer and larger study with additional patients will be necessary, but it is possible that with continued effort, we may continue in the tradition of endothelial keratoplasty by abandoning the idea of full thickness corneal transplantation and, instead, choose a more limited and specific corrective intervention.

DESCEMET MEMBRANE ENDOTHELIAL KERATOPLASTY (DMEK)

For corneal endothelial disorders, several different techniques have been in existence, and Descemet Membrane Endothelial Keratoplasty (DMEK) may have superseded its predecessor, Descemet Stripping (Automated) Endothelial Keratoplasty (DS(A)EK), as the procedure of choice for this condition (Chapter 6).[26] With a graft consisting exclusively of an isolated Descemet membrane and its attendant endothelium, DMEK effects a one-to-one replacement of donor for diseased tissue, resulting in the near complete anatomic restoration of the recipient cornea (Chapter 6).[26]

Immediately postoperatively, the measured endothelial cell density of a DMEK graft displays a sharp decline, consistently measured at approximately 35% of the preoperative value (Chapter 7).[27,28] Although this decline is frequently expressed as "cell loss" resulting from intraoperative tissue manipulation, this explanation may be overly simplistic, and other factors may also be involved, for example: cell migration/redistribution from the graft onto surrounding areas of recipient posterior stroma.[29] Nevertheless, by six months after surgery, the rate of cell density decline appears to stabilize at a low level (around 5% per year). This pattern closely resembles that seen after DS(A)EK, and differs from the cell density trends seen after Deep Lamellar Endothelial Keratoplasty (DLEK) and PK, which both show an indefinite, linear decline in cell density in perpetuity.[30-32]

The average best corrected visual acuity (BCVA) after DMEK is 20/25 (0.8), which is usually achieved by three months postoperatively and with little entailed hyperopic shift.[33] This contrasts with the average visual acuities, recovery times, and refractive shifts after both PK and DS(A)EK: after PK, BCVA averages only 20/40 (0.5), is delayed by one year, and commonly entails severe astigmatism; after DS(A)EK, BCVA is averages 20/30, is delayed by 6 months, and entails twice as much hyperopic shift as DMEK.[34] However, DMEK's visual results are limited by the condition of the anterior corneal surface and by the lens status of the recipient eye. Specifically, longstanding corneal edema may produce anterior stromal scarring/ fibrosis, which may not entirely resolve after DMEK.[35] Therefore, early endothelial replacement before these changes develop may be advisable. (Otherwise, contact lens fitting may mitigate some of these abnormalities.) In addition, while phakic and pseudophakic patients seem to achieve the same average visual results after surgery, the "extremes" of good vision are more commonly found in phakic eyes, suggesting some optical advantage in preserving the natural lens (Chapter 8).[36]

Unlike phakic eyes undergoing DS(A)EK, cataract formation is not the rule after DMEK, possibly as a result of the lower post-operative steroid burden entailed. In our series only 4% of phakic eyes undergoing DMEK required subsequent phacoemulsification within a two-year follow up period.[36] However, phakic eyes receiving DMEK do display a unique susceptibility to air-bubble induced angle closure glaucoma, in which the air-fill left postoperatively pushes against the lens, which responds by tilting forward and closing off the trabecular meshwork.[37] To prevent this occurrence, phakic eyes are best left with a smaller air-fill at the conclusion of their operation: only 50% of the volume of the anterior chamber, rather than 75%, as recommended in pseudophakic eyes. Interestingly, phakic eyes treated in this manner do not seem to display a higher percentage of postoperative graft detachments than their pseudophakic counterparts, suggesting that the postoperative air-fill may be less critical to graft adherence than is currently believed.[36]

Because DS(A)EK involves a stroma-stroma interface at the junction of donor and recipient tissues, and because this interface may be highly reflective and irregular, the optical quality of the transplanted eye may suffer. Other reasons for poor visual acuity after D(A)EK include: stromal "waves" in the donor lenticule stemming from a curvature mismatch between the recipient's cornea and the graft; and recipient Descemet membrane "remnants" left in the interface. As a result of these three factors, some eyes which receive an uncomplicated DS(A)EK operation, experience a normal postoperative course, and present with clear and well attached grafts may, nevertheless, achieve unsatisfying visual results.[38] Re-operating on these eyes to replace their DS(A)EK grafts with DMEKs has been shown to result in substantial visual improvements in these cases, likely because DMEK grafts - being devoid of stroma - fit better against the recipient posterior cornea and induce less scarring. Moreover, separate studies have independently demonstrated that - when operated with both techniques - patients subjectively prefer the vision in their DMEK eye.[39] Altogether, these results confirm the underlying philosophy of DMEK surgery: that the operation returns the eye to a nearly-normal anatomy, unlike PK, DLEK, and even DS(A)EK.[40] Preliminary results have also been returned from a modified form of DMEK, known as Hemi-DMEK, in which a single, oversized, circular DMEK graft is divided in two, and each hemi-circular graft is then implanted in a different recipient.[41-43] Because approximately the same number of cells is transplanted with each of the two Hemi-DMEK grafts as with one "regular" DMEK graft, and because the donor tissue is likewise positioned in the same location against the recipient cornea, the rate and extent of visual recovery would be expected to be similar between the two operations, which is confirmed in our initial results. A possible, theoretical advantage of Hemi-DMEK over standard/ conventional DMEK is that, by dividing each donor tissue in two, Hemi-DMEK may double the pool of available tissue for transplantation. From Hemi-DMEK the next steps remain unsettled. The operation may progress to "Quarter-DMEK" in which the

donor tissue is again divided in two.[44] Alternatively, we may proceed with injections of cultured human endothelial cells, as is currently being trailed, or even "keratoplasty-free" solutions, that totally abandon the concept of donor material altogether.[45,46]

CONCLUDING REMARKS

The past two decades have seen an explosion of new keratoplasty techniques, a historically unparalleled flurry of activity which, ironically, may be superseded in the near future by the complete end of "keratoplasty" as a concept. Corneal grafts have steadily gotten smaller, thinner, and more peculiar. This applies to both transplants for the anterior, and the posterior, corneal surfaces. The logic motivating these innovations has been consistent: minimally invasive substitutions are to be preferred over wholesale replacements of corneal tissue. As new, tailored, lamellar operations have grown in popularity worldwide, we may be approaching a point where "transplantation" itself becomes unnecessary. Already, successful reports "descemetorrhexis only" treatments for patients with Fuchs Dystrophy are accumulating,[45] and in Japan, promising results with injectable endothelial cells are likewise emerging.[46]

Our former experience with Descemet Membrane Endothelial Transfer (DMET) demonstrated that - in eyes with Fuchs Dystrophy - recipient corneas would still clear (albeit over a longer time period) if an isolated DMEK graft were merely injected into the anterior chamber and placed into contact with the recipient posterior cornea without being unfolded.[47] The mechanism for this corneal clearance has been shown to be endothelial cell migration, although it is not presently known whether these cells are migrating out from the donor tissue, or in from the recipient periphery, stimulated by the presence of the donor graft. Regardless, the concept sticks that replacing a dysfunctional endothelial layer with a similarly positioned donor graft may be unnecessary, and that we might achieve the desired effect in a simpler and safer manner by some other intervention. If so, then this would mean that "keratoplasty" as a technique may soon be finished, at least for endothelial surgeries. For disorders of the anterior cornea, the introduction of UV-crosslinking and intracorneal ring segments have already cut heavily into the number of transplants being performed, and the BL transplantation may continue this trend away from PK and DALK. As a result, this may be simultaneously the most exciting - and possibly uncertain - time in history to be a corneal surgeon. And despite all the foregoing speculation about the future of corneal transplantation, it could also be some unforeseen advance that carries the profession forward.

REFERENCES

1. Reddy J, Hammersmith. K., Nagra P, Rapuano C. The Role of Penetrating Keratoplasty in the Era of Selective Lamellar Keratoplasty. Int Ophthalmol Clin. 2013;53(2):12.
2. Wisse R, van den Hoven C, Van der Lelij A. Does lamellar surgery for keratoconus experience the popularity it deserves? Acta Ophthalmol. 2014;92(5):473-477
3. Williams K, Ash J, Pararajasegaram P, Harris S, Coster D. Long-term outcome after corneal transplantation. Visual result and patient perception of success. Ophthalmology. 1991;98(5):651-7.
4. Uiters E, van den Borne B, van der Horst F, Völker-Dieben H. Patient satisfaction after corneal transplantation. Cornea. 2001;20(7):687-94.
5. Limaiem R, Chebil A, Baba A, et al. Pediatric penetrating keratoplasty: indications and outcomes. Transplant Proc. 2011;43(2):649-51.
6. Ganekal S, Gangangouda C, Dorairaj S, Jhanji V. Early outcomes of primary pediatric keratoplasty in patients with acquired, atraumatic corneal pathology. J AAPOS. 2011;15(4):353-5.
7. Cullen J, Butler H. Mongolism (down's syndrome) and keratoconus.Br J Ophthalmol. 1963;47: 321-30.
8. Giedd K, Mannis M, Mitchell G, Zadnik K. Personality in keratoconus in a sample of patients derived from the internet. Cornea. 2005;24(3):301-7.
9. Martin T, Reed J, Legault C, et al. Cataract formation and cataract extraction after penetrating keratoplasty. Ophthalmology. 1994;101(1):113-9.
10. Nagra P, Rapuano C, Laibson P, et al. Cataract extraction following penetrating keratoplasty. Cornea. 2004;23(4):377-9.
11. McClellan K, Lai T, Grigg J, Billson F. Penetrating keratoplasty in children: visual and graft outcome. Br J Ophthalmol. 2003;87(10):1212-4.
12. Kelly T, Coster D, Williams K. Repeat penetrating corneal transplantation in patients with keratoconus. Ophthalmology. 2011;118(8):1538-42.
13. Olson R, Pingree M, Ridges R, et al. Penetrating keratoplasty for keratoconus: a long-term review of results and complications. J Cataract Refract Surg. 2000;26(7):987-91.
14. Christo C, van Rooij J, Geerards A, Remeijer L, Beekhuis W. Suture-related complications following keratoplasty: a 5-year retrospective study. Cornea. 2001;20(8):816-9.
15. Patel S, Malta J, Banitt M, et al. Recurrent ectasia in corneal grafts and outcomes of repeat keratoplasty for keratoconus. Br J Ophthalmol. 2009;93(2):191-7.
16. Chan E, Snibson G. Current status of corneal collagen cross-linking for keratoconus: a review. Clin Exp Optom. 2013;96(2):155-64.
17. Piñero D, Alio J. Intracorneal ring segments in ectatic corneal disease - a review. Clin Experiment Ophthalmol. 2010;38(2):154-67.
18. Parker J, van Dijk K, Melles G. Treatment Options for Advanced Keratoconus: A Review. Surv. Ophth. 2015;60:459-80.
19. Parker J, van Dijk K, Melles G. Updates in Anterior Lamellar Keratoplasty: The State of The Debates. Expert Rev Ophthalmol. 2016. *In press*
20. Parker J, Konder R, van Dijk K, Melles G. Towards safer treatment options for advanced keratoconus. US Ophthalmic Review. 2015;8(1)33-4.
21. van Dijk K, Parker J, Tong C, et al. Midstromal isolated Bowman layer graft for reduction of advanced keratoconus: a technique to postpone penetrating or deep anterior lamellar keratoplasty. JAMA Ophthalmol. 2014;132(4):495-501.

22. van Dijk K, Liarakos V, Parker J, et al. Bowman layer transplantationto reduce and stabilize progressive, end stage, keratoconus. Ophthalmology. 2015;122:909-17.
23. Parker J, Parker J, van Dijk K, Liarakos V, Luceri S, Dapena I, Melles G. Bowman Layer Transplantation for Advanced Keratoconus: The First American Case. *Submitted*.
24. Luceri S, Parker J, Dapena I, Baydoun L, Oellerich S, van Dijk K, Melles GR. Corneal Densitometry and Higher Order Aberrations After Bowman Layer Transplantation: 1-Year Results. Cornea. 2016 Jul;35(7):959-66
25. KenyonKR. Morphology and pathologic responses of the cornea to disease. SmolinG ThoftRA eds. The Cornea. Scientific Foundations and Clinical Practice. 1983;45.Little, Brown & Co. Boston.
26. Livny E, Parker JS, van der Kaaij M, et al. Postmortem ultrastructural analysis of a cornea transplanted with Descemet membrane endothelial keratoplasty. Cornea. 2014;33:790-4
27. Baydoun L, Tong M, Tse W, Chi H, Parker J, Ham L, Melles GRJ. Endothelial Cell Density after Descemet Membrane Endothelial Keratoplasty: 1-5 Year Follow-up. Am J Ophthalmol. 2012;154: 762-3
28. Parker J, Dirisamer M, Naveiras M, Ham L, van der Wees J, Melles GR. "Endothelial Cell Density after Descemet Membrane Endothelial Keratoplasty: 1- to 4-Year Follow-up." Am J Ophthalmol. 2011; 151:1107-1107
29. Quilendrino R, Höhn H, Tse WH, et al. Do we overestimate the endothelial cell "loss" after descemet membrane endothelial keratoplasty? Curr Eye Res. 2013;38:260-5.
30. Terry MA, Chen ES, Shamie N, Hoar KL, Friend DJ. Endothelial cell loss after Descemet's stripping endothelial keratoplasty in a large prospective series. Ophthalmology. 2008;115:488-496.
31. Lee WB, Jacobs DS, Musch DC, et al. Descemet's stripping endothelial keratoplasty: safety and outcomes: a report by the American Academy of Ophthalmology. Ophthalmology. 2009;116: 1818-30.
32. Price MO, Calhoun P, Kollman C. Descemet Stripping Endothelial Keratoplasty: Ten-Year Endothelial Cell Loss Compared with Penetrating Keratoplasty. Ophthalmology. 2016;123:1421-7.
33. Rodríguez-Calvo-de-Mora M, Quilendrino R, Ham L, et al. Clinical outcome of 500 consecutive cases undergoing Descemet's membrane endothelial keratoplasty. Ophthalmology. 2015;122: 464-70.
34. Parker J, Parker J, Melles G. Descemet membrane endothelial keratoplasty (DMEK): a review. US Ophthalmic Review, 2013;6:29-32
35. van Dijk K, Parker J, Liarakos VS, Ham L, Frank LE, Melles GR. Incidence of irregular astigmatism eligible for contact lens fitting after Descemet membrane endothelial keratoplasty. J Cataract Refract Surg. 2013;39:1036-46.
36. Parker J, Dirisamer M, Naveiras M, Tse H, van Dijk K, Frank L, Ham L, Melles G. Outcome of descemet membrane endothelial keratoplasty in phakic eyes. J Cataract Refract Surg. 2012;38:871-7
37. Naveiras M, Dirisamer M, Parker J, Ham L, van Dijk K, Frank L, Dapena I, Melles G. Causes of glaucoma after Descemet Membrane Endothelial Keratoplasty (DMEK). Am J Ophthalmol. 2012;153: 958-966.e1
38. Dirisamer M, Parker J, Naveiras M, Liarakos V, Ham L, van Dijk K, Melles G. Identifying causes for poor visual outcome after DSEK/DSAEK following secondary DMEK in the same eye. Acta Ophthalmologica. 2013;91:131-9
39. Guerra FP, Anshu A, Price MO, Price FW. Endothelial keratoplasty: fellow eyes comparison of Descemet stripping automated endothelial keratoplasty and Descemet membrane endothelial keratoplasty. Cornea. 2011;30:1382-6
40. Melles GR. Posterior lamellar keratoplasty: DLEK to DSEK to DMEK. Cornea. 2006;25:879-81

41. Lam FC, Baydoun L, Dirisamer M, et al. Hemi-Descemet membrane endothelial keratoplasty transplantation: a potential method for increasing the pool of endothelial graft tissue. JAMA Ophthalmol. 2014;132:1469-73
42. Lam FC, Baydoun L, Satué M, et al. One year outcome of hemi-Descemet membrane endothelial keratoplasty. Graefes Arch Clin Exp Ophthalmol. 2015;253:1955-8
43. Gerber-Hollbach N, Parker J, Baydoun L, Liarakos V, Ham L, Dapena I, Melles G. "Preliminary outcome of hemi-DMEK for Fuchs Endothelial Dystrophy." Br J Ophthalmol. 2016 Feb 2. [Epub ahead of print]
44. Muller T, Lavy I, Baydoun L, et al. Case Report of Quarter-DMEK for Fuchs Endothelial Dystrophy. Cornea. *In press*
45. Borkar DS, Veldman P, Colby KA. Treatment of Fuchs Endothelial Dystrophy by Descemet Stripping Without Endothelial Keratoplasty. Cornea. 2016 15. [Epub ahead of print]
46. Okumura N, Kinoshita S, Koizumi N. Cell-based approach for treatment of corneal endothelial dysfunction. Cornea. 2014;33 Suppl 11:S37-41.
47. Dirisamer M, Ham L, Dapena I, van Dijk K, Melles GR. Descemet membrane endothelial transfer: "free-floating" donor Descemet implantation as a potential alternative to "keratoplasty". Cornea. 2012;31:194-7.

Chapter 10

Samenvatting en conclusies

BOWMAN LAYER TRANSPLANTATIE

Vandaag de dag blijven perforerende keratoplastiek (PK) en diepe anterieure lamellaire keratoplastiek (DALK) de standaard voor ogen met gevorderde keratoconus (KC) wanneer de gezichtsscherpte onaanvaardbaar wordt en/of contactlensintolerantie zich ontwikkeld (hoofdstukken 1,2, en 5).[1,2] Maar terwijl de uitkomsten van deze operaties vaak omschreven worden als 'goed', zijn er nog vele onopgeloste uitdagingen.[3,4]

KC patiënten zijn over het algemeen jong, in sommige gevallen zelfs zeer jong, waardoor de procedures zoals PK en DALK technisch uitdagend zijn en postoperatieve zorg moeilijker is, vooral in combinatie met een cognitieve of gedragsmatige beperking (wat niet zelden voorkomt).[5-8] Jonge ogen zijn vaak faak, en in de eerste jaren na de transplantatie kan zich cataract ontwikkelen. Hierdoor kan een cataractextractie noodzakelijk zijn wat potentieel traumatisch kan zijn voor het transplantaat.[9,10] Bij kinderen is de transplantaatoverleving reeds slechter dan bij volwassenen,[11] maar zelfs als de statistieken identiek zouden zijn, is het zeer waarschijnlijk dat jonge patiënten hun eerste transplantatie "overleven " en dan een re-operatie of zelfs re-operaties nodig zullen hebben. Omdat de resultaten van tweede en derde transplantaten vaak inferieur zijn aan de eerste, ervaren veel patiënten, met aanvankelijk goede resultaten, uiteindelijk problemen.[12] Dit geldt vooral omdat gevorderde KC vaak voorkomt in patiënten met een ernstig "ocular surface disease", welke kan verergeren door PK / DALK en daarbij behorende grote incisies, hechtingen, leidend tot een neurotrofe cornea.[13,14] Onder het oogoppervlak kunnen eveneens problemen met de wondgenezing worden gevonden, doordat het stroma bij de verbinding tussen het transplantaat en de ontvanger waarschijnlijk nooit helemaal goed geneest; dit predisponeert deze ogen voor traumatische breuk en voortschrijdende ectasie ter plaatse van de weefsel interface (en daarmee het "terugkeren" van de ziekte).[15]

Al deze problemen zijn fundamentele problemen inherent aan een DALK en PK en zijn daardoor waarschijnlijk niet op te lossen door verfijning van de operatietechniek of instrumentatie. De oplossing dient in plaats daarvan wellicht gezocht te worden in een geheel nieuwe chirurgische benadering, mogelijk een oplossing waarbij niet wordt uitgegaan van vervanging van de aangedane cornea. Sinds enkele jaren is er een sterke ontwikkeling gaande om reeds bij mildere KC, alvorens een PK of DALK (en hun bijbehorende complicaties) noodzakelijk wordt, te proberen de progressie af te remmen of te stoppen. Zowel ultraviolet-crosslinking (UV-CXL) als intracorneale ringsegmenten (ICRS) lijken succesvol toepasbaar te zijn voor dit doeleinde. Toch lijken veel ogen niet in aanmerking te komen voor deze behandelingen. Corneas die steiler zijn dan 58 dioptrie (D) of dunner dan 400 µm, bijvoorbeeld, komen volgens gepubliceerde veiligheidsrichtlijnen niet in aanmerking voor ICRS of UV-CXL.[16,17] Verder zijn in de Verenigde Staten

ICRS niet goedgekeurd bij patiënten jonger dan 18 jaar oud, en is UV-CXL - onlangs gelegaliseerd - nog niet wijd verspreid.[16,17]

Daarnaast zijn hoornvliezen met voorafgaande herpes aandoening uitgesloten van UV-CXL, en een geschiedenis met recidiverende erosie sluit het gebruik van ICRS uit.[16,17] Kortom, om verschillende redenen, lijken veel patiënten met "actieve" of "lopende" KC niet in aanmerking te komen voor deze therapieën, kan de aandoening dus bij veel patiënten niet afgeremd worden[18], terwijl zich contactlensintolerantie kan ontwikkelen. Veel patiënten krijgen dan ofwel PK of DALK en worden onderworpen aan de mogelijke complicaties.

Een operatie om keratoconusprogressie tegen te gaan in ogen die ongeschikt zijn voor UV-CXL of ICRS, en voordat PK of DALK nodig is, lijkt dus hard nodig.[18-20] Dit was de reden dat wij in 2014 begonnen met ons onderzoek naar een nieuwe operatietechniek die bekend staat als Bowman layer (BL) transplantatie (hoofdstuk 3).[21] Eén van de meest gevoelige en specifieke uitingen van KC is fragmentatie van de BL waardoor destabilisatie van de omliggende cornea optreedt, voorafgaand aan voortschrijdende ectasie. Dientengevolge redeneerden wij dat een transplantatie van een geïsoleerde BL het hoornvlies af zou kunnen vlakken naar een meer normale architectuur en door versterking verdere vervorming zou kunnen voorkomen.

Voor onze eerste operaties kozen wij alleen patiënten met ernstige KC, allemaal met maximale keratometrie waarden ≥70D. De operatie zelf bestond uit het manueel creëren van een midstromale pocket, limbus tot limbus in 360°, in het ontvangende hoornvlies, waarna een geïsoleerd BL transplantaat werd geïmplanteerd. Operaties in deze eerste reeks waren zonder complicaties, behalve in twee gevallen waarbij een intra-operatieve perforatie van het membraan van Descemet ontstond tijdens de manuele dissectie. In de eerste 10 ogen waarbij deze techniek werd uitgevoerd, waren een jaar na de operatie noch het met bril gecorrigeerde zicht noch het met contactlens gecorrigeerde zicht significant veranderd ten opzichte van preoperatief.[21] De ontvangende cornea liet van pre- naar postoperatief een afvlakking van gemiddeld 8-9 D zien, waarna in alle gevallen de progressie van de ziekte werd voorkomen en het comfortabel dragen van contactlenzen mogelijk bleef, of weer mogelijk werd.[21]

Sinds onze oorspronkelijke studie zijn er meer patiënten met dezelfde techniek geopereerd, zowel in Nederland als nu ook in de Verenigde Staten (hoofdstuk 4).[22,23] Over het algemeen lijkt de operatie in >90% van de ogen effectief in het stoppen van voortschrijdende ectasie (nu met een gemiddelde follow-up periode van meer dan 3 jaar, en in sommige patiënten nu 5 jaar na de operatie). Bovendien is een lichte gemiddelde verbetering in de met bril gecorrigeerde gezichtsscherpte waargenomen (van 20/400 tot 20/125). Waarschijnlijk weerspiegelt deze verbetering een "normalisering" van het oogoppervlak, omdat - na BL transplantatie - hogere order aberraties (vooral de sferische aberratie) significant verminderen.[24] Tot op heden zijn geen bekende

postoperatieve complicaties waargenomen. In het bijzonder zijn er geen problemen opgetreden met betrekking tot het anterieure cornea oppervlak (waarschijnlijk omdat bij de techniek geen gebruik wordt gemaakt van corneale incisies of hechtingen), noch zijn er gevallen van ofwel cataract of allograft reactie bekend. In feite lijkt het risico op transplantaatafstoting beduidend verminderd, omdat het BL transplantaat acellulair is.[19,23,25] Hierdoor zijn er veel minder (en misschien geen) postoperatieve steroïden nodig, en wordt hiermee een belangrijke bron van postoperatief risico vermeden.

Tot nu toe heeft onze ervaring met de BLtransplantatie ons ertoe gebracht te veronderstellen dat de operatie een veelbelovende manier kan zijn om keratoconusprogressie af te remmen, zelfs in die ogen die niet in aanmerking komen voor andere procedures. Langere en grotere studies zijn nodig, maar het is mogelijk dat bij voortzetting van de inspanningen de traditie van endotheliale keratoplastiek voortgezet kan worden, het idee van volledige dikte hoornvliestransplantatie opgevend, en in plaats daarvan kiezend voor een minimaal invasieve en specifiek ziekte corrigerende interventie.

DESCEMET MEMBRANE ENDOTHELIALE KERATOPLASTY (DMEK)

Voor corneale endotheliale aandoeningen bestaan er verschillende technieken, waarbij Descemet Membrane Endotheliale Keratoplasty (DMEK) zijn voorganger Descemet Stripping (Automated) Endotheliale Keratoplasty (DS(A)EK) zou kunnen vervangen als de procedure van keuze (hoofdstuk 6).[26] Met een transplantaat, uitsluitend bestaand uit een geïsoleerde Descemet membraan en het bijbehorende endotheel, bewerkstelligt DMEK een één-op-één vervanging van aangedaan weefsel door donorweefsel, waardoor een vrijwel volledig anatomische herstel van de ontvangende cornea mogelijk is (hoofdstuk 6).[26]

Onmiddellijk na de operatie wordt een scherpe daling van ongeveer 35% van de preoperatieve endotheelceldichtheid van het DMEK-transplantaat gemeten (hoofdstuk 7).[27,28] Hoewel deze daling vaak wordt uitgedrukt als "celverlies" als gevolg van intraoperatieve weefsel manipulatie, is deze uitleg wellicht overdreven simplistisch omdat ook andere factoren een rol kunnen spelen, zoals bijvoorbeeld celmigratie en/of celherverdeling vanaf het transplantaat naar aangrenzende plaatsen op het ontvangende posterieure stroma.[29] Zes maanden na de operatie wordt er echter een vermindering in het tempo van het celverlies waargenomen en lijkt deze daling op een laag niveau (ongeveer 5% per jaar) te stabiliseren. Dit patroon komt overeen met de daling geconstateerd na DS(A)EK, en verschilt van de trends na "deep lamellar endotheliale keratoplasty" (DLEK) en PK, die beiden een voortschrijdende lineaire afname in celdichtheid tonen.[30-32]

De gemiddelde best-gecorrigeerde visus (BCVA) na DMEK is 20/25 (0.8), welke over het algemeen drie maanden postoperatief bereikt wordt, gepaard gaande met een

minimale hyperopische verandering.[33] Dit in tegenstelling tot de gemiddelde visus, hersteltijden en refractieve verschuivingen na zowel PK en DS(A)EK: na PK hersteld de BCVA gemiddeld slechts tot 20/40 (0.5) een jaar postoperatief, en is vaak vergezeld door ernstig astigmatisme; zes maanden postoperatief bedraagt de BCVA na DS(A)EK gemiddeld 20/30, met een over het algemeen tweemaal grotere hyperopische verandering dan bij DMEK.[34] De visuele resultaten na DMEK lijken echter beperkt door de conditie van het anterieure corneale oppervlak en van de lensstatus van het ontvangende oog. In het bijzonder lijkt langdurig cornea-oedeem verantwoordelijk te zijn voor anterieure stromale littekenvorming / fibrose, die niet volledig lijkt te verdwijnen na DMEK.[35] Daarom kan het raadzaam zijn om het endotheel reeds in een vroeger stadium van de endotheelaandoening te vervangen, voordat deze anterieure stromale veranderingen optreden. Terwijl fake en pseudofake patiënten dezelfde gemiddelde visuele resultaten na de operatie lijken te bereiken, worden de "extreem" goede visusresultaten vaker gevonden in fake ogen, wijzend op enig optisch voordeel bij het behoud van de natuurlijke ooglens (hoofdstuk 8).[36] In tegenstelling tot fake ogen die DS(A)EK ondergaan, lijkt cataractvorming na DMEK een minder grote rol te spelen, mogelijk als gevolg van de lagere postoperatieve steroïd belasting. In onze serie bleek slechts 4% van fake DMEK ogen binnen een follow-up periode van twee jaar een phacoemulsificatie nodig te hebben.[36] Fake ogen die DMEK ondergaan vertonen echter wel een unieke gevoeligheid voor luchtbel -geïnduceerd "angle-closure" glaucoom, waarbij de postoperatief achtergebleven luchtbel tegen de lens duwt, welke vervolgens naar voren kantelt en hierbij het trabecular meshwork afsluit.[37] Om dit te voorkomen, is het aan te raden om bij fake ogen een kleinere luchtbel aan het einde van de operatie achter te laten: 50% van het volume van de voorste oogkamer in plaats van 75% zoals aanbevolen bij pseudofake ogen. Interessant genoeg tonen op deze wijze behandelde fake ogen geen hoger percentage postoperatief afliggende transplantaten in vergelijking met behandelde pseudofake ogen, hetgeen suggereert dat de postoperatieve luchtbel minder kritisch is voor transplantaataanhechting dan tot nu toe aangenomen.[36]

Omdat er bij DS(A)EK een stroma-tot-stroma interface op het grensvlak van donor naar ontvanger aanwezig is en omdat deze interface sterk reflectief en onregelmatig kan zijn, kan de optische kwaliteit van getransplanteerde ogen hieronder lijden. Andere redenen voor een verminderde gezichtsscherpte na DS(A)EK omvatten stromale "golven" in de donor lenticule als gevolg van een mismatch in corneakromming tussen de ontvanger en het transplantaat, en Descemet membraan "restanten" in de interface. Als gevolg van deze drie factoren kunnen ogen, na een ongecompliceerde DS(A)EK operatie en een normaal postoperatief verloop met een goed aanliggend transplantaat, toch een onbevredigend visueel resultaat bereiken.[38] Re-operaties, waarbij het DS(A) EK-transplantaat werd vervangen door een DMEK-transplantaat, hebben een aanmerkelijke visuele verbetering aangetoond in deze gevallen, waarschijnlijk omdat DMEK-

transplantaten - zonder stroma – zich beter kunnen aanpassen aan de ontvangende posterieure cornea en minder littekenvorming induceren. Bovendien hebben afzonderlijke studies onafhankelijk aangetoond dat – wanneer geopereerd met beide technieken - patiënten subjectief de voorkeur geven aan het zicht van het DMEK-oog.[39] Alles bij elkaar bevestigen deze resultaten de achterliggende filosofie van DMEK dat de operatie het oog hersteld naar een bijna-normale anatomie, dit in tegenstelling tot PK, DLEK en zelfs DS(A)EK.[40] Momenteel zijn er ook al voorlopige resultaten voorhanden van een gemodificeerde vorm van DMEK, de zogenaamde Hemi-DMEK, waarbij één groot, rond DMEK-transplantaat in tweeën wordt gedeeld en elk hemi-cirkelvormige transplantaat wordt geïmplanteerd in een andere ontvanger.[41-43] Omdat ongeveer hetzelfde aantal cellen als met een "normaal" DMEK-transplantaat wordt getransplanteerd met elk van de twee Hemi-DMEK-transplantaten, en omdat het donorweefsel op dezelfde manier gepositioneerd wordt tegen de ontvangende cornea, zou verwacht kunnen worden dat de snelheid en mate van herstel van het gezichtsvermogen voor beide operaties vergelijkbaar is, wat ook wordt bevestigd in onze eerste resultaten. Een mogelijk, theoretisch voordeel van Hemi-DMEK ten opzichte van standaard /conventionele DMEK is dat, door elk donorweefsel in tweeën te verdelen, Hemi-DMEK het tekort aan voor transplantatie beschikbaar weefsel zou kunnen verminderen. Hemi-DMEK zou zich verder kunnen ontwikkelen tot "Kwart-DMEK" waarbij het donorweefsel in vieren wordt verdeeld.[44] Anderszins worden er vorderingen gemaakt met de ontwikkeling van injecties met gekweekte humane endotheliale cellen, of zelfs "keratoplastiek-vrije" oplossingen, waarbij in zijn geheel afstand wordt gedaan van het concept van donormateriaal.[45,46]

SLOTOPMERKINGEN

De afgelopen twee decennia kennen een explosie aan nieuwe keratoplastiek technieken, een historisch ongekende vlaag van activiteit die, ironisch genoeg, in de nabije toekomst mogelijk wordt vervangen door het volledige einde van "keratoplastiek" als concept. Corneatransplantaten zijn gestaag kleiner, dunner, en meer specifiek geworden. Dit geldt zowel voor transplantatie voor de voorste als de achterste corneale oppervlakken. De logische motivatie van deze innovaties is duidelijk: minimaal invasieve substituties geven de voorkeur boven de vervanging van de gehele cornea. Zoals de nieuwe, op maat gemaakte, lamellaire operaties wereldwijd in populariteit zijn gegroeid, naderen we nu een punt waarbij "corneatransplantatie" zelfs overbodig wordt, zoals aangetoond met succesvolle verslagen van een "descemetorrhexis alleen" bij patiënten met Fuchse dystrofie,[45] en de veelbelovende resultaten met injecteerbare endotheelcellen die vanuit Japan worden gerapporteerd.[46]

Onze eerdere ervaringen met Descemet Membrane endothelial Transfer (DMET) toonden aan dat - in ogen met Fuchse dystrofie - ontvangende hoornvliezen ook helder werden (zij het over een langere periode) als een geïsoleerd DMEK-transplantaat in de voorste oogkamer werd geïnjecteerd en in contact werd gebracht met de ontvangende posterieure cornea maar zonder te worden ontvouwen.[47] Het aangetoonde mechanisme hierachter lijkt endotheelcelmigratie, hoewel het momenteel niet bekend is of deze cellen migreren vanuit het donorweefsel of vanuit de periferie van de ontvangende cornea tot deling worden gestimuleerd door de aanwezigheid van het donor transplantaat. Ongeacht het mechanisme, het concept laat zien dat het gewenste effect op een eenvoudiger en veiliger manier met een andere interventie bereikt zou kunnen worden. Zo ja, dan zou dit betekenen dat "keratoplastiek" als techniek kan worden vervangen, althans voor endotheliale operaties. Voor aandoeningen van de anterieure cornea heeft de introductie van UV-crosslinking en intracorneale ringsegmenten er al sterk voor gezorgd dat het aantal uitgevoerde corneatransplantaties, zoals PK en DALK, is verminderd, en BL transplantatie kan deze trend voortzetten. Dit maakt dit een opwindende tijd in de geschiedenis van de corneachirurgie, en ondanks alle voorgaande speculaties over de toekomst van de hoornvliestransplantatie zouden het wellicht juist onvoorziene ontwikkelingen kunnen zijn die dit subspecialisme verder zullen stimuleren.

REFERENCES

1. Reddy J, Hammersmith. K., Nagra P, Rapuano C. The Role of Penetrating Keratoplasty in the Era of Selective Lamellar Keratoplasty. Int Ophthalmol Clin. 2013;53(2):12.
2. Wisse R, van den Hoven C, Van der Lelij A. Does lamellar surgery for keratoconus experience the popularity it deserves? Acta Ophthalmol. 2014;92(5):473-477
3. Williams K, Ash J, Pararajasegaram P, Harris S, Coster D. Long-term outcome after corneal transplantation. Visual result and patient perception of success. Ophthalmology. 1991;98(5):651-7.
4. Uiters E, van den Borne B, van der Horst F, Völker-Dieben H. Patient satisfaction after corneal transplantation. Cornea. 2001;20(7):687-94.
5. Limaiem R, Chebil A, Baba A, et al. Pediatric penetrating keratoplasty: indications and outcomes. Transplant Proc. 2011;43(2):649-51.
6. Ganekal S, Gangangouda C, Dorairaj S, Jhanji V. Early outcomes of primary pediatric keratoplasty in patients with acquired, atraumatic corneal pathology. J AAPOS. 2011;15(4):353-5.
7. Cullen J, Butler H. Mongolism (down's syndrome) and keratoconus.Br J Ophthalmol. 1963;47: 321-30.
8. Giedd K, Mannis M, Mitchell G, Zadnik K. Personality in keratoconus in a sample of patients derived from the internet. Cornea. 2005;24(3):301-7.
9. Martin T, Reed J, Legault C, et al. Cataract formation and cataract extraction after penetrating keratoplasty. Ophthalmology. 1994;101(1):113-9.
10. Nagra P, Rapuano C, Laibson P, et al. Cataract extraction following penetrating keratoplasty. Cornea. 2004;23(4):377-9.
11. McClellan K, Lai T, Grigg J, Billson F. Penetrating keratoplasty in children: visual and graft outcome. Br J Ophthalmol. 2003;87(10):1212-4.
12. Kelly T, Coster D, Williams K. Repeat penetrating corneal transplantation in patients with keratoconus. Ophthalmology. 2011;118(8):1538-42.
13. Olson R, Pingree M, Ridges R, et al. Penetrating keratoplasty for keratoconus: a long-term review of results and complications. J Cataract Refract Surg. 2000;26(7):987-91.
14. Christo C, van Rooij J, Geerards A, Remeijer L, Beekhuis W. Suture-related complications following keratoplasty: a 5-year retrospective study. Cornea. 2001;20(8):816-9.
15. Patel S, Malta J, Banitt M, et al. Recurrent ectasia in corneal grafts and outcomes of repeat keratoplasty for keratoconus. Br J Ophthalmol. 2009;93(2):191-7.
16. Chan E, Snibson G. Current status of corneal collagen cross-linking for keratoconus: a review. Clin Exp Optom. 2013;96(2):155-64.
17. Piñero D, Alio J. Intracorneal ring segments in ectatic corneal disease - a review. Clin Experiment Ophthalmol. 2010;38(2):154-67.
18. Parker J, van Dijk K, Melles G. Treatment Options for Advanced Keratoconus: A Review. Surv. Ophth. 2015;60:459-80.
19. Parker J, van Dijk K, Melles G. Updates in Anterior Lamellar Keratoplasty: The State of The Debates. Expert Rev Ophthalmol. 2016. *In press*
20. Parker J, Konder R, van Dijk K, Melles G. Towards safer treatment options for advanced keratoconus. US Ophthalmic Review. 2015;8(1)33-4.
21. van Dijk K, Parker J, Tong C, et al. Midstromal isolated Bowman layer graft for reduction of advanced keratoconus: a technique to postpone penetrating or deep anterior lamellar keratoplasty. JAMA Ophthalmol. 2014;132(4):495-501.

22. van Dijk K, Liarakos V, Parker J, et al. Bowman layer transplantationto reduce and stabilize progressive, end stage, keratoconus. Ophthalmology. 2015;122:909-17.
23. Parker J, Parker J, van Dijk K, Liarakos V, Luceri S, Dapena I, Melles G. Bowman Layer Transplantation for Advanced Keratoconus: The First American Case. *Submitted*.
24. Luceri S, Parker J, Dapena I, Baydoun L, Oellerich S, van Dijk K, Melles GR. Corneal Densitometry and Higher Order Aberrations After Bowman Layer Transplantation: 1-Year Results. Cornea. 2016 Jul;35(7):959-66
25. KenyonKR. Morphology and pathologic responses of the cornea to disease. SmolinG ThoftRA eds. The Cornea. Scientific Foundations and Clinical Practice. 1983;45.Little, Brown & Co. Boston.
26. Livny E, Parker JS, van der Kaaij M, et al. Postmortem ultrastructural analysis of a cornea transplanted with Descemet membrane endothelial keratoplasty. Cornea. 2014;33:790-4
27. Baydoun L, Tong M, Tse W, Chi H, Parker J, Ham L, Melles GRJ. Endothelial Cell Density after Descemet Membrane Endothelial Keratoplasty: 1-5 Year Follow-up. Am J Ophthalmol. 2012;154:762-3
28. Parker J, Dirisamer M, Naveiras M, Ham L, van der Wees J, Melles GR. "Endothelial Cell Density after Descemet Membrane Endothelial Keratoplasty: 1- to 4-Year Follow-up." Am J Ophthalmol. 2011; 151:1107-1107
29. Quilendrino R, Höhn H, Tse WH, et al. Do we overestimate the endothelial cell "loss" after descemet membrane endothelial keratoplasty? Curr Eye Res. 2013;38:260-5.
30. Terry MA, Chen ES, Shamie N, Hoar KL, Friend DJ. Endothelial cell loss after Descemet's stripping endothelial keratoplasty in a large prospective series. Ophthalmology. 2008;115:488-496.
31. Lee WB, Jacobs DS, Musch DC, et al. Descemet's stripping endothelial keratoplasty: safety and outcomes: a report by the American Academy of Ophthalmology. Ophthalmology. 2009;116: 1818-30.
32. Price MO, Calhoun P, Kollman C. Descemet Stripping Endothelial Keratoplasty: Ten-Year Endothelial Cell Loss Compared with Penetrating Keratoplasty. Ophthalmology. 2016;123:1421-7.
33. Rodríguez-Calvo-de-Mora M, Quilendrino R, Ham L, et al. Clinical outcome of 500 consecutive cases undergoing Descemet's membrane endothelial keratoplasty. Ophthalmology. 2015;122: 464-70.
34. Parker J, Parker J, Melles G. Descemet membrane endothelial keratoplasty (DMEK): a review. US Ophthalmic Review, 2013;6:29-32
35. van Dijk K, Parker J, Liarakos VS, Ham L, Frank LE, Melles GR. Incidence of irregular astigmatism eligible for contact lens fitting after Descemet membrane endothelial keratoplasty. J Cataract Refract Surg. 2013;39:1036-46.
36. Parker J, Dirisamer M, Naveiras M, Tse H, van Dijk K, Frank L, Ham L, Melles G. Outcome of descemet membrane endothelial keratoplasty in phakic eyes. J Cataract Refract Surg. 2012;38:871-7
37. Naveiras M, Dirisamer M, Parker J, Ham L, van Dijk K, Frank L, Dapena I, Melles G. Causes of glaucoma after Descemet Membrane Endothelial Keratoplasty (DMEK). Am J Ophthalmol. 2012;153: 958-966.e1
38. Dirisamer M, Parker J, Naveiras M, Liarakos V, Ham L, van Dijk K, Melles G. Identifying causes for poor visual outcome after DSEK/DSAEK following secondary DMEK in the same eye. Acta Ophthalmologica. 2013;91:131-9
39. Guerra FP, Anshu A, Price MO, Price FW. Endothelial keratoplasty: fellow eyes comparison of Descemet stripping automated endothelial keratoplasty and Descemet membrane endothelial keratoplasty. Cornea. 2011;30:1382-6
40. Melles GR. Posterior lamellar keratoplasty: DLEK to DSEK to DMEK. Cornea. 2006;25:879-81

41. Lam FC, Baydoun L, Dirisamer M, et al. Hemi-Descemet membrane endothelial keratoplasty transplantation: a potential method for increasing the pool of endothelial graft tissue. JAMA Ophthalmol. 2014;132:1469-73
42. Lam FC, Baydoun L, Satué M, et al. One year outcome of hemi-Descemet membrane endothelial keratoplasty. Graefes Arch Clin Exp Ophthalmol. 2015;253:1955-8
43. Gerber-Hollbach N, Parker J, Baydoun L, Liarakos V, Ham L, Dapena I, Melles G. "Preliminary outcome of hemi-DMEK for Fuchs Endothelial Dystrophy." Br J Ophthalmol. 2016 Feb 2. [Epub ahead of print]
44. Muller T, Lavy I, Baydoun L, et al. Case Report of Quarter-DMEK for Fuchs Endothelial Dystrophy. Cornea. *In press*
45. Borkar DS, Veldman P, Colby KA. Treatment of Fuchs Endothelial Dystrophy by Descemet Stripping Without Endothelial Keratoplasty. Cornea. 2016 15. [Epub ahead of print]
46. Okumura N, Kinoshita S, Koizumi N. Cell-based approach for treatment of corneal endothelial dysfunction. Cornea. 2014;33 Suppl 11:S37-41.
47. Dirisamer M, Ham L, Dapena I, van Dijk K, Melles GR. Descemet membrane endothelial transfer: "free-floating" donor Descemet implantation as a potential alternative to "keratoplasty". Cornea. 2012;31:194-7.

SCIENTIFIC PUBLICATIONS

1. **Parker J**, Krijgsman M, van Dijk K, Melles GRJ. Patient experience with office-based corneal transplantation. *Cornea 2017;36:445-447*.
2. Luceri S, **Parker J**, Dapena I, Baydoun L, Oellerich S, van Dijk K, Melles GRJ. Letter to the Editor: Reply to Keratoconus and Bowman Layer *Transplantation 2017;36:e8-e9*.
3. **Parker J**, Huls F, Cooper E, Graves P, Groeneveld-van Beek E, Lie J, Melles G. Technical feasibility of isolated Bowman layer graft preparation by femtosecond laser: a pilot study. *Eur J Ophthalmol*. *In press*
4. **Parker J**, Verdijk R, Muller T, Lavy I, Bruinsma M, Colby K, Binder P, Melles G. Histopathology of failed Descemet membrane endothelial transfer (DMET). Eye & Contact Lens *In press*
5. Cooper E, **Parker J**, Parker J, Melles GRJ. Descemet Membrane Endothelial Keratoplasty in an eye with Fuchs Endothelial Dystrophy and Keratoconus. Ophthalmology @ Point of Care Journals *In press*
6. Parker J, Morris R, Rooney D, **Parker J**. Boston Type 1 Keratoprosthesis: Visual Outcomes, Device Retention, and Complications. Cornea *In press*
7. Lavy I, Liarakos V, Müller T, **Parker J**, Bruinsma M, Melles G. Clinical outcome and histopathology of secondary penetrating keratoplasty failure managed by Descemet membrane endothelial keratoplasty (DMEK). Cornea *2017 Mar 21 [Epub ahead of print]*
8. Baydoun L, Müller T, Lavy I, **Parker J**, Calvo de Mora M, Liarakos V, Dapena I, Melles GR. Ten-year clinical outcome of the first patient undergoing Descemet Membrane Endothelial Keratoplasty (DMEK). *Cornea 2017;36:379-381*.
9. Müller TM, Verdijk RM, Lavy I, Bruinsma M, **Parker J**, Binder PS, Melles GR. Histopathologic features of Descemet membrane endothelial keratoplasty graft remnants, folds, and detachments. Ophthalmology *2016;12:2489-2497*.
10. Jijelava K, Le H, **Parker J**, Yee J. Getting Hooked: A Simple Technique for the Treatment of Adhesive Injuries to the Eyelids. J Emerg Med. 2016 pii: S0736-4679(16)30724-7.
11. Preda-Naumescu, Everett A, **Parker J**. A Simplified, Standardized Technique for Malyugin Ring Extraction. *J Cataract Refract Surg. 2016;42:1533-1534*.
12. **Parker J**, van Dijk K, Melles G. Updates in Anterior Lamellar Keratoplasty: The State of The Debates. *Expert Rev Ophthalmol. 2016;11:339-346*.
13. Groeneveld-van Beek EA, **Parker J**, Lie JT, Bourgonje V, Ham L, van Dijk K, van der Wees J, Melles GR. Donor Tissue Preparation for Bowman Layer Transplantation. *Cornea 2016;35:1499-1502*.
14. Luceri S, **Parker J**, Dapena I, Baydoun L, Oellerich S, van Dijk K, Melles GR. Corneal Densitometry and Higher Order Aberrations After Bowman Layer Transplantation: 1-Year Results. *Cornea 2016;35:959-966*.
15. Gerber-Hollbach N, **Parker J**, Baydoun L, Liarakos V, Ham L, Dapena I, Melles GR. Preliminary outcome of hemi- Descemet membrane endothelial keratoplasty for Fuchs Endothelial Dystrophy. *Br J Ophthalmol. 2016;100:1564-1568*.
16. **Parker J**, Huisingh C, McGwin G. Value of the P value. *J Neuroophthalmol. 2015;35: 233-234*.
17. van Dijk K, Liarakos V, **Parker J**, Ham L, Lie JT, Groenveld-van Beek EA, Melles GRJ. Bowman layer transplantation to reduce and stabilize progressive, end stage, keratoconus. *Ophthalmology 2015;122:909-91.7*
18. **Parker J,** Konder R, van Dijk K, Melles G. Towards safer treatment options for advanced keratoconus. *US Ophthalmic Review. 2015;8:33-34*.

19. **Parker J**, van Dijk K, Melles GR. Treatment Options for Advanced Keratoconus: A Review. *Surv. Ophth. 2015;60:459-480.*
20. Livny E, **Parker J,** van der Kaaij M, Haasdijk E, van der Wees J, Bruinsma M, Melles GRJ. Post-mortem ultra-structural analysis of a transplanted Descemet Membrane Endothelial Keratoplasty (DMEK) graft. *Cornea 2014;33:790-794.*
21. Li M, Jia C, Kazmierkiewicz K, Bowman, A Tian L, Liu Y, Gupta N, Yee S, Gudsieva H, Dentchev T, Kimble J, **Parker J**, Messinger J, Curcio C, Stambolian D. Transcriptome Landscape of the Human Neurosensory Retina and Photoreceptor Support System. *Hum Mol Genet. 2014;23:4001-4014.*
22. van Dijk K, **Parker J**, Tong M, Ham L, Lie JT, Groeneveld-van Beek EA, Melles GR. Midstromal isolated Bowman layer graft for reduction of advanced keratoconus: a technique to postpone penetrating or deep anterior lamellar keratoplasty. *JAMA Ophthalmol. 2014;132:495-501.*
23. van Dijk K, **Parker J**, Liarakos VS, Ham L, Frank LE, Melles GR. Incidence of irregular astigmatism eligible for contact lens fitting after Descemet membrane endothelial keratoplasty. *J Cataract Refract Surg. 2013;39:1036-1046.*
24. **Parker J**, Parker J, Melles G. Descemet membrane endothelial keratoplasty (DMEK): a review. *US Ophthalmic Review 2013;6:29-32.*
25. Baydoun L, Tong M, Tse W, Chi H, **Parker J**, Ham L, Melles GRJ. Endothelial cell density after Descemet membrane endothelial keratoplasty: 1-5 Year Follow-up. *Am J Ophthalmol. 2012;154:762-763.*
26. Dirisamer M, **Parker J,** Naveiras M, Liarakos V, Ham L, van Dijk K, Melles GR. Identifying causes for poor visual outcome after DSEK/DSAEK following secondary DMEK in the same eye. *Acta Ophthalmol. 2013;91:131-139.*
27. **Parker J**, Dirisamer M, Naveiras M, Tse WH, van Dijk K, Frank LE, Ham L, Melles GR. Outcomes of Descemet membrane endothelial keratoplasty in phakic eyes. *J Cataract Refract Surg. 2012;38:871-877.*
28. Naveiras M, Dirisamer M, **Parker J**, Ham L, van Dijk K, Dapena I, Melles GR. Causes of glaucoma after Descemet membrane endothelial keratoplasty. *Am J Ophthalmol. 2012;153:958-966.e1.*
29. Friedman D, **Parker J**, Kimble J, Delori F, McGwin G, Curcio C. Quantification of fluorescein-stained drusen associated with age-related macular degeneration. *Retina 2012; 32:19-24.*
30. **Parker J**, Dirisamer M, Naveiras M, Ham L, van der Wees J, Melles GR. Endothelial cell density after Descemet membrane endothelial keratoplasty: 1- to 4-Year Follow-up. *Am J Ophthalmol. 2011;151:1107-1107.e2.*
31. Cogen M, **Parker J**, Sleep T, Elsas F, Metz T, McGwin G. Masked Trial of Topical Anesthesia for Retinopathy of Prematurity Eye Examinations. *J AAPOS. 2011;15:45-48*
32. Myrowitz EH, Kurwa A, **Parker J**, Chuck RS. Wavefront-guided photorefractive keratectomy after radial keratotomy in nine eyes. *J Refract Surg. 2009;25:470-472.*
33. Zhu L, Shen J, Zhang C, Park CY, Kohanim S, Yew M, **Parker J**, Chuck R. Inflammatory Cytokine Expression on the Ocular Surface in the Botulium Toxin B Induced Murine Dry Eye Model. *Mol Vis. 2009;15:250-258.*
34. Park CY, Chuck RS, Cano M, Yew M, Nguyen V, **Parker** J, Mori K, Gehlbach PL. Periocular triamcinolone enhances intraocular gene expression after delivery by adenovirus. *Invest Ophthalmol Vis Sci. 2008;49:399-406.*
35. Castro-Combs J, Noguera G, Cano M, Yew M, Gehlbach PL, **Palmer J**, Behrens A. Corneal wound healing is modulated by topical application of amniotic fluid in an ex vivo organ culture model. *Exp Eye Res. 2008;87:56-63.*

ACKNOWLEDGMENTS

Spending time with Gerrit Melles has been one of the greatest fortunes of my life. He is an almost unbelievable collection of superlatives; simultaneously, one of the warmest, most charismatic, most generous, most productive men I have ever known. More than any accomplishment, I am proud to have been his student and to be his friend.

Aside from Gerrit, there are many other people who deserve my eternal gratitude and without whom, this thesis would have been impossible. To list only a few:

My father, who is and will always be my hero; my mother, who has been my biggest advocate; my sisters (Christine, Rebecca, Allison, and Melissa) who are the greatest joys in my life; and my brilliant and beautiful fiancé, Christina, who is my inspiration, my love, and my best friend.

Otherwise, there are my colleagues at the NIIOS: Isabel Dapena, Vasilis Liarakos, and Lamis Baydoun - thank you so much for your kindness, your experience, and your direction. Korine van Dijk - thank you for being my partner in so many projects; Silke Oellerich for your many invaluable insights; Christa de Kort for helping me with my Dutch; the Amnitrans Eyebank crew (Jacqueline van der Wees, Jessica Lie, and Esther Groenveld van-Beek) for all the training; Lisanne Ham for being my teacher from the very beginning; and to Martin Dirisamer and Miguel Navieres - two of my very best friends.

Finally, I would like to thank my advisor and mentor, Prof. Jager, without whom this thesis could never have been realized.

CURRICULUM VITAE

John Steven Parker, Jr. (Jack) was born on August 16th, 1986 in Birmingham, AL, USA and raised in the surrounding suburbs. He finished his undergraduate education in 2004 at the University of Alabama with major and minor degrees in political science and chemistry, respectively, before matriculating to medical school at the University of Alabama in Birmingham (UAB) in the fall of the same year. Upon graduation, he completed a transitional-year internship at the Baptist Health Systems hospitals and an ophthalmology residency at the UAB Callahan Eye Hospital, both also in Birmingham, Alabama.

His interaction with the Netherlands Institute for Innovative Ocular Surgery (NIIOS) began midway through medical school in 2010, when he travelled to Rotterdam to work with Dr. Melles as a visiting research student. That experience ultimately developed into an ongoing relationship and research partnership. Most recently, Jack has begun a fellowship position jointly offered by his father's practice (Parker Cornea) in Alabama and the NIIOS in Rotterdam.