Pharmaceutical stabilization of abdominal aortic aneurysms : changing its natural history

Kokje, V.B.C.

Author: Kokje, Vivianne
Title: Pharmaceutical stabilization of abdominal aortic aneurysms : changing its natural history
Issue Date: 2017-06-28

Chapter 1

INTRODUCTION

ABDOMINAL AORTIC ANEURYSM

An abdominal aortic aneurysm (AAA) is a dilatation of the infrarenal aorta. The most accepted definition of an AAA is based on its diameter. A diameter of 30 mm or more is considered to be aneurismal, which usually is more than two standard deviations above the mean diameter for both men and women[1, 2]. To compensate for individual variation, other researchers have proposed a diameter 1.5 times larger than the expected diameter[3, 4]. The prevalence of AAA is 3-5% in the adult population over 60 years and mainly affects men [5, 6]. AAA itself is life-threatening problem due to spontaneous rupture, a risk that increases with the diameter of the AAA. The threat of ruptured AAAs has captured the attention of physicians for centuries. The term 'aneurysm' was written down for the first time by Rufus of Ephesus and is derived from the Greek 'ana' (towards outside) and 'eurunô' (widening). However, until the 16th century only small post-traumatic aneurysms were described. Antoine Saporta (1507-1573, University of Montpellier) was the first to report aortic aneurysms and described it as a pulsatile swelling. He also reported the symptoms of a rupture resulting in death. In Western countries the incidence of ruptured AAAs ranges between 5.6-17.5 per 100.000 person/year[7, 8]. Most AAAs do not cause symptoms until the moment of rupture. A rupture can lead to intense abdominal and lower back pain and patients often present to the hospital with hypovolemic shock. Ruptured AAAs have an estimated overall mortality rate greater than 90% and probably most patients never reach the hospital because of the eminent massive abdominal blood loss[9]. The operative mortality rates of ruptured AAA are improving over the years, possibly due to new endovascular treatment options and better perioperative care[10, 11]. AAAs with a diameter less than 40 mm have a negligible risk of rupture whereas the risk of rupture of AAAs with a diameter of 55 mm is approximately 10% per year. When the AAA diameter exceeds 55 mm the risk of rupture exponentially increases[12]. In a screening study of US veterans (n=73.451) the highest prevalence of AAAs (5.9%) was found in white male smokers between the age of 50 and 79. This and other studies indicate that important risk factors for AAA disease are advanced age, smoking and male gender[13-15]. Several more factors have been identified to be associated with AAA development such as hypertension and atherosclerosis[15-17]. However, the importance of these factors is still subject to scientific debate.

CURRENT AAA TREATMENT

The treatment of AAA started with the description of wrapping the aneurysms in the early 1940s. Harrison and Chandy used cellophane around a subclavian aneurysm[18]. In 1949 Abbott reported a large series of wrapping AAA, describing the benefit of relieving pain in about 50% of the patients with advanced aneurysm disease but not reducing the risk of rupture[19]. In 1951 the first effective means to treat AAA was described[20]. Freeman used venous autografts for aortic replacement[21] and in 1952 Voorhees reported the use of synthetic grafts for aortic replacement[22]. It was not until the beginning of the nineties that Parodi et al described endoluminal approaches for elective AAA repair[23]. Currently, both operative and endovascular (EVAR) techniques are common practice and subject to continuous research and improvement. The timing of AAA repair currently depends on the diameter of the aneurysm and is a balance between the risk of rupture and the operative mortality for aneurysm repair. Due to the global

consensus based on clinical trials that the risk of rupture is negligible for small aneurysms and patients have no complaints, elective repair is currently recommended for patients with AAAs larger than 55 mm[24, 25]. Due to this consensus, a considerable amount of patients are under surveillance for years until their AAA reaches the cut-off point of 55 mm for surgical or endovascular repair. However the benefit of repair in patients with limited life expectancy or patients with serious co-morbidity and frail general condition remains uncertain. It has been estimated that up to 70% all AAA patients will eventually require surgical intervention due to the continued expansion of their AAA[26]. Outcome of elective open aneurysm repair has improved over the years. Between 1980 and 2000 an overall 30-day mortality rate between 5.3% and 27.1% was reported. In 2014, a Cochrane review on clinical trials reported a 30-day mortality of 4.2%[27]. In 2015, Chang et al reported a 30-day mortality rate of 7.8% after open AAA repair in a population-based study[28]. 30-day mortality rates of endovascular repair, in clinical trials and in population-based studies, are found to be significantly lower (0.5% - 1.54%) compared to the open surgical repair ($p<0.001$). In clinical trials the immediate (up to 4 years) and long term (>4 years) mortality rates of open and endovascular repair are not significantly different between the two (respectively for open 17.0% vs EVAR 15.8% and open 37.8% vs EVAR 37.3%)[27]. However, in a recent population based study the long-term mortality of EVAR is higher compared to open repair. This might be explained by the inclusion of high-risk patients in the population-based study[28]. EVAR is also increasingly used for ruptured AAAs (rAAAs) but controversy exists about the results of emergency EVAR of the ruptured aneurysm. A Cochrane review from 2014 reports no clear difference in short term mortality between open en EVAR repair ($p=0.52$)[29]. In contrast to a recent retrospective observational study including and matching 10.998 patients that found a significant lower long-term mortality rate using EVAR to treat ruptured AAAs[30].

OTHER TREATMENT STRATEGIES FOR AAA

AAA is a disease of the ageing population and often presents in patients with several co-morbidities and these co-morbidities have a significant effect on the outcome of AAA repair [31]. Pharmacological intervention reducing or inhibiting progression of small AAA, and thus the eventual need for surgical repair could have major advantages; both from a patients' as from socio-economical perspective[32].

Currently there are no means to intervene with the natural history of the aneurysm. Studies using human AAA tissues have helped to identify several molecular mediators and matrix-degrading proteases, which seem contribute to aneurysm disease and might be potential pharmacological targets[33-35]. These tissues are obtained during surgical open repair of (r)AAAs and therefore represent only the end stage of the disease [36]. They provide no insight in the processes driving the smaller aneurysms towards the 55mm diameter. Small animal models have been developed to allow more detailed investigations on the cellular and molecular mechanisms of the disease in a controlled manner. The models play a key role in the screening of potential therapeutics.

AAA PATHOPHYSIOLOGY

In order to find new therapeutic strategies for AAA, a better understanding of the pathophysiological processes involved in the aneurysm development and progression at cellular and molecular levels is necessary. Current knowledge indicate that the pathophysiological process of AAA disease is

distinct from atherosclerosis and dominated by degeneration of the vascular wall[12, 37, 38]. Proteolytic degradation of the aortic wall has been postulated to be a key factor involved in the pathophysiology of AAA disease. Both elastase and collagenase activity have been found in aortic aneurysms and both have been correlated with aneurysm size. In particular, matrix-metallo proteases (MMPs) are considered to be the predominant proteases. MMP-2 and MMP-9 are able to degrade elastic fibers, interstitial collagen and denatured collagen. The increase in MMP2 and MMP9 has been clinically correlated with aneurysm size[37-39].

Besides the formation and progression of AAA has been associated with chronic transmural inflammation. The majority of infiltrates contain invading monocytes and macrophages, plasma cells, B cells and T cells. These infiltrates have been correlated with abundant pro-inflammatory cytokines such as IL-6, CXCL8 and PGE2[34, 40]. Maximum AAA diameter has been found to correlate with increased circulating inflammatory markers, such as IL-6 and CRP[41, 42].

Another key feature of AAA disease is neovascularization in the arterial aortic wall. In the healthy human aortic vessel wall the media is devoid of vasa vasorum and the adventitial layer has less vaso vasora compared with other mammals[43]. Investigation of human AAA tissue reveals prominent neovascularization in the aneurysm wall[44-47]. Experimental studies suggest that the neovascularization of the aortic wall might enhance aneurysm rupture[48, 49].

ABDOMINAL AORTIC ANEURYSM MOUSE MODELS

A basic premise of animal models of disease is that they mimic the cellular and biochemical characteristics in the progression of human disease. Mice have become dominant in biomedical research due to their small size, their well-documented genetic backgrounds and the ability to delete or over-express specific genes. To date, no murine model that mimics the pathophysiology of human AAA disease exists and thus conclusions from commonly used animal models are based on the fact that they share several similar characteristics of those seen in human AAA disease. There are advantages and disadvantages associated with each of the models used in aneurysm disease. There are three categories of murine AAA models: genetically modified mice models [39, 50], models with surgically induced AAAs[51, 52] but the most frequent used murine models use chemical induction of AAAs. Three AAA models using chemical induction have been described; the elastase model, the angiotensin-II model and the calciumchloride model.

The elastase mouse model

One of the most used animal models for aneurysm disease is the transient intraluminal perfusion of the abdominal aorta of mice with porcine pancreatic elastase[53]. This model was first described in rats by Anidjar et al[54]. Currently the murine version of the model is widely used. The aortic diameter and structure remain stable for up to 7 days, after which rapid and significant increase in diameter begins to occur. The delayed onset of aortic dilatation in the model is associated with transmural aortic infiltration of monocyt, macrophages and T-cells along with increased activity of several matrix degrading proteases. The effect of the latter causes the elastin and collagen in the aortic wall to degrade resulting in a rapid secondary dilatation and aneurysm formation at day 14. The transmural aortic inflammation is a distinctive feature of this model and resembles the human

AAA. However, this model does not display rupture of the aneurysm as well as thrombus formation, both characteristic features of human aneurysms.

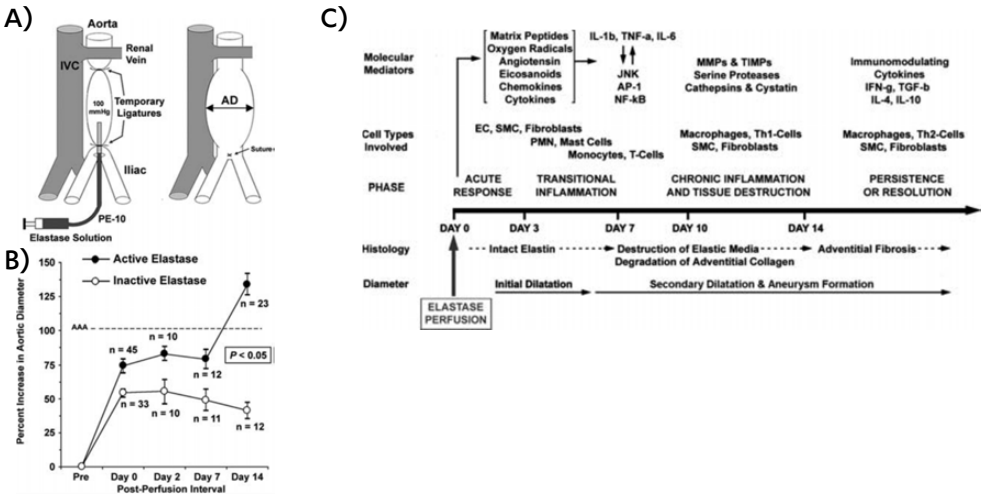

Figure 1. Elastase-induced model of AAAs [R.W. Thompson, Ann.N.Y.Acad.Sci. 1085:59-73 (2006)]. (A) Technique used for intraluminal perfusion of the infra-renal aorta. (B) Aortic dilatation at various days after aortic perfusion of elastase (black), saline (white).(C) Overview of cellular and molecular events involved in elastase-induced AAAs.

The angiotensin II model

Angiotensin II is the primary bioactive peptide of the renin angiotensin system that plays a critical role in cardiovascular diseases. Due to the infusion of angiotensin II in mice, abdominal aortic aneurysms are induced[55]. In the model constant infusion of angiotensin II, for 4 weeks, is performed by implanting osmotic mini-pumps into the subcutaneous area of the mice. Angiotensin II infusion in mice reveals progressive changes in the vascular wall as well as considerable heterogeneity in the appearance of the AAAs. The heterogeneous characteristics of angiotensin II induced AAAs are considered to be beneficial for research properties as the characteristics of human AAAs are also considerably heterogeneous. Pathological features of aneurysms generated in this way include degeneration of the aortic media, dilatation of the lumen, prominent neovascularization and presence of a wall thrombus; all hallmarks of human AAA disease. It is found that the first reaction to angiotensin II infusion is medical macrophage accumulation in the region that is prone to AAA formation. At this stage elastin degradation is found. By day 3 to 10 gross dissections of the aortas were seen leading to prominent vascular hematomas, influx of T and B cells is seen. The dilated region gradually regains elastin fibers and re-endotheliazes. The remodeled tissue prominently reveals neovascularization.

Besides the comparison in pathological features, a comparable gender preference to the human condition is seen, as male mice are more prone to aneurysm formation. However, there are some disadvantages to this model. Firstly not all infused mice develop AAA. Also, the angiotensin II induced AAAs are all located to the suprarenal aorta and no AAA's are formed. Besides, the inflammatory

response in thought to be provoked by the thrombus and therefore the aneurysms are formed secondary to an aortic dissection rather than gradual aneurysm development. Therefore, there is a discrepancy from the human situation in AAA location and morphology and therefore less comparable with the human AAA. Noteworthy further is that when infusing the angiotensin II into hypercholesterolemic mice, the AAA incidence is 3-4 fold higher than in normocholesterolemic mice[56], while there is no evidence that there is an association between hypercholesterolemia and AAA development in humans.

Calcium Chloride model

A third commonly used chemically induced model of AAA formation is the calcium chloride model. This model involves perivascular application of calcium chloride (CaCl2) onto the infra-renal aorta of mice to induce extracellular matrix remodeling. Gertz et al were the first to apply CaCl2 to the adventitia of carotid arteries of rabbits to induce aneurysm formation[57]. They found an increase of the luminal diameter of 61% in three weeks. First CaCl2 application to the aorta in mice was reported by Chio et al; an AAA formed 3 weeks after surgery[58]. The application of CaCl2 leads to the development of luminal dilatation without the preceding mechanical effects that are noted in the elastase-model. The inflammation occurs on the luminal and medial aspect of the artery. Histological examination demonstrated that aortic dilatation was accompanied by vascular smooth muscle cell depletion, elastin degradation and infiltration of T-cells and macrophages. However, the CaCl2-induced AAAs do not display the transmural inflammation, rupture and thrombus which are important features of human AAA.

AIM AND OUTLINE OF THE THESIS

The aim of this thesis was to gain more insight to the complex pathophyisiology of human AAA disease and consequently identify new possible pharmacological therapies for the stabilization of growing AAA. It specifically assesses the effectiveness of specific immunomodelatory therapies on the inhibition of aneurysm growth for potentially pharmaceutical targets and interference with aneurysm growth in clinical setting. Using a murine model, the possibilities of new and unforeseen pharmacological means to intervene with AAA growth were investigated. As a result of the close resemblance between the created mouse aneurysm and the human aneurysm, the established elastase model was used. This model is the only model where true chronic transmural inflammation is observed.

Several potential pharmacological ways to intervene with aneurysm formation have been used in murine models, such as statins, anti-hypertensive agents and doxycycline. Some have been translated into human studies. **Chapter 2** provides an up-to-date systematic review on clinical human studies exploring the pharmacological therapies for stabilizing or impeding AAA growth. **Chapter 3** explores the possible parallels between AAAs and chronic obstructive pulmonary disease (COPD), as the identification of common mechanistic pathways is relevant to detect new targets for pharmacological stabilizing therapies.

Current concepts indicate that the pathophysiological process of AAAs is dominated by degeneration of the vascular wall. Four specific pathophysiological hallmarks of human aneurysm disease have been described: chronic inflammation, medial neovascularization, a decrease in

vascular smooth muscle cells and alterations in elastin and collagen. In **Chapter 4**, the anti-inflammatory potential of a vitamin D receptor agonist (Paricalcitol) was investigated. In vitro and in vivo studies have identified the vitamin D receptor (VDR) as a potent immune regulatory factor. To investigate its effect on human AAA, a small proof-of-concept study was conducted in which aneurysm patients received Paricalciol 2-4 weeks prior to surgery. Degeneration of collagen and elastin is caused by several proteases. Literature states that the cysteine proteases, cathepsin K, L and S are prominent collagenases. We hypothesized that inhibiting these compounds might lead to stabilization of aneurysm growth. In **Chapter 5** the role of cathepsine-inhibitor E64, a broad-spectrum cystein protease inhibitor described in two different murine models ; the elastase model and the angiotensin 2 model. The obtained aortic wall samples were matched with control aneurysm aortic wall samples and prepared for further investigation. **Chapter 6** describes the study of the potential contribution of CXCL8 to the inflammatory process seen in human AAAs. CXCL8 contributes to the extreme neutrophil content and the extensive neovascularisation that hallmarks AAAs. Human AAA samples were used to validate the previous reports of high CXCL8 content and the activation of the CXCL8-pathway. The role of the CXCL8-axis was tested in the murine elastase model via the neutrophil receptor (CXCR2) antagonist DF2156A. An additional interesting candidate for diminishing neutrophil chemotaxis, besides DF2156A, is colchicine. This already clinically available compound was investigated in **Chapter 7**. The effect of colchicine on neutrophil chemotaxis might be secured via either an indirect or direct pathway. Both pathways were investigated in human aneurysm samples. Next, the role of colchicine was identified in the murine elastase model. Besides the abundance in neutrophils, CXCL8 and cystein proteases our research group previously reported an abundance of IL6 in human AAA samples. In fact, IL6 was found to be a discriminative factor between AAA and atherosclerotic disease. Because IL6 is a potential critical factor in aneurysm disease its role in aneurysm formation is investigated in **Chapter 8**. Using human aneurysm tissue samples we evaluated the IL6 pathway. Next, after induction of aneurysms via elastase perfusion, mice were treated with anti-IL6 injections to test the potential of IL6 in aneurysm formation.

Strong clinical and molecular associations exist between AAA and popliteal artery aneurysms (PAA). Yet, while the natural history of AAA is that of rupture, the primary concern in PAA's is thrombosis and rupture of PAA is rare. A patho-histological (re-)examination of human AAA samples and popliteal aneurysm wall samples was made in **Chapter 9** to provide clues towards auxiliary processes contributing to AAA wall rupture.

REFERENCES

1. Wanhainen A, Themudo R, Ahlstrom H, Lind L, Johansson L. Thoracic and abdominal aortic dimension in 70-year-old men and women--a population-based whole-body magnetic resonance imaging (MRI) study. J Vasc Surg 2008 Mar;47(3):504-12.

2. Steinberg I, Stein HL. Arteriosclerotic abdominal aneurysms. Report of 200 consecutive cases diagnosed by intravenous aortography. JAMA 1966 Mar 21;195(12):1025-9.

3. Sonesson B, Lanne T, Hansen F, Sandgren T. Infrarenal aortic diameter in the healthy person. Eur J Vasc Surg 1994 Jan;8(1):89-95.

4. Collin J, Araujo L, Walton J, Lindsell D. Oxford screening programme for abdominal aortic aneurysm in men aged 65 to 74 years. Lancet 1988 Sep 10;2(8611):613-5.

5. Pleumeekers HJ, Hoes AW, van der Does E, van UH, Hofman A, de Jong PT, et al. Aneurysms of the abdominal aorta in older adults. The Rotterdam Study. Am J Epidemiol 1995 Dec 15;142(12):1291-9.

6. Glimaker H, Holmberg L, Elvin A, Nybacka O, Almgren B, Bjorck CG, et al. Natural history of patients with abdominal aortic aneurysm. Eur J Vasc Surg 1991 Apr;5(2):125-30.

7. Johansson G, Swedenborg J. Ruptured abdominal aortic aneurysms: a study of incidence and mortality. Br J Surg 1986 Feb;73(2):101-3.

8. Acosta S, Ogren M, Bengtsson H, Bergqvist D, Lindblad B, Zdanowski Z. Increasing incidence of ruptured abdominal aortic aneurysm: a population-based study. J Vasc Surg 2006 Aug;44(2):237-43.

9. Thompson AR, Cooper JA, Ashton HA, Hafez H. Growth rates of small abdominal aortic aneurysms correlate with clinical events. Br J Surg 2010 Jan;97(1):37-44.

10. Noel AA, Gloviczki P, Cherry KJ, Jr., Bower TC, Panneton JM, Mozes GI, et al. Ruptured abdominal aortic aneurysms: the excessive mortality rate of conventional repair. J Vasc Surg 2001 Jul;34(1):41-6.

11. Bown MJ, Sutton AJ, Bell PR, Sayers RD. A meta-analysis of 50 years of ruptured abdominal aortic aneurysm repair. Br J Surg 2002 Jun;89(6):714-30.

12. Thompson RW, Geraghty PJ, Lee JK. Abdominal aortic aneurysms: basic mechanisms and clinical implications. Curr Probl Surg 2002 Feb;39(2):110-230.

13. Bengtsson H, Bergqvist D, Ekberg O, Janzon L. A population based screening of abdominal aortic aneurysms (AAA). Eur J Vasc Surg 1991 Feb;5(1):53-7.

14. Lederle FA, Wilson SE, Johnson GR, Reinke DB, Littooy FN, Acher CW, et al. Immediate repair compared with surveillance of small abdominal aortic aneurysms. N Engl J Med 2002 May 9;346(19):1437-44.

15. Lindholt JS. Screening for abdominal aortic aneurysms. Eur J Vasc Endovasc Surg 2003 May;25(5):377-9.

16. Baxter BT, Terrin MC, Dalman RL. Medical management of small abdominal aortic aneurysms. Circulation 2008 Apr 8;117(14):1883-9.

17. Lederle FA, Johnson GR, Wilson SE, Chute EP, Littooy FN, Bandyk D, et al. Prevalence and associations of abdominal aortic aneurysm detected through screening. Aneurysm Detection and Management (ADAM) Veterans Affairs Cooperative Study Group. Ann Intern Med 1997 Mar 15;126(6):441-9.

18. Harrison PW, Chandy J. A SUBCLAVIAN ANEURYSM CURED BY CELLOPHANE FIBROSIS. Ann Surg 1943 Sep;118(3):478-81.

19. ABBOTT OA. Clinical experiences with the application of polythene cellophane upon the aneurysms of the thoracic vessels. J Thorac Surg 1949 Aug;18(4):435-61.

20. DUBOST C, ALLARY M, OECONOMOS N. Resection of an aneurysm of the abdominal aorta: reestablishment of the continuity by a preserved human arterial graft, with result after five months. AMA Arch Surg 1952 Mar;64(3):405-8.

21. FREEMAN NE, LEEDS FH. Resection of aneurysms of the abdominal aorta with anastomosis of the splenic to the left iliac artery. Surgery 1953 Dec;34(6):1021-31.

22. BLAKEMORE AH, VOORHEES AB, Jr. The use of tubes constructed from vinyon N cloth in bridging arterial defects; experimental and clinical. Ann Surg 1954 Sep;140(3):324-34.

23. Parodi JC, Palmaz JC, Barone HD. Transfemoral intraluminal graft implantation for abdominal aortic aneurysms. Ann Vasc Surg 1991 Nov;5(6):491-9.

24. Powell JT, Brown LC, Forbes JF, Fowkes FG, Greenhalgh RM, Ruckley CV, et al. Final 12-year follow-up of surgery versus surveillance in the UK Small Aneurysm Trial. Br J Surg 2007 Jun;94(6):702-8.

25. Hollier LH, Taylor LM, Ochsner J. Recommended indications for operative treatment of abdominal aortic aneurysms. Report of a subcommittee of the Joint Council of the Society for Vascular Surgery and the North American Chapter of the International Society for Cardiovascular Surgery. J Vasc Surg 1992 Jun;15(6):1046-56.

26. Lederle FA, Johnson GR, Wilson SE, Chute EP, Littooy FN, Bandyk D, et al. Prevalence and associations of abdominal aortic aneurysm detected through screening. Aneurysm Detection and Management (ADAM) Veterans Affairs Cooperative Study Group. Ann Intern Med 1997 Mar 15;126(6):441-9.

27. Paravastu SC, Jayarajasingam R, Cottam R, Palfreyman SJ, Michaels JA, Thomas SM. Endovascular repair of abdominal aortic aneurysm. Cochrane Database Syst Rev 2014;1:CD004178.

28. Chang DC, Parina RP, Wilson SE. Survival After Endovascular vs Open Aortic Aneurysm Repairs. JAMA Surg 2015 Dec 1;150(12):1160-6.

29. Badger S, Bedenis R, Blair PH, Ellis P, Kee F, Harkin DW. Endovascular treatment for ruptured abdominal aortic aneurysm. Cochrane Database Syst Rev 2014;7:CD005261.

30. Edwards ST, Schermerhorn ML, O'Malley AJ, Bensley RP, Hurks R, Cotterill P, et al. Comparative effectiveness of endovascular versus open repair of ruptured abdominal aortic aneurysm in the Medicare population. J Vasc Surg 2014 Mar;59(3):575-82.

31. Patterson BO, Holt PJ, Hinchliffe R, Loftus IM, Thompson MM. Predicting risk in elective abdominal aortic aneurysm repair: a systematic review of current evidence. Eur J Vasc Endovasc Surg 2008 Dec;36(6):637-45.

32. Brown LC, Powell JT, Thompson SG, Epstein DM, Sculpher MJ, Greenhalgh RM. The UK EndoVascular Aneurysm Repair (EVAR) trials: randomised trials of EVAR versus standard therapy. Health Technol Assess 2012;16(9):1-218.

33. Golledge J, Muller J, Daugherty A, Norman P. Abdominal aortic aneurysm: pathogenesis and implications for management. Arterioscler Thromb Vasc Biol 2006 Dec;26(12):2605-13.

34. Lindeman JH, Abdul-Hussien H, Schaapherder AF, van Bockel JH, Von der Thusen JH, Roelen DL, et al. Enhanced expression and activation of pro-inflammatory transcription factors distinguish aneurysmal from atherosclerotic aorta: IL-6- and IL-8-dominated inflammatory responses prevail in the human aneurysm. Clin Sci (Lond) 2008 Jun;114(11):687-97.

35. Sukhova GK, Shi GP. Do cathepsins play a role in abdominal aortic aneurysm pathogenesis? Ann N Y Acad Sci 2006 Nov;1085:161-9.

36. Abdul-Hussien H, Hanemaaijer R, Kleemann R, Verhaaren BF, van Bockel JH, Lindeman JH. The pathophysiology of abdominal aortic aneurysm growth: corresponding and discordant inflammatory and proteolytic processes in abdominal aortic and popliteal artery aneurysms. J Vasc Surg 2010 Jun;51(6):1479-87.

37. Hellenthal FA, Buurman WA, Wodzig WK, Schurink GW. Biomarkers of AAA progression. Part 1: extracellular matrix degeneration. Nat Rev Cardiol 2009 Jul;6(7):464-74.

38. Miner GH, Faries PL, Costa KD, Hanss BG, Marin ML. An update on the etiology of abdominal aortic aneurysms: implications for future diagnostic testing. Expert Rev Cardiovasc Ther 2015 Oct;13(10):1079-90.

39. Sakalihasan N, Delvenne P, Nusgens BV, Limet R, Lapiere CM. Activated forms of MMP2 and MMP9 in abdominal aortic aneurysms. J Vasc Surg 1996 Jul;24(1):127-33.

40. Rizas KD, Ippagunta N, Tilson MD, III. Immune cells and molecular mediators in the pathogenesis of the abdominal aortic aneurysm. Cardiol Rev 2009 Sep;17(5):201-10.

41. Jones KG, Brull DJ, Brown LC, Sian M, Greenhalgh RM, Humphries SE, et al. Interleukin-6 (IL-6) and the prognosis of abdominal aortic aneurysms. Circulation 2001 May 8;103(18):2260-5.

42. Norman PE, Muller J, Golledge J. The cardiovascular and prognostic significance of the infrarenal aortic diameter. J Vasc Surg 2011 Dec;54(6):1817-20.

43. Herron GS, Unemori E, Wong M, Rapp JH, Hibbs MH, Stoney RJ. Connective tissue proteinases and inhibitors in abdominal aortic aneurysms. Involvement of the vasa vasorum in the pathogenesis of aortic aneurysms. Arterioscler Thromb 1991 Nov;11(6):1667-77.

44. Chapple KS, Parry DJ, McKenzie S, MacLennan KA, Jones P, Scott DJ. Cyclooxygenase-2 expression and its association with increased angiogenesis in human abdominal aortic aneurysms. Ann Vasc Surg 2007 Jan;21(1):61-6.

45. Thompson MM, Jones L, Nasim A, Sayers RD, Bell PR. Angiogenesis in abdominal aortic aneurysms. Eur J Vasc Endovasc Surg 1996 May;11(4):464-9.

46. Holmes DR, Liao S, Parks WC, Thompson RW. Medial neovascularization in abdominal aortic aneurysms: a histopathologic marker of aneurysmal degeneration with pathophysiologic implications. J Vasc Surg 1995 May;21(5):761-71.

47. Paik DC, Fu C, Bhattacharya J, Tilson MD. Ongoing angiogenesis in blood vessels of the abdominal aortic aneurysm. Exp Mol Med 2004 Dec 31;36(6):524-33.

48. Choke E, Cockerill GW, Dawson J, Wilson RW, Jones A, Loftus IM, et al. Increased angiogenesis at the site of abdominal aortic aneurysm rupture. Ann N Y Acad Sci 2006 Nov;1085:315-9.

49. Choke E, Thompson MM, Dawson J, Wilson WR, Sayed S, Loftus IM, et al. Abdominal aortic aneurysm rupture is associated with increased medial neovascularization and overexpression of proangiogenic cytokines. Arterioscler Thromb Vasc Biol 2006 Sep;26(9):2077-82.

50. Zhang J, Sun J, Lindholt JS, Sukhova GK, Sinnamon M, Stevens RL, et al. Mast Cell Tryptase Deficiency Attenuates Mouse Abdominal Aortic Aneurysm Formation. Circ Res 2011 Apr 14.

51. Allaire E, Guettier C, Bruneval P, Plissonnier D, Michel JB. Cell-free arterial grafts: morphologic characteristics of aortic isografts, allografts, and xenografts in rats. J Vasc Surg 1994 Mar;19(3):446-56.

52. Molacek J, Treska V, Kobr J, Certik B, Skalicky T, Kuntscher V, et al. Optimization of the model of abdominal aortic aneurysm--experiment in an animal model. J Vasc Res 2009;46(1):1-5.

53. Thompson RW, Curci JA, Ennis TL, Mao D, Pagano MB, Pham CT. Pathophysiology of abdominal aortic aneurysms: insights from the elastase-induced model in mice with different genetic backgrounds. Ann N Y Acad Sci 2006 Nov;1085:59-73.

54. Anidjar S, Dobrin PB, Eichorst M, Graham GP, Chejfec G. Correlation of inflammatory infiltrate with the enlargement of experimental aortic aneurysms. J Vasc Surg 1992 Aug;16(2):139-47.

55. Daugherty A, Cassis LA. Mouse models of abdominal aortic aneurysms. Arterioscler Thromb Vasc Biol 2004 Mar;24(3):429-34.

56. Daugherty A, Manning MW, Cassis LA. Angiotensin II promotes atherosclerotic lesions and aneurysms in apolipoprotein E-deficient mice. J Clin Invest 2000 Jun;105(11):1605-12.

57. Gertz SD, Kurgan A, Eisenberg D. Aneurysm of the rabbit common carotid artery induced by periarterial application of calcium chloride in vivo. J Clin Invest 1988 Mar;81(3):649-56.

58. Chiou AC, Chiu B, Pearce WH. Murine aortic aneurysm produced by periarterial application of calcium chloride. J Surg Res 2001 Aug;99(2):371-6.