



Universiteit  
Leiden  
The Netherlands

## Neonatal hematological and biochemical complications in TTTS and TAPS

Verbeek, L.I.

### Citation

Verbeek, L. I. (2017, June 13). *Neonatal hematological and biochemical complications in TTTS and TAPS*. Retrieved from <https://hdl.handle.net/1887/49516>

Version: Not Applicable (or Unknown)

License: [Licence agreement concerning inclusion of doctoral thesis in the Institutional Repository of the University of Leiden](#)

Downloaded from: <https://hdl.handle.net/1887/49516>

**Note:** To cite this publication please use the final published version (if applicable).

Cover Page



Universiteit Leiden



The handle <http://hdl.handle.net/1887/49516> holds various files of this Leiden University dissertation

**Author:** Verbeek, Lianne

**Title:** Neonatal hematological and biochemical complications in TTTS and TAPS

**Issue Date:** 2017-06-13

# Chapter 2

## Hematological disorders at birth in complicated monochorionic twin

Lianne Verbeek  
Femke Slaghekke  
Marieke Sueters  
Johanna M. Middeldorp  
Frans J. Klumper  
Monique C. Haak  
Dick Oepkes  
Enrico Lopriore

*Expert Rev Hematol. 2016 Dec. In Press*

## Abstract

**Introduction:** Monochorionic twins are at risk of severe complications including twin-twin transfusion syndrome (TTTS), twin anemia-polycythemia sequence (TAPS) and acute peripartum TTTS. The pathophysiology is based on inter-twin blood transfusion through placental vascular anastomoses.

**Areas covered:** This review focuses on the incidence, management and outcome of neonatal hematological complications at birth in TTTS, TAPS and acute peripartum TTTS.

**Expert commentary:** Hematological disorders are often present at birth in monochorionic twins and include acute or chronic anemia, polycythemia and thrombocytopenia. Routine measurement of complete blood counts in all complicated monochorionic twins is strongly recommended. Increased awareness on these disorders and correct diagnostic tests will lead to prompt and adequate management at birth.

1. Introduction

Twin pregnancies are associated with higher morbidity and mortality rates compared to singletons. This increased risk is partly due to premature birth and lower birth weight, but chorionicity is also an important risk factor.[1;2] Monochorionic (MC) twins carry a higher risk for severe complications than dichorionic (DC) twins due to their unique placenta architecture. In DC twins, each fetus has its own placenta while in MC twins both fetuses share a single placenta. These MC placentas are characterized by the presence of vascular anastomoses, allowing blood to flow between the fetuses during pregnancy or during delivery.[3;4] Different types of anastomoses are known. Artery to vein (AV) anastomoses or also called ‘deep anastomoses’, are mainly responsible for complications, since blood flow through AV anastomoses is unidirectional from the artery of one twin to the vein of the co-twin. Arterio-arterial (AA) anastomoses are superficial anastomoses that allow bi-directional blood flow. AA anastomoses are detected in the majority of uncomplicated MC placentas and are considered to have a protective effect against unbalanced inter-twin blood flow. Venovenous (VV) anastomoses are also superficial anastomoses. However, the clinical consequences of VV anastomoses are not well known and association with increased risk of morbidity and mortality has been reported.[5]

In the majority of cases, inter-twin blood flow is in balance, not causing complications. However, in up to 20% of cases net inter-twin blood flow is unbalanced and may lead to disorders such as twin-twin transfusion syndrome (TTTS) or twin anemia-polycythemia sequence (TAPS) during pregnancy. In addition, acute inter-twin blood transfusion can occur during delivery. The differences between TTTS, TAPS and acute peripartum TTTS are shown in table 1.

TABLE 1 Differences between TTTS, TAPS and acute TTTS

	Pathogenesis	Timing of diagnosis and criteria	Hematological disorders at birth
TTTS	Chronic inter-twin transfusion through anastomoses, usually during 2 <sup>nd</sup> trimester of pregnancy	<i>Antenatal</i> : oligo-polyhydramnios sequence on ultrasound	Inter-twin Hb discordance might occur depending on antenatal treatment
TAPS	Chronic inter-twin transfusion through small (diameter < 1 mm) anastomoses, may occur during 2 <sup>nd</sup> or 3 <sup>rd</sup> trimester of pregnancy	<i>Antenatal</i> : discordant MCA-PSV values on Doppler ultrasound or <i>postnatal</i> : inter-twin Hb discordance and large inter-twin reticulocyte count ratio or small AV-anastomoses <1mm	- Large inter-twin Hb difference (> 8 g/dL) - Reticulocytosis in the donor and inter-twin reticulocyte count ratio > 1.7 - Polycythemia in the recipient - Increased risk of thrombocytopenia in recipient
Acute peripartum TTTS	Acute inter-twin transfusion through anastomoses during delivery	<i>Postnatal</i> : inter-twin Hb discordance without inter-twin difference in reticulocyte count	- Large inter-twin Hb difference > 8 g/dL - No reticulocytosis in donor - Reticulocyte count ratio < 1.7

Hb = hemoglobin

In this review we focus on the hematological disorders in MC twin neonates with various forms of inter-twin blood transfusion such as TTTS and TAPS. In addition, we will discuss the incidence, risks and management of anemia, polycythemia and thrombocytopenia in these high-risk twins. Given the paucity of published data on hematological complications at birth, we evaluated the incidence and severity of these complications in MC twins delivered at our center. Since 2002, we routinely perform a complete blood count in all MC twins admitted to our neonatal ward (standard of care), and information of the need for blood transfusion due to anemia or partial exchange transfusion due to polycythemia is prospectively recorded in a dedicated database.

Based on our clinical experience and in agreement with the literature, white blood cell disorders are not a relevant clinical complication in monochorionic twins at birth. Information on leukocytopenia and on its possible clinical implications will not be a part of this review.

## **2.1 TTTS**

TTTS is a severe complication caused by chronic unbalanced inter-twin blood transfusion through placental anastomoses that occurs in 10% of MC twins.[6;7] Diagnosis is based on prenatal ultrasound detection of large inter-twin amniotic fluid difference, so called twin oligo-polyhydramnios sequence (TOPS). Oligohydramnios in the donor is defined as a deepest vertical pocket of amniotic fluid  $\leq 2$  cm, and polyhydramnios in the recipient is defined as  $\geq 8$  cm within the first 20 weeks of gestation or, according to the Eurofoetus criteria,  $\geq 10$  after 20 weeks of gestation.[8] A classification system was defined by Quintero et al.[9] The five stages are based on ultrasound findings and Doppler velocimetry in the umbilical artery and the umbilical vein. In all stages TOPS is present. In stage I the bladder of the donor is still visible and the Doppler measurements in both twins are normal. In stage II is the bladder of the donor twin not visible anymore. In stage III the donor's bladder is not visible and Doppler measurements are abnormal consisting of absent/reversed end-diastolic velocity in the umbilical artery or pulsatile flow in the umbilical vein in either fetuses. In the 'atypical' presentation of stage III the bladder of the donor twin is visible. In stage IV one of the fetuses shows signs of hydrops (mainly due to progressive cardiac failure). Stage V is characterized by intrauterine fetal demise of one or both fetuses.

The reported mortality rate in TTTS is very high (up to 73-100%) if left untreated.[10] Several antenatal treatment options have been proposed during the past decades including serial amnioreduction and fetoscopic laser surgery. Amnioreduction is mainly a symptomatic treatment aiming to treat the severe polyhydramnios in the recipient and reduce the risk of premature delivery due to premature uterine distension, contractions or rupture of the membranes. Fetoscopic laser surgery is the only causal treatment and aims to separate the fetal circulations by coagulating all vascular anastomoses. A randomized controlled trial proved that fetoscopic laser coagulation results in higher survival rates and lower rates of neurologic complications compared to amnioreduction.[8]

## **2.2 Hematological disorders in TTTS**

Hematological disorders in TTTS are already present antenatally. Some small studies examining fetal blood samples showed that hematocrit, hemoglobin and red blood cell count levels are significantly lower in donor twins compared to recipient twins.[11;12] In the past, large inter-twin difference in hemoglobin level at birth was considered diagnostic for TTTS, often in combination with large inter-twin birth weight discordances.[13;14]

These criteria were abandoned several decades ago, when it became clear that birth weight and/or hemoglobin discordance are relatively common in MC twins and that the prenatal criteria described above were more useful to reach the diagnose of TTTS.[15] Donors in TTTS may be severely anemic, whereas recipients may suffer from severe hyperviscosity-polycythemia. In addition, several case reports described vascular ischemic limb necrosis in recipient twins, mainly in TTTS cases not treated with laser surgery. The pathogenesis of limb necrosis is related to vascular occlusion due to severe hyperviscosity and polycythemia and secondary thrombosis, though hypertension and vasoconstriction may also play a role.[16;17]

At birth, neonates with TTTS often have hematological disorders. The presence of hematologic complications and inter-twin hemoglobin differences depends on the type of antenatal treatment. In TTTS twins treated conservatively (expectant management or serial amnioreduction), we found that donors had a significant lower hemoglobin level at birth compared to recipient twins. Median inter-twin hemoglobin difference was 3.6 (1.6-6.0) g/dL. In contrast, in TTTS treated with laser coagulation surgery no significant difference in hemoglobin levels was found.[18]

Between 2002 and 2016, 62 TTTS twin pairs treated conservatively were delivered at our center. Due to missing values and fetal or postnatal demise, the total number of recruited twins and described twins varies between the different variables throughout this article. For each variable the number of twins with complete information was stated as total number (n). The percentage of donors requiring a blood transfusion on day 1 was 33% (14 of a total twin number of 43). Recipients required a partial exchange transfusion at birth in 24% (10/42). In the group of TTTS twin pairs treated with complete laser coagulation and born alive at our center, only 5% (13/251) of the ex-donors needed a blood transfusion on day 1 and 1% (2/252) of the recipients needed a partial exchange transfusion (table 2). Coagulation of all vascular anastomoses thus allows re-equilibration of the hematological imbalance: after surgery the hemoglobin level in the donor twin will gradually increase due to cessation of blood loss, while the hemoglobin level in the recipient twin will gradually decrease as transfusion from its co-twin stops. However, fetoscopic laser surgery is not always complete and (small) residual anastomoses may be left patent in up to a third of cases, allowing persistence of TTTS or development of post-laser TAPS (see next paragraph).[19] In both situations large inter-twin hemoglobin differences may still be found at birth.[20] Between 2002 and 2016, 47 TTTS twin pairs were treated with laser coagulation surgery and had residual anastomoses, resulting in post-laser TAPS or recurrent TTTS. The percentage of donors requiring a blood transfusion on day 1 was 55% (26/47) and the percentage of recipients requiring a partial exchange transfusion on day 1 was 35% (16/46) (table 2). As shown in the recently published Solomon trial, the use of the Solomon laser technique (in which a laser coagulation line is drawn along the vascular equator) reduces the risks of post-laser TAPS or recurrent TTTS from 21% (in the classic selective laser technique) to 4% in the Solomon technique.[21]

Since presence of residual anastomoses may not always be predicted antenatally, we strongly advise to measure hemoglobin levels in TTTS twins at birth in all cases, whether treated with laser surgery or not. Blood transfusion in donors and partial exchange transfusion in recipients may be required depending on the local, national protocols for the man-

agement of anemia and polycythemia. Figure 1 shows the incidence of anemia and polycythemia in complicated MC twins delivered at our center between 2002 and 2016.

**TABLE 2 Hemoglobin levels and reticulocyte counts at birth, and presence of anemia or polycythemia**

	Hb level - g/dL		Reticulocyte count - g/dL		Anemia - n (%) <sup>a</sup>	Polycythemia - n (%) <sup>b</sup>
	Donors	Recipients	Donors	Recipients		
<b>TTTS - conservative management</b> <b>N = 62</b>	13.9 ± 3.5 <i>n</i> = 43	18.4 ± 3.6 <i>n</i> = 42	83.9 ± 50.1 <i>n</i> = 33	76.7 ± 31.0 <i>n</i> = 33	14 (33%) <i>n</i> = 43	10 (24%) <i>n</i> = 42
<b>TTTS - complete laser</b> <b>N = 357</b>	16.8 ± 2.9 <i>n</i> = 245	17.1 ± 2.5 <i>n</i> = 257	67.3 ± 35.1 <i>n</i> = 198	64.6 ± 28.4 <i>n</i> = 201	13 (5%) <i>n</i> = 251	2 (1%) <i>n</i> = 252
<b>TTTS - incomplete laser</b> <b>N = 47</b>	11.6 ± 5.0 <i>n</i> = 46	20.1 ± 3.6 <i>n</i> = 45	127.7 ± 88.6 <i>n</i> = 40	56.8 ± 31.1 <i>n</i> = 39	26 (55%) <i>n</i> = 47	16 (35%) <i>n</i> = 46
<b>Spontaneous TAPS</b> <b>N = 27</b>	9.4 ± 4.7 <i>n</i> = 25	21.6 ± 3.7 <i>n</i> = 26	175.2 ± 128.8 <i>n</i> = 24	46.3 ± 21.5 <i>n</i> = 24	19 (83%) <i>n</i> = 23	13 (54%) <i>n</i> = 24
<b>Acute peripartum TTTS</b> <b>N = 12</b>	13.5 ± 4.5 <i>n</i> = 12	20.7 ± 4.0 <i>n</i> = 12	52.4 ± 10.5 <i>n</i> = 9	53.6 ± 12.3 <i>n</i> = 9	3 (27%) <i>n</i> = 11	3 (27%) <i>n</i> = 11

Values given as mean ± SD

<sup>a</sup>Anemia at birth defined as low hemoglobin level requiring a blood transfusion on day 1, <sup>b</sup>Polycythemia at birth defined as an increased hematocrit requiring a partial exchange transfusion on day 1, N; Refers to numbers of twin pairs, n; refers to number of neonates

### 3.1 TAPS

TAPS is a newly described form of chronic inter-twin blood transfusion leading to anemia in the donor and polycythemia in the recipient, without signs of oligo-polyhydramnios as seen in TTTS. TAPS is caused by the presence of only few small placental vascular anastomoses (diameter < 1 mm). These minuscule anastomoses allow slow transfusion of blood from one twin to the other, without the hemodynamic imbalance and discordant fetal urine production, as in TTTS. In a few cases, we were able to measure the blood flow over the anastomoses and found it be approximately 5 to 10 ml/24 hours.[22]

Two types of TAPS have been described. The form which occurs sometimes after laser treatment for TTTS, 'post-laser TAPS', was first described in 2006 by Robyr et al.[23] The 'spontaneously' occurring form of TAPS, as well as the acronym TAPS, was first described in 2007 by Lopriore et al.[24] The close relationship between minuscule anastomoses and TAPS was then clearly established. The incidence of spontaneous TAPS is 3-5% of MC twin pregnancies while post-laser TAPS can occur in 2-16% of TTTS twins after laser surgery. [23;25-27]



TAPS can be diagnosed antenatally and postnatally. The antenatal diagnosis depends on Doppler ultrasound abnormalities and includes increased middle cerebral artery peak systolic velocity (MCA-PSV) of  $> 1.5$  multiples of the median (MoM), predicting anemia in the donor, and reduced MCA-PSV of  $< 1.0$  MoM in the recipient, a sign of polycythemia. Absence of TOPS is a *conditio sine qua non*, since the presence of TOPS is pathognomonic for TTTS.[23;25;28] The postnatal diagnosis is made based on hematological criteria at birth. Several definitions for postnatal TAPS have been proposed, such as a hemoglobin level  $< 11$  g/dL in the anemic twin and  $> 20$  g/dL in the polycythemic twin, by Lewi et al.[6] The most important limitation of this definition is the fact that it does not take into account that hemoglobin is known to increase linearly with gestation.[29;30] Currently accepted postnatal criteria include an inter-twin hemoglobin difference  $> 8.0$  g/dL and at least one of the following: reticulocyte count ratio  $> 1.7$  or placenta with only small (diameter  $< 1$  mm) placental vascular anastomoses.[23;25] Reticulocyte count ratio can be measured by dividing the reticulocyte count of the donor with those of the recipient. Detection of the minuscule anastomoses can only accurately be assessed by careful placental injections studies using color dye.

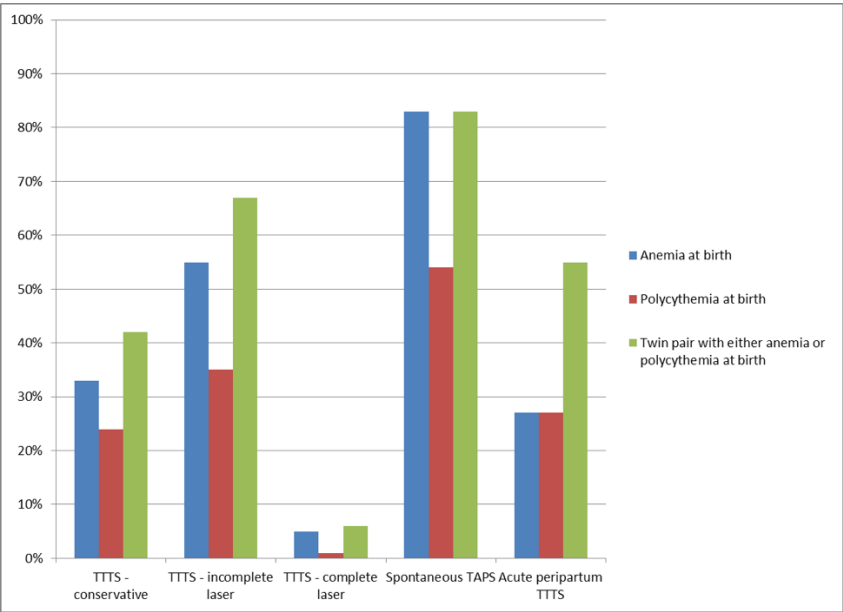
In analogy with TTTS, a TAPS staging system has been developed, subdivided in an antenatal and postnatal classification. In the antenatal stage I and II there are no signs of fetal compromise except for MCA-PSV in the donor  $> 1.5$  MoM in stage I and  $> 1.7$  in stage II and MCA-PSV in the recipient  $< 1.0$  MoM in stage I and  $< 0.8$  MoM in stage II. In stage III, the MCA-PSV is as in stage I or II and besides the donor suffers from cardiac compromise defined as critically abnormal flow (absent or reversed end-diastolic flow in umbilical artery, pulsatile flow in the umbilical vein, increased pulsatility index or reversed flow in ductus venosus). In stage IV, hydrops of the donor is seen due to severe anemia and in stage V intrauterine demise of one or both fetuses occurred. The postnatal classification is based on the inter-twin hemoglobin difference starting at  $> 8.0$  g/dL in stage I,  $> 11.0$  g/dL in stage II,  $> 14.0$  g/dL in stage III,  $> 17.0$  g/dL in stage IV and  $> 20.0$  g/dL in stage V.[25] The optimal antenatal treatment for TAPS is still not clear. Although the pathophysiology of TAPS is also based on vascular anastomoses and fetoscopic laser surgery or delivery would be the only curative treatment, this is more challenging than in TTTS because of the absence of the polyhydramnios-oligohydramnios situation. The uterus is less distended, making insertion of instruments more risky, and the wavering inter-twin membrane prevents visualization of vessels behind it. In addition, the anastomoses in TAPS are minuscule and therefore more difficult to detect during fetoscopic laser coagulation. Moreover, laser surgery is associated with complications as premature rupture of the membranes, disruption of the inter-twin membrane and fetal demise. Besides (repeat) fetoscopic laser coagulation, possible management options are induction of labor, intrauterine transfusion (IUT) (intravascular or intraperitoneal) in the donor with or without partial exchange transfusion (PET) in the recipient, selective termination, pregnancy termination or expectant management since spontaneous resolution has been described as well. Some authors describe a combination of treatments.[25;31-35] Prevention of post-laser TAPS can be successfully achieved by using the Solomon laser coagulation technique, as previously mentioned.[21]

3.2 Hematological disorders in TAPS

Neonates with TAPS have mainly short-term hematologic complications. Donor twins have chronic anemia with highly increased reticulocyte counts, reflecting chronic blood loss. A blood transfusion is often needed in the first 24 hours of birth in 57-80% of cases.[36-39] However, given the chronic nature of the anemia, immediate transfusion at birth or in the delivery room is not necessary. In contrast, recipients may be severely polycythemic and require PET in 40-71% of cases.[36-39] Severe hyperviscosity in recipients may lead to necrosis of the skin and multiple limb ischemia or severe cerebral injury.[23;40] Prompt detection and treatment at birth with partial exchange transfusion is of paramount importance. Some studies report blood transfusion in the donor with the blood concomitantly obtained from the polycythemic co-twin during PET.[41] Between 2002 and 2016 27 spontaneous TAPS twin pairs were delivered in our center. A blood transfusion on day 1 was required in 83% (19/23) of the donor twins and 54% (13/24) of the recipient twins required partial exchange transfusion on day 1 (see table 2 and figure 1).

Thrombocytopenia (platelet count < 150 x 10<sup>9</sup>/L) occurs more often in twins affected by TAPS compared to MC twins. In a study of Lopriore et al. with 38 TAPS neonates 1 recipient with severe thrombocytopenia required a platelet transfusion at birth. However, thrombocytopenia in TAPS is mostly self-limiting.[37] Polycythemia is generally associated with thrombocytopenia.[42] Recipient twins are by definition polycythemic and several studies reported lower platelet count in recipients than in donors. Platelet count in recipient twins is also negatively correlated to hemoglobin level at birth. Low platelet count in polycythemic recipients might be explained by impaired production secondary to tissue hypoxia, slow spleen blood flow and decreased plasma fraction with normal concentrations.[37;42]

FIGURE 1 Anemia (needing blood transfusion) and/or polycythemia (needing PET) at birth in complicated monochorionic twins



#### 4. Acute peripartum TTTS

Acute peripartum TTTS, sometimes referred to as 'acute perinatal TTTS', is a rare form of inter-twin transfusion which may occur due to acute shifts of blood between the two fetuses during delivery. Knowledge on acute peripartum TTTS is limited and mainly based on casuistic reports and small, often incomplete, cases series. The incidence is reported to range from 1.5 to 2.5% in all MC twins.[39;43;44] The pathogenesis is not clear and several hypothetic mechanisms have been suggested. Reports suggest that acute peripartum TTTS may be due to acute shifts of relatively large volumes of blood from one twin to the other due to blood pressure differences following uterine contractions or changes in fetal positions. This is likely only possible through large AA or VV anastomoses. Mode of delivery and birth order could play a role, since acute peripartum TTTS mostly occurs in twins born vaginally and first-born twins are usually the ones with the lower hemoglobin levels.[44-47] However, Mabuchi et al. described 5 twins with acute peripartum TTTS born through emergency cesarean section.[39] The diagnostic criteria for acute peripartum TTTS are not clear and most reports use a hemoglobin difference of more than 8 g/dL at birth in the absence of TTTS or TAPS. Characteristically, twins with acute peripartum TTTS have a large color difference at birth and large differences in hemoglobin levels and may thus resemble cases with TAPS. Differentiation with TAPS can be made after birth by measuring reticulocyte counts. In acute peripartum TTTS, the reticulocyte count in the donor twins should be low since increased erythropoiesis (and increased reticulocytes) cannot occur in a short instant of time. In contrast in TAPS, the donor twin always has a highly increased reticulocyte count as a sign of chronic blood loss.

In addition, placental injection studies should also be performed to help differentiate between the various complications. As mentioned above, acute shifts of blood between two fetuses could only occur through superficial AA or VV anastomoses. These superficial anastomoses have a large diameter and a low vascular resistance allowing rapid shifts of blood. The absence of such large anastomoses should prompt investigators to envisage other causes. In most case reports on acute peripartum TTTS published in the past, measurement of reticulocyte count or placental injection studies were not performed hampering the differentiation with TAPS. We hypothesize that most case reports of acute peripartum TTTS in the past were probably TAPS cases, wrongly diagnosed due to limited knowledge on TAPS.

Importantly, the donor twin in acute peripartum TTTS may suffer from acute blood loss resulting in severe anemia and hypovolemic shock. Management in case of acute peripartum TTTS warrant prompt use of volume expanders and blood transfusion in the donor twin, and possibly partial exchange transfusion in the recipient in case of polycythemia hyperviscosity. The donor twins described in the case reports needed a blood transfusion in 33-40% of cases and recipients needed partial exchange transfusion in 17-20%.[39;44] Between 2002 and 2016 12 twin pairs with acute peripartum TTTS were born at our center. In 27% (3/11) of the donors a blood transfusion was needed and in 27% (3/11) of the recipients a blood transfusion was needed (see table 2 and figure 1).

## 5. Acute perimortem TTTS due to acute exsanguination

Acute perimortem TTTS occurs during intrauterine fetal demise of a co-twin and is due to acute exsanguination from the surviving twin into the low-pressure circulation of the dying co-twin who fails to maintain its sympathetic tone. It is thought to be mainly mediated by large, superficial, AA or VV anastomoses, since these anastomoses have a low resistance and therefore allow blood to flow rapidly from one twin to the other.[48] The acute hypovolemic shock and ischemia occurs so rapidly that treatment using a blood transfusion practically always comes too late. Similarly, an emergency cesarean section would require detecting the impending fetal demise as it happens or very shortly after, a rare situation. Whether intrauterine transfusion at a later stage, when the surviving fetus remains anemic as diagnosed by MCA Doppler measurements, is useful is unclear. The acute blood loss during the process of demise of the co-twin likely stops quickly after its death. The resulting anemia cannot be reversed by a late blood transfusion. The resulting anemia likely improves by itself, however this may take several days or more. Transfusion may help restore normal hemoglobin levels. More data on this situation is needed, and several studies are on their way.[48-50]

Acute exsanguination may also occur in specific conditions such as in cases of ruptured vasa previa, one of the most dramatic complications in MC twins. In the literature 10 cases of MC twins with antenatally undetected ruptured vasa previa and a velamentous cord insertion are described, with a perinatal mortality rate of 55%.[51]

A velamentous umbilical cord insertion is characterized by membranous umbilical vessels at the placental insertion site. In vasa previa one or more fetal blood vessels run through the amniotic membranes and cross or run near the external orifice of the uterus.[52] Rupture of the membranes can lead to tearing of these vessels and thereby cause acute fetal exsanguination.

Vasa previa is more common in placenta previa, conception by assisted reproductive technologies, velamentous cord insertion and bilobed placenta.[53] Velamentous cord insertion with vasa previa occurs more frequently in twin pregnancies compared to singletons, with a higher prevalence in MC twins than in DC twins.[54] In singletons or DC twins, rupture of vasa previa can result in acute exsanguination and subsequently severe hypoxic-ischemic injury. In MC twins, due to placental vascular anastomoses, rupture of vasa previa of one of the twins can lead to exsanguination in both twins. This can lead to hypovolemic shock and severe anemia requiring prompt management with rapid iv bolus and blood transfusion. Hypovolemic shock can lead to hypoxic-ischemic injury mainly to the brain and kidneys, and result in severe cerebral injury or terminal kidney failure or double fatal outcome. Prevention is the key to reduce the risks of acute exsanguination and is based on prenatal detection of vasa previa and delivery through cesarean section before spontaneous rupture of membranes.[55]

## 6. Uncomplicated monochorionic twins

Various studies showed that hemoglobin levels are higher in term and preterm neonates born after vaginal delivery compared to neonates delivered through cesarean section.[56-58] These studies also show that hemoglobin levels are often higher in second-born twins compared to their first-born co-twin. The cause of this discordance may be due to various reasons. First, higher hemoglobin levels in second-borns may result from unbalanced inter-twin transfusion during delivery. It might be that due to differences in pressure gradients and uterine contractions relatively more blood flows from the first-born twin to the second-born twin. Another hypothesis could be that after delivery and umbilical cord clamping of the first twin, the yet unborn second twin receives blood from both placental shares through placento-fetal transfusion. An alternative explanation could be that the timing of umbilical cord clamping differs in the first and second twin. Since delayed cord clamping (> 30 seconds) leads to higher hemoglobin levels due to increased placento-fetal transfusion, it might be that the umbilical cord of the first-born twin is clamped relatively early compared to the second-born co-twin. In this case we theorize that once the first twin is born, obstetricians may tend to clamp the cord relatively early in order to focus on the delivery of the second twin. The obstetrician may leave a longer interval for clamping the cord of the second twin, resulting in a higher hemoglobin level in the second twin.[59;60]

Stagnati et al. describe that third-trimester inter-twin MCA-PSV discrepancy in uncomplicated MC is associated with selective intrauterine growth restriction (sIUGR) at birth and an inter-twin birth weight discrepancy of > 25%.[26] MCA-PSV values are highly correlated with hemoglobin levels.[61] One would therefore also expect to find hemoglobin discordances at birth in sIUGR twins. However, hemoglobin levels were not reported in this study. In another small group of sIUGR twins, Chang et al. found increased umbilical plasma erythropoietin concentrations. Increased levels of erythropoietin reflect hypoxia and increased hemoglobin levels are expected. However, erythropoietin ratio was not paralleled by alterations in hemoglobin levels.[62] Further research to investigate hemoglobin levels in MC twins with sIUGR in a larger cohort is warranted.

## 7. Expert commentary

MC twins are at risk for severe complications including TTTS, acute peripartum TTTS and TAPS. The pathophysiology of these complications is based in all cases on the presence of placental vascular anastomoses. Differentiation between these various disorders is important. TTTS and TAPS are based on chronic unbalanced inter-twin blood transfusion during pregnancy (usually 2<sup>nd</sup> trimester), while acute peripartum TTTS is based on acute inter-twin blood transfusion during delivery. Untreated or incompletely treated TTTS often results in hematological complications in neonates. After complete laser surgery, hematological complications are rare. In TAPS and in acute peripartum TTTS, large inter-twin hemoglobin differences are found and measurement of reticulocyte counts is of paramount importance to differentiate between the two disorders. In addition, TAPS recipient twins are also at risk for thrombocytopenia probably due to hyperviscosity.

In uncomplicated vaginally delivered MC twins, the second-born twins often have a higher hemoglobin level than the first-born co-twins. Whether this is due to vascular anastomoses in the placenta or differences in umbilical cord clamping interval is not yet known. Lastly, the most dramatic hematologic complication in MC twins occurs in case of rupture of vasa

previa. Acute exanguination in both twins due to transfusion through vascular anastomoses may occur and which may lead to a double fatal outcome. Increased knowledge and awareness of the characteristic placental angioarchitecture and associated complications is important for prompt and adequate management and to reduce the risk of adverse outcome in MC twins.

## **8. Five-year view**

Improved antenatal management in complicated MC twins with TTTS or TAPS has led to an increased perinatal survival. Attention is now shifting towards postnatal morbidity in survivors, including hematological complications after delivery. Despite the improvements in perinatal care in complicated MC twins, hematological disorders are frequently detected. Given the important effect of timing of cord clamping on hemoglobin values at birth, more research is needed to study this effect in specific subgroups of MC twins. Delayed cord clamping could be beneficial to reduce the risk in anemia in donors, and early cord clamping to reduce the risks of hyperviscosity in recipients.

## References

- 1 Kiely JL: The epidemiology of perinatal mortality in multiple births. *Bull N Y Acad Med* 1990;66:618-637.
- 2 Biggio JR, Anderson S: Spontaneous Preterm Birth in Multiples. *Clin Obstet Gynecol* 2015;58:654-667.
- 3 Denbow ML, Cox P, Taylor M, Hammal DM, Fisk NM: Placental angioarchitecture in monochorionic twin pregnancies: relationship to fetal growth, fetofetal transfusion syndrome, and pregnancy outcome. *Am J Obstet Gynecol* 2000;182:417-426.
- 4 Zhao D, Lipa M, Wielgos M, Cohen D, Middeldorp JM, Oepkes D, Lopriore E: Comparison Between Monochorionic and Dichorionic Placentas With Special Attention to Vascular Anastomoses and Placental Share. *Twin Res Hum Genet* 2016;19:191-196.
- 5 Slaghekke F, Zhao DP, Middeldorp JM, Klumper FJ, Haak MC, Oepkes D, Lopriore E: Antenatal management of twin-twin transfusion syndrome and twin anemia-polycythemia sequence. *Expert Rev Hematol* 2016;9:815-820.
- 6 Lewi L, Jani J, Blickstein I, Huber A, Gucciardo L, Van MT, Done E, Boes AS, Hecher K, Gratacos E, Lewi P, Deprest J: The outcome of monochorionic diamniotic twin gestations in the era of invasive fetal therapy: a prospective cohort study. *Am J Obstet Gynecol* 2008;199:514-518.
- 7 Baschat A, Chmait RH, Deprest J, Gratacos E, Hecher K, Kontopoulos E, Quintero R, Skupski DW, Valsky DV, Ville Y: Twin-to-twin transfusion syndrome (TTTS). *J Perinat Med* 2011;39:107-112.
- 8 Senat MV, Deprest J, Boulvain M, Paupe A, Winer N, Ville Y: Endoscopic laser surgery versus serial amnioreduction for severe twin-to-twin transfusion syndrome. *N Engl J Med* 2004;351:136-144.
- 9 Quintero RA, Morales WJ, Allen MH, Bornick PW, Johnson PK, Kruger M: Staging of twin-twin transfusion syndrome. *J Perinatol* 1999;19:550-555.
- 10 Berghella V, Kaufmann M: Natural history of twin-twin transfusion syndrome. *J Reprod Med* 2001;46:480-484.
- 11 Denbow M, Fogliani R, Kyle P, Letsky E, Nicolini U, Fisk N: Haematological indices at fetal blood sampling in monochorionic pregnancies complicated by fetofetal transfusion syndrome. *Prenat Diagn* 1998;18:941-946.
- 12 Berry SM, Puder KS, Bottoms SF, Uckele JE, Romero R, Cotton DB: Comparison of intrauterine hematologic and biochemical values between twin pairs with and without stuck twin syndrome. *Am J Obstet Gynecol* 1995;172:1403-1410.
- 13 Tan KL, Tan R, Tan SH, Tan AM: The twin transfusion syndrome. Clinical observations on 35 affected pairs. *Clin Pediatr (Phila)* 1979;18:111-114.
- 14 Rausen AR, Seki M, Strauss L: Twin transfusion syndrome. A review of 19 cases studied at one institution. *J Pediatr* 1965;66:613-628.
- 15 Wenstrom KD, Tessen JA, Zlatnik FJ, Sipes SL: Frequency, distribution, and theoretical mechanisms of hematologic and weight discordance in monochorionic twins. *Obstet Gynecol* 1992;80:257-261.
- 16 Schrey S, Huber A, Hecher K, Quintero R, Alkazaleh F, Moise KJ, Jr., Allbert JR, Schneider C, Palermo M, Yinon Y, Chmait RH, Windrim R, Ryan G: Vascular limb occlusion in twin-twin transfusion syndrome (TTTS): case series and literature review. *Am J Obstet Gynecol* 2012;207:131-10.
- 17 Carr SR, Luks F, Tracy T, Plevyak M: Antenatal necrotic injury in severe twin-to-twin transfusion syndrome. A case and review. *Fetal Diagn Ther* 2004;19:370-372.
- 18 Verbeek L, Middeldorp JM, Hulzebos CV, Oepkes D, Walther FJ, Lopriore E: Hypoalbuminemia in donors with twin-twin transfusion syndrome. *Fetal Diagn Ther* 2013;33:98-102.
- 19 Slaghekke F, Lewi L, Middeldorp JM, Weingertner AS, Klumper FJ, Dekoninck P, Devlieger R, Lanna MM, Deprest J, Favre R, Oepkes D, Lopriore E: Residual anastomoses in twin-twin transfusion syndrome after laser: the Solomon randomized trial. *Am J Obstet Gynecol* 2014;211:285-287.

- 20 Lopriore E, Middeldorp JM, Oepkes D, Klumper FJ, Walther FJ, Vandenbussche FP: Residual anastomoses after fetoscopic laser surgery in twin-to-twin transfusion syndrome: frequency, associated risks and outcome. *Placenta* 2007;28:204-208.
- 21 Slaghekke F, Lopriore E, Lewi L, Middeldorp JM, van Zwet EW, Weingertner AS, Klumper FJ, DeKoninck P, Devlieger R, Kilby MD, Rustico MA, Deprest J, Favre R, Oepkes D: Fetoscopic laser coagulation of the vascular equator versus selective coagulation for twin-to-twin transfusion syndrome: an open-label randomised controlled trial. *Lancet* 2014;383:2144-2151.
- 22 Lopriore E, van den Wijngaard JP, Pasman SA, Oepkes D, Walther FJ, van Gemert MJ, Vandenbussche FP: Quantification of feto-fetal transfusion rate through a single placental arterio-venous anastomosis in a monochorionic twin pregnancy. *Placenta* 2009;30:223-225.
- 23 Robyr R, Lewi L, Salomon LJ, Yamamoto M, Bernard JP, Deprest J, Ville Y: Prevalence and management of late fetal complications following successful selective laser coagulation of chorionic plate anastomoses in twin-to-twin transfusion syndrome. *Am J Obstet Gynecol* 2006;194:796-803.
- 24 Lopriore E, Middeldorp JM, Oepkes D, Kanhai HH, Walther FJ, Vandenbussche FP: Twin anemia-polycythemia sequence in two monochorionic twin pairs without oligo-polyhydramnios sequence. *Placenta* 2007;28:47-51.
- 25 Slaghekke F, Kist WJ, Oepkes D, Pasman SA, Middeldorp JM, Klumper FJ, Walther FJ, Vandenbussche FP, Lopriore E: Twin anemia-polycythemia sequence: diagnostic criteria, classification, perinatal management and outcome. *Fetal Diagn Ther* 2010;27:181-190.
- 26 Stagnati V, Pagani G, Fichera A, Prefumo F: Intertwin discrepancy in middle cerebral artery peak systolic velocity and third-trimester fetal growth restriction in monochorionic-diamniotic twin pregnancy. *Ultrasound Obstet Gynecol* 2016;48:66-71.
- 27 Gucciardo L, Lewi L, Vaast P, Debska M, De CL, Van MT, Done E, Devlieger R, Deprest J: Twin anemia polycythemia sequence from a prenatal perspective. *Prenat Diagn* 2010;30:438-442.
- 28 Tollenaar LS, Slaghekke F, Middeldorp JM, Klumper FJ, Haak MC, Oepkes D, Lopriore E: Twin Anemia Polycythemia Sequence: Current Views on Pathogenesis, Diagnostic Criteria, Perinatal Management, and Outcome. *Twin Res Hum Genet* 2016;19:222-233.
- 29 Jopling J, Henry E, Wiedmeier SE, Christensen RD: Reference ranges for hematocrit and blood hemoglobin concentration during the neonatal period: data from a multihospital health care system. *Pediatrics* 2009;123:e333-e337.
- 30 Nicolaides KH, Thilaganathan B, Mibashan RS: Cordocentesis in the investigation of fetal erythropoiesis. *Am J Obstet Gynecol* 1989;161:1197-1200.
- 31 Slaghekke F, van den Wijngaard JP, Akkermans J, van Gemert MJ, Middeldorp JM, Klumper FJ, Oepkes D, Lopriore E: Intrauterine transfusion combined with partial exchange transfusion for twin anemia polycythemia sequence: modeling a novel technique. *Placenta* 2015;36:599-602.
- 32 Abdel-Sattar M, Platt LD, DeVore G, Porto M, Benirschke K, Chmait RH: Treatment of Complicated Spontaneous Twin Anemia-Polycythemia Sequence via Fetoscopic Laser Ablation of the Vascular Communications. *Fetal Diagn Ther* 2015;38:233-237.
- 33 Genova L, Slaghekke F, Klumper FJ, Middeldorp JM, Steggerda SJ, Oepkes D, Lopriore E: Management of twin anemia-polycythemia sequence using intrauterine blood transfusion for the donor and partial exchange transfusion for the recipient. *Fetal Diagn Ther* 2013;34:121-126.
- 34 Lopriore E, Hecher K, Vandenbussche FP, van den Wijngaard JP, Klumper FJ, Oepkes D: Fetoscopic laser treatment of twin-to-twin transfusion syndrome followed by severe twin anemia-polycythemia sequence with spontaneous resolution. *Am J Obstet Gynecol* 2008;198:e4-e7.
- 35 Guenot C, Robyr R, Jastrow N, Vial Y, Raio L, Baud D: Fetal Intra-Peritoneal Transfusion for the Management of Very Early Spontaneous Twin Anemia-Polycythemia Sequence in an Obese Patient With a Whole Anterior Placenta. *Twin Res Hum Genet* 2016;19:154-157.



- 36 Lopriore E, Slaghekke F, Oepkes D, Middeldorp JM, Vandenbussche FP, Walther FJ: Clinical outcome in neonates with twin anemia-polycythemia sequence. *Am J Obstet Gynecol* 2010;203:54-55.
- 37 Lopriore E, Slaghekke F, Oepkes D, Middeldorp JM, Vandenbussche FP, Walther FJ: Hematological characteristics in neonates with twin anemia-polycythemia sequence (TAPS). *Prenat Diagn* 2010;30:251-255.
- 38 Ashwal E, Yinon Y, Fishel-Bartal M, Tsur A, Chayen B, Weisz B, Lipitz S: Twin Anemia-Polycythemia Sequence: Perinatal Management and Outcome. *Fetal Diagn Ther* 2016;40:28-34.
- 39 Mabuchi A, Ishii K, Yamamoto R, Taguchi T, Murata M, Hayashi S, Mitsuda N: Clinical characteristics of monochorionic twins with large hemoglobin level discordance at birth. *Ultrasound Obstet Gynecol* 2014;44:311-315.
- 40 Stranak Z, Korcek P, Hympanova L, Kyncl M, Krofta L: Prenatally Acquired Multiple Limb Ischemia in a Very Low Birth Weight Monochorionic Twin. *Fetal Diagn Ther* 2015.
- 41 Yarci E, Alyamac DE, Oncel MY, Kose CA, Derme T, Canpolat FE, Oguz SS, Dilmen U: Successful management of twin anemia/polycythemia sequence by syngeneic partial exchange transfusion. *Fetal Diagn Ther* 2014;36:251-254.
- 42 Sarkar S, Rosenkrantz TS: Neonatal polycythemia and hyperviscosity. *Semin Fetal Neonatal Med* 2008;13:248-255.
- 43 Suzuki S, Iwasaki N, Ono S, Igarashi M, Murata T: Fetal heart rate patterns in monochorionic twins following acute twin-twin transfusion. *Obstet Gynecol Int* 2009;2009:498530.
- 44 Lopriore E, Holtkamp N, Sueters M, Middeldorp JM, Walther FJ, Oepkes D: Acute peripartum twin-twin transfusion syndrome: incidence, risk factors, placental characteristics and neonatal outcome. *J Obstet Gynaecol Res* 2014;40:18-24.
- 45 Klebe JG, Ingomar CJ: The fetoplacental circulation during parturition illustrated by the interfetal transfusion syndrome. *Pediatrics* 1972;49:112-116.
- 46 Faxelius G, Raye J, Gutberlet R, Swanstrom S, Tsiantos A, Dolanski E, Dehan M, Dyer N, Lindstrom D, Brill AB, Stahlman M: Red cell volume measurements and acute blood loss in high-risk newborn infants. *J Pediatr* 1977;90:273-281.
- 47 Galea P, Scott JM, Goel KM: Feto-fetal transfusion syndrome. *Arch Dis Child* 1982;57:781-783.
- 48 Lopriore E, Oepkes D: Fetal and neonatal haematological complications in monochorionic twins. *Semin Fetal Neonatal Med* 2008;13:231-238.
- 49 Senat MV, Bernard JP, Loizeau S, Ville Y: Management of single fetal death in twin-to-twin transfusion syndrome: a role for fetal blood sampling. *Ultrasound Obstet Gynecol* 2002;20:360-363.
- 50 Senat MV, Loizeau S, Couderc S, Bernard JP, Ville Y: The value of middle cerebral artery peak systolic velocity in the diagnosis of fetal anemia after intrauterine death of one monochorionic twin. *Am J Obstet Gynecol* 2003;189:1320-1324.
- 51 van SA, Zhao DP, Steggerda SJ, Kist WJ, Haak MC, Oepkes D, Lopriore E: Double fatal outcome after ruptured vasa previa in monochorionic twins: case report and review of the literature. *J Matern Fetal Neonatal Med* 2016;29:2523-2526.
- 52 Bohiltea RE, Cirstoiu MM, Ciuvica AI, Munteanu O, Bodean O, Voicu D, Ionescu CA: Velamentous insertion of umbilical cord with vasa praevia: case series and literature review. *J Med Life* 2016;9:126-129.
- 53 Ruiter L, Kok N, Limpens J, Derks JB, de Graaf IM, Mol B, Pajkrt E: Incidence of and risk indicators for vasa praevia: a systematic review. *BJOG* 2016;123:1278-1287.
- 54 Gandhi M, Cleary-Goldman J, Ferrara L, Ciorica D, Saltzman D, Rebarber A: The association between vasa previa, multiple gestations, and assisted reproductive technology. *Am J Perinatol* 2008;25:587-589.
- 55 Oyelese Y, Catanzarite V, Prefumo F, Lashley S, Schachter M, Tovbin Y, Goldstein V, Smulian JC: Vasa

- previa: the impact of prenatal diagnosis on outcomes. *Obstet Gynecol* 2004;103:937-942.
- 56 Lubetzky R, Ben-Shachar S, Mimouni FB, Dollberg S: Mode of delivery and neonatal hematocrit. *Am J Perinatol* 2000;17:163-165.
  - 57 Sheffer-Mimouni G, Mimouni FB, Lubetzky R, Kupfermanc M, Deutsch V, Dollberg S: Labor does not affect the neonatal absolute nucleated red blood cell count. *Am J Perinatol* 2003;20:367-371.
  - 58 Wu JH, Chou HC, Chen PC, Jeng SF, Chen CY, Tsao PN, Hsieh CJ, Huang HM, Hsieh WS: Impact of delivery mode and gestational age on haematological parameters in Taiwanese preterm infants. *J Paediatr Child Health* 2009;45:332-336.
  - 59 Lopriore E, Sueters M, Middeldorp JM, Vandenbussche FP, Walther FJ: Haemoglobin differences at birth in monochorionic twins without chronic twin-to-twin transfusion syndrome. *Prenat Diagn* 2005;25:844-850.
  - 60 Verbeek L, Zhao DP, Te Pas AB, Middeldorp JM, Hooper SB, Oepkes D, Lopriore E: Hemoglobin Differences in Uncomplicated Monochorionic Twins in Relation to Birth Order and Mode of Delivery. *Twin Res Hum Genet* 2016;1-5.
  - 61 Teixeira JM, Duncan K, Letsky E, Fisk NM: Middle cerebral artery peak systolic velocity in the prediction of fetal anemia. *Ultrasound Obstet Gynecol* 2000;15:205-208.
  - 62 Chang YL, Chao AS, Peng HH, Chang SD, Su SY, Chen KJ, Cheng PJ, Wang TH: Increased Fetal Plasma Erythropoietin in Monochorionic Twin Pregnancies With Selective Intrauterine Growth Restriction and Abnormal Umbilical Artery Doppler. *Twin Res Hum Genet* 2016;19:383-388.



