



Universiteit  
Leiden  
The Netherlands

## Near-infrared image guidance in cancer surgery

Schaafsma, B.E.

### Citation

Schaafsma, B. E. (2017, April 19). *Near-infrared image guidance in cancer surgery*. Retrieved from <https://hdl.handle.net/1887/48097>

Version: Not Applicable (or Unknown)

License: [Licence agreement concerning inclusion of doctoral thesis in the Institutional Repository of the University of Leiden](#)

Downloaded from: <https://hdl.handle.net/1887/48097>

**Note:** To cite this publication please use the final published version (if applicable).

Cover Page



Universiteit Leiden



The handle <http://hdl.handle.net/1887/48097> holds various files of this Leiden University dissertation.

**Author:** Schaafsma , B.E.

**Title:** Near-infrared image guidance in cancer surgery

**Issue Date:** 2017-04-19

# PART II

---

## Clinical translation of optical tumor imaging





# Chapter 6

---

## **Optical mammography using diffuse optical spectroscopy for monitoring tumour response to neoadjuvant chemotherapy in women with locally advanced breast cancer**

Schaafsma BE, van de Giessen M, Charehbil A, Smit VTHBM, Kroep JR, Lelieveldt BPF, Liefers GJ, Chan A, Löwik CWGM, Dijkstra J, van de velde CJH, Wasser MNJM, Vahrmeijer AL

*Clinical Cancer Research* 2014;21;577-584

## ABSTRACT

### Purpose

Diffuse optical spectroscopy (DOS) has the potential to enable monitoring of tumour response during chemotherapy, particularly in the early stages of treatment. This study aims to assess feasibility of DOS for monitoring treatment response in HER2-negative breast cancer patients receiving neoadjuvant chemotherapy (NAC) and compare DOS with tumour response assessment by MRI.

### Experimental Design

Patients received NAC in six cycles of 3 weeks. In addition to standard treatment monitoring by dynamic contrast enhanced MRI (DCE-MRI), DOS scans were acquired after the first, third, and last cycle of chemotherapy. The primary goal was to assess feasibility of DOS for early assessment of tumour response. The predictive value of DOS and DCE-MRI compared with pathologic response was assessed.

### Results

Of the 22 patients, 18 patients had a partial or complete tumour response at pathologic examination, whereas 4 patients were nonresponders. As early as after the first chemotherapy cycle, a significant difference between responders and nonresponders was found using DOS ( $\text{HbO}_2$  86%  $\pm$  25 vs. 136%  $\pm$  25,  $P = 0.023$ ). The differences between responders and nonresponders continued during treatment (halfway treatment,  $\text{HbO}_2$  68%  $\pm$  22 vs. 110%  $\pm$  10,  $P = 0.010$ ). Using DCE-MRI, a difference between responders and nonresponders was found halfway treatment ( $P = 0.005$ ) using tumour volume measurement calculations.

### Conclusions

DOS allows for tumour response assessment and is able to differentiate between responders and nonresponders after the first chemotherapy cycle and halfway treatment. In this study, DOS was equally effective in predicting tumour response halfway treatment compared with DCE-MRI. Therefore, DOS may be used as a novel imaging modality for (early) treatment monitoring of NAC.

## INTRODUCTION

Neoadjuvant chemotherapy (NAC) has been established as the standard-of-care treatment for locally advanced inoperable breast cancer, and is increasingly being used for patients with operable cancer.<sup>1,2</sup> A pathologic complete response (pCR) has been consistently shown to be associated with increased long term survival.<sup>2</sup> A significant number of patients, however, is unresponsive to NAC or even experience tumour growth under NAC.<sup>3,4</sup> A key advantage of NAC is the opportunity to assess response during treatment as a predictor of final pathologic response, with the potential to modify therapy. Therefore, the early knowledge of response to NAC is essential for providing the optimal treatment strategy.

Currently, response of the tumour to NAC is most often monitored by a combination of clinical examination and conventional imaging techniques, such as mammography, ultrasound, or dynamic contrast enhanced MRI (DCE-MRI). However, clinical examination and these imaging techniques are often unable to objectively assess treatment response during the course of treatment.<sup>5</sup> Moreover, the correlation between MRI and pCR assessment is limited.<sup>6-8</sup> Therefore, novel, noninvasive imaging techniques are needed to improve early monitoring response of the tumour to NAC. In addition to DCE MRI and PET modalities, optical imaging has received new interest as a noninvasive and nonionizing technique to assess tumour response.<sup>9-14</sup>

Diffuse optical spectroscopy (DOS) uses near-infrared light to provide quantitative spectral information about tissue absorption and scattering properties.<sup>15,16</sup> These optical properties of tissue can be used to assess tissue microstructure and functional parameters, such as oxygenated hemoglobin, deoxygenated hemoglobin, relative oxygen desaturation, and water and lipid composition. Hypoxia, blood flow, oxygen saturation, and hemoglobin concentration are correlated to tumour response.<sup>17</sup> As DOS is noninvasive and does not require contrast agents, it is a promising modality for frequent measurements of tumour response.

Multiple studies have assessed DOS for monitoring NAC treatment in patients with breast cancer.<sup>9-14</sup> These studies have suggested that DOS may provide clinically useful information on tumour response on NAC treatment. In previous studies, patients using different chemotherapeutic regimens were included. This study aims to assess the feasibility and predictive power of DOS for monitoring treatment response in patients with breast cancer receiving NAC directly after the start of NAC until surgery. Moreover, this study compares the tumour response assessment by DOS to tumour response assessment by MRI.

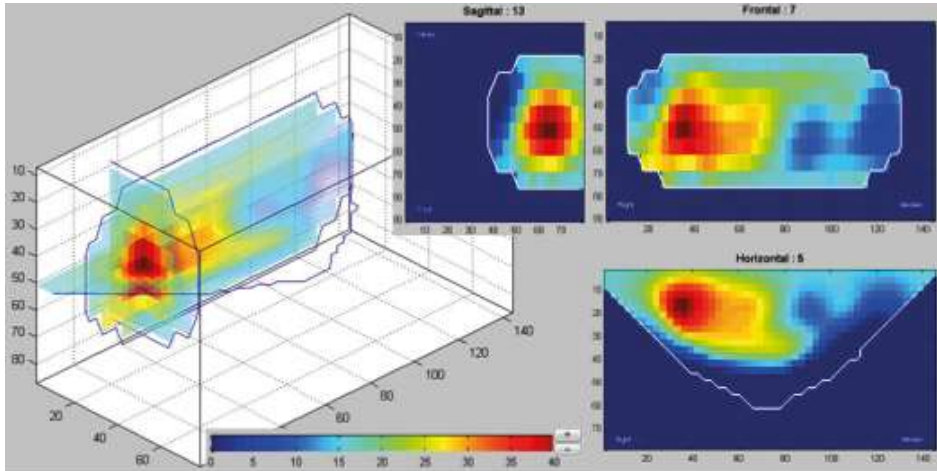


Fig. 1. Acquired DOS data of HbO<sub>2</sub> ( $\mu\text{mol/L}$ ) was reconstructed to allow 3D analysis (BreastViewer 3.1).

## MATERIALS AND METHODS

This prospective, single-arm, single-center study was approved by the Medical Ethics Committee of the Leiden University Medical Center (Leiden, the Netherlands) and was performed in accordance with the ethical standards of the Helsinki Declaration of 1975. Inclusion criteria were patients with breast cancer with- HER2 negative tumours larger than 2 cm or HER2-negative tumours with lymph node metastases, without distant metastases and eligible for neoadjuvant treatment. Patients with known allergies to materials used in the DOS apparatus, prior breast surgery or chemotherapy or radiation therapy were excluded. Patients were included in the period from March 2011 to October 2012. All included patients gave informed consent and the acquired data were anonymized.

### Clinical trial

Patients received TAC (docetaxel, doxorubicin, and cyclophosphamide) with or without zoledronic acid in six cycles of 3 weeks. Patients were mainly enrolled in the context of the NEOZOTAC trial (NCT01099436). Standard monitoring of treatment response of the tumour to NAC was based on clinical examination before each cycle and three dynamic contrast enhanced MRI (DCE-MRI) scans (before NAC, before fourth cycle, before surgery) performed on a 1.5 Tesla system (Philips Medical Systems). In addition, patients were scheduled for four optical mammographies using DOS (before NAC, before second cycle, before fourth cycle, before surgery). DOS was performed using a commercially available breast imaging system (Softscan; Softscan Healthcare Group) as described previously.<sup>18</sup> Briefly, Softscan is a bed-based imaging system on which the patient has to lie down with the breast inserted into an aquarium filled with



optical compensation media (OCM). OCM is an oil-in-water emulsion that mimics average optical properties of the human breast. It is used to minimize light reflections at the breast surface to improve image quality. The system consists of four individual pulsed diode lasers operating at 690, 730, 780, and 830 nm. Light is collected by a mobile detector in a 1 cm-X constellation composed of five optical fibers and detected by a photomultiplier. The breast is scanned in approximately 10 to 20 minutes. The count by the detector was time correlated with the synchronization signal provided by the laser system driver. Using the measured absorption and scattering, an accurate estimate of the oxyhemoglobin (HbO<sub>2</sub>), deoxyhemoglobin (Hb), total hemoglobin (HbT), and scattering amplitude (SA) and power (SP) can be obtained. Water (H<sub>2</sub>O) and %lipids have low, but non-negligible absorption coefficients at the higher NIR wavelengths and were estimated as well. Patients were positioned into the Softscan aperture under guidance of a radiology technician. Breasts were scanned in the craniocaudal angle and the scanning area encompassed the whole breast. To ensure consistency, stabilizing plates were used to secure the breast in place. The acquired data were reconstructed using the software associated with the Softscan device, and three-dimensional (3D) tomographic images were created from the optical parameters with a typical voxel size of 3 x 3 x 7 mm<sup>3</sup> (Fig. 1).

### **MRI- and pathologic assessment of tumour response to neoadjuvant chemotherapy**

**DCE-MRI response assessment.** Tumour response to NAC on DCE-MRI was assessed in two ways: (i) according to the response evaluation criteria in solid tumours (RECIST 1.1) guidelines and (ii) by semiautomated measurement of tumour volume using a dedicated software program. All measurements were performed by a single observer (M.N.J.M. Wasser).

Following RECIST 1.1, tumour response was measured by changes in the longest diameter of the enhancing tumour target lesions. Complete reduction of the target lesions was termed as a complete response (CR). Partial response (PR) was deemed to have occurred if tumour size was reduced by at least 30%. Progressive disease (PD) was defined as an increase in tumour size of at least 20%. The remaining cases were considered to have stable disease (SD).

Measurement of tumour volumes on the subtracted 3D T1- weighted DCE-MR images was done using dedicated software (Vitrea Enterprise Suite version 6.6.3 software, Vital Images Inc.). Calculation of tumour volume consisted of semiautomated summing of all voxels with enhancement above background parenchymal enhancement.

**Pathology.** Following definitive surgery, the excised specimens were cut in multiple serial sections of approximately 5 mm, fixed in 10% formalin, paraffin embedded as tissue blocks, stained by hematoxylin and eosin, and evaluated by an experienced

Table 1. Patient and Tumour Characteristics

Characteristic	All patients (N=22)	Responders (N=18)	Non-responders (N=4)
	N	N	N
Age in years (median; range)	50 (38-66)	50 (38-59)	50 (46-66)
Menopausal status			
-Premenopausal	16	13	3
-Postmenopausal	6	5	1
Tumour histology			
-Invasive ductal carcinoma	16	12	4
-Invasive lobular carcinoma	6	6	0
Estrogen receptor status			
-Positive	20	17	3
-Negative	22	1	1
Progesterone receptor status			
-Positive	15	12	3
-Negative	7	6	1
HER receptor status			
-Positive	0	0	0
-Negative	22	18	4
Tumour size in mm (median; range)	30 (16-81)	33 (16-81)	29 (16-36)

\* staging according to AJCC guidelines

pathologist to determine the degree of pathologic tumour response of the primary breast lesion. Pathologic response was scored according to the Miller and Payne criteria.

### Diffuse optical spectroscopy assessment of neoadjuvant chemotherapy

Tumour regions in each of the four DOS scans were manually annotated. The tumour in the baseline scan was annotated as an ellipsoid with axes of the sizes reported in the first radiologic assessment. The annotated region was centered on the maximum scatter amplitude in breast section containing the tumour based on conventional radiology. In DOS scans 2 to 4, an annotated region of the same size and shape as in the first scan was centered at the maximum scatter amplitude in these respective scans. Within each annotated region, the mean Hb and HbO<sub>2</sub> contents were measured in  $\mu\text{mol/L}$ . Hb and HbO<sub>2</sub> contents in follow-up scans were normalized by the baseline scan for inter-subject comparison. Subjects where the baseline scan was unreliable were completely excluded. Subjects where a follow-up scan was unreliable were removed from the respective groups. Criteria for unreliable scans were tumour on the edge of the scan or outside the scan and severe reconstruction artifacts in the breast section containing the tumour. Severe reconstruction artifacts were identified as physically improbable measurements, particularly zero SA and negative scatter power.

## Patient and tumour characteristics

A total of 25 patients were initially included in the study. Two patients were excluded because of a failed baseline DOS scan and one patient due to a failed scan after one cycle. Patient and tumour characteristics of the 22 analyzed patients are summarized in Table 1. The median age was 50 years (range, 38–66), and median tumour size before NAC was 30mm (range, 16–81). Of the patients, 6 patients had lobular carcinoma, 16 had ductal carcinoma, 20 had an ER-positive tumour, and 15 had a PR-positive tumour. All patients received a DOS scan before NAC and before the second cycle. In 2 patients, the DOS scan halfway therapy and in 4 patients the DOS scan before surgery was not performed because of patient complications (not related to Softscan) or logistic reasons.

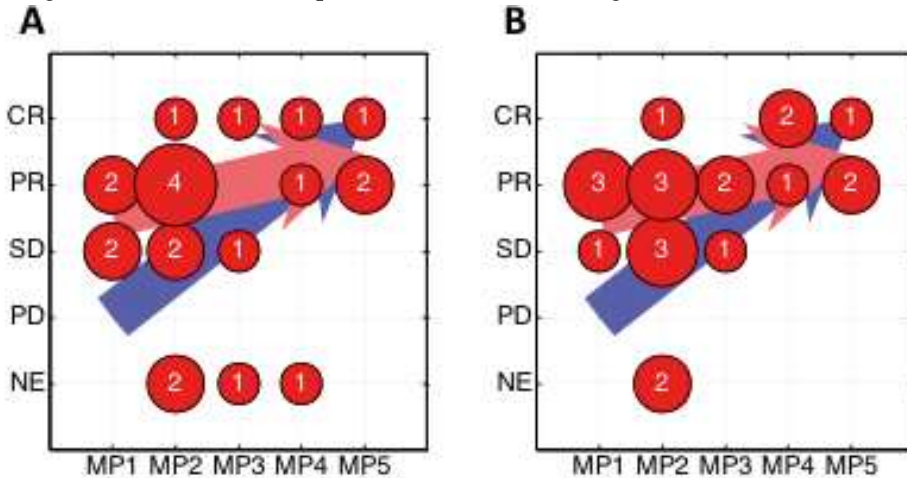
## Data and statistical analysis

The primary goal of this study was to assess feasibility of DOS for assessment of tumour response to NAC based on pathologic response before the second NAC cycle. Failure of a missed first or second DOS scan resulted in exclusion from further DOS scans. All subjects were divided in two groups based on the Miller and Payne criteria: nonresponders (MP 1; i.e., 0% decrease of tumour cellularity after NAC) and (partial) responders (MP 2-5). For DOS time points, the changes in Hb and HbO<sub>2</sub> with respect to baseline were compared between the two groups and tested for significant differences using the Mann–Whitney U test. To test the predictive power of the DOS scans for identification of nonresponders, a linear logistic classifier was trained. For the DOS scans, HbO<sub>2</sub> was used as the feature. The classification performance was tested by training on 50% of the data, using the other 50% for testing. The classifier was evaluated by estimating an ROC. Because of the small number of patients, the training and testing were repeated 100 times with different permutations of training and test datasets. The average ROC was computed for final predictive power evaluation.

To compare DOS with DCE-MRI, the sensitivity and specificity of both RECIST and MRI volume measurements to predict tumour response (pathologic) to chemotherapy were assessed. The radiologic assessment by RECIST criteria was converted into a numerical ordering as: PD: 1, SD: 2, PR: 3 and CR: 4. Volume measurements after three and six cycles were normalized to the baseline tumour volume. Subjects were divided in two groups based on the same Miller and Payne criteria: nonresponders (MP 1) and (partial) responders (MP 2-5). The RECIST criteria and normalized volumes after three and six cycles were compared between the two groups and tested for significant differences using the Man Whitney U test. Moreover, the predictive power of MRI was assessed. Both assessment by MRI using

the RECIST 1.1 criteria and MRI volume were used to predict tumour response to NAC (MP criteria) by training a logistic classifier as for DOS.

Predictive power is estimated from classification results. The classification result is a trade-off between the desired fraction of true positives (nonresponders classified as nonresponders) and the accepted fraction of false positives (responders classified as nonresponders). The area under the curve (AUC) is a measure for the predictive power and is 1 for a perfect classifier (100% true positives for 0% false negatives), 0.5 for a random classification (similar to a coin-flip), and 0 for a completely wrong classification (0% true positives for 100% false negatives).



**Fig. 2.** Agreement between Miller and Payne (MP) criteria and radiology assessment by DCE-MRI using RECIST criteria after three cycles (A) and after six cycles (B) of NAC. The values indicate the patient count. The blue arrow denotes the expected relation, whereas the red arrow shows the linear regression Between MP and DCE-MRI. MRI was assessed according to the RESIST criteria. NE, not evaluated.

## RESULTS

### MRI and pathologic assessment of tumour response

A summary of DCE-MRI response (RECIST criteria) and pathologic response (Miller and Payne criteria) measurements is given in Fig. 2. In 4 patients after three cycles and in 2 patients after six cycles, RECIST criteria could not be applied because of scattered presentation of the contrast-enhanced lesions and as in 1 patient no, MRI was obtained. Tumour volume could not be accurately measured in 1 patient after six cycles because of too scattered presentation.

MRI response measurements after three cycles (halfway treatment) indicated zero patients with PD, 5 patients with SD, 9 patients with a PR, and 4 patients with a CR.

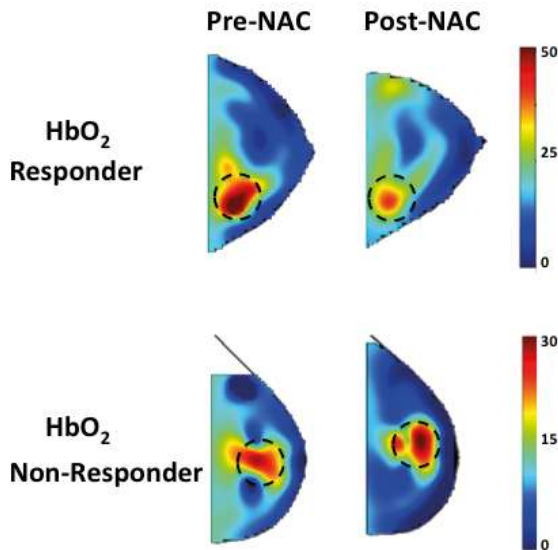
After six cycles and before surgery, MRI response measurements indicated 0 patients with PD, 5 patients with SD, 11 patients with a PR, and 4 patients with a CR.

The distribution of the pathologic response classification, following Miller and Payne, was as follows: grade 1, 4 patients; grade 2, 9 patients, grade 3, 3 patients; grade 4, 3 patients; grade 5, 3 patients.

### Comparison between responders and nonresponders

**Diffuse optical spectroscopy.** In all 22 patients, the tumour could be located on the optical mammography. The mean HbO<sub>2</sub> content (SDs between parentheses) for tumours at baseline were 25.9 (7.8)  $\mu\text{mol/L}$  for responders and 16.7 (3.8)  $\mu\text{mol/L}$  for nonresponders. Corresponding Hb content was 10.5 (3.8)  $\mu\text{mol/L}$  and 8.2 (0.8)  $\mu\text{mol/L}$ . These differences were nonsignificant:  $P = 0.064$  (HbO<sub>2</sub>),  $P = 0.335$  (Hb). In follow-up scans, interpatient variability remained and Hb and HbO<sub>2</sub> content ( $\mu\text{mol/L}$ ) was not significantly different between responders and nonresponders:  $P > 0.500$  for all follow-up scans.

However, the average Hb and HbO<sub>2</sub> contents relative to baseline in Table 2 show clear significant differences between responders and nonresponders that are distributed on the basis of pathologic criteria. The relative HbO<sub>2</sub> content (compared with baseline) is significantly lower in all three treatment stages:  $P = 0.023$  after one cycle,  $P = 0.010$  after three cycles, and  $P = 0.009$  after therapy completion. Representative examples of DOS in responders ( $n = 18$ ; decrease of HbO<sub>2</sub> content) and nonresponders ( $n = 4$ ; stable or increasing HbO<sub>2</sub> content) are shown in Fig. 3. The average Hb content for responders is lower for all cycles, but this is not statistically significant.



**Fig. 3.** Transverse DOS images (after interpolation) before and after NAC of a typical responder, which shows a significant decrease of HbO<sub>2</sub> ( $\mu\text{mol/L}$ ) in the area of the tumour after NAC (top row), and nonresponder, which shows increase of HbO<sub>2</sub> in the area of the tumour after NAC (bottom row). The circle indicates where the tumour is located.

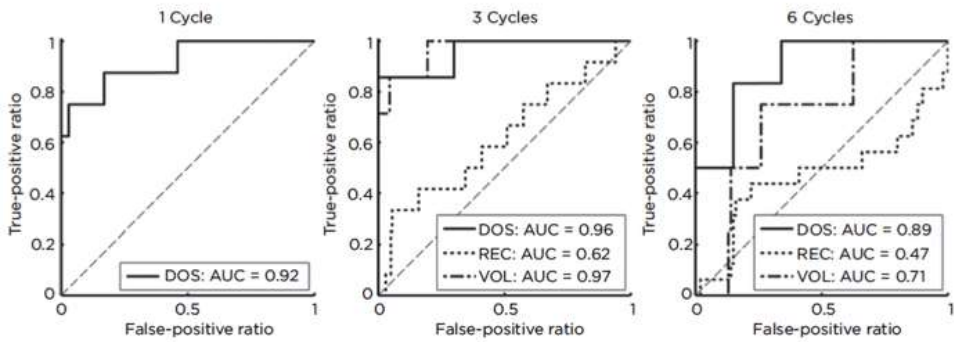
**Table 2.** Differentiation between responders and non-responders using DOS

<b>DOS Measurements</b>				
<b>Hb</b>	<b>Baseline</b>	<b>1 Cycle</b>	<b>3 Cycles</b>	<b>6 Cycles</b>
Responder Hb (%)	100 (0)	91 (42)	76 (25)	83 (40)
Nonresponder Hb (%)	100 (0)	118 (11)	101 (3)	119 (39)
U-test p-value	1	0.109	0.076	0.233
<b>HbO<sub>2</sub></b>				
<b>HbO<sub>2</sub></b>	<b>Baseline</b>	<b>1 Cycle</b>	<b>3 Cycles</b>	<b>6 Cycles</b>
Responder HbO <sub>2</sub> (%)	100 (0)	86 (25)	68 (22)	65 (20)
Nonresponder HbO <sub>2</sub> (%)	100 (0)	136 (25)	110 (10)	109 (18)
U-test p-value	1	0.023	0.010	0.009
<b>MRI volume measurements</b>				
	<b>Baseline</b>		<b>3 Cycles</b>	<b>6 Cycles</b>
Responder	100 (0)		32 (23)	12 (24)
Nonresponder	100 (0)		78 (11)	65 (64)
U-test p-value	1		0.005	0.011

Average Hb and HbO<sub>2</sub> content relative to baseline for responders and non-responders selected based on pathology criteria. Standard deviations are between parentheses. The Mann-Whitney U-test p-values estimate significance of the differences between the two groups. Bold text highlights p-values indicating statistically significant differences (p<0.05).

**Dynamic contrast enhanced MRI.** The Mann–Whitney U test shows no significant difference in DCE- MRI assessment using RECIST for pathologic responders (MP 2-5, n = 18) and nonresponders (MP 1, n = 4) both after three cycles (P = 0.10) and after six cycles (P = 0.77). This is further illustrated in Fig. 2. After both three and six cycles, a weak trend is visible in which a better response seems to correspond to a higher Miller and Payne ranking. This is, however, far from statistically significant. Correlation coefficients between Miller and Payne and RECIST assessment were 0.43 after both three and six cycles of NAC.

MRI volume measurements show statistically significant differences between responders and nonresponders after both three (P = 0.005) and six cycles (P = 0.011; Table 2). In both responders and nonresponders, the tumour has decreased halfway therapy and decreased even further in the scan before surgery. The decrease in tumour volume is much stronger in the group with responders. Correlations between normalized MRI volumes and normalized Hb/HbO<sub>2</sub> content after three cycles were 0.46 and 0.69 for Hb and HbO<sub>2</sub>, respectively, and 0.64 (Hb) and 0.70 (HbO<sub>2</sub>) after six cycles.



**Fig. 4.** Predictive value of DOS and MRI-ROC curves for DOS and conventional radiology by MRI using RECIST (REC) and volume measurements (VOL) after one, three, and six cycles of NAC. The dashed diagonal shows a ROC for a completely random classification result with an AUC of 0.5.

### Predictive power of diffuse optical spectroscopy and MRI

The ROC curves in Fig. 4 show the prediction sensitivity and specificity for different trade-offs for DOS, RECIST, and DCE-MRI volumes normalized to baseline. For DOS assessment after only one cycle, accepting incorrect classification of 5% of the responders as nonresponders would correctly identify 75% of the nonresponders and allow them to change therapy. Similarly, accepting 10% incorrectly identified responders would correctly identify 87% of the nonresponders as responders.

The ROC curves show that DOS and normalized volume measurements have a comparable predictive power, both far better than RECIST. For example, predicting if a patient is a nonresponder after three cycles with a 20% false-positive rate is correct in 86% of the DOS scans and volume measurements, while this is only correct in 58% of the RECIST assessments. Considering the AUC, the predictive power for DOS is similar for all time points, with AUC values of 0.92, 0.96, and 0.89 after, respectively, one, three, and six cycles. The MRI volume AUC is 0.97 after three cycles and 0.71 after six cycles. The RECIST AUC is 0.62 after three cycles and only 0.47 after six cycles. These RECIST figures are much lower than that for DOS and MRI volume measurements, especially when taking into account that an AUC of 0.5 corresponds to a random prediction. The MRI volume measurements at six cycles have a decreased predictive power due to tumours that were nonresponders based on the MP criteria, but showed no contrast enhancement after six cycles. The large SD of 64 in Table 2 is indicative for the wide spread of nonresponding tumour volumes after six cycles.

## DISCUSSION

The present study demonstrates the clinical use of DOS for treatment monitoring of NAC in patients with breast cancer. Treatment monitoring using DOS showed a significant difference in the physiologic tumour parameters between responders and nonresponders as early as after the first gift of NAC. Moreover, the predictive value of DOS to determine tumour response corresponded to MRI volume measurements after three cycles but appeared to outperform DCE-MRI evaluation based on RECIST.

DOS showed a decrease in Hb and HbO<sub>2</sub> content in the patients with a response of the tumour to NAC. We found this decrease to be only statistically significant for HbO<sub>2</sub>, but not for Hb. Similar results were obtained in previous studies.<sup>9–13, 20</sup> In comparative studies between Hb and HbO<sub>2</sub> levels in tumour tissue and healthy tissue, tumour tissue shows nearly a 2-fold increased level of Hb and HbO<sub>2</sub> as a result of increased vascular supply.<sup>17</sup> The decrease of Hb and HbO<sub>2</sub> levels observed in the study suggests a decrease of tumour tissue and an increase of nontumourous tissue in the region of interest (ROI) where the tumour was located. The reason we did not find a statistically significant decrease of Hb can be partly attributed to the small number of nonresponders (N = 4), compared with the large number of responders. Under these circumstances, the Mann–Whitney U test has a strongly decreased sensitivity and only large group differences as in the relative HbO<sub>2</sub> changes were tested as statistically significantly different.

The absolute quantities of Hb and HbO<sub>2</sub> at baseline were varying greatly between tumours and did not show significant differences between potential responders and nonresponders. This large inter patient variability was also present in the follow-up scans, and responders and nonresponders could not be separated on the basis of absolute Hb and HbO<sub>2</sub> content (μmol/L). Normalization with respect to the baseline scan is thus essential. Apart from Hb and HbO<sub>2</sub>, the two most important absorbers in NIR are water and lipids. The low absorption coefficients of the latter two, compared with Hb and HbO<sub>2</sub>, prevented reliable estimates, with frequent erroneous estimates (0% or 100% water/lipids content).

Correlating the normalized DOS parameters Hb, HbO<sub>2</sub> with normalized MRI volume measurements showed a strong positive relationship between changes in MRI volume and changes in (de)oxyhemoglobin content. Although it is likely that tumour volume and oxygenation have a positive relationship, a confounder may be in the hemoglobin measurements where a constant volume is used to measure these parameters, while the tumour volume has decreased and additional normal tissue can be in the measurement volume. One should therefore be careful with interpreting the absolute hemoglobin measurements in relation to tumour viability.

In the current study, a homogenous HER2-negative group of patients with locally advanced breast cancer was used receiving the same NAC regime. It is important



to validate DOS in a homogenous patient group as tumour variables such as HER2 status and tumour size have a significant effect on the optical properties of tumours. Positive HER2 tumours have a significant higher Hb level by DOS assessment.<sup>21</sup> This is most likely related to angiogenesis as HER2 overexpression is associated with increased angiogenesis. As the difference between Hb levels between HER2-positive tumours and healthy tissue is larger compared with HER2-negative tumours, it can be expected that DOS assessment of NAC in HER2-positive tumours will result in even a more distinct difference between responders and nonresponders.

Moreover, in addition to NAC, neoadjuvant hormonal therapy is also increasing rapidly and has shown similar patient outcomes compared with NAC.<sup>22</sup> Many different anticancer agents are available (chemotherapy, hormonal therapy, monoclonal agents), all have different antitumour and antiangiogenic effects. Therefore, when assessing early treatment response, it is crucial to use a homogenous treatment regime. As the therapeutic effect of hormonal therapy acts on a different mechanism compared with chemotherapy, validation of using DOS for treatment monitoring in neoadjuvant hormonal therapy is essential to provide wide clinical use of DOS in the treatment monitoring of patients with breast cancer.<sup>23</sup>

With the increasing interest in neoadjuvant treatment, improved imaging modalities that can provide early prediction of tumour response will be required to select patient who may benefit from a different treatment. In case of locally advanced breast cancer, early detection of nonresponders could prevent unnecessary toxic NAC treatment and allow selecting patient who would benefit from a different neoadjuvant treatment regime or early surgery. In the current study, after one cycle of NAC, DOS would correctly identify most nonresponders, allowing them to change treatment strategy early. Prediction accuracies were evaluated as AUCs of 0.92, 0.96, and 0.87 after one, three, and six cycles, respectively. The lower AUC after six cycles is due to a smaller number of available scans for classifier training. Previous studies have shown similar results showing specificity of 80% to 83%.<sup>9,11</sup> These data suggest that DOS is able to identify a large set of patients early during treatment that would benefit from a different treatment regime. However, it should be emphasized that prospective studies are necessary to validate these results.

In the current study, the predictive value of DOS to determine tumour response corresponded to MRI volume measurements after three cycles but appeared to outperform DCE-MRI evaluation based on RECIST. To date, DCE-MRI is the most accurate response assessment.<sup>24</sup> However, this modality is not in all breast tumours equally reliable. Several breast tumour subtypes, such as HER2-negative and ER-positive breast tumours, are associated with reduced accuracy.<sup>25</sup> This might explain the poor adequacy of MRI in our study, as our study population consisted almost completely of HER2-negative and ER-positive patients. The biologic explanation for this may be that HER2-negative breast cancer is associated with decreased angiogenesis, resulting in

impaired tumour tissue perfusion of MRI contrast.<sup>26</sup> Also, hormone receptor-positive tumours have a different growth pattern than hormone receptor-negative tumours, with less often (unifocal) mass-like lesions, making it more difficult to accurately determine the residual tumour diameter.<sup>8,27</sup>

Limitation of the used DOS device in our study is that determination of the correct ROI for the DOS was difficult because DOS provided limited anatomical context. Therefore, the ROI at baseline was partly based upon data of conventional mammography and MRI acquired before therapy. Localization of the ROI was not trivial during data analysis and incorrect ROI placement can lead to an underestimation of tissue changes and consequently decrease the sensitivity. A 5-mm displacement of the ROI introduces variations in Hb/HbO<sub>2</sub> estimates of about 2% for tumours of about 30 cm<sup>3</sup>, whereas for smaller tumours of approximately 5 cm<sup>3</sup>, estimates could differ by up to 8%. The possibility of merging MRI and DOS could therefore improve DOS assessment and provide more functional parameters to the MRI and further increase the sensitivity.

DOS is a relatively novel imaging modality in the field of breast cancer and is rapidly evolving by increasing spatial resolution and by increasing analytic techniques to provide more accurate assessment of functional parameters.<sup>28,29</sup> A recent study by Roblyer and colleagues indicated that DOS as early as the first day after NAC may possibly discriminate nonresponding from responding patients.<sup>30</sup> Remarkably, this study found an increase in HbO<sub>2</sub> for responders, compared with nonresponders, while monitoring in the first week. Roblyer and colleagues hypothesized that this increase can be attributed to an acute inflammatory reaction in the responding tumours. Measurements with the same device as Roblyer and colleagues at mid-therapy and before surgery showed lower HbO<sub>2</sub> values for responders, comparable with our findings.<sup>30</sup> We therefore hypothesize that after the acute inflammatory reaction stops, the responding tumours have a lower metabolism and that our measurement after 3 weeks (one cycle) is measuring the same decrease in metabolism in the tumour as response to NAC as the measurements after three and six cycles. A future study with frequent measurements during the first 3 weeks after NAC therapy starts could provide further insight.

Moreover, several optical contrast agents are available, which may improve contrast and sensitivity.<sup>31,32</sup> Furthermore, DOS can be combined with other imaging modalities, such as ultrasound, for improved tumour localization accuracy.<sup>11</sup> These developments will allow further improvement of DOS sensitivity and accuracy.

In conclusion, DOS allows early response monitoring of tumour tissue to chemotherapy and is able to differentiate between responders and nonresponders in early stages of therapy. Therefore, DOS could be used as a novel imaging modality for treatment monitoring of NAC to assist patient tailored medicine.

## ACKNOWLEDGMENTS

The authors thank the Softscan Healthcare Group for providing OCM and technical support and for providing the Softscan breast imaging system, and Gemma Ranke and Elly Krol-Warmerdam (Breast Cancer Unit) for their contribution to this study. This work was supported in part by the Dutch Cancer Society grants UL2010- 4732. This research was performed within the framework of CTMM, the Center for Translational Molecular Medicine, project MUSIS (grant 03O-202). The costs of publication of this article were defrayed in part by the payment of page charges. This article must therefore be hereby marked advertisement in accordance with 18 U.S.C. Section 1734 solely to indicate this fact.

## REFERENCES

1. Mieog JS, van derHage JA, van de Velde CJ. Neoadjuvant chemotherapy for operable breast cancer. *Br J Surg* 2007;94:1189–200.
2. Kaufmann M, von Minckwitz G, Mamounas EP, et al. Recommendations from an international consensus conference on Optical Imaging for Treatment Monitoring in Breast Cancer the current status and future of neoadjuvant systemic therapy in primary breast cancer. *Ann Surg Oncol* 2012;19:1508–16.
3. von Minckwitz G, Blohmer JU, Raab G, et al. In vivo chemosensitivity-adapted preoperative chemotherapy in patients with early-stage breast cancer: the GEPARTRIO pilot study. *Ann Oncol* 2005;16:56–63.
4. Caudle AS, Gonzalez-Angulo AM, Hunt KK, et al. Predictors of tumor progression during neoadjuvant chemotherapy in breast cancer. *J Clin Oncol* 2010;28:1821–8.
5. Yeh E, Slanetz P, Kopans DB, et al. Prospective comparison of mammography, sonography, and MRI in patients undergoing neoadjuvant chemotherapy for palpable breast cancer. *AJR Am J Roentgenol* 2005;184:868–77.
6. Croshaw R, Shapiro-Wright H, Svensson E, et al. Accuracy of clinical examination, digital mammogram, ultrasound, and MRI in determining postneoadjuvant pathologic tumor response in operable breast cancer patients. *Ann Surg Oncol* 2011;18:3160–3.
7. Marinovich ML, Sardanelli F, Ciatto S, et al. Early prediction of pathologic response to neoadjuvant therapy in breast cancer: systematic review of the accuracy of MRI. *Breast* 2012; 21:669–77.
8. Loo CE, Straver ME, Rodenhuis S, et al. Magnetic resonance imaging response monitoring of breast cancer during neoadjuvant chemotherapy: relevance of breast cancer subtype. *J Clin Oncol* 2011;29:660–6.
9. Falou O, Soliman H, Sadeghi-Naini A, et al. Diffuse optical spectroscopy evaluation of treatment response in women with locally advanced breast cancer receiving neoadjuvant chemotherapy. *Transl Oncol* 2012;5:238–46.
10. Ueda S, Roblyer D, Cerussi A, et al. Baseline tumor oxygen saturation correlates with a pathologic complete response in breast cancer patients undergoing neoadjuvant chemotherapy. *Cancer Res* 2012;72:4318–28.
11. Zhu Q, DeFusco PA, Ricci A Jr, et al. Breast cancer: assessing response to neoadjuvant chemotherapy by using US-guided near-infrared tomography. *Radiology* 2013;266:433–42.
12. O'Sullivan TD, Leproux A, Chen JH, et al. Optical imaging correlates with magnetic resonance imaging breast density and reveals composition changes during neoadjuvant chemotherapy. *Breast Cancer Res* 2013;15:R14.
13. Soliman H, Gunasekara A, Rycroft M, et al. Functional imaging using diffuse optical spectroscopy of neoadjuvant chemotherapy response in women with locally advanced breast cancer. *Clin Cancer Res* 2010;16:2605–14.
14. Busch DR, Choe R, Rosen MA, et al. Optical malignancy parameters for monitoring progression of breast cancer neoadjuvant chemotherapy. *Biomed Opt Express* 2013;4:105–21.
15. Tromberg BJ, Shah N, Lanning R, et al. Noninvasive in vivo characterization of breast tumors using photon migration spectroscopy. *Neoplasia* 2000;2:26–40.
16. Ntziachristos V, Chance B. Probing physiology and molecular function using optical imaging: applications to breast cancer. *Breast Cancer Res* 2001;3:41–6.
17. Tromberg BJ, Cerussi A, Shah N, et al. Imaging in breast cancer: diffuse optics in breast cancer: detecting tumors in pre-menopausal women and monitoring neoadjuvant chemotherapy. *Breast Cancer Res* 2005;7:279–85.
18. Intes X. Time-domain optical mammography SoftScan: initial results. *Acad Radiol* 2005;12:934–47.
19. Ogston KN, Miller ID, Payne S, et al. A new histological grading system to assess response of breast cancers to primary chemotherapy: prognostic significance and survival. *Breast* 2003; 12:320–7.
20. Jiang S, Pogue BW, Carpenter CM, et al. Evaluation of breast tumor response to neoadjuvant chemotherapy with tomographic diffuse optical spectroscopy: case studies of tumor region-of-interest changes. *Radiology* 2009;252:551–60.

21. Choi JS, Kim MJ, Youk JH, et al. US-guided optical tomography: correlation with clinicopathologic variables in breast cancer. *Ultrasound Med Biol* 2013;39:233–40.
22. Charehbili A, Fontein DB, Kroep JR, et al. Neoadjuvant hormonal therapy for endocrine sensitive breast cancer: a systematic review. *Cancer Treat Rev* 2014;40:86–92.
23. Enfield L, Cantanhede G, Douek M, et al. Monitoring the response to neoadjuvant hormone therapy for locally advanced breast cancer using three dimensional time-resolved optical mammography. *J Biomed Opt* 2013;18:56012.
24. Marinovich ML, Macaskill P, Irwig L, et al. Meta-analysis of agreement between MRI and pathologic breast tumour size after neoadjuvant chemotherapy. *Br J Cancer* 2013;109:1528–36.
25. Charehbili A, Wasser MN, Smit VT, et al. Accuracy of MRI for treatment response assessment after taxane- and anthracycline-based neoadjuvant chemotherapy in HER2-negative breast cancer. *Eur J Surg Oncol* 2014;40:1216–21.
26. Blackwell KL, Dewhirst MW, Liotcheva V, et al. HER-2 gene amplification correlates with higher levels of angiogenesis and lower levels of hypoxia in primary breast tumors. *Clin Cancer Res* 2004;10:4083–8.
27. Kuzucan A, Chen JH, Bahri S, et al. Diagnostic performance of magnetic resonance imaging for assessing tumor response in patients with HER2-negative breast cancer receiving neoadjuvant chemotherapy is associated with molecular biomarker profile. *Clin Breast Cancer* 2012;12:110–8.
28. Karkala D, Yalavarthy PK. Data-resolution based optimization of the data collection Strategy for near infrared diffuse optical tomography. *Med Phys* 2012;39:4715–25.
29. Lin AJ, Ponticorvo A, Konecky SD, et al. Visible spatial frequency domain imaging with a digital light microprojector. *J Biomed Opt* 2013;18:096007.
30. Roblyer D, Ueda S, Cerussi A, et al. Optical imaging of breast cancer oxyhemoglobin flare correlates with neoadjuvant chemotherapy response one day after starting treatment. *PNAS U S A* 2011;108:14626–31.
31. Poellinger A, Burock S, Grosenick D, et al. Breast cancer: early- and late-fluorescence near-infrared imaging with indocyanine green—a preliminary study. *Radiology* 2011;258:409–16.
32. van de Ven S, Wiethoff A, Nielsen T, et al. A novel fluorescent imaging agent for diffuse optical tomography of the breast: first clinical experience in patients. *Mol Imaging Biol* 2010;12:343–8.

