



Universiteit
Leiden
The Netherlands

Near-infrared image guidance in cancer surgery

Schaafsma, B.E.

Citation

Schaafsma, B. E. (2017, April 19). *Near-infrared image guidance in cancer surgery*. Retrieved from <https://hdl.handle.net/1887/48097>

Version: Not Applicable (or Unknown)

License: [Licence agreement concerning inclusion of doctoral thesis in the Institutional Repository of the University of Leiden](#)

Downloaded from: <https://hdl.handle.net/1887/48097>

Note: To cite this publication please use the final published version (if applicable).

Cover Page



Universiteit Leiden



The handle <http://hdl.handle.net/1887/48097> holds various files of this Leiden University dissertation.

Author: Schaafsma , B.E.

Title: Near-infrared image guidance in cancer surgery

Issue Date: 2017-04-19

Chapter 5

Ex vivo sentinel node mapping in colon cancer combining blue dye staining and fluorescence imaging

Schaafsma BE, Verbeek FPR, van der Vorst JR, Hutteman M, Kuppen PJK, Frangioni JV, van de Velde CJH, Vahrmeijer AL

Journal of Surgical Research 2013;183:253-257

ABSTRACT

Background

The sentinel lymph node procedure has been proposed to improve nodal staging in colon cancer patients. The aim of this study was to assess the added value of near-infrared (NIR) fluorescence imaging to conventional blue dye staining for ex vivo sentinel lymph node mapping.

Materials and methods

We included 22 consecutive patients undergoing surgery for colon cancer. After tumour resection, we submucosally injected a premixed cocktail of the near-infrared lymphatic tracer HSA800 and blue dye around the tumour for detection of sentinel lymph nodes. We used the Mini-FLARE imaging system for fluorescence imaging.

Results

In 95% of patients, we identified at least one sentinel lymph node. Overall, a total of 77 sentinel lymph nodes were identified, 77 of which were fluorescent (100%) and 70 of which were blue (91%). Sentinel lymph nodes that were located deeper in the mesenteric fat could easily be located by NIR fluorescence. In four of five patients with lymph node metastases, tumour cells were present in at least one of the sentinel lymph nodes.

Conclusions

This study shows the successful use and added value of the NIR fluorescence tracer HSA800 to conventional blue dye for the ex vivo sentinel lymph node procedure in colon cancer.

INTRODUCTION

Colorectal cancer is the third most common cancer and remains a major public health issue because of its high prevalence, morbidity, and mortality.¹ Complete surgical removal with en bloc regional lymphadenectomy is pivotal for patient staging and prognosis. Lymph node status is of major importance in proper clinicopathologic staging and determines the need for adjuvant chemotherapy. Although surgery is often considered curative in node-negative disease, approximately 20%-30% of these patients will develop disease recurrence.^{1,2} This is most likely caused by understaging during the initial procedure.

Correct nodal staging depends on multiple factors, including number of examined nodes.³ Moreover, occult tumour cells and micrometastases are easily missed by conventional histopathologic examination. Various retrospective studies have shown poor prognosis for patients with micrometastases compared with patients without metastases.^{4,5} Multiple clinical trials are currently ongoing in which patients with micrometastatic disease are treated with adjuvant chemotherapy, which is currently not considered for this indication.⁶ However, detection of micrometastases often requires ultrastaging techniques for each lymph node using serial sectioning and additional immunohistochemistry or reverse transcriptase-polymerase chain reaction.^{7,8} However, this is currently beyond standard histopathologic analysis and is time consuming, and expensive. To overcome this disadvantage, the sentinel lymph node (SLN) procedure for colon cancer patients has been evaluated extensively.⁹

Sentinel lymph nodes are the first lymph nodes that receive lymphatic drainage from the tumour, and identification of the SLN and analysis for tumour involvement could predict the tumour status of the remaining lymph nodes. Therefore, the SLN procedure in colon cancer can be a useful tool to select the nodes for ultrastaging.⁴ In colon cancer patients, both blue dyes and radiotracers have been used as SLN tracers in an in vivo and ex vivo setting.⁹ However, both have disadvantages. The use of gamma ray emitting radiotracers requires involvement of a nuclear medicine physician, and localization requires a handheld gammaprobe, which does not permit real-time visualization. Also, preoperative access to the injection site is often required, which in colon cancer patients requires endoscopic injection. Blue dyes cannot be easily seen through fatty tissue and can easily diffuse through the true SLN to second- to third-tier nodes because of their small size.

Recently, optical imaging using near-infrared (NIR) fluorescence has been introduced for real-time visualization of structures during surgery. Advantages of NIR fluorescent (700-900 nm) light include high tissue penetration (several millimeters) and low autofluorescence of tissue in this wavelength region, thereby providing high contrast. To date, indocyanine green is the only clinically available NIR fluorescent tracer and has been used with success for the SLN procedure in several types of cancer including gastrointestinal cancer.¹⁰⁻¹⁸ However, because of relative low fluorescence

brightness (quantum yield) and poor SLN retention, indocyanine green is not an ideal SLN tracer.¹⁹ To improve retention of the NIR tracer in the SLN, conjugation of an NIR fluorescent dye, such as IRDye 800CW, to a larger molecule, such as human serum albumin (HSA; complex: HSA800) is recommended.¹⁹ However, because HSA800 is not yet clinically approved, it can only be used for ex vivo SLN mapping. Previously, our group used HSA800 successfully ex vivo in a feasibility study with patients with colon cancer, and we were able to identify SLNs in all patients.²⁰ However, in our earlier study we used no blue dye staining because blue dyes might interfere with NIR fluorescence imaging by absorbing the fluorescent light and thereby decreasing the identification rate. At present, blue dye staining is frequently used for the ex vivo SLN procedure, and blue dye staining also provides visual information, which could make it easier to identify and resect SLNs. The aims of this study were to assess the feasibility of the combined use of NIR fluorescence using HSA800 and blue dye staining, and to assess the added value of NIR fluorescence to blue dye staining for SLN mapping in colon cancer patients.

MATERIALS AND METHODS

Preparation of lymphatic tracers

The preparation of HSA800 (IRDye 800CW conjugated to HSA) has been described in detail previously.¹⁹ Briefly, after conjugation of CW800-NHS to albumin, we purified HSA800 using a 7K Zeba Spin Desalting Column (Thermo Scientific, Rockford, IL). The ratio of fluorophore (IRDye 800CW; Li-Cor, Lincoln, NE) to albumin (HSA) was 1.5:1, estimated using the extinction coefficients of HSA ($\epsilon_{280\text{nm}} = 32,900 \text{ mol/L}\cdot\text{cm}^{-1}$) and CW800 ($\epsilon_{778\text{nm}} = 240,000 \text{ mol/L}\cdot\text{cm}^{-1}$) in phosphate buffered saline, with a stock concentration of approximately 600 $\mu\text{mol/L}$. Peak absorbance and emission of HSA800 were 778 and 795 nm, respectively. To obtain a solution of 50 $\mu\text{mol/L}$ HSA800, we diluted 50 nmol HSA800 in 1 mL patent blue (Bleu Patente V; Guerbet, Brussels, Belgium) before injection.

Intraoperative NIR imaging system (Mini-FLARE)

We performed clinical SLN mapping using the Mini-FLARE imaging system, which has been described in detail elsewhere.^{21,22} Briefly, the system consists of two wavelength isolated light sources: a white light source, generating 26,600 lx of 400- to 650-nm light and an NIR light source, generating 7.7 mW/cm² of 760-nm light. Color video and NIR fluorescence images are simultaneously acquired and displayed in real time using custom optics and software that separate the color video and NIR fluorescence images. A pseudo-colored (lime green) merged image of the color video and NIR fluorescence

images is also displayed. The imaging head is attached to a flexible gooseneck arm, which permits positioning of the imaging head virtually anywhere over the surgical field and at extreme angles.

Table 1. Patient and tumour characteristics

Characteristic	N	%
Gender		
Male	12	55
Female	10	45
Age (median, range)	69 (41 – 88)	
Body mass index (median, range)	25 (20 - 40)	
Tumour size (cm; median, range)	3.7 (0.9 – 9.0)	
Tumour location		
Cecum	3	13
Ascending colon	9	41
Transverse colon	1	5
Sigmoid colon	9	41
Tumour differentiation		
Well	1	5
Moderately	17	77
Poorly	4	18
Tumour invasion		
T1	2	9
T2	7	32
T3	10	46
T4	3	13

Clinical trial

We enrolled 22 consecutive patients undergoing surgery with curative intent for colon cancer. Patients with known metastatic disease were excluded. The Leiden University Medical Center Medical Ethics Committee approved this study, which we performed in accordance with the Declaration of Helsinki. All known patients underwent a standard oncological resection including a segmental colonic resection and lymphadenectomy. Tumours were endoscopically marked before surgery when indicated. Directly after resection, the resection specimen was freshly delivered to the Department of Pathology, where the specimen was opened antimesenterically by the pathologist. Subsequently, 1 mL of 50 µmol/L HSA800 diluted in patent blue was injected submucosally circumferentially with a 5-mm margin around the tumour. The injection site was massaged for 5 min, which has been proven sufficient to secure drainage to the SLN in both an in vivo and ex vivo setting.²⁰ After 5 min, the specimen was inspected using the Mini-FLARE camera system and by visual inspection. We allocated all fluorescent hotspots as SLN and noted whether these nodes were stained blue. The SLNs were separately fixated in 2% buffered formalin for 24 h. After

fixation, we harvested all remaining lymph nodes from the specimen and paraffin-embedded all lymph nodes (sentinel and nonsentinel); 4-mm sections were stained with hematoxylin-eosin and subsequently analyzed microscopically for the presence of tumour cells.

Table 2. Results of sentinel lymph node procedure

Characteristic	N	%
Detection rate	21	95
SLNs detected per patient		
0	1	5
1	3	13
2	2	9
3	6	28
4	3	13
5	4	18
6	1	5
7	2	9
>7	0	0
Method of detection		
Fluorescence and blue staining	70	91
Fluorescence only	7	9
Number of total dissected nodes (median, range)	21 (11 – 38)	
Histology		
Negative	17	77
Positive	5	23
False negatives	1	20

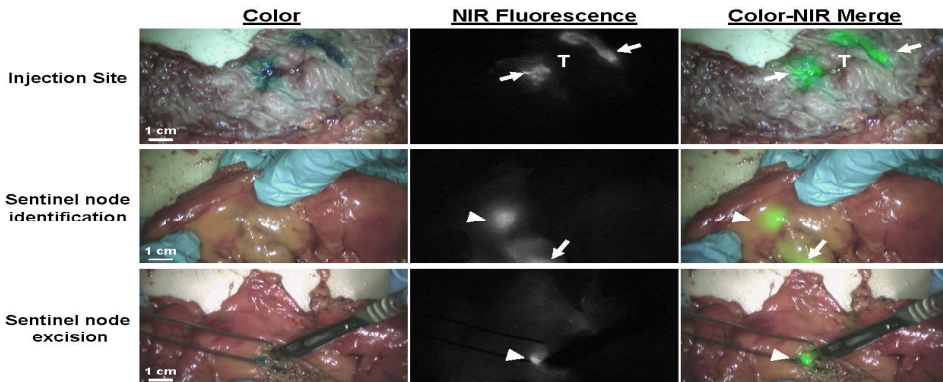


Fig. Sentinel lymph node mapping using NIR fluorescence and blue dye in colon cancer. (Upper) Peritumoural submucosal injection (arrows) of 1.0 mL of 50 $\mu\text{mol/L}$ HSA800 and patent blue. (Middle) Identification of the SLN (arrowheads) by NIR fluorescence located in the mesenteric fat near the injection site (arrows). The NIR fluorescence signal is scattered (i.e., blurred) by the mesenteric fat covering the node. (Lower) After incision of the mesentery by the pathologist, a clear blue and fluorescent SLN (arrowhead) can be identified. Camera exposure times were 25 ms (upper panel), 100 ms (middle panel), and 67 ms (lower panel). Scale bars = 1 cm.

RESULTS

We enrolled 22 consecutive patients undergoing surgery for colon cancer. Table 1 lists patient and tumour characteristics. Of these 22 patients, the median age was 69 y (range, 41-88 y); median body mass index was 25 kg/m² (range, 20-40 kg/m²). A total of 12 patients were male. Tumour invasion ranged from stage T1 to T4. The median tumour size was 3.7 cm (range, 0.9-9 cm). Four patients had a poorly differentiated tumour, 17 patients had a moderately differentiated tumour, and one had a well-differentiated tumour. Twelve patients received preoperative endoscopic tattooing of the tumour.

After administration of the lymphatic tracer cocktail, at least one SLN was identified in 21 of 22 patients (95%) (Table 2). Sentinel lymph nodes that were located deeper in the mesenteric fat could easily be located by NIR fluorescence but not with the blue dye. After the pathologist subsequently incised the mesentery, in most cases, blue staining of the lymph node was also detected, which provided the pathologist with direct visual support (Fig.). On average, 3.5±1.9 SLNs/patient were identified. Overall, a total of 77 SLNs were identified, of which 77 (100%) were fluorescent and 70 (91%) were blue (Pearson's correlation coefficient, 0.94). In five patients, fluorescent SLNs were identified (average 1.4±0.5 nodes/patient) that were not stained blue. A total (sentinel and nonsentinel) of 20.5±8.1 nodes were harvested on average from each specimen. Standard histologic analysis showed that five of 22 patients had lymph node metastases. In all but one of these five patients, tumour cells were present in at least one of the SLNs. The false-negative (neither fluorescent nor blue) lymph node was almost completely filled with tumour cells and was easily detected by the pathologist.

DISCUSSION

Nodal status in colon cancer is the most important prognostic factor, which makes it crucial in deciding whether a patient should be considered for adjuvant treatment. Therefore, the main purpose of the SLN procedure in colon cancer patients is the selection of lymph nodes to be assessed by ultrastaging techniques. The current study shows the successful use of NIR fluorescence imaging in combination with blue dye during ex vivo SLN mapping in colon cancer. The NIR fluorescent tracer HSA800 permitted detection of the SLN located deeper into the mesenteric fat. The detection rate of 95% in this study is in concordance with previously reported detection rates in SLN mapping using radiotracers, blue dyes, or a combination of both.⁹

This is the first study in which an NIR fluorescent tracer is used in combination with conventional blue dye staining, which is most commonly used as lymphatic tracer, in the ex vivo SLN procedure. Because NIR fluorescence imaging is capable of penetrating millimeters into tissue, it allowed identification of small amounts of the lymphatic tracer deeper into the mesenteric fatty tissue. Moreover, owing to the high spatial resolution of NIR fluorescence, we observed no interference between the fluorescent signal of the injection site and SLNs. We premixed HSA800 with patent blue, and we therefore anticipated staining the same nodes NIR fluorescent and blue. Indeed, there was a high correlation between identification using fluorescence and identification using blue dye staining. However, several fluorescent nodes (9%) did not stain blue. Possible explanations could be the high sensitivity of NIR fluorescence imaging, which allows detection of low concentrations of the tracer, and dilution of the blue dye to concentrations not visible with the human eye.²³⁻²⁵ Because there appears to be little interference of blue dye with NIR fluorescence, in most cases blue staining could be used as complementary direct visual support to assist the pathologist in resecting the SLNs.

Preoperative tattooing of the tumour, which is mostly used for tumour localization during laparoscopic surgery, can result in staining of lymph nodes and has been suggested for SLN mapping.²⁶⁻²⁹ In the current study, multiple patients received preoperative endoscopic tattooing of the tumour, which resulted in multiple blue colored nodes before the SLN procedure. Because it appeared to be difficult to differentiate between staining by endoscopic tattooing and patent blue staining, the blue dye staining could be less reliable for detecting the first echelon nodes in the current study. Therefore, in patients who received preoperative endoscopic tattooing, the use of NIR fluorescence imaging could overcome these problems.

One false-negative case occurred out of five patients with nodal metastases, which is in concordance with other, earlier studies.^{9,30} In the current study, we identified the SLNs approximately 15 min after injection of HSA800, which adds extra time to the standard workup. In addition, identification of the SLN can be difficult, because not all lymph nodes can be exposed. Identification of SLNs after fixation would allow the pathologist to identify the SLN during routine practice. When SLN detection is performed several hours after injection, optimal retention of the lymphatic tracer in the SLN tracer is essential. However, HSA800 still migrates to higher-echelon lymph nodes, albeit slower than small molecules such as patent blue.¹⁹ When improved retention in the SLN is wanted, nanocolloidal albumin combined with fluorescence can be used, which provides optimal retention in the SLN because of its favorable large hydrodynamic diameter and charge.^{19,31-33} Moreover, rather than being only potentially useful for pathologic staging, in vivo SLN mapping has been suggested for patient-tailored extent of surgery.^{11,34,35} Clinical approval of HSA800 would also allow in vivo NIR fluorescence SLN mapping using this tracer.

This study demonstrated the successful use of a combination of an NIR fluorescence tracer and a conventional blue dye for the ex vivo SLN detection in colon cancer, which can be used as a tool to select the nodes for ultrastaging techniques to identify micrometastases and improve nodal staging. NIR fluorescence was of added value compared with blue dye staining, because NIR fluorescence allowed detection of additional SLNs and easy detection of SLNs located deeper into the mesenteric fat. Moreover, NIR fluorescence cannot be confused with blue nodal staining resulting from preoperative tattooing of the tumour.

ACKNOWLEDGMENTS

The authors thank Lindsey Gendall for editing. This work was supported in part by NIH Grants R01-CA-115296 and R21- CA-130297 and Dutch Cancer Society Grant UL2010-4732. This research was performed within the framework of the Center for Translational Molecular Medicine, project DeCoDe (Grant 03O-101). Joost van der Vorst is an MD-medical research trainee funded by The Netherlands Organisation for Health Research and Development (Grant 92003593).

REFERENCES

1. Iddings D, Ahmad A, Elashoff D, et al. The prognostic effect of micrometastases in previously staged lymph node negative (N0) colorectal carcinoma: a meta-analysis. *Ann Surg Oncol* 2006;13:1386.
2. Nicastrì DG, Doucette JT, Godfrey TE, et al. Is occult lymph node disease in colorectal cancer patients clinically significant? A review of the relevant literature. *J Mol Diagn* 2007;9:563.
3. Govindarajan A, Baxter NN. Lymph node evaluation in early-stage colon cancer. *Clin Colorectal Cancer* 2008;7:240.
4. Sirop S, Kanaan M, Korant A, et al. Detection and prognostic impact of micrometastasis in colorectal cancer. *J Surg Oncol* 2011;103:534.
5. Doekhie FS, Mesker WE, Kuppen PJ, et al. Detailed examination of lymph nodes improves prognostication in colorectal cancer. *Int J Cancer* 2010;126:2644.
6. Lips DJ, Koebrugge B, Liefers GJ, et al. The influence of micrometastases on prognosis and survival in stage I-II colon cancer patients: the Enroute plus sign in circle study. *BMC Surg* 2011;11:11.
7. Cutait R, Alves VA, Lopes LC, et al. Restaging of colorectal cancer based on the identification of lymph node micrometastases through immunoperoxidase staining of CEA and cytokeratins. *Dis Colon Rectum* 1991;34:917.
8. Liefers GJ, Cleton-Jansen AM, van de Velde CJ, et al. Micrometastases and survival in stage II colorectal cancer. *N Engl J Med* 1998;339:223.
9. van der Pas MH, Meijer S, Hoekstra OS, et al. Sentinel-lymphnode procedure in colon and rectal cancer: a systematic review and meta-analysis. *Lancet Oncol* 2011;12:540.
10. Ankersmit M, van der Pas MH, van Dam DA, et al. Near infrared fluorescence lymphatic laparoscopy of the colon and mesocolon. *Colorectal Dis* 2011;13(Suppl 7):70.
11. Cahill RA, Anderson M, Wang LM, et al. Near-infrared (NIR) laparoscopy for intraoperative lymphatic road-mapping and sentinel node identification during definitive surgical resection of early-stage colorectal neoplasia. *Surg Endosc* 2012;26:197.
12. Hirche C, Mohr Z, Kneif S, et al. Ultrastaging of colon cancer by sentinel node biopsy using fluorescence navigation with indocyanine green. *Int J Colorectal Dis* 2012;27:319.
13. Schaafsma BE, Mieog JS, Hutteman M, et al. The clinical use of indocyanine green as a near-infrared fluorescent contrast agent for image-guided oncologic surgery. *J Surg Oncol* 2011;104:323.
14. Crane LM, Themelis G, Arts HJ, et al. Intraoperative near-infrared fluorescence imaging for sentinel lymph node detection in vulvar cancer: first clinical results. *Gynecol Oncol* 2011;120:291.
15. van der Vorst JR, Hutteman M, Gaarenstroom KN, et al. Optimization of near-infrared fluorescent sentinel lymph node mapping in cervical cancer patients. *Int J Gynecol Cancer* 2011;21:1472.
16. Mieog JS, Vahrmeijer AL, Hutteman M, et al. Novel intraoperative near-infrared fluorescence camera system for optical image-guided cancer surgery. *Mol Imaging* 2010;9:223.
17. Fujiwara M, Mizukami T, Suzuki A, et al. Sentinel lymph node detection in skin cancer patients using real-time fluorescence navigation with indocyanine green: preliminary experience. *J Plast Reconstr Aesthet Surg* 2009;62:e373.
18. Kusano M, Tajima Y, Yamazaki K, et al. Sentinel node mapping guided by indocyanine green fluorescence imaging: a new method for sentinel node navigation surgery in gastrointestinal cancer. *Dig Surg* 2008; 25:103.
19. Ohnishi S, Lomnes SJ, Laurence RG, et al. Organic alternatives to quantum dots for intraoperative near-infrared fluorescent sentinel lymph node mapping. *Mol Imaging* 2005;4:172.
20. Hutteman M, Choi HS, Mieog JS, et al. Clinical translation of ex vivo sentinel lymph node mapping for colorectal cancer using invisible near-infrared fluorescence light. *Ann Surg Oncol* 2011;18:1006.
21. Mieog JS, Troyan SL, Hutteman M, et al. Towards optimization of imaging system and lymphatic tracer for near-infrared fluorescent sentinel lymph node mapping in breast cancer. *Ann Surg Oncol* 2011;18:2483.

22. Troyan SL, Kianzad V, Gibbs-Strauss SL, et al. The FLARE intraoperative near-infrared fluorescence imaging system: a first-in-human clinical trial in breast cancer sentinel lymph node mapping. *Ann Surg Oncol* 2009;16:2943.
23. Murawa D, Hirche C, Dresel S, et al. Sentinel lymph node biopsy in breast cancer guided by indocyanine green fluorescence. *Br J Surg* 2009;96:1289.
24. Frangioni JV. In vivo near-infrared fluorescence imaging. *Curr Opin Chem Biol* 2003;7:626.
25. Fujisawa Y, Nakamura Y, Kawachi Y, et al. Indocyanine green fluorescence-navigated sentinel node biopsy showed higher sensitivity than the radioisotope or blue dye method, which may help to reduce false-negative cases in skin cancer. *J Surg Oncol* 2012;16:41.
26. Dawson K, Wiebusch A, Thirlby RC. Preoperative tattooing and improved lymph node retrieval rates from colectomy specimens in patients with colorectal cancers. *Arch Surg* 2010;145:826.
27. Viehl CT, Guller U, Hamel CT, et al. Carbon dye staining of sentinel lymph nodes facilitates microstaging of colon cancer patients. *World J Surg* 2006;30:453.
28. Spatz H, Probst A, Oruzio D, et al. Sentinel lymph node mapping as a side-effect of colonoscopic tattooing. *Surg Endosc* 2010;24:589.
29. Cahill RA, Lindsey I, Cunningham C. Sentinel node mapping by colonic tattooing. *Surg Endosc* 2010;24:2365.
30. Cahill RA, Leroy J, Marescaux J. Could lymphatic mapping and sentinel node biopsy provide oncological providence for local resectional techniques for colon cancer? A review of the literature. *BMC Surg* 2008;8:17.
31. Heuveling DA, Visser GW, de GM, et al. Nanocolloidal albumin-IRDye 800CW: a near-infrared fluorescent tracer with optimal retention in the sentinel lymph node. *Eur J Nucl Med Mol Imaging* 2012;39:1161.
32. van der Poel HG, Buckle T, Brouwer OR, et al. Intraoperative laparoscopic fluorescence guidance to the sentinel lymph node in prostate cancer patients: clinical proof of concept of an integrated functional imaging approach using a multimodal tracer. *Eur Urol* 2011;60:826.
33. Brouwer OR, Klop WM, Buckle T, et al. Feasibility of sentinel node biopsy in head and neck melanoma using a hybrid radioactive and fluorescent tracer. *Ann Surg Oncol* 2012;19:1988.
34. Brigic A, Fraser C, Sibbons P, et al. Individualization of surgical management for early-stage colonic cancer. *Colorectal Dis* 2011;13(Suppl 7):59.
35. Cahill RA, Asakuma M, Trunzo J, et al. Intraoperative virtual biopsy by fibered optical coherence tomography (OCT) at natural orifice transluminal endoscopic surgery (NOTES). *J Gastrointest Surg* 2010;14:732.

