



Universiteit  
Leiden  
The Netherlands

## **Imaging techniques in aortic valve and root surgery**

Regeer, M.V.

### **Citation**

Regeer, M. V. (2017, April 18). *Imaging techniques in aortic valve and root surgery*. Retrieved from <https://hdl.handle.net/1887/47977>

Version: Not Applicable (or Unknown)

License: [Licence agreement concerning inclusion of doctoral thesis in the Institutional Repository of the University of Leiden](#)

Downloaded from: <https://hdl.handle.net/1887/47977>

**Note:** To cite this publication please use the final published version (if applicable).

Cover Page



Universiteit Leiden



The handle <http://hdl.handle.net/1887/47977> holds various files of this Leiden University dissertation.

**Author:** Regeer, M.V.

**Title:** Imaging techniques in aortic valve and root surgery

**Issue Date:** 2017-04-18

## Chapter 3:

Mitral valve geometry changes  
in patients with aortic regurgitation

M.V. Regeer, I. Al Amri, M.I.M. Versteegh,  
J.J. Bax, N. Ajmone Marsan, V. Delgado  
*J Am Soc Echocardiogr. 2015;28:455-462*

## Abstract

**Background:** Changes in mitral valve geometry in patients with significant aortic regurgitation (AR) have not been evaluated. The aim of the present study was to assess the prevalence of significant secondary mitral regurgitation (MR; grade  $\geq 2$ ) and the geometrical characteristics of the mitral valve in patients with moderate and severe AR (grade  $\geq 2$ ) undergoing aortic valve and root surgery.

**Methods:** One-hundred twenty patients (mean age,  $54 \pm 15$  years; 65% men) with AR grade  $\geq 2$  undergoing aortic valve and root surgery were retrospectively evaluated. The presence of MR grade  $\geq 2$  and geometry of the mitral valve were assessed on preoperative transthoracic echocardiography. Left ventricular (LV) dimensions and mitral valve geometry were compared between patients with MR grade  $\geq 2$  and patients without.

**Results:** MR grade  $\geq 2$  was present in 28 (23%) patients. Patients with MR grade  $\geq 2$  had higher European System for Cardiac Operative Risk Evaluation II scores and more often used  $\beta$ -blockers and diuretics than their counterparts. Patients with MR grade  $\geq 2$  had larger tenting areas (mean,  $1.59 \pm 0.79$  vs.  $1.25 \pm 0.41$  cm<sup>2</sup>;  $p=0.003$ ), larger inter-papillary muscle distances (mean,  $28.4 \pm 9.5$  vs.  $24.8 \pm 5.2$  mm;  $p=0.014$ ), larger left atria (mean,  $40.9 \pm 13.7$  vs.  $32.0 \pm 12.2$  ml/m<sup>2</sup>;  $p=0.002$ ) and lower LV ejection fractions (mean,  $47.3 \pm 12.2$  vs.  $54.3 \pm 9.3\%$ ;  $p=0.002$ ) as compared to patients with MR grade  $< 2$ . However, there were no differences in indexed LV volumes. On multivariate logistic regression analysis, LV ejection fraction (odds ratio: 0.94; 95% confidence interval: 0.89-0.99;  $p=0.018$ ) and indexed left atrial volume (odds ratio: 1.05; 95% confidence interval: 1.01-1.10;  $p=0.019$ ) remained independently associated with MR grade  $\geq 2$  after correcting for tenting area and inter-papillary muscle distance.

**Conclusion:** Among patients with AR grade  $\geq 2$  undergoing aortic valve and root surgery, the prevalence of MR grade  $\geq 2$  was 23%. Lower LV ejection fraction and larger left atrial volume were independently associated with MR grade  $\geq 2$ .

## Introduction

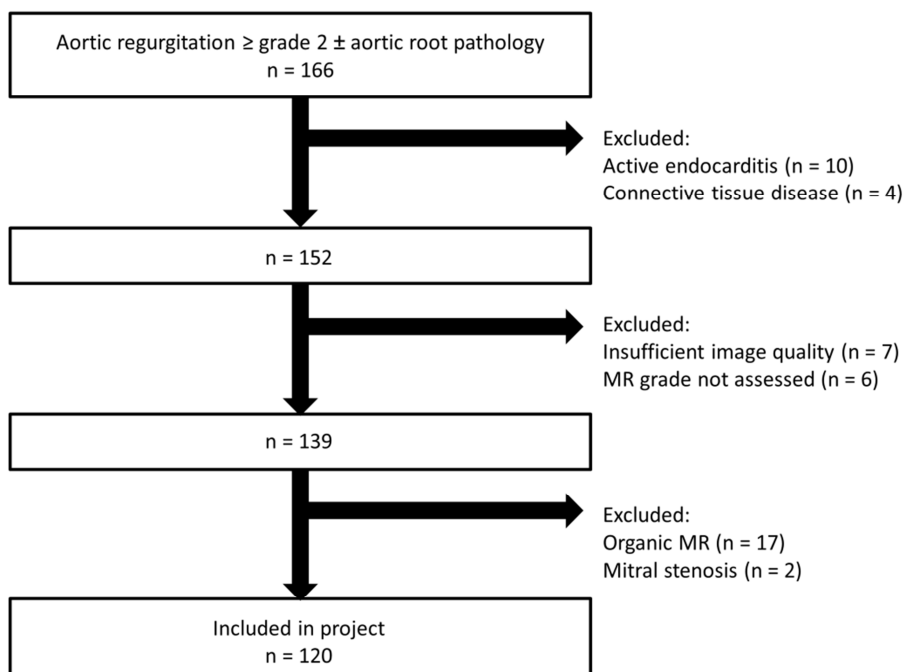
The prevalence of secondary mitral regurgitation (MR) in patients with significant aortic regurgitation (AR) ranges between 6 and 45%.<sup>1,2</sup> The left ventricular (LV) pressure and volume overload caused by significant AR leads to LV dilation, with subsequent changes in papillary muscle position and tethering of the mitral leaflets, which may cause coaptation failure and regurgitation. The prognostic implications of concomitant secondary MR in patients with significant AR are not benign and it has been shown that mitral valve surgery in addition to aortic valve surgery is associated with better prognosis.<sup>2</sup> However, it remains unclear why some patients with significant AR have concomitant significant secondary MR while other patients do not show MR.<sup>1</sup>

A pioneer study using three-dimensional transthoracic echocardiography suggested that patients with significant AR show significantly larger total mitral leaflet area compared with patients without AR, which may reflect mitral leaflet remodeling to prevent failure of mitral leaflet coaptation.<sup>1</sup> However, changes in mitral valve geometry, including the subvalvular apparatus in patients with significant AR, have not been evaluated. In addition, the effects of confounding factors such as concomitant ischemic heart disease on LV remodeling and development of secondary MR in this specific subpopulation have not been elucidated. Therefore, the aims of the present study were to investigate the prevalence of significant MR, evaluate changes in mitral valve geometry, and investigate the associates of MR in patients with significant AR.

## Methods

### *Patients*

Pre-operative two-dimensional echocardiograms from 166 patients with AR grade  $\geq 2$  referred for valve-sparing aortic root reconstruction to the Cardio-Thoracic Surgery department of the Leiden University Medical Center from 2001 to 2014 were evaluated. Patients with acute endocarditis, connective tissue disease, insufficient image quality, organic mitral regurgitation or mitral stenosis were excluded (Figure 1). Clinical characteristics were prospectively collected in the departmental cardiology information system (EPD-Vision; Leiden University Medical Center, Leiden, The Netherlands) and retrospectively analyzed. Mitral valve geometry, MR grade, AR grade, and LV volumes and function were analyzed. Mitral valve geometry was compared between patients with moderate or severe secondary MR and patients without. The institutional review board approved this retrospective analysis of clinically acquired data and waived the need for patient written informed consent.



**Figure 1. Flowchart of the patient inclusion.**

### *Two-dimensional transthoracic echocardiography*

Transthoracic echocardiography was performed preoperatively using commercially available ultrasound systems (System Five, Vivid 7, and Vivid E9, GE Vingmed Ultrasound AS, Horten, Norway) equipped with 3.5-MHz or M5S transducers. Parasternal, apical, subcostal, and suprasternal views were obtained at rest with patients in the left decubitus position. Two-dimensional and Doppler data were acquired according to current recommendations.<sup>3,4</sup> The echocardiographic data were digitally stored in cine-loop format and data were retrospectively analyzed using commercially available software (EchoPAC version 112.0.1, Vingmed Ultrasound AS, Horten, Norway).

AR grade was assessed using a multiparametric approach including the measurement of the jet width relative to the LV outflow tract (LVOT) width and the vena contracta in the parasternal and apical views. AR was graded as grade 2 (mild-moderate; jet width/LVOT width of 0.25-0.45 and/or vena contracta of 3.0-4.5 mm), grade 3 (moderate-severe; jet width/LVOT width of 0.46-0.64 and/or vena contracta of 4.6-5.9 mm) or grade 4 (severe; jet width/LVOT width  $\geq 0.65$  and/or vena contracta  $\geq 6.0$  mm).<sup>5</sup> The severity of secondary MR was quantitatively determined by proximal isovelocity surface area method or by measuring the vena contracta in the parasternal long-axis view, according to current recommendations.<sup>6</sup> MR was graded as absent when there was no regurgitant jet. Among patients with regurgitant jets,

proximal isovelocity surface area method could be performed in 45 patients. In the remaining 33 patients, vena contracta measurement in parasternal long axis view was used to classify MR. Secondary MR was defined as mild (regurgitant volume <15 ml or vena contracta of 0.1-2.9 mm), moderate (regurgitant volume of 15-29 ml or vena contracta 3-6.9 mm) or severe (regurgitant volume  $\geq$ 30 ml or vena contracta  $\geq$ 7 mm).

Mitral valve geometry was assessed in the parasternal long-axis view (Figure 2).

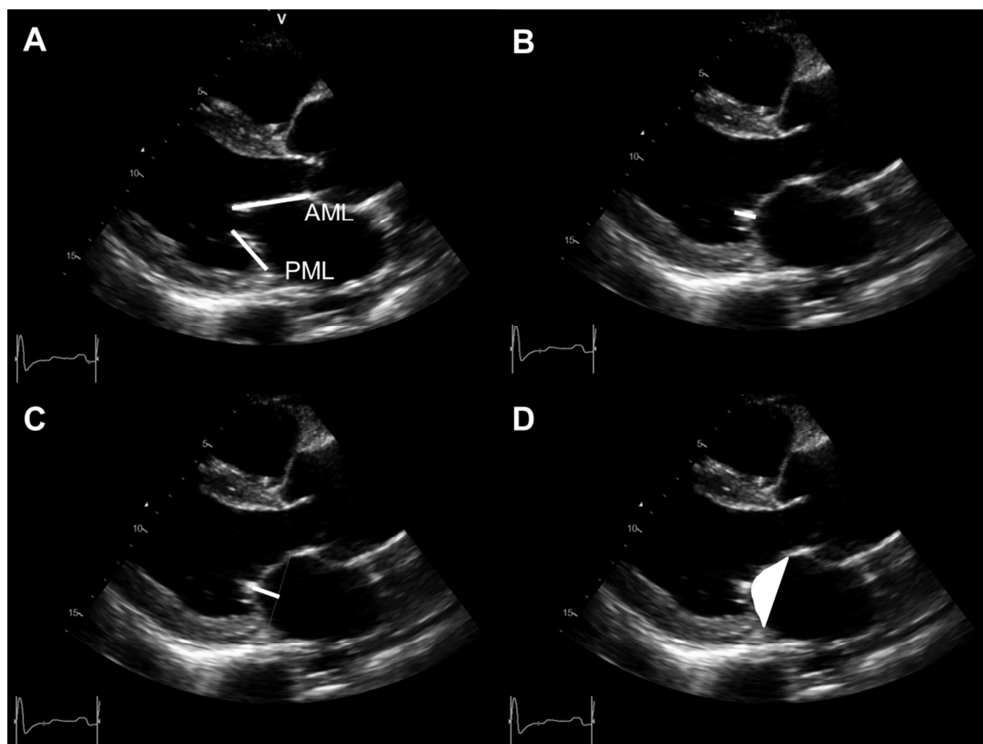
Retrospectively, the images were zoomed in on the mitral valve. The measurements were performed by two independent observers, and values were averaged. The length of coaptation between the anterior and posterior mitral leaflets (coaptation length), the distance between the annular plane and the coaptation point (coaptation height), and the area enclosed between the annular line and the mitral leaflets (tenting area) were measured in mid-systole. Anterior and posterior mitral leaflet length was measured in mid-diastole. The parasternal short-axis view was used to measure the end-diastolic inter-papillary muscle distance. The mitral annulus was measured at end-systole in the apical views. The anterior-posterior diameter and intercommissural diameter were obtained from the apical four- and two-chamber views, respectively.

Left atrial volume, LV end-diastolic volume and LV end-systolic volume were measured in the apical two- and four-chamber views and indexed to body surface area (LAVi, LVEDVi and LVESVi). Sphericity index was calculated by dividing the length by the width of the left ventricle in the apical four-chamber view, as previously described.<sup>6</sup> LV ejection fraction (LVEF) was calculated according to the Simpson's biplane method.<sup>3</sup>

### *Surgery*

After median sternotomy, cardiopulmonary bypass was set through cannulation of the distal ascending aorta or the subclavian or femoral artery (in patients with ascending aorta pathology). The aorta was incised at the level of the pulmonary artery and resected until the sinotubular junction.

Intraoperatively, the surgeon decided whether a valve-sparing aortic root reconstruction was feasible. In these patients, either the sinotubular junction was restored using a vascular graft or the native sinuses of Valsalva were resected, a graft was implanted using the reimplantation technique (modified David procedure), or the remodeling technique (Yacoub procedure) and the coronary buttons were reimplanted.<sup>7,8</sup> Otherwise, aortic valve and root replacement using the Medtronic Freestyle stentless bioprosthesis (Medtronic, Minneapolis, MN) was performed. In these patients, the coronary buttons were mobilized, and the aortic root and valve were completely excised. The bioprosthesis was then implanted, usually with a 120° clockwise rotation, with interrupted sutures at one plane at the level of the nadir of the sinus. Thereafter, the coronary buttons were reattached to the bioprosthesis.<sup>9</sup>



**Figure 2. Measurements of mitral valve geometry.**

During mid-diastole: mitral valve leaflet length (A) of the anterior mitral leaflet (AML) and the posterior mitral leaflet (PML). At mid-systole: coaptation length (B), coaptation height (C) and tenting area (D).

If secondary MR was present, concomitant mitral valve surgery was performed at the discretion of the surgeon. In all patients in whom concomitant mitral valve surgery was performed, a restrictive ring annuloplasty was used to repair the mitral valve. No mitral valve replacements were performed.

#### *Statistical analysis*

All data analyses were performed using SPSS version 20.0 (IBM, Armonk, NY). Continuous variables are reported as mean  $\pm$  standard deviation or medians and interquartile ranges, as appropriate. Categorical variables are reported as counts and percentages. Patients with no or mild MR (grade  $<2$ ) were compared with patients with moderate or severe MR (grade  $\geq 2$ ). Continuous and categorical variables were compared by the Student's t-test (or the Mann Whitney U test for variables non-normally distributed) and chi-square test, respectively. Mitral valve geometric changes were compared between patients with normal left ventricles (LVESVi  $<31$  ml/m<sup>2</sup>) and patients with dilated left ventricles (LVESVi  $\geq 31$  ml/m<sup>2</sup>). Multivariate logistic



regression analysis was performed to investigate the independent associates of significant (moderate or severe) secondary MR. All echocardiographic variables with p-values <0.05 on univariate logistic regression analysis were included in the multivariate model. The odds ratio and 95% confidence interval were calculated. All statistical tests were two-sided. A p-value <0.05 was considered statistically significant. Interobserver and intraobserver variability of mitral valve geometric measurements was evaluated using Bland-Altman analysis in 40 randomly selected patients. Furthermore the coefficients of variation were calculated for coaptation length, coaptation height and tenting area.

## Results

A total of 120 patients (mean age, 54±15 years; 65% men) were included in the present analysis. AR was grade 2 in 52 patients (43%), grade 3 in 43 patients (36%), and grade 4 in 25 patients (21%). Forty-two patients (35%) did not have MR. Mild, moderate and severe MR were observed in 50 (42%), 25 (21%) and 3 (2%) patients, respectively. The prevalence of significant secondary MR (moderate and severe) was 23%. Patients were divided into two groups according to the presence and severity of the secondary MR: patients without significant secondary MR (n=92) were compared with those with moderate or severe secondary MR (n=28). Table 1 shows the differences in baseline clinical characteristics between groups.

Patients were comparable regarding age, gender, and comorbidities. Patients with significant secondary MR had a higher frequency of prior myocardial infarction than patients without MR; however this difference was not statistically significant. In addition, the presence of cardiovascular risk factors and the need for coronary artery bypass grafting was not different between patients with and without MR. However,  $\beta$ -blockers and diuretics were more frequently used among patients with MR grade  $\geq 2$  as compared to their counterparts.

### *Surgical characteristics*

Patients with moderate or severe secondary MR had a higher European System for Cardiac Operative Risk Evaluation II scores (median, 3.6% [interquartile range: 2.5-7.8%] vs. median, 2.4% [interquartile range: 1.6-4.5%]; p=0.003) compared with their counterparts. Seventy-three patients (61%) underwent valve-sparing aortic root reconstruction. The remaining 47 patients (39%) were considered ineligible for repair during surgery and underwent aortic valve and root replacement using the Medtronic Freestyle stentless bioprosthesis. Concomitant coronary artery bypass grafting was performed in 25 patients (21%). Concomitant mitral valve surgery with restrictive ring mitral annuloplasty was performed in 13 patients (11%). Concomitant tricuspid valve surgery (annuloplasty) was performed in 10 patients (8%).

**Table 1. Baseline characteristics**

	Non-significant secondary MR (n=92)	Significant secondary MR (n=28)	p-value
Age (years)	53.3±15.2	57.7±13.7	0.174
Male	58 (63%)	20 (71%)	0.556
Smoking	25 (27%)	7 (25%)	0.989
Diabetes	3 (3%)	2 (7%)	0.719
Hypertension	45 (49%)	18 (64%)	0.226
Dyslipidaemia	20 (22%)	3 (11%)	0.252
NYHA functional class			1
I – II	70 (76%)	21 (75%)	
III – IV	22 (24%)	7 (25%)	
Creatinine clearance (ml/min)	103±37	85±29	0.023
Coronary artery disease	16 (17%)	6 (21%)	0.838
Previous myocardial infarction			0.435
Anterior	1 (1%)	1 (4%)	
Non-anterior	3 (3%)	2 (7%)	
ACE-inhibitor or Angiotensin Receptor Blocker	45 (49%)	19 (68%)	0.123
Beta-blocker	31 (34%)	18 (64%)	0.008
Calcium channel antagonist	17 (19%)	2 (7%)	0.253
Diuretics	25 (27%)	15 (54%)	0.018
Aortic regurgitation			0.312
Grade 2	39 (42%)	13 (46%)	
Grade 3	36 (39%)	7 (25%)	
Grade 4	17 (19%)	8 (29%)	
EuroSCORE II (%)	2.4 (1.6-4.5)	3.6 (2.5-7.8)	0.003
Aortic valve/root technique			0.048
repair	51 (55%)	22 (79%)	
replacement	41 (45%)	6 (21%)	
CABG	19 (21%)	6 (21%)	1
Mitral valve repair	2 (2%)	11 (39%)	<0.001
Tricuspid valve repair	1 (1%)	9 (32%)	<0.001

*Continuous data are presented as mean ± standard deviation or median (interquartile range). Categorical data are presented as number (percentage). ACE = Angiotensin converting enzyme, CABG = Coronary Artery Bypass Grafting, EuroSCORE: European System for Cardiac Operative Risk Evaluation, MR = Mitral Regurgitation, NYHA = New York Heart Association.*

#### *Echocardiographic measurements associated with preoperative secondary MR*

The preoperative echocardiographic data are presented in Table 2. LV volumes and mitral valve geometric measurements in the parasternal long-axis view were available in all 120 patients, whereas inter-papillary muscle distance and LAVi were available in 108 patients and 119 patients, respectively. Coaptation length, coaptation height and lengths of the anterior and posterior leaflets were comparable in both groups. Patients with moderate or severe secondary MR had larger tenting areas ( $1.59 \pm 0.79$  vs.  $1.25 \pm 0.41$  cm<sup>2</sup>;  $p=0.003$ ) and larger inter-papillary muscle distances ( $28.4 \pm 9.5$  vs.  $24.8 \pm 5.2$  mm;  $p=0.014$ ) compared with those without significant secondary MR. There was a tendency toward larger mitral annular

diameters among patients with MR grade  $\geq 2$ . LVEDVi was comparable between patients with and without secondary MR whereas LVESVi was slightly larger (nonsignificant) in patients with moderate or severe secondary MR. Consequently, the LVEF was significantly lower in patients with moderate or severe secondary MR ( $47.3 \pm 12.2$  vs.  $54.3 \pm 9.3\%$ ;  $p=0.002$ ).

**Table 2. Preoperative echocardiographic characteristics**

	<b>Non-significant secondary MR (n=92)</b>	<b>Significant secondary MR (n=28)</b>	<b>p-value</b>
Anterior leaflet length (mm)	24.6 $\pm$ 4.1	24.6 $\pm$ 4.1	0.970
Posterior leaflet length (mm)	18.3 $\pm$ 3.2	18.9 $\pm$ 3.6	0.383
Coaptation length (mm)	7.8 $\pm$ 1.7	7.3 $\pm$ 1.9	0.273
Coaptation height (mm)	8.0 $\pm$ 2.3	8.5 $\pm$ 2.6	0.287
Tenting area (cm <sup>2</sup> )	1.25 $\pm$ 0.41	1.59 $\pm$ 0.79	0.003
Interpapillary muscle distance (mm)	24.8 $\pm$ 5.2	28.4 $\pm$ 9.5	0.014
Mitral annulus AP diameter (mm)	31.0 $\pm$ 4.9	33.1 $\pm$ 6.0	0.068
Mitral annulus intercommissural diameter (mm)	31.4 $\pm$ 5.2	33.5 $\pm$ 5.6	0.068
LAVi (ml/m <sup>2</sup> )	32.0 $\pm$ 12.2	40.9 $\pm$ 13.7	0.002
LVEDVi (ml/m <sup>2</sup> )	77.4 $\pm$ 27.9	79.6 $\pm$ 28.9	0.715
LVESVi (ml/m <sup>2</sup> )	36.1 $\pm$ 17.5	42.8 $\pm$ 23.9	0.104
Sphericity index	1.59 $\pm$ 0.27	1.59 $\pm$ 0.25	0.949
LVEF (%)	54.3 $\pm$ 9.3	47.3 $\pm$ 12.2	0.002

*Data are presented as mean  $\pm$  standard deviation. AP = Anterior-Posterior, LAVi = Left Atrial Volume indexed for body surface area, LVEDVi = Left Ventricular End Diastolic Volume indexed for body surface area, LVEF = Left Ventricular Ejection Fraction, LVESVi = Left Ventricular End Systolic Volume indexed for body surface area, MR = Mitral Regurgitation.*

Subgroup analysis was performed to assess the effect of LV dilation on the mitral valve geometry. LVESVi  $\geq 31$  ml/m<sup>2</sup> was defined as abnormal according to current recommendations.<sup>3</sup> The left ventricle was dilated in 68 patients (57%), with a mean LVESVi of  $49.4 \pm 17.6$  ml. In the remaining 52 patients, the mean LVESVi was  $22.2 \pm 5.6$  ml. In the group of patients with dilated left ventricles, larger inter-papillary muscle distances ( $26.9 \pm 7.5$  vs.  $24.3 \pm 5.3$  mm;  $p=0.047$ ), larger mitral valve annuli (anteroposterior diameter,  $32.7 \pm 5.4$  vs.  $30.0 \pm 4.6$  mm;  $p=0.005$  and intercommissural diameter,  $33.6 \pm 4.8$  vs.  $29.7 \pm 5.2$  mm;  $p<0.001$ ) and larger left atria (LAVi:  $37.0 \pm 12.1$  vs.  $30.2 \pm 13.3$  ml/m<sup>2</sup>;  $p=0.004$ ) were observed. Furthermore, the sphericity index and LVEF were significantly lower in patients with dilated left ventricles ( $1.51 \pm 0.20$  vs.  $1.69 \pm 0.29$ ;  $p<0.001$  and  $48.5 \pm 10.0$  vs.  $58.1 \pm 8.5\%$ ;  $p<0.001$ , respectively). Mitral leaflet tethering was more pronounced in patients with dilated left ventricles as indicated by larger coaptation heights and larger tenting areas ( $9.0 \pm 2.4$  vs.  $6.9 \pm 1.8$  mm;  $p<0.001$  and  $1.51 \pm 0.60$  vs.  $1.10 \pm 0.34$  cm<sup>2</sup>;  $p<0.001$ , respectively). Probably as a compensatory mechanism, patients with a dilated left ventricles had significant larger mitral leaflets compared with those without

dilated left ventricles (anterior leaflet length, 25.9±4.2 vs. 23.0±3.4 mm;  $p < 0.001$  and posterior leaflet length, 19.4±3.0 vs. 17.2±3.3 mm;  $p < 0.001$ ). This resulted in slightly larger coaptation length (7.9±1.8 vs. 7.4±1.6 mm;  $p = 0.151$ ).

#### *Correlates of significant secondary MR in patients with significant AR*

Table 3 presents the results of the logistic regression analysis to assess correlates of significant secondary MR in patients with AR. Tenting area, inter-papillary muscle distance, LAVi, and LVEF were included as independent variables in the multivariate analysis. However, only LVEF (odds ratio, 0.94; 95% confidence interval: 0.89-0.99;  $p = 0.018$ ) and LAVi (odds ratio, 1.05; 95% confidence interval: 1.01-1.10;  $p = 0.019$ ) remained independently associated with MR grade  $\geq 2$  after adjusting for the other echocardiographic parameters in the model.

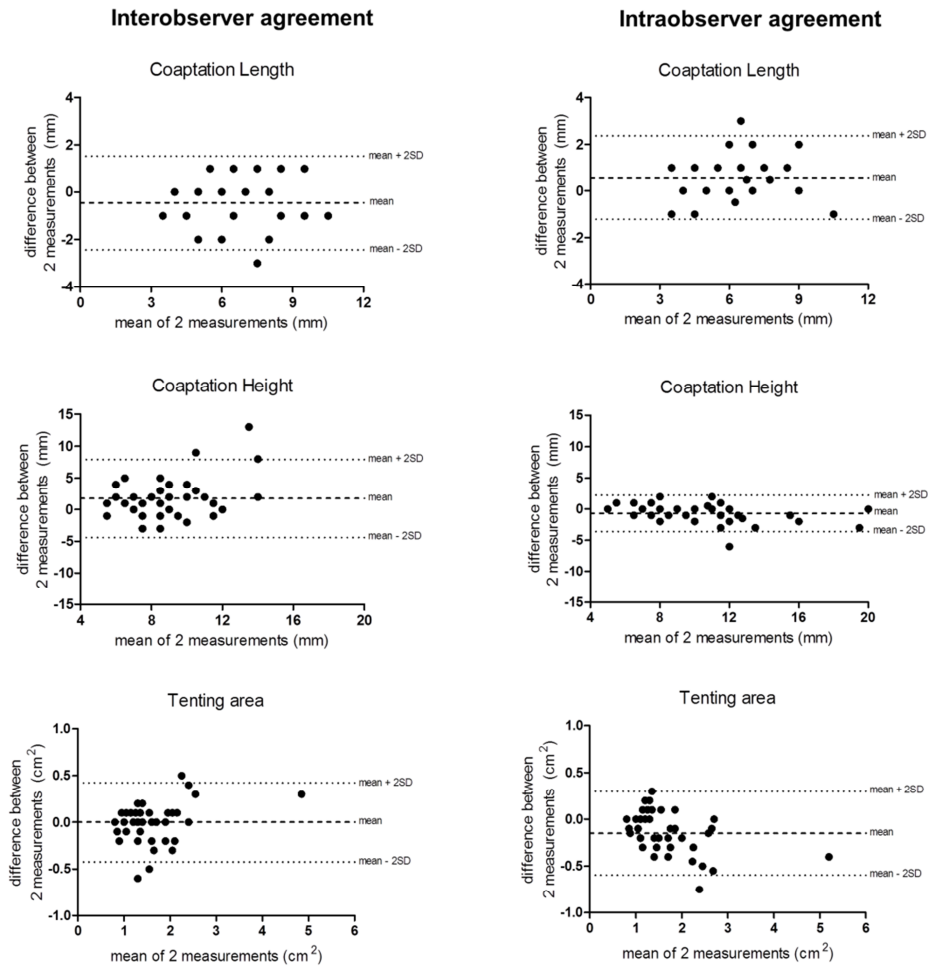
**Table 3. Correlates of significant MR in patients with significant AR**

	Univariate analysis			Multivariate analysis		
	OR	95% CI	p-value	OR	95% CI	p-value
Anterior leaflet length (mm)	1.00	0.90-1.11	0.969			
Posterior leaflet length (mm)	1.06	0.93-1.20	0.380			
Coaptation length (mm)	0.87	0.68-1.12	0.272			
Coaptation height (mm)	1.10	0.92-1.31	0.286			
Tenting area (cm <sup>2</sup> )	3.26	1.30-8.17	0.012	1.30	0.43-3.98	0.641
Interpapillary muscle distance (mm)	1.08	1.01-1.17	0.028	1.05	0.97-1.15	0.230
Mitral annulus AP diameter (mm)	1.08	0.99-1.17	0.072			
Mitral annulus inter-commissural diameter (mm)	1.08	0.99-1.18	0.071			
LAVi (ml/m <sup>2</sup> )	1.05	1.02-1.09	0.003	1.05	1.01-1.10	0.019
LVEDVi (ml/m <sup>2</sup> )	1.00	0.99-1.02	0.712			
LVESVi (ml/m <sup>2</sup> )	1.02	1.00-1.04	0.111			
Sphericity index	0.95	0.19-4.86	0.948			
LVEF (%)	0.94	0.90-0.98	0.003	0.94	0.89-0.99	0.018

*Data are presented from univariate and multivariate logistic regression analysis. AP = Anterior-Posterior, CI = Confidence Interval, LAVi = Left Atrial Volume indexed for body surface area, LVEDVi = Left Ventricular End Diastolic Volume indexed for body surface area, LVEF = Left Ventricular Ejection Fraction, LVESVi = Left Ventricular End Systolic Volume indexed for body surface area, OR = Odds Ratio.*

#### *Interobserver and intraobserver variability*

Reproducibility of the mitral valve geometric measurements was assessed in 40 randomly selected patients. Figure 3 shows the Bland Altman analysis which indicated fair interobserver and intraobserver agreement for the measurement of the coaptation length, coaptation height, and tenting area. The interobserver and intraobserver coefficients of variation were 11.3% and 11.9% for coaptation length, 28.0% and 11.2% for coaptation height and 9.4% and 11.4% for tenting area, respectively.



**Figure 3. Interobserver and intraobserver agreement.**

Bland Altman plots for interobserver and intraobserver agreement of the measurement of the coaptation length, coaptation height and tenting area

## Discussion

The present evaluation shows that in selected patients with AR undergoing aortic valve and aortic root surgery, the presence of significant secondary MR was frequent (23%). Lower LVEF and larger LAVi were independently associated with significant secondary MR.

### *Prevalence of significant secondary MR in patients with significant AR*

The previously reported prevalence of significant MR in patients with significant AR differs significantly across the studies (from 6% to 45%).<sup>1,2,10</sup> These differences are probably due to different methodologies to grade MR and different selection of patients. Although some

studies included less load-dependent measures to grade MR, such as vena contracta diameter,<sup>1,2</sup> in other studies, MR was graded on the basis of regurgitant jet area.<sup>10</sup> In terms of patients characteristics, Beaudoin et al.<sup>1</sup> performed a retrospective analysis of an institutional echocardiographic database and included all patients with moderate or severe AR without LV systolic dysfunction (LVEF>40%), associated degenerative mitral valve disease, or connective tissue pathologies (Marfan syndrome), leading to a prevalence of concomitant significant MR of 5.6%. In contrast, Pai and Varadarajan<sup>2</sup> performed a retrospective analysis of patients with severe AR with less strict inclusion and exclusion criteria and reported a prevalence of significant MR of 45%. The present study included a selected cohort of patients undergoing aortic valve and root surgery and further evaluated the differences in mitral valve geometry between patients with concomitant significant secondary MR and patients without. The prevalence of significant MR was 23%. The inclusion of patients undergoing surgical aortic valve replacement may lead to an increased prevalence of significant MR because the presence of combined valvular heart disease prompts the treating physician to refer the patient for surgical repair or replacement. In contrast, the series described by Beaudoin et al. a larger population of patients with moderate or severe AR independently of therapeutic management, which may explain the lower prevalence of concomitant significant MR. The disparate prevalence rates of the present study and the study by Pai and Varadarajan may be attributed to the different methodologies used to grade MR: whereas we used the proximal isovelocity surface area method and vena contracta width to grade MR, Pai and Varadarajan used a more load-dependent measure of MR (regurgitant jet size) which may overestimate the grade of MR.

#### *Mechanisms underlying significant secondary MR in patients with significant AR*

In significant AR, LV volume and pressure overload results in an increase in LV dimensions to maintain LVEF. If compensatory LV remodeling fails, LV function deteriorates.<sup>11</sup> Reduced systolic LV function leads to a decrease in closing forces of the mitral valve and MR.<sup>12</sup> Furthermore, LV dilation results in tethering of the mitral leaflets.<sup>13</sup> The imbalance between decreased closing forces and increased tethering forces may lead to secondary MR.<sup>14</sup> The present evaluation confirmed that in LV dilation due to AR, there is a reduction in LV systolic function and more mitral leaflet tethering. Lower LVEF was independently associated with significant MR in patients with AR indicating that the main mechanism of MR in these patients is the reduction in closing forces.

Annular dilation is another contributing factor in developing secondary MR in patients with significant AR.<sup>14</sup> However, MR secondary to isolated annular dilation remains controversial, and a previous surgical study did not show an association between secondary MR and the annular diameter.<sup>15</sup> Also, in our patient population, although annular diameters increased in

patients with dilated left ventricles, there was no significant difference in annular diameters between patients with and without significant secondary MR.

Lastly, it has been shown in both necropsy and echocardiography studies that in patients with AR, compensatory mitral valve enlargement occurs and could prevent MR.<sup>1,16</sup> When this compensatory mechanism fails, MR may appear worsening the LV remodeling process and causing more severe MR. In our cohort of patients with AR and dilated left ventricles, the mitral leaflets were longer, probably in order to increase the coaptation length in an attempt to compensate the leaflet tethering. However, there were no significant differences in mitral leaflet length between patients with and without significant secondary MR.

### *Clinical implications*

The present study shows that secondary MR in patients with AR results mainly from an imbalance in closing forces and tethering forces. Aortic valve surgery in these patients resolves the pressure and volume overload in the left ventricle, which leads to LV reverse remodeling.<sup>17</sup> In theory, this may result in a decrease in tethering of the mitral valve and subsequently a decrease in MR grade. It was recently shown that secondary MR improves after aortic valve surgery for AR in the majority of patients.<sup>10</sup> However, it remains unclear whether this improvement is related to restoration of normal mitral valve geometry postoperatively. Further research is needed to elucidate the mechanisms of decrease in MR grade after aortic valve surgery to determine when additional mitral valve repair is indicated in this specific patient population. Prospective randomized trials comparing aortic valve surgery with and without additional mitral valve repair would provide the evidence to this unmet clinical need.

### *Limitations*

The present study was limited by its retrospective nature. The duration of significant AR before surgery was not recorded. This may have resulted in a more dilated left ventricle and therefore have an effect on the MR grade. Data were acquired over a long period of time and the images were not always zoomed on the mitral valve, which may have hampered the accuracy of the mitral valve geometric measurements. Patients were followed up at the discretion of the treating cardiologist. Changes in MR after aortic valve surgery were not evaluated, because systematic echocardiographic follow-up was not available in all patients. Furthermore, the cohort consisted of patients referred for valve sparing aortic root replacement. The underlying pathology of AR was thus aortic root dilation and/or cusp prolapse, because valve sparing surgery is often feasible in these AR mechanisms. There were no patients with endocarditis or cusp restriction so results cannot be extrapolated to those patients. Also, the present results may not be applicable in a nonsurgical AR cohort. Evaluation of mitral regurgitant volume and fraction using proximal isovelocity surface area method was

feasible in 58% of patients with a regurgitant jet. In the remaining patients, vena contracta was used to grade MR. Measurements of the mitral valve geometry using three-dimensional echocardiography may have been more accurate; however three-dimensional echocardiography was not available in this cohort.

## Conclusion

Significant secondary MR was present in 23% of patients with significant AR undergoing aortic valve and aortic root surgery. Multivariate logistic regression analysis identified lower LVEF and larger LAVi as independent associates of significant MR.

## References

1. Beaudoin J, Handschumacher MD, Zeng X, Hung J, Morris EL, Levine RA, Schwammenthal E. Mitral valve enlargement in chronic aortic regurgitation as a compensatory mechanism to prevent functional mitral regurgitation in the dilated left ventricle. *J Am Coll Cardiol* 2013;61:1809-1816.
2. Pai RG, Varadarajan P. Prognostic implications of mitral regurgitation in patients with severe aortic regurgitation. *Circulation* 2010;122:S43-S47.
3. Lang RM, Bierig M, Devereux RB, Flachskampf FA, Foster E, Pellikka PA, Picard MH, Roman MJ, Seward J, Shanewise JS, Solomon SD, Spencer KT, Sutton MS, Stewart WJ; Chamber Quantification Writing Group; American Society of Echocardiography's Guidelines and Standards Committee; European Association of Echocardiography. Recommendations for chamber quantification. *J Am Soc Echocardiogr* 2005;18:1440-1463.
4. Zoghbi WA, Chambers JB, Dumesnil JG, Foster E, Gottdiener JS, Grayburn PA, Khandheria BK, Levine RA, Marx GR, Miller FA Jr, Nakatani S, Quiñones MA, Rakowski H, Rodriguez LL, Swaminathan M, Waggoner AD, Weissman NJ, Zabalgoitia M; American Society of Echocardiography's Guidelines and Standards Committee; Task Force on Prosthetic Valves; American College of Cardiology Cardiovascular Imaging Committee; Cardiac Imaging Committee of the American Heart Association; European Association of Echocardiography; European Society of Cardiology; Japanese Society of Echocardiography; Canadian Society of Echocardiography; American College of Cardiology Foundation; American Heart Association; European Association of Echocardiography; European Society of Cardiology; Japanese Society of Echocardiography; Canadian Society of Echocardiography. Recommendations for evaluation of prosthetic valves with echocardiography and doppler ultrasound. *J Am Soc Echocardiogr* 2009;22:975-1014.
5. Lancellotti P, Tribouilloy C, Hagendorff A, Moura L, Popescu BA, Agricola E, Monin JL, Pierard LA, Badano L, Zamorano JL; European Association of Echocardiography. European Association of Echocardiography recommendations for the assessment of valvular regurgitation. Part 1: aortic and pulmonary regurgitation (native valve disease). *Eur J Echocardiogr* 2010;11:223-44.
6. Lancellotti P, Moura L, Pierard LA, Agricola E, Popescu BA, Tribouilloy C, Hagendorff A, Monin JL, Badano L, Zamorano JL; European Association of Echocardiography. European Association of Echocardiography recommendations for the assessment of valvular regurgitation. Part 2: mitral and tricuspid regurgitation (native valve disease). *Eur J Echocardiogr* 2010;11:307-332.
7. Demers P, Miller DC. Simple modification of "T. David-V" valve-sparing aortic root replacement to create graft pseudosinuses. *Ann Thorac Surg*. 2004;78:1479-1481.
8. Sarsam MA, Yacoub M. Remodeling of the aortic valve annulus. *J Thorac Cardiovasc Surg* 1993;105:435-438.
9. Kon ND, Cordell AR, Adair SM, Dobbins JE, Kitzman DW. Aortic root replacement with the freestyle stentless porcine aortic root bioprosthesis. *Ann Thorac Surg* 1999;67:1609-1615.



10. Lim JY, Jung SH, Kim JB, Chung CH, Lee JW, Song H, Choo SJ. Management of concomitant mild to moderate functional mitral regurgitation during aortic valve surgery for severe aortic insufficiency. *J Thorac Cardiovasc Surg* 2014;148:441-446.
11. Bonow RO, Lakatos E, Maron BJ, Epstein SE. Serial long-term assessment of the natural history of asymptomatic patients with chronic aortic regurgitation and normal left ventricular systolic function. *Circulation* 1991;84:1625-1635.
12. Breithardt OA, Sinha AM, Schwammenthal E, Bidaoui N, Markus KU, Franke A, Stellbrink C. Acute effects of cardiac resynchronization therapy on functional mitral regurgitation in advanced systolic heart failure. *J Am Coll Cardiol* 2003;41:765-770.
13. Magne J, Pibarot P, Dagenais F, Hachicha Z, Dumesnil JG, Sénéchal M. Preoperative posterior leaflet angle accurately predicts outcome after restrictive mitral valve annuloplasty for ischemic mitral regurgitation. *Circulation* 2007;115:782-791.
14. Levine RA, Schwammenthal E. Ischemic mitral regurgitation on the threshold of a solution: from paradoxes to unifying concepts. *Circulation* 2005;112:745-758.
15. Gogoladze G, Dellis SL, Donnino R, Ribakove G, Greenhouse DG, Galloway A, Grossi E. Analysis of the mitral coaptation zone in normal and functional regurgitant valves. *Ann Thorac Surg* 2010;89:1158-1161.
16. Mautner SL, Klues HG, Mautner GC, Proschan MA, Roberts WC, Maron BJ. Comparison of mitral valve dimensions in adults with valvular aortic stenosis, pure aortic regurgitation and hypertrophic cardiomyopathy. *Am J Cardiol* 1993;71:949-953.
17. D'Ancona G, Amaducci A, Prodrorno J, Pirone F, Follis M, Falletta C, Pilato M. Midterm follow-up dynamic echocardiography evaluation after aortic valve repair for aortic valve insufficiency. *Interact Cardiovasc Thorac Surg* 2012;14:721-724.

