



Universiteit
Leiden

The Netherlands

Matrix metalloproteinases in gastric inflammation and cancer : clinical relevance and prognostic impact

Kubben, F.J.G.M.

Citation

Kubben, F. J. G. M. (2007, September 27). *Matrix metalloproteinases in gastric inflammation and cancer : clinical relevance and prognostic impact*. Retrieved from <https://hdl.handle.net/1887/12356>

Version: Corrected Publisher's Version

License: [Licence agreement concerning inclusion of doctoral thesis in the Institutional Repository of the University of Leiden](#)

Downloaded from: <https://hdl.handle.net/1887/12356>

Note: To cite this publication please use the final published version (if applicable).

CHAPTER 2

Mucosal gelatinases MMP-2 and MMP-9 in *Helicobacter pylori*-associated gastritis

F.J.G.M. Kubben¹, A.M.C. Witte¹, A.A. Dihal¹, R.A. Veenendaal¹, W. van Duijn¹, J.H. Verheijen², R. Hanemaaijer², C.B.H.W. Lamers¹, H.W. Verspaget¹
¹Department of Gastroenterology and Hepatology, Leiden University Medical Centre, Leiden, The Netherlands; ²TNO Quality of Life, Biomedical Research, Leiden, The Netherlands

Summary

Colonization of the gastric mucosa with *Helicobacter pylori* (*H. pylori*) leads to an acute gastritis, which will develop into a chronic gastric inflammatory reaction in the majority of infected individuals. This long-term *H. pylori*-associated gastritis is recognized as an important pathogenic factor in peptic ulcer disease and gastric carcinogenesis, disorders where tissue remodelling through matrix metalloproteinases (MMPs) is known to occur. The present study was performed to investigate whether the gastric mucosal MMP-2 and MMP-9 levels are affected by an *H. pylori* infection. The levels, isoform constitution and activity of MMP-2 and MMP-9 were determined by quantitative gelatin-zymography, bioactivity assay (BIA), Enzyme-Linked Immunosorbent Assay (ELISA) and immunohistochemistry in mucosal biopsies of the antrum and corpus originating from patients with an *H. pylori*-associated gastritis ($n=45$) and *H. pylori* negative control patients ($n=27$). *H. pylori* infection and gastritis was established by a combination of culture and/or histological identification, and confirmed by specific IgG *H. pylori* antibodies.

Patients with an *H. pylori* infection showed significantly elevated levels of all forms of MMP-9 (5- up to 70-fold, $P\leq 0.005$) in both antrum and corpus mucosa when compared with *H. pylori* negative controls, whereas the MMP-2 levels were almost identical. The increase of MMP-9 in the corpus mucosa of patients with antral gastritis only was less impressive (3- to 6-fold) and intermediate ($0.001\leq P\leq 0.05$) to that of *H. pylori* negative patients and pangastritis patients. A highly significant correlation between quantitative gelatin-zymography, BIA and ELISA was observed for MMP-9 ($R>0.81$, $P<0.001$), which was less coherent for MMP-2. Semi-quantitative histology scores confirmed that both active as well as chronic inflammation were significantly ($P<0.001$) increased in antrum as well as in corpus mucosa of *H. pylori* infected patients compared with *H. pylori* negative patients. The increase of MMP-9, primarily expressed in phagocytic inflammatory cells, correlated significantly ($0.27\leq R\leq 0.53$) with the severity of both the active as well as chronic inflammation in antrum ($P<0.05$) and particularly in corpus mucosa ($P<0.01$).

In conclusion, *H. pylori*-associated gastritis is characterized by a significant increase in the MMP-9 levels in both antrum and corpus mucosa, which is particularly present in phagocytes and correlates with the severity of the mucosal inflammation. In contrast, MMP-2 levels are almost unaltered when compared with *H. pylori* negative patients. This MMP-9 profile in the *H. pylori*-infected gastric mucosa is comparable to that seen in gastric ulceration and carcinomas.

Introduction

Helicobacter pylori (*H. pylori*) is a curved or spiral-shaped Gram-negative bacterium that lives in the mucus layer of the gastric epithelium and in metaplastic gastric epithelium of the oesophagus and duodenum [1-3]. Infection with *H. pylori* is the most common cause of gastritis, preceded by colonization of the gastric mucosa [4]. This infection leads to an acute gastritis that, over the course of several weeks, will develop into a chronic inflammatory reaction of the mucosa [5]. Patients with longstanding *H. pylori*-associated chronic gastritis are predisposed for peptic ulcer disease as well as gastric carcinoma and lymphoma [6, 7]. In this sequence of events cells migrate through the gastric tissue that thereby undergoes constant remodelling.

Matrix metalloproteinases (MMPs) are thought to be key enzymes in these kinds of inflammatory, ulcerative, and malignant processes [8-12]. The (patho)physiologic degradation of basement membrane components and the extracellular matrix is executed by these secreted or transmembrane endo-proteinases, which share a zinc-containing catalytic domain required for their proteolytic activity. Currently, at least 17 MMP family members have been identified which can be divided into 4 major subgroups, based on their substrate preferences: i.e. collagenases, stromelysins, gelatinases and membrane-type MMPs. Most of these enzymes are secreted in a latent form and require extracellular activation. Their activity is regulated by the interaction with their antagonists, the tissue inhibitors of metalloproteinases (TIMPs), and through inhibition by α_2 -macroglobulin [8, 11, 12]. Previous studies have shown that gastric ulceration, both in animal models and in humans, is accompanied by enhanced expression and levels of several MMPs within the mucosa [13-16]. In addition, gastric cancer is also reported to be characterized by an increase of MMPs [17-22]. The aim of the present study was to assess whether the levels of the gelatinases MMP-2 and MMP-9 in the gastric mucosa are affected already early in these pathophysiological processes, i.e. during an *H. pylori* infection, which has to our knowledge not been reported before.

Patients, materials and methods

Patients

Biopsy specimens at upper gastrointestinal endoscopy were obtained from 72 consecutive dyspeptic patients, between 21 and 80 years of age (mean age: 51.8 ± 1.9 years), consisting of 42 males and 30 females. Patients who had recently used proton-pump inhibitors, corticosteroids, non-steroidal anti-inflammatory drugs (NSAIDs), bismuth compounds, sucralfate, or antibiotics were excluded. For histological examination, 2

biopsies were taken from the antrum, 3-5 cm proximal to the pylorus, and 2 from the corpus, 5 cm above the junction between antrum and corpus. These specimens were examined by an experienced pathologist according to the guidelines of the revised Sydney system, which provides a semi-quantitative grading of histological parameters (0 = normal, 1 = mild, 2 = moderate, 3 = marked) [23]. One biopsy was taken from the antrum for *H. pylori* culture and processed as described previously [24]. In 27 cases, the stomach was *H. pylori* negative, which is defined as normal, while 31 patients had a pangastritis. In these cases both antrum and corpus showed histological signs of inflammation. In the other 14 cases, only the antrum was inflamed. All cases of gastritis were caused by *H. pylori*. The presence of these bacteria was assessed by a culture and/or histological identification, and confirmed by specific IgG *H. pylori* antibodies. Two biopsies of antrum and corpus were used for the determination of MMP-2 and MMP-9.

Tissue extraction and protein concentration

Homogenates were made by adding 100 μ l PBST (0.05% Tween[®]20 in phosphate buffered saline) per mg biopsy material and homogenizing on ice in a Potter S (B. Braun). The protein concentration in the supernatant was determined by the Lowry method [25].

Gelatin-zymography

The presence of active and pro forms of the matrix metalloproteinases were assessed by gelatin-zymography, as previously described [18]. Ten per cent polyacrylamide gels were casted in a Mini-Protean[®] II Dual Slab Cell (Biorad). These gels contained 1.5M Tris buffer (pH 8.8), 0.2% gelatin, 0.1% sodium dodecyl sulphate, 0.07% ammonium persulphate and 0.07% tetramethylenediamine. First sample volumes were adjusted to obtain an equal protein content of 5 μ g per sample. Two amounts (6.1 and 12.2 μ g protein) of an internal standard preparation, i.e. a homogenate of a colonic carcinoma containing both MMP-2 and MMP-9, were included on each gel for correction of intergel variation and as reference for the expression in arbitrary units. After electrophoresis the gels were incubated overnight at 37°C, stained with Amido Black (0.1% amido black, 30% methanol and 10% acetic acid), and destained in a solution containing 30% methanol and 10% acetic acid. Subsequently the gels were dried between sheets of cellophane. Finally the degree of gelatin digestion was quantified by making a digital photo with a CCD Imaging System (Appligene), scanned in Aldus Photostyler 2.0 (Aldus Corporation) and analysed with Imagequant (Molecular Dynamics), using the peakfinder-mode. The gelatin digestion was reflected as a peak and the MMP levels were calculated referring to the internal standard preparations, of which the peak-height correlated highly significant with the included concentration

($R=0.99$, $P < 0.001$). The MMPs were analysed for the pro, active and total MMP levels, the latter defined as the sum of the two isoforms, and expressed as Arbitrary Units per 5 μg protein.

Bioactivity assay

Latent (activatable) and active MMP were also measured using a newly developed immunocapture colorimetric activity assay (BIA) [26, 27]. Briefly, a polyclonal anti-MMP-2 or monoclonal anti-MMP-9 antibody (TNO-PG) was used as catching antibody to capture MMP-2 or MMP-9 from appropriate dilutions of the tissue homogenates, respectively 1:4, and 1:20, by overnight incubation at 4°C. Active MMP was determined directly, whereas latent MMP was activated by incubation with 0.5 mM APMA (*p*-aminophenylmercuric acetate) for 0.5 and 2 hr at 37°C for MMP-2 and MMP-9, respectively. After washing MMP activity was assessed by adding 750 ng modified MMP-activatable pro-urokinase (Ukcol) and 0.6 mM of its chromogenic substrate S-2444 (pyro-Glu-Gly-Arg-*p*-nitroanilide; Chromogenix, Sweden) in assay buffer and incubating at 37°C. Reactions were performed in 96-well flat-bottomed microtitre plates, and a Titertek Multiskan photometer was used to follow the absorbance kinetics at 405 nm. Results were expressed as MMP activity Units per mg protein, with Units defined as $(\Delta A_{405}/\text{hr}^2) * 10$.

ELISAs

The total amount of MMP-2 and MMP-9 protein was determined by sandwich-ELISAs [27]. In brief, the same catching antibodies were used as for the immunocapture activity assays and appropriate dilutions of tissue homogenates, respectively 1:6.7 and 1:5, were incubated overnight at 4°C. Immunodetection of MMP-9 was performed with biotinylated rabbit anti-MMP-9 and for MMP-2 using rabbit anti-MMP-2 (TNO-PG) followed by biotinylated goat anti-rabbit-IgG. After incubation with avidin/horseradish-peroxidase the chromogenic substrate 3,3',5,5'-tetramethyl benzidine and H_2O_2 were added and the reaction was stopped with H_2SO_4 and read at 405 nm. The amount of MMP was calculated from the parallel standard curves and expressed in ng MMP per mg protein.

Immunohistochemistry

MMP-2 and MMP-9 were localized by routine indirect peroxidase-labelled antibody immunohistochemistry. Briefly, 4 μm paraffin sections were sequentially treated with 0.005% proteinase K (Boehringer Mannheim, Germany) in Tris-buffered saline (TBS) to retrieve hidden antigens and with 0.3% H_2O_2 in methanol to block endogenous peroxidase activity. After permeabilization in 0.5% Triton X-100 in 0.1% sodium citrate the sections were rinsed in TBS and 5% normal goat serum was applied for 20 minutes

to block non-specific binding. Excess serum was drained off, and sections were incubated overnight at 4°C with rabbit anti-MMP-2 or anti-MMP-9 polyclonal antibodies, appropriately diluted in TBS containing 0.5% BSA. The sections were subsequently incubated with biotinylated goat anti-rabbit IgG and peroxidase-labelled streptavidin for 45 minutes each. Sections were stained by incubation in 0.1 M acetate buffer (pH 5.2) containing 0.03% 3-amino-9-ethylcarbazole and 0.03% H₂O₂ for 10 minutes, resulting in a red staining product. Finally, sections were counterstained in Mayer's haematoxylin and mounted in Aquamount™.

Statistical analysis

Group means are given as mean \pm s.e.m. Differences between groups were evaluated for significance using the Kruskal-Wallis and Mann-Whitney *U* tests or the Wilcoxon Signed-Ranks test. The correlations between zymography, immunocapture activity assay, and ELISA were assessed by the Pearson correlation procedure (SPSS for Windows 7.0 statistical package, SPSS Inc., Chicago, Illinois, U.S.A.). Differences were considered significant when $P \leq 0.05$.

Results

Patients with an *H. pylori* infection were found to have a significantly higher level of total MMP-9, as assessed by zymography, in both antrum [216 ± 50 ($n=45$) vs. 4.8 ± 1.5 ($n=27$), $P < 0.001$] and corpus mucosa [100 ± 20 ($n=45$) vs. 4.2 ± 1.2 ($n=27$), $P < 0.001$] compared

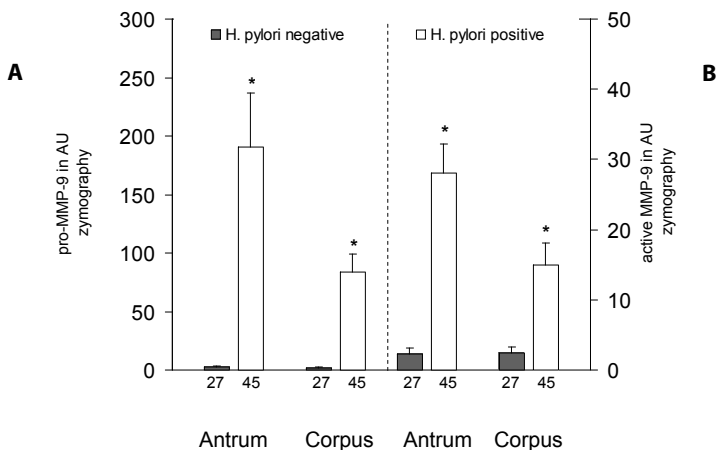


Figure 1. Mean levels of pro (A) and active (B) MMP-9 \pm s.e.m. in antrum and corpus mucosa originating from subjects with or without an *H. pylori* infection, as assessed by gelatin-zymography. The number of patients is indicated. * $P < 0.001$

with patients who were *H. pylori* negative. The same was true for both zymographic MMP-9 isoforms, i.e. pro and active MMP-9, which were also significantly increased in both antrum and corpus mucosa (Figure 1). These results were further substantiated by the BIA and ELISA for MMP-9. Latent MMP-9 as well as the total amount of MMP-9 protein were also found to be approximately 6- to 30-fold enhanced in both antrum and corpus mucosa of *H. pylori* positive versus *H. pylori* negative patients (Figure 2). Active MMP-9, as assessed by the BIA, was found to be similarly enhanced in both antrum

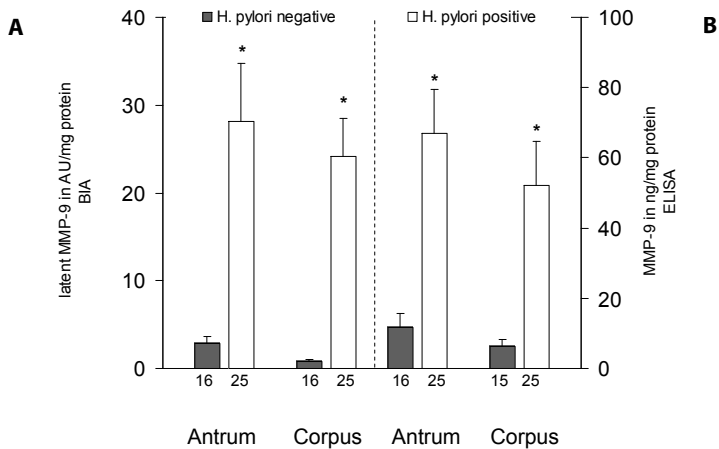


Figure 2. Mean levels of latent or activatable (A) and total amount protein (B) MMP-9 \pm s.e.m. in antrum and corpus mucosa originating from subjects with or without an *H. pylori* infection, as determined by BIA and ELISA, respectively. The number of patients is indicated. * $P \leq 0.005$

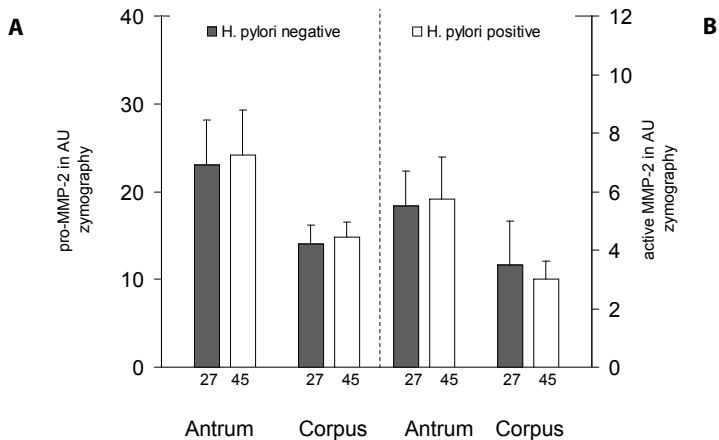


Figure 3. Mean levels of pro (A) and active (B) MMP-2 \pm s.e.m. in antrum and corpus mucosa originating from subjects with or without an *H. pylori* infection, as assessed by gelatin-zymography. The number of patients is indicated. Differences between *H. pylori* positive and *H. pylori* negative patients were not significant.

[9.6±2.0 (n=25) vs. 1.1±0.4 (n=16), $P<0.001$] and corpus mucosa [8.0±2.2 (n=25) vs. 0.6±0.2 (n=16), $P<0.001$] compared with patients who were *H. pylori* negative. Highly significant correlations between the different detection assays, i.e. zymography, BIA and ELISA, for MMP-9 were found in both tissue types ($0.81 < R < 0.91$, $P < 0.001$).

In contrast, the total MMP-2 levels in the zymographic analyses were found to be almost identical in the two patient-groups, in antrum [30±6.6 (n=45) vs. 29±6.3 (n=27), NS] as well as in corpus mucosa [19±1.9 (n=45) vs. 18±2.9 (n=27), NS]. The levels of the pro and active isoform of MMP-2 were also found to be highly similar in the gastric mucosa of *H. pylori* positive and negative patients (Figure 3). These results were confirmed by the BIA and ELISA for MMP-2 in these tissues. Latent MMP-2 in the antrum [2.1±0.5 (n=23) vs. 2.8±0.7 (n=15), NS] and corpus mucosa [2.4±0.5 (n=25) vs. 2.8±0.5 (n=15), NS] of patients with an *H. pylori* infection were almost identical to controls. The ELISA for MMP-2 also failed to show significant differences between *H. pylori* positive and negative patients, i.e. 6.7±1.3 (n=25) vs. 7.7±2.1 (n=15) in antrum and 6.4±1.3 (n=25) vs. 4.5±0.7 (n=17) in corpus mucosa. Active MMP-2 by the BIA was not assessed because of the absence of differences in the other determinations. Overall, the differ-

Table 1 - Mean values of MMP-2 and -9 in antrum and corpus mucosa, as assessed by gelatin-zymography and given in Arbitrary Units (AU) ± s.e.m. Total MMP is defined as the sum of pro and active MMP. Normal mucosa is defined as *H. pylori* negative.

Antrum		Normal Mucosa (n=27)	Antral Gastritis (n=14)	Pangastritis (n=31)
MMP-2	Pro	23 ± 5.1	19 ± 3.4	27 ± 7.0
	Active	5.5 ± 1.2	2.7 ± 0.7	7.0 ± 3.0
	Total	29 ± 6.3	21 ± 3.5	34 ± 9.4
MMP-9	Pro	2.6 ± 0.7	108 ± 34 ^{o1}	224 ± 64 ^{•1}
	Active	2.3 ± 0.8	20 ± 4.9 ^{o1}	31 ± 6.0 ^{•1}
	Total	4.8 ± 1.5	127 ± 38 ^{o1}	256 ± 69 ^{•1}
Corpus		Normal Mucosa (n=27)	Antral Gastritis (n=14)	Pangastritis (n=31)
MMP-2	Pro	14 ± 2.2	13 ± 1.9	17 ± 2.2
	Active	3.5 ± 1.5	2.0 ± 0.9	3.5 ± 0.7
	Total	18 ± 2.9	15 ± 2.0	20 ± 2.6
MMP-9	Pro	1.8 ± 0.5	12 ± 3.7 ^{o2}	119 ± 22 ^{•1} ◊ ¹
	Active	2.4 ± 0.9	6.0 ± 2.7	18 ± 4.3 ^{•1} ◊ ²
	Total	4.2 ± 1.2	18 ± 5.7 ^{o3}	137 ± 26 ^{•1} ◊ ¹

The following significances are based on the differences between the groups.

• = pangastritis compared with normal mucosa

° = antral gastritis compared with normal mucosa

◊ = pangastritis compared with antral gastritis

¹ $P \leq 0.001$, ² $P \leq 0.01$, ³ $P \leq 0.05$

ent detection assays for MMP-2 were found to be less coherent than for MMP-9, with the best correlation found between the BIA and the ELISA ($0.46 < R < 0.67$, $P < 0.005$).

Both *H. pylori* infected groups, i.e. patients with antral gastritis only or those with pangastritis, showed remarkably higher levels of MMP-9 in both antrum and corpus compared to control mucosa, exemplified by the zymographic results (Table 1). Considering the *H. pylori* positives separately, the corpus mucosa of patients with pangastritis showed significantly higher pro, active, and total MMP-9 levels than that of patients with antral gastritis only, whereas in the antrum mucosa a similar trend was observed, without reaching statistical significance. In addition, patients with antral gastritis only were found to have significantly elevated levels of the MMP-9 isoforms ($0.002 < P < 0.05$) within the antrum mucosa when compared with their corresponding corpus mucosa. In the patients with pangastritis and the *H. pylori* negative patients the antrum only showed somewhat higher MMP-9 levels, although not statistically significant, when compared with their corpus mucosa.

The antrum of *H. pylori*-infected patients showed significantly more active inflammation [1.3 ± 0.1 ($n=44$) vs. 0 ($n=27$), $P < 0.001$] as well as chronic inflammation [1.5 ± 0.1 ($n=44$) vs. 0.6 ± 0.1 ($n=27$), $P < 0.001$] compared with the *H. pylori* negative patients. A similar effect was seen in the corpus mucosa of *H. pylori*-infected patients for both active inflammation [0.7 ± 0.1 ($n=42$) vs. 0 ($n=26$), $P < 0.001$] and chronic inflammation [1.2 ± 0.1 ($n=42$) vs. 0.5 ± 0.1 ($n=26$), $P < 0.001$]. Compared with *H. pylori* negative patients, both *H. pylori*-infected groups showed significantly more active as well as chronic inflammation in the antrum (Table 2). A similar trend was found in the corpus mucosa for active inflammation, whereas chronic inflammation was only significantly

Table 2 - Mean values \pm s.e.m. of active, i.e. presence of neutrophilic polymorphonuclear leukocytes, and chronic, i.e. cellular infiltrate consisting of lymphocytes, plasma cells, monocytes, mast cells and eosinophils, inflammation in antrum and corpus mucosa [23]. Normal mucosa is defined as *H. pylori* negative.

Inflammation Antrum	Normal Mucosa ($n=27$)	Antral Gastritis ($n=14$)	Pangastritis ($n=30$)
Active	0	1.2 ± 0.1 ° ¹	1.3 ± 0.1 • ¹
Chronic	0.6 ± 0.1	1.4 ± 0.1 ° ¹	1.5 ± 0.1 • ¹
Inflammation Corpus	Normal Mucosa ($n=26$)	Antral Gastritis ($n=14$)	Pangastritis ($n=28$)
Active	0	0.1 ± 0.1 ° ³	1.0 ± 0.1 • ¹ ◊ ¹
Chronic	0.5 ± 0.1	0.7 ± 0.2	1.4 ± 0.1 • ¹ ◊ ²

The following significances are based on the differences between the groups.

• = pangastritis compared with normal mucosa

° = antral gastritis compared with normal mucosa

◊ = pangastritis compared with antral gastritis

¹ $P \leq 0.001$, ² $P \leq 0.01$, ³ $P \leq 0.05$

higher in patients with pangastritis. Regarding the two *H. pylori*-infected patient-groups separately, the corpus of patients with pangastritis showed significantly more active as well as chronic inflammation than that of patients with antral gastritis only, in contrast to the corresponding antrum in which a similar intensity of active and chronic inflammation was found. As expected, the antrum of patients with antral gastritis only showed significantly higher scores of active ($P<0.001$) and chronic inflammation ($P<0.01$) compared with their corresponding corpus mucosa. Within the *H. pylori* negatives only minimal chronic inflammation was detected in both antrum and corpus mucosa.

Immunohistochemically MMP-9 was predominantly observed in inflammatory and stromal cells, i.e. neutrophilic granulocytes, macrophages, and (myo)fibroblasts, and in zymogen producing chief cells of corpus mucosa (data not shown). Faint MMP-2 immunoreactivity was predominantly observed in inflammatory cells as well, but not in chief cells.

In the overall patient-group, i.e. *H. pylori* positives and negatives together, a significant correlation was found between the zymographically determined total MMP-9 levels and the active as well as chronic inflammation in both antrum [respectively, $R=0.27$, $P<0.05$ and $R=0.33$, $P<0.01$ ($n=71$)] and corpus mucosa [respectively, $R=0.53$ and $R=0.45$, both $P<0.001$ ($n=68$)]. In the corpus mucosa of patients with an *H. pylori* gastritis both the active and chronic inflammation correlated significantly with these MMP-9 levels [respectively, $R=0.38$ and $R=0.36$, both $P<0.05$ ($n=42$)], in contrast to the antrum where no correlation was found.

Discussion

Previous studies revealed an increased expression of MMPs during gastric ulceration [13-16] and in carcinomas of the stomach [17-22]. *H. pylori*-associated chronic gastritis is known to be able to evolve in peptic ulcer disease or gastric cancer in some patients. Therefore, we assessed the expression of the gelatinases MMP-2 and MMP-9 in gastric mucosal biopsies from patients with a *H. pylori* gastritis. We found *H. pylori* positive patients to have significantly elevated levels of MMP-9 in antrum and corpus mucosa when compared with *H. pylori* negative patients, whereas the MMP-2 levels were highly similar. The increase in MMP-9 was very consistent and irrespective of the detection technique used, i.e. gelatin-zymography, BIA or ELISA. Moreover, not only the total mucosal MMP-9 protein level was enhanced due to the *H. pylori* infection, also the two isoforms latent (pro) and active MMP-9 were similarly increased. With regard to MMP-2 no changes were found neither in the total mucosal protein level nor in the isoform composition.

The significantly elevated levels of mucosal MMP-9 in patients with an *H. pylori*-associated gastritis was found to be primarily localized in the infiltrating inflammatory cells such as macrophages, neutrophils and also in some (myo)fibroblasts. The presence and activation of these cells is most probably caused by the locally produced mucosal substances like cytokines, e.g. TNF- α and IL-8, which have been reported to be increased in *H. pylori*-induced chronic gastritis [28-31]. The finding of a significant difference in the corpus MMP-9 levels between *H. pylori* negative controls and patients with only an antral gastritis is remarkable. This might be due to both the presence of some minimal active inflammation and to proinflammatory alterations occurring in the corpus, induced by mediators such as cytokines and cytotoxins, originating from the infected and inflamed adjacent antrum, thereby creating a kind of paracrine stimulation.

The antrum of patients with an antral gastritis only showed significantly higher levels of MMP-9 compared with their corresponding corpus. The antrum of *H. pylori* negative patients and that of patients with a pangastritis, however, contained similar MMP levels compared with their corpus mucosa. Therefore, one might conclude that there is at least no intrinsic difference between antrum and corpus mucosa, regarding the MMP levels. The inflammatory reaction in the corpus mucosa of patients with an antral gastritis only was found to be less intense compared with the antrum mucosa as illustrated by the smaller amount of inflammatory cell infiltrate. This is probably related to the slow pyloro-cardial progression of gastritis as a consequence of a less dense *H. pylori* colonization of the corpus due to local acid production [32]. The differences in MMP-9 levels found between the antrum and corpus mucosa of antral gastritis patients are thus most probably caused by the larger amount of MMP producing and secreting cells present within the antrum mucosa. In addition, within the antrum of all the patients a fairly good correlation was found between the MMP-9 level and the severity of both the active and chronic inflammation, which was even better in the corpus mucosa. This latter observation might be explained by the fact that the corpus mucosa of patients with an antral gastritis is intermediately inflamed, when compared with *H. pylori* negatives and patients with a pangastritis, causing a more gradual increase of inflammation and accompanying MMP secreting inflammatory cells.

Gastric ulceration is known to be accompanied by an enhanced expression of several metalloproteinases within the mucosal lesions, but gelatinases have only been assessed in animal models [13-16]. Interestingly also in the acetic acid-induced ulcers in rats only MMP-9 was found to be impressively increased whereas MMP-2 expression was hardly affected [13, 15]. These findings are highly similar to our observations in *H. pylori*-associated gastritis. In contrast, studies in patients with gastric cancer, including one by our group using similar techniques, consistently revealed that both MMP-2

and -9 levels are significantly elevated within the malignant tissue [18-20]. Apparently the premalignant inflammatory and ulcerative lesions are accompanied by the induction of only MMP-9, whereas the end-stage of the spectrum, i.e. gastric cancer, is characterized by a general upregulation of both gelatinases. Part of this difference might be explained by the fact that MMP-9 is an inducible matrix metalloproteinase in contrast to MMP-2, which is expressed constitutively [8, 11]. Particularly with regard to the *H. pylori* infection it has been reported that the inflammation is associated with an increase of mucosal cytokines [28-31], which are able to enhance the MMP-9 production. Furthermore, the divergence in MMP-2 and MMP-9 induction is probably also related to the differences in predominant cellular origin of these gelatinases. MMP-2 is expressed amongst others by stromal fibroblasts and epithelial cells [11, 33, 34], whereas MMP-9 is particularly secreted by cells of the phagocytic lineage [11, 35-38], which fits well with our immunohistochemical results in the *H. pylori*-infected gastric mucosa. Further prospective studies in patients with an *H. pylori*-associated chronic gastritis with a long follow-up might help to identify whether those patients with a relatively high MMP-2 level in the mucosa are the ones with the strongest predisposition for gastric carcinoma.

Another aspect of the high MMP-9 levels in *H. pylori* gastritis might be the relation with wound healing. Acute wounds and impaired healing, i.e. chronic persistent wounds, have been shown to be accompanied by a high expression of MMP-9 [39-41]. Therefore, it is likely that the excessive MMP-9 expression as found in the *H. pylori*-infected mucosa, may prevent spontaneous healing. Previous studies by our group indicate that successful eradication of *H. pylori* leads to improvement and normalization of the active and chronic inflammatory reaction in the stomach, which is accompanied by a reversal of alterations in other mucosal parameters, e.g. plasminogen activators and superoxide dimutases [42, 43]. Similar studies will have to elucidate whether the MMP-9 levels will also be normalized by eradication of the *H. pylori* infection.

In conclusion, *H. pylori*-associated gastritis is characterized by a significant increase of MMP-9 in both antrum and corpus mucosa of the stomach, with no changes in MMP-2, compared with *H. pylori* negative patients. Moreover, the increase of the gastric mucosal MMP-9 level is significantly correlated with the severity of both the active as well as the chronic inflammation. Future studies will elucidate the clinical relevance of these findings by evaluating the effect of therapy and the association with gastric carcinogenesis.

References

1. Marshall BJ, Warren JR. Unidentified curved bacilli in the stomach of patients with gastritis and peptic ulceration. *Lancet* 1984; i: 1311-1315
2. Steer HW. Surface morphology of gastroduodenal mucosa in duodenal ulceration. *Gut* 1984; 25: 1203-1210
3. Talley NJ, Cameron AJ, Shorter RG, Zinmeister AR, Phillips SF. *Campylobacter pylori* and Barrett's oesophagus. *Mayo Clin Proc.* 1988; 63: 1176-1180
4. Taylor DN, Blaser MJ. The epidemiology of *Helicobacter pylori* infection. *Epidemiol Rev* 1991; 13: 42-59
5. Blaser MJ. *Helicobacter pylori* and the pathogenesis of gastroduodenal inflammation. *J Infect Dis* 1990; 161: 626-633
6. Correa P. Human gastric carcinogenesis: a multistep and multifactorial process. *Cancer Res* 1992; 52: 6735-6740
7. Møller H, Heseltine E, Vainio H. Working group report on schistosomes, liver flukes and *Helicobacter pylori*. *Int J Cancer* 1995; 60: 587-589
8. Goetzl EJ, Banda MJ, Leppert D. Matrix metalloproteinases in immunity. *J Immunol* 1996; 156: 1-4
9. Saarialho-Kere UK. Patterns of matrix metalloproteinase and TIMP expression in chronic ulcers. *Arch Dermatol Res* 1998; 290 suppl:547-554
10. Ohtani H. Stromal reaction in cancer tissue: pathophysiologic significance of the expression of matrix-degrading enzymes in relation to matrix turnover and immune/inflammatory reactions. *Pathol Int* 1998; 48: 1-9
11. Parsons SL, Watson SA, Brown PD, Collins HM, Steele RJC. Matrix metalloproteinases. *Br J Surg* 1997; 84: 160-166
12. Duffy MJ, McCarthy K. Matrix metalloproteinases in cancer: prognostic markers and targets for therapy. *Int J Oncol* 1998; 12: 1341-1348
13. Ito A, Nagase H, Mori Y. Characterization of metalloproteinases in rat gastric tissues with acetic acid-induced ulcers. *Scand J Gastroenterol* 1989; 24 suppl162: 146-149
14. Saarialho-Kere UK, Vaalamo M, Puolakkainen P, Airola K, Parks WC, Karjalainen-Lindsberg ML. Enhanced expression of matrilysin, collagenase, and stromelysin-1 in gastrointestinal ulcers. *Am J Pathol* 1996; 148: 519-526
15. Baragi VM, Qiu L, Gunja-Smith Z, Woessner JF, Lesch CA, Guglietta A. Role of metalloproteinases in the development and healing of acetic acid-induced gastric ulcer in rats. *Scand J Gastroenterol* 1997; 32: 419-426
16. Otani Y, Sakurai Y, Kameyama K, Igarashi N, Yokoyama T, Kubota T, Kumai K, Kitajima M. Matrix metalloproteinase gene expression in chronic gastric ulcer: a potential role of eosinophils in perforation. *J Clin Gastroenterol* 1997; 25 suppl1: S101-S104
17. McDonnell S, Navre M, Coffey RJ, Matrisian LM. Expression and localisation of the matrix metalloproteinase Pump-1 (MMP-7) in human gastric and colon carcinomas. *Mol Carcinog* 1991; 4: 527-533
18. Sier CFM, Kubben FJGM, Ganesh S, Heerding MM, Griffioen G, Hanemaaijer R, van Krieken JHJM, Lamers CBHW, Verspaget HW. Tissue levels of matrix metalloproteinases MMP-2 and MMP-9 are related to the overall survival of patients with gastric carcinoma. *Br J Cancer* 1996; 74: 413-417

19. Murray GI, Duncan ME, Arbuckle E, Melvin WT, Fothergill JE. Matrix metalloproteinases and their inhibitors in gastric cancer. *Gut* 1998; 43: 791-797
20. Parsons SL, Watson SA, Collins HM, Griffin NR, Clarke PA, Steele RJC. Gelatinase (MMP-2 and -9) expression in gastrointestinal malignancy. *Br J Cancer* 1998; 78: 1495-1502
21. Adachi Y, Itoh F, Yamamoto H, Matsuno K, Arimura Y, Kusano M, Endoh T, Hinoda Y, Oohara M, Hosokawa M, Imai K. Matrix metalloproteinase matrilysin (MMP-7) participates in the progression of human gastric and esophageal cancers. *Int J Oncol* 1998; 13: 1031-1035
22. Migita T, Sato E, Saito K, Mizoi T, Shiiba KI, Matsuno S, Nagura H, Ohtani H. Differing expression of MMPs-1 and -9 and urokinase receptor between diffuse- and intestinal-type gastric carcinoma. *Int J Cancer (Pred Oncol)* 1999; 84: 74-79
23. Dixon MF, Genta RM, Yardley JH, Correa P. Classification and grading of gastritis. The updated Sydney system. *Am J Surg Pathol* 1996; 20: 1161-1181
24. Veenendaal RA, Lichtendahl-Bernards AT, Peña AS, Endtz HP, van Boven CPA, Lamers CBHW. Effect of transport medium and transportation time on culture of *Helicobacter pylori* from gastric biopsy specimens. *J Clin Pathol* 1993; 46: 561-563
25. Lowry OH, Rosenbrough NJ, Farr AL, Randall RJ. Protein measurement with the folin phenol reagent. *J Biol Chem* 1951; 193: 265-275
26. Verheijen JH, Nieuwenbroek NME, Beekman B, Hanemaaijer R, Verspaget HW, Ronday HK, Bakker AHF. Modified proenzymes as artificial substrates for proteolytic enzymes: colorimetric assay of bacterial collagenase and matrix metalloproteinase activity using modified pro-urokinase. *Biochem J* 1997; 323: 603-609
27. Hanemaaijer R, Visser H, Konttinen YT, Koolwijk P, Verheijen JH. A novel and simple immunocapture assay for determination of gelatinase-B (MMP-9) activities in biological fluids: saliva from patients with Sjögren's syndrome contain increased latent and active gelatinase-B levels. *Matrix Biol* 1998; 17: 657-665
28. Crabtree JE, Shallcross TM, Heatley RV, Wyatt JI. Mucosal tumour necrosis factor alpha and interleukin-6 in patients with *Helicobacter pylori* associated gastritis. *Gut* 1991; 32: 1473-1477
29. Nielsen H, Andersen LP. Chemotactic activity of *Helicobacter pylori* sonicate for human polymorphonuclear leucocytes and monocytes. *Gut* 1992; 33: 738-742
30. Crabtree JE, Peichl P, Wyatt JI, Stachl U, Lindley IJD. Gastric interleukin-8 and IgA IL-8 autoantibodies in *Helicobacter pylori* infection. *Scand J Immunol* 1993; 37: 65-70
31. Crabtree JE, Covacci A, Farmery SM, Xiang Z, Tompkins DS, Perry S, Lindley IJ, Rappuoli R. *Helicobacter pylori* induced interleukin-8 expression in gastric epithelial cells is associated with CagA positive phenotype. *J Clin Pathol* 1995; 48: 41-45
32. Stolte M, Edit S, Ohnsmann A. Differences in *Helicobacter pylori* associated gastritis in the antrum and body of the stomach. *Z Gastroenterol* 1990; 28: 229-233
33. Poulson R, Pignatelli M, Stetler-Stevenson WG, Liotta LA, Wright PA, Jeffery RE, Longcroft JM, Rogers L, Stamp GWH. Stromal expression of 72 kDa Type IV collagenase (MMP-2) and TIMP-2 mRNAs in colorectal neoplasias. *Am J Pathol* 1992; 141: 389-396
34. Liabakk NB, Talbot I, Smith RA, Wilkinson K, Balkwill F. Matrix metalloprotease 2 (MMP-2) and matrix metalloprotease 9 (MMP-9) type IV collagenases in colorectal cancer. *Cancer Res* 1996; 56: 190-196
35. Garbisa S, Ballin M, Daga-Giordini D, Fastelli G, Naturale M, Negro A, Semenzato G, Liotta LA. Transient expression of type IV collagenolytic metalloproteinase by human mononuclear phagocytes. *J Biol Chem* 1986; 261: 2369-2375

36. Welgus HG, Campbell EJ, Cury JD, Eisen AZ, Senior RM, Wilhelm SM, Goldberg GJ. Neutral metalloproteinases produced by human mononuclear phagocytes. Enzyme profile, regulation and expression during cellular development. *J Clin Invest* 1990; 86: 1496-1502
37. Ahrens D, Koch AE, Pope RM, Stein-Picarella M, Niedbala MJ. Expression of matrix metalloproteinase 9 (96-kd gelatinase B) in human rheumatoid arthritis. *Arthritis Rheum*. 1996; 39: 1576-1587
38. Mautino G, Oliver N, Chanez P, Bousquet J, Capony F. Increased release of matrix metalloproteinase-9 in bronchoalveolar fluid and by alveolar macrophages in asthmatics. *Am J Respir Cell Mol Biol* 1997; 17: 583-591
39. Oikarinen A, Kylmäniemi M, Autio-Harmainen H, Autio P, Salo T. Demonstration of 72-kDa and 92-kDa forms of type IV collagenase in human skin: variable expression in various blistering diseases, induction during re-epithelialization, and decrease by topical glucocorticoids. *J Invest Dermatol* 1993; 101: 205-210
40. Salo T, Mäkelä M, Kylmäniemi M, Autio-Harmainen H, Larjava H. Expression of matrix metalloproteinase-2 and -9 during early human wound healing. *Lab Invest* 1994; 70: 176-182
41. Tarlton JF, Vickery CJ, Leaper DJ, Bailey AJ. Postsurgical wound progression monitored by temporal changes in the expression of matrix metalloproteinase-9. *Br J Dermatol* 1997; 137: 506-516
42. Götz JM, Ravensbergen JW, Verspaget HW, Biemond I, Sier CFM, Offerhaus GJA, Lamers CBHW, Veenendaal RA. The effect of treatment of *Helicobacter pylori* infection on gastric mucosal plasminogen activators. *Fibrinolysis* 1996; 10 suppl2: 85-89
43. Götz JM, Thio JL, Verspaget HW, Offerhaus GJA, Biemond I, Lamers CBHW, Veenendaal RA. Treatment of *Helicobacter pylori* infection favourably affects gastric mucosal superoxide dismutases. *Gut* 1997; 40: 591-596