

Cover Page



Universiteit Leiden

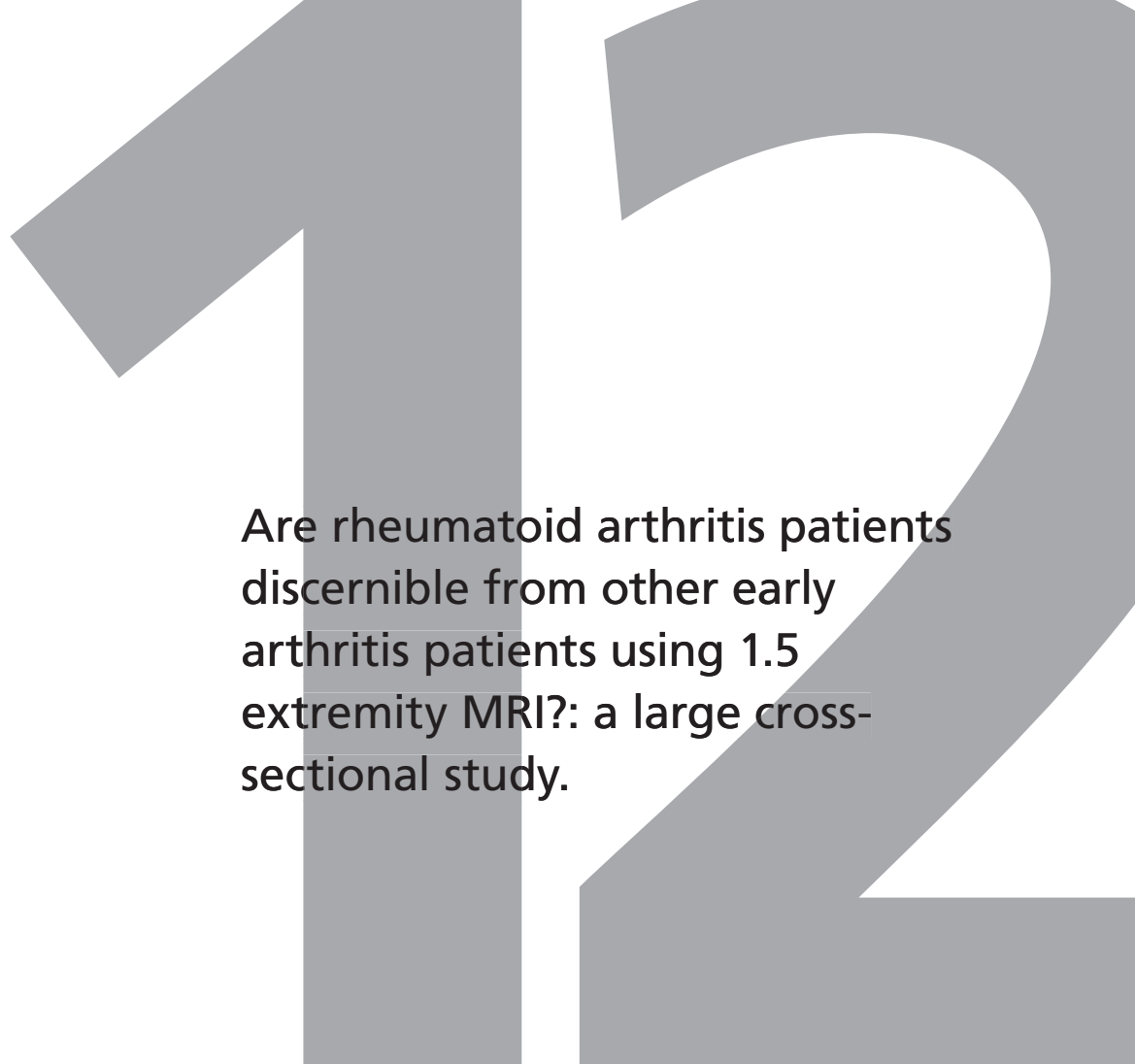


The handle <http://hdl.handle.net/1887/29578> holds various files of this Leiden University dissertation.

**Author:** Krabben, Annemarie

**Title:** Predictive factors for the development and disease course of rheumatoid arthritis

**Issue Date:** 2014-10-30



Are rheumatoid arthritis patients discernible from other early arthritis patients using 1.5 extremity MRI?: a large cross-sectional study.

W. Stomp, A. Krabben, D. van der Heijde, T. W. J. Huizinga, J. L. Bloem, A. H. M. van der Helm-van Mil, M. Reijnders

*Journal of Rheumatology*, 2014 August;41(8):1630-1637.

## ABSTRACT

### Objective

MRI is increasingly used in Rheumatoid arthritis (RA) research. A EULAR task-force recently suggested that MRI can improve the certainty of the diagnosis RA. Since this recommendation may reflect a tendency to use MRI in daily practice, thorough studies on the value of MRI are required. Thus far no large studies have evaluated the accuracy of MRI to differentiate early RA from other early arthritis patients. We therefore performed a large cross-sectional study to determine if patients that are clinically classified with RA differ in MRI features compared to patients with other diagnoses.

### Methods

179 patients presenting with early arthritis (median symptom duration 15.4 weeks) underwent 1.5T-extremity MR-imaging of unilateral wrist, metacarpophalangeal and metatarsophalangeal joints according to our arthritis protocol, the foot without contrast. Images were scored according to OMERACT RAMRIS by two independent readers. Tenosynovitis was also assessed. The main outcome was fulfilling the 1987 ACR-criteria for RA. Test characteristics and areas under the receiver-operator-characteristic-curves (AUCs) were evaluated. In sub-analyses the 2010-ACR/EULAR-criteria were used as outcome and analyses were stratified for ACPA.

### Results

The ACR87-criteria were fulfilled in 43 patients (24.0%). RA-patients had higher scores for synovitis, tenosynovitis and bone marrow edema (BME) than non-RA patients ( $p < 0.05$ ). ACPA-positive patients had more BME (median scores 6.5 vs. 4.25,  $p = 0.016$ ) than ACPA-negative patients. For all MRI features the predictive value for the presence of RA was low (PPV  $< 50\%$ ). For all MRI features the AUCs were  $< 0.70$ . 2010+1987- patients had less synovitis than 2010+1987+ patients ( $p = 0.029$ )

### Conclusion

Although RA-patients had higher scores of MRI-inflammation and ACPA-positive patients had more BME, the severity of MRI-inflammation assessed according to RAMRIS does not accurately differentiate RA-patients from other early arthritis patients.

## INTRODUCTION

Early identification of rheumatoid arthritis (RA) is important because early initiation of aggressive treatment results in a better outcome.<sup>1</sup> However, this requires that RA-patients are identified amongst other early arthritis patients. Magnetic Resonance Imaging (MRI) in RA is presently mainly used for research purposes. The value of MRI is supported by its sensitivity to depict changes that are not detectable by physical examination and the association of bone marrow edema (BME) with radiographic progression over time.<sup>2</sup> A recent EULAR taskforce recommended that "in case of diagnostic doubt, MR imaging can improve the certainty of a diagnosis of RA".<sup>3</sup> Since this recommendation may reflect a tendency to use MRI in daily practice, thorough studies on the value of MRI in a general setting of early arthritis patients are required. Thus far no large studies evaluated the accuracy of MRI to differentiate RA-patients from early arthritis patients with other diagnoses. The majority of studies performed on the diagnostic accuracy primarily evaluated patients with undifferentiated arthritis or RA but not the entire spectrum of early arthritis patients.<sup>4,5</sup> Furthermore, they included a low number of early arthritis patients (less than 50) and reported variable test characteristics (the sensitivity and specificity of certain MR imaging findings ranged between 20–100% and 0–100%). Therefore at present the accuracy to differentiate RA patients from other patients with early arthritis is unclear. We performed a large cross-sectional study to determine this. The outcome was the diagnosis according to classification criteria at two weeks. On purpose we did not explore the additional value of MRI when added to clinical diagnoses, but we started with addressing an even more basic question, being whether patients that are clinically classified with RA differ in MRI features compared to patients with other diagnoses. Because these patients are clinically clearly distinctive, amongst other things in the joints that are typically involved and the extent of inflammation, we anticipated finding differences at 1.5T extremity MRI of the joints most frequently involved in RA. Also, these findings will serve as a basis for further future analyses in the current cohort of patients.

## MATERIALS AND METHODS

### Patients

Patients were included in the Leiden Early Arthritis Clinic (EAC). Inclusion required the presence of clinically confirmed arthritis of  $\geq 1$  joint and symptoms for  $\leq 2$ -years. Parameters collected at inclusion were medical history, questionnaires, joint counts, laboratory tests, and radiographs of hands and feet. For a detailed description see reference.<sup>6</sup> Anti-citrullinated-peptide-antibodies (ACPA) were measured (anti-CCP2; Eurodiagnostica, Arnhem, The Netherlands). After two weeks, when the laboratory results were known, patients

were diagnosed with RA or other diagnoses according to existing classification criteria, blinded to MR findings. RA was classified according to the 1987-criteria; in sub-analyses RA according to the 2010-criteria was also studied as outcome. These cross-sectional data were studied.

From August 2010 until April 2012, 350 patients were included in the EAC. MR imaging was performed in 179 patients based on voluntary participation. The patients with and without MR did not significantly differ in age, sex, symptom duration or ACPA status (data not shown). The study was approved by the local ethical committee. All patients signed informed consent.

### MR imaging

MR imaging of the hand (wrist and metacarpophalangeal joints) and forefoot (metatarsophalangeal joints) was performed within two weeks after inclusion, at the most painful side, or in case of completely symmetric symptoms at the dominant side. The presence of clinical arthritis at physical examination of the joints that were scanned was not a prerequisite. Two patients were excluded because of contraindications for MR imaging. Patients with impaired renal function or known hypersensitivity or allergic reactions to contrast media were imaged without contrast administration ( $n=2$ ).

MR imaging was performed on a MSK-extreme 1.5T extremity MR imaging system (GE, Wisconsin, USA) using a 145 mm coil for the foot and a 100 mm coil for the hand. The patient was positioned in a chair beside the scanner, with the hand or foot fixed in the coil with cushions.

The forefoot was scanned using a T1-weighted fast spin-echo (FSE) sequence in the axial plane with repetition time (TR) of 650 ms, echo time (TE) 17 ms, acquisition matrix, 388×288, echo train length (ETL) 2; and a T2-weighted FSE sequence with frequency selective fat saturation in the axial plane (TR/TE 3000/61.8; acquisition matrix 300×224, ETL 7). Due to time constraints, imaging of the foot was limited to pre-contrast sequences only.

In the hand, the following sequences were acquired before contrast injection: T1-weighted FSE sequence in the coronal plane (TR/TE 650/17 ms; acquisition matrix 388×88; ETL 2); T2-weighted FSE sequence with frequency selective fat saturation in the coronal plane (TR/TE 3000/61.8 ms; acquisition matrix, 300×224, ETL 7). After intravenous injection of gadolinium contrast (gadoteric acid, Guerbet, Paris, France, standard dose of 0.1 mmol/kg) the following sequences were obtained: T1-weighted FSE sequence with frequency selective fat saturation in the coronal plane (TR/TE 650/17 ms, acquisition matrix 364×224, ETL2), T1-weighted FSE sequence with frequency selective fat saturation in the axial plane (TR/TE 570/7 ms; acquisition matrix 320×192; ETL 2).

Field-of-view was 100 mm for the hand and 140 mm for the foot. Coronal sequences had 18 slices with a slice thickness of 2 mm and a slice gap of 0.2 mm. All axial sequences

had a slice thickness of 3 mm and a slice gap of 0.3 mm, with 20 slices for the hand and 16 for the foot. Total imaging time was approximately 75 minutes.

### MR imaging scoring

MR images were scored by two readers (WS and AK), blinded to clinical data. Each reader separately analyzed each set of images and the mean total scores for each feature of both readers were used for further analyses. Synovitis, bone marrow edema and erosions were scored semi-quantitatively according to OMERACT RAMRIS definitions and score. Tenosynovitis in the MCP and wrist joints was evaluated using the method proposed by Haavardsholm et al., with tenosynovitis assessed for the flexor and extensor tendons of each MCP joint at the same 0-3 scale as for the wrist.<sup>7</sup> Tenosynovitis was not assessed in the foot because of the lack of axial images.

Total RAMRIS score was defined as the total of all scores including tenosynovitis. Some joints could not be completely scored due to insufficient image quality (1.1% of all individual scores), in most cases due to incomplete fat suppression or movement artifacts. In these cases values were imputed with the median value for that feature across all joints or bones within the same patient. The inter-reader reliability was assessed by computing the intra-class correlation for total scores of each MR imaging parameter. In addition, a subset of 25 randomly selected MR image sets (14.0%) was scored twice by each reader to determine intra-reader ICC's. Intra-reader ICCs for total RAMRIS-score were 0.98 for reader 1 and 0.83 for reader 2 and inter-reader ICC for total RAMRIS-score was 0.89. For synovitis intra-reader ICCs were 0.93 and 0.64 and inter-reader ICC 0.65, for tenosynovitis 0.91, 0.93 and 0.90, for bone marrow edema 0.96, 0.72 and 0.86 and for erosions 0.89, 0.65 and 0.76 respectively.

### Statistical analysis

The Wilcoxon Rank Sum and Kruskal-Wallis tests were used where appropriate. To evaluate the discriminative ability of MRI the area under the receiver-operating-characteristic-curves (AUC), test characteristics and positive and negative likelihood ratio (LR+, LR-) were assessed. Optimal cut-off points for dichotomization were determined per MRI feature using Youden's method.<sup>8</sup> Analyses were performed using R, version 2.15.0 (R Development Core Team). P-values <0.05 were considered significant.

## RESULTS

### Patient characteristics

Of the 179 patients, 99 were female (55.3%). The median age was 57 years (IQR 20), the median symptom duration 15.4 weeks (IQR 21) and 45 (25.1%) of the patients were

ACPA-positive. Patients were classified according to the following diagnoses: 1987-RA 43 (24.0%), UA 88 (49.2%), inflammatory osteoarthritis 12 (6.7%), psoriatic arthritis 15 (8.4%) and other rheumatic diagnoses 21 (11.7%). The patient characteristics per diagnosis are presented in Table 1.

**Table 1.** Patient characteristics per diagnosis.

| Characteristic                        | RA<br>(n=43) | UA<br>(n=88) | OA<br>(n=12) | PsA<br>(n=15) | Other<br>(n=21) |
|---------------------------------------|--------------|--------------|--------------|---------------|-----------------|
| Age, yrs, median (IQR)                | 59 (24)      | 55 (20)      | 62.5 (9)     | 47.5 (14)     | 52.5 (33)       |
| Sex (women/men)                       | 23/20        | 52/36        | 7/5          | 6/9           | 11/10           |
| Symptom duration, weeks, median (IQR) | 17.3 (28.2)  | 10.7 (20)    | 33.8 (78.5)  | 30.9 (32.9)   | 10.6 (17.3)     |
| Rheumatoid factor positivity, n(%)    | 27 (62.8)    | 21 (23.9)    | 0 (0.0)      | 4 (26.7)      | 2 (9.5)         |
| ACPA positivity, n(%)                 | 21 (48.8)    | 20 (22.7)    | 0 (0.0)      | 3 (20.0)      | 1 (4.8)         |
| CRP, mg/l, median (IQR)               | 8 (19)       | 4 (5)        | 3 (1)        | 4 (10)        | 12 (23)         |
| 66 Swollen joint count, median (IQR)  | 7 (8)        | 2 (3)        | 3 (3)        | 5 (3)         | 2 (4)           |

RA: rheumatoid arthritis according to the 1987 ACR-criteria, UA: undifferentiated arthritis, OA: inflammatory osteoarthritis, PsA: psoriatic arthritis, other: other rheumatic diagnoses including reactive arthritis (n=6), spondylarthropathy (n=3), gout (n=2), pseudogout (1), palindromic arthritis (n=1), paramalignant arthritis (n=1), lyme disease (n=1), systemic lupus erythematosus (n=1) RS3PE (n=1), sarcoidosis (1) and unspecified other (n=3).

### MRI scores per group of diagnoses

The median scores for synovitis, bone marrow edema, erosions and tenosynovitis per joint group are presented in Table 2. Figure 1 depicts the scores for patients with different diagnoses. Scores for synovitis, tenosynovitis and bone marrow edema seemed higher in RA-patients than in early arthritis patients with other diagnoses (Figure 1). Subsequently we tested whether patients with RA had different MR imaging results than patients with other diagnoses. These differences were statistically significant when comparing RA with all patients with other diagnoses. The median scores for RA and other diagnoses were respectively 5.5 and 4.0 for synovitis ( $p=0.003$ ) 3.0 and 1.5 for tenosynovitis ( $p=0.005$ ), and 6.5 and 4.5 for bone marrow edema ( $p=0.038$ ). The erosion scores were not statistically significantly different (4.5 and 3.5 for RA and other diagnoses respectively,  $p=0.15$ ).

### Accuracy of MR imaging in differentiating RA from other diagnoses

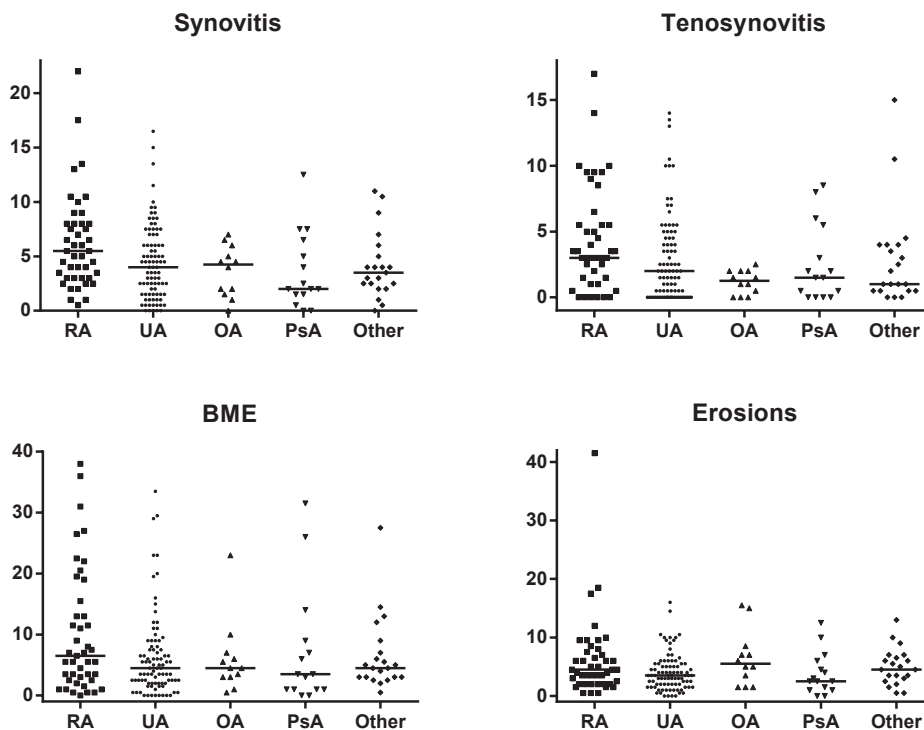
Next the accuracy to differentiate RA from patients with other diagnoses was evaluated by determining the test characteristics and the AUC (Table 2). In the presence of a certain MRI feature, the chance that this patient had RA was low (low positive predictive value). The AUCs of all features were lower than 0.70.

**Table 2.** Median values for the total RAMRIS and the individual features and the diagnostic accuracy to differentiate RA from other diagnoses per MRI feature

|               | Total     | Wrist     | MCP       | MTP       | Sensitivity | Specificity | PPV  | NPV  | LR+  | LR-  | AUC  |
|---------------|-----------|-----------|-----------|-----------|-------------|-------------|------|------|------|------|------|
| Synovitis     | 4.0 (5.0) | 1.5 (3.0) | 1.0 (2.5) | 0.5 (1.0) | 93%         | 27%         | 0.29 | 0.92 | 1.27 | 0.26 | 0.63 |
| Tenosynovitis | 2.0 (4.0) | 1.0 (3.0) | 0.5 (2.0) | n.a.      | 65%         | 63%         | 0.36 | 0.85 | 1.76 | 0.56 | 0.62 |
| BME           | 4.5 (6.5) | 2.0 (5.0) | 0.5 (1.5) | 0.5 (1.5) | 37%         | 84%         | 0.42 | 0.81 | 2.31 | 0.75 | 0.61 |
| Erosions      | 3.5 (4.0) | 2.5 (3.0) | 0.5 (1.0) | 0.5 (1.0) | 40%         | 78%         | 0.36 | 0.64 | 1.82 | 0.77 | 0.60 |

Scores per feature by joint area, median (IQR) values. BME = bone marrow edema. PPV = positive predictive value; NPV = negative predictive value; LR+ = positive likelihood ratio; LR- = negative likelihood ratio; AUC = Area under the curve. The cut-off to dichotomize the scores were 1.75 for synovitis, 2.75 for tenosynovitis, 10.50 for BME and 5.75 for erosions





**Figure 1:** RAMRIS-scores for the different MRI features per group of diagnoses

Horizontal lines represent median values. RA: rheumatoid arthritis according to the 1987 ACR-criteria, UA: undifferentiated arthritis, OA: inflammatory osteoarthritis, PsA: psoriatic arthritis, other: other rheumatic diagnoses including reactive arthritis (n=6), spondylarthropathy (n=3), gout (n=2), pseudogout (1), palindromic arthritis (n=1), paramalignant arthritis (n=1), lyme disease (n=1), systemic lupus erythematosus (n=1) RS3PE (n=1), sarcoidosis (1) and unspecified other (n=3). Total RAMRIS: sum of synovitis, tenosynovitis, BME and erosion scores.

### RA according to the 1987ACR or 2010 ACR/EULAR criteria

We subsequently questioned whether the results would be different when the 2010 criteria would be used to classify RA. Analyses were repeated with 2010-RA as outcome, yielding similar results (Supplementary Figure 1). As many patients classified positive on both criteria sets, we also compared RA-patients that were 1987+/2010+ (n=34), 1987+2010- (n=9) and 1987-/2010+ (n=32) (patients with clear diagnoses other than RA and UA were not included). This showed that 1987-/2010+ patients had lower synovitis scores (median 3.25 versus 6.0,  $p=0.029$ ) than 1987+/2010+ patients (Supplementary Figure 2). No differences were found between 1987+/2010+ and 1987+/2010-RA.

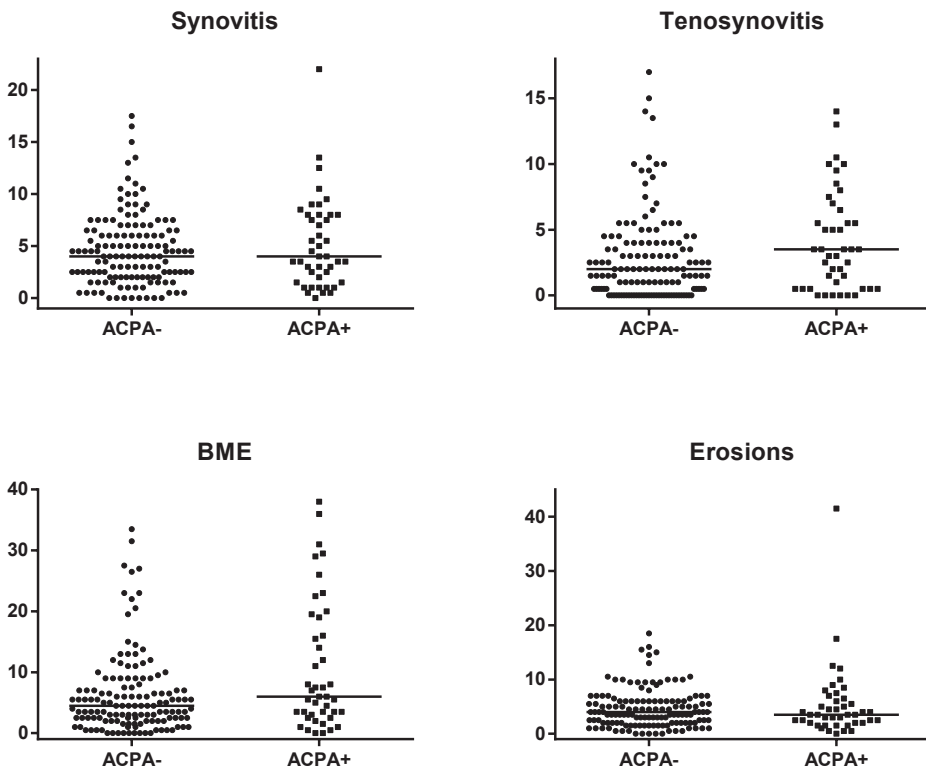


Figure 2: RAMRIS-scores for the different MRI features per group of diagnoses for RA and UA patients with and without ACPA (n=39 and 92 respectively).

Horizontal lines represent median values. For tenosynovitis in the ACPA-negative group many scores are clustered at 0. Synovitis  $p=0.57$ , tenosynovitis  $p=0.40$ , BME  $p=0.017$ , erosions  $p=0.93$ .

### ACPA-positive versus ACPA-negative arthritis

Next we evaluated whether RA or UA-patients (according to the 1987-criteria) with (n=39) or without ACPA (n=92) had differences in scores. ACPA-positive patients showed higher scores for BME (median 6.5) than ACPA-negative patients (median 4.25,  $p=0.016$ ). However, no differences in the extend of synovitis, tenosynovitis and erosions scores were observed (Figure 2).

### Value of hand and foot joints

The RAMRIS is developed for wrists and MCP joints. We also performed MR imaging of the forefoot. When we evaluated the scores of hands and feet separately, it was observed that the scores in the feet were lower (Table 2), but that the distributions of the scores of hands and feet among the different diagnoses were comparable (Supplementary Figure 3). Also

when the test characteristics were determined with and without the feet, similar results were obtained (data not shown).

## DISCUSSION

Many questions remain to be answered before it can be decided whether 1.5T extremity MRI is valuable for use in clinical practice in the field of RA. One of these is a basic question, namely whether the abnormalities seen on MRI are different in patients with RA compared to early arthritis patients with other diagnoses. The present cross-sectional study set out to explore this, making use of an unselected set of early arthritis patients. It was observed that among all patients presenting with early arthritis, patients with RA had significantly higher synovitis, bone marrow edema and tenosynovitis scores than patients without RA, but also that high synovitis, bone marrow edema and tenosynovitis scores were not confined to patients diagnosed with RA. Consequently, the ability of MR imaging to differentiate RA from non-RA patients was low.

In this study we did not focus on the subset of patients with UA. The number of UA-patients was relatively low and follow-up data were not yet available. The definite diagnosis of these patients can be established after 1 or 2 year time. The present study addressed a basic issue by evaluating which differences in MRI features occur between patients with different diagnoses. Although several statistically significant differences were found, RA patients did not have striking differences in the severity of MRI inflammatory scores. Furthermore, in the presence of a certain MRI feature the chance that this patient had RA was low (low positive predictive value). As the undifferentiated arthritis patients group included patients that will go on to develop rheumatoid arthritis and other diagnoses, results may differ when final diagnoses are used to define groups. Particularly, prospective studies are required to determine whether MRI is valuable for classification of patients that are clinically undefined. Follow-up of the studied cohort of patients is currently underway and will be presented in future studies.

Our study has several limitations. The joints scanned are the joint regions that are most commonly involved in RA, also the RAMRIS method was developed for RA. Patients with other diagnoses may have abnormalities in structures that were not scanned or scored, being for instance inflammation in other joints or capsulitis. When a protocol would be developed for use in practice in RA patients, the joints as assessed here will likely be included. Adding other small joints, for instance interphalangeal joints or other structures may possibly enhance the discriminative ability. This is subject for further studies.

One strength of our study was that we scanned MTP joints in addition to the more often assessed wrist and MCP joints. This seems relevant because foot involvement is common in early RA and abnormalities may be found even when the hand MR imaging results are nor-

mal.<sup>9,10</sup> Unfortunately time constraints prohibited the addition of axial and post-contrast imaging of the foot. However the contribution of the foot to total scores was generally low. This was not only true for synovitis, for which the lack of gadolinium contrast might have decreased sensitivity, but also for bone marrow edema and erosions. The MRI features were similarly distributed in hand and foot. Thus findings from this study do not support routine inclusion of MRI of the foot and hand/wrist MRI is probably adequate, however studies with a more complete assessment of the MTP joints including post-contrast imaging are necessary for a more definite recommendation.

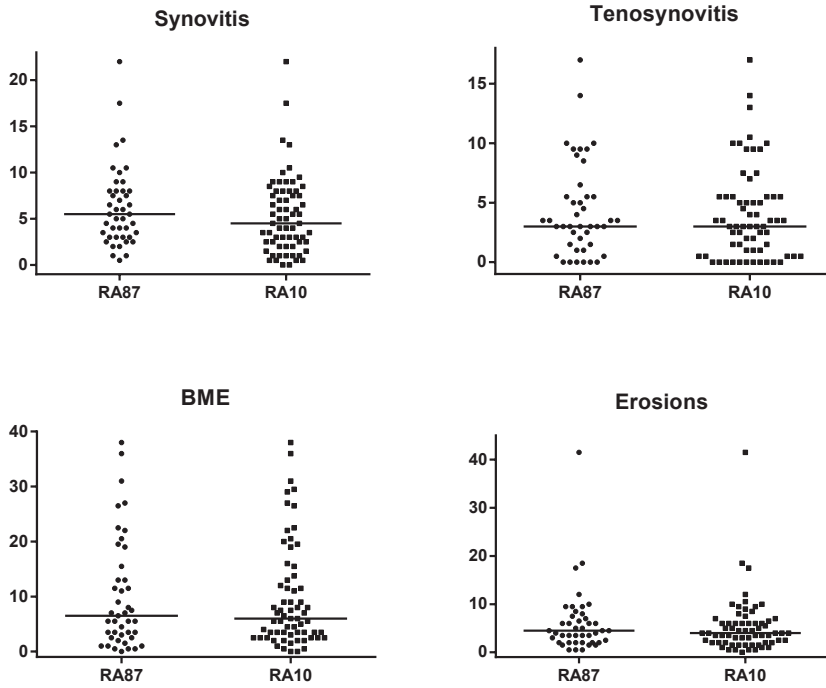
Although many clinical studies have been performed comparing the 1987 and 2010 criteria for RA, to the best of our knowledge no MRI studies on this subject have been published. We observed no difference in MRI scores between RA when classifying RA according to the 1987 ACR-criteria or the 2010ACR/EULAR-criteria. However a majority of patients overlapped between these two groups. When assessing the patients that were positive for both or for one of these sets of criteria separately, we did observe that RA-patients fulfilling 2010 criteria but not the 1987-criteria had less synovitis. These baseline MRI data suggest that patients that only fulfill the 2010-criteria have a milder disease; an observation which is in line with the results of studies comparing the long-term outcome of RA when using the different classification criteria for RA.<sup>11</sup>

Because it has been suggested that ACPA+ and ACPA- disease are separate entities of RA,<sup>12</sup> we performed stratified analyses. ACPA-positive patients had significantly more BME than ACPA-negative patients. As BME is a predictor for progression of joint destruction,<sup>3</sup> this observation is in line with ACPA-positive RA being a more severe disease. Only one earlier study has explored the relation between ACPA and BME, also reporting a significantly higher proportion of patients with BME in the ACPA+ group.<sup>13</sup> Furthermore, subclinical inflammation including bone marrow edema has been observed in ACPA positive arthralgia patients (although no ACPA- control group was present in that study).<sup>14</sup> This observation also relates to the recent observation that ACPA may be able to directly activate osteoclasts.<sup>15</sup> Altogether these data support the use of MRI to further increase the understanding of the relation between these two risk markers for severe RA, as MRI is the only imaging modality able to show BME.

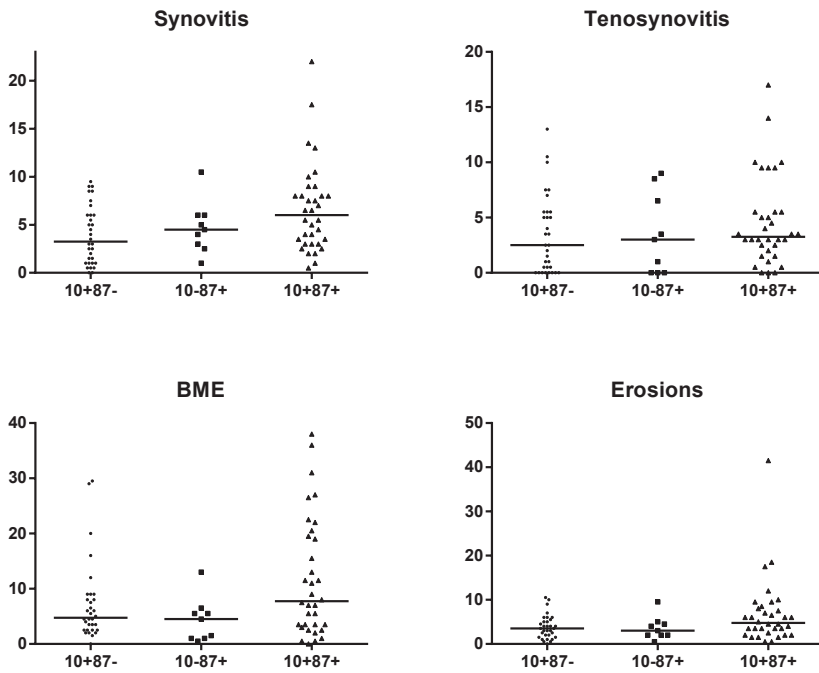
In conclusion, MRI inflammatory scores were higher in RA than in other diagnoses and ACPA-positive patients had more BME than ACPA-negative patients. Nonetheless, the severity of MRI-inflammation assessed according to RAMRIS does not accurately differentiate patients fitting ACR criteria for RA at one time point from other early arthritis patients.

## REFERENCE LIST

1. Van Nies JA, Krabben A, Schoones JW, et al. What is the evidence for the presence of a therapeutic window of opportunity in rheumatoid arthritis? A systematic literature review. *Ann Rheum Dis* 2013.
2. McQueen FM, Benton N, Perry D, et al. Bone edema scored on magnetic resonance imaging scans of the dominant carpus at presentation predicts radiographic joint damage of the hands and feet six years later in patients with rheumatoid arthritis. *Arthritis Rheum* 2003;48:1814–1827.
3. Colebatch AN, Edwards CJ, Ostergaard M, et al. EULAR recommendations for the use of imaging of the joints in the clinical management of rheumatoid arthritis. *Ann Rheum Dis* 2013.
4. Suter LG, Fraenkel L, Braithwaite RS. Role of magnetic resonance imaging in the diagnosis and prognosis of rheumatoid arthritis. *Arthritis Care Res* 2011;63:675–688.
5. Tamai M, Kawakami A, Uetani M, et al. A prediction rule for disease outcome in patients with undifferentiated arthritis using magnetic resonance imaging of the wrists and finger joints and serologic autoantibodies. *Arthritis Rheum* 2009;61:772–778.
6. De Rooy DP, van der Linden MP, Knevel R, et al. Predicting arthritis outcomes—what can be learned from the Leiden Early Arthritis Clinic? *Rheumatol Oxf Engl* 2011;50:93–100.
7. Haavardsholm EA, Østergaard M, Ejbjerg BJ, et al. Introduction of a novel magnetic resonance imaging tenosynovitis score for rheumatoid arthritis: reliability in a multireader longitudinal study. *Ann Rheum Dis* 2007;66:1216–1220.
8. Fluss R, Faraggi D, Reiser B. Estimation of the Youden Index and its associated cutoff point. *Biom J Biom Z* 2005;47:458–472.
9. Calisir C, Murat Aynaci AI, Korkmaz C. The accuracy of magnetic resonance imaging of the hands and feet in the diagnosis of early rheumatoid arthritis. *Jt Bone Spine Rev Rheum* 2007;74:362–367.
10. Ostendorf B, Scherer A, Mödder U, et al. Diagnostic value of magnetic resonance imaging of the forefeet in early rheumatoid arthritis when findings on imaging of the metacarpophalangeal joints of the hands remain normal. *Arthritis Rheum* 2004;50:2094–2102.
11. Burgers LE, van Nies JA, Ho LY, et al. Long-term outcome of Rheumatoid Arthritis defined according to the 2010-classification criteria. *Ann Rheum Dis* 2013.
12. Skogh T. Does a positive anti-CCP test identify a distinct arthritis entity? *Arthritis Res Ther* 2005;7:230–232.
13. Tamai M, Kawakami A, Uetani M, et al. The presence of anti-cyclic citrullinated peptide antibody is associated with magnetic resonance imaging detection of bone marrow oedema in early stage rheumatoid arthritis. *Ann Rheum Dis* 2006;65:133–134.
14. Krabben A, Stomp W, van der Heijde DM, et al. MRI of hand and foot joints of patients with anticitrullinated peptide antibody positive arthralgia without clinical arthritis. *Ann Rheum Dis* 2013;72:1540–1544.
15. Harre U, Georgess D, Bang H, et al. Induction of osteoclastogenesis and bone loss by human autoantibodies against citrullinated vimentin. *J Clin Invest* 2012;122:1791–1802.

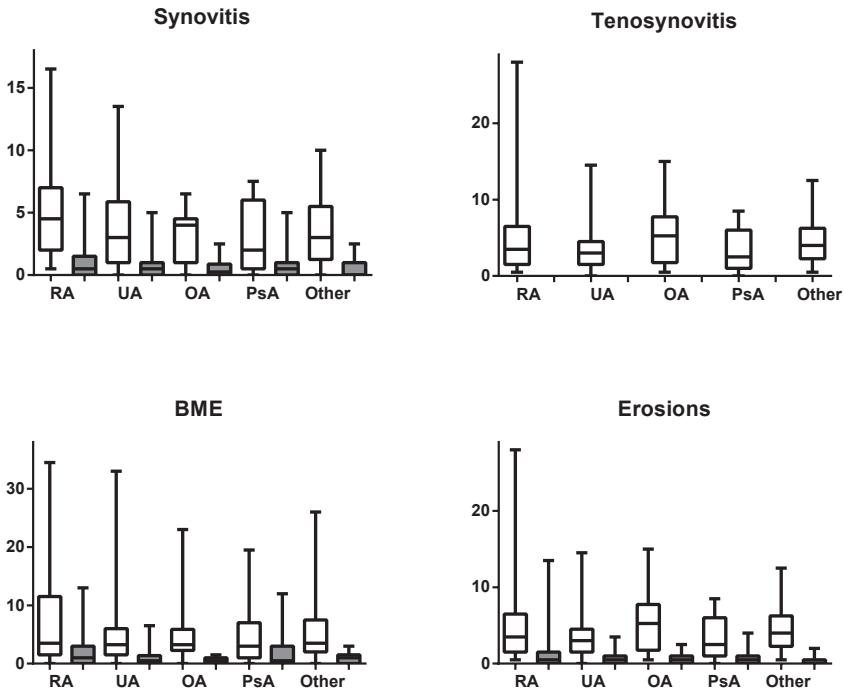


Supplementary Figure 1: RAMRIS-scores for the different MRI features for RA patients according to 1987 and 2010 criteria  
Horizontal lines represent median values.



**Supplementary Figure 2:** RAMRIS-scores for the different MRI features for RA patients fulfilling both the 1987 and 2010 criteria and one of these two sets of criteria.

Horizontal lines represent median values. 1987-/2010+ versus 1987+/2010+ patients: synovitis  $p=0.029$ . All other combinations  $p>0.05$ .



**Supplementary Figure 3:** RAMRIS-scores for the different MRI features per group of diagnoses, separated for hand and foot joints

Box and whisker plots showing median, interquartile and range of scores separately for the hand (wrist and MCP joints combined, white) and forefoot (grey). Tenosynovitis was only assessed in the hand.



