



Universiteit
Leiden
The Netherlands

Giant cell tumor of bone and tenosynovial tissue : surgical outcome

Heijden, L. van der

Citation

Heijden, L. van der. (2014, September 4). *Giant cell tumor of bone and tenosynovial tissue : surgical outcome*. Retrieved from <https://hdl.handle.net/1887/28526>

Version: Corrected Publisher's Version

License: [Licence agreement concerning inclusion of doctoral thesis in the Institutional Repository of the University of Leiden](#)

Downloaded from: <https://hdl.handle.net/1887/28526>

Note: To cite this publication please use the final published version (if applicable).

Cover Page



Universiteit Leiden

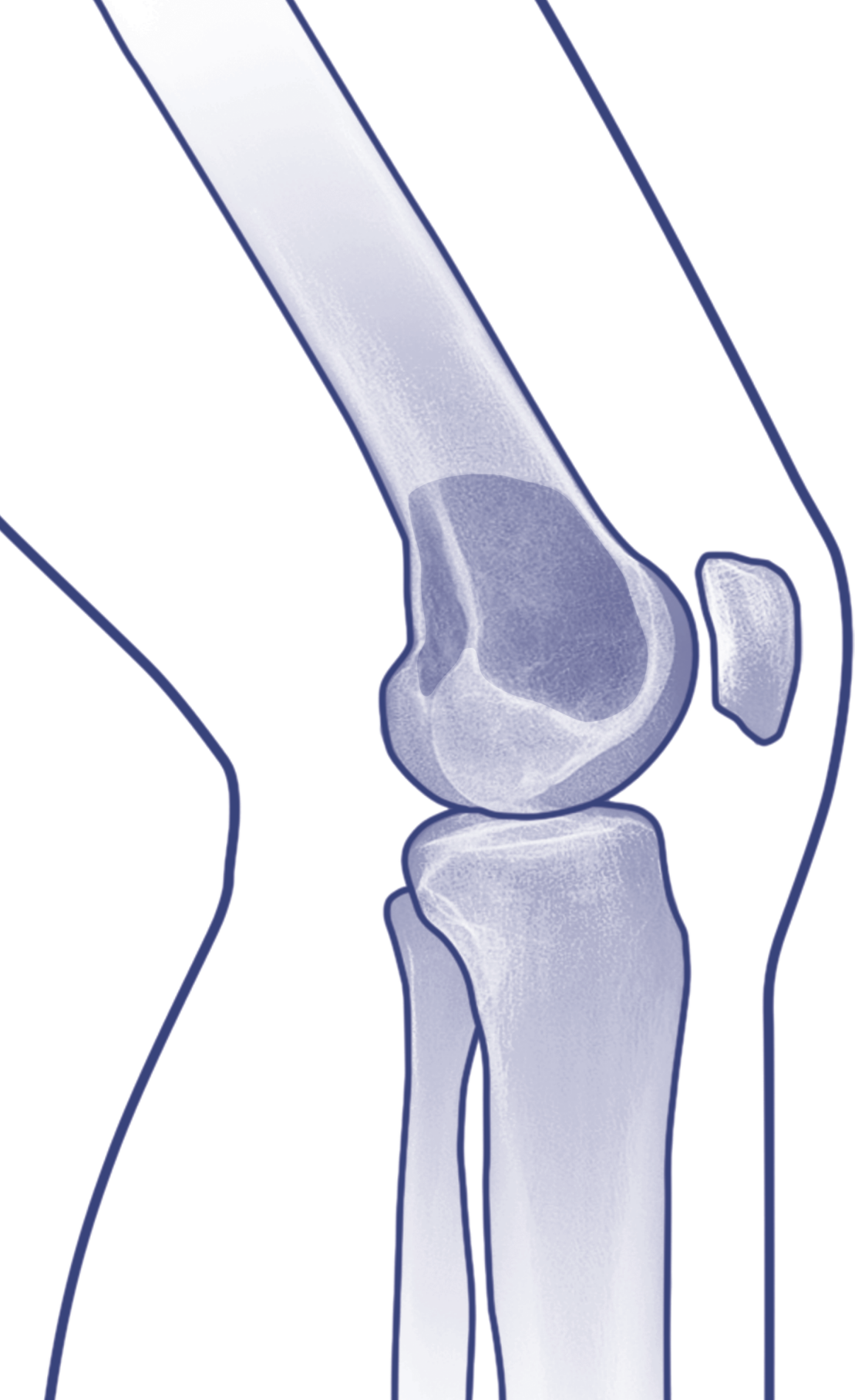


The handle <http://hdl.handle.net/1887/28526> holds various files of this Leiden University dissertation.

Author: Heijden, Lizz van der

Title: Giant cell tumor of bone and tenosynovial tissue : surgical outcome

Issue Date: 2014-09-04



Chapter 12

General summary

General summary

Patients with giant cell tumor of bone and tenosynovial tissue pose challenging problems for surgical treatment. For giant cell tumor of bone (GCTB), the clinical challenge is to extend indications for intralesional excision, while providing optimal oncological, functional and quality of life results. For tenosynovial giant cell tumor (Dt-GCT), the clinical challenge is to improve oncological results and maintain a functional joint and quality of life. Therefore, the aims of this thesis were to improve patient selection for different types of surgery by identifying risk factors for recurrences and complications, to define indications for systemic targeted therapy and to evaluate clinical outcome after treatment for both diseases by providing a clinical decision analysis based on outcome data.

Giant cell tumor of bone

Chapter 2 provided an overview of imaging, genetics, histopathology and multidisciplinary treatment of GCTB. Overexpression of receptor activator of nuclear factor kappa-B ligand (RANKL) by mononuclear neoplastic stromal cells promotes recruitment of numerous reactive multinucleated giant cells capable of bone resorption. Radiologically, GCTB shows typical eccentric lytic lesions. Computed tomography can be performed to assess cortical thinning, pathologic fractures and (pending) joint involvement. MR imaging is required to evaluate extent of GCTB within the bone and surrounding soft tissues for surgical planning. MR imaging typically shows low to intermediate intensity on T1-weighted images and intermediate to high signal intensity on T2-weighted images. The preferred treatment for the majority of GCTB is extended curettage with local adjuvants. A large oval window is made in the cortex, creating sufficient exposure of the tumor cavity. The tumor is then carefully curetted with different sizes curettes followed by high-speed burring of cavity walls. Local adjuvants can be phenol, alcohol or liquid nitrogen. The remaining cavity may be filled with either bone grafts or polymethylmethacrylate (PMMA); advantages of the latter are a hypothesized lower recurrence risk through hyperthermic properties, immediate mechanical support and early radiographic detection of local recurrences. Reported recurrence rates are

comparable for different local adjuvants (27-31%); most recurrences occur within two years after surgery. Resection can be performed when joint salvage is not feasible and in expandable bones. Denosumab (RANKL-inhibitor) blocks and zoledronic acid (bisphosphonate) inhibits GCTB-derived osteoclast resorption. With zoledronic acid, stabilization of local and metastatic disease has been reported, although level of evidence was low. Denosumab has been studied to a larger extent and seems to be effective in enabling less invasive forms of surgery. Denosumab was recently registered by the FDA for unresectable disease. Therefore, the role of systemic therapy in standard treatment of GCTB needs to be further explored. Moderate dose radiotherapy should be restricted to rare cases of unresectable, residual or recurrent GCTB when surgery would lead to unacceptable morbidity.

Chapter 3 compared the relative effectiveness of several local adjuvants in a retrospective cohort study in two tertiary referral centers in which different standard treatments are applied. Treatment assignment depended purely on the center patients were admitted to and both centers had similar indications for intralesional surgery and comparable surgical expertise (i.e. pseudo-randomization). Thus, 132 patients with primary GCTB who underwent either curettage with phenol and PMMA (P-PMMA; n=82), liquid nitrogen and PMMA (LN-PMMA; n=26) or liquid nitrogen and bone grafts (LN-BG; n=24) between 1990 and 2010 were retrospectively analyzed. Mean follow-up was 8 years (range 2 to 22). The three cohorts were comparable, except for tumor localization: bone grafts were more commonly applied instead of PMMA in non-weightbearing bones in the center specialized in cryosurgery. Recurrence rates were comparable for P-PMMA (28%; 23/82), LN-PMMA (31%; 8/26) and LN-BG (38%; 9/24) ($p=0.52$). Soft tissue extension increased risk for recurrence two-fold. When using liquid nitrogen, attention should be paid to the complication risk, as this was increased after LN-BG (33%; 8/24) and LN-PMMA (27%; 7/26) compared with P-PMMA (11%; 9/82) ($p=0.019$). In addition, preoperative pathologic fractures increased risk for complications four-fold. Functional outcome was excellent and comparable in all three cohorts ($p=0.52$).

Approximately 20% of patients with GCTB present with a pathologic fracture, which may impede adequate intralesional surgery. **Chapter 4** involved a retrospective multicenter analysis of 48 patients with a pathologic fracture, treated with curettage plus adjuvants (n=23) or *en bloc* resection (n=25) in one of three tertiary referral centers between 1981 and 2009. Mean follow-up was

8.4 years (range 2.3 to 24). Local recurrence rate was higher after intralesional surgery (30%; 7/23) compared with *en bloc* resection (0%) and was five-fold increased in patients with soft tissue extension. Complication rate was lower after intralesional surgery (4%; 1/23) compared with resection (16%; 4/25). Fracture healing after curettage occurred in all but one patient. Functional outcome was superior after intralesional surgery.

Approximately 2-5% of all GCTB occur in the small bones of the hands and feet. **Chapter 5** described a systematic review including twelve papers comprising a total of 91 patients with GCTB of the small bones. Published mean recurrence rates were 72% after curettage, 13% after curettage with local adjuvants, 15% after resection and 10% after amputation. Second, a retrospective multicenter analysis was performed of all 30 patients treated for GCTB of the small bones in one of five tertiary referral centers between 1987 and 2010. Mean follow-up was 7.9 years (range 2 to 26). Recurrence rates were 50% after curettage (3/6), 22% after curettage with adjuvants (4/18) and 17% after *en bloc* resection (1/6; $p=0.40$). No individual factors associated with a higher risk of recurrence or complication could be identified. Functional outcome was superior after intralesional surgery compared with resection. Repeated curettage and adjuvants finally resulted in cure of all patients.

Around 2-8% of all GCTB are localized in the sacrum. **Chapter 6** contained a nationwide retrospective evaluation of all 26 patients surgically treated for sacral GCTB in the Netherlands between 1990 and 2010. The majority of our patients had cortical destruction, large soft tissue components and sacral nerve root involvement at presentation. Preoperative selective arterial embolization was performed in nineteen patients. All patients underwent intralesional excision of which 21 with different local adjuvants, systemic therapy or adjuvant radiotherapy. In eight patients with extensive cortical destruction and soft tissue masses, no chemical adjuvants were used. Surgical margins were extended in four patients with anterior sacral wall excision. Posterior stabilization with lumbopelvic fixation with PMMA or bone grafts was indicated in three patients, reconstruction with bone grafts in seven and with PMMA in one. All but one patient had a minimum follow-up of two years (mean 8.3; range 0.5 to 19). Two patients died from tumor progression and metastases and one died from radiation-induced sarcoma (after 6-102 months). Overall recurrence rate was 54% (14/26). Soft tissue masses larger than 10 cm increased the risk for recurrence three-fold. Complications were reported in 46% (12/26) patients

and included massive hemorrhage, infection, neuropraxia, hardware failure, radiation-induced sarcoma, radiation-induced menopause, pubic dissociation fracture due to osteopenia after radiotherapy and delayed wound healing. Functional outcome in patients without complications was good. In eight patients, all preoperative symptoms resolved after surgery. Persistent pain was reported by eight patients. Neurological symptoms were transient in eight and permanent in five patients. Recurrence rate was highest after curettage alone (80%; 4/5), indicating that some kind of local or systemic adjuvant treatment is necessary.

Chapter 7 aimed at retrospectively analyzing individual risk factors for recurrence in 93 patients treated with curettage, phenol and PMMA (n=75) or curettage with PMMA (n=18) in one tertiary referral center between 1981 and 2009. Mean follow-up was 8 years (range 2 to 24). Twenty-five patients had recurrent GCTB (27%). Seventeen patients were disease free after second curettage with adjuvants and eight patients eventually required *en bloc* resection. We found a five-fold increased risk for recurrence in presence of soft tissue extension, whereas age, gender, localization and pathologic fracture did not increase recurrence risk.

Chapter 8 was a radiological study on the prevalence and impact of radiological osteoarthritis (Kellgren and Lawrence grades 3-4) in 53 patients who underwent curettage and PMMA for GCTB around the knee in one tertiary referral center between 1987 and 2007. Mean follow-up was 7 years (range 5 to 24). Radiological osteoarthritis was found in 17% of patients at a median of 57 months (range 33-285) after curettage and PMMA. None of these patients had surgery for clinical osteoarthritis at latest follow-up. A nine-fold increased risk for radiological osteoarthritis was found when more than 70% of subchondral bone was involved by GCTB and a four-fold increased risk for radiological osteoarthritis for a distance between GCTB and the articular cartilage of less than 3 mm. Functional outcome and quality of life were comparable for patients with Kellgren and Lawrence grades 3-4 and 0-2, suggesting modest clinical impact of radiological osteoarthritis at intermediate follow-up. However, this may increase with time and a prolonged follow-up is required.

Giant cell tumor of tenosynovial tissue

Chapter 9 outlined an overview of imaging, genetics, histopathology and multidisciplinary treatment of localized (GCT-TS) and diffuse type (Dt-GCT) tenosynovial giant cell tumor. Overexpression of macrophage colony-stimulating factor 1 (M-CSF) and its receptor (M-CSFR) by synovial fibroblasts promotes formation of a tumor-like mass. On MR images, hemosiderin depositions cause local changes in susceptibility, resulting in the characteristic low signal intensity appearance of Dt-GCT on T1- and T2-weighted spin echo and gradient echo sequences. Although arthroscopic synovectomy has been advocated as an alternative to open synovectomy, there is a significant risk of inadequate excision and recurrence, particularly in the posterior knee compartment. In addition, there is a risk of seeding the disease into the soft tissues around the portals. For GCT-TS or limited anterior Dt-GCT, arthroscopic synovectomy may be sufficient. For initial and recurrent Dt-GCT, especially in the posterior knee compartment, open synovectomy is advised. Combined or staged surgery may be considered. For posterior disease, a lazy-S incision is performed with elevation of the origin of the gastrocnemius muscle to protect neurovascular structures. This is followed by arthrotomy to visualize the posterior cruciate ligament and articular surfaces and a complete capsulotomy to achieve adequate synovectomy. For anterior disease, a midline anterior approach is advised, as this allows good visualization of the synovial cavity, fat pad, cruciate and collateral ligaments. Residual tumor adjacent to the joint line and unilateral gutters can also be safely resected. For recurrent and extra-articular disease, moderate dose radiotherapy or systemic targeted therapy can be considered. Although there is yet little evidence on the efficacy of neoadjuvant M-CSFR-targeted tyrosine kinase inhibitors (e.g. imatinib) for Dt-GCT treatment, it may in the future be incorporated in the treatment strategy for more extended disease, in analogy with systemic treatment for GCTB.

Chapter 10 presented a systematic review on tenosynovial giant cell tumor including 59 papers comprising a total of 313 patients with GCT-TS and 777 patients with Dt-GCT. Methodological quality (Newcastle-Ottawa Scale for quality assessment of cohort studies) was good in 40%, intermediate in 50% and poor in 10% of the included papers. Reported mean recurrence rates were 4% after open and 6% after arthroscopic synovectomy of GCT-TS in the knee and 14% after open and 40% after arthroscopic synovectomy of Dt-GCT in the

knee. With use of intra-articular radioactive colloids, mean recurrence rates were 15% after open and 22% after arthroscopic synovectomy for intra-articular Dt-GCT in the knee and hip. With adjuvant radiotherapy, mean recurrence rates were 12% after open and 13% after arthroscopic synovectomy for extra-articular Dt-GCT in the knee. In general, open synovectomy of the lesion plus excision of extra-articular disease is recommended to reduce the relatively high recurrence risk.

Chapter 11 retrospectively evaluated the influence of disease severity and type of surgery on functional outcome and quality of life in 30 patients treated for Dt-GCT in the knee between 1980 and 2011. Fifteen patients were primarily treated at our tertiary referral center; 15 were referred to our center with recurrence. Disease severity was assessed on preoperative MR imaging or imaging reports. Sixteen patients (53%) had simple disease, defined as a solitary pedunculated lesion or diffuse involvement of the anterior or posterior knee compartment. Fourteen patients (47%) had severe disease, defined as involvement of anterior and posterior compartments or extra-articular extension. Patients with initially severe Dt-GCT often underwent multiple surgeries including initial arthroscopic synovectomy and open synovectomy for latest recurrence. After a mean follow-up of 8 years (range 2-33), these patients reported significantly lower functional and quality of life results. In this study, primary open synovectomy did not result in impaired function or decreased quality of life when compared to arthroscopic synovectomy.

Conclusions, clinical implications and future perspectives for the subjects of this thesis are discussed in **Chapter 13**.