



Universiteit
Leiden
The Netherlands

Massive deep-frozen bone allografts : contamination, immunogenicity and clinical use

Deijkers, Ruud

Citation

Deijkers, R. (2005, January 18). *Massive deep-frozen bone allografts : contamination, immunogenicity and clinical use*. Retrieved from <https://hdl.handle.net/1887/3765>

Version: Corrected Publisher's Version

License: [Licence agreement concerning inclusion of doctoral thesis in the Institutional Repository of the University of Leiden](#)

Downloaded from: <https://hdl.handle.net/1887/3765>

Note: To cite this publication please use the final published version (if applicable).

Hemicortical allograft reconstruction after resection of low-grade malignant bone tumours

R.L.M. Deijkers*†, R.M. Bloem*, P.C.W. Hoogendoorn‡, J.J. Verlaan*,
H.M. Kroon¶, A.H.M. Taminiau*

From Leiden University Medical Center, Leiden, The Netherlands

* Department of Orthopaedic Surgery, Leiden University Medical Center

† Department of Orthopaedic Surgery, Reinier de Graaf Group

‡ Department of Pathology, Leiden University Medical Center

¶ Department of Radiology, Leiden University Medical Center

ABSTRACT

Low-grade surface tumours of bone may theoretically be treated by hemicortical resection, retaining part of the circumference of the cortex. An inlay allograft may be used to reconstruct the defect. Since 1988 we have performed 22 hemicortical procedures in selected patients with low-grade parosteal osteosarcoma (6), peripheral chondrosarcoma (6) and adamantinoma (10). Restricted medullary involvement was not a contraindication for this procedure.

There was no evidence of local recurrence or distant metastasis at a mean follow-up of 64 months (27 to 135). Wide resection margins were obtained in 19 patients. All allografts incorporated completely and there were no fractures or infections. Fractures of the remaining hemicortex occurred in six patients and were managed successfully by casts or by osteosynthesis. The functional results were excellent or good in all except one patient.

Hemicortical procedures for selected cases of low-grade surface tumours give excellent oncological and functional outcomes. There was complete remodelling and fewer complications when compared with larger intercalary procedures. The surgery is technically demanding but gives good clinical results.

INTRODUCTION

Advances in MRI¹⁻³ and histological and molecular pathology^{4,5} have dramatically improved the diagnosis and staging of bone tumours. The sensitivity of MRI to determine the extent of a tumour makes wide resection possible without unnecessary removal of normal bone. The indications for such 'limited' wide resection have not been determined.

Wide *en-bloc* resection while retaining part of the cortical circumference should be possible for low-grade surface tumours of bone. We believe that this so-called hemicylindrical or hemicortical resection may be used in selected cases of low-grade parosteal osteosarcoma, peripheral chondrosarcoma and adamantinoma. In contrast to previous reports,⁶⁻⁸ we believe that medullary involvement does not always necessitate resection of an intercalary segment in order to achieve a wide surgical margin. Recently, hemicortical resection for parosteal osteosarcoma has been described.⁹ We now add our experience of hemicortical resection for peripheral chondrosarcoma and adamantinoma.

It should be possible to tailor an inlay allograft precisely to reconstruct a hemicortical defect. Because of the limited soft-tissue dissection and the large contact area with the patient's own bone an excellent environment for the allograft is provided. Due to this, more complete remodelling and fewer graft complications, as compared with larger intercalary allograft reconstruction, may occur.

We describe our medium-term clinical results with such hemicortical procedures for selected cases of low-grade malignant bone tumours and have analysed the oncological and allograft outcome to determine the efficacy and safety of this technique.

PATIENTS AND METHODS

Between 1989 and 1999, 22 patients with low-grade malignant surface bone tumours had a reconstruction using an inlay allograft after *en-bloc* resection (Table I). The mean follow-up period was 64 months (27 to 135). There were 12 men and ten women with a median age at the time of surgery of 22 years (16 to 60), with six low-grade parosteal osteosarcomas, six low-grade peripheral chondrosarcomas, and ten adamantinomas. All the parosteal osteosarcomas were located in the distal femur and all adamantinomas in the tibia. The peripheral chondrosarcomas, which arise

within an osteochondroma⁴ were located in the proximal humerus (2), the proximal femur (2) and the distal femur (2).

Local preoperative staging of the tumour was done using plain radiography and MRI with T1- and T2-weighted sequences and contrast-enhanced series with gadolinium.¹⁻³ Distant metastases were sought using plain radiography and CT of the lungs, and bone scintigraphy. The nature of the tumour was established by histological examination of a biopsy and definitive staging by examination of the resected specimen. All resected specimens were sliced on a diamond-band saw (Exact Apparatebau, Norderstedt, Germany), in planes corresponding to the MR images and

sections were made for tumour typing and assessment of surgical margins.

All tumours were low grade (stage I).¹⁰ Since the three selected types of tumour originated from different compartments, different criteria for extracompartmental involvement (stage IB) were used.¹⁰ For parosteal osteosarcoma and peripheral chondrosarcoma, spread from the parosteal compartment was recognised by invasion of the medullary canal or penetration of soft-tissue structures. For adamantinoma, cortical destruction with subperiosteal bulging in the soft tissues and medullary invasion were indicative of extracompartmental involvement.

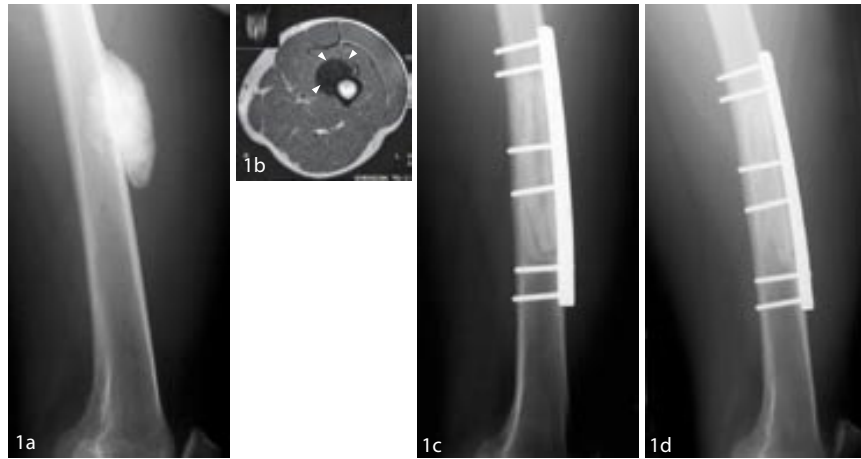
Table 1. Details of the 22 patients with hemicortical resection and reconstruction

Case	Age (yrs)	Gender	Tumour*	Stage†	Site	Length (cm)	Surgical Margin‡	Graft Fixation	Follow-up (mths)	Reconstruction Complications	MSTS score
1	31	F	CS	IA	Humerus	12	m-st	Screws	135	No	29
2	18	M	POS	IA	Femur dist	14	w	Screws	117	No	30
3	28	F	AD	IA	Tibia	9	w	Press- Fit	115	No	23
4	20	F	AD	IB	Tibia	7	w	Screws	84	Sympathetic dystrophy of legs and arms after 2 yrs	-
5	17	F	AD	IA	Tibia	15	w	Screws	84	No	30
6	46	M	POS	IB	Femur	11	m-st	Plate	75	No	26
7	32	M	POS	IB	Femur dist	13	m-st	Screws	72	Intra-operative fracture host bone (→ screws); Fixation failure at 1 mth (→ plate); Fixation failure at 17 mth (→ new plate)	9
8	37	F	AD	IB	Tibia	8	w	Screws	69	Fracture host bone at 1 mth (→ conservative)	29
9	16	F	CS	IB	Humerus	7	m-b	Screws	65	No	30
10	39	M	CS	IA	Femur prox	11	w	Cerclage	64	Fracture host bone at first day (→ plate and screws)	26
11	34	F	POS	IB	Femur dist	7	w	Plate	64	No	30
12	60	M	CS	IA	Femur dist	14	m-st	Plate	56	No	30
13	19	F	AD	IB	Tibia	10	m-b	Screws	51	Intra-operative fissure host bone (→ initially conservative, at 5 mth → plate)	21
14	19	M	AD	IA	Tibia	14	w	Plate	48	Intra-operative fracture host bone (→ plate)	28
15	29	F	AD	IA	Tibia	6	w	Screws	46	No	30
16	22	F	AD	IA	Tibia	12	w	Screws	45	No	26
17	22	F	AD	IA	Tibia	20	w	Screws	43	No	21
18	15	M	AD	IA	Tibia	14	m-b	Screws	43	No	29
19	25	M	POS	IB	Femur dist	9	m-st	Screws	33	Fracture host bone at 13 days (→ plate)	27
20	21	M	CS	IA	Femur prox	10	w	Plate	33	No	26
21	21	M	CS	IB	Femur dist	7	m-st	Screws	31	No	28
22	23	F	POS	IA	Femur dist	9	m-st	Screws	27	No	24

* POS = parosteal osteosarcoma; CS = chondrosarcoma; AD = adamantinoma

† according to MSTS

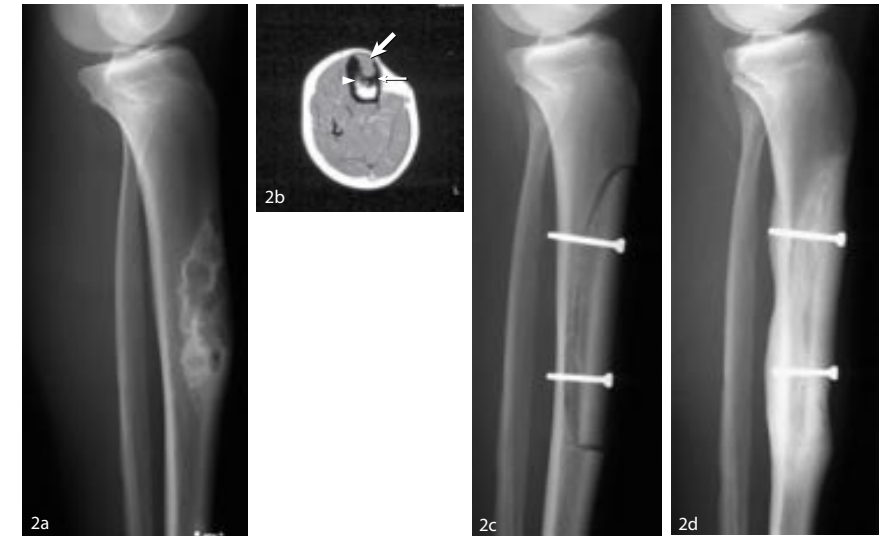‡ w = wide; m-st = marginal in soft-tissue; m-b = marginal in bone



Figures 1a-d. Case 6. A 46-year-old man with a parosteal osteosarcoma of the femur. 1a – Preoperative radiograph. Figure 1b – Preoperative axial T1-weighted MR scan showing predominantly low signal intensity from the parosteal osteosarcoma arising from the anterior cortex of the femur (arrowheads). About 40% of the circumferential cortex is involved. There is relatively ill-defined delineation from the surrounding soft tissue (the final histological examination showed microscopic invasion into the soft tissues) and no indication of the medullary involvement. Figure 1c – initial postoperative radiograph showing reconstruction with a fitted inlay allograft and plate fixation. Figure 1d – Radiograph showing complete union at 16 months.

The sites of resection and osteotomy were determined on the basis of preoperative MRI (Figs 1 to 3). Frozen sections were analysed if there was a close or questionable surgical margin as assessed at operation. Additional bone was resected in one patient because residual tumour tissue was seen in the medulla, and confirmed on frozen sections (case 9). The mean length of resected bone was 10.9 cm (6 to 26). The extent of the circumferential resection varied between 50% and 80%. In two patients (cases 13 and 18) the resection included the inner part of the opposing cortex, because of extensive medullary involvement (Fig. 3).

The defects were reconstructed using fresh, deep-frozen inlay allografts. They were retrieved and preserved according to the guidelines of the American Association of Tissue Banks and the European Association of

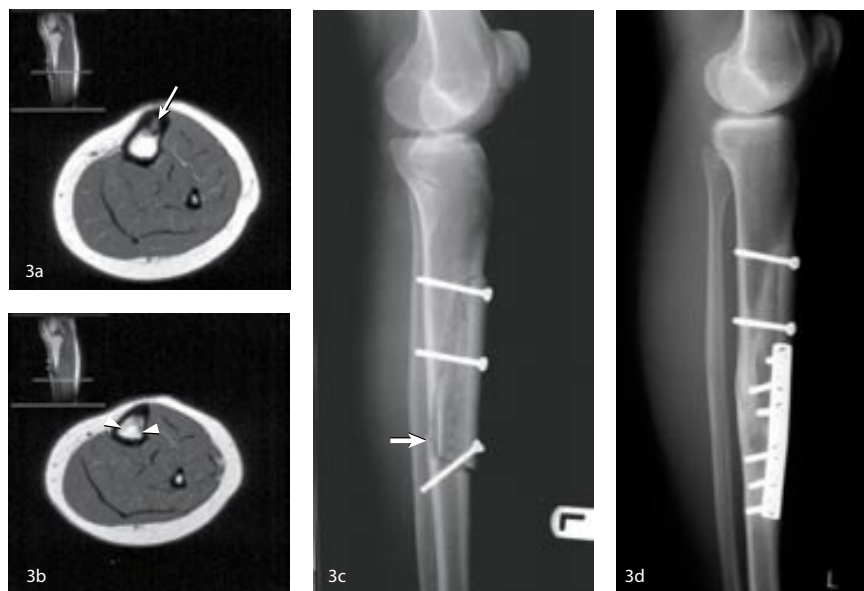

Figures 2a-d. Case 5. A 17-year-old girl with an adamantinoma of the tibia. Figure 2a – Preoperative lateral radiograph. Figure 2b – Preoperative axial T1-weighted MR scan showing intermediate signal intensity from the centre of the tumour (large arrow), low signal intensity from the sclerotic ridge (small arrow) and medullary involvement (arrowhead). Figure 2c – Postoperative radiograph showing reconstruction with a fitted inlay allograft and fixation with screws. Figure 2d – radiograph at 84 months showing incorporation and hypertrophy of the remaining hemicortex.

Musculoskeletal Transplantation, and were stored at -80°C .¹¹ The grafts were not irradiated.

Each graft was meticulously cut to fit the defect precisely, and was secured by lag screws, cerclage wires or a neutralisation plate (Figs 1c and 2c). In one patient no osteosynthesis was needed since the allograft was press-fitted into the defect. We preferred the minimal use of fixation material to avoid interference with radiological and MR evaluation of potential local recurrences. Allogenic and autogenous cancellous bone was placed and impacted in the medullary cavity beneath the allograft.

Postoperatively, the limb was immobilised in a cast or brace until radiological union was demonstrated. Partial weight-bearing was started when there appeared to be at least 50% union of the transverse and longi-



Figures 3a-d. Case 13. A 17-year-old girl with an adamantinoma involving 80% of the circumferential cortex. Figure 3a – Preoperative axial T1 – weighted MR image of the tibia showing the tumour arising from the anterior cortex (arrow) with intermediate signal intensity in the centre and low signal intensity from the surrounding sclerotic border. Figure 3b – MR scan distal to the centre of the tumour, showing extensive horse-shoe-shaped medullary involvement (arrowheads) extending close to the dorsal cortex of the tibia. Resection of more than 80% of the circumferential cortex was needed to obtain wide margins. Figure 3c – Postoperative radiograph showing reconstruction with a fitted inlay allograft and fixation by a lag screw. Distally, where less than 20% of the cortical circumference remained, a fracture occurred (arrow). Figure 3d – Radiograph at 51 months after plate fixation of the distal fracture showing incorporation of the allograft beneath the plate. There is hypertrophy of the remaining hemicortex at the site of the fracture.

tudinal osteotomies. Plain radiographs of the primary site and of the chest were taken every three to four months for the first two years and at least yearly thereafter to evaluate potential recurrence and distant metastases.

Radiological features of the allograft-to-host union were estimated according to the criteria of the International Symposium on Limb Salvage.¹²

Functional analysis of all patients was assessed at final follow-up using the revised 30-point functional evaluation system of the Musculoskeletal Tumor Society (MSTS).¹³ This system assigns numerical values (0 to 5) for each of six categories of pain, function, emotional acceptance in both the upper and lower limb, support, walking and gait in the lower limb or hand positioning, dexterity and lifting and lifting ability in the upper limb.

RESULTS

The resection margins were judged to be wide in 12 specimens and marginal in ten (Table I). Marginal resections, through apparently tumour-free but reactive tissue, occurred in four of six chondrosarcomas (3 in soft tissue and 1 in bone), four of six parosteal osteosarcomas (all in soft tissue) and two of ten adamantinomas (both in bone).

Marginal resections in soft tissue occurred in order to preserve neurovascular structures. In one patient (case 4) the peroneal nerve had to be sacrificed. Marginal bone resection was made twice at the transverse osteotomies (cases 13 and 18) and once at the longitudinal osteotomy (case 9). Inadequate bone resection at the longitudinal osteotomy (case 9) was detected during surgery and treated by additional resection and application of phenol and alcohol to extend the margin further. Marginal bone resection at the transverse osteotomy (cases 13 and 18) was diagnosed after surgery, and no additional resection was undertaken. No adjuvant therapy was given after marginal resection in soft tissue or bone. At the final follow-up, at a mean of 64 months (27 to 135), there was no local recurrence or metastasis.

After the reconstruction there were no wound complications or infections. There was complete incorporation of all grafts and no allograft fractures occurred. There was fracture of the remaining hemicortex in three patients during the operation and in three others shortly afterwards (Table I). They occurred mainly at a sharp corner of the resection, close to a transverse osteotomy, but not through a screw hole. In one patient (case 7), the fracture progressed between the femoral condyles into the knee. Treatment of the fractures varied. One undisplaced postoperative fracture (case 8) was successfully treated in a cast and another undisplaced fracture (case 13) was initially treated in a cast, but it proved to be unstable

and internal fixation was eventually necessary (Figs 3c and 3d). The four displaced fractures were treated by immediate internal fixation. The internal fixation of a supra- and intercondylar fracture of the femur (case 7) was inadequate, and further fixation was necessary followed by prolonged immobilisation resulting in a restricted range of movement of the knee (flexion 25°). None of the other fractures affected the final functional outcome.

The exact time of incorporation was difficult to define. Complete incorporation was assumed when the osteotomy line disappeared (Fig. 1d).¹² All grafts incorporated at a mean of 15 months (6 to 30) after adequate internal fixation. If the initial gap between the graft and host was 1 mm or less, complete incorporation occurred within 12 months. Sufficient union to allow partial weight-bearing occurred at a mean of seven months (3 to 12).

Radiological examination showed marked hypertrophy of the remaining hemicortex in seven cases. The hemicortex showed increased density or thickening (Figs 2d and 3d). No relation to the site of the graft, localisation or the time of the graft incorporation could be found. There was no massive resorption or progressive deterioration of allografts. Minor subcortical resorption of the graft was seen in two patients, most pronounced in one in whom there was no spongiosa impacted beneath it (case 1).

Good or excellent functional results with MSTS scores above 20 were found in all except one patient (case 7) (Table I). The maximal score of 30 was seen in six patients. All except one (case 7) returned to their preoperative level of activity; only four (cases 3, 7, 17, 21) had recreational restrictions because of modest pain or insecurity.

In one patient (case 4) no reliable score was obtained because of the development of reflex sympathetic dystrophy affecting both legs affecting both legs and arms which began two years after surgery. This patient, however, had no pain at the site of the reconstructed proximal tibia, with good knee function and rapid and complete ingrowth of the graft.

DISCUSSION

Our results of 22 hemicortical procedures for low-grade malignant bone tumours showed good oncological and functional outcomes. There was no evidence of local recurrence or distant metastases in any of the patients. No allograft complications occurred and all incorporated completely.

Fracture of the remaining hemicortex occurred in six patients and these were managed successfully by a cast or osteosynthesis. The functional results were excellent or good for all except one patient, and compare favourably with those of larger intercalary procedures.^{6,8,14}

A hemicortical resection is potentially possible for low-grade tumours arising from the parosteal or cortical compartment such as parosteal osteosarcoma, peripheral chondrosarcoma and adamantinoma. We defined peripheral chondrosarcoma as a tumour arising within the cartilaginous cap of an osteochondroma.⁴ All these tumours are usually well differentiated with slow growth and are unlikely to metastasise. Medullary involvement may occur, but we considered its mere presence not to be a contraindication for a hemicortical resection.

Our decision to carry out a hemicortical resection depended on the possibility of obtaining a wide medullary surgical margin. This seems possible for many patients with parosteal osteosarcoma or peripheral chondrosarcoma because invasion usually involves less than 25% of the medullary canal.^{4,7} Adamantinomas, however, are less reliable. An osteofibrous dysplasia-like adamantinoma is usually confined to the cortex, but the classic type of adamantinoma may show extensive medullary involvement.¹⁵ In two cases, in order to obtain wide resection of an adamantinoma we needed to resect 80% of the medullary canal, including the inner part of the opposing cortex.

It is also important preoperatively to identify dedifferentiated high-grade areas and satellite or skip lesions which must be differentiated from the conventional low-grade parosteal tumour. The former is not suitable for hemicortical resection and may need adjuvant chemotherapy. Satellite or skip lesions occur frequently in adamantinoma. MRI is essential for detection of such dedifferentiation and satellite lesions.³ Contrast-enhanced MRI with gadolinium has been a part of our preoperative evaluation, enabling us to distinguish between oedema and tumour.^{2,3} With this protocol, wide resection margins can be determined accurately. Initial resection with an adequate margin remains the most critical factor in determining a good prognosis.^{7,14,16}

In 22 hemicortical resections we achieved wide margins in 12 and marginal margins through tumour-free but reactive tissue in ten. The marginal resections occurred most often (7 to 10) in the soft tissues in order to preserve adherent neurovascular structures. Other investigators encountered the same difficulty in obtaining a wide resection margin in the area

of neurovascular structures.^{6,7,9} Marginal bone resection occurred twice at the transverse osteotomy and only once at the longitudinal medullary osteotomy. Only the latter is typical for a hemicortical resection. It is often difficult to distinguish normal cortical bone from tumour while undertaking the longitudinal osteotomy. Nevertheless, hemicortical resections with wide bone margins can be obtained even when medullary involvement or satellite lesions are present.

We found no local recurrences or metastases after a mean follow-up of 5.3 years (2.2 to 11.2). This seems low compared with other reports. In large clinical studies rates of recurrence of 18% to 20% for parosteal sarcomas,^{6,7} 15% for all types of low-grade chondrosarcoma,¹⁶ and 18% to 32% for adamantinoma have been found.^{14,15} Comparison with these results, however, is not valid because the studies included a variety of tumour grades, surgical margins and follow-up times. The time to recurrence may be eight years for osteosarcomas⁷ and 21 years for adamantinomas. Our satisfactory oncological outcomes so far may be due to selection of relatively small-to-moderately sized, low-grade stage-I lesions.

The principal advantage of a hemicortical over an intercalary procedure is that less normal bone is resected. The resultant defect provides an excellent environment for reconstruction with an inlay allograft. The limited dissection of soft tissue, the good vascularity of the remaining hemicortex and the large contact area between allograft and host bone may reduce infection and facilitate union and remodelling. Our results with inlay reconstructions compare favourably with those of large studies using intercalary allograft reconstruction^{8,14} which recorded a rate of infection of 12%, of fracture of the allograft of 18% and of nonunion of 30%.

The time of incorporation of the graft is always difficult to assess and varied widely in our group between five and 30 months. Stable fixation and close contact between the allograft and host bone will facilitate incorporation.^{17,18} We found incorporation to be faster when the initial gap between the allograft and host was less than 1 mm. Because of the irregular shape of the resection specimen, it was sometimes difficult to cut the allograft exactly to the same shape. Other reasons for the large variation in the time of incorporation may be the location (diaphysis or metaphysis)^{17,18} and the immunological response to the allograft.^{19,20}

The hemicortical reconstruction is vulnerable until the graft becomes incorporated. No fractures of the allograft occurred, but in six patients there was fracture of the remaining host hemicortex. All fractures occurred

when plate fixation was not (yet) present. The remaining hemicortex is specially vulnerable when a large hemicortical segment is resected and stress rising corners are present.²¹ Although these fractures can successfully be managed by a cast or internal fixation and in general do not affect the outcome, initial plate fixation should be considered when the residual cortex is judged to be fragile.

The good clinical results with high MSTS scores seem the logical result of the limited resection, complete incorporation of the allograft and no serious complications. All except one patient had an MSTS score above 20; six patients had a maximal score of 30.

In summary, hemicortical procedures for the treatment of low-grade surface tumours are safe and effective. Wide resection bone margins can be achieved, even when the medulla is involved and satellite or skip lesions are present. Precise preoperative planning using MRI is essential to define the margins of resection. Although the hemicortical resection is technically demanding, gratifying clinical results make it clearly worthwhile for selected patients.

ACKNOWLEDGEMENT

We thank Dr H.M. Hazelbag for the helpful discussion and critical reading of the manuscript.

REFERENCES

1. Bloem JL, Taminiou AH, Eulderink F, Hermans J, Pauwels EK. Radiologic staging of primary bone sarcoma: MR imaging, scintigraphy, angiography, and CT correlated with pathologic examination. *Radiology* 1988;169:805-10.
2. Van der Woude HJ, Bloem JL, Verstraete KL, Taminiou AH, Nooy MA, Hogendoorn PC. Osteosarcoma and Ewing's sarcoma after neoadjuvant chemotherapy: value of dynamic MR imaging in detecting viable tumor before surgery. *AJR Am J Roentgenol* 1995;165:593-8.
3. Van der Woude HJ, Bloem JL, Pope TL Jr. Magnetic resonance imaging of the musculoskeletal system: Part 9. Primary tumors. *Clin Orthop* 1998;347:272-86.

4. Bovee JV, Cleton-Jansen AM, Kuipers-Dijkshoorn NJ, Van de Broek LJ, Taminiou AH, Cornelisse CJ, Hogendoorn PC. Loss of heterozygosity and DNA ploidy point to a diverging genetic mechanism in the origin of peripheral and central chondrosarcoma. *Genes Chromosomes Cancer* 1999;26:237-46.
5. Graadt van Roggen JF, Bovee JV, Van der Woude HJ, Hogendoorn PC. An update of diagnostic strategies using molecular genetic and magnetic resonance imaging techniques for musculoskeletal tumours. *Curr Opin Rheumatol* 2000;12:77-83.
6. Kavanagh TG, Cannon SR, Pringle J, Stoker DJ, Kemp HBS. Parosteal osteosarcoma: treatment by wide resection and prosthetic replacement. *J Bone Joint Surg [Br]* 1990;72-B:959-65.
7. Okada K, Frassica FJ, Sim FH, Beabout JW, Bond JR, Unni KK. Parosteal osteosarcoma: a clinicopathological study. *J Bone Joint Surg [Am]* 1994;76-A:366-78.
8. Ortiz-Cruz E, Gebhardt MC, Jennings LC, Springfield DS, Mankin HJ. The results of transplantation of intercalary allograft after resection of tumors: a long-term follow-up study. *J Bone Joint Surg [Am]* 1997;79-A:97-106.
9. Lewis VO, Gebhardt MC, Springfield DS. Parosteal osteosarcoma of the posterior aspect of the distal part of the femur: oncological and functional results following a new resection technique. *J Bone Joint Surg [Am]* 2000;82-A:1083-8.
10. Enneking WF. The staging system for benign and malignant tumors of the musculoskeletal system. In: Enneking WF, ed. *Clinical musculoskeletal pathology*. Gainesville, Florida: University Presses of Florida, 1990:451-66.
11. Deijkers RL, Bloem RM, Petit PLC, Brand R, Vehmeyer SB, Veen MR. Contamination of bone allografts: analysis of incidence and predisposing factors. *J Bone Joint Surg [Br]* 1997;79-B:161-6.
12. Glasser D, Langlais F. The ISOLS radiological implants evaluation system. In: Langlais F, Tomeno B, eds *Limb salvage: major reconstructions in oncologic and nontumoral conditions*. 5th International Symposium on Limb Salvage (ISOLS). Berlin, etc: Springer-Verlag;1991:1-2.
13. Enneking WF, Dunham W, Gebhardt MC, Malawar M, Pritchard DJ. A system for the functional evaluation of reconstructive procedures after surgical treatment of tumors of the musculoskeletal system. *Clin Orthop* 1993;286:241-6.

14. Qureshi AA, Shott S, Mallin BA, Gitelis S. Current trends in the management of adamantinoma of long bones: an international study. *J Bone Joint Surg [Am]* 2000;82-A:1122-31.
15. Hazelbag HM, Taminiou AH, Fleuren GJ, Hogendoorn PC. Adamantinoma of the long bones: a clinicopathological study of thirty-two patients with emphasis on histological subtype, precursor lesion, and biological behavior. *J Bone Joint Surg [Am]* 1994;76-A:1482-99.
16. Lee FY, Mankin HJ, Fondren G, Gebhardt MC, Springfield DS, Rosenberg AE, Jennings LC. Chondrosarcoma of bone: an assessment of outcome. *J Bone Joint Surg [Am]* 1999;81-A:326-38.
17. Vander Griend RA. The effect of internal fixation on the healing of large allografts. *J Bone Joint Surg [Am]* 1994;76-A:657-63.
18. San Julian Aranguren M, Leyes M, Mora G, Canadell J. Consolidation of massive bone allografts in limb-preserving operations for bone tumours. *Int Orthop* 1995;19:377-82.
19. Stevenson S, Li XQ, Martin B. The fate of cancellous and cortical bone after ransplantation of fresh and frozen tissue-antigen-matched and mismatched osteochondral allografts in dogs. *J Bone Joint Surg [Am]* 1991;73-A:1143-56.
20. Deijkers RL, Bouma GJ, van der Meer-Prins EM, Huysmans PE, Taminiou AH, Claas FH. Human bone allografts can induce T cells with high affinity for donor antigens. *J Bone Joint Surg [Br]* 1999;81-B:538-44.
21. Clark CR, Morgan C, Sonstegard DA, Matthews LS. The effect of biopsy-hole shape and size on bone strength. *J Bone Joint Surg [Am]* 1977;59-A:213-7.

