



Universiteit
Leiden
The Netherlands

Clinical and virological aspects of human parvovirus B19 Infection during Gestation.

Haan, T.R. de

Citation

Haan, T. R. de. (2007, November 13). *Clinical and virological aspects of human parvovirus B19 Infection during Gestation*. Retrieved from <https://hdl.handle.net/1887/12426>

Version: Corrected Publisher's Version


License: [Licence agreement concerning inclusion of doctoral thesis in the Institutional Repository of the University of Leiden](#)

Downloaded from: <https://hdl.handle.net/1887/12426>

Note: To cite this publication please use the final published version (if applicable).

Chapter 7

Fetal stroke and congenital Parvovirus B19 infection complicated by activated protein C resistance



T.R. de Haan, MD
G. van Wezel-Meijler, MD, PhD
M.C.F. Beersma, MD, PhD
J.S. von Lindern, MD
S.G. van Duinen, MD, PhD
F.J. Walther, MD, PhD

Acta Paediatrica 2006; 95: 863-867

Abstract

Parvovirus B19 infection in gestation has been associated with severe fetal complications such as anemia, hydrops and fetal demise. Fetal infection in the first trimester poses the greatest risk for these complications, but infection during the third trimester is more common than previously appreciated and can be associated with severe complications, ie fetal death in the absence of hydrops or classical clinical symptoms. Parvovirus B19 infection in infants has been associated with vasculitis and pathological changes in the central nervous system, which may cause stroke. We report a newborn infant with the rare combination of a recent central nervous system infection with parvovirus B19 and a Factor V Leiden mutation, who developed fetal stroke. Factor V Leiden mutation leads to activated protein C resistance and increases the risk for thromboembolism. In heterozygote carriers, as in our case, the risk for thromboembolism is increased sevenfold. Thromboembolism occurs rarely in newborns with activated protein C resistance, but may be precipitated by dehydration, asphyxia and infection. Although parvovirus B19 infection of the central nervous system may be a precipitant in neonatal and/or fetal stroke, it can also cause stroke independent of a thrombophilic mutation. In this case both causative factors may have coincided.

Introduction

Human parvovirus B19 (B19V) is a small single stranded DNA virus with a size of 24 nm. B19V is a member of the family *Parvoviridae* and belongs to the Erythrovirus genus. About 55–65% of women in the reproductive age have protective B19V-specific IgG antibodies. The remaining 35–45% is susceptible to infection. The rate of vertical transmission during maternal B19V infection is estimated at 33%. The risk of fetal complications, such as severe anemia, hydrops fetalis, and fetal demise, is greatest when infection occurs during the first 22 weeks of pregnancy (1-3). The blood group P-antigen (Globoside antigen) serves as a receptor for B19V. This Globoside antigen is found on the villous trophoblast layer of the placenta, fetal erythroid precursor cells, myocardial cells and endothelial cells (1).

Few reports have been published on B19V infection with CNS involvement such as encephalopathy and meningitis (4-6). B19V infection can cause cerebral vasculitis leading to stroke (7-9). Fetal B19V infection with cerebral complications has been reported in one case (10).

Activated protein C (APC) is a natural anticoagulant inhibiting conversion of prothrombin to thrombin and of factor X to Factor Xa. APC resistance is caused by a mutation in the Factor V (FV)-gene, the FV Leiden mutation. In APC resistance, substitution of Arginine by Glutamine in the Factor Va molecule at the 506 position renders factor Va resistant to APC. APC-resistance has an autosomal dominant inheritance. It is the most common hereditary prothrombotic disorder in Caucasians and occurs in 25-40% of patients with a family history of thrombosis. Both homozygous and heterozygous individuals can develop thrombosis. In heterozygote carriers the risk for thromboembolism is increased sevenfold (11). APC resistance rarely manifests in the neonatal period (12). When thromboembolism occurs in newborns with the FV Leiden mutation additional acquired risk factors are usually present (13). Thromboembolism may be precipitated by dehydration, asphyxia and infection (14, 15). In this case report we describe severe cerebral damage in a patient with a proven B19V infection in late third trimester and a proven APC resistance.

91

Case report

The mother was a 36-year-old gravida 3 para 1. At 39 weeks' gestation she manifested a short period of fatigue and fever, without skin rash. There had been no contact with children or adults with an erythematous rash. Two days before delivery the mother noted a reduction in fetal movements. At 41⁺³ weeks of gestation a 3250 g girl was born by vaginal delivery, complicated by meconium-stained amniotic fluid. Apgar scores were 7, 6, and 10 after 1, 5 and 10 minutes. Eight hours after birth the infant developed respiratory insufficiency, due to meconium aspiration, and needed artificial ventilation.

At 12 hours post delivery she had an epileptic seizure with signs of lateralization. The serum glucose and electrolyte values were normal. Hemoglobin concentration was

Figure 1. Cerebral ultrasound images: (1a) coronal section through the occipital lobes and (1b) sagittal section through the left lateral ventricle, demonstrating large areas of increased echogenicity in the parietal and occipital white matter.

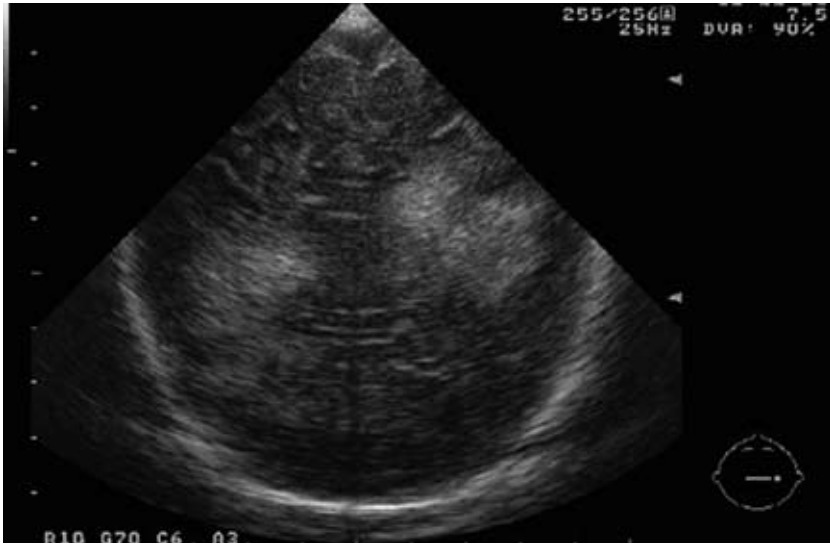

Figure 1a

92

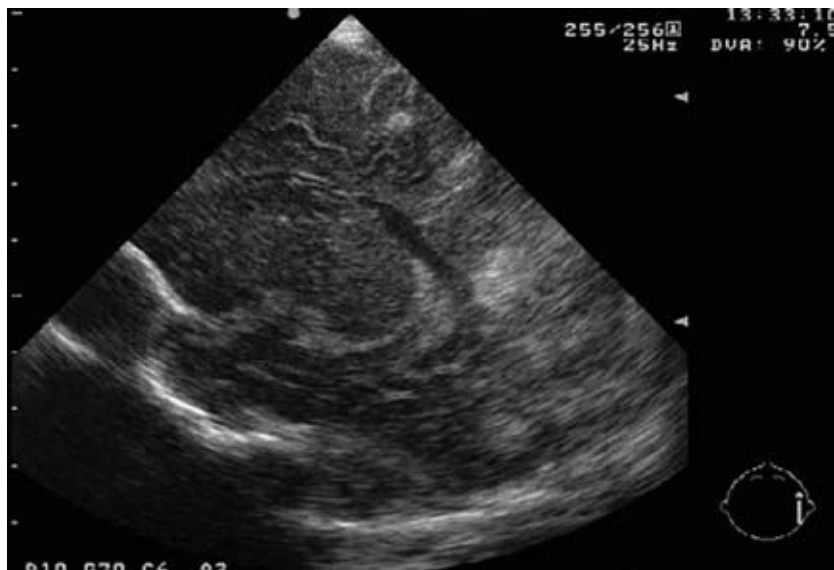

Figure 1b

10.2 mmol/L, the white blood count had an IT (immature/ total neutrophil count) ratio of 22%, and the platelet count was $170 \times 10^9/L$. C-reactive protein was 56 g/L. A gram stain and culture of the CSF were negative for pathogenic micro-organisms. Sepsis therapy was started (Amoxicillin and Gentamicin). A phenobarbital loading dose was administered intravenously and cerebral function monitoring was initiated. The convulsions subsided. Clinical investigation demonstrated absence of motor activity on the right side of the body. Cerebral ultrasound examinations on the first day of life showed extensive echodensities in the cerebral white matter, the distribution and shape being suggestive of multiple venous infarctions (Fig.1). Doppler signals in the major cerebral arteries and in the sagittal and straight sinuses were normal. The lesions noted on cerebral ultrasound were confirmed with MR imaging on the third day of life. On conventional T1- and T2-weighted MR images multiple bilateral signal intensity changes in the frontal, parietal and occipital white matter were seen. On diffusion weighted images, signs of cytotoxic oedema were detected in these regions. In addition, on T2-weighted images, hyperintensity in the thalamus at the right side was seen. Otherwise, the MRI showed a normal myelination pattern, normal gyral development, no structural CNS abnormalities and no signs of hydrocephalus (Fig. 2). The MR images were consistent with haemorrhagic infarctions in multiple vascular regions of the brain. Additional investigations were based on a differential diagnosis of perinatal asphyxia, clotting disorders and congenital infections.

93

Figure 2. T2-weighted transverse MR images (2a) and (2b) at supraventricular level, demonstrating extensive hemorrhagic white matter damage in the parieto-occipital regions and frontal regions, consistent with multiple venous infarctions. Also note diffuse increased signal intensity of the white matter.

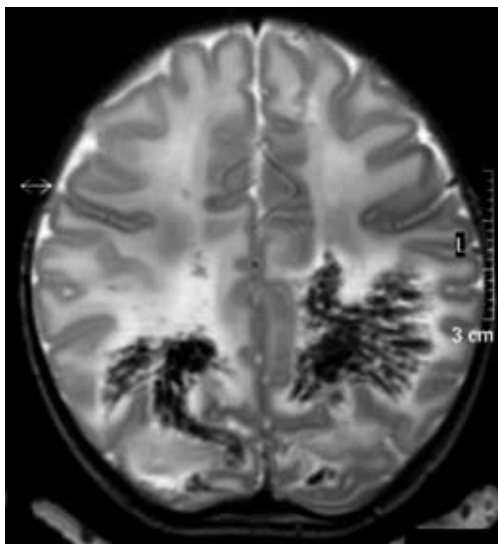

Figure 2a.

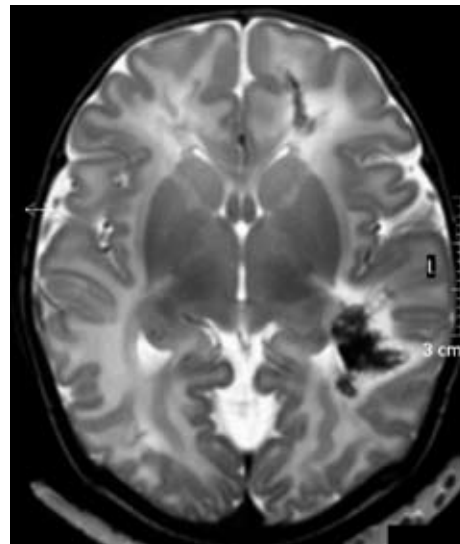


Figure 2b.

Blood chemistry showed signs of neonatal asphyxia (with elevated creatinine and urea values and elevated liver enzymes). Hematological and initial coagulation studies were normal (prothrombin time 15.6 sec, activated partial thromboplastin time 27.7 sec, international normalized ratio (INR) 1.3, fibrinogen 3.8 g/L, hemoglobin 10.2 mmol/L, platelets $170 \times 10^9/L$). Extensive investigation of inherited clotting disorders showed an APC resistance with a heterozygote FV Leiden mutation and normal protein-S and -C values, and a normal Factor VIII activity. The mother was also heterozygous for the FV Leiden mutation. Serologic screening for herpes simplex virus-, toxoplasma-, cytomegalovirus-, and rubella-IgM was negative. Neonatal serum B19V specific IgG and IgM titers were strongly positive (sample/control value ratios of 2.3 and 9.5 respectively). The neonatal B19V viral load in cerebrospinal fluid was ten times higher than in serum (log 10.6 versus 9.7 copies/mL), indicating local replication of B19V. IgM in cerebrospinal fluid was 1.63, whereas IgG was negative, indicating a local immunological response to B19V infection. Maternal B19V specific IgM and IgG values were indicative of a recent infection (sample/control value ratios of 7.9 and 3.6 respectively). The maternal serum B19V viral load was log 7.9 copies/mL. Because of the severe cerebral damage with unfavourable neurological prognosis, intensive treatment was withdrawn, and the infant died shortly after. At autopsy, the brain showed small and large areas of hemorrhagic infarction in the white matter of both cerebral hemispheres and the brain stem, which were several days to weeks old. Partially organized venous thrombi were found in both infarcted and non-infarcted areas throughout the brain (Fig. 3). There were no signs of vasculitis or inflammation. Brain tissue was strongly positive for B19V DNA.

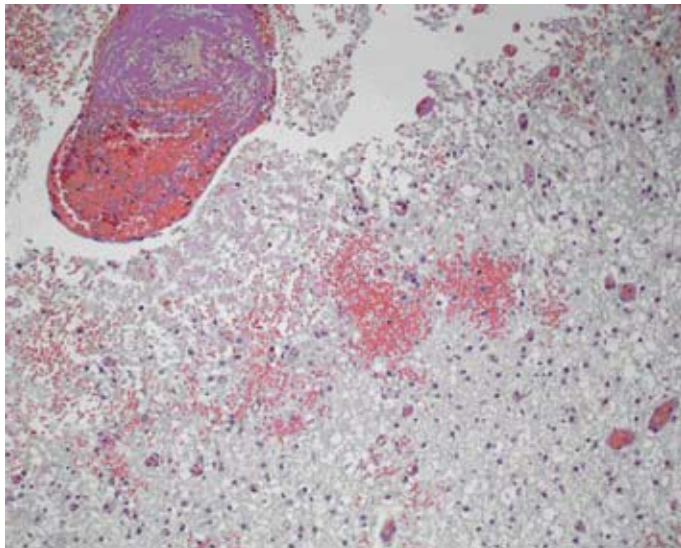


Figure 3. Thrombosed vein in cerebral white matter and area of hemorrhagic necrosis and gliosis. Hematoxylin Eosin, magnification 10x.

Discussion

CNS involvement in cases of intrauterine parvovirus B19 infection is extremely rare, only three cases of B19V neonatal encephalitis / meningitis have been reported (at 23, 27, and 36 weeks of gestation) (4, 10). B19V has also been associated with pediatric stroke (10, 8, and 9). Isumi et al. (10) demonstrated perivascular calcifications in the fetal cerebral cortex, basal ganglia, thalamus and germinal layer following congenital B19V infection. In the cerebral white matter multinucleated giant cells were seen. Immunohistochemical techniques identified these cells as reactive microglial cells. B19V DNA could be detected in glial cells and endothelial cells and suggested that immature fetal blood vessels permit infection of B19V, leading to perivascular inflammatory changes. This phenomenon has also been reported in human placentas infected with B19V (1, 2 and 6). Magro et al. demonstrated that endothelial cells and surrounding mononuclear cells are the viral target of B19V (7). In a series of 12 pediatric cases of meningo-encephalitis caused by B19V, B19V-DNA was invariably detected in the CSF during infection. However, B19V was not detected in the brain tissue itself as in our case. Perivascular calcifications and infiltrates were noted throughout the brain. Following B19V CNS infection, signs of demyelination, abnormal white matter signal and cerebral atrophy have been seen on MRI and were accompanied by long-term neurological sequelae (4). Inflammatory cytokines IL-6, TNF- α , IFN- γ , MCP-1 and GM-CSF may play an important role in the development of cerebral damage as their levels are raised in serum and CSF during B19V infection (4). Bilge et al. (16) described cerebral vasculitis and narrowing of cerebral arteries on MR-angiography in a pediatric patient with a prolonged B19V infection. Viral infection with B19V represents an independent risk factor for ischemic stroke in infants (8, 9). In the case reported here, fetal B19V infection probably occurred late in the 3rd trimester and caused only mild symptoms (fatigue and fever) in the mother. A very high B19V viral load could be demonstrated in maternal and neonatal blood samples and in the neonatal CSF. All neonatal brain tissues were B19V positive on PCR. Gliosis was noted, but no signs of vasculitis were seen at autopsy.

The stroke work-up in our case demonstrated an APC resistance caused by a FV Leiden mutation. Both the newborn infant and her mother were found to be heterozygous carriers of the FV Leiden mutation, which is associated with a sevenfold increased relative risk for thromboembolism. APC resistance has an autosomal dominant inheritance and occurs in 25-40% of patients with a family history of thrombosis. APC resistance is an important cause of fetal/neonatal thrombosis, which can be triggered by severe dehydration, asphyxia and infection (17, 18). In our case, the noted decrease in fetal movements two days before delivery, meconium stained amniotic fluid at birth, the cranial ultrasound, MR images and the autopsy findings point to a fetal stroke in an otherwise uncomplicated pregnancy. Asphyxia did not contribute to any cerebral venous thrombosis as the MR images and pathological examination demonstrated areas of cerebral infarction predating the occurrence of perinatal asphyxia. Although both conditions alone could account for the

observed pathology and clinical picture, the absence of signs of vasculitis or inflammation in the brain suggests that, in this cases, the fetal stroke was probably due to the presence of heterozygous APC resistance and triggered by a fetal B19V infection.

References

1. Corcoran A, Doyle S. Advances in the biology, diagnosis and host-pathogen interactions of parvovirus B19. *J Med Microbiol* 2004;53:459-75.
2. Young NS, Brown KE. Parvovirus B19. *N Engl J Med* 2004;350:586-97.
3. Enders M, Weidner A, Zoellner I, Searle K, Enders G. Fetal morbidity and mortality after acute human parvovirus B19 infection in pregnancy: prospective evaluation of 1018 cases. *Obstet Gynecol Surv* 2005;60:83-4.
4. Kerr JR, Barah F, Chiswick ML, McDonnell GV, Smith J, Chapman MD, Bingham JB, Kelleher P, Sheppard MN. Evidence for the role of demyelination, HLA-DR alleles, and cytokines in the pathogenesis of parvovirus B19 meningoencephalitis and its sequelae. *J Neurol Neurosurg Psychiatry* 2002;73:739-46.
5. Barah F, Vallely PJ, Chiswick ML, Cleator GM, Kerr JR. Association of human parvovirus B19 infection with acute meningoencephalitis. *Lancet* 2001;358:729-30.
6. Morey AL, Keeling JW, Porter HJ, Fleming KA. Clinical and histopathological features of parvovirus B19 infection in the human fetus. *Br J Obstet Gynaecol* 1992;99:566-74.
7. Magro CM, Crowson AN, Dawood M, Nuovo GJ. Parvoviral infection of endothelial cells and its possible role in vasculitis and autoimmune diseases. *J Rheumatol* 2002;29:1227-35.
8. Guidi B, Bergonzini P, Crisi G, Frigieri G, Portolani M. Case of stroke in a 7-year-old male after parvovirus B19 infection. *Pediatr Neurol* 2003;28:69-71.
9. Craze JL, Salisbury AJ, Pike MG. Prenatal stroke associated with maternal parvovirus infection. *Dev Med Child Neurol* 1996;38:84-5.
10. Isumi H, Nunoue T, Nishida A, Takashima S. Fetal brain infection with human parvovirus B19. *Pediatr Neurol* 1999;21:661-3.
11. van der Meer FJ, Koster T, Vandenbroucke JP, Briet E, Rosendaal FR. The Leiden Thrombophilia Study (LETS). *Thromb Haemost* 1997;78:631-5.
12. Simioni P, Sanson BJ, Prandoni P, Tormene D, Friederich PW, Girolami B, Gavasso S, Huisman MV, Buller HR, Wouter ten Cate J, Girolami A, Prins MH. Incidence of venous thromboembolism in families with inherited thrombophilia. *Thromb Haemost* 1999;81:198-202.
13. Lynch JK, Nelson KB, Curry CJ, Grether JK. Cerebrovascular disorders in children with the factor V Leiden mutation. *J Child Neurol* 2001;16:735-44.
14. Mercuri E, Cowan F, Gupte G, Manning R, Laffan M, Rutherford M, Edwards AD, Dubowitz L, Roberts I. Prothrombotic disorders and abnormal neurodevelopmental outcome in infants with neonatal cerebral infarction. *Pediatrics* 2001;107:1400-4.
15. de Galan-Roosen AE, Kuijpers JC, Rosendaal FR, Steegers EA, van Beers WA, Ponjee GA, Merkus HM. Maternal and paternal thrombophilia: risk factors for perinatal mortality. *BJOG* 2005;112:306-11.
16. Bilge I, Sadikoglu B, Emre S, Sirin A, Aydin K, Tatli B. Central nervous system vasculitis secondary to parvovirus B19 infection in a pediatric renal transplant patient. *Pediatr Nephrol* 2005;20:529-533.
17. Abrantes M, Lacerda AF, Abreu CR, Levy A, Azevedo A, Da SL. Cerebral venous sinus thrombosis in a neonate due to factor V Leiden deficiency. *Acta Paediatr.* 2002;91:243-5. Comment in *Acta Paediatr.* 2002;91:1143.
18. Ozduman K, Pober BR, Barnes P, Copel JA, Ogle EA, Duncan CC, Ment LR. Fetal stroke. *Pediatr Neurol* 2004;30:151-62.

