



Universiteit
Leiden
The Netherlands

Clinical and virological aspects of human parvovirus B19 Infection during Gestation.

Haan, T.R. de

Citation

Haan, T. R. de. (2007, November 13). *Clinical and virological aspects of human parvovirus B19 Infection during Gestation*. Retrieved from <https://hdl.handle.net/1887/12426>

Version: Corrected Publisher's Version


License: [Licence agreement concerning inclusion of doctoral thesis in the Institutional Repository of the University of Leiden](#)

Downloaded from: <https://hdl.handle.net/1887/12426>

Note: To cite this publication please use the final published version (if applicable).

Chapter 4

Parvovirus B19 infection in pregnancy, studied by maternal viral load and immune responses



T.R. de Haan, MD
M.C.F. Beersma, MD, PhD
E.C.J. Claas, PhD
D. Oepkes, MD, PhD
A.C.M. Kroes, MD, PhD
F.J. Walther, MD, PhD

Fetal Diagnosis and Therapy 2007; 22: 55-62

Abstract

Objectives: Facilitate risk assessment of vital complications in fetuses of pregnancies affected by acute parvovirus B19 infection.

Design: Study of the natural course of maternal parvovirus B19 infection in four cases, from early pregnancy on.

Setting: University medical center in the Netherlands.

Population: Pregnant mothers attending obstetric services.

Methods: Serial measurements of the maternal and fetal or neonatal viral load and antibody responses.

Main outcome measures: Maternal and fetal/neonatal serum parvovirus B19 viral DNA load and specific IgM and IgG antibodies in maternal serum.

Results: Peak viral load levels occurred within one week after maternal infection and peak IgM levels were observed one week after the peak viral load levels. Approximation of IgG and IgM ratios usually took place 4 weeks after infection. Vertical transmission occurred 1 to 3 weeks after maternal infection, suggesting that fetal infection occurs during the maternal peak viral load.

Conclusions: Maternal parvovirus B19 DNA load levels and IgM responses are useful to estimate the risk of parvovirus B19-associated fetal complications. The maternal peak viral load directly precedes the onset of fetal infection and may be used to indicate the stage of intrauterine parvovirus B19 infection.

Introduction

Human parvovirus B19 (B19 virus, B19V) is a small single stranded DNA virus which is a member of the family *Parvoviridae* and belongs to the Erythrovirus genus. Parvovirus was discovered in 1975 by Yvonne Cossart in serum samples of healthy blood donors, and clinical consequences of infection were first described in 1983 (1). Clinical disease is biphasic. Symptoms, such as fever, myalgia and lethargy, occur 6-12 days after infection and are associated with a peak in viremia and infectivity through the respiratory route. After 2-3 weeks, erythema infectiosum or fifth disease, arthropathy, and transient aplastic crises may occur. The disease is asymptomatic in 25% of the cases; in 50% symptoms are mild and non-specific, and 25% present with arthralgia and the classical "slapped cheek rash" (2, 3). B19V infection in the second trimester of pregnancy can be life-threatening for the fetus as it can cause severe anemia, hydrops fetalis, and fetal demise. About 35–45% of women in the childbearing age lack protective B19V-specific IgG antibodies and are susceptible to B19V infection (3-5).

The rate of vertical transmission during maternal B19V infection is estimated at 33% (2, 6). The risk of fetal complications, such as severe anemia, hydrops, and demise, is greatest when infection occurs in the first 22 weeks of pregnancy (5, 7, 8). Fetal anemia results from decreased red cell production, due to the tropism of B19V for replicating erythroid precursor cells. The blood group P-antigen (globoside antigen) serves as a receptor for B19V, which probably induces apoptosis in erythroid precursor cells regulated by the NS1-protein (2, 9). Globoside antigen is also found on the villous trophoblast layer of the placenta, a possible route for vertical transmission (10).

The diagnosis of B19V infection during pregnancy can be difficult, since maternal IgM antibodies may have disappeared at the time of hydrops fetalis. Furthermore, fetal IgM is usually not measurable (2, 3, 5). Viral DNA in fetal or maternal blood can be detected by polymerase chain reaction (PCR) with a sensitivity of 1-100 copies/mL pending on the type of PCR used (11,12), facilitating the diagnosis of B19V infection in pregnancy (2, 13-17). In cases of hydrops fetalis suspect for B19V infection, PCR can also be performed on amniotic fluid, umbilical cord blood, and fetal or placental tissue (18-20). Early diagnosis of fetal anemia by flow velocity measurements in the middle cerebral artery (MCA) with Doppler ultrasound and treatment with intrauterine transfusion improves outcome of affected fetuses (8, 21).

The early events of B19V infection during pregnancy and the timing and risk factors of vertical transmission are not well known. In the present study we investigated the course of parvovirus B19 infection in four affected pregnancies, with emphasis on the early and longitudinal changes in the maternal and fetal viral load and antibody responses.

Patients and Methods

Based on clinical or epidemiological suspicion, four pregnant women with an acute B19V infection were identified between May and December 2004 at the Department of Obstetrics and Gynecology of the Leiden University Medical Center. Medical information was collected from the charts of the pregnant patients, after informed consent was obtained. At each outpatient visit after diagnosing B19V infection, maternal blood (serum and plasma) and urine samples were collected for determination of B19V viral load and IgM and IgG. Urine samples were frozen at -70°C before use. Routine early pregnancy screening samples were retested for B19V viral load and serology. During intrauterine erythrocyte transfusion (IUT) of two fetuses, cord blood samples were analyzed for B19V viral load and B19V-specific IgM and IgG. After delivery, specimens of the placenta and cord blood were sampled for viral load and immunoglobulin status.

Quantitative real-time PCR

54

DNA was isolated from 200 μl serum using a QIAamp DNA Mini Blood Kit (Qiagen) or a MagNa Pure LC Total Nucleic Acid Isolation Kit (Roche Molecular Diagnostics 3038505). For quantitative detection of B19V DNA in blood, a real time PCR assay using Taq-polymerase was developed. Primers were selected on the NS part of the parvovirus B19 genome (22, 23). Sense and anti-sense primers were used at a concentration of 0.4 μM . Using these primers, a PCR product of 112 bp was generated. PCR reaction was performed using 25 μl QIAGEN Taq PCR HotStart Mix (Qiagen 203445) containing 5.0 mM MgCl_2 and 200 μM dNTPs. Amplification was carried out in an iCycler iQ real-time PCR platform (BioRad). Specific PCR product was detected on an iCycler iQ detection system or by agar gel electrophoresis. Porcine herpes virus, added to each sample prior to DNA extraction, was used as an internal control for the PCR reaction. The primers were both used at a concentration of 0.3 μM and the probe at 0.5 μM . Sensitivity of the real-time B19V DNA PCR was 100 copies/mL by duplicate testing ten-fold dilutions of WHO B19V DNA international standard. Specificity was evaluated by testing a number of sera positive for DNA of a variety of potentially cross-reactive viruses, including adenovirus, hepatitis B virus, cytomegalovirus, Herpes simplex virus 1 and 2, Epstein Barr Virus, human herpes virus-6, and varicella zoster virus. All the control sera tested negative. For quantification of parvo-DNA in clinical samples, serial ten-fold dilutions of WHO International standard for B19V DNA (5×10^5 copies/mL or genome equivalents) were used (22, 23).

Parvovirus B19 EIA antibody assay

B19V IgG and IgM enzyme immunoassay (EIA), based on recombinant VP2 antigen, was obtained from Biotrin (Biotrin International, Dublin, Ireland) (23). The assay detects B19V IgG and IgM in a qualitative way. IgM microtiter plates are coated with rabbit anti-human IgM (U-capture assay). Assays were performed according to the manufacturer's instruc-

tion. Serum sample/control (S/Co) value ratios for positive or negative results were 1.1 and 0.9 respectively for both IgG and IgM assays. S/Co value ratios between 0.9 and 1.1 were interpreted as equivocal.

Ultrasound investigations

At each obstetric outpatient visit, fetal middle cerebral artery (MCA) peak systolic flow velocities were measured with Doppler ultrasound to detect fetal anemia [24, 25] and standard ultrasound studies were done to detect signs of hydrops fetalis.

Results-clinical cases

Case 1 is a 32 year old gravida 2 para 1. Screening serology in early pregnancy was negative. At 13 weeks' gestation her 5-year-old son developed an erythematous rash and high fever during a B19V virus outbreak at school. B19 virus serology was negative at that time, but at 15 weeks seroconversion took place with low positive IgG and high positive IgM titers and a strongly positive PCR reaction in plasma (Fig. 1). At 16 weeks, fetal ultrasound examination showed an increased MCA peak flow velocity (42 cm/sec, Fig. 2) without cardiac enlargement or hydrops. At 18 weeks and 4 days, the fetal condition deteriorated with a further increase in MCA flow velocity (43 cm/sec), reduced fetal movements, and the appearance of ascites. An IUT increased the fetal hemoglobin concentration from 3.8 to 17 g/dL. Fetal IgM titers for B19V were negative, but both fetal blood and amniotic fluid had a high B19V viral load (Fig.1). Fetal karyotyping was normal. There were no signs of fetal anemia or ascites at follow up. A healthy girl was born at term with a birth weight of

55

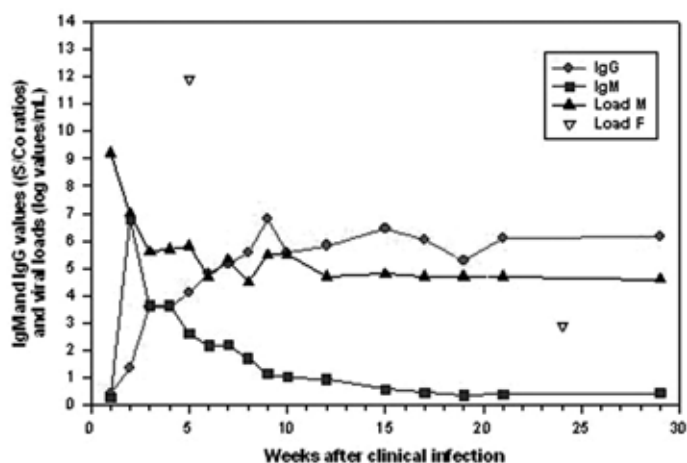


Figure 1. Maternal and fetal viral load and the maternal immune response for case 1 according to weeks following clinical infection. Load M = maternal viral load, Load F = fetal viral load.

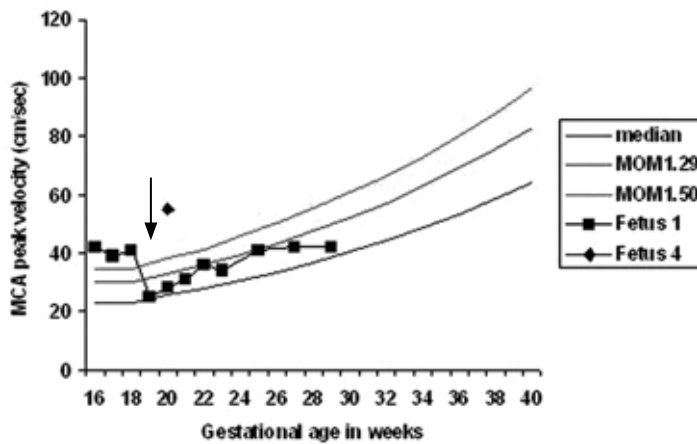


Figure 2. Fetal middle cerebral artery (MCA) peak systolic flow velocity measurements for cases 1 and 4 according to gestational age in weeks. Arrow indicates IUT of case 1. MOM 1.29 = 1.29 multiples of the mean; MOM 1.5 = 1.5 multiples of the mean. Values > MOM 1.5 are indicative of severe fetal anemia.^{23,24}

56

3400 gram and a hemoglobin level of 16 g/dL. Neonatal blood samples were tested for B19V viral load (Log 3 copies/ml) and specific IgG and IgM (Fig. 1), B19V specific PCR on placental tissue was positive.

Case 2 is a 29 year gravida 2 para 1. Early pregnancy screening was negative. At 18 weeks' gestation, her 7-year-old daughter developed erythema infectiosum with a rash, fever, malaise, and positive B19V IgM and IgG. One week later, the patient developed a rash on face and limbs, experienced general malaise and developed a fever. B19V IgM and IgG titers and B19V DNA load in serum were positive. Examination at the obstetric outpatient clinic until 32 weeks of gestation showed no signs of fetal anemia, hydrops, or congenital malformations. At each outpatient visit maternal blood samples were collected for measurements of B19V IgM and IgG titers and viral load measurements (Fig. 3-5). At 40 weeks of gestation a healthy boy was born with a birth weight of 3200 g. The B19V specific PCR on placental tissue was positive. Viral DNA was not demonstrated in neonatal blood samples. No signs of anemia were detected at birth.

Case 3 is a 28 year old gravida 2 para 1, who conceived after fertility treatment. Routine serological screening at the start of this pregnancy was negative. At a gestational age of 16 weeks and 4 days she visited with a 7 year old niece with a proven B19V infection. She experienced no symptoms, but immediate testing showed that IgM and IgG titers were positive with a B19V viral load of log 5.7 copies/mL (Fig. 3-5). A serum sample collected 5 weeks before the B19V contact to screen for a possible varicella contact had, in retrospect, a B19V viral load of log 6.4 copies/mL, which indicated that the B19V infection had occurred before the suspected contact. No signs of fetal anemia or hydrops were detected at weekly outpatient visits and she delivered a healthy boy at term with a birth weight

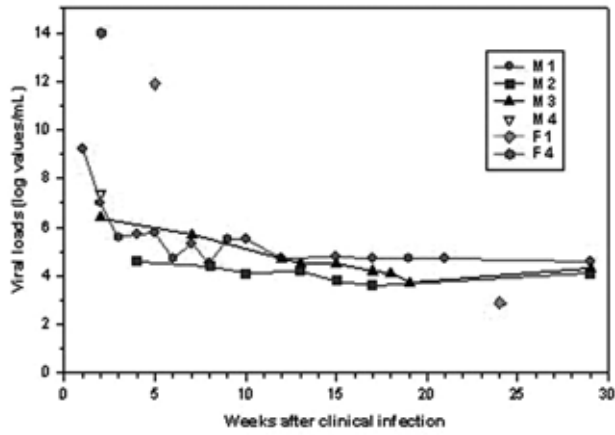


Figure 3. Maternal and fetal viral load according to weeks following clinical infection cases 1-4. M 1 = mother of case 1; F 1 = fetus of case 1.

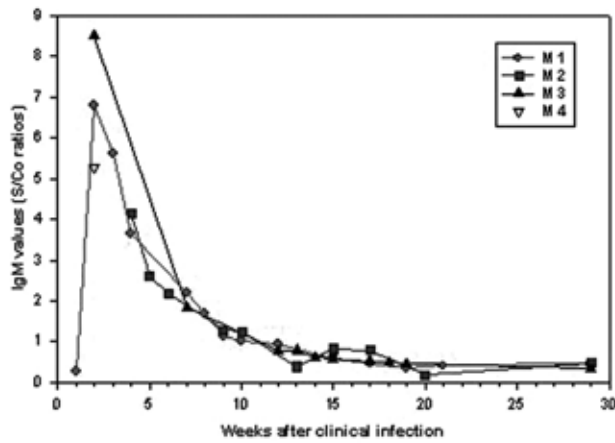


Figure 4. Maternal IgM values according to weeks following clinical infection for cases 1-4 (M 1-4).

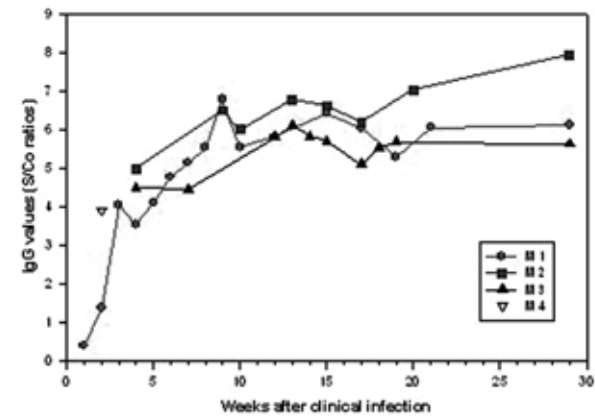


Figure 5. Maternal IgG values according to weeks following clinical infection for cases 1-4 (M 1-4).

of 3310 g. B19V specific PCR on placental tissue was positive. Viral DNA was not demonstrated in neonatal blood samples. No signs of anemia were detected at birth.

Case 4 is a 36 year old gravida 3 para 2. Early pregnancy screening was negative. At 20 weeks and 3 days' gestation she was referred because a classmate of her son had a proven B19V infection two weeks earlier. Both mother and son had experienced no symptoms. A screening ultrasound study showed generalized skin edema, ascites, cardiomegaly and pericardial effusion with an elevated MCA peak systolic flow velocity (Fig. 2) indicative of severe fetal anemia. No congenital malformations were noted. Maternal serum samples were positive for B19V specific IgG, IgM, and viral DNA (Fig. 3-5). An IUT increased the fetal hemoglobin concentration from 3.2 to 15.3 g/dL. Fetal B19V load was log 14 copies/mL (Fig. 3). Directly after the IUT cardiac contractility dropped and led to an irreversible cardiac arrest. Three days later a stillborn hydropic fetus without external congenital anomalies was born with a birth weight of 230 g. Autopsy confirmed the clinical diagnosis of hydrops fetalis and cardiac decompensation, the PCR for B19V on all fetal tissues and placental tissue was strongly positive.

Table 1. Synopsis of data for each case.

| | case 1 | case 2 | case 3 | case 4 |
|----------------------------------|----------|----------|----------|----------------------------|
| Gestational age at infection | 13 weeks | 18 weeks | 11 weeks | 20 weeks |
| Maternal symptoms ¹ | 1 week | 1 week | none | 2 weeks |
| Source of infection | son | daughter | unknown | son |
| Time to fetal anemia | 3 weeks | - | - | 1 week |
| Maternal viral load ² | 9.2 | 4.5 | 6.2 | 7.4 |
| Fetal viral load ² | 12 | - | - | 14 |
| MCA flow ³ | raised | normal | normal | raised |
| Fetal anemia | 3.8 g/dL | no | no | 3.2 g/dL |
| IUT ⁴ | yes | no | no | yes |
| Fetal outcome | survived | survived | survived | died due to cardiac arrest |

¹: Maternal symptoms: time (in weeks) to develop clinical symptoms, ²: Maternal and fetal peak viral load (log values of copies/mL), ³: MCA flow: middle cerebral artery peak systolic flow velocity ⁴: IUT: intrauterine transfusion

Discussion

In the present study, four cases of maternal parvovirus B19 virus (B19V) infection in pregnancy were studied by early and longitudinal follow-up of viral load and antibody responses. By carefully estimating the first day of maternal infection, several key features and time points of maternal and fetal B19V infection during pregnancy could be addressed in detail. No longitudinal studies have been published on B19V infections in pregnancy and, therefore, essential data on the timing and range of the viral load peak, the course of IgG and IgM antibodies, the onset of MCA peak systolic flow velocity increase, and the risk of fetal complications are not known in detail. As a consequence, it remains difficult in clinical practice to estimate the stage of B19V infection and the risk of fetal complications, once B19V infection has been diagnosed during pregnancy. Limitations of this study are the small number of patients and the lack of having fetal blood in all four cases and more importantly the lack of serial fetal blood.

The estimation of the first day of maternal infection in this study was based on both the patient's history and laboratory parameters such as antibodies and viral load. Using this approach, a fairly accurate assessment of the first day of maternal infection in each patient could be made. Particularly useful was a highly characteristic pattern of the maternal IgG and IgM antibody responses, which was observed in all patients who were monitored, showing high peak IgM levels followed by gradually increasing IgG levels. IgM antibodies appeared to be relatively short lived and were detectable until approximately six weeks following infection, which is in accordance with earlier reports (2, 3, and 20). However, B19V IgM can be detected in sera of pregnant women at low levels as long as 26 weeks after onset of maternal disease (26).

Based on the first day of maternal infection, several characteristic time points could be recognized in the four patients. First, peak viral load levels in the absence of antibodies (window-phase) occurred within one week after infection (case 1). Second, peak IgM levels (ratio >6) tended to occur one week after the peak viral load levels (cases 1 and 3). Third, approximation of IgG and IgM ratios usually occurred 4 weeks after infection (cases 1 and 4). Finally, maximal IgG and low IgM ratios, indicating convalescence phase, occurred more than 5 weeks following clinical infection. An interesting observation of this study is the finding that vertical transmission occurred 1 to 3 weeks after maternal infection. This suggests that fetal infection occurs during the maternal peak viral load. Persistent viremia was present in all infected mothers until delivery, but apparently did not lead to vertical transmission in cases 2 and 3. This could relate to the low level of the maternal viral load after the acute infection, but may also reflect the presence of neutralizing antibodies crossing the placenta barrier after 20 weeks' gestation. Furthermore, a reduction of placental globoside (the B19V receptor)-specific immunoreactivity expression is seen with increasing gestational age (10). Levels of globoside become undetectable during the midstage of the third trimester (2, 10, and 27).

Early vertical transmission of B19V during a restricted period of maternal peak viral load causes fetal anemia during week 3-4 of maternal infection. The time span of four weeks to develop hydrops fetalis is in agreement with published reports and coincides with the stage of declining IgM and rising IgG in maternal blood (3, 4, and 28).

Since regular follow-up by fetal blood sampling cannot be done on infected fetuses, the data on fetal infection parameters were limited. However, fetal viral load levels in case 1 showed a decrease of log 9 copies/mL between viral infection and time of birth, whereas maternal viral load levels only decreased by log 4 copies/mL and remained readily detectable at delivery. The reason for this discrepancy is unclear, but these data suggest that PCR screening for congenital B19V infection after delivery may better be done in maternal blood samples than in cord blood. Maternal viral loads did not decrease until one month after delivery, excluding the possibility of the placenta being the main source of ongoing maternal B19V DNA in blood during pregnancy. Notwithstanding high viral loads and clinical signs of fetal B19V infection, fetal IgM and IgG remained negative in the cordocentesis blood. This finding can be ascribed to the immature fetal immune response in the first 20 weeks of gestation (29).

During the period of maternal viremia, B19V DNA was found intermittently in maternal urine samples, both in the presence and absence of fetal infection. Therefore, urinary excretion of B19V DNA was not related to fetal infection.

60

Six months after fetal infection, a neonatal cord blood sample of case 1 demonstrated only trace amounts of B19V DNA. This nearly total decrease in fetal viral load contrasts with the continued presence of B19V viral load in the maternal blood at a constant level until delivery. In cases 2 and 3 viral DNA could not be detected in neonatal blood samples at birth, but this does not exclude intrauterine B19V infection as viral DNA was isolated from their placenta at birth. Asymptomatic fetal infection in these two cases is supported by the fact that all ultrasound measurements of the MCA peak systolic flow velocity were within normal limits.

In conclusion, by performing a longitudinal weekly follow-up of B19V viral load and antibodies in pregnancy, the present study for the first time followed the course of B19V infection during pregnancy and provides evidence for early transmission of B19V during acute maternal infection. It should be emphasized that the absence of maternal B19V IgM does not exclude an ongoing risk for B19V-associated fetal hydrops (13, 30, and 31) and that B19V DNA can persist at low concentrations in maternal blood for several months following acute maternal infection (26). Therefore, timely invasive diagnosis should be performed in the presence of fetal symptoms to exclude (or confirm) fetal B19V infection reliably. Future prospective studies could further specify the variations in time of fetal infection and also address the possibility of late transmission in rare cases. These data are relevant in the development of more accurate guidelines for monitoring of B19V infected pregnant women. Although a recent Dutch study (32) suggests that routine B19V screening of pregnant mothers may not be cost effective, timely diagnosis of suspected cases

by measuring maternal viral load and immune responses in combination with serial ultrasound scans to check for fetal anemia should be the gold standard of fetal diagnosis and therapy in parvovirus B19 infections (32).

Acknowledgments

We wish to thank E.A.N.M. Mooi-Kokenberg, MD, PhD, and R.G.W. Nijman, MD, from the Groene Hart Hospital in Gouda for their support in follow-up of patients and for donating blood samples.

References

1. Anderson MJ, Pattison JR. The human parvovirus. Brief review. *Arch Virol* 1984; 82:137-148.
2. Corcoran A, Doyle S. Advances in the biology, diagnosis and host-pathogen interactions of parvovirus B19. *J Med Microbiol* 2004; 53:459-475.
3. Young NS, Brown KE. Parvovirus B19. *N Engl J Med* 2004; 350:586-597.
4. Yaegashi N, Niinuma T, Chisaka H, Watanabe T, Uehara S, Okamura K, Moffatt S, Sugamura K, Yajima A. The incidence of, and factors leading to, parvovirus B19-related hydrops fetalis following maternal infection; report of 10 cases and meta-analysis. *J Infect* 1998; 37:28-35.
5. Enders M, Weidner A, Zoellner I, Searle K, Enders G. Fetal morbidity and mortality after acute human parvovirus b19 infection in pregnancy: prospective evaluation of 1018 cases. *Prenat Diagn* 2004; 24:513-518.
6. Norbeck O, Papadogiannakis N, Petersson K, Hirbod T, Broliden K, Tolfvenstam T. Revised clinical presentation of parvovirus B19-associated intrauterine fetal death. *Clin Infect Dis* 2002; 35:1032-1038.
7. von Kaisenberg CS, Jonat W. Fetal parvovirus B19 infection. *Ultrasound Obstet Gynecol* 2001; 18:280-288.
8. van Kamp IL, Klumper FJ, Bakkum RS, Oepkes D, Meerman RH, Scherjon SA, Kanhai HH. The severity of immune fetal hydrops is predictive of fetal outcome after intrauterine treatment. *Am J Obstet Gynecol* 2001; 185:668-673.
9. Chisaka H, Morita E, Murata K, Ishii N, Yaegashi N, Okamura K, Sugamura K. A transgenic mouse model for non-immune hydrops fetalis induced by the NS1 gene of human parvovirus B19. *J Gen Virol* 2002; 83:273-281.
10. Jordan JA, DeLoia JA. Globoside expression within the human placenta. *Placenta* 1999; 20:103-108.
11. Searle K, Guilliard C, Wallat S, Schalasta G, Enders G. Acute parvovirus B19 infection in pregnant women—an analysis of serial samples by serological and semi-quantitative PCR techniques. *Infecties* 1998; 26:139-143.
12. Schalasta G, Schmid M, Lachmund T, Enders G. Lightcycler consensus PCR for rapid and differential detection of human erythrovirus B19 and V9 isolates. *J Med Virol* 2004; 73:54-59.
13. Dieck D, Schild RL, Hansmann M, Eis-Hubinger AM. Prenatal diagnosis of congenital parvovirus B19 infection: value of serological and PCR techniques in maternal and fetal serum. *Prenat Diagn* 1999; 19:1119-1123.
14. de Krijger RR, Elsacker-Niele AM, Mulder-Stapel A, Salimans MM, Dreef E, Weiland HT, van Krieken JH, Vermeij-Keers C. Detection of parvovirus B19 infection in first and second trimester fetal loss. *Pediatr Pathol Lab Med* 1998; 18:23-34.
15. Hoebe CJ, Claas EC, Steenbergen JE, Kroes AC. Confirmation of an outbreak of parvovirus B19 in a primary school using IgM ELISA and PCR on thumb prick blood samples. *J Clin Virol* 2002; 25:303-307.
16. Hokynar K, Norja P, Laitinen H, Palomaki P, Garbarg-Chenon A, Ranki A, Hedman K, Soderlund-Venermo M. Detection and differentiation of human parvovirus variants by commercial quantitative real-time PCR tests. *J Clin Microbiol* 2004; 42:2013-2019.
17. Knoll A, Louwen F, Kochanowski B, Plentz A, Stussel J, Beckenlehner K, Jilg W, Modrow S. Parvovirus B19 infection in pregnancy: quantitative viral DNA analysis using a kinetic fluorescence detection system (Taq-Man PCR). *J Med Virol* 2002; 67:259-266.

18. Trotta M, Azzi A, Meli M, Borchì B, Periti E, Pontello V, Leoncini F. Intrauterine parvovirus B19 infection: early prenatal diagnosis is possible. *Int J Infect Dis* 2004; 8:130-131.
19. Baschat AA, Towbin J, Bowles NE, Harman CR, Weiner CP. Prevalence of viral DNA in amniotic fluid of low-risk pregnancies in the second trimester. *J Matern Fetal Neonatal Med* 2003; 13:381-384.
20. Heegaard ED, Brown KE. Human parvovirus B19. *Clin Microbiol Rev* 2002; 15:485-505.
21. Rodis JF, Rodner C, Hansen AA, Borgida AF, Deoliveira I, Shulman RS. Long-term outcome of children following maternal human parvovirus B19 infection. *Obstet Gynecol* 1998; 91:125-128.
22. Saldanha J, Lelie N, Yu MW, Heath A. B19 Collaborative Study Group. Establishment of the first World Health Organization International Standard for human parvovirus B19 DNA nucleic acid amplification techniques. *Vox Sang* 2002; 82:24-31.
23. Beersma MF, Claas EC, Sopaheluakan T, Kroes AC. Parvovirus B19 viral loads in relation to VP1 and VP2 antibody responses in diagnostic blood samples. *J Clin Virol* 2005; 34:71-75.
24. Mari G. Noninvasive diagnosis by Doppler ultrasonography of fetal anemia due to maternal red-cell alloimmunisation. *N Engl J Med* 2000; 342:9-14.
25. Cosmi E, Mari G, Delle Chiaie L, Detti L, Akiyama M, Murphy J, Stefos T, Ferguson JE 2nd, Hunter D, Hsu CD, Abuhamad A, Bahado-Singh R. Noninvasive diagnosis by Doppler ultrasonography of fetal anemia resulting from parvovirus infection. *Am J Obstet Gynecol* 2002; 187:1290-1293.
26. Enders M, Schalasta G, Baisch C, Weidner A, Pukkila L, Kaikkonen L, Lankinen H, Hedman L, Soderlund-Venermo M, Hedman K. Human parvovirus B19 infection during pregnancy - Value of modern molecular and serological diagnostics. *J Clin Virol* 2006; 35:400-406.
27. Jordan JA, Huff D, DeLoia JA. Placental cellular immune response in women infected with human parvovirus B19 during pregnancy. *Clin Diagn Lab Immunol* 2001; 8:288-292.
28. Reintjes R, Bosman A, Buitenwerf J. Parvovirus B19 infection in pregnancy: a cause of non-immune hydrops fetalis. *Ned Tijdschr Geneesk* 1999; 143:542.
29. Durandy A. Development of the immune system. *Pathol Biol (Paris)* 1992; 40:685-689.
30. Zerbini M, Musiani M, Gentilomi G, Venturoli S, Gallinella G, Morandi R. Comparative evaluation of virological and serological methods in prenatal diagnosis of parvovirus B19 fetal hydrops. *J Clin Microbiol* 1996; 34:603-608.
31. Wattré P, Dewilde A, Subtil D, Andreoletti L, Thirion V. A clinical and epidemiological study of human parvovirus B19 infection in fetal hydrops using PCR Southern blot hybridization and chemiluminescence detection. *J Med Virol* 1998; 54:140-144.
32. van Gessel PH, Gaytant MA, Vossen AC, Galama JM, Ursem NT, Steegers EA, Wildschut HI. Incidence of parvovirus B19 infection among an unselected population of pregnant women in the Netherlands: A prospective study. *Eur J Obstet Gynecol Reprod Biol* 2006; 128:46-49.

