



Universiteit
Leiden
The Netherlands

Clinical and virological aspects of human parvovirus B19 Infection during Gestation.

Haan, T.R. de

Citation

Haan, T. R. de. (2007, November 13). *Clinical and virological aspects of human parvovirus B19 Infection during Gestation*. Retrieved from <https://hdl.handle.net/1887/12426>

Version: Corrected Publisher's Version

License: [Licence agreement concerning inclusion of doctoral thesis in the Institutional Repository of the University of Leiden](#)

Downloaded from: <https://hdl.handle.net/1887/12426>

Note: To cite this publication please use the final published version (if applicable).

Chapter 3

Parvovirus B19 in pregnancy.



E.P. de Jong
T.R. de Haan, MD
A.C.M. Kroes, MD, PhD
M.C.F. Beersma, MD, PhD
D. Oepkes, MD, PhD
F.J. Walther, MD, PhD

Journal of Clinical Virology 2006;36: 1-7

Abstract

Parvovirus B19 is a small single-stranded DNA virus and a potent inhibitor of erythropoiesis, due to its cytotoxicity to erythroid progenitor cells. Infection with parvovirus B19 during pregnancy can cause several serious complications in the fetus, such as fetal anemia, neurological anomalies, hydrops fetalis, and fetal death. Early diagnosis and treatment of intrauterine parvovirus B19 infection is essential in preventing these fetal complications. Testing maternal serum for IgM antibodies against parvovirus B19 and DNA detection by PCR can confirm maternal infection. If maternal infection has occurred, ultrasound investigation of the fetus and measurement of the peak systolic flow velocity of the middle cerebral artery are sensitive non-invasive procedures to diagnose fetal anemia and hydrops. Intrauterine transfusion is currently the only effective treatment to alleviate fetal anemia, but if the fetus is (near) term, induction of delivery should be considered. Most maternal infections with parvovirus B19 occur through contact with infected children at home. Individual counseling of susceptible pregnant women will reduce unnecessary fetal deaths.

B19 virus: virology

Human Parvovirus B19 (B19V) is a small single-stranded DNA virus (10). It is the only member of the Parvoviridae family, genus Erythrovirus, known to be pathogenic to humans (30). Its genome of about 2,500 base pairs encodes for three major proteins. Two structural proteins (VP1 and VP2) make up the viral capsid. The viral capsid consists for 95% of VP2; the remaining 5% is made up of VP1. VP1 differs from VP2 only in the N-terminal region with the addition of 227 amino acids that mainly are located outside the virion and accessible to antibody binding (26, 27). The non-structural protein (NS1) is presumed to be involved in viral replication, activation of viral gene transcription and inducing apoptosis in target cells (7, 32).

Pathogenesis of B19V in pregnancy

B19V is a potent inhibitor of hematopoiesis because it lytically infects erythroid precursor cells. The cellular receptor for B19V is globoside or P-antigen. It is found on erythrocyte progenitor cells (erythroblasts and megakaryocytes), but also on erythrocytes, synovium, placental tissue, fetal myocardium, and endothelial cells (7, 42). Viral replication of B19V is restricted to erythroid progenitor cells. Expression of globoside on the cell surface is not sufficient for viral cell entry and therefore for viral replication. Globoside is a binding-site for B19V on the cell surface, but B19V needs $\alpha 5\beta 1$ integrin as a cellular co-receptor and functional activity of $\beta 1$ integrin for cell entry (40). Recent data suggest that Ku80 auto antigen may also function as a co-receptor (33). The NS1 protein of B19V is involved in inducing cell death. Both direct toxic cell injury and the induction of apoptosis contribute to this effect. Infection with B19V usually takes place through respiratory droplets, but B19V can also be transmitted by blood and blood derived products and can be transmitted vertically from mother to fetus (16). No vertical transmission has been described if the mother is immune at the time of exposure. It is highly unlikely that fetal infection occurs if the mother has IgG antibodies since this is thought to give life-long protection against re-infection with B19V. When maternal infection occurs, maternal viremia reaches its peak approximately 1 week after infection. Symptoms such as erythema infectiosum, mild fever, arthralgia and headache start approximately 10-14 days after infection in about 50% of infected women. At the time of the occurrence of IgM antibodies, presumably during the maternal peak viral load (day 7), the risk of vertical transmission may be maximal (20). Until now, the exact route of transmission is unknown.

Jordan et al. (24) showed a decreasing expression of globoside within the villous trophoblast layer of the human placenta with increasing gestational age. This may explain why the incidence of fetal morbidity and mortality related to B19V infection decreases with gestational age (16). More likely, passive transfer of maternal antibodies after the age of 25 weeks may reduce fetal morbidity and mortality at late stages of pregnancy.

Epidemiology of B19V

Infection with parvovirus B19 is common worldwide. The yearly peak incidence of infection occurs during spring and epidemics occur every four years (5). The prevalence of IgG antibodies directed against B19V in the population ranges from 2 to 15% in children 1 to 5 years old, 15 to 60% in children 6 to 19 years old 30 to 60% in adults and more than 85% in the geriatric population (22).

About 35-45% of women of childbearing age do not possess protective IgG-antibodies against B19V. The incidence of acute B19V infection in pregnancy is approximately 1-2% in endemic periods, but in epidemic periods infection rate may rise to >10% (38, 14, 37). In case of maternal infection, vertical transmission occurs in 33-51% of cases, the risk of adverse fetal outcome is approximately 10% (7, 34). Infections with B19V are estimated to cause 48 cases of fetal death each year in the Netherlands (5).

Clinical manifestations of B19V in pregnancy

Fetal infection with B19V is associated with intrauterine fetal death (IUFD), non-immune hydrops fetalis (NIHF) and neurological manifestations. Fetal infection can also be asymptomatic.

40

Fetal death

Cases of fetal death due to B19V infection have been described mostly between 20 and 24 weeks' gestation, but cases of IUFD as early as 10 weeks and as late as 41 weeks' gestation have also been described (34).

Non-immune hydrops fetalis

The observed risk of B19V-induced hydrops fetalis is 3.9% after maternal infection throughout pregnancy, with a maximum of 7.1% when infection occurred between 13 and 20 weeks of gestational age. The peak incidence of B19V associated hydrops fetalis is between 17 and 24 weeks of gestation (16). A fetus affected by B19V may show signs of hydrops fetalis on ultrasound investigation, typically marked ascites, cardiomegaly and pericardial effusion (Figure 2). In advanced stages, generalized edema and a thick, hydropic placenta can be found. The latter may be responsible for a maternal pre-eclampsia-like syndrome with swollen legs, hypertension, proteinuria and maternal anemia, the 'mirror-syndrome', which is so called because maternal signs apparently reflect those present in the fetus. The underlying mechanism responsible for the fetal symptoms is severe anemia, which leads to high output cardiogenic heart failure. NIHF is more frequent during the hepatic stage (8-20 weeks of gestation) of haematopoietic activity (41). In this stage of haematopoiesis the half-life of erythrocytes is shorter compared to the later bone marrow and splenic haematopoietic stage (7). Therefore the fetus is at this gestational age especially vulnerable to

severe anemia and hydrops fetalis. The interval between B19V infection and development of NIHF ranges from 2 to 6 weeks (41).

Neurological manifestations

Few cases of encephalopathy and severe CNS abnormalities following intrauterine B19V have been reported and only three cases of B19V neonatal encephalitis / meningitis have been reported (23, 28). The low frequency of neurological complications suggests that this is an uncommon complication. B19V has also been associated with pediatric stroke (11, 23, 19, and 31). Isumi et al. (23) demonstrated perivascular calcifications in the fetal cerebral cortex, basal ganglia, thalamus and germinal layer following congenital B19V infection. In the cerebral white matter multinucleated reactive microglial cells were seen. B19V DNA could be detected in glial cells and endothelial cells and suggest that immature fetal blood vessels permit infection of B19V, leading to perivascular inflammatory changes.

Diagnosis

Serological tests

Serologic examination of maternal blood is the first and most useful diagnostic test that should be performed as soon as possible once B19V infection is suspected during pregnancy (see algorithm). B19 IgG or IgM antibody detection now is most often performed by enzyme immuno assays, which tend to replace the immunofluorescent technique (3, 15). B19V specific IgM antibodies become detectable in maternal serum within 7-10 days after infection, sharply peak at 10-14 days, and then rapidly decrease within 2 or 3 months (1). IgG antibodies will rise considerably more slowly and reach a plateau at 4 weeks after infection. As a result, comparison of the IgG and IgM EIA ratio's (or IFA titers) can provide an indication of the actual stage of B19 infection. If IgM titers exceed IgG titers, the B19V infection took place less than month ago, viral load levels will be high, and fetal complications, if absent, may still develop (3). Although measurement of maternal IgM is highly sensitive and specific, one should be aware of two classic pitfalls. First, after a recent contact, there will be a serologic window of seven days, during which both IgG and IgM remain negative. Secondly, at the time of clinically overt hydrops fetalis, IgM levels may already have become low or (rarely) even undetectable. It is even conceivable that continued antigenic shedding resulting from the fetal infection may contribute to the decline of maternal IgM levels. In such cases, PCR analysis of the same blood sample will be highly informative.

In contrast to the reliability of B19V serology in maternal blood, serologic examination of fetal and neonatal blood samples is highly unreliable since most unborn children will not produce IgG or IgM responses to B19V. Therefore examination of fetal serum or neonatal (cord blood) for B19V infection should be confined to B19 DNA detection by PCR, which effectively will confirm or exclude fetal B19V infection.

Viral DNA detection (PCR)

Nucleic acid amplification to detect B19V DNA is an extremely sensitive means (most published PCR assays are able to detect viral DNA at 1 to 100 copies/mL) to detect viral DNA in a sample. This method is especially useful in patients lacking an adequate antibody-mediated immune response, immunocompromised or immunosuppressed individuals, and fetuses. In such cases serological testing for B19V is unreliable (25). Using standard procedures, detection of B19V specific IgM in fetal blood has a sensitivity of 29% compared to almost 100% for PCR (3, 16). However, low B19V DNA levels may persist for years after acute infection and therefore low-positive PCR results for B19V do not prove recent infection (29).

Ultrasound measurements

If a recent parvovirus infection is suspected during pregnancy, ultrasound examination should be performed to exclude the presence of fetal anemia and hydrops. Blood flow in anemic fetuses has a hyper dynamic pattern, which can be detected non-invasively with Doppler ultrasonography in various fetal blood vessels. These changes in blood flow are thought to result from increased cardiac output and decreased viscosity of fetal blood. Blood flow in the middle cerebral artery is the first to respond to fetal anemia due to the early response of brain tissue to anemia. An increase in the middle cerebral artery peak systolic velocity (MCA-PSV) (Figure 1) is a very sensitive measure to identify fetal anemia caused by B19V infection (9, 12). Timing of intrauterine transfusion for treatment of fetal anemia and prevention of fetal hydrops can be based on these MCA-PSV measurements.

42

B19V-associated fetal hydrops, an accumulation of excess fluid in at least two body compartments of the fetus, can be easily seen on fetal ultrasound (Figure 2) (4, 6, and 18). Hydrops caused by anemia usually manifests itself first by ascites, with enlargement and thickening of the fetal heart. Untreated, fluid accumulation progresses with skin edema, pericardial effusion and placental edema. Pleural effusions are late and minimal in anemic hydrops. Amniotic fluid volume may be normal or even decreased; polyhydramnios is rare (39).

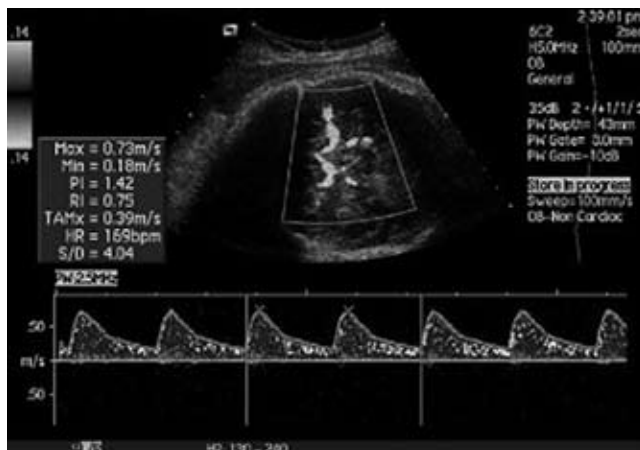


Figure 1. Measurement of peak systolic velocity in the middle cerebral artery (MCA-PSV).

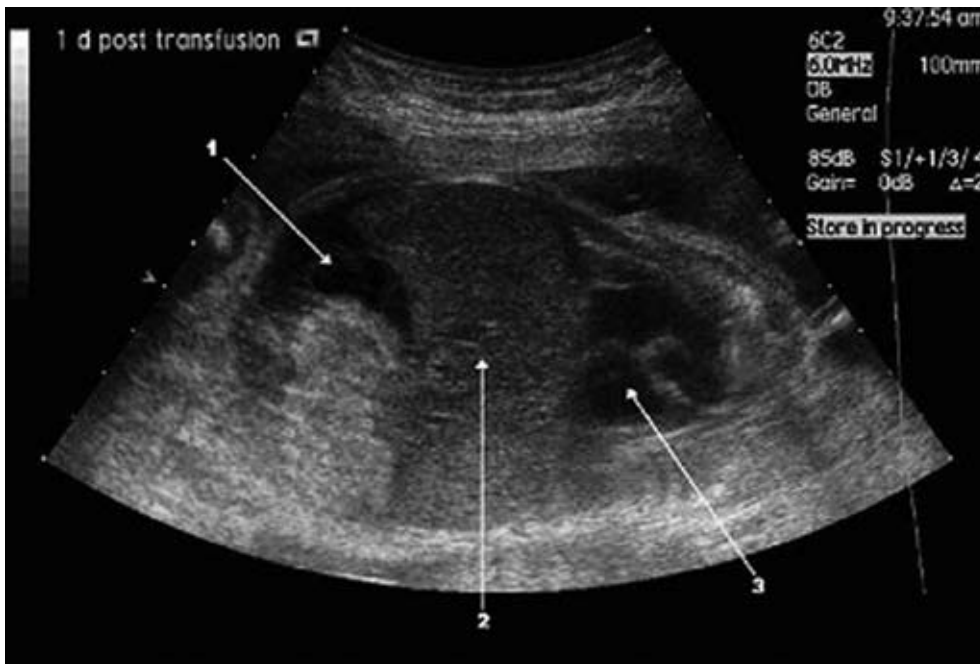


Figure 2. Fetal ascites (1) and enlargement of fetal liver (2) and fetal heart (3).

Therapy

Intrauterine transfusion (IUT)

Management of B19V infection with IUT can correct fetal anemia and may reduce the mortality of B19V infection significantly (Figure 3). Timely IUT of fetuses with severe hydrops reduces the risk of fetal death (17, 35, 36, and 16). In most cases, one transfusion is sufficient for fetal recovery. Following successful transfusion, it may take weeks for all hydropic signs to disappear. A few cases of spontaneous resolution of hydrops due to parvovirus infection have been described. This has led to discussion on the best time to intervene or whether to intervene at all. Only fetal blood sampling can provide information on fetal hemoglobin and reticulocyte count, and thus on whether the fetus may be in a spontaneous recovery phase or not. Most clinicians choose to proceed with transfusion when the fetal blood sample shows anemia, even if there is already evidence of recovery of erythropoiesis by a high reticulocyte count. Due to the rarity of the disease, a randomized trial to find the best policy is unlikely ever to be performed.

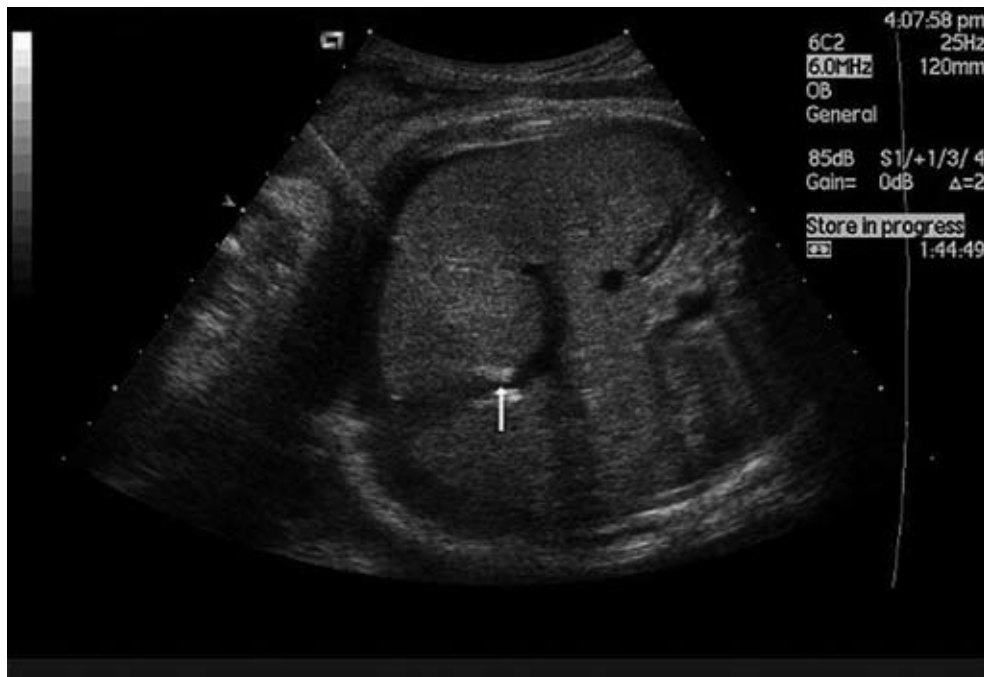

Figure 3. Insertion of the transfusion needle in the umbilical vein (arrow).

44

Management of intrauterine B19V infection

Pregnant women who have been exposed to B19V, or those developing symptoms compatible with B19V infection, should be assessed for susceptibility or the presence of infection, by determining their B19V IgG and IgM status (Figure 4). If the woman is immune to B19V (IgG positive, IgM negative) she can be reassured that recent exposure will not result in adverse consequences in her pregnancy. If there is no immunity to the virus and no seroconversion has taken place after 1-2 weeks, the woman is not infected with the virus. She should be counseled about the risk of B19V infection. If the woman has been infected with B19V (IgM positive), the fetus should be monitored for the development of hydrops fetalis by ultrasound examination including assessment of MCA-PSV, preferably weekly until 10-12 weeks post-exposure. If the fetus subsequently develops hydrops and/or anemia (increase in MCA-PSV), an IUT should be considered. A fetal blood sample should be taken during IUT to perform a measurement of B19V DNA, hemoglobin and reticulocyte counts. If the fetus is near term or at term, delivery should be considered (8). Intrauterine transfusion may be preferable to delivering a severely hydropic fetus, even close to term. Hydropic neonates usually are prone to severe respiratory problems, which can be prevented by allowing intrauterine recovery.

Prognosis, risk factors and prevention

Prognosis

Children who survived a successful IUT for B19V-induced fetal anemia and hydrops fetalis have a good neurodevelopmental prognosis (13).

Risk factors

A prospective evaluation of 618 pregnant women exposed to B19V in an endemic period was performed by Harger et al. (21). In this study the single statistically significant risk factor that was found for B19V infections in pregnant women was exposure to B19V by their own children. Other studies have found an increased risk for B19V infections in elementary school teachers and day-care workers (21).

Prevention

Because maternal exposure to B19V occurs before her child or any other contact has a rash or is otherwise symptomatic, and considering that around 20% of children are asymptomatic, no reasonable strategy to avoid B19V exposure to pregnant women is apparent. Also, it would not be justified excluding pregnant women from the workplace during endemic periods, since the risk of occupational infection may be similar to or less than in the community or at home. Individual counseling of pregnant women, identified to be seronegative, with a high-risk profile (school teachers, day-care workers) should be done to prevent unnecessary fetal death (21, 16). This would require an active policy of serological testing of these categories early in pregnancy. Recently Ballou et al. (2) described a recombinant parvovirus B19 vaccine composed of VP1 and VP2 capsid proteins, which proved to be immunogenic and safe to use in human volunteers. Vaccination of non-immune pregnant women could be a highly effective method to prevent fetal infection with B19V, but doubt exists about the cost-effectiveness of this strategy in the general population.

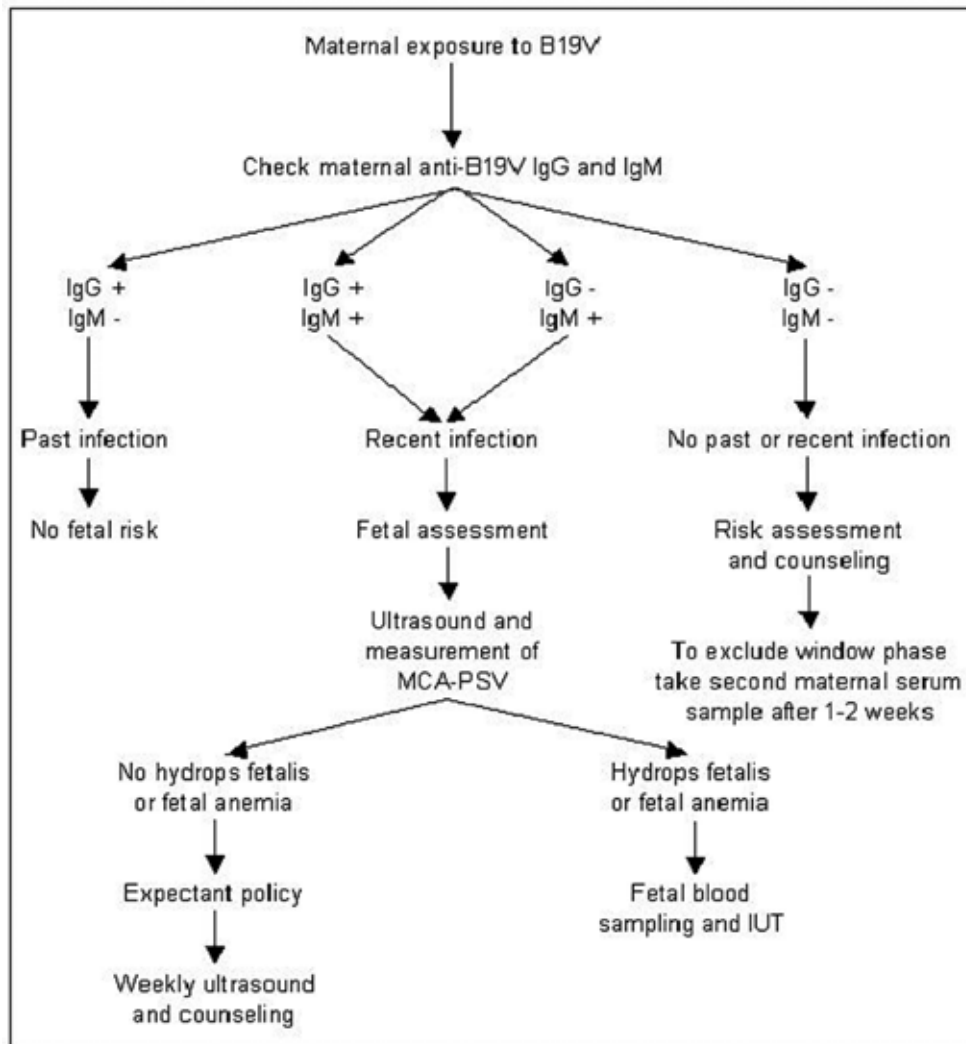


Figure 4. Clinical and laboratory protocol for the first weeks after maternal exposure to B19V. This does not apply to longer intervals after exposure.

References

1. Anderson MJ, Higgins PG, Davis LR, Willman JS, Jones SE, Kidd IM, Pattison JR, Tyrrell DAJ. Experimental parvoviral infection in humans. *J Infect Dis* 1985; 152:257-65.
2. Ballou WR, Reed JL, Noble W, Young NS, Koenig S. Safety and immunogenicity of a recombinant parvovirus B19 vaccine formulated with MF59C.1. *J Inf Dis* 2003; 187: 675-8
3. Beersma MFC, Claas ECJ, Sopaheluakan T, Kroes ACM. Parvovirus B19 viral loads in relation to VP1 and VP2 antibody responses in diagnostic blood samples. *J Clin Virol* 2005; 34: 71-5.
4. Bond PR, Caul EO, Usher J, Cohen BJ, Clewley JP, Field AM. Intrauterine infection with human parvovirus. *Lancet* 1986; 1: 448-9.
5. Bosman A, Wallinga J, Kroes ACM. Fifth disease every four years: Parvovirus B19. *Infectieziektenbulletin* 2002; 6:215-9. Accessible at: <http://www.rivm.nl/infectieziektenbulletin/bul1306/parvo.html>
6. Brown T, Anand A, Ritchie LD, Clewley JP, Reid TMS. Intrauterine parvovirus infection associated with hydrops fetalis. *Lancet* 1984; 2: 1033-4.
7. Chisaka H, Morita E, Yaegashi N, Sugamura K. Parvovirus B19 and the pathogenesis of anemia. *Rev Med Virol* 2003; 13: 347-59.
8. Cohen BJ, Kumar S. Parvovirus B19 infection in pregnancy. *Fetal Matern Med Review* 2005; 16: 123-50.
9. Cosmi E, Mari G, Delle Chiaie L, Detti L, Akiyama M, Murphy J, Stefos T, Ferguson JE, Hunter D, Hsu C, Abuhamad A, Bahado-Singh R. Noninvasive diagnosis by Doppler ultrasonography of fetal anemia resulting from parvovirus infection. *Am J Obstet Gynecol* 2002; 187: 1290-3.
10. Cossart YE, Field AM, Cant B, Widdows D. Parvovirus-like particles in human sera. *Lancet* 1975; 11: 72-3
11. Craze JL, Salisbury AJ, Pike MG. Prenatal stroke associated with maternal parvovirus infection. *Dev Med Child Neurol* 1996; 38: 84-5.
12. Delle Chiaie L, Buck G, Grab D, Terinde R. Prediction of fetal anemia with Doppler measurement of the middle cerebral artery peak systolic velocity in pregnancies complicated by maternal blood group alloimmunization or parvovirus B19 infection. *Ultrasound Obstet Gynecol.* 2001; 18: 232-6.
13. Dembinski J, Haverkamp F, Maara H, Hansmann M, Eis-Hübinger AM, Bartmann P. Neurodevelopmental outcome after intrauterine red cell transfusion for parvovirus B19-induced fetal hydrops. *Br J Obstet Gynaecol* 2002; 109: 1232-4.
14. Dembinski J, Eis-Hübinger AM, Maar J, Schild R, Bartman P. Long term follow up of serostatus after maternal-fetal parvovirus B19 infection. *Arch Dis Child* 2003; 88: 219-21.
15. Doyle S, Kerr S, O'Keefe G, O'Carroll D, Daly P, Kilty C. Detection of parvovirus B19 IgM by antibody capture enzyme immunoassay: receiver operating characteristic analysis. *J Virol Methods* 2000; 90: 143-52.
16. Enders M, Weidner A, Zoellner I, Searle K, Enders G. Fetal morbidity and mortality after acute human parvovirus B19 infection in pregnancy: prospective evaluation of 1018 cases. *Prenat Diagn* 2004; 24: 513-8.
17. Fairley CK, Smoleniec JS, Caul OE, Miller E. Observational study of effect of intrauterine transfusions on outcome of fetal hydrops after parvovirus B19 infection. *Lancet* 1995; 346: 1335-7.
18. Gray ES, Anand A, Brown T. Parvovirus infections in pregnancy. *Lancet* 1986; 1: 208.

19. Guidi B, Bergonzini P, Crisi G, Frigieri G, Portolani M. Case of stroke in a 7-year-old male after parvovirus B19 infection. *Pediatr Neurol* 2003; 28: 69-71.
20. De Haan TR, Oepkes D, Beersma MFC, Walther FJ. Aetiology, diagnosis and treatment of hydrops foetalis. *Current pediatric reviews* 2005; 1: 63-72.
21. Harger JH, Adler SP, Koch WC, Harger GF. Prospective evaluation of 618 pregnant women exposed to parvovirus B19: risks and symptoms. *Obstet Gynecol* 1998; 91: 413-20.
22. Heegaard ED, Brown KE. Human parvovirus B19. *Clin Microbiol Rev* 2002; 15: 485-505.
23. Isumi H, Nunoue T, Nishida A, Takashima S. Fetal brain infection with human parvovirus B19. *Pediatr Neurol* 1999; 21: 661-3.
24. Jordan JA, DeLoia JA. Globoside expression within the human placenta. *Placenta* 1999; 20: 103-8.
25. Jordan JA. Diagnosing human parvovirus B19 infection: guidelines for test selection. *Mol Diagn* 2001; 6: 307-12.
26. Kaufmann B, Simpson AA, Rossmann MG. The structure of human parvovirus B19. *PNAS* 2004; 101: 11628-33.
27. Kawase M, Momoeda M, Young NS, Kajigaya S. Most of the VP1 unique region of B19 parvovirus is on the capsid surface. *Virology* 1995; 211: 359-66.
28. Kerr JR, Barah F, Chiswick ML, McDonnell GV, Smith J, Chapman MD, Bingham JB, Kelleher P, Sheppard MN. Evidence for the role of demyelination, HLA-DR alleles, and cytokines in the pathogenesis of parvovirus B19 meningoencephalitis and its sequelae. *J Neurol Neurosurg psychiatry* 2002; 73: 739-46.
29. Lindblom A, Isa A, Norbeck O, Wolf S, Johansson B, Broliden K, Tolfvenstam T. Slow clearance of human parvovirus B19 viremia following acute infection. *Clin Infect Dis* 2005; 41: 1201-3.
30. Lukashov VV, Goudsmit J. Evolutionary relationships among parvoviruses: virus-host coevolution among autonomous primate parvoviruses and links between adeno-associated and avian parvoviruses. *J Virol* 2001; 75: 2729-40.
31. Mandrioli J, Portolani M, Cortelli P, Sola P. Middle cerebral artery thrombosis in course of parvovirus B19 infection in a young adult: a new risk factor for stroke? *J Neurovirol* 2004; 10: 71-4.
32. Moffat S, Yaegashi N, Tada K, Tanaka N, Sugamura K. Human parvovirus B19 nonstructural (NS1) protein induces apoptosis in erythroid lineage cells. *J Virol* 1998; 72: 3018-28.
33. Munakata Y, Saito-Ito T, Kumura-Ishii K, Huang J, Kodera T, Ishii T, Hirabayashi Y, Koyanagi Y, Sasaki T. Ku80 autoantigen as a cellular coreceptor for human parvovirus B19 infection. *Blood* 2005; 106: 3449-56.
34. Norbeck O, Papadogiannakis N, Petersson K, Hirbod T, Broliden K, Tolfvenstam T. Revised clinical presentation of parvovirus B19-associated intrauterine fetal death. *Clin Infect Dis* 2002; 35: 1032-8.
35. Rodis JF, Rodner C, Hansen AA, Borgida AF, Deoliveira I, Shulman Rosengren S. Long-term outcome of children following maternal human parvovirus B19 infection. *Obstet Gynecol* 1998; 91: 125-8.
36. Schild RL, Bald R, Plath H, Eis-Hübinger AM, Enders G, Hansmann M. Intrauterine management of fetal parvovirus B19 infection. *Ultrasound Obstet Gynecol* 1999; 13: 161-6.
37. Trotta M, Azzi A, Meli M, Borch B, Periti E, Pontello V, Leoncini F. Intrauterine parvovirus B19 infection: early prenatal diagnosis is possible. *Int J Infect Dis* 2004; 8: 130-1.

38. Valeur-Jensen AK, Pedersen CB, Westergaard T, Jensen IP, Lebech M, Andersen PK, Aaby P, Pedersen BN, Melbye M. Risk factors for parvovirus B19 infection in pregnancy. *JAMA* 1999; 1099-1105.
39. Van Kamp IL, Klumper FJCM, Bakkum RSLA, Oepkes D, Meerman RH, Scherjon SA, Kanhai HHH. The severity of immune fetal hydrops is predictive of fetal outcome after intrauterine treatment. *Am J Obstet Gynecol* 2001; 185: 668-73.
40. Weigel-Kelley KA, Yoder MC, Srivastava A. $\alpha 5\beta 1$ integrin as a cellular coreceptor for human parvovirus B19: requirement of functional activation of $\beta 1$ integrin for viral entry. *Blood* 2003; 102: 3927-33.
41. Yaegashi N, Niinuma T, Chisaka H, Watanabe T, Uehara S, Okamura K, Moffatt S, Sugamura K, Yajima A. The incidence of, and factors leading to, parvovirus B19-related hydrops fetalis following maternal infection; report of 10 cases and meta-analysis. *J Infect* 1998; 37: 28-35.
42. Young NS, Brown KE. Mechanics of disease: parvovirus B19. *N Engl J Med* 2004; 350: 586-97.
43. Zerbini M, Gallinella G, Cricca M, Bonvicini F, Musiani M. Diagnostic procedures in B19 infection. *Pathol Biol* 2002; 50: 332-8.

