

Cover Page



Universiteit Leiden



The handle <http://hdl.handle.net/1887/18591> holds various files of this Leiden University dissertation.

**Author:** Pansuriya, Twinkal C.

**Title:** Genetics of Ollier disease and Maffucci syndrome

**Issue Date:** 2012-03-15

# Chapter 2



## Enchondromatosis: insights on the different subtypes

Twinkal C. Pansuriya<sup>1</sup>, Herman M. Kroon<sup>2</sup>, Judith V.M.G. Bovée<sup>1</sup>

<sup>1</sup>Department of Pathology, Leiden University Medical Center, Leiden, The Netherlands. <sup>2</sup>Department of Radiology, Leiden University Medical Center, Leiden, The Netherlands

*Int J Clin Exp Pathol.* 2010, 26;3(6):557-69

## Abstract

Enchondromatosis is a rare, heterogeneous skeletal disorder in which patients have multiple enchondromas. Enchondromas are benign hyaline cartilage forming tumors in the medulla of metaphyseal bone. The disorder manifests itself early in childhood without any significant gender bias. Enchondromatosis encompasses several different subtypes of which Ollier disease and Maffucci syndrome are most common, while the other subtypes (metachondromatosis, genochondromatosis, spondyloenchondrodysplasia, dys-spondyloenchondromatosis and cheirospondyloenchondromatosis) are extremely rare. Most subtypes are non-hereditary, while some are autosomal dominant or recessive. The gene(s) causing the different enchondromatosis syndromes are largely unknown. They should be distinguished and adequately diagnosed, not only to guide therapeutic decisions and genetic counseling, but also with respect to research into their etiology. For a long time enchondromas have been considered a developmental disorder caused by the failure of normal endochondral bone formation. With the identification of genetic abnormalities in enchondromas however, they were being thought of as neoplasms. Active hedgehog signaling is reported to be important for enchondroma development and *PTH1R* mutations have been identified in ~10% of Ollier patients. One can therefore speculate that the gene(s) causing the different enchondromatosis subtypes are involved in hedgehog/*PTH1R* growth plate signaling. Adequate distinction within future studies will shed light on whether these subtypes are different ends of a spectrum caused by a single gene, or that they represent truly different diseases. We therefore review the available clinical information for all enchondromatosis subtypes and discuss the little molecular data available hinting towards their cause.

## Keywords

Ollier disease, Maffucci syndrome, enchondroma, metachondromatosis, enchondromatosis, central chondrosarcoma

## Introduction

Enchondromas are common, benign, and usually asymptomatic hyaline cartilage forming neoplasms in the metaphyses and diaphyses of the short and long tubular bones of the limbs, especially the hands and feet [1,2]. They usually occur as a single lesion (solitary enchondroma) which is most often found incidentally when radiographic studies are performed for other reasons. Occasionally patients present with multiple enchondromas causing severe deformity of the affected bones, generally defined as enchondromatosis [2,3]. The distribution of the enchondromas, and other accompanying symptoms as well as the mode of inheritance define the different subtypes of enchondromatosis (Figure 1), which mainly includes Ollier disease, Maffucci syndrome, metachondromatosis, genochondromatosis, spondyloenchondrodysplasia, cheirospondyloenchondromatosis and dyssspondyloenchondromatosis. These subtypes should be distinguished and adequately diagnosed, not only to guide therapeutic decision and genetic counseling, but also to enable future studies to shed light on whether these are different ends of a spectrum caused by a single gene, or that they represent true different diseases. We therefore review the available clinical information for all enchondromatosis subtypes and discuss the little molecular data available hinting towards their cause.

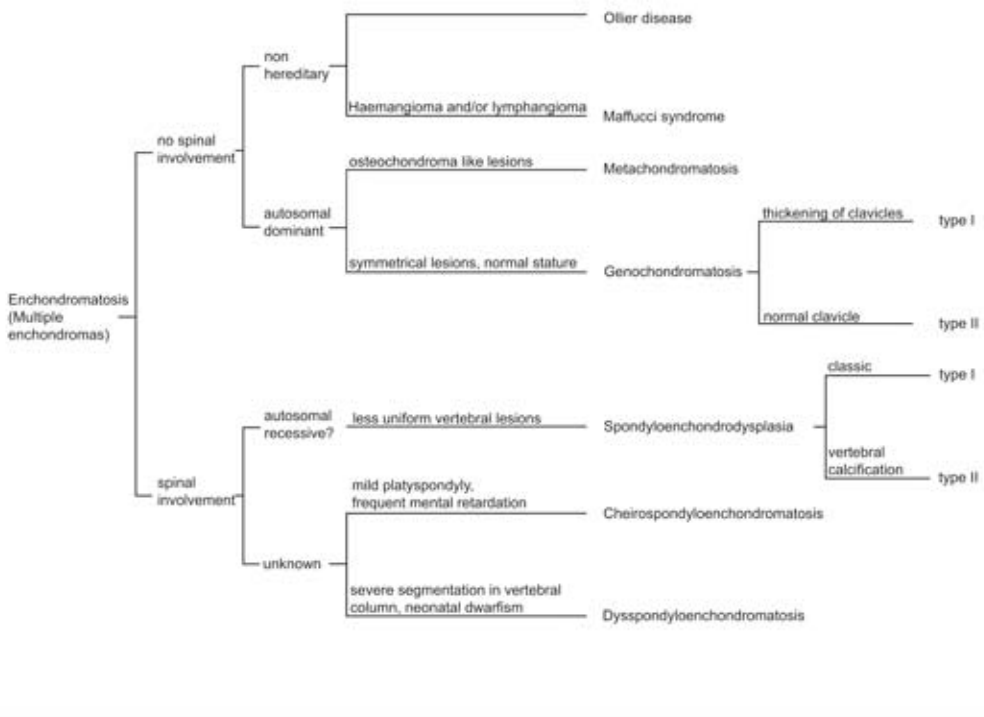
### Enchondroma

On conventional radiographs enchondromas present as multiple, oval-shaped, linear and/or pyramidal osteolytic lesions with well-defined margins in the metaphysis and/or diaphysis of the long tubular and in the flat bones [4]. Magnetic resonance (MR) studies demonstrate lobulated lesions with intermediate signal intensity on T1-weighted images and predominantly high signal intensity on T2-weighted sequences [5]. Histologically enchondromas show low cellularity with an abundant hyaline cartilage matrix sometimes with extensive calcifications [1]. When enchondromas are located in the phalangeal bones or when they occur in enchondromatosis patients, cellularity is increased and more worrisome histological features are tolerated, since they are not correlated with malignant behavior in this specific context (Figure 2) [1]. Treatment of solitary enchondroma is surgical but only in case of complains or cosmetic deformity [6]. In case of enchondromatosis, the deformities as well as malignant progression of enchondromas may require multiple surgical interventions [7-12].

### Secondary central chondrosarcoma

While solitary enchondromas almost never progress to secondary central chondrosarcoma, malignant transformation in enchondromatosis is estimated to occur in 25-30% of the patients [1]. Central chondrosarcoma is a malignant bone tumor forming hyaline cartilage and arising centrally in the medullary cavity of bone [13]. The distinction between enchondroma and low grade chondrosarcoma is difficult on conventional radiographs [14]. Fast contrast-enhanced dynamic MRI is more helpful in this regard [15].

Figure 1 Enchondromatosis sub-types



Classification diagram for patients with multiple enchondromas based on spinal involvement and genetic transmission.

At the histological level the distinction can also be very difficult and is subject to interobserver variability [16] [17]. Low grade chondrosarcomas (grade I) can be treated surgically with local curettage combined with cryosurgery or phenol treatment while resection and reconstruction is obligatory in case of grade II or III chondrosarcoma [18].

### Enchondromagenesis

The underlying mechanism for enchondroma development is largely unknown. Several cytogenetic/genetic reports are present in the literature using solitary enchondromas, suggesting these lesions to be neoplastic (<http://atlasgeneticsoncology.org/Tumors/EnchondromaID5333.html>). Enchondromas in Ollier disease are comparable to solitary enchondromas at m-RNA expression level [19].

Since enchondromas arise in the metaphysis in close proximity to the growth plate, they may result from failure of terminal differentiation of growth plate chondrocytes. In support of this, transgenic mice expressing the hedgehog (Hh) regulated transcription factor *Gli2* in chondrocytes, which mimics activated Hh signaling, develop lesions similar to human enchondromas [20]. Hedgehog signaling is a crucial regulator of normal chondrocytes proliferation and differentiation within the normal growth plate. Enchondromas indeed demonstrate levels of hedgehog signaling that are comparable to normal growth plate [20-23].

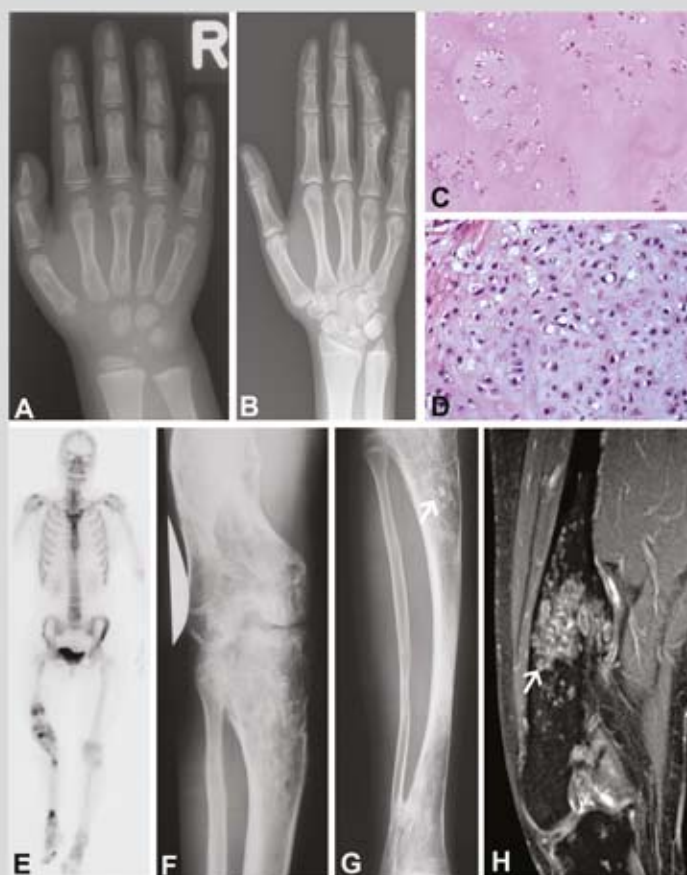
Additionally, ten percent of patients with en-chondromatosis harbour a mutation in the PTHLH receptor, *PTH1R*, in their tumor tissue [20,22,23]. The mutations were shown to decrease the function of the PTHLH receptor with ~30% [22]. PTH1R is a receptor for parathyroid hormone and for parathyroid hormone-related peptide which acts in a negative feedback loop with Indian Hedgehog (IHH) regulating normal endochondral bone formation [24-26]. PTHLH signaling is active in solitary enchondromas and in chondrosarcomas [27]. In parallel, multiple osteochondromas (MO) syndrome (multiple benign cartilaginous tumors arising from the surface of bone) is an auto-somal dominant disorder caused by mutations in the *EXT1* and *EXT2* genes, leading to disturbed hedgehog signaling based on their involvement in heparan sulphate (HS) biosynthesis [28-30]. The *EXT* genes are not affected in central chondrosarcomas and their m-RNA expression is normal [21]. It may be hypothesized that the genes causing the different enchondromatosis subtypes also affect the HS dependent signaling pathways.

#### **Ollier disease**

Ollier disease (also known as dyschondroplasia, multiple cartilaginous enchondromatosis, enchondromatosis Spranger type I), is the most common subtype, first described in 1889. It is defined by the presence of multiple enchondromas with asymmetric distribution (Figure 2) [4,31-34]. Ollier disease is non-familial and mostly encountered early in childhood, affecting both sexes equally. The estimated prevalence of Ollier disease is 1/100,000 [2]. The true incidence can be higher since mild phenotypes without skeletal deformities can go undetected. Few cases of familial occurrence have been reported (OMIM 166000) [35-37]. There is large clinical variability with respect to size, number, location, age of onset, and requirement of surgery [1,2,4,34]. Lesions are usually distributed unilaterally and may involve the entire skeleton, although the skull and vertebral bodies are very rarely involved. Sometimes lesions are bilateral or present in only one extremity [4].

Malignant transformation of one or more enchondromas towards secondary central chondrosarcoma is estimated to occur in 5-50% of the patients and can be life threatening [38-42]. Malignant transformation most frequently occurs in long tubular and flat bones while this is far less common in the small bones of hands and feet (Figure 2). This is interesting since enchondromas preferentially occur at the hands and feet. In addition to the risk of developing chondrosarcoma, Ollier patients also seem to have an increased risk for the development of non-skeletal malignancies as reported in Table 1, especially intracranial tumors of glial origin [43]. There is at present no curative or preventive treatment option for patients with Ollier disease. The underlying cause of Ollier disease is so far unknown. The nonhereditary asymmetrical polyostotic distribution of the lesions might suggest a somatic mosaic mutation [14]. This is similar to McCune-Albright syndrome / polyostotic fibrous dysplasia in which an activating mutation in *GNAS1* occurs during early embryogenesis leading to a somatic mosaic state resulting in fibrous dysplasia affecting several bones [44,45].

Figure 2 Ollier disease



(A) 4-year-old female patient with Ollier disease. Multiple enchondromas, manifesting as central end eccentric osteolytic lesions and deformities in the metacarpals and phalanges of the fourth and fifth ray of the right hand. (B) Same patient as in Figure 2A 13 years later. The enchondromas have increased in size and some are more evidently visible compared to the previous study. This has resulted in deformity of the fourth finger. (C) Histology of enchondroma of long bone from Ollier patient showing moderate cellularity and abundance of hyaline cartilage matrix (200 times magnification). (D) Histology of chondrosarcoma grade II of the long bone from Ollier patient showing increased cellularity and atypical chondrocytes (200 times magnification).

(E) Technetium-99m bone scintigraphy, anterior projection, demonstrates shortening of the right lower limb. Varus deformity of the femur and valgus deformity of the tibia. Multiple areas of focally increased uptake of the tracer in femur and tibia. (F-G) Anteroposterior radiograph of the right knee and lower leg of same patient as 2E. Deformity of both the distal femur and the tibia and fibula. Structural changes in the marrow cavity and cortical bone of femur and tibia consisting of osteolysis and osteosclerosis. Specifically in the proximal tibia areas with mineralization in the sense of calcifications can be appreciated (arrow). The appearance is consistent with multiple chondromatous tumors. (H) Coronal fatsuppressed T1-weighted magnetic resonance image after intravenous contrast administration of the femur. Varus deformation of the femur. Multiple, partially lobulated, areas with increased signal intensity due to enhancement of the chondromatous lesions. Large lesion in the distal diaphysis of the femur, of which histology showed a chondrosarcoma (arrow). The enhancement demonstrates rings and arcs (also known as septal or nodular enhancement) consistent with the chondromatous nature of the lesions.

Not many genetic studies are reported for Ollier tumors due to the rarity of the disease (summarized in Table 2). As discussed above, four different heterozygous mutations, affecting either the germ line or only the tumor tissue, were found in the *PTH1R* gene (R150C, R255H, G121E and A122T) [20,22,23] in 5 of 48 Ollier patients (~10%). Thus, *PTH1R* mutations may contribute to the disease in a small subset of Ollier patients but is probably not causative for the disease [22].

**Table 1. Non-cartilaginous malignancies associated with Ollier disease**

Associated tumors	No. of patients	References
Glioma	17	[38,43,90-99]
Juvenile granulosa cell tumor	7	[38,100-105]
Non-small cell lung cancer	1	[106]

**Table 2 Genetic findings in Ollier enchondromas and chondrosarcoma**

Tumor per patient	Technique used	Results of chromosomal abnormality	References
low grade CS	cytogenetics	deletion at 1p	[108]
high grade CS	microsatellite marker, SSCP, IHC	LOH at 13q14 (RB1), 9p21 and over expression of TP53	[109]
Enchondroma	array-CGH	noalteration	[110]
Enchondroma	array-CGH	deletion of 6	
CS II	array-CGH	gain at 1, 2, 5, 7, 8, 9, 15, 16, 17, 18, 19, 20, 21 and 22	[110]
CS II	array-CGH	gain at 6, 7, 12, 14, 15, 16, 17, 18, 19 and loss at 1, 3, 4, 6, 9, 10, 13, 15, 16 and 22	[110]

### Maffucci syndrome

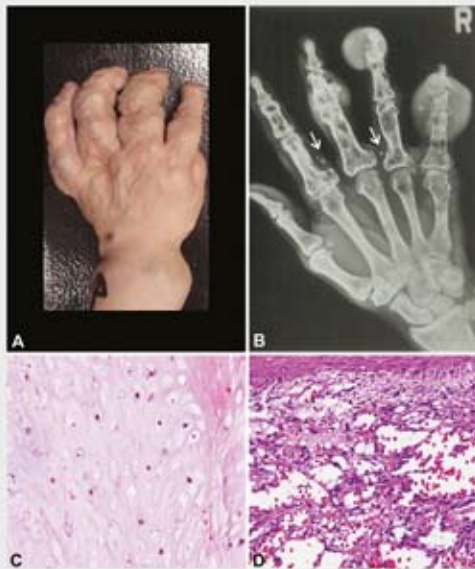
Maffucci syndrome (also known as dyschondrodysplasia with haemangiomas, enchondromatosis with multiple cavernous haemangiomas, Kast syndrome, haemangiomatosis chondrodystrophica, enchondromatosis Spranger type II) was first described in 1881 [32,46,47]. It is non-hereditary and characterized by the presence of multiple enchondromas combined with multiple haemangiomas of soft tissue or, less commonly, lymphangiomas (Figure 3) [34, 48]. Lesions are asymmetrically distributed and there is no gender discrimination. The disease appears to develop in 25% of cases from the time of birth or during the first year of life, in 45% of cases symptoms start before the age of 6 and in 78% of cases symptoms developed before puberty [49,50]. Lewis et al reviewed ninety-eight cases and showed that hand, foot, femur, tibia, and fibula were most frequently affected by enchondromas [50].

Haemangiomas are benign vascular tumors which often protrude as bluish or reddish soft nodules. They can be found anywhere in the body. In addition to the enchondromas, radiographs can show phleboliths, associated with soft tissue calcifications in haemangiomas. Histologically, haemangiomas can be of the capillary or cavernous subtype. Spindle cell haemangioendothelioma is more specific for Maffucci syndrome [51,52]. Both the enchondromas and the vascular lesions may progress to malignancy. The risk of malignancy is higher than in Ollier disease [2,49]. When considering intracranial tumors, the majority is of mesenchymal origin and includes secondary central chondrosarcoma and angiosarcoma associated with Maffucci syndrome [43]. Non-mesodermal tumors associated with Maffucci syndrome are summarized in Table 3.

While in Ollier disease intracranial tumors other than chondrosarcomas of the cranium are exclusively of glial origin, in Maffucci syndrome different tumor types are encountered [43]. Also, patients with Maffucci syndrome are almost 10 years older when developing intracranial tumors, and are more likely to live in Asia or South America as compared to Ollier disease [43].

Genetic studies on Maffucci syndrome are sparse. An inversion of chromosome bands p11 and q21 of chromosome 1 were reported in one patient with Maffucci syndrome [53]. Robinson et al showed an increased number of nerve fibers in tumors as well as in normal tissue of Maffucci patients, while in enchondroma and haemangioma tissue numerous methionine enkephalin positive nerves were detected, serving as a growth factor for cartilage proliferation [54]. In total, 26 patients with Maffucci syndrome were screened for mutations in *PTH1R* and revealed absence of mutation [23,55].

**Figure 3 Maffucci Syndrome**



(A) Hand of a patient with Maffucci syndrome showing deformities due to multiple enchondromas and a superficial haemangioma. (B) Radiograph of a patient with Maffucci syndrome. Multiple enchondromas with and without soft tissue extension in the second to fifth digit and the fifth metacarpal bone. In addition phleboliths in the soft tissue at the basis of the second and fourth finger (arrows) indicating haemangiomas. (C) Histology of enchondroma and (D) Haemangioma (400 times magnification).

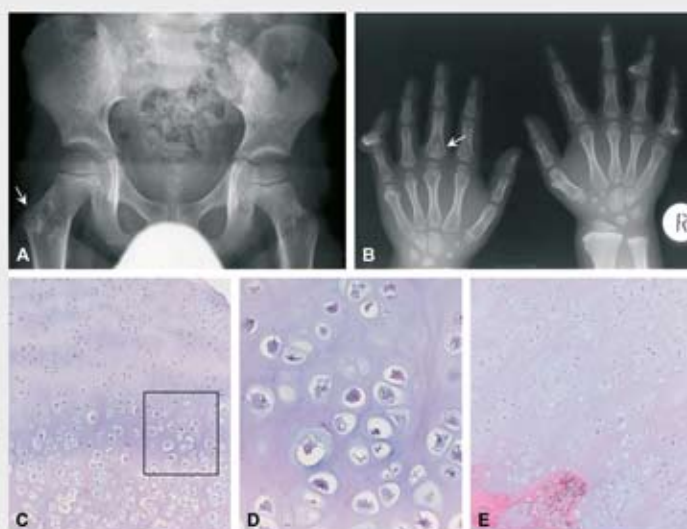
**Table 3 Non-cartilaginous and non-vascular neoplasms associated with Maffucci syndrome**

Associated tumors	No. of patients	References
Astrocytoma	6	[38,50,111-113]
Pituitary adenoma	4	[50,114-116]
Juvenile granulosa cell tumor	6	[50,117-120]
Pancreatic adenocarcinoma	3	[38,50,121]
Adrenal adenoma	1	[50]
Intracranial chordoma	1	[122]
Biliary adenocarcinoma	1	[38]
Olfactory neuroblastoma	1	[123]
Paraganglioma	1	[124]
Fibrosarcoma	1	[50]
Thyroid adenoma	1	[51]
Hepatic adenocarcinoma	1	[121]
Fibro adenoma breast	2	[125]
Breast carcinoma	1	[114]
Squamous cell carcinoma	1	[126]
Fibroadenoma of thorax and canalicular adenoma	1	[127]
Acute myeloblastic leukemia	1	[51]
Lymphoid leukemia	1	[128]
Ovarian fibrosarcoma	1	[129]

### Metachondromatosis

This rare hereditary condition displays a combination of multiple enchondromas with multiple osteochondroma-like lesions [32,56,57] (MIM 156250, enchondromatosis Spranger type III). The enchondromas mainly involve the iliac crests and metaphyses of the long bones of the lower extremities while the osteochondroma-like lesions are mainly located in hands and feet [58]. The syndrome manifests early in childhood [59,60]. In contrast to conventional osteochondromas, the osteochondroma-like lesions in metachondromatosis point towards the joint, do not cause bone deformities, and may regress spontaneously [3,59] (Figure 4). Importantly, malignant transformation has not been reported. Avascular necrosis of the femoral epiphysis can be found due to interference with the integrity of the lateral epiphyseal vessels by enchondromas [59,61-63].

**Figure 4 Metachondromatosis**



(A) Radiograph of the pelvis with an enchondroma in the right proximal femur (arrow) adjacent to the apophysis of the greater trochanter; (B) radiograph of both hands showing multiple osteochondromas pointing towards the epiphyses. Enchondroma in the proximal phalanx of the left third digit (arrow); (C, E) micrographs of osteochondroma-like lesions (D) magnification of C. These lesions are histologically indistinguishable from conventional osteochondroma recapitulating the normal growth plate architecture (reproduced with permission from [64]).

The mode of inheritance is autosomal dominant but the underlying gene has not been identified so far, due to the extreme rarity of the disease. In a single case, mutations in the EXT genes causing multiple osteochondromas were absent and EXT mRNA expression levels were normal. IHH/PTHLH signaling was normally active in two cases. These data suggest that EXT related pathways are not involved in the pathogenesis of metachondromatosis [64].

### **Genochondromatosis**

Genochondromatosis is an extremely rare autosomal dominant disorder manifesting itself in childhood [65](MIM 137360). Patients have normal stature and enchondromas are distributed symmetrically with characteristic localization in the metaphyses of the proximal humerus and distal femur. Two subtypes are distinguished: genochondromatosis type I includes the presence of a chondroma on the medial side of the clavicle while in type II the short tubular bones of the hand, wrist and feet are affected while the clavicle is normal [65-68]. The enchondroma like lesions will not lead to any bone deformities, may be discovered accidentally, and tend to regress in adulthood [65] in which they differ from the enchondromas in the other subtypes. Moreover, no malignancies associated with genochondromatosis have been described in the literature. No spinal involvement is reported which emphasizes it being different from spondyloenchondrodysplasia, cheirospondyloenchondromatosis and dyspondyloenchondromatosis [3]. No genetic studies have been reported for this rare subtype.

### **Spondyloenchondrodysplasia**

Spondyloenchondrodysplasia (SPENCD, enchondromatosis Spranger type IV) is an autosomal recessive inherited disorder characterized by vertebral dysplasia combined with enchondroma like lesions in the pelvis or long tubular bones (MIM 271550) [32,69-81]. Estimated prevalence is higher in Israel [77]. The spinal aberrations include platyspondyly; flat, often rectangular vertebral bodies are seen at radiography with irregular areas of increased and decreased mineralization, and short broad ilia. Spondyloenchondrodysplasia can manifest itself from birth to later infancy [71]. Patients usually have a short stature (short limbs), with increased lumbar lordosis, barrel chest and kyphoscoliosis, genua valga or vara, facial anomalies, and may show clumsy movements [3]. Type I is classic, and type II also affects the central nervous system including spasticity, developmental delay, and lateonset cerebral calcifications [76,81]. In addition, clinical manifestation of autoimmunity can be seen. The spine is less severely affected as compared with dyspondyloenchondromatosis and cheirospondyloenchondromatosis, in which the vertebral lesions are less uniform and the ilia are not short [3].

The clinical features of spondyloenchondrodysplasia are highly variable within and between the families; neurological and autoimmune manifestations were seen in different combinations within one single family suggesting remarkable pleiotropic manifestations of a single disease [81]. In addition, there are two reports suggesting an association of spondyloenchondromatosis with D-2-hydroxyglutaric aciduria, a neurometabolic disorder [82,83]. Although the disease is thought to be autosomal recessive, an autosomal dominant inheritance pattern has also been described [77,80].

### **Cheirospodyloenchondromatosis**

Cheirospodyloenchondromatosis (generalized enchondromatosis with platyspondyly, enchondromatosis Spranger type VI) combines symmetrically distributed multiple enchondromas with marked involvement of metacarpals and phalanges resulting in short hands and feet with mild platyspondyly [3,32]. It occurs at very early age. There is mild to moderate dwarfism and joints, especially of the fingers, become enlarged. Mental retardation is frequently seen. Genetic transmission is unknown [3].

### **Dysspondyloenchondromatosis**

Dysspondyloenchondromatosis (enchondromatosis with irregular vertebral lesions, enchondromatosis type V) is a nonhereditary disorder characterized by spondyloenchondromatosis combined with malformation of the spine [3,32,70,80,84]. The irregularity of the vertebral anomalies differentiates dysspondyloenchondromatosis from other enchondromatosis with spinal involvement. Severe segmentation abnormalities and secondary deformities of the vertebral column can be seen [3]. In addition, neonatal dwarfism, unequal limb length or asymmetric limb shortening, a flat midface with a frontal prominence, and progressive kyphoscoliosis can be found [3,80,85]. Multiple enchondromas are present in the long tubular and flat bones while the bones of hands and feet are not or only mildly affected. The disease manifests itself at birth. Haga et al reported a case with dysspondyloenchondromatosis along with Maffucci syndrome in one patient [86] which suggests that these two different syndromes may be part of one spectrum caused by a pleiotropic gene. Malignant transformation is not yet reported in the literature.

### **Other less well delineated subtypes**

Halal and Azouz provisionally added three more subtypes to the Spranger classification including generalized enchondromatosis with irregular vertebral lesions (type VII), generalized enchondromatosis with mucopolysaccharides (type VIII) and enchondromatosis with concave vertebral bodies (type IX), all of which are non-hereditary [87]. Gabos and Bowen describe 8 patients with extensive unilateral involvement of epiphyseal and metaphyseal regions by enchondromas appearing before growth plate closure leading to severe deformity. It is however unclear whether this is a variant of Ollier disease, or that it should be classified separately as epiphysealmetaphyseal enchondromatosis as proposed by the authors [88]. In addition, metaphyseal chondrodysplasia, Vandraager Pena type may also be considered an enchondromatosis subtype (MIM 250300) [89] although it is more often considered a subtype of metaphyseal dysplasia. It is an autosomal recessive disorder in which the metaphyses of the long bones have an extensive sponge like appearance at radiographs while histologically numerous islands of cartilage reminiscent of enchondromatosis are seen [89].

### **Conclusions**

Many different syndromes are present with multiple enchondromas, and most of them are extremely rare. None of these syndromes seem to be determined by a simple mendelian manner, and it is unclear whether they represent separate entities, or that they are manifestations of a single causal process. Since they all share the occurrence of multiple enchondromas, this may suggest that the same gene or gene family may be involved in at least a proportion of the different types of enchondromatosis.

It can be expected that within the upcoming era of next generation sequencing approaches, elucidating the genes causing rare genetic disorders, also the gene(s) that causes the different enchondromatosis subtypes may be identified. Adequate classification of the different enchondromatosis subtypes as reviewed here is not only relevant for clinical management with regards to genetic counseling and the risk of malignant transformation, but also to allow future molecular studies to reveal whether (a proportion of) the different subtypes are different ends of a spectrum caused by a pleiotropic single gene, or that they truly represent separate disease entities.

**Note added in proof**

Sobreira et al recently reported mutations in the *PTPN11* gene in two metachondromatosis families (PLOS Genet, 2010;6;6). Future studies should reveal whether this gene is also involved in other enchondromatosis subtypes.

**Acknowledgements**

We are thankful to S.H.M Verdegaal and R. J. Grimer for kindly providing Figure 3A and Henk Jan van der Woude for Figure 3B. Our work on enchondromatosis is supported by The Netherlands Organization for Scientific Research (917-76-315) and is performed within EuroBoNet, a European Commission granted Network of Excellence for studying the pathology and genetics of bone tumors (018814).

## References

1. Lucas DR, Bridge JA: Chondromas: enchondroma, periosteal chondroma, and enchondromatosis. World Health Organization classification of tumours. Pathology and genetics of tumours of soft tissue and bone. Edited by Fletcher CDM, Unni KK, Mertens F. Lyon: IARC Press, 2002, pp. 237-40.
2. Silve C, Juppner H. Ollier disease. *Orphanet J Rare Dis* 2006; 1: 37.
3. Spranger JW, Brill PW, Poznanski AK Bone Dysplasias. An Atlas of Genetic Disorders of Skeletal Development. second ed. New York: Oxford University Press; 2002, pp. 554-70.
4. Unni KK. Cartilaginous lesions of bone. *J Orthop Sci* 2001; 6: 457-72.
5. Loder RT, Sundberg S, Gabriel K, Mehrood A, Meyer C. Determination of bone age in children with cartilaginous dysplasia (multiple hereditary osteochondromatosis and Ollier's enchondromatosis). *J Pediatr Orthop* 2004; 24: 102-8.
6. Shapiro F. Ollier's Disease. An assessment of angular deformity, shortening, and pathological fracture in twenty-one patients. *J Bone Joint Surg Am* 1982; 64: 95-103.
7. Watanabe K, Tsuchiya H, Sakurakichi K, Yamashiro T, Matsubara H, Tomita K. Treatment of lower limb deformities and limb-length discrepancies with the external fixator in Ollier's disease. *J Orthop Sci* 2007; 12: 471-5.
8. Baumgart R, Burklein D, Hinterwimmer S, Thaller P, Mutschler W. The management of leg length discrepancy in Ollier's disease with a fully implantable lengthening nail. *J Bone Joint Surg Br* 2005; 87: 1000-4.
9. Van LP, Lammens J. Malformation of the humerus in a patient with Ollier disease treated with the Ilizarov technique. *J Shoulder Elbow Surg* 2008; 17: e9-11.
10. Urist MR. A 37-year follow-up evaluation of multiple stage femur and tibia lengthening in dyschondroplasia (enchondromatosis) with a net gain of 23.3 centimeters. *Clin Orthop Relat Res* 1989; 137-57.
11. Pandey R, White SH, Kenwright J. Callus distraction in Ollier's disease. *Acta Orthop Scand* 1995; 66: 479-80.
12. Martson A, Haviko T, Kirjanen K. Extensive limb lengthening in Ollier's disease: 25-year followup. *Medicina (Kaunas)* 2005; 41: 861-6.
13. Bertoni F, Bacchini P, Hogendoorn PCW: Chondrosarcoma. World Health Organisation classification of tumours. Pathology and genetics of tumours of soft tissue and bone. Edited by Fletcher CDM, Unni KK, Mertens F. Lyon: IARC Press, 2002, pp. 247-51.
14. D'Angelo L, Massimi L, Narducci A, Di RC. Ollier disease. *Childs Nerv Syst* 2009; 25: 647-53.
15. Geirnaerd MJ, Hogendoorn PCW, Bloem JL, Taminiau AHM, Van der Woude HJ. Cartilaginous tumors: fast contrast-enhanced MR imaging. *Radiology* 2000; 214: 539-46.
16. Eelting D, Schrage YM, Geirnaerd MJ, Le Cessie S, Taminiau AH, Bovee JVMG, Hogendoorn PCW. Assessment of interobserver variability and histologic parameters to improve reliability in classification and grading of central cartilaginous tumors. *Am J Surg Pathol* 2009; 33: 50-7.
17. Reliability of Histopathologic and Radiologic Grading of Cartilaginous Neoplasms in Long Bones. *J Bone Joint Surg Am* 2007; 89-A: 2113-23.
18. Veth R, Schreuder B, van Beem H, Pruszczynski M, de Rooy J. Cryosurgery in aggressive, benign, and low-grade malignant bone tumours. *Lancet Oncol* 2005; 6: 25-34.
19. Rozeman LB, Hameetman L, van Wezel T, Taminiau AHM, Cleton-Jansen AM, Hogendoorn PCW, Bovee JVMG. cDNA expression profiling of central chondrosarcomas: Ollier disease resembles solitary tumors and alteration in genes coding for energy metabolism with increasing grade. *J Pathol* 2005; 207: 61-71.
20. Hopyan S, Gokgoz N, Poon R, Gensure RC, Yu C, Cole WG, Bell RS, Juppner H, Andrusis IL, Wunder JS, Alman BA. A mutant PTH/PTHrP type I receptor in enchondromatosis. *Nat Genet* 2002; 30: 306-10.

21. Schrage YM, Hameetman L, Szuhai K, Cleton Jansen AM, Taminiau AHM, Hogendoorn PCW, Bovée JVMG. Aberrant heparan sulfate proteoglycan localization, despite normal exostosin, in central chondrosarcoma. *Am J Pathol* 2009; 174: 979-88.
22. Couvineau A, Wouters V, Bertrand G, Rouyer C, Gerard B, Boon LM, Grandchamp B, Vikkula M, Silve C. PTHR1 mutations associated with Ollier disease result in receptor loss of function. *Hum Mol Genet* 2008; 17: 2766-75.
23. Rozeman LB, Sangiorgi L, Bruijn IH, Mainil Varlet P, Bertoni F, Cleton-Jansen AM, Hogendoorn PC, Bovée JVMG. Enchondromatosis (Ollier disease, Maffucci syndrome) is not caused by the PTHR1 mutation p.R150C. *Hum Mutat* 2004; 24: 466-73.
24. Alexandre C, Jacinto A, Ingham PW. Transcriptional activation of hedgehog target genes in *Drosophila* is mediated directly by the cubitus interruptus protein, a member of the GLI family of zinc finger DNA-binding proteins. *Genes Dev* 1996; 10: 2003-13.
25. Vortkamp A, Lee K, Lanske B, Segre GV, Kronenberg HM, Tabin CJ. Regulation of rate of cartilage differentiation by indian hedgehog and PTH-related protein. *Science* 1996; 273: 613-22.
26. Amling M, Neff L, Tanaka S, Inoue D, Kuida K, Weir E, Philbrick WM, Broadus AE, Baron R. Bcl 2 lies downstream of parathyroid hormone related peptide in a signalling pathway that regulates chondrocyte maturation during skeletal development. *J Cell Biol* 1997; 136: 205-13.
27. Bovée JVMG, Van den Broek LJC, Cleton Jansen AM, Hogendoorn PCW. Up-regulation of PTHrP and Bcl-2 expression characterizes the progression of osteochondroma towards peripheral chondrosarcoma and is a late event in central chondrosarcoma. *Lab Invest* 2000; 80: 1925-33.
28. Ahn J, Ludecke H-J, Lindow S, Horton WA, Lee B, Wagner MJ, Horsthemke B, Wells DE. Cloning of the putative tumour suppressor gene for hereditary multiple exostoses (EXT1). *Nature Genet* 1995; 11: 137-43.
29. Stickens D, Clines G, Burbee D, Ramos P, Thomas S, Hogue D, Hecht JT, Lovett M, Evans GA. The EXT2 multiple exostoses gene defines a family of putative tumour suppressor genes. *Nature Genet* 1996; 14: 25-32.
30. Wuyts W, Van Hul W, De Boulle K, Hendrickx J, Bakker E, Vanhoenacker F, Mollica F, Ludecke H-J, Sitki Sayli B, Pazzaglia UE, Mortier G, Hamel B, Conrad EU, Matsushita M, Raskind WH, Willems PJ. Mutations in the EXT1 and EXT2 genes in hereditary multiple exostoses. *Am J Hum Genet* 1998; 62: 346-54.
31. Ollier M. De la dyschondroplasia. *Bull Soc Chir Lyon* 1899; 3: 22-3.
32. Spranger J, Kemperdieck H, Bakowski H, Opitz JM. Two peculiar types of enchondromatosis. *Pediatr Radiol* 1978; 7: 215-9.
33. Flemming DJ, Murphey MD. Enchondroma and chondrosarcoma. *Semin Musculoskelet Radiol* 2000; 4: 59-71.
34. Mertens F, Unni KK. Enchondromatosis; Ollier disease and Maffucci syndrome. *World Health Organization Classification of Tumours. Pathology and genetics of tumours of soft tissue and bone*. Edited by Fletcher CDM, Unni KK, Mertens F. Lyon: IARC Press, 2002, pp. 356-7.
35. ROSSBERG A. [Heredity of osteochondromas.]. *Fortschr Geb Rontgenstr Nuklearmed* 1959; 90: 138-9.
36. CARBONELL JM, VINETA TJ. [A further case of congenital generalized dyschondrotheosis, Ollier type.]. *Rev Esp Pediatr* 1962; 18: 91-9.
37. Lamy M, Aussannaire M, Jammet ml, Nezelof C. [Three cases of Ollier's disease in one family.]. *Bull Mem Soc Med Hop Paris* 1954; 70: 62-70.
38. Schwartz HS, Zimmerman NB, Simon MA, Wroble RR, Millar EA, Bonfiglio M. The malign nant potential of enchondromatosis. *J Bone Joint Surg Am* 1987; 69: 269-74.
39. Schaison F, Anract P, Coste F, De PG, Forest M, Tomeno B. [Chondrosarcoma secondary to multiple cartilage diseases. Study of 29 clinical cases and review of the literature]. *Rev Chir Orthop Reparatrice Appar Mot* 1999; 85: 834-45.
40. Rozeman LB, Hogendoorn PCW, Bovée JVMG. Diagnosis and prognosis of chondrosarcoma of bone. *Expert Rev Mol Diagn* 2002; 2: 461-72.
41. Liu J, Hudkins PJ, Swee RG, Unni KK. Bone sarcomas associated with Ollier's disease. *Cancer* 1987; 59: 1376-85.

42. Bukte Y, Necmioğlu S, Nazaroğlu H, Kilinc N, Yılmaz F. A case of multiple chondrosarcomas secondary to severe multiple symmetrical enchondromatosis (Ollier's disease) at an early age. *Clin Radiol* 2005; 60: 1306-10.
43. Ranger A, Szymczak A. Do intracranial neoplasms differ in Ollier disease and maffucci syndrome? An in-depth analysis of the literature. *Neurosurgery* 2009; 65: 1106-13.
44. Riminucci M, Saggio I, Robey PG, Bianco P. Fibrous dysplasia as a stem cell disease. *J Bone Miner Res* 2006; 21 Suppl 2: 125-31.
45. Cohen MM, Jr., Siegal GP; McCune-Albright syndrome. World Health Organization Classification of Tumours. Pathology & Genetics. Tumours of Soft Tissue and Bone. Edited by Fletcher C.D.M, Unni KK, Mertens F. Lyon: IARC Press, 2002, pp. 357-9.
46. Maffucci A. Di un caso encondroma ed angioma multiplo. *Movimento medico-chirurgico, Napoli* 1881; 3: 399-412; 565-575.
47. Mertens F, Unni KK: Congenital and inherited syndromes associated with bone and soft tissue tumours: Enchondromatosis. World Health Organisation classification of tumours. Pathology and genetics of tumours of soft tissue and bone. Edited by Fletcher CDM, Unni KK, Mertens F. Lyon: IARC Press, 2002, pp. 356-7.
48. Auyeung J, Mohanty K, Tayton K. Maffucci lymphangioma syndrome: an unusual variant of Ollier's. *J Pediatr Orthop B* 2003; 12: 147-50.
49. Zwenneke FH, Ginai AZ, Wolter OJ. Best cases from the AFIP: Maffucci syndrome: radiologic and pathologic findings. *Armed Forces Institutes of Pathology. RadioGraphics* 2001; 21: 1311-6.
50. Lewis RJ, Ketcham AS. Maffucci's syndrome: functional and neoplastic significance. Case report and review of the literature. *J Bone Joint Surg Am* 1973; 55: 1465-79.
51. Fanburg JC, Meis-Kindblom JM, Rosenberg AE. Multiple enchondromas associated with spindle cell hemangi endotheliomas. An overlooked variant of Maffucci's syndrome. *Am J Surg Pathol* 1995; 19: 1029-38.
52. Perkins P, Weiss SW. Spindle cell hemangi endothelioma. An analysis of 78 cases with reassessment of its pathogenesis and biologic behavior. *Am J Surg Pathol* 1996; 20: 1196-204.
53. Matsumoto N, Fukushima T, Tomonaga M, Imamura M. [Maffucci's syndrome with intracranial manifestation and chromosome abnormalities a case report]. *No Shinkei Geka* 1986; 14: 403-10.
54. Robinson D, Tieder M, Halperin N, Burshtein D, Nevo Z. Maffucci's syndrome--the result of neural abnormalities? Evidence of mitogenic neurotransmitters present in enchondromas and soft tissue hemangiomas. *Cancer* 1994; 74: 949-57.
55. Couvineau A, Wouters V, Bertrand G, Rouyer C, Gerard B, Boon LM, Grandchamp B, Vikkula M, Silve C. PTHR1 mutations associated with Ollier disease result in receptor loss of function. *Hum Mol Genet* 2008; 17: 2766-75.
56. Maroteaux P. [Metachondromatosis]. *Z Kinderheilkd* 1971; 109: 246-61.
57. Kennedy LA. Metachondromatosis. *Radiology* 1983; 148: 117-8.
58. Wittram C, Carty H. Metachondromatosis. *Pediatr Radiol* 1995; 25 Suppl 1: S138-S139.
59. Bassett GS, Cowell HR. Metachondromatosis. Report of four cases. *J Bone Joint Surg Am* 1985; 67: 811-4.
60. Beals RK. Metachondromatosis. *Clin Orthop Relat Res* 1982; 167-70.
61. Keret D, Bassett GS. Avascular necrosis of the capital femoral epiphysis in metachondromatosis. *J Pediatr Orthop* 1990; 10: 658-61.
62. Wenger DR, Birch J, Rathjen K, Tobin R, Billman G. Metachondromatosis and avascular necrosis of the femoral head: a radiographic and histologic correlation. *J Pediatr Orthop* 1991; 11: 294-300.
63. Ikegawa S, Nagano A, Matsushita T, Nakamura K. Metachondromatosis: a report of two cases in a family. *Nippon Seikeigeka Gakkai Zasshi* 1992; 66: 460-6.
64. Bovee JVMG, Hameetman L, Kroon HM, Aigner T, Hogendoorn PCW. EXT-related pathways are not involved in the pathogenesis of dysplasia epiphysealis hemimelica and metachondromatosis. *J Pathol* 2006; 209: 411-9.
65. Le Merrer M, Fressinger P, Maroteaux P. Genochondromatosis. *J Med Genet* 1991; 28: 485-9.

66. Kozłowski KS, Masel J. Distinctive enchondromatosis with spine abnormality, regressive lesions, short stature, and coxa vara: importance of long-term follow-up. *Am J Med Genet* 2002; 107: 227-32.
67. Kozłowski K, Jarrett J. Genochondromatosis II. *Pediatr Radiol* 1992; 22: 593-5.
68. Isidor B, Guillard S, Hamel A, Le CC, David A. Genochondromatosis type II: report of a new patient and further delineation of the phenotype. *Am J Med Genet A* 2007; 143A: 1919-21.
69. Schorr S, Legum C, Ochshorn M. Spondyloenchondrodysplasia. Enchondromatosis with severe platyspondyly in two brothers. *Radiology* 1976; 118: 133-9.
70. Uhlmann D, Rupprecht E, Keller E, Hormann D. Spondyloenchondrodysplasia: several phenotypes the same syndrome. *Pediatr Radiol* 1998; 28: 617-21.
71. Menger H, Kruse K, Spranger J. Spondyloenchondrodysplasia. *J Med Genet* 1989; 26: 93-9.
72. Gustavson KH, Holmgren G, Probst F. Spondylometaphyseal dysplasia in two sibs of normal parents. *Pediatr Radiol* 1978; 7: 90-6.
73. Sauvegrain J, Maroteaux P, Ribier J, Garel L, Tato L, Rochiccioli P, de Magalhaes J, Duhamel B. [Multiple chondroma affecting the spine: spondylo-enchondroplasia and other forms (author's trans)]. *J Radiol* 1980; 61: 495-501.
74. Chagnon S, Lacerp P, Blery M. [Spondyloenchondrodysplasia]. *J Radiol* 1985; 66: 75-7.
75. Ziv N, Grunebaum M, Kornreich L, Mirmouni M. Case report 512: Spondyloenchondrodysplasia (SED) in two siblings. *Skeletal Radiol* 1989; 17: 598-600.
76. Frydman M, Bar-Ziv J, Preminger-Shapiro R, Brezner A, Brand N, Ben-Ami T, Lachman RS, Gruber HE, Rimoin DL. Possible heterogeneity in spondyloenchondrodysplasia: quadriparesis, basal ganglia calcifications, and chondrocyte inclusions. *Am J Med Genet* 1990; 36: 279-84.
77. Robinson D, Tieder M, Copeliovitch L, Halperin N. Spondyloenchondrodysplasia. A rare cause of short-trunk syndrome. *Acta Orthop Scand* 1991; 62: 375-8.
78. Zack P, Beighton P. Spondyloenchondromatosis: syndromic identity and evolution of the phenotype. *Am J Med Genet* 1995; 55: 478-82.
79. Tuysuz B, Arapoglu M, Ungur S. Spondyloenchondrodysplasia: clinical variability in three cases. *Am J Med Genet A* 2004; 128A: 185-9.
80. Bhargava R, Leonard NJ, Chan AK, Spranger J. Autosomal dominant inheritance of spondyloenchondrodysplasia. *Am J Med Genet A* 2005; 135: 282-8.
81. Renella R, Schaefer E, Lemerrer M, Alanay Y, Kandemir N, Eich G, Costa T, Ballhausen D, Boltshauser E, Bonafe L, Giedion A, Unger S, Superti-Furga A. Spondyloenchondrodysplasia with spasticity, cerebral calcifications, and immune dysregulation: clinical and radiographic delineation of a pleiotropic disorder. *Am J Med Genet A* 2006; 140: 541-50.
82. Honey EM, van RM, Knoll DP, Mienie LJ, van dW, I, Beighton P. Spondyloenchondromatosis with D-2-hydroxyglutaric aciduria: a report of a second patient with this unusual combination. *Clin Dysmorphol* 2003; 12: 95-9.
83. Talkhani IS, Saklatvala J, Dwyer J. D-2- hydroxyglutaric aciduria in association with spondyloenchondromatosis. *Skeletal Radiol* 2000; 29: 289-92.
84. Freisinger P, Finidori G, Maroteaux P. Dysspondyloenchondromatosis. *Am J Med Genet* 1993; 45: 460-4.
85. Kozłowski K, Brostrom K, Kennedy J, Lange H, Morris L. Dysspondyloenchondromatosis in the newborn. Report of four cases. *Pediatr Radiol* 1994; 24: 311-5.
86. Haga N, Nakamura K, Taniguchi K, Nakamura S. Enchondromatosis with features of dysspondyloenchondromatosis and Maffucci syndrome. *Clin Dysmorphol* 1998; 7: 65-8.
87. Halal F, Azouz EM. Generalized enchondromatosis in a boy with only platyspondyly in the father. *Am J Med Genet* 1991; 38: 588-92.

88. Gabos PG, Bowen JR. Epiphyseal-metaphyseal enchondromatosis. A new clinical entity. *J Bone Joint Surg Am* 1998; 80: 782-92.
89. Spranger JW. Metaphyseal chondrodysplasia. *Postgrad Med J* 1977; 53: 480-7.
90. Walid MS, Troup EC. Cerebellar anaplastic astrocytoma in a teenager with Ollier Disease. *J Neurooncol* 2008; 89: 59-62.
91. Patt S, Weigel K, Mayer HM. A case of dyschondroplasia associated with brain stem glioma: diagnosis by stereotactic biopsy. *Neurosurgery* 1990; 27: 487-91.
92. Rawlings CE, III, Bullard DE, Burger PC, Friedman AH. A case of Ollier's disease associated with two intracranial gliomas. *Neurosurgery* 1987; 21: 400-3.
93. Bendel CJ, Gelmers HJ. Multiple enchondromatosis (Ollier's disease) complicated by malignant astrocytoma. *Eur J Radiol* 1991; 12: 135-7.
94. Mellon CD, Carter JE, Owen DB. Ollier's disease and Maffucci's syndrome: distinct entities or a continuum. Case report: enchondromatosis complicated by an intracranial glioma. *J Neurol* 1988; 235: 376-8.
95. Mahafza WS. Multiple enchondromatosis Ollier's disease with two primary brain tumors. *Saudi Med J* 2004; 25: 1261-3.
96. Hofman S, Heeg M, Klein JP, Krikke AP. Simultaneous occurrence of a supra- and an infratentorial glioma in a patient with Ollier's disease: more evidence for non-mesodermal tumor predisposition in multiple enchondromatosis. *Skeletal Radiol* 1998; 27: 688-91.
97. Chang S, Prados MD. Identical twins with Ollier's disease and intracranial gliomas: case report. *Neurosurgery* 1994; 34: 903-6.
98. van Nielen KM, de Jong BM. A case of Ollier's disease associated with two intracerebral lowgrade gliomas. *Clin Neurol Neurosurg* 1999; 101: 106-10.
99. Frappaz D, Ricci AC, Kohler R, Bret P, Mottolese C. Diffuse brain stem tumor in an adolescent with multiple enchondromatosis (Ollier's disease). *Childs Nerv Syst* 1999; 15: 222-5.
100. Rietveld L, Nieboer TE, Kluijvers KB, Schreuder HW, Bulten J, Massuger LF. First case of juvenile granulosa cell tumor in an adult with Ollier disease. *Int J Gynecol Pathol* 2009; 28: 464-7.
101. Leyva-Carmona M, Vazquez-Lopez MA, Lendinez Molinos F. Ovarian juvenile granulosa cell tumors in infants. *J Pediatr Hematol Oncol* 2009; 31: 304-6.
102. Vaz RM, Turner C. Ollier disease (enchondromatosis) associated with ovarian juvenile granulosa cell tumor and precocious pseudopuberty. *J Pediatr* 1986; 108: 945-7.
103. Tamimi HK, Bolen JW. Enchondromatosis (Ollier's disease) and ovarian juvenile granulosa cell tumor. *Cancer* 1984; 53: 1605-8.
104. Le GC, Bouvier R, Chappuis JP, Hermier M. [Ollier's disease and juvenile ovarian granulosa tumor]. *Arch Fr Pediatr* 1991; 48: 115-8.
105. Gell JS, Stannard MW, Ramnani DM, Bradshaw KD. Juvenile granulosa cell tumor in a 13-year-old girl with enchondromatosis (Ollier's disease): a case report. *J Pediatr Adolesc Gynecol* 1998; 11: 147-50.
106. Sendur OF, Turan Y, Odabasi BB, Berkil IK. A case of Ollier disease with non-small cell lung cancer and review of the literature. *Rheumatol Int* 2010; 30: 699-703.
107. Balcer LJ, Galetta SL, Cornblath WT, Liu GT. Neuro-ophthalmologic manifestations of Maffucci's syndrome and Ollier's disease. *J Neuroophthalmol* 1999; 19: 62-6.
1108. Ozisik YY, Meloni AM, Spanier SS, Bush CH, Kingsley KL, Sandberg AA. Deletion 1p in a lowgrade chondrosarcoma in a patient with Ollier disease. *Cancer Genet Cytogenet* 1998; 105: 128-33.
109. Bovee JV, van Roggen JF, Cleton-Jansen AM, Taminiau AH, Van der Woude HJ, Hogendoorn PC. Malignant progression in multiple enchondromatosis (Ollier's disease): an autopsy-based molecular genetic study. *Hum Pathol* 2000; 31: 1299-303.
110. Rozeman LB, Szuhai K, Schrage YM, Rosenberg C, Tanke HJ, Taminiau AHM, Cleton-Jansen AM, Bovee JVMG, Hogendoorn PCW. Arraycomparative genomic hybridization of central chondrosarcoma. Identification of ribosomal protein S6 and cyclin-dependent kinase 4 as candidate target genes for genomic aberrations. *Cancer* 2006; 107: 380-8.

111. Jirattanaphochai K, Jitpimolmard S, Jirattanaphochai K. Maffucci's syndrome with frontal lobe astrocytoma. *J Med Assoc Thai* 1990; 73: 288-93.
112. Goto H, Ito Y, Hirayama A, Sakamoto T, Kowada M. [Maffucci's syndrome associated with primary brain tumor; report of a case]. *No Shinkei Geka* 1987; 15: 971-5.
113. Cremer H, Gullotta F, Wolf L. The Maffucci-Kast Syndrome. Dyschondroplasia with hemangiomas and frontal lobe astrocytoma. *J Cancer Res Clin Oncol* 1981; 101: 231-7.
114. Marymont JV, Fisher RF, Emde GE, Limbird TJ. Maffucci's syndrome complicated by carcinoma of the breast, pituitary adenoma, and mediastinal hemangioma. *South Med J* 1987; 80: 1429 -31.
115. Miki K, Kawamoto K, Kawamura Y, Matsumura H, Asada Y, Hamada A. A rare case of Maffucci's syndrome combined with tuberculum sellae enchondroma, pituitary adenoma and thyroid adenoma. *Acta Neurochir (Wien)* 1987; 87: 79-85.
116. Ruivo J, Antunes JL. Maffucci syndrome associated with a pituitary adenoma and a probable brainstem tumor. *J Neurosurg* 2009; 110: 363-8.
117. Tanaka Y, Sasaki Y, Nishihira H, Izawa T, Nishi T. Ovarian juvenile granulosa cell tumor associated with Maffucci's. *Am J Clin Pathol* 1992; 97: 523-7.
118. Hamdoun L, Mouelhi C, Zhioua F, Jedoui A, Meriah S, Houet S. [Maffucci syndrome and ovarian tumor]. *Bull Cancer* 1993; 80: 816-9.
119. Hachi H, Othmany A, Douayri A, Bouchikhi C, Tijami F, Laalou L, Chami M, Boughtab A, Jalil A, Benjelloun S, Ahyoud F, Kettani F, Souadka A. [Association of ovarian juvenile granulosa cell tumor with Maffucci's syndrome]. *Gynecol Obstet Fertil* 2002; 30: 692-5.
120. Yuan JD, Lin XN, Xu JY, Zhu J, Zheng WL. Ovarian juvenile granulosa cell tumor associated with Maffucci's syndrome: case report. *Chin Med J (Engl)* 2004; 117: 1592-4.
121. Sun TS, Swee RG, Shives TC, Unni KK. Chondrosarcoma in Maffucci's syndrome. *J Bone Joint Surg* 1985; 67A: 1214-9.
122. Nakayama Y, Takeno Y, Tsugu H, Tomonaga M. Maffucci's syndrome associated with intracranial chordoma: case. *Neurosurgery* 1994; 34: 907-9.
123. Kurian S, Ertan E, Ducatman B, Crowell EB, Rassekh C. Esthesioneuroblastoma in Maffucci's syndrome. *Skeletal Radiol* 2004; 33: 609-12.
124. Lamovec J, Frkovic-Grazio S, Bracko M. Nonsporadic cases and unusual morphological features in. *Arch Pathol Lab Med* 1998; 122: 63-8.
125. Cheng FC, Tsang PH, Shum JDOGB. Maffucci's syndrome with fibroadenomas of the breast. *J Roy Coll Surg Edinburgh* 1981; 26: 181-3.
126. Yazidi A, Benzekri L, Senouci K, Bennouna-Biaz F, Hassam B. [Maffucci syndrome associated with epidermoid carcinoma of the nasopharynx]. *Ann Dermatol Venereol* 1998; 125: 50-1.
127. Strzalka M, Drozd W, Kulawik J. [Maffucci's syndrome with giant tumor of the thoracic wall]. *Przegl Lek* 2003; 60 Suppl 7:77-80.: 77-80.
128. Rector JT, Gray CL, Sharpe RW, Hall FW, Thomas W, Jones W. Acute lymphoid leukemia associated with Maffucci's syndrome. *Am J Pediatr Hematol Oncol* 1993; 15: 427-9.
129. Christman JE, Ballon SC. Ovarian fibrosarcoma associated with Maffucci's syndrome. *Gynecol Oncol* 1990; 37: 290-1.