



Universiteit
Leiden
The Netherlands

Rotator cuff degeneration in the rheumatoid shoulder : 'the issue is soft tissue'

Sande, M.A.J. van de

Citation

Sande, M. A. J. van de. (2008, February 14). *Rotator cuff degeneration in the rheumatoid shoulder : 'the issue is soft tissue'*. Retrieved from <https://hdl.handle.net/1887/12603>

Version: Corrected Publisher's Version

License: [Licence agreement concerning inclusion of doctoral thesis in the Institutional Repository of the University of Leiden](#)

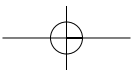
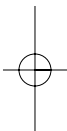
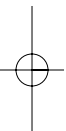
Downloaded from: <https://hdl.handle.net/1887/12603>

Note: To cite this publication please use the final published version (if applicable).

Chapter 3

New methods
in clinical and
radiological
assessment
of the rotator
cuff muscles





Quantitative analysis of Fatty Degeneration in the rotator cuff muscles determined with computed tomography.

*M.A.J. van de Sande, B.C. Stoel, W.R. Obermann, J.G.S. Tjong a Lieng, P.M. Rozing
Invest. Radiology 2005 May; 40(5): 313-9*

Summary

Reliable assessment of fatty degeneration of rotator cuff muscles is desirable to predict the outcome of shoulder surgery. Currently used qualitative assessments are limited by relatively high inter- and intraobserver variability. It was hypothesized that a quantitative measurement of muscle density using computed tomography (CT) was more reliable and reproducible. Thirty shoulders from patients with rheumatoid arthritis were analyzed using parasagittal multiplanar reconstructions acquired from a 16-slice CT scanner. Three observers visually rated the severity of fatty degeneration and independently outlined the rotator cuff muscles, after which the mean density was calculated. Inter- and intraobserver agreement on both measurements was expressed by the interclass correlation coefficient (ICC) and the standard deviation of the differences (SDD) between the measurements. A strong correlation was found between the quantitative measure and the visual rating ($R^2=0.94$; $P<0.0001$). The SDD in muscle density did not exceed 2.3 Hounsfield units, and the mean rotator cuff ICC (0.98) was substantially greater than that of the visual rating (0.63).

This study describes a reproducible method to quantify fatty degeneration of the rotator cuff muscles in CT images, with a higher interobserver agreement than the visual score, and may prove a reliable tool to evaluate the quality of the rotator cuff muscles.

Introduction

Recent studies have shown a significant negative influence of rotator cuff muscle fatty degeneration on the functional outcome of shoulder surgery.^{1; 15; 81; 119-121} These studies demonstrated that fatty degeneration was related to a higher risk of failure after tendon repair and was associated with inferior functional results in both tendon repair and shoulder arthroplasty. Other studies have shown that fatty degeneration was not improved following rotator cuff tear repair and seemed irreversible.^{8; 12}

Both studies implied that timely diagnosis and treatment of a rotator cuff tear are of great importance. Hence, an early and accurate assessment of fatty degeneration of the rotator cuff muscles is desirable to predict the outcome of shoulder arthroplasty and rotator cuff surgery. To that end, the Goutallier score was developed to qualitatively assess the extent of fatty degeneration.⁸ Reports suggest that the Goutallier score has moderate reproducibility, provided that the observer is experienced.^{17; 18} Conversely, a reliable quantitative measurement should improve the reproducibility of assessment by limiting the inter- and intraobserver variability without observer training. Quantitative measurement of fatty degeneration has been explored using signal intensity measurements in T1-weighted magnetic resonance images (MRI), but produced inconsistent results and was unreliable in assessing fatty degeneration and thus in

Quantitative analysis of Fatty Degeneration in the rotator cuff muscles determined with computed tomography

predicting rotator cuff pathology.¹⁹ A decreased cross-sectional area (CSA) of the rotator cuff muscles, indicating muscle atrophy, was related to the degree of fatty degeneration using the same parasagittal T1-weighted MRI images.^{18; 19} While both studies showed correlation between the degree of fatty degeneration and the degree of atrophy, the strength of correlation was insufficient to predict the amount of fatty degeneration based on the CSA. Computed tomography (CT) has been used to estimate the density of different tissues in various applications based on the relationship between physical density and x-ray attenuation, expressed in Hounsfield units (HU). In 2000, Goodpaster et al.¹²² used this densitometric measurement to quantify the lipid content of muscle in the lower extremities. They compared the average CT number in HU with skeletal muscle lipid content, measured by biochemical extraction of triglyceride from muscle fibres of the lower extremity and showed that the CT measurement was highly reliable.^{122; 123} They showed also that repeated measurements of muscle density in CT scans had a very small test-retest variability (SDD=0.4 HU). The precision of this measurement was calculated in an animal study which showed a high correlation between CT assessment of the fat-muscle ratio and the exact weight of fat and muscle after dissection (R2=0.95).¹²⁴ Hence, we hypothesized that CT assessment of muscle density could be used also to quantify fatty degeneration of the rotator cuff muscles and provide a more reproducible assessment of fatty degeneration than the Goutallier score. In testing this hypothesis, the correlation between the quantitative density measurement and the Goutallier score was assessed. Inter- and intraobserver variability was determined, as was the influence of CT slice selection on the outcome of measurement.

Materials and Methods

After the institutional review boards had approved the study protocol, patients were selected prospectively on the following selection criteria: a clinical diagnosis of rheumatoid arthritis (RA) being in accord with the "American Rheumatism Association criteria 1987" as all degrees of fatty degeneration are commonly seen in rheumatoid shoulders,⁵ patients aged over 50 years, at least 1 symptomatic shoulder, no prior trauma

Table 1. All rotator cuff muscles were screened for other pathologies using ultrasound and were subdivided in four different groups (16)

	SSp	ISp	SSc
None	10	15	22
Tendonitis	12	13	8
Small tear (<4 cm)	2	0	0
Massive tear (>4 cm)	6*	2	0

* Only one shoulder presented with retraction of more than 1 cm from the original insertion on the greater tuberosity.

SSp: Supraspinatus tendon

ISp: Infraspinatus tendon

SSc: Subscapularis tendon

or surgery to the shoulders being studied. The age limit was chosen as to impose the smallest risk from radiation exposure. Fifteen patients were included (30 shoulders), 5 male and 10 female, with an average age of 65 years (range: 50–80 years). All patients were informed fully and signed informed consent. The mean interval between the diagnosis of RA and the CT scan was 13 years (range: 1–40 years). To assess the influence of a rotator cuff tear or tendon retraction on the reliability of this technique, all shoulders were screened for rotator cuff pathology by an experienced muscular-skeletal radiologist using ultrasound (Table 1). Standard ultrasound methods and criteria were applied to assess rotator cuff pathology.¹²⁵

Figure 1. Parasagittal MPR reconstruction (top) of the coronal CT images (bottom) using the most lateral section on which the scapular spine was in contact with the scapular body, parallel to glenohumeral joint space.

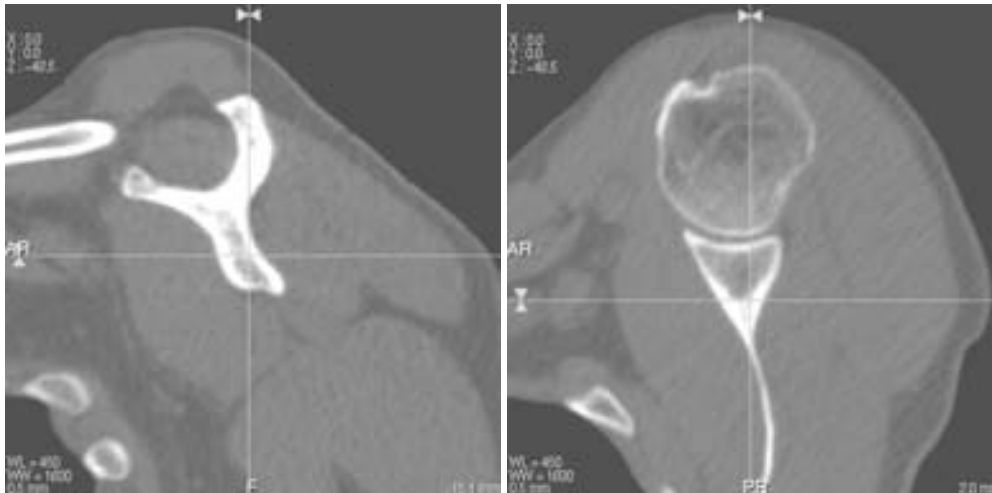


Image Acquisition

All patients were scanned successively in 1 day, using a Toshiba Aquilion 16-slice CT scanner with the same protocol and calibration technique throughout. The scanning parameters were 120 kVp, 125 mAs, field of view 250 mm, and a detector pitch of 15. A soft-tissue filter and raster artefact suppression were used, producing a 512 x 512 matrix of 1-mm-thick slices (slice overlap: 0.5 mm). The effective radiation dose was estimated at 1.6 mSv. Consecutive 0.5-mm-thickness multiplanar reconstruction images (MPR) were computed in the parasagittal plane parallel to glenohumeral joint space (Figure 1). The parasagittal images to be evaluated were the most lateral section on which the scapular spine was still in continuity with the body of the scapula.¹⁸

Quantitative analysis of Fatty Degeneration in the rotator cuff muscles determined with computed tomography

Figure 2. Regions of interest for the Supraspinatus, Infraspinatus/ Teres Minor and Subscapularis muscles (SSp, ISp/TMI, SSc) on the parasagittal CT-images. SSp and ISp muscles showing grade 1 fatty degeneration according to Goutallier (white arrows). TMa, Teres Major.

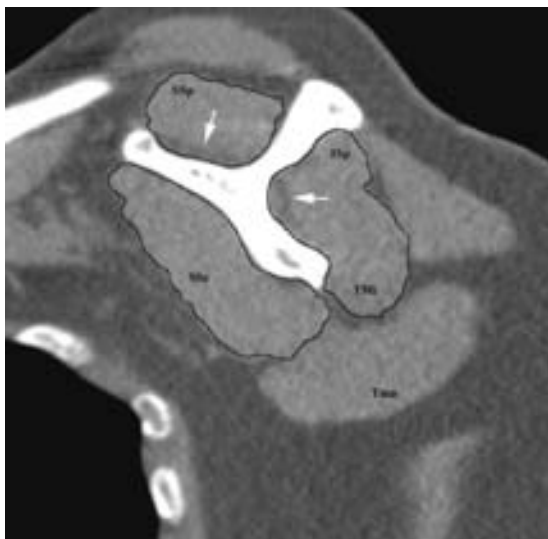


Table 2. The inter-observer variability of the mean muscle density expressed by the interclass correlation coefficient (ICC) and the standard deviation of the difference (SDD) between the 3 investigators, in Hounsfield units*

Patient groups	Supraspinatus		Infraspinatus/ Teres Minor		Subscapularis	
	ICC (95% CI)	SDD	ICC (95% CI)	SDD	ICC (95% CI)	SDD
All shoulders n=30	0.99 (± 0.006)†	1.9	0.98 (± 0.01) †	2.1	0.95 (± 0.03) †	2.3
Goutallier 0	-	-	-	-	0.92† n=15	1.9
Goutallier 1	0.91† n=12	1.6	0.85† n=14n	2.1	0.93† =13	2.2
Goutallier 2	0.98† n=10	1.6	0.97† n=9	2.1	-	-
Goutallier 3	0.99† n=5	1.9	0.99† n=5	2.1	-	-

CI: confidence interval

* The ICC and SDD are only presented if the Goutallier score group consisted of more than five shoulders.

† p < 0.0001

Image Analysis

The parasagittal images were used to visually grade the degree of fatty degeneration in the rotator cuff muscles as described by Fuchs et al in parasagittal MRI sections using the Goutallier score (0, no fat; 1, some strands of fat; 2, less fat than muscle; 3, as much fat as muscle; 4, more fat than muscle).¹⁸ Fuchs et al. showed that that fatty degeneration is most reliably graded in these parasagittal MRI images; furthermore, they showed that this is a very reproducible section to evaluate the CSA of the rotator cuff muscles, our region of interest (ROI).¹⁸ The images were randomized and subsequently graded independently by 3 experienced observers, blinded to patient data. X-ray attenuation was analyzed using software developed from our division of image processing (www.lkeb.nl) As in lung densitometry, all images were first recalibrated for air (-1000 HU) based on samples outside the patient.¹²⁶ Subsequently, the individual muscle borders were outlined manually by the 3 observers, carefully excluding pixels containing subcutaneous / intermuscular fat (Figure 2). The Teres Minor (TMi) and Infraspinatus (ISp) muscles were analyzed together, as separation of these muscles has been proven very difficult and unreliable.¹⁹ All pixels containing bone tissue were automatically excluded from the segmentation by applying a threshold value of 200 HU. One observer repeated the manual outlining and measurement of muscle density using the same parasagittal CT images 3 weeks later. Again, all images were randomized and blinded for patient characteristics. A histogram was constructed from all pixels within the outlined ROI to calculate the mean muscle density (MMD), the fat-muscle ratio, and the 30th percentile point for the rotator cuff muscles. The MMD was defined as the mean CT number. For the definition of a fat-muscle ratio, all pixels were divided into adipose tissue and muscle tissue using a threshold of -30 HU, similar to the ratio used in the original paper by Goodpaster et al.¹²³ The 30th percentile point is defined as the HU value at which 30% of all pixels have a lower density. Additionally, the ROI was used to calculate the CSA (in square millimetres) of the rotator cuff muscles and of the Supraspinatus (Supraspinatus) fossa. The ratio of the CSAs of the individual rotator cuff muscles and of the SSp fossa was used to correct for patient size.^{18; 127} All rotator cuff muscles were analyzed in the most lateral reformation, where the scapular spine was in contact with the scapular body and in 2 other reformations taken from the same plane, 1.0 mm in lateral and medial direction to evaluate the variation in MMD caused by the difference between the parasagittal reformations in the same plane of the original CT image. The mean time required to construct the MPR and measure the MMD was recorded.

Statistical Analysis

The Spearman correlation between MMD and the Goutallier score was used to determine the ability of MMD to discriminate between patients and patient groups. For this evaluation, the average Goutallier score and MMD values from the 3 observers were used. Pearson correlation coefficients were used to assess the association between the CSA and the MMD. Inter- and intraobserver agreement of MMD and the Goutallier score was evaluated as a whole and in the Goutallier subgroups, as defined by the mean Goutallier score of the 3 observers (Table 1). The agreement was quantified by the interclass correlation coefficient (ICC) and the standard deviation of the differences (SDD)

Quantitative analysis of Fatty Degeneration in the rotator cuff muscles determined with computed tomography

between the measurements, expressed in HU. The ICC represents the contribution of the observer variability to the total variance of the MMD within the (sub)group. An ICC of 1 indicates that the interobserver variability did not contribute at all and that all variation was caused by the difference between the patients. The ICC of the quantitative measure for the total patient group was then compared with that of the Goutallier score. A general linear model for repeated measurements was used to assess the influence of age, sex, and rotator cuff pathology on the reproducibility. All analyses were performed using SPSS for Windows (SPSS Inc, Chicago, IL). P values smaller than 0.05 were considered significant.

Results


The MMD of the rotator cuff muscles was significantly different between the Goutallier score groups (Figure 3) and showed a strong correlation with the corresponding Goutallier score for all rotator cuff muscles (Figure 3). For the quantitative measurement, the interobserver variation, quantified by the SDD and ICC, is presented in Table 2. The SDD did not exceed 2.3 HU for any of the rotator cuff muscles. The ICC for the Goutallier score was 0.76 (± 0.14), 0.66 (± 0.19) and 0.46 (± 0.22) for the SSp, ISp/Tmi and Subscapularis (SSc) muscles, respectively. The 95% confidence intervals of the ICC of both measurements did not overlap, indicating a significant difference between both interclass correlations. The intraobserver variability quantified by the SDD and ICC is given in Table 3. The difference between the repeated measurements was small and did not exceed 1.4 HU. No confounding influence was shown when age, sex, or the presence of a rotator cuff tear was added as a covariate in a general linear model. The results remained unchanged when the analyses were repeated using the fat-muscle ratio or the CT number at the 30th percentile (data not shown). The ICC between the different slices was 0.99 for all rotator cuff muscles, and the SDD was 1.8, 1.6, and 1.2 HU for the SSp, ISp/TM, and SSc muscles, respectively. The correlation between MMD of SSp and ISp muscles, indicating fatty degeneration and the CSA ratio of the SSp muscle, indicated muscle atrophy was significant; still, the CSA ratio explained less than 20% of the variance of MMD (CC 0.42 and 0.48; $P < 0.05$). Significant differences in MMD were found between the individual rotator cuff muscles (SSp: 32.2 HU; ISp/TMi: 41.0 HU; SSc: 47.7 HU) ($P < 0.05$). A decreased MMD of the SSp muscle was significantly related to the MMD of both the ISp/TMi and SSc muscles (CC 0.60 and 0.61; $P < 0.01$).

The mean time required to construct the MPR and measure the MMD was 1.55 minutes.

Discussion

Over the last 2 decades, the preoperative assessment of rotator cuff muscles has grown in importance.^{16; 119; 121; 126-128} Most results and derived conclusions in the literature are based on the qualitative assessment according to Goutallier et al.⁸ This visual scoring method is based on the fact that adipose tissue in between the muscle fibres causes "striping" on the CT/MR images, which is easily recognized and categorized.⁸ However, the interobserver variability is moderate even in experienced hands since the human visual system is unable to perceive subtle differences in brightness caused by a change in the amount of intramuscular fat.^{17; 129} The question arises whether quantitative

Figure 3. Mean muscle density compared with the Goutallier score for all rotator cuff muscles. Linear regression and correlation coefficient (CC) between the mean muscle density and the Goutallier score.



* Significant difference in the mean muscle density between these Goutallier-score groups. $P < 0.0001$. SSp, Supraspinatus; Isp/TMI, Infraspinatus/Teres Minor; SSc, Subscapularis muscles.

Quantitative analysis of Fatty Degeneration in the rotator cuff muscles determined with computed tomography

assessment of fatty degeneration using CT is more reliable and reproducible. This study showed good concordance between muscle density and the Goutallier score in the assessment of fatty degeneration. Thus, it is capable of discriminating between different degrees of fatty degeneration. The low inter- and intraobserver SDDs indicates that the methodological variability of this quantitative measurement technique in CT images is very small. The high ICC showed an excellent interobserver reliability that was significantly better than that of the Goutallier score. This indicates that the variance of the Goutallier score was more operator dependent. This smaller variability and the possibility to detect a minor degree of fatty degeneration reflected by a decrease in the MMD provide clinicians and researchers alike with a reliable tool to evaluate the quality of the rotator cuff muscles. In contrast to Goodpaster et al,¹²² a significant difference was found in the MMD between the individual muscles of the rotator cuff, which could partially be explained by the presence of a rotator cuff tear in the SSp tendon. A decreased MMD of the SSp was significantly related to the MMD of both the ISp/TMi and SSc muscles. This may indicate that fatty degeneration is progressive not only within 1 muscle but also throughout the rotator cuff.¹⁵

Recent studies have described new techniques to quantify muscle atrophy of the rotator cuff muscles using MRI.^{130, 131} In 1999, Fuchs et al. showed a significant relation between the Goutallier score for fatty degeneration and the average CSA, a measure for muscle atrophy.¹⁸ A similar correlation was found in the present study between MMD of SSp and ISp muscles and the CSA ratio of the SSp muscle. We agree with Fuchs et al¹⁸ that this correlation is insufficient to quantify the degree of fatty degeneration using the CSA alone. We believe this is because adipose tissue is included inappropriately inside the ROI while measuring the CSA of a rotator cuff muscle. Only recently, Pfirrmann et al. presented a study using proton MR spectroscopy for the assessment of the SSp lipid content.¹³¹ Their results for the apparent lipid content in percentages are highly comparable to our results for the MMD for the SSp muscle (Figure 3a). However, we believe there are several disadvantages to its use. Primarily, proton MR spectroscopy is not yet readily available in most clinical settings and requires knowledge of sophisticated software. Second, it is more susceptible to external and internal errors of measurement produced by temperature differences, field inhomogeneity, patient characteristics, and limited spatial resolution due to motion artefacts. We therefore believe this technique is less feasible in assessing lipid content between and within patients in a standard clinical setting. There are some limitations of measuring muscle fatty degeneration using CT densitometry. First, it does not provide a direct measure of muscle lipid content. Second, it is known that alterations in muscle density are subject to changes in muscle protein, perfusion, and extracellular water content.¹²³ However, animal studies have shown a high correlation between CT assessment of the fat-muscle ratio and the exact weight of fat and muscle after dissection.¹²⁴ Rotator cuff characteristics (eg, anatomic variation in tendon length and retraction) are thought to influence the size and contents of the cross-section measured.¹⁹ Voxel intensity measurements using volume CT scans might be addressed in the future to assess the rotator cuff muscles as a whole and prevent for selection bias. Last, although the radiation exposure for this specific technique is relatively low, ionizing radiation may be a problem in follow-up studies. Nevertheless, CT imaging

Table 3. The intra-observer variability of the mean muscle density expressed by the interclass correlation coefficient (ICC) and standard deviation of the difference between the repeated measures in Hounsfield units (SDD)*

Patient groups	Supraspinatus		Infraspinatus/ Teres Minor		Subscapularis	
	ICC	SDD	ICC	SDD	ICC	SDD
All shoulders n=30	0.99	1.0	0.99†	1.1	0.98	1.4
Goutallier 0	-	-	-	-	0.97† n=15	1.3
Goutallier 1	0.98† n=12	0.7	0.97† n=14	1.2	0.99† n=13	0.9
Goutallier 2	0.99† n=10	1.6	0.99† n=9	0.9	-	-
Goutallier 3	0.99† n=5	1.1	0.99† n=5	0.9	-	-

* The ICC and variance are only presented if the Goutallier score group consisted of more than five shoulders.

† $p < 0.0001$

is widely available, has relatively low costs, uses relatively simple software, and is rapid, making it highly suitable for both clinical investigation and specific research on rotator cuff disease. All measurements were performed using software designed to recalibrate the images and to exclude automatically pixels containing bone in the calculation of MMD. Although not yet available, these features could be implemented easily in standard commercial CT software. We believe that the total amount of time required to measure the MMD was small enough to be implemented in the standard evaluation of a shoulder CT scan. By recalibration of the image data for air (and possibly for fat), performed during image analysis, the density measurement is more independent on CT scanner type, reformatting software, and acquisition protocol used. Standardization of reformatting software and acquisition protocol would, however, still improve general applicability. In this study, we examined RA patients since they present a high incidence of rotator cuff pathology, apart from glenohumeral arthritis.⁵ As said, the amount of fatty degeneration is not only believed to increase the chance of a re-tear in rotator-cuff-tear-repair patients but is also believed to have a negative correlation with the functional outcome of shoulder arthroplasty.^{1; 15; 81; 119-121} Since all clinical studies used the Goutallier score to qualitatively assess fatty degeneration, further research using specific patient groups such as RA and rotator cuff- tear patients is needed to present a reliable estimation of these clinical implications. Furthermore cut-off values for the MMD should be calculated based on postoperative results to present the surgeon with an easy-to-use but reliable indication for optimal choice of treatment.

Quantitative analysis of Fatty Degeneration in the rotator cuff muscles determined with computed tomography

In summary, this study presents a reproducible and reliable technique to quantify fatty degeneration of the rotator cuff muscles with a higher interobserver agreement compared with the Goutallier score. This quantitative measurement of fatty degeneration therefore presents the opportunity for quick, easy-to-use, and reliable assessment of the rotator cuff muscles. This may result in timely intervention and optimal planning of treatment, stimulating further research to evaluate its clinical implications and applications.