



Universiteit
Leiden
The Netherlands

Clinical and molecular aspects of MUTYH- and APC-associated polyposis

Nielsen, M.

Citation

Nielsen, M. (2011, March 10). *Clinical and molecular aspects of MUTYH- and APC-associated polyposis*. Retrieved from <https://hdl.handle.net/1887/16611>

Version: Corrected Publisher's Version

License: [Licence agreement concerning inclusion of doctoral thesis in the Institutional Repository of the University of Leiden](#)

Downloaded from: <https://hdl.handle.net/1887/16611>

Note: To cite this publication please use the final published version (if applicable).

2.3

Expanded extracolonic tumor spectrum in *MUTYH*-associated polyposis

Vogt S
Jones N
Christian D
Engel C
Nielsen M
Kaufmann A
Steinke V
asen HF
Propping P
Sampson JR
Hes FJ
Aretz S

Background & aims:

MUTYH-associated polyposis (MAP) is characterized by a lifetime risk of colorectal cancer of up to 100%. However, no systematic evaluation of extracolonic manifestations has been reported.

Methods:

A large cohort of MAP patients was recruited from a European multicenter study. Data were collected on 276 cases from 181 unrelated families. Information on extracolonic tumor spectrum and incidence were evaluated to determine cumulative lifetime risk, which was compared with that of the general population to obtain standardized incidence ratios (SIRs).

Results:

Duodenal polyposis occurred in 17% of cases; the relative risk (SIR) of duodenal cancer was 129 (95% confidence interval [CI]: 16–466), whereas the lifetime risk was 4%. The incidence of extraintestinal malignancies among cases was almost twice that of the general population (SIR: 1.9; 95% CI: 1.4–2.5), with a lifetime risk of 38%. We observed a significant increase in the incidence of ovarian, bladder, and skin cancers (SIR: 5.7, 7.2, and 2.8, respectively) and a trend of increased risk of breast cancer among cases. The median ages of onset of these 4 malignancies ranged from 51 to 61 years. In contrast to familial adenomatous polyposis, no desmoid tumors were observed, but sebaceous gland tumors, characteristic of the Muir-Torre variant of Lynch syndrome, occurred in 5 patients.

89

Conclusions:

The relative risks for several extraintestinal malignancies increased in patients with MAP, but based on the spectrum of cancers (which overlaps with that of Lynch syndrome) and the relatively advanced age at onset, intensive surveillance measures other than frequent endoscopy are unlikely to be helpful to patients with MAP.

MUTYH-associated polyposis (MAP) (OMIM #608456) is recognized as an autosomal recessive disorder associated with adenomas and cancers of the colorectum. It is caused by biallelic germline mutations in the base excision repair gene *MUTYH* (*MUTYH*) that lead to an increase in 8-oxoG–induced somatic G:C>T:A transversions in other genes, including tumor suppressors such as the *APC* gene. The condition was described for the first time in 2002.¹ During recent years, the colorectal phenotype has been delineated in different groups of patients.^{2–12} MAP is characterized by the appearance of multiple adenomas throughout the colorectum, usually numbering between dozens and a few hundreds. The attenuated or atypical form of familial adenomatous polyposis (FAP) is the most important differential diagnosis (for review see Galiatsatos and Foulkes).¹³ Colorectal adenomas or colorectal cancer (CRC) usually become symptomatic between the 4th and 7th decade of life,^{2,5,6,8} and the cumulative lifetime risk for CRC has been estimated to be up to 100%.¹⁴ Recently, a robust correlation has been established between the most frequent *MUTYH* genotypes and the severity of colorectal polyposis and age-related risk of CRC.¹⁵ In contrast to the colorectal phenotype, there is little information on the spectrum of extracolonic manifestations in MAP. In up to one-quarter of cases the duodenum is affected,^{2,5,12} but other extracolonic lesions have been reported only anecdotally.^{2,6,12,16–18} It has been unclear whether the apparent scarcity of extraintestinal lesions is truly characteristic of the disease or reflects limited attempts so far to gather comprehensive phenotypic data. Moreover, there is likely to be a strong ascertainment bias toward colorectal polyposis and CRC because it is these phenotypes that usually lead to referral for *MUTYH* mutation analysis. To date, no study has systematically evaluated extraintestinal manifestations in a large cohort of MAP patients. Nonetheless, knowledge of the natural course of a disease, including the true spectrum of manifestations and clinopathological features, is important for differential diagnosis, adequate clinical surveillance of those at risk, and identification of the molecular pathways involved. To determine the spectrum and risk of extracolonic manifestations of MAP, and to overcome the limitations of small sample size, we conducted a retrospective collaborative study by pooling data from 3 research groups in the United Kingdom, the Netherlands, and Germany. Comprehensive clinical data were collected on 276 MAP patients with confirmed biallelic *MUTYH* mutations. Here we report the findings and suggest preliminary surveillance recommendations.

MATERIALS AND METHODS

Patients and Sample Collection

Index patients had an adenomatous polyposis and were referred to 1 of 3 participating centers (Institute of Human Genetics, Bonn, Germany; Institute of Medical Genetics, Cardiff, UK; Centre for Human and Clinical Genetics, Leiden, The Netherlands) for mutation analysis of the *MUTYH* gene that was performed as described previously.^{5,12,19} Index cases with biallelic *MUTYH* mutations (MAP patients) and their affected relatives were contacted and offered participation in the study. In addition, all available deceased siblings were included. Siblings were regarded as being affected only if medical records confirmed colorectal adenomatous polyposis or if biallelic germline *MUTYH* mutations were confirmed. Affected children and parents of index cases were included only if biallelic germline *MUTYH* mutations were identified. The study was approved by national and/or local ethics review boards at each center (the Multi-Centre Research Ethics Committee for Wales, ref. 06/MRE09/19, Medical Faculty of the University of Bonn ethics review board no. 063/04, and Leiden University Medical Centre ethics review board no. P01.019) and all patients enrolled in this study had given informed consent.

Genotyping/Nomenclature

To describe mutations we used the most up-to-date annotation for *MUTYH* (NM_001128425.1), which meant that numbering after nucleotide position c.157 (5' end of exon 3; amino acid 53) is extended by 42 nucleotides (14 amino acids) compared to a previously used sequence (GenBank accession: U63329.1) and by 9 nucleotides compared to a previously introduced sequence (GenBank: NM_012222.1). This changes, for example, the description of the missense mutation c.494A>G; p.Tyr165Cys (Y165C) to c.536A>G;p.Tyr179Cys (Y179C) and c.1145G>A;p.Gly382Asp (G382D) to c.1187G>A; p.Gly396Asp (G396D).

91

Genotype-Phenotype Analysis

To examine potential genotype-phenotype correlations *MUTYH* genotypes were classified as described previously¹⁵ to assess truncating vs nontruncating *MUTYH* mutations and alternative combinations of the 2 common *MUTYH* mutations G396D/Y179C. Separate analyses for biallelic combinations of mutations other than the G396D and Y179C were not done because the corresponding numbers of MAP patients were too small.

Phenotype/Data Collection

Information on medical and family histories was obtained during genetic counseling sessions and from medical records. A standardized inventory was used to ensure systematic evaluation of all potentially relevant disease manifestations. However, because of the different health care systems, ethics board decisions, and privacy policies, the procedures for gathering data differed between the centers. In the United Kingdom, information was gathered from regional genetics centers, hospital records, and by mailing a questionnaire to patients. In the Netherlands, this was supplemented by information obtained at telephone interview with MAP patients or their families in cases where there was unclear or incomplete data. In Germany, in addition to data collection by questionnaire and from medical records, a structured telephone interview was conducted with all index patients and affected relatives. Wherever possible, information provided by patients was confirmed from medical notes and histopathology records obtained from general practitioners, medical specialists, hospitals, and institutes. Multiple benign tumors of the same type in a patient were counted as 1 tumor. Seventeen cases were excluded from the study because there was insufficient clinical information (deceased long ago, lack of family contact, or untraceable medical records).

92

Statistical Analysis

Standardized incidence ratios (SIR) for different tumors were calculated by dividing observed numbers of cancers in the study cohort by the expected number in the general population. The expected number of cancers was calculated by multiplying the age- and gender-specific incidence rate in the general population with the corresponding cumulative observation time (personyears) in the study cohort. The age- and gender-specific incidence rates in the general population (years 2000 – 2004) were obtained from the population-based Cancer Registry of the Saarland, Germany, where multiple primary tumors and nonmelanoma skin cancers are routinely documented. Comparisons

Table 1. Baseline Data of the 3 Patient Groups

| | Germany | UK | Netherlands | Combined no. of patients | | |
|--|------------|------------|-------------|--------------------------|-------------|------------|
| | | | | Total | Index | Relatives |
| No. of patients | 98 | 87 | 91 | 276 | 181 | 95 |
| Gender ratio (<i>male/female</i>) | 50/48 | 53/34 | 55/36 | 158/118 | 99/82 | 59/36 |
| Age (y) at diagnosis, mean (range) | 43 (24–68) | 45 (12–65) | 47 (21–70) | 45 (12–70) | 45 (12–68) | 45 (27–70) |
| Age at evaluation, mean (range) | 53 (28–84) | 54 (17–78) | 56 (32–83) | 54 (17–84) | 55 (17–84) | 52 (19–82) |
| Mode of diagnosis (symptomatic/screening) | 64/27 | 58/20 | 62/14 | 184/61 | 141/28 | 43/33 |
| Deceased | 8/98 | 19/87 | 30/91 | 57/276 (21) | 29/181 (16) | 28/95 (29) |
| Patients with extraintestinal lesions, n (%) | 41/98 (42) | 13/87 (15) | 23/91 (25) | 77/276 (28) | 59/181 (33) | 18/95 (19) |
| Patients with at least 1 extraintestinal malignancy, n (%) | 18/98 (18) | 4/87 (5) | 13/91 (15) | 35/276 (13) | 26/181 (14) | 9/95 (10) |

with the nation-specific incidence rates in the United Kingdom and the Netherlands did not show significant differences for relevant tumors such as duodenal, bladder, breast, ovarian, or endometrial cancer. In 1 patient, the age at diagnosis of ovarian cancer was unknown. To avoid over- or underestimation of risk, we used the mean age at diagnosis of ovarian cancer in the female general population (67 years of age), in this case, to enable estimation of the SIR for ovarian cancer. The 95% confidence intervals of SIRs were calculated assuming that the numbers of observed cases followed a Poisson distribution. Cumulative age-dependent risks were calculated using the Kaplan–Meier method. Patients without cancer were censored at last observation or death, whichever occurred first. The log-rank test was used to compare cumulative risks between different genotypes. All reported P values are 2-sided. A P value <0.05 was considered statistically significant. SPSS 15.0.1.1 (SPSS, Chicago, IL) was used for all analyses.

RESULTS

Three-hundred and forty-six MAP patients with biallelic *MUTYH* mutations were approached and written consent was given by 293. Sufficient medical information could be obtained from 276 MAP patients (181 apparently unrelated index cases and 95 affected relatives) for inclusion in the study. The mutation spectrum and some phenotypic features of a subset of these patients have been described previously.^{3,5,12,20} The characteristics of the patient groups from each participating country are summarized in Table 1. Detailed genetic and clinical information on all MAP patients included in this study is provided in Supplementary Table 1 and histological findings for all carcinomas identified more than once in the patient sample are listed in Supplementary Table 2. The mean age at diagnosis of MAP was 45 years and the mean age at evaluation was 54 years. Most patients were diagnosed following symptomatic presentation. The male-to-female ratio was 1:3. The 3 national cohorts were similar in their size and characteristics, except for proportion of deceased patients, which ranged from <10% in the German cohort to approximately 30% in the Dutch cohort (Table 1). No significant differences in basic characteristics, such as mean age of diagnosis and mean age at evaluation, were identified between index-cases and their affected relatives (Table 1). No correlations between genotype and age-dependent extracolonic tumor incidence were seen for either truncating vs nontruncating mutations or for different biallelic combinations of the mutations Y179C and G396D (data not shown).

Table 2. Gastroduodenal Findings

| | Germany | UK | Netherlands | All patients | Median age at diagnosis (range) | FAP (reference) |
|---------------------------------|-------------|-------------|-------------|---------------|---------------------------------|--------------------------|
| Duodenoscopy conducted | 80% (77/96) | 45% (27/60) | 51% (46/91) | 61% (150/247) | — | — |
| Age (y) at duodenoscopy (range) | 45 (24–69) | 48 (14–48) | 54 (28–70) | 48 (14–70) | — | — |
| Duodenal polyps | 19% (15/77) | 7.5% (2/27) | 20% (9/46) | 17% (26/150) | 48 (25–67) | 50%–90% ^{24,25} |
| Duodenal cancer | — | — | 4% (2/46) | 1.3% (2/150) | 61 (56–65) | 3%–5% ^{24,25} |
| Gastric polyps | 9% (7/77) | 15% (4/27) | 13% (6/46) | 11% (17/150) | 49 (17–67) | 13%–84% ^{22,23} |
| Gastric cancer | 2.6% (2/77) | 3.7% (1/27) | — | 2% (3/150) | 38 (17–48) | <0.5% ²⁷ |
| Esophagus carcinoma | 1% (1/77) | — | 2% (1/46) | 1.5% (2/150) | 53 (46–59) | — |

FAP, familial adenomatous polyposis.

Table 3. Frequency of Extracolonic Cancers Observed More Than Once in 276 MAP Patients (158 Male, 118 Female)

| Site of cancer | Gender | n | SIR (95% CI) | Obs %-risk by 75 y (95% CI) | Age (y) at diagnosis, median (range) |
|---|----------------|-----------------|------------------|-----------------------------|--------------------------------------|
| All extraintestinal malignancies ^a | Both | 44 | 1.9 (1.4–2.5) | 38 (23–52) | 54 (27–78) |
| Esophagus | Both | 2 | 5.5 (0.7–19.8) | 2 (0–4) | 53 (46–59) |
| Stomach | Both | 3 | 4.2 (0.9–12.3) | 1 (0–3) | 38 (17–48) |
| Duodenum | Both | 2 | 129 (15.7–465.9) | 4 (0–9) | 61 (56–65) |
| Bladder | Both | 4 | 7.2 (2.0–18.4) | 6 (0–12) | 61 (45–67) |
| Skin ^b | Both | 13 | 2.8 (1.5–4.8) | 17 (4–29) | 58 (30–71) |
| Lung | Both | 2 | 0.6 (0.1–2.3) | 3 (0–8) | 60 (51–69) |
| Breast | F ^c | 8 | 2.1 (0.9–4.2) | 25 (0–51) | 53 (45–76) |
| | | 11 ^d | 3.0 (1.5–5.3) | | 55 (45–78) |
| | M | 1 | 53.5 (1.4–298) | 1.5 (0–4.5) | 56 |
| Ovary ^e | F | 3 ^e | 5.7 (1.2–16.7) | 10 (0–22) | 51 (45–56) |
| Endometrium ^f | F | 2 | 4.6 (0.6–16.5) | 3 (0–7) | 51 (47–54) |

CI, confidence interval; F, female; M, male; Obs%-Risk by 75 y, cumulative lifetime risk by 75 years in *MUTYH*-associated polyposis patients; SIR, standardized incidence ratio.

^aInclude also extraintestinal malignancies, which were observed only once.

^bInclude melanoma, spinous cell carcinoma, and basal cell carcinoma.

^cData related to female *MUTYH*-associated polyposis patients only.

^dRelated to affected females (n = 8) and total number of breast cancers (n = 11).

^eAge of diagnosis was not known in 1 patient; for calculation mean age at diagnosis of ovarian cancer in the female general population (67 years of age) was used.

Gastroduodenal Lesions

Of 150 patients who underwent esophagogastroduodenoscopy, 17 (11%) had gastric lesions (Table 2). In 4 of them (24%), gastric adenomas were described and 9 patients had fundic gland polyps only. Gastric cancer was observed 3 times; however, the incidence was not significantly increased compared to the general population (SIR: 4.2; 95% CI: 0.9–12) (Table 3). One patient with gastric cancer became symptomatic at 17 years of age, suggesting additional causative factors.

Duodenal polyposis occurred in 26 of 150 patients (17%) who underwent esophagogastroduodenoscopy. In 16 of these patients, adenomas were confirmed histologically, in 1 patient hyperplastic polyps were present, and in the 65 years of age, resulting in a high relative risk (SIR: 129; 95% CI: 16–466) (Table 3); the cumulative lifetime risk was calculated as 4%. No extraduodenal small-bowel cancer was found. In addition, carcinoid tumors were noted in 4 patients (2 located in the appendix, 2 in the small bowel).

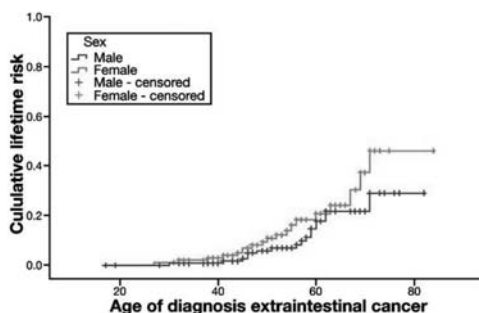


Figure 1. Cumulative lifetime risks for extraintestinal cancer in *MUTYH*-associated polyposis (MAP) patients.

Malignant Extraintestinal Tumors

Seventy-seven (28%) of the 276 MAP patients had at least 1 extraintestinal tumor. A total of 110 extraintestinal lesions was documented (including both synchronous and metachronous tumors), of which 44 (40%) were malignant. Thirty-five of the 276 MAP patients (13%) had at least 1 malignant extraintestinal lesion. The frequencies of both benign and malignant tumors differed between national cohorts (Table 1). Extraintestinal cancers had been diagnosed before presentation of colorectal MAP in 14 cases (12 index patients, 2 relatives) of the 35 patients (26 index cases, 9 relatives) with extraintestinal malignancies. The difference between index patients and relatives was not significant ($P = .26$). None of the 14 patients had a possible FAP-related extraintestinal tumor; all patients were referred for *MUTYH* mutation screening after the colorectal polyposis became apparent.

Compared to the general population, the incidence of extraintestinal malignancies as a whole was almost doubled in MAP patients (SIR: 1.9; 95% CI: 1.4–2.5) and lifetime risk was 38% (95% CI: 23%–52%) (Figure 1). The difference in tumor frequency between index patients and relatives was not significant ($P = .085$). Extraintestinal cancers reported at least 2 times in the whole patient sample included the 5 cancer types listed in Table 4A. A variety of other malignancies occurred only once (Supplementary Table 1). Eight female MAP patients had been affected by breast cancer at a median age of 55 years (Table 4). Notably, in 3 of them this cancer had occurred twice (bilateral synchronous, bilateral metachronous, and unilateral metachronous). In 1 of 3 females BRCA1 and BRCA2 germline mutation screening was performed with normal results. The incidence of breast cancer in females with MAP was significantly increased (SIR: 3.0; 95% CI: 1.5–5.3), but only if the number of cancers rather than the number of affected females was considered. Breast cancer was also diagnosed in 1 male MAP

patient who tested negative for BRCA1 and BRCA2 germline mutations (SIR: 54; 95% CI: 1.4–298).

Skin cancers (melanomas, squamous epithelial carcinomas [spinaliomas, spinous cell carcinomas], and basal cell cancers) were the second most commonly reported cancers followed by bladder carcinomas (5% and 1.5% of patients, respectively) and their incidences were significantly increased (SIR: 2.8; 95% CI: 1.5–4.8 and SIR: 7.2; 95% CI: 2.0–18, respectively). As for breast cancer, the median ages at diagnosis of these cancers did not appear to be early (58 and 61 years, respectively). Ovarian cancer was observed 3 times. Assuming an age at diagnosis of 67 years (the mean age at diagnosis of ovarian cancer in the female general population) in the 1 patient with unknown age at diagnosis, the risk was increased significantly (SIR: 5.7; 95% CI: 1.2–17). Endometrial cancer was noted in 2 patients, but the incidence was not increased significantly (Table 3). The present study may be underpowered to identify association of some cancers with MAP.

Table 4. Extraintestinal Tumors

| | Germany, % (n) | UK, % (n) | Netherlands, % (n) | All patients, % (n) | Median age at diagnosis (range) |
|---------------------------------------|----------------|------------|--------------------|--------------------------|---------------------------------|
| (A) Malignancies | | | | | |
| Breast cancer ^c | 6 (3/48) | 3 (1/34 F) | 11 (4/36 F) | 7 (8/118 F) ^a | 55 (45–78) ^b |
| Endometrial cancer ^c | 4 (2/48) | — | — | 1.7 (2/118 F) | 51 (47–54) |
| Ovarian cancer ^c | 4 (2/48) | 3 (1/34 F) | — | 2.5 (3/118 F) | 51 (45–56) |
| Bladder carcinoma | 2 (2/98) | — | 2 (2/91) | 1.5 (4/276) | 61 (45–67) |
| Skin cancer | 6 (6/98) | 1 (1/87) | 6.5 (6/91) | 5 (13/276) | 58 (30–71) |
| (B) Benign tumors | | | | | |
| Benign skin tumors | 12 (12/98) | 7 (6/87) | 13 (12/91) | 11 (30/276) | 50 (15–71) |
| Sebaceous gland adenoma/epithelioma | 2 (2/98) | 1.7 (2/87) | 1 (1/91) | 1.8 (5/276) | — |
| Epidermoid cysts/atheroma | 3 (3/98) | — | 1 (1/91) | 1 (3/276) | — |
| Others ^d | 8 (8/98) | 5 (4/87) | 11 (10/91) | 8 (22/276) | — |
| Lipomas | 7 (7/98) | 1 (1/87) | — | 3 (8/276) | 37 (30–65) |
| Benign endometrial tumor ^c | 6 (3/48) | — | 2.7 (1/36) | 3.4 (4/118 F) | 43 (32–48) |
| Benign breast tumors ^c | 4 (2/48) | 3 (1/34 F) | 2.7 (1/36) | 3.5 (4/118 F) | 43 (22–59) |

^aIn 3 of 8 cases, a second metachronous or synchronous breast cancer occurred (F, female).

^bAll 11 breast cancers.

^cAll data related to female *MUTYH*-associated polyposis patients only.

^dFibrous histiocytoma, capillary hemangioma, pilar cyst, dermatofibroma, follicle cyst.

Benign Extraintestinal Lesions

No patients were identified with osteomas or desmoids. About half of the German and 7 Dutch patients were seen by an ophthalmologist (55 cases) and 3 (5.5%) of them were diagnosed with congenital hypertrophy of the retinal pigment epithelium (CHRPE), although we were unable to confirm whether the reported CHRPEs were of the type associated with FAP (multiple uni- or bilateral, sharp bordered, diffuse distributed lesions). At least 1 cystic lesion was found in 11 probands (jaw-bone cysts in 11 cases, hepatic cysts in 5 cases, and kidney cysts in 2 patients). A variety of different benign cutaneous tumors were observed in 11% of patients (Table 4B). Interestingly,

in 5 of the patients (1.8%), sebaceous gland adenomas (SGA) or sebaceous gland epitheliomas were reported (in 2 patients 1 SGA or sebaceous gland epitheliomas, in 2 patients 2 SGAs, and in 1 patient several SGAs). All 5 cases had a colorectal phenotype compatible with MAP (>20 to >100 adenomas), 4 patients had well-known pathogenic biallelic *MUTYH* mutations, and none of their families were suggestive of Lynch syndrome (Supplementary Table 1).

In the German cohort, subcutaneous lipomas were diagnosed in 7 patients; however, this finding was not confirmed by the other 2 groups. Benign “endometrial polyps” or endometrial hyperplasia was reported in several patients (Table 4B). In addition, a variety of other benign tumors were observed only once (Supplementary Table 1).

DISCUSSION

Since its first description as an adenomatous colorectal polyposis in 2002, a number of extracolonic manifestations of MAP have been described.^{2,5,6,12,16–18} However, many lesions have been reported sporadically and could suggest coincidence with limited clinical relevance. In this collaborative study involving 3 European centers, we undertook a comprehensive retrospective analysis of 276 MAP patients, the largest cohort to date, and assessed the incidence of both malignant and benign extracolonic lesions.

97

Upper Gastrointestinal Findings

We found gastric polyps in 11% and duodenal polyps in 17% of patients with MAP who had undergone upper gastrointestinal endoscopy, which is in accordance with previous findings in smaller studies.^{2,21} It is unlikely that a substantial number of fundic gland polyps were caused by treatment with proton pump inhibitors because none of the patients were reported to suffer from gastroesophageal reflux, gastritis, or unspecific gastric symptoms. Thus, involvement of the upper gastrointestinal tract in MAP is not as common as in FAP, where gastric polyposis is present in approximately half of patients (range, 13%–84%)^{22,23} and duodenal polyposis in 50%–90%.^{24,25} However, the gastric polyps in MAP cases included a number that were reported to be adenomas (although the histology could not be verified by independent review) and gastric cancers were noted in 3 patients. Our preliminary observations are based on small numbers, but the previously reported identification of biallelic somatic *MUTYH* mutations in sporadic gastric cancer²⁶ suggests that defects in the base excision repair pathway may be relevant in development of some gastric cancers.

Table 5. Distribution of Duodenal Polyps

| Site of duodenal polyps | No. of patients ^a |
|----------------------------------|------------------------------|
| Total | 24 |
| Bulbus duodeni | 5 |
| Periampullary region | 4 |
| Duodenum descendens ^b | 6 |
| Flexura duodeni inferior | 3 |
| Site unknown | 11 |

^aSome patients are listed more than once depending on the distribution of duodenal polyps.

^bOutside periampullary region.

The distribution and relative frequency of duodenal polyps was comparable to FAP;^{25,27} however, the numbers were small (Table 5). Although duodenal polyps were found to be less frequent in MAP (17%) than is reported in FAP, the increase in relative risk (SIR: 129) and the lifetime risk of duodenal cancer (around 4%) appeared similar.^{25,28,29} Recently, 2 additional cases of advanced duodenal carcinoma were reported in MAP patients.¹⁸ It is noteworthy that development of duodenal cancer in MAP in the absence of obvious duodenal polyposis has been observed,²⁰ indicating that screening strategies that have been developed for patients with FAP may not be appropriate or adequate in MAP.

Extraintestinal Cancers

98

Extraintestinal malignancies were diagnosed in 35 of 276 MAP patients (13%). Compared to the general population, the incidence was almost doubled (SIR: 1.9) and the cumulative lifetime risk was approximately 38%. A characteristic feature of the extraintestinal malignancies that were observed more than once was their relatively advanced age at diagnosis (median 51–61 years; range, 30–78 years).

The risk of bladder cancer in MAP was similar to the risk of urinary tract cancers in Lynch syndrome.^{30–33} However, in contrast to Lynch syndrome, no cancers were located in the upper part of the urinary tract (renal pelvis, ureter), and the MAP-associated cancers included 1 squamous cell carcinoma in addition to urothelial cancers.

A single thyroid carcinoma occurred in the cohort, and only 1 additional case in a patient with MAP has been reported in the literature.¹⁶ The 2 cancers were of different histological types. Thus, there does not appear to be a significant association of thyroid cancer with MAP, in contrast to the established association with FAP.

A trend toward an increased risk for breast cancer and gynecological cancers (endometrial cancer and ovarian cancer) was seen in our data and has also been suggested by others. A significant increase in breast cancer was reported previously in the Dutch subgroup of our cohort.¹² Breast tumors have also been reported in *MUTYH* knockout mice,³⁴ and the BRCA genes are involved in base excision repair

of 8-oxo-G lesions,³⁵ suggesting a mechanistic basis for a phenotypic association. The high frequency of metachronous or synchronous breast cancer in our cohort was striking, and the number of cancers observed in female MAP patients was increased significantly. Nonetheless, breast cancer is very rarely associated with MAP because no biallelic carriers of the 2 common *MUTYH* mutations were found among 691 breast cancer patients.³⁶ In contrast to hereditary breast and ovarian cancer, breast cancer in MAP patients was a late onset manifestation occurring between the 5th and 8th decades of life.

The occurrence of 3 MAP patients with ovarian and 2 with endometrial cancer in our cohort was conspicuous. Systematic screening for *MUTYH* mutations has been undertaken in 225 endometrial cancer patients and 1 biallelic mutation carrier was identified.³⁷ Recently, 2 additional MAP patients with endometrial cancer were reported,³⁸ and we have identified another in an MAP patient who was not included in this study.

Benign Extraintestinal Lesions

FAP-associated extraintestinal lesions were not prevalent in MAP patients. Importantly, no osteomas or desmoids were reported in any of the 276 patients in the present study and epidermoid cysts were seen rarely. CHRPE was diagnosed in only 3 patients, and it is questionable whether or not the specific type characteristic of classical FAP was seen. Given the rarity of CHRPE in our cohort and the literature on MAP, the presence of retinal pigment anomalies in the general population, and taking into account the subjective diagnosis by inexperienced ophthalmologists,³⁹ there is no evidence for an association between MAP and CHRPE. It has been reported that the presence of osteomas, CHRPE, and desmoids give a high probability of detecting an *APC* germline mutation;⁴⁰ our data suggest that osteomas and desmoids are valuable markers that differentiate between (attenuated) FAP and MAP.

Benign cutaneous tumors were reported frequently (11%) in our MAP cohort. Reliable population-based figures are not available for comparison, but the identification of 5 cases with sebaceous gland tumors was striking. Such tumors (sebaceous gland adenomas, epitheliomas, and carcinomas) are extremely rare in the general population, but are recognized as marker tumors for Muir–Torre syndrome, a variant of Lynch syndrome.^{41–44} Three case reports have also described sebaceous gland tumors in MAP patients with proved biallelic *MUTYH* mutations (in 1 patient together with an endometrial carcinoma),^{16,37,45} supporting the notion that the association of these tumors with colorectal tumors is not restricted to patients with germline mutations of the mismatch-repair genes. Thus, similar to Lynch syndrome, sebaceous gland tumors

might serve as a marker lesion that allows a presymptomatic diagnosis of MAP in a subset of patients. In contrast to Muir–Torre syndrome, sebaceous gland tumors in MAP patients are microsatellite stable with normal expression of mismatch-repair genes.¹⁶ Recently, it was noticed that up to one-third of Muir–Torre patients had microsatellite stable tumors⁴³; as a consequence, the authors stated that there must be at least 1 other variant of Muir–Torre syndrome with different molecular genetic mechanisms.

The high incidence of lipomas (3 cases occurred within a sibship) in the German subgroup might be due to chance or underreporting in the Dutch and UK subgroups, or represent a rare potential MAP manifestation similar to other specific lesions reported in single families only, eg, pilomatrixomas (pilomatricomas) in 3 siblings.¹⁷ Lipomas occurred in 3 of 93 APC mutation–positive Swiss FAP patients⁴⁶; multiple pilomatrixomas were also described in patients with FAP^{47,48} and also appear to be associated with a variety of hereditary disorders rather than only adenomatous polyposis syndromes.⁴⁹

Phenotypic and Mechanistic Overlap Between MAP and Lynch Syndrome?

The occurrence of Lynch syndrome–associated tumors in MAP (sebaceous gland tumors, colorectal, endometrial, and ovarian cancers) may reflect shared aspects of pathophysiology. Both the mismatch-repair and the base-excision-repair pathway are involved in the removal of oxidative DNA damage, partly in different ways, partly in a synergistic manner.^{50,51} In particular, the MSH2/MSH6 protein complex seems to be relevant for a physical and functional cooperation between the pathways by enhancing the substrate recognition, binding affinity, and glycosylase activity of the *MUTYH* enzyme,⁵² and in mismatch-repair–deficient cells the repair of oxidative damage is impaired and 8-oxoG is increased.⁵³

Ascertainment Bias

Retrospective studies like the present one are prone to various sources of bias and it is impossible to eliminate all of them. The patient groups from the 3 centers and the index patients vs relatives were very similar in terms of size, gender ratio, age at diagnosis, and age at evaluation. The high number of deceased patients in the Dutch cohort can be explained partly by the inclusion of relatively older patients and the better access to this group in the Dutch registry. The frequency of documented extracolonic lesions differed between the centers. The lower incidence of gastroduodenal tumors in the UK cohort might be caused by chance because the number of patients who underwent gastroduodenoscopy was low. The differences in incidence of extraintestinal lesions

could also reflect the different methods of data gathering that were used by the centers because of their different health care systems and privacy and research ethics policies. The telephone interview conducted with every German patient and in half of the Dutch patients proved to be a very sensitive method to collect medical information and may explain their apparently higher tumor incidence. Therefore, a slight underestimation of the extracolonic tumor incidence in the sample as a whole cannot be excluded. Conversely, an overestimation of cancer risk could have been made because the more intensive medical follow-up of MAP patients than individuals from the general population might increase detection of tumors.⁵⁴

No strong ascertainment bias toward or against extra-colonic tumors is expected in MAP index patients because the presence of an adenomatous polyposis is the selection criterion for initiating *MUTYH* screening. None of the MAP index patients were referred for mutation analysis in polyposis genes because of extraintestinal tumors; *MUTYH* screening was performed routinely in patients with an adenomatous polyposis (>20 adenomas) irrespective of the severity of colorectal disease. There were no known selection criteria regarding recruitment of at-risk relatives. Frequency of extraintestinal cancer did not differ significantly between index cases and relatives. However, patients who died early due to an extraintestinal malignancy before colorectal polyposis became apparent would escape inclusion in a systematic MAP study such as the present one, and this could lead to a relative underestimation of the risk of early onset cancers with a poor prognosis. Indeed, in 14 of 35 patients with extracolonic malignancies (40%), the extracolonic cancer manifested before (by 2–15 years) the diagnosis of polyposis was made.

In accordance with studies on other hereditary tumor syndromes,^{30,54,55} some extracolonic cancers that are observed frequently in the general population, such as lung cancer, prostate cancer, and leukemia, were comparatively infrequent in our series. Mostly, the low frequency can be attributed to mean age at last observation of the patients, which was before the age by which the majority of the late-onset sporadic cancers occurs in the general population.

Surveillance

Based upon the attenuated or atypical FAP-like colorectal phenotype in the vast majority of MAP patients, it has been suggested by a European expert panel that the surveillance protocol applied in attenuated FAP is appropriate for MAP patients.⁵⁶ This protocol includes complete colonoscopy at biannual intervals starting from 18 to 20 years and gastroduodenoscopy starting at between 25 and 30 years of age. Our findings support these recommendations for gastrointestinal surveillance in MAP,

although recent genotype-phenotype correlation might enable refinement of these protocols in the future.¹⁵

Although the overall incidence of extraintestinal cancers was almost doubled in MAP patients, no predominant tumor type or marked shift toward early onset was observed, suggesting that extraintestinal tumor surveillance is unlikely to offer great benefit. The borderline increase in the risk of (late onset) breast cancer should be addressed adequately by existing surveillance protocols that are offered to females in the general population in most Western countries.⁵⁷⁻⁵⁹ The risk of endometrial cancer was not increased significantly and current screening modalities for ovarian and endometrial cancers are of limited or uncertain value.^{30,60} In Lynch syndrome, most surveillance protocols no longer include screening for urinary tract tumors by urine cytology because of the low sensitivity and high number of false-positive results.^{33,61} As with other tumor predisposition syndromes associated with a variety of different rare tumors, MAP patients and their clinicians should be sensitive to suspicious or unusual symptoms and be aware of the overall increase in cancer incidence.

Conclusions

We evaluated the spectrum and incidence of gastroduodenal and extraintestinal tumors in the largest cohort of MAP patients examined so far. Although no predominant cancer was apparent, the overall incidence of extraintestinal malignancies was increased. The tumor spectrum associated with MAP is wider than previously recognized and there are phenotypic overlaps with Lynch syndrome. No genotype-phenotype correlation was found for extracolonic lesions. The presence of osteomas or desmoids in a patient with polyposis points strongly to a diagnosis of FAP rather than MAP, while the presence of sebaceous gland tumors is a characteristic of a subgroup of patients with either MAP or Lynch syndrome.

References

1. Al-Tassan N, Chmiel NH, Maynard J, *et al.* Inherited variants of *MUTYH* associated with somatic G:C>T:A mutations in colorectal tumors. *Nat Genet* 2002;30:227–232.
2. Sieber OM, Lipton L, Crabtree M, *et al.* Multiple colorectal adenomas, classic adenomatous polyposis, and germ-line mutations in *MUTYH*. *N Engl J Med* 2003;348:791–799.
3. Sampson JR, Dolwani S, Jones S, *et al.* Autosomal recessive colorectal adenomatous polyposis due to inherited mutations of *MUTYH*. *Lancet* 2003;362:39–41.
4. Fleischmann C, Peto J, Cheadle J, *et al.* Comprehensive analysis of the contribution of germline *MUTYH* variation to early-onset colorectal cancer. *Int J Cancer* 2004;109:554–558.
5. Aretz S, Uhlhaas S, Goergens H, *et al.* *MUTYH*-associated polyposis: 70 of 71 patients with biallelic mutations present with an attenuated or atypical phenotype. *Int J Cancer* 2006;119:807–814.
6. Gismondi V, Meta M, Bonelli L, *et al.* Prevalence of the Y165C, G382D and 1395delGGA germline mutations of the *MUTYH* gene in Italian patients with adenomatous polyposis coli and colorectal adenomas. *Int J Cancer* 2004;109:680–684.
7. Isidro G, Laranjeira F, Pires A, *et al.* Germline *MUTYH* (*MUTYH*) mutations in Portuguese individuals with multiple colorectal adenomas. *Hum Mutat* 2004;24:353–354.
8. Wang L, Baudhuin LM, Boardman LA, *et al.* *MUTYH* mutations in patients with attenuated and classic polyposis and with young-onset colorectal cancer without polyps. *Gastroenterology* 2004; 127:9–16.
9. Eliason K, Hendrickson BC, Judkins T, *et al.* The potential for increased clinical sensitivity in genetic testing for polyposis colorectal cancer through the analysis of *MUTYH* mutations in North American patients. *J Med Genet* 2005;42:95–96.
10. Venesio T, Molatore S, Cattaneo F, *et al.* High frequency of *MUTYH* gene mutations in a subset of patients with familial adenomatous polyposis. *Gastroenterology* 2004;126:1681–1685.
11. Kairupan CF, Meldrum CJ, Crooks R, *et al.* Mutation analysis of the *MUTYH* gene in an Australian series of colorectal polyposis patients with or without germline *APC* mutations. *Int J Cancer* 2005;116:73–77.
12. Nielsen M, Franken PF, Reinards TH, *et al.* Multiplicity in polyp count and extracolonic manifestations in 40 Dutch patients with *MUTYH* associated polyposis coli (MAP). *J Med Genet* 2005;42: e54.
13. Galiatsatos P, Foulkes WD. Familial adenomatous polyposis. *Am J Gastroenterol* 2006;101:385–398.
14. Farrington SM, Tenesa A, Barnetson R, *et al.* Germline susceptibility to colorectal cancer due to base-excision repair gene defects. *Am J Hum Genet* 2005;77:112–119.
15. Nielsen M, Joerink-van de Beld MC, Jones N, *et al.* Analysis of *MUTYH* genotypes and colorectal phenotypes in patients with *MUTYH*-associated polyposis. *Gastroenterology* 2009;136:471–476.
16. Ponti G, Ponz de Leon M, Maffei S, *et al.* Attenuated familial adenomatous polyposis and Muir-Torre syndrome linked to compound biallelic constitutional *MUTYH* gene mutations. *Clin Genet* 2005;68:442–447.
17. Baglioni S, Melean G, Gensini F, *et al.* A kindred with *MUTYH*-associated polyposis and pilomatricomas. *Am J Med Genet A* 2005;134:212–214.
18. Buecher B, Baert-Desurmont S, Leborgne J, *et al.* Duodenal adenocarcinoma and Mut Y human homologue-associated polyposis. *Eur J Gastroenterol Hepatol* 2008;20:1024–1027.
19. Jones S, Emmerson P, Maynard J, *et al.* Biallelic germline mutations in *MUTYH* predispose to multiple colorectal adenoma and somatic G:C>T:A mutations. *Hum Mol Genet* 2002;11:2961–2967.
20. Nielsen M, Poley JW, Verhoef S, *et al.* Duodenal carcinoma in *MUTYH*-associated polyposis. *J Clin Pathol* 2006;59:1212–1215.
21. Kanter-Smoler G, Bjork J, Fritzell K, *et al.* Novel findings in Swedish patients with *MUTYH*-associated polyposis: mutation detection and clinical characterization. *Clin Gastroenterol Hepatol* 2006;4: 499–506.

22. Offerhaus GJ, Entius MM, Giardiello FM. Upper gastrointestinal polyps in familial adenomatous polyposis. *Hepatogastroenterology* 1999;46:667–669.
23. Burt RW. Gastric fundic gland polyps. *Gastroenterology* 2003;125:1462–1469.
24. Kadmon M, Tandara A, Herfarth C. Duodenal adenomatosis in familial adenomatous polyposis coli. A review of the literature and results from the Heidelberg Polyposis Register. *Int J Colorectal Dis* 2001;16:63–75.
25. Bülow S, Bjork J, Christensen IJ, et al. Duodenal adenomatosis in familial adenomatous polyposis. *Gut* 2004;53:381–386.
26. Kim CJ, Cho YG, Park CH, et al. Genetic alterations of the *MUTYH* gene in gastric cancer. *Oncogene* 2004;23:6820–6822.
27. Wallace MH, Phillips RK. Upper gastrointestinal disease in patients with familial adenomatous polyposis. *Br J Surg* 1998;85: 742–750.
28. Offerhaus GJ, Giardiello FM, Krush AJ, et al. The risk of upper gastrointestinal cancer in familial adenomatous polyposis. *Gastroenterology* 1992;102:1980–1982.
29. Asen HF, Bulow S, Myrholm T, et al. Decision analysis in the management of duodenal adenomatosis in familial adenomatous polyposis. *Gut* 1997;40:716–719.
30. Aarnio M, Sankila R, Pukkala E, et al. Cancer risk in mutation carriers of DNA-mismatch-repair genes. *Int J Cancer* 1999;81: 214–218.
31. Sijmons RH, Kiemeneij LA, Witjes JA, et al. Urinary tract cancer and hereditary nonpolyposis colorectal cancer: risks and screening options. *J Urol* 1998;160:466–470.
32. Vasen HF, Stormorken A, Menko FH, et al. MSH2 mutation carriers are at higher risk of cancer than MLH1 mutation carriers: a study of hereditary nonpolyposis colorectal cancer families. *J Clin Oncol* 2001;19:4074–4080.
33. Myrholm T, Andersen MB, Bernstein I. Screening for urinary tract cancer with urine cytology in Lynch syndrome and familial colorectal cancer. *Fam Cancer* 2008;7:303–307.
34. Sieber OM, Howarth KM, Thirlwell C, et al. *MUTYH* deficiency enhances intestinal tumorigenesis in multiple intestinal neoplasia (*APCMin/*) mice. *Cancer Res* 2004;64:8876–8881.
35. Le Page F, Randrianarison V, Marot D, et al. BRCA1 and BRCA2 are necessary for the transcription-coupled repair of the oxidative 8-oxoguanine lesion in human cells. *Cancer Res* 2000;60:5548–5552.
36. Beiner ME, Zhang WW, Zhang S, et al. Mutations of the *MUTYH* gene do not substantially contribute to the risk of breast cancer. *Breast Cancer Res Treat* 2009;114:575–578.
37. Barnettson RA, Devlin L, Miller J, et al. Germline mutation prevalence in the base excision repair gene, *MUTYH*, in patients with endometrial cancer. *Clin Genet* 2007;72:551–555.
38. Tricarico R, Bet P, Ciambotti B, et al. Endometrial cancer and somatic G T KRAS transversion in patients with constitutional *MUTYH* biallelic mutations. *Cancer Lett* 2009;274:266–270.
39. Campbell WJ, Spence RA, Parks TG. The role of congenital hypertrophy of the retinal pigment epithelium in screening for familial adenomatous polyposis. *Int J Colorectal Dis* 1994;9:191–196.
40. Giardiello FM, Petersen GM, Piantadosi S, et al. *APC* gene mutations and extraintestinal phenotype of familial adenomatous polyposis. *Gut* 1997;40:521–525.
41. Mangold E, Pagenstecher C, Leister M, et al. A genotype–phenotype correlation in HNPCC: strong predominance of *msh2* mutations in 41 patients with Muir–Torre syndrome. *J Med Genet* 2004;41:567–572.
42. South CD, Hampel H, Comeras I, et al. The frequency of Muir–Torre syndrome among Lynch syndrome families. *J Natl Cancer Inst* 2008;100:277–281.
43. Entius MM, Keller JJ, Drillenburger P, et al. Microsatellite instability and expression of hMLH-1 and hMSH-2 in sebaceous gland carcinomas as markers for Muir–Torre syndrome. *Clin Cancer Res* 2000;6:1784–1789.

44. ruse R, Rutten A, Lamberti C, et al. Muir-Torre phenotype has a frequency of DNA mismatch-repair-gene mutations similar to that in hereditary nonpolyposis colorectal cancer families defined by the Amsterdam criteria. *Am J Hum Genet* 1998;63:63–70.
45. Ajith Kumar VK, Gold JA, Mallon E, et al. Sebaceous adenomas in an *MUTYH* associated polyposis patient of Indian (Gujarati) origin. *Fam Cancer* 2008;7:187–189.
46. Heinimann K, Mullhaupt B, Weber W, et al. Phenotypic differences in familial adenomatous polyposis based on *APC* gene mutation status. *Gut* 1998;43:675–679.
47. Pujol RM, Casanova JM, Egado R, et al. Multiple familial pilomatricomas: a cutaneous marker for Gardner syndrome? *Pediatr Dermatol* 1995;12:331–335.
48. Urabe K, Xia J, Masuda T, et al. Pilomatricoma-like changes in the epidermoid cysts of Gardner syndrome with an *APC* gene mutation. *J Dermatol* 2004;31:255–257.
49. Chuang CC, Lin HC. Pilomatricoma of the head and neck. *J Chin Med Assoc* 2004;67:633–636.
50. Kairupan C, Scott RJ. Base excision repair and the role of *MUTYH*. *Hered Cancer Clin Pract* 2007;5:199–209.
51. Mazurek A, Berardini M, Fishel R. Activation of human MutS homologs by 8-oxo-guanine DNA damage. *J Biol Chem* 2002;277: 8260–8266.
52. Gu Y, Parker A, Wilson TM, et al. Human MutY homolog, a DNA glycosylase involved in base excision repair, physically and functionally interacts with mismatch repair proteins human MutS homolog 2/ human MutS homolog 6. *J Biol Chem* 2002;277:11135–11142.
53. Russo MT, De Luca G, Degan P, et al. Different DNA repair strategies to combat the threat from 8-oxoguanine. *Mutat Res* 2007;614:69–76.
54. Giardiello FM, Offerhaus GJ, Lee DH, et al. Increased risk of thyroid and pancreatic carcinoma in familial adenomatous polyposis. *Gut* 1993;34:1394–1396.
55. Goecke T, Schulmann K, Engel C, et al. Genotype-phenotype comparison of German MLH1 and MSH2 mutation carriers clinically affected with Lynch syndrome: a report by the German HNPCC Consortium. *J Clin Oncol* 2006;24:4285–4292.
56. Vasen HF, Moslein G, Alonso A, et al. Guidelines for the clinical management of familial adenomatous polyposis (FAP). *Gut* 2008;57:704–713.
57. Albert USH. Stufe-3-Leitlinie Brustkrebs-Früherkennung in Deutschland. 1. Aktualisierung 2008. W. Zuckschwerdt Verlag München, Wien, New York. Available at: <http://leitlinien.net>. Accessed February 2008.
58. Perry N, Broeders M, de Wolf C, et al. European Guidelines for quality assurance in breast cancer screening and diagnosis. 4th ed. Luxembourg: Office for Official Publications of the European Communities, 2006.
59. Otto SJ, Fracheboud J, Looman CW, et al. Initiation of populationbased mammography screening in Dutch municipalities and effect on breast-cancer mortality: a systematic review. *Lancet* 2003;361:1411–1417.
60. Dove-Edwin I, Boks D, Goff S, et al. The outcome of endometrial carcinoma surveillance by ultrasound scan in women at risk of hereditary nonpolyposis colorectal carcinoma and familial colorectal carcinoma. *Cancer* 2002;94:1708–1712.
61. Bastacky S, Ibrahim S, Wilczynski SP, et al. The accuracy of urinary cytology in daily practice. *Cancer* 1999;87:118–128.

Supplementary Table 1. Intestinal and Extraintestinal Tumor Spectrum, MUTYH Mutations and Cause of Death in 276 MUTYH-Associated Polyposis Patients

| Patient no. (1)/relative case no. | Center | Gender | Mutation 1 | Mutation 2 | Age at diagnosis (age ^a) | Cause and age ^a at death | Maximal polyp number | Colorectal cancer (age ^a) | Gastroenterology (age ^a) | No. and histology of duodenal polyps | Duodenal cancer | No. and type of gastric polyps | Extracolonic tumor (age ^a at diagnosis) | |
|-----------------------------------|--------|--------|------------|------------------------|--------------------------------------|-------------------------------------|----------------------|---------------------------------------|--------------------------------------|--------------------------------------|-----------------------------|--------------------------------|--|--|
| 10 | 1 | B | M | c.749G>A, p.Gly250Asp | c.1147delC; p.Ala385ProfsX25 | 37 | alive | multiple | Yes (50) | yes | no | no | Extracolonic tumor (age ^a at diagnosis) | |
| 10 | 2 | B | M | c.749G>A, p.Gly250Asp | c.1147delC; p.Ala385ProfsX25 | 43 | alive | unknown | no | yes | unknown | no | melanoma (59) | |
| 26 | 1 | B | F | c.536A>G, p.Tyr179Cys | c.1457_1459delGGA; p.Gly460del | 29 | alive | multiple | yes (29) | yes (37) | no | no | lipoma (30), 2 other benign cysts (33), hepatic cysts | |
| 26 | 2 | B | F | c.536A>G, p.Tyr179Cys | c.1457_1459delGGA; p.Gly460del | 33 | alive | 250 | yes (33) | yes (36) | 1 adenoma | no | lipoma (30), 2 other benign cysts (33), hepatic cysts | |
| 26 | 3 | B | F | c.536A>G, p.Tyr179Cys | c.1437_1439delGGA; p.Gly460del | 33 | alive | 50 | no | yes (45) | no | no | lipoma | |
| 94 | 1 | B | F | c.536A>G, p.Tyr179Cys | c.1187G>A, p.Gly396Asp | 68 | alive | >100 | no | no | unknown | unknown | benign skin tumor (15), maxillary cysts (21) | |
| 370 | 1 | B | F | c.536A>G, p.Tyr179Cys | c.1147delC; p.Ala385ProfsX25 | 29 | alive | >50 | no | yes (41) | 1 adenoma | no | benign skin tumor (50), spinalioma (60) | |
| 395 | 1 | B | M | c.1187G>A; p.Gly396Asp | c.1214C>T; p.Pro405Leu | 34 | alive | unknown | no | yes (49) | no | no | benign skin tumor (50), spinalioma (60) | |
| 398 | 1 | B | F | c.536A>G, p.Tyr179Cys | c.734G>A; p.Arg245His | 43 | alive | 500-1000 | yes (44) | yes (44) | few polyps, histology no | no | lipoma (54), ovarian cancer (56), benign skin tumor (56) | |
| 415 | 1 | B | M | c.504+19_31del13 | c.734G>A; p.Arg245His | 53 | alive | >100 | yes (49) | yes | no | no | lipoma (54), ovarian cancer (56), benign skin tumor (56) | |
| 489 | 1 | B | F | c.536A>G, p.Tyr179Cys | c.1187G>A, p.Gly396Asp | 36 | alive | 100-500 | no | yes (49) | no | no | lipoma (54), ovarian cancer (56), benign skin tumor (56) | |
| 489 | 2 | B | F | c.536A>G, p.Tyr179Cys | c.1187G>A, p.Gly396Asp | 45 | alive | 100 | yes (46) | yes (45) | no | no | lipoma (54), ovarian cancer (56), benign skin tumor (56) | |
| 526 | 1 | B | F | c.536A>G, p.Tyr179Cys | c.933T>3A>C | 41 | alive | 50-100 | yes (41) | yes (41) | yes | no | lipoma (54), ovarian cancer (56), benign skin tumor (56) | |
| 526 | 2 | B | F | c.536A>G, p.Tyr179Cys | c.933T>3A>C | 27 | alive | <50 | yes (38) | yes (25) | 2 adenomas | no | lipoma (54), ovarian cancer (56), benign skin tumor (56) | |
| 548 | 1 | B | M | c.734G>A, p.Arg245His | c.1147delC; p.Ala385ProfsX25 | 36 | gastric cancer (41) | 100-200 | no | yes (32) | no | no | lipoma (54), ovarian cancer (56), benign skin tumor (56) | |
| 620 | 1 | B | M | c.1187G>A; p.Gly396Asp | c.1187G>A, p.Gly396Asp | 60 | alive | >100 | yes (60) | yes (60) | no | no | lipoma (54), ovarian cancer (56), benign skin tumor (56) | |
| 641 | 1 | B | F | c.536A>G, p.Tyr179Cys | c.1147delC; p.Ala385ProfsX25 | 31 | alive | 70 | no | yes (31) | no | no | lipoma (54), ovarian cancer (56), benign skin tumor (56) | |
| 659 | 1 | B | M | c.536A>G, p.Tyr179Cys | c.933T>3A>C | 52 | alive | 100-500 | yes (52) | yes (52) | no | no | lipoma (54), ovarian cancer (56), benign skin tumor (56) | |
| 660 | 1 | B | M | c.536A>G, p.Tyr179Cys | c.1187G>A, p.Gly396Asp | 46 | alive | 50 | yes (46) | yes (46) | no | no | lipoma (54), ovarian cancer (56), benign skin tumor (56) | |
| 660 | 2 | B | M | c.536A>G, p.Tyr179Cys | c.1187G>A, p.Gly396Asp | 45 | alive | >50 | no | yes (24) | no | no | lipoma (54), ovarian cancer (56), benign skin tumor (56) | |
| 660 | 4 | B | F | c.536A>G, p.Tyr179Cys | c.1187G>A, p.Gly396Asp | 41 | alive | multiple | no | yes (43) | no | no | lipoma (54), ovarian cancer (56), benign skin tumor (56) | |
| 660 | 5 | B | F | c.536A>G, p.Tyr179Cys | c.1187G>A, p.Gly396Asp | 43 | CRC (43) | multiple | yes (43) | no | unknown | unknown | lipoma (54), ovarian cancer (56), benign skin tumor (56) | |
| 676 | 1 | B | M | c.1187G>A; p.Gly396Asp | c.1187G>A, p.Gly396Asp | 38 | unknown (52) | 30-40 | no | yes (46) | no | no | lipoma (54), ovarian cancer (56), benign skin tumor (56) | |
| 698 | 1 | B | M | c.536A>G, p.Tyr179Cys | c.536A>G, p.Tyr179Cys | 49 | alive | multiple | yes (49) | yes (53) | 1 adenoma | no | lipoma (54), ovarian cancer (56), benign skin tumor (56) | |
| 719 | 1 | B | F | c.536A>G, p.Tyr179Cys | c.536A>G, p.Tyr179Cys | 47 | alive | 150 | yes (47) | yes (47) | no | no | lipoma (54), ovarian cancer (56), benign skin tumor (56) | |
| 757 | 1 | B | F | c.536A>G, p.Tyr179Cys | c.933T>3A>C | 40 | alive | 50-100 | no | yes (40) | no | no | lipoma (54), ovarian cancer (56), benign skin tumor (56) | |
| 760 | 1 | B | F | c.1187G>A; p.Gly396Asp | c.1187G>A, p.Gly396Asp | 57 | alive | 5 | yes (57) | yes (61) | no | no | lipoma (54), ovarian cancer (56), benign skin tumor (56) | |
| 774 | 1 | B | M | c.1187G>A; p.Gly396Asp | c.1187G>A, p.Gly396Asp | 48 | alive | >40 | no | no | unknown | unknown | lipoma (54), ovarian cancer (56), benign skin tumor (56) | |
| 786 | 1 | B | F | c.1187G>A; p.Gly396Asp | c.1187G>A, p.Gly396Asp | 39 | alive | 30 | no | yes (39) | no | no | lipoma (54), ovarian cancer (56), benign skin tumor (56) | |
| 787 | 1 | B | M | c.1187G>A; p.Gly396Asp | c.1187G>A, p.Gly396Asp | 51 | alive | 100-500 | no | yes (56) | 4 polyps, histology unknown | no | no | lipoma (54), ovarian cancer (56), benign skin tumor (56) |

Supplementary Table 1. (Continued)

| Patient no. | (J)/relative | Center | Gender | Mutation 1 | Mutation 2 | Age* at diagnosis (age) | Cause and age* at death | Maximal polyp number/colorectum | Colorectal cancer (age) | Gastroenterology (age) | No. and histology of duodenal polyps | No. and type of gastric polyps | Extracolonic tumor (age at diagnosis) | |
|-------------|--------------|--------|--------|------------------------------|---|-------------------------|-------------------------|---------------------------------|-------------------------|------------------------|--------------------------------------|----------------------------------|--|------|
| 818 | 1 | B | M | c.536A>G; p.Tyr1790ys | c.1187G>A, p.Gly396Asp | 37 | alive | >100 | no | yes (37) | no | none | none | |
| 818 | 2 | B | M | c.536A>G; p.Tyr1790ys | c.1187G>A, p.Gly396Asp | 35 | alive | multiple | no | yes (40) | no | none | none | |
| 826 | 1 | B | F | c.536A>G; p.Tyr1790ys | c.933>3A>C | 28 | alive | multiple | no | yes (35) | no | 3 adenomas | adenoma small bowel (4) | |
| 826 | 7 | B | F | c.536A>G; p.Tyr1790ys | c.933>3A>C | 31 | alive | 40 | yes (31) | yes (31) | no | none | none | |
| 848 | 1 | B | F | c.1147delC; p.Ala385ProfsX25 | c.1437_1499delGGA; p.Glu480del | 38 | alive | 100-500 | yes (38) | yes (38) | no | none | lipoma (65) | |
| 858 | 1 | B | M | c.536A>G; p.Tyr1790ys | c.824-829dupCAGGAG; p.Gly276_Gly277insAla_Gly | 49 | alive | >150 | yes (49) | yes (49) | no | none | bladder carcinoma (62), basaloma (62) | |
| 872 | 1 | B | F | c.536A>G; p.Tyr1790ys | c.536A>G; p.Tyr1790ys | 36 | alive | 50-100 | no | yes (37) | 3 adenomas | no | none | |
| 885 | 1 | B | F | c.470C>T; p.Pro157Leu | c.1187G>A; p.Gly396Asp | 36 | alive | <100 | yes (46) | yes (46) | no | none | melanoma (32) | |
| 914 | 1 | B | M | c.289G>T; p.Arg37X | c.1214C>T; p.Pro405Leu | 51 | alive | unknown | yes (51) | yes (51) | no | none | testicular cancer (41) | |
| 925 | 1 | B | M | c.536A>G; p.Tyr1790ys | c.536A>G; p.Tyr1790ys | 48 | CRC (51) | 36 | yes (48) | yes (48) | no | none | benign skin tumor (15) | |
| 973 | 1 | B | M | c.536A>G; p.Tyr1790ys | c.1187G>A; p.Gly396Asp | 50 | alive | 21-50 | no | yes (54) | no | none | none | |
| 973 | 2 | B | M | c.536A>G; p.Tyr1790ys | c.1187G>A; p.Gly396Asp | 43 | alive | 21-50 | yes (43) | yes (43) | unknown | unknown | unknown | none |
| 982 | 1 | B | M | c.536A>G; p.Tyr1790ys | c.536A>G; p.Tyr1790ys | 39 | alive | multiple | yes (54) | yes (54) | no | none | none | |
| 994 | 1 | B | F | c.884C>T; p.Pro295Leu | c.1437_1499delGGA; p.Glu480del | 39 | alive | 20-30 | yes (39) | no | unknown | unknown | unknown | none |
| 1062 | 1 | B | M | c.536A>G; p.Tyr1790ys | c.1187G>A; p.Gly396Asp | 48 | alive | 500-1000 | yes (48) | yes (48) | no | none | benign skin tumor (36), benign endometrial tumor (45) | |
| 1065 | 1 | B | F | c.536A>G; p.Tyr1790ys | c.536A>G; p.Tyr1790ys | 42 | alive | unknown | yes (42) | yes (50) | no | none | none | |
| 1065 | 2 | B | M | c.536A>G; p.Tyr1790ys | c.536A>G; p.Tyr1790ys | 28 | alive | 50-100 | no | yes (28) | no | none | none | |
| 1068 | 1 | B | F | c.820C>T; p.Arg274Ile | c.1518>21>C | 60 | alive | unknown | no | yes (55) | no | none | none | |
| 1077 | 1 | B | F | c.536A>G; p.Tyr1790ys | c.1187G>A; p.Gly396Asp | 44 | alive | 90-100 | no | no | unknown | unknown | unknown | |
| 1077 | 2 | B | M | c.536A>G; p.Tyr1790ys | c.1187G>A; p.Gly396Asp | 61 | alive | >60 | yes (64) | no | unknown | unknown | unknown | |
| 1083 | 1 | B | M | c.536A>G; p.Tyr1790ys | c.1012C>T; p.Gln338X | 24 | alive | 50-100 | no | yes (25) | no | none | hepatic cysts (70) | |
| 1087 | 1 | B | M | c.536A>G; p.Tyr1790ys | c.536A>G; p.Tyr1790ys | 54 | CRC (55) | >100 | yes (54) | yes (54) | no | none | none | |
| 1111 | 1 | B | M | c.536A>G; p.Tyr1790ys | c.1171C>T; p.Gln391X | 49 | alive | 50-70 | no | yes (44) | no | none | no | |
| 1111 | 4 | B | M | c.536A>G; p.Tyr1790ys | c.1171C>T; p.Gln391X | 42 | alive | 100 | yes (43) | yes (52) | no adenomas | no | no | |
| 1114 | 1 | B | F | c.734G>A; p.Arg245His | c.1147delC; p.Ala385ProfsX25 | 63 | alive | 500-1000 | yes (68) | no | unknown | unknown | unknown | |
| 1114 | 2 | B | F | c.734G>A; p.Arg245His | c.1147delC; p.Ala385ProfsX25 | 66 | CRC (68) | unknown | yes (66) | no | unknown | unknown | unknown | |
| 1114 | 3 | B | M | c.734G>A; p.Arg245His | c.1147delC; p.Ala385ProfsX25 | 66 | CRC (63) | unknown | yes (63) | unknown | unknown | unknown | unknown | |
| 1125 | 1 | B | F | c.536A>G; p.Tyr1790ys | c.1187G>A; p.Gly396Asp | 30 | alive | 6-10 | yes (30) | yes (51) | 2 adenomas | no | benign breast tumor (59) | |
| 1126 | 1 | B | F | c.536A>G; p.Tyr1790ys | c.1187G>A; p.Gly396Asp | 38 | alive | >100 | yes (38) | yes (38) | no | no | fundic gland polyp | |
| 1175 | 1 | B | F | c.536A>G; p.Tyr1790ys | c.734G>A; p.Arg245His | 36 | alive | 80 | no | yes (36) | no | none | none | |
| 1175 | 2 | B | F | c.536A>G; p.Tyr1790ys | c.734G>A; p.Arg245His | 40 | alive | <100 | no | yes (40) | no | 1 adenoma, 2 fundic gland polyps | benign skin tumor (36) | |
| 1180 | 1 | B | M | c.536A>G; p.Tyr1790ys | c.1187G>A; p.Gly396Asp | 35 | alive | <100 | yes (47) | yes (47) | no | none | sebaceous gland epithelioma (51) | |
| 1211 | 1 | B | F | c.1147delC; p.Ala385ProfsX25 | c.1187G>A; p.Gly396Asp | 37 | alive | >50 | yes (37) | yes (61) | no | none | none | |
| 1222 | 1 | B | M | c.734G>A; p.Arg245His | c.1187G>A; p.Gly396Asp | 52 | alive | 70 | yes (52) | yes (53) | no | none | sebaceous gland adenoma (47), other benign tumors (48) | |
| 1229 | 1 | B | M | c.1187G>A; p.Gly396Asp | c.1187G>A; p.Gly396Asp | 63 | alive | >50 | yes (63) | no | unknown | unknown | unknown | |
| 1241 | 1 | B | M | c.536A>G; p.Tyr1790ys | c.1187G>A; p.Gly396Asp | 52 | alive | 6-10 | no | no | unknown | unknown | unknown | |

Supplementary Table 1. (Continued)

| Patient no. | Index case (1)/relative | Center | Gender | Mutation 1 | Mutation 2 | Age at diagnosis, age at death | Cause and number of colorectal polyps | Maximal polyp number | Colorectal cancer (age ^a) | Gastroduodenoscopy (age ^a) | No. and histology of duodenal polyps | Duodenal cancer | No. and type of gastric polyps | Extragenital tumor (age ^a at diagnosis) |
|-------------|-------------------------|--------|--------|--------------------------------|--------------------------------|--------------------------------|---------------------------------------|----------------------|---------------------------------------|--|--------------------------------------|---------------------------------------|--------------------------------|--|
| 1241 | 2 | B | M | c.536A>G; p.Tyr1790ys | c.1187G>A; p.Gly396Asp | 53 | alive | >150 | no | yes (53) | no | no | no | pancreatic tumor (51) |
| 1257 | 1 | B | M | c.536A>G; p.Tyr1790ys | c.536A>G; p.Tyr1790ys | 48 | alive | 100-500 | yes (48) | yes (47) | no | no | none | fundic gland polyp |
| 1258 | 1 | B | F | c.536A>G; p.Tyr1790ys | c.536A>G; p.Tyr1790ys | 49 | alive | 50-100 | yes (49) | yes (49) | no | no | none | none |
| 1260 | 1 | B | F | c.628C>T; p.Gln210X | c.1147delC; p.Ala385ProfsX25 | 44 | alive | <50 | no | yes (48) | 2 polyps, histology unknown | no | none | none |
| 1286 | 1 | B | F | c.536A>G; p.Tyr1790ys | c.1214C>T; p.Pro405Leu | 39 | alive | 30 | no | no | unknown | unknown | unknown | thyroid cancer (38), |
| 1286 | 2 | B | M | c.536A>G; p.Tyr1790ys | c.1214C>T; p.Pro405Leu | 44 | alive | many | no | yes (51) | no | no | none | breast cancer (45), |
| 1293 | 1 | B | F | c.536A>G; p.Tyr1790ys | c.933+3A>C | 45 | CRC (52) | multiple | yes (45) | yes (45) | no | no | none | gastric cancer (48), lipoma (33) |
| 1309 | 1 | B | M | c.4631G>C | c.1147delC; p.Ala385ProfsX25 | 32 | alive | 75 | no | yes (32) | no | no | none | none |
| 1309 | 2 | B | F | c.4631G>C | c.1147delC; p.Ala385ProfsX25 | 37 | alive | >25 | no | yes (37) | no | no | none | none |
| 1309 | 3 | B | M | c.4631G>C | c.1147delC; p.Ala385ProfsX25 | 36 | alive | 50-100 | no | yes (36) | no | no | none | none |
| 1315 | 1 | B | M | c.536A>G; p.Tyr1790ys | c.1187G>A; p.Gly396Asp | 66 | alive | >200 | yes (66) | yes (69) | no | no | none | endometrial carcinoma (54), |
| 1323 | 1 | B | F | c.536A>G; p.Tyr1790ys | c.1187G>A; p.Gly396Asp | 33 | alive | few | no | yes (35) | no | no | none | benign skin tumor |
| 1334 | 1 | B | F | c.643G>A; p.Val215Met | c.884C>T; p.Pro295Leu | 30 | alive | multiple | yes (30) | yes (30) | multiple adenomas | no | none | none |
| 1338 | 1 | B | M | c.884C>T; p.Pro295Leu | c.884C>T; p.Pro295Leu | 36 | alive | 50-100 | no | yes (41) | no | no | none | none |
| 1358 | 1 | B | F | c.536A>G; p.Tyr1790ys | c.536A>G; p.Tyr1790ys | 40 | alive | 51 | yes (48) | yes (49) | no | no | none | breast cancer (49) |
| 1358 | 2 | B | M | c.536A>G; p.Tyr1790ys | c.536A>G; p.Tyr1790ys | 45 | alive | <40 | no | yes (53) | no | no | none | none |
| 1371 | 1 | B | F | c.536A>G; p.Tyr1790ys | c.1147delC; p.Ala385ProfsX25 | 37 | alive | multiple | no | yes (37) | no | no | none | none |
| 1372 | 1 | B | M | c.1437_1499delGGA; p.Glu480del | c.1437_1499delGGA; p.Glu480del | 37 | alive | multiple | yes (37) | yes (37) | no | no | none | none |
| 1389 | 1 | B | M | c.595C>T; p.Arg19X | c.1147delC; p.Ala385ProfsX25 | 43 | alive | 60-70 | yes (43) | yes (44) | no | no | none | none |
| 1406 | 1 | B | M | c.536A>G; p.Tyr1790ys | c.1187G>A; p.Gly396Asp | 53 | alive | >100 | yes (53) | no | unknown | unknown | unknown | none |
| 1406 | 2 | B | M | c.536A>G; p.Tyr1790ys | c.1187G>A; p.Gly396Asp | 55 | alive | 50-100 | yes (53) | yes (55) | no | no | none | none |
| 1412 | 1 | B | M | c.536A>G; p.Tyr1790ys | c.536A>G; p.Tyr1790ys | 44 | alive | numerous | yes (44) | yes (50) | no | no | none | lipoma |
| 1412 | 2 | B | F | c.536A>G; p.Tyr1790ys | c.536A>G; p.Tyr1790ys | 34 | alive | <5 | no | unknown | no | no | none | endometrial carcinoma (47) |
| 1412 | 3 | B | F | c.536A>G; p.Tyr1790ys | c.536A>G; p.Tyr1790ys | 33 | alive | multiple | yes (33) | no | unknown | unknown | unknown | benign endometrial tumor (32), ovarian cancer (45) |
| 1421 | 1 | B | M | c.536A>G; p.Tyr1790ys | c.933+3A>C | 52 | alive | some | no | no | unknown | unknown | unknown | benign skin tumor (25) |
| 1451 | 1 | B | M | c.536A>G; p.Tyr1790ys | c.1187G>A; p.Gly396Asp | 49 | alive | some | yes (49) | no | unknown | unknown | unknown | testicular teratoma (28) |
| 1451 | 2 | B | F | c.536A>G; p.Tyr1790ys | c.1187G>A; p.Gly396Asp | 44 | alive | 26 | yes (44) | no | unknown | unknown | unknown | benign endometrial tumor (48) |
| 561 | 1 | B | F | c.722G>A; p.Arg241Gln | c.1187G>A; p.Gly396Asp | 45 | alive | 100-500 | yes (45) | yes (69) | no | no | none | breast cancer (60, 68), spinalioma (68), benign skin tumor |
| 1434 | 1 | B | F | c.536A>G; p.Tyr1790ys | c.1187G>A; p.Gly396Asp | 52 | alive | 50-60 | no | no | unknown | unknown | unknown | unknown |
| 1440 | 1 | B | F | c.536A>G; p.Tyr1790ys | c.884C>T; p.Pro295Leu | 51 | alive | 50-60 | yes (31) | yes (31) | no | no | none | none |
| 1468 | 1 | B | M | c.536A>G; p.Tyr1790ys | c.1187G>A; p.Gly396Asp | 58 | alive | 50-60 | yes (64) | yes (50) | no | unknown number of hyperplastic polyps | unknown number and histology | unknown |

Supplementary Table 1. (Continued)

| Patient no. | Indx | case no. | Relative Center | Gender | Mutation 1 | Mutation 2 | Age at diagnosis | Cause and age ^a at death | Maximal polyp number | Colorectal cancer (age ^b) | Gastrointestinal polyps (age ^c) | No. and histology of duodenal polyps | Duodenal cancer | No. and type of gastric polyps | Extracolonic tumor (age ^d at diagnosis) | |
|-------------|------|----------|-----------------|------------------------|--------------------------------|------------|--------------------------------|-------------------------------------|----------------------|---------------------------------------|---|--------------------------------------|-----------------|--------------------------------|--|---------------|
| 1512 | 1 | B | M | c.536A>G; p.Y1790Ys | c.933+3A>C | 40 | alive | multiple | no | no | yes (40) | no | no | none | Extracolonic tumor | |
| 2220 | 1 | L | F | c.1214C>T; p.Pro405Leu | c.1214C>T; p.Pro405Leu | 40 | alive | multiple | no | no | no | no | unknown | unknown | | |
| 2380 | 1 | L | M | c.1214C>T; p.Pro405Leu | c.739 C>T; p.Arg247X | 48 | alive | 10-100 | yes (48) | yes (47) | no | no | no | none | | |
| 19036 | 1 | L | M | c.536A>G; p.Y1790Ys | c.536A>G; p.Y1790Ys | 41 | CRC (44) | multiple | yes (41) | no | no | unknown | unknown | unknown | unknown | |
| 19045 | 1 | L | F | c.536A>G; p.Y1790Ys | c.6911 G>A | 42 | alive | 10-50 | yes (41) | no | no | unknown | unknown | unknown | unknown | |
| 19047 | 1 | L | F | c.1187G>A; p.Gly396Asp | c.1187G>A; p.Gly396Asp | 33 | alive | 10-20 | no | no | no | unknown | unknown | unknown | unknown | |
| 19047 | 1 | L | F | c.1187G>A; p.Gly396Asp | c.1187G>A; p.Gly396Asp | 40 | alive | polypsis | no | no | yes (60) | no | no | none | | |
| 19047 | 2 | L | M | c.1187G>A; p.Gly396Asp | c.1187G>A; p.Gly396Asp | 30 | alive | 1 | no | no | no | unknown | unknown | unknown | unknown | |
| 19047 | 3 | L | M | c.1187G>A; p.Gly396Asp | c.1187G>A; p.Gly396Asp | 38 | alive | 2 | no | no | no | unknown | unknown | unknown | unknown | |
| 19047 | 4 | L | M | c.1187G>A; p.Gly396Asp | c.1187G>A; p.Gly396Asp | 57 | CRC (58) | polyps | yes (57) | no | no | unknown | unknown | unknown | unknown | |
| 19047 | 5 | L | M | c.1187G>A; p.Gly396Asp | c.1187G>A; p.Gly396Asp | 70 | alive | polypsis | yes (70) | no | no | unknown | unknown | unknown | unknown | |
| 19049 | 1 | L | M | c.536A>G; p.Y1790Ys | c.536A>G; p.Y1790Ys | 46 | alive | multiple | no | no | no | unknown | unknown | unknown | bladder carcinoma (60), other benign tumors (62), benign skin tumor | |
| 19049 | 2 | L | M | c.536A>G; p.Y1790Ys | c.536A>G; p.Y1790Ys | 53 | unknown (71) | 100-1000 | yes (53) | yes (53) | no | unknown | unknown | unknown | unknown | unknown |
| 19049 | 3 | L | M | c.536A>G; p.Y1790Ys | c.536A>G; p.Y1790Ys | 56 | other cancer than CRC (74) | 100-1000 | yes (56) | yes (56) | yes (57) | no | no | none | carcinoma of the skin (48), benign skin tumor (60), bladder carcinoma (67) | |
| 19049 | 4 | L | M | c.536A>G; p.Y1790Ys | c.536A>G; p.Y1790Ys | 50 | accident (77) | 100-1000 | no | no | no | unknown | unknown | unknown | prostate cancer (62), benign skin tumor (63) | |
| 19053 | 1 | L | M | c.536A>G; p.Y1790Ys | c.933+3A>C | 51 | alive | polypsis | yes (51) | yes (51) | no | unknown | unknown | unknown | unknown | |
| 19053 | 2 | L | M | c.536A>G; p.Y1790Ys | c.933+3A>C | 53 | disease other than cancer (76) | polypsis | yes (53) | yes (53) | no | unknown | unknown | unknown | unknown | |
| 19095 | 1 | L | M | c.536A>G; p.Y1790Ys | c.536A>G; p.Y1790Ys | 37 | alive | >100 | no | no | no | unknown | unknown | unknown | unknown | |
| 19095 | 2 | L | M | c.536A>G; p.Y1790Ys | c.536A>G; p.Y1790Ys | 44 | alive | 3 | no | no | yes (52) | unknown | unknown | unknown | unknown | |
| 19095 | 3 | L | M | c.536A>G; p.Y1790Ys | c.536A>G; p.Y1790Ys | 46 | alive | 25-50 | no | no | yes (50) | no | no | none | fundic gland polyp | |
| 19095 | 4 | L | M | c.536A>G; p.Y1790Ys | c.536A>G; p.Y1790Ys | 46 | alive | numerous | no | no | yes (50) | no | no | none | fundic gland polyp | |
| 19106 | 1 | L | F | c.536A>G; p.Y1790Ys | c.536A>G; p.Y1790Ys | 40 | alive | 10-50 | yes (40) | yes (40) | yes (50) | 25 adenomas | adenomas | no | fundic gland polyp | |
| 19221 | 1 | L | M | c.536A>G; p.Y1790Ys | c.1214C>T; p.Pro405Leu | 45 | CRC (56) | 30-100 | yes (45) | yes (45) | yes (56) | 1 adenoma | adenoma | yes | none | melanoma (30) |
| 19241 | 2 | L | F | c.536A>G; p.Y1790Ys | c.1214C>T; p.Pro405Leu | 46 | CRC (46) | unknown | yes (46) | yes (46) | no | unknown | unknown | unknown | unknown | |
| 19247 | 1 | L | M | c.536A>G; p.Y1790Ys | c.536A>G; p.Y1790Ys | 48 | CRC (64) | multiple | yes (43) | yes (43) | yes (63) | no | no | none | benign skin tumor | |
| 19247 | 2 | L | M | c.536A>G; p.Y1790Ys | c.536A>G; p.Y1790Ys | 51 | CRC (61) | unknown | yes (61) | yes (61) | no | unknown | unknown | unknown | unknown | |
| 19247 | 3 | L | M | c.536A>G; p.Y1790Ys | c.536A>G; p.Y1790Ys | 47 | unknown (52) | 60 | no | no | no | unknown | unknown | unknown | unknown | |
| 20090 | 1 | L | M | c.536A>G; p.Y1790Ys | c.1214C>T; p.Pro405Leu | 0 | alive | 10-100 | yes (50) | yes (50) | yes (62) | no | no | none | none | |
| 20090 | 2 | L | M | c.536A>G; p.Y1790Ys | c.114C>T; p.Pro405Leu | 29 | CRC (40) | few | no | no | no | unknown | unknown | unknown | unknown | unknown |
| 5076 | 1 | L | M | c.536A>G; p.Y1790Ys | c.1187G>A; p.Gly396Asp | 48 | alive | 50 | no | no | yes (52) | no | no | none | none | |
| 5076 | 2 | L | F | c.536A>G; p.Y1790Ys | c.1187G>A; p.Gly396Asp | 48 | alive | 7 | yes (44) | yes (44) | yes (51) | no | no | none | none | |
| 51063 | 1 | L | F | c.536A>G; p.Y1790Ys | c.536A>G; p.Y1790Ys | 33 | alive | 50-100 | yes (44) | yes (44) | yes (46) | no | no | 20 fundic gland polyps | benign skin tumor (46) | |
| 51545 | 1 | L | M | c.536A>G; p.Y1790Ys | c.1147delC; p.Ala385P>ProfsK25 | 42 | alive | polypsis | no | no | yes (61) | no | no | none | none | |

Supplementary Table 1. (Continued)

| Patient no. | (1)/relative | Index case | Center | Gender | Mutation 1 | Mutation 2 | Age at diagnosis (age) | Cause and age at death | Maximal poly number | Colorectal polyp (age) | Gastroenterology (age) | No. and histology of duodenal polyps | Duodenal cancer | No. and type of gastric polyps | Extracolonic tumor (age at diagnosis) | |
|-------------|--------------|------------|--------|------------------------------|------------------------------|------------|---------------------------|------------------------|---------------------|------------------------|------------------------|--------------------------------------|-----------------|--------------------------------|---------------------------------------|------------------------|
| 52105 | 1 | L | M | c.536A>G; p.Y1790ys | c.536A>G; p.Y1790ys | 43 | alive | polyps | no | no | yes (58) | 1 adenoma | no | none | basalioma (71) | |
| 52105 | 1 | L | M | c.536A>G; p.Y1790ys | c.1187G>A; p.Gly396Asp | 53 | alive | polyps | no | no | yes (50) | unknown | unknown | none | breast cancer (55) | |
| 52240 | 1 | L | F | c.1214C>T; p.Pro405Leu | c.1214C>T; p.Pro405Leu | 57 | CRC (58) | polyps | yes (58) | yes (58) | no | unknown | unknown | none | breast cancer (55) | |
| 52596 | 1 | L | F | p.Pro405Leu | c.536A>G; p.Y1790ys | 39 | alive | polyps | yes (39) | yes (39) | yes (42) | no | no | none | benign skin tumor (50) | |
| 52638 | 1 | L | M | c.1187G>A; p.Gly396Asp | c.325C>T; p.Arg109Tyr | 52 | CRC (53) | polyps | yes (52) | yes (52) | yes (50) | no | no | none | benign skin tumor (50) | |
| 52654 | 1 | L | M | c.1214C>T; p.Pro405Leu | c.1214C>T; p.Pro405Leu | 37 | CRC (39) | polyps | yes (37) | yes (37) | no | unknown | unknown | none | benign skin tumor (50) | |
| 52654 | 2 | L | F | c.1214C>T; p.Pro405Leu | c.1214C>T; p.Pro405Leu | 41 | CRC (42) | numerous | yes (41) | yes (41) | no | unknown | unknown | unknown | none | benign skin tumor (50) |
| 52689 | 1 | L | M | c.1171C>T; p.Gln391X | c.1171delC; p.Gln391X | 36 | unknown cause/age | numerous | no | no | no | unknown | unknown | unknown | none | benign skin tumor (50) |
| 52699 | 1 | L | M | c.536A>G; p.Y1790ys | c.1147delC; p.Ala85ProfsX25 | 37 | alive | 10-100 | no | no | yes (37) | no | no | none | benign skin tumor (50) | |
| 53029 | 1 | L | F | c.536A>G; p.Y1790ys | c.1214C>T; p.Pro405Leu | 44 | alive | 10-100 | no | no | yes (59) | no | no | fundic gland polyp | benign skin tumor (50) | |
| 53029 | 2 | L | M | c.536A>G; p.Y1790ys | c.1214C>T; p.Pro405Leu | 41 | CRC (46) | multiple | yes (41) | yes (41) | yes (42) | no | no | none | benign skin tumor (50) | |
| 53231 | 1 | L | F | c.1187G>A; p.Gly396Asp | c.1187G>A; p.Gly396Asp | 59 | CRC (62) | polyps | yes (59) | yes (59) | no | unknown | unknown | none | benign skin tumor (50) | |
| 53276 | 1 | L | M | c.1187G>A; p.Gly396Asp | c.1214C>T; p.Pro405Leu | 48 | alive | 100-1000 | yes (48) | yes (48) | yes (57) | yes | no | none | basalioma (58) | |
| 54092 | 1 | L | F | p.Gly396Asp | c.1187G>A; p.Gly396Asp | 60 | alive | <100 | yes (60) | yes (60) | no | unknown | unknown | none | benign skin tumor (50) | |
| 54092 | 2 | L | M | c.1187G>A; p.Gly396Asp | c.1187G>A; p.Gly396Asp | 57 | alive | 30-50 | no | no | yes (42) | no | unknown | unknown | none | benign skin tumor (50) |
| 54140 | 1 | L | F | c.1227_1228dupGG; p.Gln1084S | c.1227_1228dupGG; p.Gln1084S | 42 | alive | 10-50 | yes (42) | yes (42) | no | unknown | unknown | none | benign skin tumor (50) | |
| 54178 | 1 | L | F | c.1187G>A; p.Gly396Asp | c.1214C>T; p.Pro405Leu | 44 | alive | 50-100 | yes (44) | yes (44) | yes (52) | no | no | none | benign skin tumor (50) | |
| 54186 | 1 | L | F | c.536A>G; p.Y1790ys | c.536A>G; p.Y1790ys | 45 | CRC (49) | polyps | yes (45) | yes (45) | no | unknown | unknown | none | benign skin tumor (50) | |
| 54186 | 2 | L | F | c.536A>G; p.Y1790ys | c.536A>G; p.Y1790ys | 43 | CRC (44) | 50 | yes (43) | yes (43) | yes (43) | yes | no | none | benign skin tumor (50) | |
| 54245 | 1 | L | F | c.536A>G; p.Y1790ys | c.536A>G; p.Y1790ys | 54 | unknown, 83 | 10-100 | yes (54) | yes (54) | no | unknown | unknown | none | benign skin tumor (50) | |
| 54245 | 2 | L | F | c.536A>G; p.Y1790ys | c.536A>G; p.Y1790ys | 64 | disease other than cancer | 1 | yes (64) | yes (64) | no | unknown | unknown | none | benign skin tumor (50) | |
| 54856 | 1 | L | F | c.536A>G; p.Y1790ys | c.1187G>A; p.Gly396Asp | 54 | alive | 10-100 | no | no | yes (55) | no | no | none | benign skin tumor (50) | |
| 54856 | 2 | L | F | c.536A>G; p.Y1790ys | c.1187G>A; p.Gly396Asp | 60 | CRC (71) | unknown | yes (61) | yes (61) | no | unknown | unknown | none | benign skin tumor (50) | |
| 54856 | 3 | L | M | c.536A>G; p.Y1790ys | c.1187G>A; p.Gly396Asp | 66 | CRC (68) | numerous | yes (66) | yes (66) | yes (47) | no | no | none | benign skin tumor (50) | |
| 54962 | 1 | L | F | c.1187G>A; p.Gly396Asp | c.1214C>T; p.Pro405Leu | 41 | alive | 50-100 | no | no | yes (47) | no | no | none | benign skin tumor (50) | |
| 54962 | 2 | L | F | c.1187G>A; p.Gly396Asp | c.1214C>T; p.Pro405Leu | 51 | alive | 1 | yes (51) | yes (51) | yes (55) | no | no | none | benign skin tumor (50) | |
| 55123 | 1 | L | F | c.536A>G; p.Y1790ys | c.1187G>A; p.Gly396Asp | 58 | alive | 30 | yes (58) | yes (58) | yes (65) | no | no | none | benign skin tumor (50) | |
| 55247 | 1 | L | F | c.536A>G; p.Y1790ys | c.739 C>T; p.Arg247X | 46 | alive | 50-100 | yes (46) | yes (46) | yes (63) | no | no | none | benign skin tumor (50) | |
| 55356 | 1 | L | F | c.1214C>T; p.Ala85ProfsX25 | c.1147delC; p.Ala85ProfsX25 | 40 | unknown (70) | polyps | yes (42) | yes (42) | yes (58) | no | no | none | benign skin tumor (50) | |

Supplementary Table 1. (Continued)

| Patient no. | Index case | Center | Gender | Mutation 1 | Mutation 2 | Age* at diagnosis | Cause and age* at death | Maximal polyp number | Colorectal cancer (age*) | Gastroenteroscopy (age*) | No. and histology of duodenal polyps | Duodenal cancer | No. and types of gastric polyps | Extracolonic tumor (age* at diagnosis) |
|-------------|------------|--------|--------|--------------------------------|--------------------------------|-------------------|--------------------------------|----------------------|--------------------------|--------------------------|--------------------------------------|-----------------|---------------------------------|--|
| 55535 | 1 | L | M | c.536A>G; p.TyT1790ys | c.536A>G; p.TyT1790ys | 45 | CRC (45) | 35 | yes (45) | no | unknown | unknown | unknown | |
| 56081 | 1 | L | F | c.536A>G; p.TyT1790ys | c.1187G>A; p.Gly396Asp | 59 | alive | >20 | yes (59) | no | unknown | unknown | unknown | |
| 56081 | 2 | L | M | c.536A>G; p.TyT1790ys | c.1187G>A; p.Gly396Asp | 50 | alive | 20-25 | yes (49) | no | unknown | unknown | unknown | |
| 56081 | 3 | L | M | c.536A>G; p.TyT1790ys | c.1187G>A; p.Gly396Asp | 58 | alive | multiple | no | no | unknown | unknown | unknown | |
| 56081 | 4 | L | M | c.536A>G; p.TyT1790ys | c.1187G>A; p.Gly396Asp | 42 | alive | multiple | no | yes (48) | no | no | none | |
| 56351 | 1 | L | M | c.536A>G; p.TyT1790ys | c.536A>G; p.TyT1790ys | 34 | alive | >100 | yes (36) | yes (36) | yes | no | none | benign skin tumor |
| 56566 | 1 | L | M | c.536A>G; p.TyT1790ys | c.1187G>A; p.Gly396Asp | 67 | alive | >100 | yes (67) | yes (67) | no | no | none | benign skin tumor |
| 56566 | 2 | L | M | c.536A>G; p.TyT1790ys | c.1187G>A; p.Gly396Asp | 67 | unknown if deceased | | unknown | unknown | no | unknown | unknown | |
| 56641 | 1 | L | F | c.536A>G; p.TyT1790ys | c.1187G>A; p.Gly396Asp | 43 | alive | 10-50 | yes (43) | yes (53) | no | no | none | benign endometrial tumor (57) |
| 57135 | 1 | L | F | c.536A>G; p.TyT1790ys | c.536A>G; p.TyT1790ys | 45 | CRC (49) | >25 | yes (46) | no | unknown | unknown | unknown | basaloma (44) |
| 57137 | 1 | L | F | c.536A>G; p.TyT1790ys | c.1147delC; p.Ala385ProfsX25 | 21 | alive | 36 | yes (21) | yes (28) | no | no | none | |
| 57139 | 1 | L | M | c.1187G>A; p.Gly396Asp | c.1147delC; p.Ala385ProfsX25 | 42 | alive | 10-50 | yes (42) | yes (61) | no | no | none | |
| 57246 | 1 | L | M | c.536A>G; p.TyT1790ys | c.536A>G; p.TyT1790ys | 65 | alive | 10-100 | yes (65) | yes (65) | 2 adenomas | yes | none | esophageal cancer (59) |
| 57249 | 1 | L | M | c.536A>G; p.TyT1790ys | c.536A>G; p.TyT1790ys | 49 | alive | polyps | yes (49) | yes (49) | no | no | none | |
| 57249 | 2 | L | F | c.536A>G; p.TyT1790ys | c.536A>G; p.TyT1790ys | 48 | alive | multiple | yes (49) | yes (49) | no | no | none | |
| 57249 | 3 | L | M | c.536A>G; p.TyT1790ys | c.536A>G; p.TyT1790ys | 52 | alive | numerous | yes (52) | yes (58) | no | no | none | |
| 57308 | 1 | L | M | c.1187G>A; p.Gly396Asp | c.1187G>A; p.Gly396Asp | 44 | disease other than cancer (47) | >15 | no | no | unknown | unknown | unknown | |
| 57449 | 1 | L | M | c.536A>G; p.TyT1790ys | c.536A>G; p.TyT1790ys | 45 | alive | >100 | yes (45) | yes (58) | no | no | none | sebaceous gland adenoma (68), benign skin tumor (74) |
| 57591 | 1 | L | M | c.1214C>T; p.Pro405Leu | c.933+3A>C | 40 | CRC (41) | 50-100 | yes (40) | no | unknown | unknown | unknown | |
| 57976 | 1 | L | F | c.536A>G; p.TyT1790ys | c.1214C>T; p.Pro405Leu | 49 | unknown if deceased | 12 | no | no | unknown | unknown | unknown | |
| 58746 | 1 | L | F | c.536A>G; p.TyT1790ys | c.536A>G; p.TyT1790ys | 27 | alive | 30-40 | no | yes (29) | no | no | none | |
| 60322 | 2 | L | M | c.536A>G; p.TyT1790ys | c.536A>G; p.TyT1790ys | 64 | alive | 30-40 | yes | yes | no | unknown | unknown | |
| 60322 | 3 | L | F | c.536A>G; p.TyT1790ys | c.536A>G; p.TyT1790ys | 55 | alive | 30-40 | yes | no | unknown | unknown | unknown | |
| 60406 | 1 | L | M | c.1437_1499delGGG; p.Glu480del | c.1437_1499delGGG; p.Glu480del | 49 | alive | 10-100 | yes (51) | no | unknown | unknown | unknown | |
| 60406 | 2 | L | M | c.1437_1499delGGG; p.Glu480del | c.1437_1499delGGG; p.Glu480del | 49 | unknown if deceased | 30 | no | yes (50) | no | no | fundic gland polyps | benign skin tumor (53) |
| 62515 | 1 | L | M | c.536A>G; p.TyT1790ys | c.1214C>T; p.Pro405Leu | 29 | alive | 30-40 | no | no | unknown | unknown | unknown | benign skin tumor (38) |
| 62805 | 1 | L | M | c.536A>G; p.TyT1790ys | c.536A>G; p.TyT1790ys | 63 | alive | 10-100 | no | yes (67) | no | unknown | unknown | |
| 65739 | 1 | L | M | c.536A>G; p.TyT1790ys | c.925C>T; p.Arg300Gys | 63 | alive | 10-20 | no | yes (58) | no | no | none | |
| 67143 | 1 | L | F | c.536A>G; p.TyT1790ys | c.1187G>A; p.Gly396Asp | 61 | alive | 20-50 | yes (61) | yes (70) | no | no | none | benign skin tumor (54) |
| 67143 | 2 | L | M | c.536A>G; p.TyT1790ys | c.1187G>A; p.Gly396Asp | 61 | unknown if deceased | | unknown | no | unknown | unknown | unknown | |
| 1 | 1 | C | M | c.536A>G; p.TyT1790ys | c.1187G>A; p.Gly396Asp | 31 | alive | 2 | yes (36) | no | unknown | unknown | unknown | benign skin tumor (33) |
| 2 | 1 | C | F | c.536A>G; p.TyT1790ys | c.1187G>A; p.Gly396Asp | 40 | alive | 1 | no | no | unknown | unknown | unknown | benign breast tumor (22) |
| 2 | 2 | C | F | c.1187G>A; p.Gly396Asp | c.933+3A>C | 34 | alive | >6 | no | yes (35) | no | unknown | unknown | |
| 2 | 2 | C | F | c.1187G>A; p.Gly396Asp | c.933+3A>C | 41 | alive | 20 | no | unknown | no | unknown | unknown | |
| 2 | 3 | C | F | c.1187G>A; p.Gly396Asp | c.933+3A>C | 57 | alive | unknown | yes (57) | unknown | no | unknown | unknown | ovarian cancer |
| 2 | 4 | C | F | c.1187G>A; p.Gly396Asp | c.933+3A>C | 40 | alive | multiple | no | no | unknown | unknown | unknown | other benign tumors |
| 2 | 5 | C | M | c.1187G>A; p.Gly396Asp | c.933+3A>C | 40 | alive | a number of polyps | no | unknown | no | unknown | unknown | |

Supplementary Table 1. (Continued)

| Patient no. (1)/relative no. | Sex | Center | Gender | Mutation 1 | Mutation 2 | Age at diagnosis | Cause and age at death | Maximal polyp number/colorectum | Colorectal cancer (age ^a) | Gastrointestinal (age ^b) | No. and histology of duodenal polyps | Duodenal cancer | No. and type of gastric polyps | Extragenital tumor (age ^c at diagnosis) |
|------------------------------|-----|--------|--------|------------------------|------------------------|------------------|------------------------|---------------------------------|---------------------------------------|--------------------------------------|--------------------------------------|-----------------|------------------------------------|--|
| 3 | 1 | C | F | c.14386>T; p.Glu480X | c.14386>T; p.Glu480X | 51 | alive | 40-50 | no | yes (48) | no | no | none | |
| 4 | 1 | C | M | c.536A>G; p.Tyr1790ys | c.1187G>A; p.Gly396Asp | 47 | alive | 25-30 | yes (47) | yes (50) | no | no | none | |
| 5 | 1 | C | F | c.536A>G; p.Tyr1790ys | c.536A>G; p.Tyr1790ys | 36 | alive | >100 | yes (51) | unknown | no | no | none | |
| 6 | 1 | C | M | c.536A>G; p.Tyr1790ys | c.1187G>A; p.Gly396Asp | 47 | alive | 20-50 | no | no | unknown | unknown | unknown | |
| 7 | 1 | C | M | c.536A>G; p.Tyr1790ys | c.536A>G; p.Tyr1790ys | 41 | alive | 156 | no | no | unknown | unknown | unknown | |
| 8 | 1 | C | M | c.1187G>A; p.Gly396Asp | c.1187G>A; p.Gly396Asp | 62 | alive | 70 | yes (62) | unknown | no | no | none | |
| 9 | 1 | C | F | c.536A>G; p.Tyr1790ys | c.3894G>A | 56 | alive | 14 | no | unknown | no | no | none | |
| 10 | 1 | C | M | c.536A>G; p.Tyr1790ys | c.1187G>A; p.Gly396Asp | 48 | unknown cause/age | <100 | no | no | unknown | unknown | unknown | |
| 11 | 1 | C | M | c.312C>A; p.Tyr104X | c.312C>A; p.Tyr104X | 51 | alive | 432 | yes (51) | yes (55) | no | no | none | |
| 12 | 1 | C | M | c.14386>T; p.Glu480X | c.14386>T; p.Glu480X | 37 | CRC (38) | >25 | yes (37) | yes (37) | no | no | none | |
| 12 | 2 | C | F | c.14386>T; p.Glu480X | c.14386>T; p.Glu480X | 44 | alive | 143 | no | unknown | unknown | unknown | unknown | |
| 12 | 3 | C | F | c.14386>T; p.Glu480X | c.14386>T; p.Glu480X | 36 | alive | 120 | no | unknown | unknown | unknown | unknown | |
| 13 | 1 | C | M | c.536A>G; p.Tyr1790ys | c.536A>G; p.Tyr1790ys | 45 | alive | >10 | no | yes (36) | no | no | none | |
| 14 | 1 | C | F | c.536A>G; p.Tyr1790ys | c.1187G>A; p.Gly396Asp | 43 | alive | 3 | yes (43) | yes (46) | no | no | none | |
| 14 | 2 | C | M | c.536A>G; p.Tyr1790ys | c.1187G>A; p.Gly396Asp | 53 | alive | >100 | yes (45) | no | unknown | unknown | unknown | |
| 14 | 3 | C | M | c.536A>G; p.Tyr1790ys | c.1187G>A; p.Gly396Asp | CRC (47) | | multiple | yes (45) | no | unknown | unknown | unknown | |
| 14 | 4 | C | M | c.536A>G; p.Tyr1790ys | c.1187G>A; p.Gly396Asp | CRC (43) | | unknown | no | no | unknown | unknown | unknown | |
| 15 | 1 | C | M | c.536A>G; p.Tyr1790ys | c.1187G>A; p.Gly396Asp | 49 | alive | 50-100 | no | no | unknown | unknown | unknown | |
| 15 | 2 | C | F | c.536A>G; p.Tyr1790ys | c.1187G>A; p.Gly396Asp | 51 | alive | multiple | no | no | unknown | unknown | unknown | |
| 15 | 3 | C | M | c.536A>G; p.Tyr1790ys | c.1187G>A; p.Gly396Asp | 46 | CRC (47) | 2 adenomas in resection | yes (46) | unknown | no | no | none | |
| 16 | 1 | C | M | c.1187G>A; p.Gly396Asp | Gln338X | 49 | alive | multiple | no | no | unknown | unknown | unknown | |
| 16 | 2 | C | F | c.1187G>A; p.Gly396Asp | Gln338X | 50 | CRC (50) | 19 | yes (50) | unknown | no | no | none | |
| 17 | 1 | C | F | c.536A>G; p.Tyr1790ys | c.536A>G; p.Tyr1790ys | 38 | alive | multiple | yes (38) | no | unknown | unknown | unknown | breast cancer (71) |
| 18 | 1 | C | F | c.536A>G; p.Tyr1790ys | c.1518+2T>C | 41 | alive | multiple | yes (41) | no | unknown | unknown | unknown | benign skin tumor (95) |
| 19 | 1 | C | M | c.14386>T; p.Glu480X | c.14386>T; p.Glu480X | 49 | alive | 200 | no | yes (49) | no | no | none | |
| 20 | 1 | C | M | c.312C>A; p.Tyr104X | c.312C>A; p.Tyr104X | 62 | alive | unknown (47) | unknown | unknown | no | no | none | |
| 20 | 2 | C | F | c.312C>A; p.Tyr104X | c.312C>A; p.Tyr104X | 57 | alive | >100 | yes (59) | yes (63) | no | no | none | |
| 20 | 3 | C | F | c.312C>A; p.Tyr104X | c.312C>A; p.Tyr104X | 38 | alive | >100 | yes (59) | no | unknown | unknown | unknown | |
| 20 | 4 | C | F | c.312C>A; p.Tyr104X | c.312C>A; p.Tyr104X | 46 | alive | >100 | no | no | unknown | unknown | unknown | |
| 20 | 5 | C | F | c.312C>A; p.Tyr104X | c.312C>A; p.Tyr104X | 46 | alive | >100 | no | no | unknown | unknown | unknown | |
| 21 | 1 | C | M | c.536A>G; p.Tyr1790ys | c.536A>G; p.Tyr1790ys | 35 | alive | 10-50 | yes (45) | yes (49) | no | no | none | |
| 21 | 2 | C | M | c.536A>G; p.Tyr1790ys | c.536A>G; p.Tyr1790ys | 53 | CRC (53) | 17 | yes (53) | yes (53) | no | no | none | |
| 22 | 1 | C | F | c.536A>G; p.Tyr1790ys | c.1187G>A; p.Gly396Asp | 65 | CRC (69) | >100 | yes (65) | unknown | no | no | none | |
| 23 | 1 | C | M | c.14386>T; p.Glu480X | c.14386>T; p.Glu480X | 65 | CRC (69) | >150 | yes (65) | yes (65) | no | no | multiple polyps, histology unknown | kidney cysts |
| 24 | 1 | C | M | c.1187G>A; p.Gly396Asp | Asn238Ser | 50 | alive | multiple small sessile polyps | yes (50) | no | unknown | unknown | unknown | benign skin tumor (50) |
| 25 | 1 | C | M | c.536A>G; p.Tyr1790ys | c.1187G>A; p.Gly396Asp | 65 | alive | numerous | yes (65) | no | unknown | unknown | unknown | |
| 26 | 1 | C | M | c.536A>G; p.Tyr1790ys | c.1187G>A; p.Gly396Asp | 46 | alive | 50-75 | no | no | unknown | unknown | unknown | |
| 26 | 2 | C | M | c.536A>G; p.Tyr1790ys | c.1187G>A; p.Gly396Asp | 45 | alive | few | no | no | unknown | unknown | unknown | |
| 26 | 3 | C | F | c.536A>G; p.Tyr1790ys | c.1187G>A; p.Gly396Asp | 45 | alive | >100 | no | no | unknown | unknown | unknown | |
| 26 | 4 | C | M | c.536A>G; p.Tyr1790ys | c.1187G>A; p.Gly396Asp | 41 | alive | few | no | no | unknown | unknown | unknown | |
| 26 | 5 | C | M | c.536A>G; p.Tyr1790ys | c.1187G>A; p.Gly396Asp | 44 | alive | 76 than cancer (46) | yes (44) | yes (44) | no | no | none | |

Supplementary Table 1. (Continued)

| Patient no. (1/Relative no.) | Index case | Center | Gender | Mutation 1 | Mutation 2 | Age* at diagnosis, age* at death | Case and age* at death | Maximal polyp number colorectum | Colorectal cancer (age*) | Gastroenterology (age*) | No. and histology of duodenal polyps | Duodenal cancer | No. and type of gastric polyps | Extraesophageal tumor (age* at diagnosis) |
|------------------------------|------------|--------|--------|-----------------------|------------------------------|----------------------------------|--------------------------------|---------------------------------|--------------------------|-------------------------|--------------------------------------|-----------------|--------------------------------|--|
| 27 | 1 | C | F | c.536A>G; p.Y1790ys | c.536A>G; p.Y1790ys | 45 | alive | numerous | yes (45) | yes (59) | no | no | none | Extraesophageal tumor (age* at diagnosis) |
| 28 | 1 | C | M | c.536A>G; p.Y1790ys | c.1187G>A; p.G1396Asp | 52 | alive | 20-30 | no | yes (62) | no | no | none | cancer of soft palate (46), sebaceous gland adenoma (28) |
| 29 | 1 | C | M | c.536A>G; p.Y1790ys | c.1187G>A; p.G1396Asp | 44 | alive | >20 | no | yes (45) | no | no | none | gastric cancer (17) |
| 30 | 1 | C | M | c.1187G>A; p.G1396Asp | c.1187G>A; p.G1396Asp | 36 | alive | 4 | yes (37) | yes (38) | no | no | none | |
| 31 | 1 | C | M | c.536A>G; p.Y1790ys | c.1187G>A; p.G1396Asp | 12 | gastric cancer (17) | >100 | no | yes (17) | no | no | none | |
| 31 | 2 | C | M | c.536A>G; p.Y1790ys | c.1187G>A; p.G1396Asp | 14 | alive | >100 | no | yes (14) | unknown | no | none | |
| 32 | 1 | C | F | c.536A>G; p.Y1790ys | c.1187G>A; p.G1396Asp | 58 | CRC (60) | multiple | yes (58) | yes (59) | no | no | none | |
| 33 | 1 | C | M | c.1438G>T; p.G1480X | c.1438G>T; p.G1480X | 55 | disease other than cancer (69) | multiple | yes (55) | yes (55) | no | no | none | |
| 34 | 1 | C | M | c.1187G>A; p.G1396Asp | c.647G>A; p.G12156Iu | 65 | alive | 22 | yes (67) | no | unknown | unknown | unknown | |
| 35 | 1 | C | M | c.1187G>A; p.G1396Asp | c.1101del | 36 | alive | multiple | yes (36) | yes (43) | no | no | 3 adenomas | |
| 36 | 1 | C | F | c.536A>G; p.Y1790ys | c.1187G>A; p.G1396Asp | 43 | alive | 19 | yes (43) | yes (44) | no | no | none | |
| 36 | 2 | C | M | c.536A>G; p.Y1790ys | c.1187G>A; p.G1396Asp | 36 | alive | unknown | unknown | unknown | no | no | none | |
| 36 | 3 | C | F | c.536A>G; p.Y1790ys | c.1187G>A; p.G1396Asp | 36 | alive | unknown | unknown | unknown | no | no | none | |
| 36 | 4 | C | M | c.536A>G; p.Y1790ys | c.1187G>A; p.G1396Asp | 36 | CRC | unknown | yes | unknown | no | no | none | |
| 37 | 1 | C | F | c.1187G>A; p.G1396Asp | c.1187G>A; p.G1396Asp | 57 | alive | 10 | yes (57) | yes (64) | no | no | none | lipoma |
| 37 | 2 | C | M | c.1187G>A; p.G1396Asp | c.1187G>A; p.G1396Asp | 62 | CRC (62) | unknown | yes (62) | yes (62) | no | no | none | |
| 38 | 1 | C | F | c.1187G>A; p.G1396Asp | c.1187G>A; p.G1396Asp | 50 | alive | 123 | no | no | unknown | unknown | unknown | |
| 38 | 2 | C | F | c.1187G>A; p.G1396Asp | c.1187G>A; p.G1396Asp | 50 | CRC | unknown | unknown | unknown | no | no | none | |
| 38 | 3 | C | F | c.1187G>A; p.G1396Asp | c.1187G>A; p.G1396Asp | 38 | alive | unknown | yes | unknown | no | no | none | |
| 39 | 1 | C | M | c.536A>G; p.Y1790ys | c.1147delC; p.Ala389ProfsX25 | 53 | CRC (57) | 11-30 | yes (53) | no | unknown | unknown | unknown | |
| 40 | 1 | C | M | c.536A>G; p.Y1790ys | c.536A>G; p.Y1790ys | 50 | unknown (52) | 50 | yes (50) | unknown | unknown | unknown | unknown | |
| 41 | 1 | C | M | c.536A>G; p.Y1790ys | c.536A>G; p.Y1790ys | 33 | alive | 50-100 | no | no | no | no | few, one | |
| 42 | 1 | C | M | c.536A>G; p.Y1790ys | c.536A>G; p.Y1790ys | 30 | alive | multiple | yes (30) | yes (30) | >10 adenomas | no | adenoma | |
| 42 | 2 | C | M | c.536A>G; p.Y1790ys | c.536A>G; p.Y1790ys | 28 | alive | multiple | no | no | unknown | no | unknown | |
| 42 | 3 | C | M | c.536A>G; p.Y1790ys | c.536A>G; p.Y1790ys | 28 | alive | multiple | no | no | unknown | no | unknown | |
| 43 | 1 | C | M | c.536A>G; p.Y1790ys | c.1187G>A; p.G1396Asp | 49 | alive | multiple | no | no | unknown | no | unknown | |
| 43 | 2 | C | M | c.536A>G; p.Y1790ys | c.1187G>A; p.G1396Asp | 49 | alive | multiple | no | no | unknown | no | unknown | |
| 44 | 1 | C | M | c.536A>G; p.Y1790ys | Trp131Arg | 30 | alive | 152 | unknown | no | unknown | no | unknown | |
| 45 | 1 | C | M | c.536A>G; p.Y1790ys | c.933>3A>C | 46 | alive | 119 | yes (47) | no | unknown | unknown | unknown | skin cancer (45) |
| 46 | 1 | C | F | c.536A>G; p.Y1790ys | c.690 G>A; p.Gln230Gln | 47 | alive | 200 | yes (48) | yes (50) | no | no | none | |
| 47 | 1 | C | F | c.536A>G; p.Y1790ys | c.1187G>A; p.G1396Asp | 53 | alive | 15 | yes (53) | no | unknown | unknown | unknown | |
| 48 | 1 | C | M | c.536A>G; p.Y1790ys | c.690 G>A; p.Dln230Gln | 42 | alive | 120 | no | yes (43) | no | no | none | sebaceous gland adenoma (45), other benign tumors (47) |

Supplementary Table 1. (Continued)

| Patient no. | Index case no. | Center | Gender | Mutation 1 | Mutation 2 | Age at diagnosis | Cause and age at death | Maximal polyp number | Colorectal cancer (age) | Gastrointestinal (age) | No. and histology of duodenal polyps | No. and type of gastric polyps | Endocolonic tumor (age at diagnosis) |
|-------------|----------------|--------|--------|----------------------------|----------------------------|------------------|------------------------|----------------------|-------------------------|------------------------|--------------------------------------|--------------------------------|--------------------------------------|
| 50 | 1 | C | F | c.536A>G; p.Tyr179Cys | c.536A>G; p.Tyr179Cys | 31 | alive | 88 | yes (57) | no | unknown | unknown | unknown |
| 51 | 1 | C | F | c.536A>G; p.Tyr179Cys | c.536A>G; p.Tyr179Cys | 33 | alive | 13 | yes (60) | no | unknown | unknown | unknown |
| 52 | 1 | C | F | c.536A>G; p.Tyr179Cys | c.536A>G; p.Tyr179Cys | 48 | alive | multiple | yes (48) | yes (63) | no | unknown | carcinoid tumor (49) |
| 53 | 1 | C | M | c.1147delC; p.Val388PheX25 | c.1147delC; p.Val388PheX25 | 45 | alive | >100 | yes (45) | no | unknown | unknown | unknown |
| 53 | 2 | C | M | c.1147delC; p.Val388PheX25 | c.1147delC; p.Val388PheX25 | 51 | alive | 30-40 | yes (51) | no | unknown | unknown | unknown |
| 54 | 1 | C | F | c.1187G>A; p.Gly396Asp | Arg245His | 48 | alive | 22 | yes (41) | no | unknown | unknown | carcinoid tumor (42) |

B, Institute of Human Genetics, Bonn, Germany; C, Institute of Medical Genetics, Cardiff, UK; CRC, colorectal cancer; L, Centre for Human and Clinical Genetics, Leiden, The Netherlands; F, female; M, male. Age is in years.

Supplementary Table 2. Histology and Age at Diagnosis in the 38 *MUTYH*-Associated Polyposis Patients Affected by Extracolonic Cancer

| Patient no. | Cancer | Gender | Age (y) at diagnosis | Histology result | Origin |
|-------------|-------------|--------|----------------------|---|--------|
| 57249 | Esophagus | M | 59 | Barrett carcinoma | Dutch |
| 676 | Esophagus | M | 46 | Carcinoma in situ | German |
| 1293 | Stomach | F | 48 | Early cancer mucosal type | German |
| 548 | Stomach | M | 38 | Adenocarcinoma | German |
| 31 | Stomach | M | 17 | Gastric cancer | UK |
| 57246 | Duodenum | M | 65 | Adenocarcinoma | Dutch |
| 19221 | Duodenum | M | 56 | Adenocarcinoma | Dutch |
| 19049-3 | Bladder | M | 67 | Papillar urothelial carcinoma (grade I-II) | Dutch |
| 858 | Bladder | M | 62 | Urothelial carcinoma | German |
| 19049-1 | Bladder | M | 60 | Papillar urothelial carcinoma (grade II) | Dutch |
| 526 | Bladder | F | 45 | Squamous cell carcinoma | German |
| 10 | Skin | M | 59 | Melanoma | German |
| 885 | Skin | F | 32 | Melanoma | German |
| 19221 | Skin | M | 30 | Melanoma | Dutch |
| 561 | Skin | F | 68 | Spinalioma (spinous cell carcinoma) | German |
| 395 | Skin | M | 60 | Spinalioma (spinous cell carcinoma) | German |
| 52105 | Skin | M | 71 | Basalioma (basal cell carcinomas) | Dutch |
| 54245 | Skin | F | 63 | Basalioma (basal cell carcinoma) | Dutch |
| 858 | Skin | M | 62 | Basalioma (basal cell carcinoma) | German |
| 53276 | Skin | M | 58 | Basalioma (basal cell carcinoma) | Dutch |
| 1111 | Skin | M | 48 | Basalioma (basal cell carcinoma) | German |
| 45 | Skin | M | 45 | Basalioma (basal cell carcinoma) | UK |
| 57135 | Skin | F | 44 | Basalioma (basal cell carcinoma) | Dutch |
| 54186 | Skin | F | 41 | Basalioma (basal cell carcinoma) | Dutch |
| 787 | Breast | M | 56 | Breast cancer | German |
| 54245 | Breast | F | 76 | Intracystic papillary carcinoma | Dutch |
| | | | 78 | Ductal carcinoma (unilateral) | |
| 18 | Breast | F | 71 | Infiltrating ductal carcinoma (grade II) | UK |
| 561 | Breast | F | 60 | Intracystic papillary carcinoma | German |
| | | | 68 | Ductal carcinoma (unilateral) | |
| 52240 | Breast | F | 55 | Ductal carcinoma in situ | Dutch |
| 54140 | Breast | F | 50 | Breast cancer | Dutch |
| 1358 | Breast | F | 49 | Lobular differentiated with intratumoral DCIS | German |
| 54856 | Breast | F | 50 | Right: lobular carcinoma with an in situ component and a DCIS component; left: DCIS | Dutch |
| 1293 | Breast | F | 45 | Invasive ductal cancer | German |
| 489 | Ovary | F | 56 | Ovarian carcinoma | German |
| 1412 | Ovary | F | 45 | Mucinous cystadenocarcinoma | German |
| 2 | Ovary | F | ? | Ovarian carcinoma | UK |
| 1323 | Endometrium | F | 54 | Adenocarcinoma | German |
| 1412 | Endometrium | F | 47 | Endometrium carcinoma | German |

DCIS, ductal carcinoma in situ; F, female; M, male.