



Universiteit
Leiden
The Netherlands

Regulation and modulation of growth : insights from human and animal studies

Gool, S.A.van

Citation

Gool, S. Avan. (2011, May 18). *Regulation and modulation of growth : insights from human and animal studies*. Retrieved from <https://hdl.handle.net/1887/17645>

Version: Corrected Publisher's Version

License: [Licence agreement concerning inclusion of doctoral thesis in the Institutional Repository of the University of Leiden](#)

Downloaded from: <https://hdl.handle.net/1887/17645>

Note: To cite this publication please use the final published version (if applicable).



Chapter 5

Impaired body weight and tail length gain and altered bone quality after treatment with the aromatase inhibitor exemestane in male rats

S.A. van Gool¹, J.M. Wit¹, T. de Schutter², N. de Clerck², A.A. Postnov², S. Kremer Hovinga¹, J. van Doorn³, S.J. Veiga⁴, L.M. Garcia-Segura⁴, M. Karperien⁵

¹Department of Pediatrics, Leiden University Medical Center, Leiden, the Netherlands.

²Department of Biomedical Sciences and Department of Physics, University of Antwerp, Antwerp, Belgium.

³Department of Metabolic and Endocrine Diseases, University Medical Center Utrecht, Utrecht, the Netherlands.

⁴Instituto Cajal, Consejo Superior de Investigaciones Científicas, Madrid, Spain.

⁵Department of Tissue Regeneration, Biomedical Technology Institute, Twente University, the Netherlands.

Abstract

Background: Estrogen deficiency induced by aromatase inhibitors may be a novel treatment modality for growth enhancement in short children, but may have adverse effects on bone, brain and reproduction.

Aim: To assess growth effects and potential adverse effects of aromatase inhibition in male rats.

Methods: 26 days old prepubertal rats received intramuscular injections with placebo (PLC) or the aromatase inhibitor exemestane at a dose of 10, 30 or 100 mg/kg/week [E10, E30, E100(6)] for 6 weeks completely covering the sexual maturation phase, or with 3 weeks E100 followed by 3 weeks PLC [E100(3)]. Growth parameters and histology of the testis, seminal vesicle and brain were analyzed. Bone architecture was studied with X-ray microtomography.

Results: Exemestane dose-dependently decreased body weight and tail length gain, and liver and seminal vesicle weights, but did not affect nose-anus length gain, growth plate width or radial growth. E100(6) decreased trabecular thickness (epiphysis and metaphysis) and number (metaphysis). Normal IGF-I levels and brain, testis and seminal vesicle morphology were observed. E100(3) resulted in decreased tail length gain only.

Conclusion: Exemestane treatment during sexual maturation did not augment linear growth in male rats, but caused impaired body weight and tail length gain and osteopenia.

Introduction

The phenotypes of estrogen resistance (1) and estrogen deficiency (1-4) are characterized by a lacking pubertal growth spurt, ongoing growth into adulthood and tall stature, demonstrating the crucial role of estrogens in skeletal growth and maturation in both genders (5-8). These clinical observations have led to the hypothesis that estrogen deficiency pharmaceutically induced by aromatase inhibitors may be a novel treatment modality for growth enhancement in children with idiopathic short stature (9;10).

Our limited knowledge on the effects of aromatase inhibition on growth in boys is derived from one clinical trial in patients with idiopathic short stature (ISS) (11) and two trials in boys with constitutional delay of growth and puberty (CDGP) (12;13). Treatment with the nonsteroidal aromatase inhibitor letrozole (either or not combined with testosterone) resulted in an increased predicted adult height and near-final height, without apparent detrimental effects on bone mineralization (11-14). In growth hormone-deficient (GHD) patients treated with growth hormone (GH), co-treatment with the nonsteroidal aromatase inhibitor anastrozole led to an increased predicted adult height, but adult height results have not yet been published (15).

The ubiquitous expression of aromatase in humans underscores the importance of locally produced estrogens (16) and implies that aromatase inhibition may have adverse effects as well. Male patients with congenital estrogen deficiency have been found to suffer from osteoporosis in adulthood (5). Since aromatase has an established neuroprotective function both under physiological and pathological conditions, aromatase inhibition may result in unwanted side-effects on the brain and, as a result, on behavior (17). Finally, estrogen deficiency may result in disorders of the reproductive system.

In this study, the effects of treatment with the steroidal, irreversible aromatase inhibitor exemestane (E) were analyzed in male rats during the phase of sexual maturation in order to test the hypothesis that aromatase inhibitors can increase growth and to evaluate potential side-effects. To mimic the potential treatment strategy in boys with ISS, exemestane treatment was initiated 4 days before the start of sexual maturation and lasted 6 weeks. This treatment regime covered the whole period of sexual maturation in rats

We applied exemestane instead of other aromatase inhibitors. An important advantage of exemestane is that it is available as a slow release preparation that can be administered once a week, in contrast to other inhibitors that require daily dosing. Exemestane completely abolishes estrogen biosynthesis by irreversibly blocking aromatase, which can only be overcome by *de novo* aromatase synthesis. The continuous slow release of exemestane from the injected depot ensures that *de novo* aromatase synthesis is counteracted. In addition, exemestane may exert

androgenic effects on bone that may prevent the loss of bone mineral density (BMD) resulting from estrogen deficiency. We have previously established that exemestane effectively inhibited aromatase activity in female rats, resulting in a marginal growth increase, polycystic ovaries and a decreased bone quality (Van Gool *et al.*, *Horm Res*, in press). The present study is the first detailed analysis of the impact and side effects of aromatase inhibition on growth in male rats.

Experimental design

Animals

Weight-matched male Wistar rats (n=30), 26 days old and sexually immature, were purchased from Harlan. Animals were kept in a light and temperature controlled room (12 hours light, 20-22°C) with water and food (Hope Farms) ad libitum and a maximum of 3 animals per cage. Rats enter sexual maturation at day 30 and the whole process is completed in 6 weeks. Experiments were approved by the Committee for the ethical care and use of laboratory animals of the Leiden University.

Five groups of 6 rats were treated with placebo (PLC) or with the slow-release preparation exemestane (E) at three different doses: 10, 30 or 100 mg/kg body weight/week (coded as E10, E30, E100, respectively). E100(6) was treated for 6 weeks with E100, covering the complete period in which young male rats usually exhibit fast growth. E100(3) received E100 for 3 weeks, followed by 3 weeks of placebo. This treatment regimen covers only the first half of the period of sexual maturation in male rats. The two groups were included in order to determine whether short- or long-term aromatase inhibition would have the most profound effect on growth. Exemestane (Aromasin[®], provided by Pfizer) was administered once per week by intramuscular injections in alternated hind paws.

Nose-anus length, tail length and body weight were measured weekly. At the end of the experimental period, animals were anaesthetized by intraperitoneal Nembutal injection and blood samples were collected by cardiac puncture. Serum was separated for insulin-like growth factor I (IGF-I) measurements. Femora were collected for X-ray microtomography (micro-CT). Subsequent *in vivo* fixation was performed by transcardiac perfusion with 4% paraformaldehyde and 0.2% glutaraldehyde in 0.1 M phosphate buffer with 75 mM lysine monohydrochloride and 10 mM Na-periodate. After fixation, rats were decapitated, and brains were stored in the same fixative for at least 12 weeks. Tibiae of the right hind legs were measured, postfixed for 24 hours, decalcified in 12.5 % EDTA, pH 7.4 for 4 weeks, cut in

halves in a sagittal orientation and processed for paraffin embedding. Testis and seminal vesicle were weighed and processed for paraffin embedding.

Growth plate histomorphometry

Paraffin sections (5 μm) perpendicular to the growth plate axis were mounted on APES/glutaraldehyde-coated slides, deparaffinized in Paraclear[®] and graded ethanols, stained with Hematoxylin/Eosin and mounted in Histomount (National Diagnostics). A Nikon DXM 1200 digital camera was used for photographing the proximal tibial growth plate. Widths of the total growth plate, proliferative zone and hypertrophic zone were measured in ImagePro Plus[®].

X-ray microtomography (micro-CT)

To examine the effects of exemestane treatment on whole bone parameters and on trabecular bone in particular, right femora of PLC, E100(3) and E100(6) were analyzed by high resolution X-ray microtomography. Micro-CT has been shown to be well suited for the non-destructive visualization and quantitative analysis of bone and calcified tissue (18;19).

a. 'Whole bone' parameters

Isolated whole femora were scanned with a high resolution desktop micro-CT scanner ((7); Skyscan 1076). In this X-ray micro-CT system, both the X-ray source (focal spot size 5 μm , energy range 40-100 keV) and the detector (CCD camera 2.3kx4k) rotate around the bone. Scans were isotropic and a voxel size of 35 \times 35 \times 35 μm was chosen with 1.0 mm A1 filter. Virtual cross-sections were reconstructed by Feldkamp cone beam algorithm (20). Further technical details about the scanner have been published elsewhere (21).

The same threshold and reconstruction parameters were used for the reconstruction of all cross-sections. Frequency distribution of the grey levels was analyzed. 3D models were created using Skyscan software packages ANT and CT Analyzer. From the virtual cross-sections the volumes taken by bone as well as the anatomical volume (Archimedean volume) were calculated. Distinction between bone and other tissues was based on thresholding of the grey values in the reconstruction. Analysis of the grey values according to previously reported calculations (35) resulted in a relative value for total calcium and overall calcium density. Details of these calculations have been reported previously (18). In addition, the length of the femora was measured.

b. Trabecular bone

For analysis of the trabecular bone, the distal end of the femur was scanned, but for this purpose at a higher resolution than required for the 'whole bone' scans. Therefore, an *in vitro* desktop micro-CT system (Skyscan 1072) with a rotating stage was used (22). Polychromatic X-rays with peak energy of 80 kV were generated by a microfocus X-ray source with a focal spot size of 8 microns. A (1024×1024) 12 bit CCD camera was used as detector. The rotation step was 0.9°, acquisition time 6 s/projection, and total acquisition time about 2 hours. Scanning was isotropic with a voxel size of 13.28 μm^3 .

The growth plate was chosen as a reference for selecting comparable and reproducible regions of interest for analysis of trabecular number, trabecular thickness, bone volume and distribution of trabecular thickness. Two different regions of the femur were analyzed: the metaphysis (primary ossification center) and the epiphysis (secondary ossification center). For analysis of the primary ossification center at the proximal side of the growth plate, a transverse reference slice of the growth plate was selected and used to reconstruct a cylinder with fixed dimensions as from 50 slices above the reference slice. The base of the cylinder was a circle and the height was 150 slices.

Gonadal histology

Midsagittal sections of the testis and seminal vesicle (5 μm) were stained with Haematoxylin/Eosin. A minimum of three sections was analyzed per organ.

Brain histology

Brains were rinsed with PBS, cut in coronal sections (30 μm) in a Vibratome and Nissl-stained with toluidine blue for morphometric analysis. Immunohistochemical staining of astrocytes (anti-GFAP, Glial Fibrillary Acidic Protein, DAKO, dilution 1:1000), microglia (OX-42, Serotec, dilution 1:300) and reactive astrocytes (anti-vimentin, clone V9, DAKO, dilution 1:500) was performed. For morphometric analysis of GFAP immunoreactive astroglia, quantitative evaluation of the surface density of GFAP immunoreactive cell bodies and cell processes in the hippocampus was performed using a stereological grid, according to the point-counting method of Weibel (23). A minimum of two slides was evaluated per animal.

Insulin-like Growth Factor I (IGF-I) assay

Total serum IGF-I levels were measured by specific radioimmunoassay (RIA) after acid Sep-Pak C18 (Waters Associates) extraction of 250 µl aliquots, as described previously (24).

Statistical analysis

The study was designed to analyze the effect of exemestane on growth and to assess potential adverse effects on bone, brain and organ development. Comparisons between treatment and control groups were made using one-way analysis of variance (ANOVA). Results are expressed as mean and SD. The significance level was set at 0.05.

Results

Effects on growth and organs

At baseline, there were no significant differences between groups in growth parameters. Body weight gain, nose-anus and tail length gain, tibia length, growth plate characteristics, and IGF-I levels are summarized in table 1. The effects of exemestane on organ weights are summarized in table 2. Figure 1 shows body weight, nose-anus length, and tail length gain for all groups.

Previous experiments in female rats demonstrated that 3 weeks treatment with E100 effectively inhibited aromatase activity, using ovarian development as a bioassay. Treatment with E100 induced polycystic polycystic ovarian syndrome-like features generally known to be due to estrogen-deficiency (chapter 4). In male rats, exemestane treatment did not influence nose-anus length gain. When compared to PLC, the animals that received exemestane showed decreased gains of tail length and body weight in a dose-dependent manner, with E10 having a modest and E100(6) the most pronounced effect. At termination of the experimental period, body weight gain of E100(3) was similar as that of PLC. Exemestane treatment did not affect the lengths of tibia and femur, growth plate width or serum IGF-I levels.

Both E100(3) and E100(6) caused a dose-dependent decrease of the liver/total body weight (TBW) ratio compared to PLC. A normal aspect of the livers was found during macroscopic evaluation. Only E100(6) resulted in a significantly reduced seminal vesicle/TBW ratio, but no apparent morphometrical anomalies were found in the testes or seminal vesicle as revealed by histological examination (data not shown).

Effects on bone

a. 'Whole bone' parameters

No differences were found in femur length, anatomical volume, bone volume, total calcium and calcium density between the groups (data not shown).

Table 1. Effect of aromatase inhibition on growth parameters and epiphyseal morphology

Parameter	PLC	E10	E30	E100(6)	E100(3)
Tail length gain (cm)	12.1 (0.9)	11.1 (0.2)**	10.7 (0.5)***	10.8 (0.5)***	10.9 (0.3)**
Nose-anus length gain (cm)	9.7 (1.1)	9.7 (0.7)	9.6 (0.4)	9.2 (0.5)	9.7 (0.5)
Body weight gain (g)	280.5 (17.9)	268.1 (5.8)	247.9 (14.6)**	236.5 (18.0)***	268.8 (19.1)
Tibia length (mm)	38.3 (0.9)	38.2 (0.3)	37.9 (0.5)	37.8 (0.7)	37.9 (0.7)
Femur length (mm)	33.2 (0.4)	ND	ND	32.9 (0.3)	33.6 (0.4)
Growth plate width (mm)	0.32 (0.02)	ND	ND	0.29 (0.03)	0.33 (0.02)^
proliferative zone (mm)	0.18 (0.00)	ND	ND	0.16 (0.02)#	0.19 (0.01)§
hypertrophic zone (mm)	0.14 (0.02)	ND	ND	0.13 (0.02)	0.14 (0.01)
P/H-ratio	1.29 (0.14)	ND	ND	1.23 (0.13)	1.33 (0.10)
Serum IGF-I (ng/ml)	1.5 (0.1)	1.3 (0.3)	1.4 (0.2)	1.5 (0.6)	1.1 (0.1)# §

Means (SD). ND, not determined; P/H-ratio, ratio between proliferative zone and hypertrophic zone. **p<0.01; ***p<0.001; #p<0.1 (compared to PLC). E100(3) versus E100(6): ^p<0.05; §p<0.1.

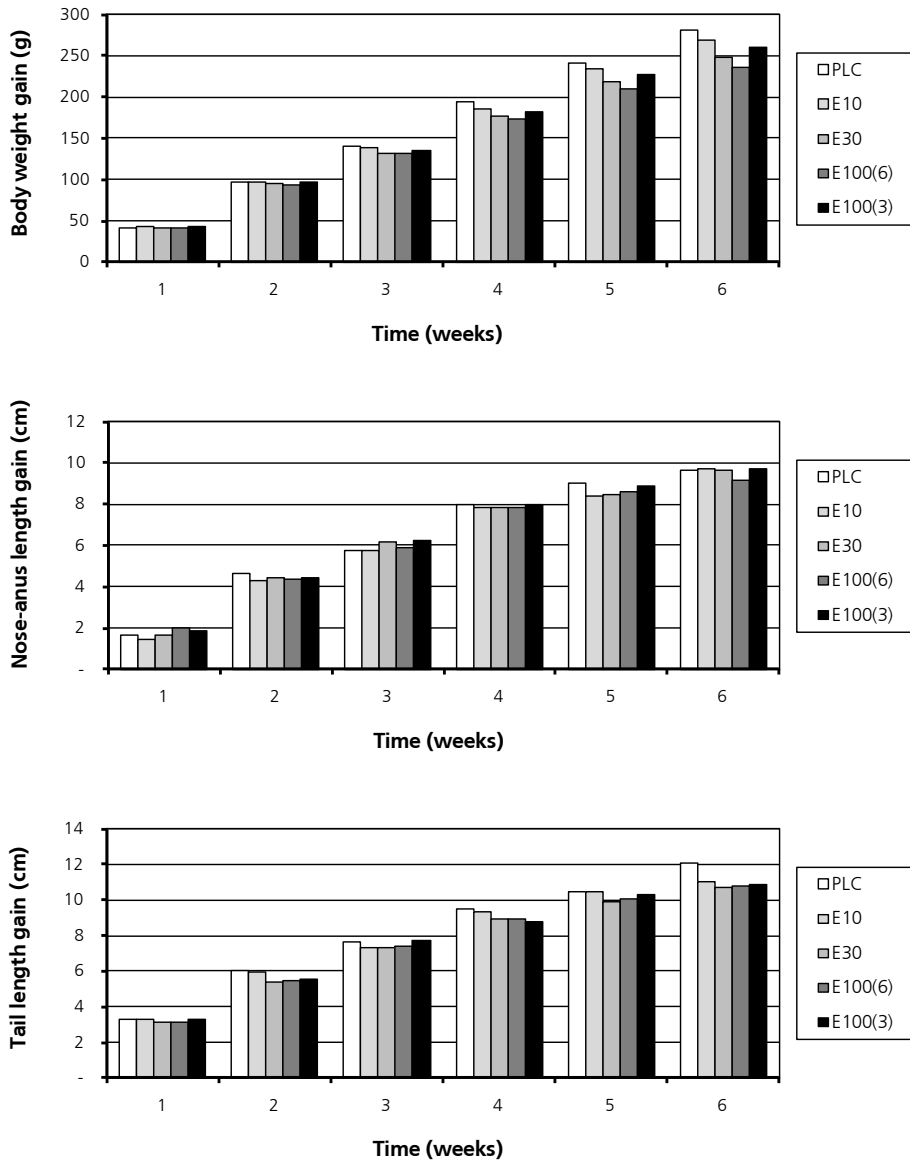
Table 2. Effect of aromatase inhibition on organ weights

Parameter	PLC	E10	E30	E100(6)	E100(3)
liver	48.2 (6.5)	41.7 (2.6)#	41.5 (7.4)#	38.8 (6.1)*	37.8 (6.2)**
thymus	1.5 (0.2)	1.8 (0.3)#	1.6 (0.4)	1.4 (0.2)	1.7 (0.2)§
kidney	4.0 (0.2)	3.6 (0.7)	4.0 (0.3)	3.8 (0.3)*	3.5 (0.6)
testis	4.0 (0.9)	4.5 (0.1)	4.5 (0.2)#	3.7 (0.6)	4.1 (0.4)
seminal vesicle	2.4 (0.4)	2.4 (0.3)	2.2 (0.2)	1.6 (0.2)***	2.4 (0.3)^^

Organ weights as permillage of total body weight. Means (SD). *p<0.05; **p<0.01; ***p<0.001; #p<0.1 (compared to PLC). E100(3) versus E100(6): ^^p<0.001; §p<0.1.

Figure 1

Growth parameters (A) body weight gain, (B) nose-anus length gain, (C) tail length gain.



b. Trabecular bone analysis

E100(6) caused a decline in trabecular thickness in the epiphysis and metaphysis (table 3). In the metaphysis, the number of trabeculae was also decreased. The percentage of small trabeculae was increased after three or six weeks of E100 treatment in both the epiphysis and metaphysis (<5.0 pixel and <7.0 pixel, respectively; figure 2). E100(3) exhibited a normal trabecular number, and a trabecular bone volume intermediate between those of PLC and E100(6) animals.

Brain histology

Gliosis, a hallmark sign of neurodegeneration, was not found in E100(6). The surface area of GFAP immunoreactive astrocytes was not different between groups and reactive astrocytes or reactive microglia were not detected. There was no qualitative evidence of neuronal loss or degeneration (data not shown) caused by exemestane treatment.

Table 3. Trabecular bone analysis

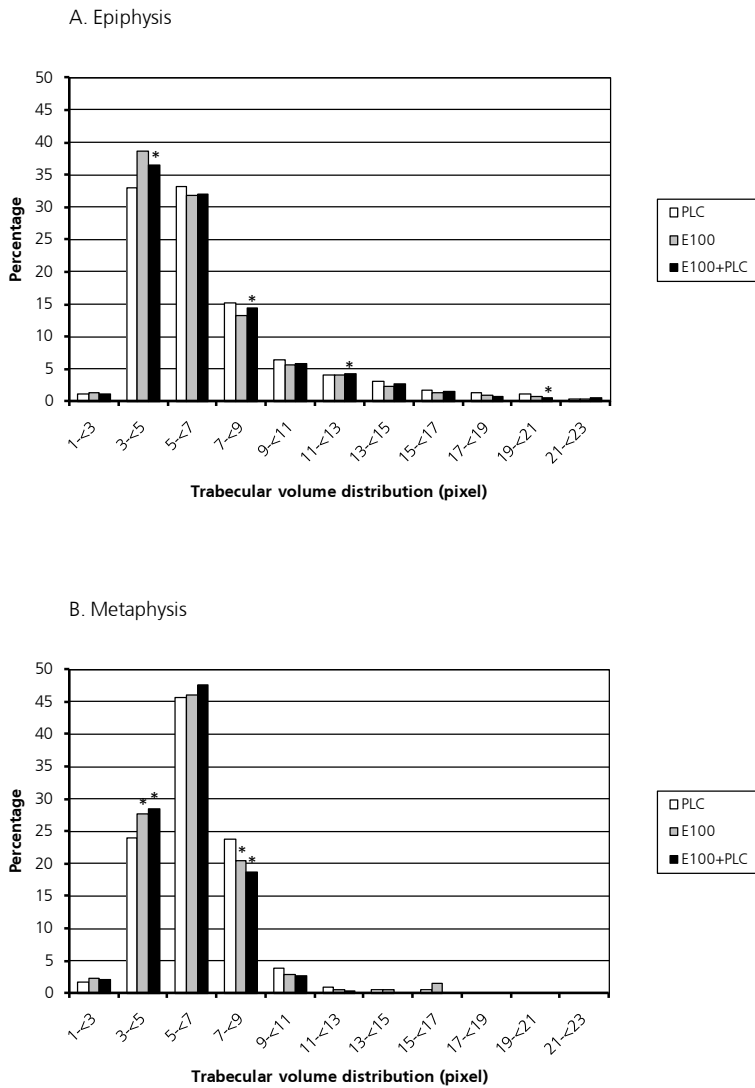
Parameter		PLC	E100(6)	E100(3)
Epiphysis				
Trabecular bone volume	mm ³	48.4 (4.8)	41.0 (3.5) [*]	43.9 (2.3)
Trabecular thickness	μm	189.1 (9.1)	178.3 (4.0) [*]	182.1 (5.0)
Trabecular number	1/mm	1.6 (0.3)	1.6 (0.3)	1.7 (0.2)
Metaphysis				
Trabecular bone volume	mm ³	1.8 (0.2)	1.4 (0.2) [*]	1.8 (0.3) [^]
Trabecular thickness	μm	84.9 (3.1)	81.9 (2.9)	80.6 (3.0) [*]
Trabecular number	1/mm	2.6 (0.2)	2.1 (0.2) [*]	2.6 (0.3)

Volume of objects is the volume taken by bone tissue in the selected region of interest. Means (SD);

^{*} p<0.05 as compared to PLC; [^] p<0.05 E100(3) versus E100(6).

Figure 2

(A) Normalized trabecular volume distribution in the secondary ossification center (epiphysis). Only the volume taken by bone tissue in the epiphysis is taken into account. Notice the increase of trabeculae <5.0 pixels (pixel size= 27.64 μm) in E100(3) and E100(6). (B) Normalized trabecular volume distribution in the primary ossification center (metaphysis). Only the volume taken by bone tissue in the selected cylinder is taken into account. Notice the increase in trabeculae <7.0 pixels in E100(3) and E100(6) (pixel size= 13.82 μm). *p <0.05.



Discussion

The aims of this study were to analyze the effect of aromatase inhibition on growth parameters during the phase of sexual maturation in male rats and to assess potential side-effects of this treatment on organ weight development, bone, and brain morphology. The main conclusion from this study is that exemestane treatment decreased tail length and body weight gain, but also caused alterations in bone architecture that usually occur in early stage osteopenia.

Human growth is characterized by an evident pubertal growth spurt and growth plate fusion at the end of puberty. The clinical phenotype of estrogen-resistant or -deficient patients illustrates that these characteristic features are mediated by the exclusive action of estrogen (25). In contrast, the adult length of estrogen receptor knockout mice is normal, demonstrating a clear difference in hormonal regulation of growth between humans and mice (26-30). For this study, the rat was chosen as an animal model. Although rats do not show a clear growth spurt and lack epiphyseal fusion, their response to estrogen is similar as in humans, with estrogen deficiency stimulating growth and estrogen treatment causing growth arrest (31). We therefore feel that the rat is the most valid of all available animal models for *in vivo* studies on the impact of chemically induced aromatase deficiency.

Serological determination of estradiol levels would have contributed to the interpretation of the effects of exemestane on growth. However, estradiol levels in male rats are very low, and expected to be even lower during treatment with an aromatase inhibitor. The available estradiol assays have been developed for analyzing human serum and are not sufficiently sensitive for quantification of such low levels of estradiol (32). Exemestane treatment further complicates estradiol detection, because the compound and its metabolites interfere with the available assays (33). To our knowledge, there is currently no laboratory experienced with estradiol serological measurements in exemestane-treated rats.

As an alternative to serological evidence, we have demonstrated the effectiveness of exemestane to inhibit aromatase activity in a previous study in female rats (chapter 4) which normally have high serum levels of estrogen during the sexual maturation phase. In this model we used ovarian development as a bioassay for aromatase inhibition. Exemestane at a dose of 100 mg/kg/week resulted in a pronounced decrease of ovarian weight and histological evidence of anovulation and polycystic ovarian syndrome-like features commonly seen in estrogen deficiency. The effects on ovarian development were comparable to ovariectomy letting us conclude that E100 resulted in a near complete inhibition of the aromatization of androgens. Since estrogen biosynthesis is significantly lower in male than in female rats, exemestane is expected to inhibit aromatase activity even more effectively in males.

In contrast with our hypothesis, exemestane treatment did not result in increased linear growth. Instead, although the decreases in nose-anus length gain and appendicular growth did not reach statistical significance, a smaller increment in body weight and tail length gain was found in exemestane-treated rats compared with PLC. Our results are in line with previous reports. Treatment of 6 weeks old male rats with the nonsteroidal aromatase inhibitor vorozole resulted in a decreased body weight gain and bone mineral density (BMD) but had no effect on femoral length (34). Four weeks old male rats treated with the selective estrogen receptor modulator (SERM) tamoxifen led to a declined body weight, nose-anus length, tibial and femoral length, and trabecular BMD (35). Similarly, the growth phenotype of male aromatase knockout (ArKO) mice and estrogen receptor alpha (ER α) and ER $\alpha\beta$ knockout mice are characterized by a lower body weight and retarded axial and radial growth (29;30;36). In contrast with our results and the other animal models of estrogen deficiency or resistance, peripubertal letrozole-treated mice were found to display increased growth (37), which may be attributed to species differences and differences between the aromatase inhibitors employed.

Exemestane has a very low binding affinity for the androgen receptor *in vitro* (0.22%) and a marginal androgenic activity *in vivo* as demonstrated in castrated male rats (1% of the activity of testosterone propionate) (38). It is unlikely that such marginal effects may explain the growth inhibition observed. The serum levels of IGF-I were normal during exemestane treatment, suggesting that the observed effects on growth were not mediated systemically through the GH/IGF-I axis. This observation is in line with the normal IGF-I level reported in a male aromatase-deficient patient (2).

The effects of exemestane treatment appeared to be dose-dependent, E100(6) having the most pronounced impact on growth. E100(3) rats showed a growth phenotype intermediate between those of E100(6) and PLC animals. This could mean that the treatment period of 3 weeks was too short to cause significant effects on growth or that potential exemestane-induced changes already had been undone during the 3 weeks follow-up phase without treatment. Likewise, Karimian *et al.* described a complete catch-up growth of body weight when the rats were allowed to recover after cessation of tamoxifen treatment, whereas the femora and tibia remained shorter than in untreated controls (35). The smaller body weight increment of exemestane-treated rats compared to PLC in our study is consistent with findings in male rats treated with other aromatase inhibitors or with Tamoxifen (34;35;39). A lower food intake or a decreased visceral fat mass have been suggested as possible explanations for the lower weight gain in those studies, but these aspects were not analyzed in our study.

Analysis of the trabecular bone of E100(6) rats demonstrated a significant loss of bone tissue that is generally considered as an early stage of osteoporosis. Impaired skeletal development

and a decreased bone mineral density were also reported in male letrozole-treated rats (34;40) and in tamoxifen-treated rats (35). Similarly, male patients with P-450 aromatase deficiency or estrogen receptor mutations have a low bone mass, probably because they do not achieve a normal peak bone mass during childhood. Moreover, Coleman *et al.* reported on the skeletal effects of exemestane treatment in bone quality in postmenopausal women with a status after complete resection of unilateral breast carcinoma, who were disease-free after 2-3 years of tamoxifen treatment and who were randomly assigned to continue tamoxifen treatment or to receive additional exemestane treatment to complete a total of 5 years of adjuvant endocrine treatment. Two years of exemestane treatment was found to result in a 4% lower lumbar spine BMD and higher levels of bone turnover markers (41). It is unknown whether the observed osteoporotic changes in our study would render the mature skeleton vulnerable to osteoporotic fractures later in life, or whether these changes are reversible.

Impaired liver function has been described in aromatase-deficient males (25), with a wide range of symptoms including variable degrees of impaired glucose tolerance, hyperinsulinemia, dyslipidemia and nonalcoholic hepatosteatosis. Those symptoms can be reversed by estradiol treatment (42;43). In our study, estrogen deprivation by exemestane treatment resulted in a dose-dependent decrease of the liver/TBW ratio, which confirms literature reports showing that the liver is a target organ for estrogen signaling (44;45). This effect seems to be rather persistent since in the E100(3) rats the liver/TBW ratio did not normalize, but 3 weeks may have been too short to allow for a complete recovery of liver weight. Karimian *et al.* also reported a reduced liver weight, without signs of hepatotoxicity in tamoxifen-treated rats (35). The physiological consequences of liver weight reduction in exemestane-treated rats remain unknown, as liver function was not assessed in this study.

Exemestane caused a dose-dependent decrease of the seminal vesicle/TBW ratio, but had no effect on the testis/TBW ratio. E100(3) did not influence seminal vesicle weights. ER α and ER β expression and aromatase activity have been demonstrated in the reproductive tract of the male rat, implying that estrogen bioactivity is regulated, at least in part, locally (46;47). Our results are not compatible with the increased testis/TBW ratio and normal to increased seminal vesicle/TBW ratio described in adult male anastrozole-treated rats (44). Differences in age of the animals, type and pharmacokinetic properties of the applied aromatase inhibitor, and route of administration may explain the discrepancies. Our results are also in contrast with the normal reproductive tract in male ER β knockout mice (48) and in aromatase knockout (ArKO) mice (49). There may be species differences in dependency of the reproductive tract on estrogen. The reproductive function was not analyzed in this study and therefore, the consequence of a reduced seminal vesicle weight remains unclear.

Male patients with aromatase deficiency show a variable degree of decreased fertility (25). Testis biopsies of an aromatase-deficient patient have revealed a normal aspect of testicular morphology, with signs of impaired spermatogenesis (43). Semen analysis in another aromatase-deficient patient also identified mild impairment of spermatogenesis (42), which may explain subfertility in these patients. In our rats, a normal testicular morphology was found, but semen analysis was not performed and reproductive disorders based on abnormal spermatogenesis cannot be excluded. Whether discontinuation of treatment reverses such abnormalities remains uncertain. Estrogen replacement in an aromatase-deficient patient did not result in normalization of spermatogenesis (42). Since obesity was very prominent in this patient both before and during estrogen replacement (BMI 29.3 and 32.0, respectively), reproductive disorders may also be secondary to overweight.

Aromatase expression plays an important role in the mammalian nervous system in neural differentiation and plasticity, neuroendocrine functions and sexual behavior (17). It was found to be upregulated and neuroprotective after a neurotoxic or mechanical lesion in the rat and mouse brain (50-52). In our study, no signs of neurodegeneration were observed in the hippocampus, a brain area that is sensitive to estradiol levels throughout the brain (53). This is in agreement with the normal hippocampal morphology in young, adult ArKO mice. We cannot exclude that aromatase inhibition may affect brain nuclei that develop during sexual maturation (e.g. the medial amygdala) (54). Moreover, aromatase inhibitor-treated rats may be more susceptible to neurodegeneration, as was reported for adult ArKO mice (55). Those mice also showed aberrant sexual behavior, which could be reversed by estrogen supplementation (56). In our study, sexual behavior was not studied.

The results of our study contrast with the increased predicted adult height after aromatase inhibitor treatment of boys with ISS, CDGP or GHD (11;13;15). Moreover, male patients with aromatase deficiency or estrogen resistance show a growth phenotype characterized by absence of a pubertal growth spurt, ongoing growth into adulthood, and absence of epiphyseal fusion, resulting in tall stature (25). Presumably, there are marked species differences in the influence of estrogens on longitudinal growth regulation.

The effects of aromatase inhibition by exemestane in the male rats in this study are distinctly different from those observed previously in female rats. The phenotype of the female exemestane-treated rats mimicked the clinical phenotype of aromatase-deficient female patients characterized by augmented growth. In contrast, the male rats in this study showed growth stagnation, whereas male aromatase-deficient patients exhibit a tall adult stature. Although the experimental designs applied in both studies were not completely identical, the distinct discrepancies allow us to conclude that marked gender differences in growth response to aromatase inhibition occur. The osteoporotic changes observed in both male and female rats

demonstrate that estrogen is important in the maintenance of bone quality in both genders. We conclude that six weeks of aromatase inhibition by the steroidal aromatase inhibitor exemestane in male rats causes retardation of tail growth and body weight gain, but has no significant effect on nose-anus length gain or appendicular growth. The adverse effect of treatment on bone quality was prominent, but long-term consequences for bone health and fracture risk remain unclear. The contrasting growth phenotypes of male exemestane-treated rats and human patients with estrogen deficiency or resistance indicate that a species difference in the role of estrogen signaling in growth regulation exists. Therefore, extrapolation of our results to clinical practice does not seem justified.

Acknowledgements

The authors thank Ivo Que for supervising experimental animal procedures, Cok Hoogerbrugge for facilitating IGF-I radioimmunoassays, and prof. Dr. Anton Grootegoed and Mrs. Marja Ooms for sharing their expert opinion on gonadal histology with us. Pfizer (New York, USA) is gratefully acknowledged for Aromasin® supply and unrestricted financial support of the study. ZonMW, the Netherlands Organization for Health Research and Development, provided a grant to S.A. van Gool (grant number: 920-03-392).

Reference List

- 1 Smith EP, Boyd J, Frank GR, Takahashi H, Cohen RM, Specker B, Williams TC, Lubahn DB, Korach KS: Estrogen resistance caused by a mutation in the estrogen-receptor gene in a man. *N Engl J Med* 20-10-1994;331:1056-1061.
- 2 Morishima A, Grumbach MM, Simpson ER, Fisher C, Qin K: Aromatase deficiency in male and female siblings caused by a novel mutation and the physiological role of estrogens. *J Clin Endocrinol Metab* 1995;80:3689-3698.
- 3 Carani C, Qin K, Simoni M, Faustini-Fustini M, Serpente S, Boyd J, Korach KS, Simpson ER: Effect of testosterone and estradiol in a man with aromatase deficiency. *N Engl J Med* 10-7-1997;337:91-95.
- 4 Herrmann BL, Saller B, Janssen OE, Gocke P, Bockisch A, Sperling H, Mann K, Broecker M: Impact of estrogen replacement therapy in a male with congenital aromatase deficiency caused by a novel mutation in the CYP19 gene. *J Clin Endocrinol Metab* 2002;87:5476-5484.
- 5 Grumbach MM: Estrogen, bone, growth and sex: a sea change in conventional wisdom. *J Pediatr Endocrinol Metab* 2000;13 Suppl 6:1439-1455.
- 6 Juul A: The effects of oestrogens on linear bone growth. *Hum Reprod Update* 2001;7:303-313.
- 7 Cutler GB, Jr.: The role of estrogen in bone growth and maturation during childhood and adolescence. *J Steroid Biochem Mol Biol* 1997;61:141-144.
- 8 Van der Eerden BC, Karperien M, Wit JM: The estrogen receptor in the growth plate: implications for pubertal growth. *J Pediatr Endocrinol Metab* 2001;14 Suppl 6:1527-1533.
- 9 Shulman DI, Francis GL, Palmert MR, Eugster EA: Use of aromatase inhibitors in children and adolescents with disorders of growth and adolescent development. *Pediatrics* 2008;121:e975-e983.
- 10 Dunkel L: Use of aromatase inhibitors to increase final height. *Mol Cell Endocrinol* 25-7-2006;254-255:207-216.
- 11 Hero M, Makitie O, Kroger H, Nousiainen E, Toiviainen-Salo S, Dunkel L: Impact of aromatase inhibitor therapy on bone turnover, cortical bone growth and vertebral morphology in pre- and peripubertal boys with idiopathic short stature. *Horm Res* 2009;71:290-297.

- 12 Wickman S, Sipila I, Ankarberg-Lindgren C, Norjavaara E, Dunkel L: A specific aromatase inhibitor and potential increase in adult height in boys with delayed puberty: a randomised controlled trial. *Lancet* 2001;357:1743-1748.
- 13 Hero M, Wickman S, Dunkel L: Treatment with the aromatase inhibitor letrozole during adolescence increases near-final height in boys with constitutional delay of puberty. *Clin Endocrinol (Oxf)* 2006;64:510-513.
- 14 Wickman S, Kajantie E, Dunkel L: Effects of suppression of estrogen action by the p450 aromatase inhibitor letrozole on bone mineral density and bone turnover in pubertal boys. *J Clin Endocrinol Metab* 2003;88:3785-3793.
- 15 Mauras N, Gonzalez de PL, Hsiang HY, Desrosiers P, Rapaport R, Schwartz ID, Klein KO, Singh RJ, Miyamoto A, Bishop K: Anastrozole increases predicted adult height of short adolescent males treated with growth hormone: a randomized, placebo-controlled, multicenter trial for one to three years. *J Clin Endocrinol Metab* 2008;93:823-831.
- 16 Simpson ER, Mahendroo MS, Means GD, Kilgore MW, Hinshelwood MM, Graham-Lorence S, Amarneh B, Ito Y, Fisher CR, Michael MD: Aromatase cytochrome P450, the enzyme responsible for estrogen biosynthesis. *Endocr Rev* 1994;15:342-355.
- 17 Garcia-Segura LM: Aromatase in the brain: not just for reproduction anymore. *J Neuroendocrinol* 2008;20:705-712.
- 18 Postnov AA, Vinogradov AV, Van Dyck D, Saveliev SV, De Clerck NM: Quantitative analysis of bone mineral content by x-ray microtomography. *Physiol Meas* 2003;24:165-178.
- 19 Waarsing JH, Day JS, van der Linden JC, Ederveen AG, Spanjers C, De Clerck N, Sasov A, Verhaar JA, Weinans H: Detecting and tracking local changes in the tibiae of individual rats: a novel method to analyse longitudinal in vivo micro-CT data. *Bone* 2004;34:163-169.
- 20 Feldkamp LA, Davis LC, Kress J.W.: Practical cone-beam algorithm. *J Opt Soc AM* 1984;1:612-619.
- 21 De Clerck N, Postnov A: High resolution X-ray microtomography: Applications in biomedical research.; in Ntziachristos V, Leroy-Willig A, Tavitian B (eds): *Textbook of in vivo imaging in vertebrates*. Wiley, 2007, pp 57-77.
- 22 Sasov A, Van Dyck D: Desktop X-ray microscopy and microtomography. *J Microsc* 1998;191:151-158.

- 23 Weibel ER: in Academic Press (ed): Stereological methods. Vol.I. Practical methods for Biological Morphometry. London, 1979.
- 24 Buul-Offers SC, Reijnen-Gresnigt MG, Hoogerbrugge CM, Bloemen RJ, Kuper CF, Van den Brande JL: Recombinant insulin-like growth factor-II inhibits the growth-stimulating effect of growth hormone on the liver of Snell dwarf mice. *Endocrinology* 1994;135:977-985.
- 25 Zirilli L, Rochira V, Diazzi C, Caffagni G, Carani C: Human models of aromatase deficiency. *J Steroid Biochem Mol Biol* 2008;109:212-218.
- 26 Chagin AS, Savendahl L: Oestrogen receptors and linear bone growth. *Acta Paediatr* 2007;96:1275-1279.
- 27 Dupont S, Krust A, Gansmuller A, Dierich A, Chambon P, Mark M: Effect of single and compound knockouts of estrogen receptors alpha (ERalpha) and beta (ERbeta) on mouse reproductive phenotypes. *Development* 2000;127:4277-4291.
- 28 Lindberg MK, Alatalo SL, Halleen JM, Mohan S, Gustafsson JA, Ohlsson C: Estrogen receptor specificity in the regulation of the skeleton in female mice. *J Endocrinol* 2001;171:229-236.
- 29 Oz OK, Zerwekh JE, Fisher C, Graves K, Nanu L, Millsaps R, Simpson ER: Bone has a sexually dimorphic response to aromatase deficiency. *J Bone Miner Res* 2000;15:507-514.
- 30 Oz OK, Hirasawa G, Lawson J, Nanu L, Constantinescu A, Antich PP, Mason RP, Tsyganov E, Parkey RW, Zerwekh JE, Simpson ER: Bone phenotype of the aromatase deficient mouse. *J Steroid Biochem Mol Biol* 2001;79:49-59.
- 31 Turner RT, Riggs BL, Spelsberg TC: Skeletal effects of estrogen. *Endocr Rev* 1994;15:275-300.
- 32 Santen RJ, Lee JS, Wang S, Demers LM, Mauras N, Wang H, Singh R: Potential role of ultra-sensitive estradiol assays in estimating the risk of breast cancer and fractures. *Steroids* 7-7-2008.
- 33 Evans TR, di Salle E, Ornati G, Lassus M, Benedetti MS, Pianezzola E, Coombes RC: Phase I and endocrine study of exemestane (FCE 24304), a new aromatase inhibitor, in postmenopausal women. *Cancer Res* 1-11-1992;52:5933-5939
- 34 Vanderschueren D, van Herck E, Nijs J, Ederveen AG, De Coster R, Bouillon R: Aromatase inhibition impairs skeletal modeling and decreases bone mineral density in growing male rats. *Endocrinology* 1997;138:2301-2307.

- 35 Karimian E, Chagin AS, Gjerde J, Heino T, Lien EA, Ohlsson C, Savendahl L: Tamoxifen impairs both longitudinal and cortical bone growth in young male rats. *J Bone Miner Res* 2008;23:1267-1277.
- 36 Vidal O, Lindberg MK, Hollberg K, Baylink DJ, Andersson G, Lubahn DB, Mohan S, Gustafsson JA, Ohlsson C: Estrogen receptor specificity in the regulation of skeletal growth and maturation in male mice. *Proc Natl Acad Sci U S A* 9-5-2000;97:5474-5479.
- 37 Eshet R, Maor G, Ben Ari T, Ben Eliezer M, Gat-Yablonski G, Phillip M: The aromatase inhibitor letrozole increases epiphyseal growth plate height and tibial length in peripubertal male mice. *J Endocrinol* 2004;182:165-172.
- 38 di Salle E, Ornati G, Giudici D, Lassus M, Evans TR, Coombes RC: Exemestane (FCE 24304), a new steroidal aromatase inhibitor. *J Steroid Biochem Mol Biol* 1992;43:137-143.
- 39 Turner KJ, Morley M, Atanassova N, Swanston ID, Sharpe RM: Effect of chronic administration of an aromatase inhibitor to adult male rats on pituitary and testicular function and fertility. *J Endocrinol* 2000;164:225-238.
- 40 Vanderschueren D, Boonen S, Ederveen AG, de Coster R, Van Herck E, Moermans K, Vandendput L, Verstuyf A, Bouillon R: Skeletal effects of estrogen deficiency as induced by an aromatase inhibitor in an aged male rat model. *Bone* 2000;27:611-617.
- 41 Coleman RE, Banks LM, Girgis SI, Kilburn LS, Vrdoljak E, Fox J, Cawthorn SJ, Patel A, Snowdon CF, Hall E, Bliss JM, Coombes RC: Skeletal effects of exemestane on bone-mineral density, bone biomarkers, and fracture incidence in postmenopausal women with early breast cancer participating in the Intergroup Exemestane Study (IES): a randomised controlled study. *Lancet Oncol* 2007;8:119-127.
- 42 Lanfranco F, Zirilli L, Baldi M, Pignatti E, Corneli G, Ghigo E, Aimaretti G, Carani C, Rochira V: A novel mutation in the human aromatase gene: insights on the relationship among serum estradiol, longitudinal growth and bone mineral density in an adult man under estrogen replacement treatment. *Bone* 2008;43:628-635.
- 43 Maffei L, Rochira V, Zirilli L, Antunez P, Aranda C, Fabre B, Simone ML, Pignatti E, Simpson ER, Houssami S, Clyne CD, Carani C: A novel compound heterozygous mutation of the aromatase gene in an adult man: reinforced evidence on the relationship between congenital oestrogen deficiency, adiposity and the metabolic syndrome. *Clin Endocrinol (Oxf)* 2007;67:218-224.
- 44 Eisenfeld AJ, Aten RF: Estrogen receptors and androgen receptors in the mammalian liver. *J Steroid Biochem* 1987;27:1109-1118.

- 45 Krishnan V, Heath H, Bryant HU: Mechanism of action of estrogens and selective estrogen receptor modulators. *Vitam Horm* 2000;60:123-147.
- 46 Tsai-Morris CH, Aquilano DR, Dufau ML: Cellular localization of rat testicular aromatase activity during development. *Endocrinology* 1985;116:38-46.
- 47 Janulis L, Bahr JM, Hess RA, Janssen S, Osawa Y, Bunick D: Rat testicular germ cells and epididymal sperm contain active P450 aromatase. *J Androl* 1998;19:65-71.
- 48 Krege JH, Hodgkin JB, Couse JF, Enmark E, Warner M, Mahler JF, Sar M, Korach KS, Gustafsson JA, Smithies O: Generation and reproductive phenotypes of mice lacking estrogen receptor beta. *Proc Natl Acad Sci U S A* 22-12-1998;95:15677-15682.
- 49 Robertson KM, O'Donnell L, Jones ME, Meachem SJ, Boon WC, Fisher CR, Graves KH, McLachlan RI, Simpson ER: Impairment of spermatogenesis in mice lacking a functional aromatase (cyp 19) gene. *Proc Natl Acad Sci U S A* 6-7-1999;96:7986-7991.
- 50 Garcia-Segura LM, Wozniak A, Azcoitia I, Rodriguez JR, Hutchison RE, Hutchison JB: Aromatase expression by astrocytes after brain injury: implications for local estrogen formation in brain repair. *Neuroscience* 1999;89:567-578.
- 51 Carswell HV, Dominiczak AF, Garcia-Segura LM, Harada N, Hutchison JB, Macrae IM: Brain aromatase expression after experimental stroke: topography and time course. *J Steroid Biochem Mol Biol* 2005;96:89-91.
- 52 Veiga S, Azcoitia I, Garcia-Segura LM: Extragonadal synthesis of estradiol is protective against kainic acid excitotoxic damage to the hippocampus. *Neuroreport* 28-9-2005;16:1599-1603.
- 53 McEwen B: Estrogen actions throughout the brain. *Recent Prog Horm Res* 2002;57:357-384.
- 54 Johansen JA, Jordan CL, Breedlove SM: Steroid hormone masculinization of neural structure in rats: a tale of two nuclei. *Physiol Behav* 15-11-2004;83:271-277.
- 55 Azcoitia I, Sierra A, Veiga S, Honda S, Harada N, Garcia-Segura LM: Brain aromatase is neuroprotective. *J Neurobiol* 15-6-2001;47:318-329.
- 56 Matsumoto T, Honda S, Harada N: Alteration in sex-specific behaviors in male mice lacking the aromatase gene. *Neuroendocrinology* 2003;77:416-424