



**Universiteit
Leiden**
The Netherlands

Development of a vernix caseosa substitute : a novel strategy to improve skin barrier function and repair

Rißmann, R.

Citation

Rißmann, R. (2009, March 17). *Development of a vernix caseosa substitute : a novel strategy to improve skin barrier function and repair*. Retrieved from <https://hdl.handle.net/1887/13664>

Version: Not Applicable (or Unknown)

License: [Leiden University Non-exclusive license](#)

Downloaded from: <https://hdl.handle.net/1887/13664>

Note: To cite this publication please use the final published version (if applicable).



Development of a murine model to evaluate the effect of vernix caseosa on skin barrier recovery

Robert Rissmann^{1,a}, Marion Oudshoorn^{2,a}, Dennis van der Coelen¹,
Wim Hennink², Maria Ponec¹ and Joke Bouwstra¹

¹Department of Drug Delivery Technology, Leiden/Amsterdam Center for Drug Research

²Department of Pharmaceutics, Utrecht Institute for Pharmaceutical Sciences

^a Contributed equally as first author

Adapted from *Experimental Dermatology*, in press

Abstract

The aim of this study was twofold, that is generation of a reliable model for skin barrier disruption and repair and to evaluate recovery of damaged skin after application of vernix caseosa. This biofilm was selected as its wound healing properties were suggested previously but never clearly demonstrated. Five different levels of barrier disruption in mice, accomplished by tape stripping, were evaluated. Disruption models moderate, severe #1 and #2 (TEWL of 31 ± 2 , 59 ± 4 and 66 ± 3 g/m²/h, respectively) showed complete recovery within 72h. However, not all corneocytes were removed after tape stripping. Additionally models severe #3 and #4 (TEWL of 73 ± 5 and 79 ± 6 g/m²/h, respectively) with a more severe disruption were evaluated. After tape stripping, all corneocytes were removed and the remaining epidermis was intact. However, model #3 still showed complete recovery within 72h. With model #4 a crust was formed and almost complete recovery (~90%) was obtained within only 8 days. The effect of vernix caseosa application on recovery of disrupted skin was evaluated with model #3 and #4. Model #3 showed that application of vernix caseosa predominantly influenced initial recovery and is therefore merely appropriate to study the effect of formulations in the initial recovery period. Topical application of vernix caseosa on model #4 considerably increased initial and long-term recovery. Moreover, vernix caseosa application promoted rapid formation of stratum corneum and prevented epidermal thickening. These observations not only confirm the ability of vernix caseosa to enhance barrier recovery, but also suggest potential use of this treatment clinically.

Introduction

The cutaneous permeability barrier is an essential defense system against exogenous agents on the one hand, and prevents dehydration on the other. The stratum corneum (SC), the outermost layer of the epidermis, forms the main barrier for diffusion of substances across the skin [1, 2]. One of the commonly used methods to remove SC is sequential tape stripping [2-5]. Increasing the number of tape strips increases the amount of corneocytes removed. Once the barrier function is impaired, a homeostatic repair response is initiated within the epidermis, which results in a recovery of the skin barrier [3, 6]. By measuring the changes in transepidermal water loss (TEWL), the barrier recovery can be monitored non-invasively [3, 5, 7, 8].

Epidermal barrier perturbation can be a consequence of various environmental factors such as burns or injuries. Furthermore, an impaired barrier function is also encountered in diseased skin and in skin of pre-term infants. These infants have an ineffective skin barrier due to a deficient or even absent SC [9-11].

Importantly, in preterm infants the protective natural biofilm vernix caseosa (VC) is also lacking. VC is a lipid-rich material that covers the skin surface of the foetus and the newborn. The structure of VC is very similar to that of SC. VC consists of dead cells with high water binding capacity, nevertheless, it lacks intercorneocyte desmosomal connections and might therefore be referred to as a 'mobile phase' SC [12-14]. It is suggested that VC promotes the formation of the horny layer of the fetus [12, 13] and, moreover, that it acts as a lubricant and moisturizer. Additionally, VC shows a temperature-dependent dehydration behaviour [15] and exhibit anti-infective [16], anti-oxidant [17], skin hydrating [18] and skin cleansing properties postnatally [10]. These multiple biological functions of VC imply that this natural biofilm is an excellent candidate to promote the repair of the skin barrier of preterm infants [10, 11], and may enhance wound healing in adult skin as well [12].

The purpose of the present study is twofold, namely to generate a reliable model for skin barrier disruption and repair, and to evaluate the recovery of damaged skin after application of VC. As previous studies [3, 8, 19, 20] only examined barrier disruption models that resulted in a very fast recovery (i.e. a few hours), it is difficult to design and study formulations that would accelerate skin barrier repair. Our study therefore focused on a skin barrier disruption model with slow recovery. Disruption of the skin barrier was accomplished by tape stripping, which induces skin damage also observed in a variety of clinically relevant situations [3]. VC was applied topically on the disrupted mouse skin to determine whether the barrier recovery could be accelerated. This natural biofilm was selected as its wound healing properties were suggested previously [9, 12, 13, 21], but were never clearly demonstrated. Results of VC were compared to the oil-based ointment Vaseline (petrolatum; Vas). Changes in TEWL were selected to monitor barrier recovery. Additionally, biopsies were harvested to evaluate the recovery of the SC by histology.

Materials & Methods

Materials

Tissue-Tek® O.C.T.™ compound was obtained from Sakura Finetek Europe B.V. (Zoeterwoude, The Netherlands). Black D-squame (rectangles of 70 mm x 25 mm) was obtained from CuDerm (Dallas, USA). Gelatin capsules were provided by Spruyt-Hillen (IJsselstein, The Netherlands). Safranin O was purchased from Sigma (Schnellendorf, Germany). Vaseline (petrolatum) was purchased from Elida Fabergé (London, UK).

Vernix caseosa collection

VC was gently scraped off from healthy full-term neonates immediately after vaginal delivery or caesarean section. The samples were transferred into sterile plastic tubes and stored at 4°C until use. The collection of VC was approved by the ethical committee of the Leiden University Medical Center and informed consent was given by the parents.

Model for skin barrier disruption

Male hairless mice (SKH-rh1), 7-9 weeks old and 28 ± 2 g in weight, were purchased from Charles River Laboratories (St Aubin Les Elbeuf, France). All animal experiments were conducted in conformity with the Public Health Service Policy on use of laboratory animals and had been approved by the Research Ethical Committee of Leiden University (UDEC, nr. 07002). The mice were maintained in the animal care facility of the Gorlaeus Laboratories, Leiden University, in temperature- and humidity-controlled rooms, and fed standard laboratory chow and tap water *ad libitum*.

The animals were anesthetized using a mixture of Ketamine (150 mg/kg body weight; Nimatek®, Euovet Animal Health B.V., Bladel, The Netherlands) and Xylazine (10 mg/kg body weight; Rompun®, Bayer B.V., Mijdrecht, The Netherlands) by intraperitoneal injection (i.p.). During anaesthesia, the mice were kept on a warm mattress with their face down and their eyes wetted with Visagel®. The mice were grouped randomly (six per group), with each group receiving a different treatment. The skin of the mice was washed carefully with deionised water prior to marking two areas (~1 cm², both left and right) on the upper flank of the back of the mice, near the head. The skin barrier was disrupted by sequential tape stripping by a single individual. For this purpose, tape strips (black D-squame) of ~1 cm² were cut and applied on the marked areas. The strips were compressed with finger tips for 5 seconds before rapid removal in alternated stripping direction. An increase in the number of tape strips led to an increase in number of removed SC cells and consequently reduces the skin barrier function. Several levels of barrier disruption were induced: from moderate (defined as TEWL of 30 g/m² per h; 4 tape strips) to severe (defined as TEWL of ≥ 60 g/m² per h; 12 tape strips). After treatment, the mice were housed individually to avoid fight-induced skin injury. No scratching of the treated area or any abnormal behaviour was observed during the studies.

Application

Immediately after disruption of the skin barrier, one test area per mouse was treated with either 5 mg/cm², two times 5 mg/cm² (second application 4h after first application), 15 mg/cm² VC or 5 mg/cm² Vas. VC was not pooled but VC from three different donors was applied on different mice. A single individual rubbed the samples onto the treatment area with a spatula. Untreated contra lateral sites served as controls.

Biophysical evaluation of the skin

a. Transepidermal water loss

The level of barrier disruption and the repair rate were assessed by measuring the TEWL at regular intervals using the Tewameter TM 210 (Courage & Khazaka, Cologne, Germany). The TEWL was measured by holding the probe lightly against the test area until a constant TEWL value was obtained. The pressure applied to the probe was just enough to prevent leakage of air between the lower rim of the Teflon cylinder and the skin.

The percentage of barrier recovery was calculated using the following equation: $1 - ((\text{TEWL at indicated time point} - \text{TEWL of average control 'undamaged skin'}) / (\text{TEWL immediately after stripping} - \text{TEWL of average control 'undamaged skin'})) \times 100\%$.

b. Histology

Biopsies were taken, using a pair of scissors in conjunction with metal tweezers, from the central part of the (treated) sites. The biopsies were immediately placed in a gelatine capsule, processed by fixation in Tissue-Tek®, frozen in liquid nitrogen and stored in liquid nitrogen prior to slicing. Samples (thickness 5 µm) were sliced perpendicular to the skin surface with a cryotome (Leica CM 3050S, Wetzlar, Germany). After fixation in cold acetone (4°C), the sections were stained for 1 min with a 1% (w/v) aqueous safranin solution for contrast. Subsequently, the sections were washed with deionised water. To allow the corneocytes to swell, a 2% (w/v) KOH solution was applied to the sections for 20 min. Visualization was performed with a light microscope combined with a digital camera (Carl Zeiss axioskop, Jena, Germany).

The thickness of the viable epidermis was measured in at least 18 different locations of the stained cross-sections. Statistical differences between the groups (i.e. VC treated, Vas treated and untreated) were determined by a one-way ANOVA with a Bonferroni post-test. All data analysis was performed using GraphPad Prism 4.0.

Results & Discussion

Skin barrier disruption

Disruption of the skin barrier was accomplished by tape stripping. The mice were grouped in several grades of barrier perturbation (i.e. varying from moderate to severe disruption), which simulate a variety of clinically relevant situations [3]. In table 1 the various characteristics of the different skin barrier disruption models are listed. The moderate (4 tape strips) and severe #1 (6 tape strips) barrier disruption model resulted in a TEWL of 31 ± 2 g/m²/h and 59 ± 4 g/m²/h, respectively. In comparison, normal (undisrupted and untreated) skin has a TEWL of ~ 9 g/m²/h. Both models did not show any sign of redness or irritation. The recovery of the skin was monitored by TEWL measurements at regular time intervals and it was observed that complete recovery occurred already within 72 h for both moderate and severe #1 (data not shown). Importantly, histological images of the cross-sections clearly revealed that not all corneocytes were removed directly after tape stripping (Fig. 1A and 1B). As the skin repair process occurred within 3 days and not all corneocytes were removed, additional models with a more severe barrier disruption were evaluated: the number of sequential tape strips was increased to 7 (severe #2; mean TEWL of 66 ± 3 g/m²/h), 8 (severe #3; mean TEWL of 73 ± 5 g/m²/h) or 12 (severe #4; mean TEWL of 79 ± 6 g/m²/h). Disruption model severe #2 did not show any sign of redness or irritation but showed a slight glistening of the skin, which is indicative for complete removal of the SC [5]. However, still some corneocytes were visible by histology (Fig. 1C).

Table 1. Applied levels of barrier disruption by tape stripping with their characteristics.

Disruption level	Nr of strips applied	TEWL* (g/m ² /h)	Skin appearance	Corneocytes present	Recovery (24 h)	Recovery (72 h)
Moderate	4	31 ± 2	normal	Yes	70%	95%
Severe #1	6	59 ± 4	normal	Yes	70%	95%
Severe #2	7	66 ± 3	shiny	Yes	70%	95%
Severe #3	8	73 ± 5	shiny, slightly red	No	64%	95%
Severe #4	12	79 ± 6	very shiny, very red	No	4% [§]	50% [§]

* Undamaged skin has a TEWL of ~ 9 g/m²/h

§ After disruption a crust was formed within a few hours

Between disruption model severe #3 and #4 a considerable difference in both skin appearance and barrier recovery was observed. With model severe #3, the skin was glistening and showed some initial redness indicating an irritation of the skin. The skin of model severe #4 was clearly glistening and an intense redness of the skin was observed. Light microscopic images of the biopsies, taken directly after tape stripping, confirmed that the SC was completely removed for both severe #3 (data not shown) and severe #4 (Fig. 1D), and that the remaining epidermis was intact. Although the SC was completely removed, model severe #3 still showed complete recovery of the TEWL within 72h. However, with model severe #4 a crust was formed on the disrupted area within a few hours. As a result only 50% recovery of the TEWL was observed in 72h. As no scratching of the treated area or any abnormal behaviour was observed, the recovery was monitored for an additional 5 days and an almost complete recovery (~90%) of the skin barrier was obtained within this time period, although some scars developed. As the light microscopic images of both model severe #3 and model severe #4 showed complete removal of SC, and severe #4 showed a rather long recovery time, both models were assessed to study the changes in barrier repair rate after topical application of VC.

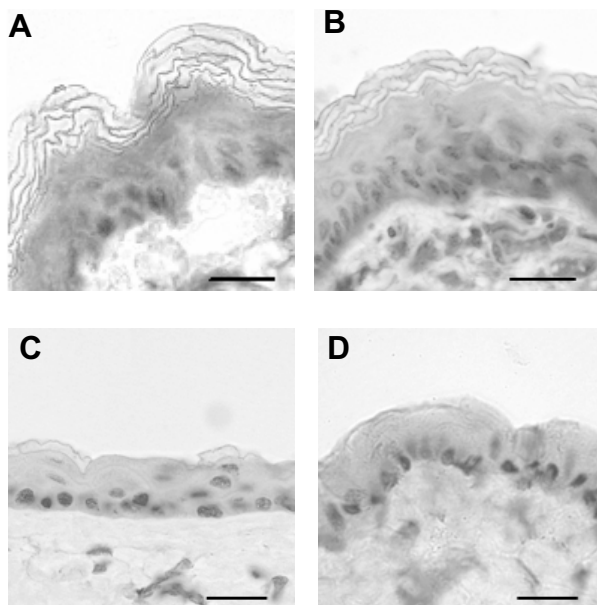


Figure 1. Cross-sections of hairless mouse skin prior to (A) and directly after tape stripping to obtain the barrier disruption model moderate (B), severe #2 (C) or severe #4 (D). Scale bars = 20 μm .

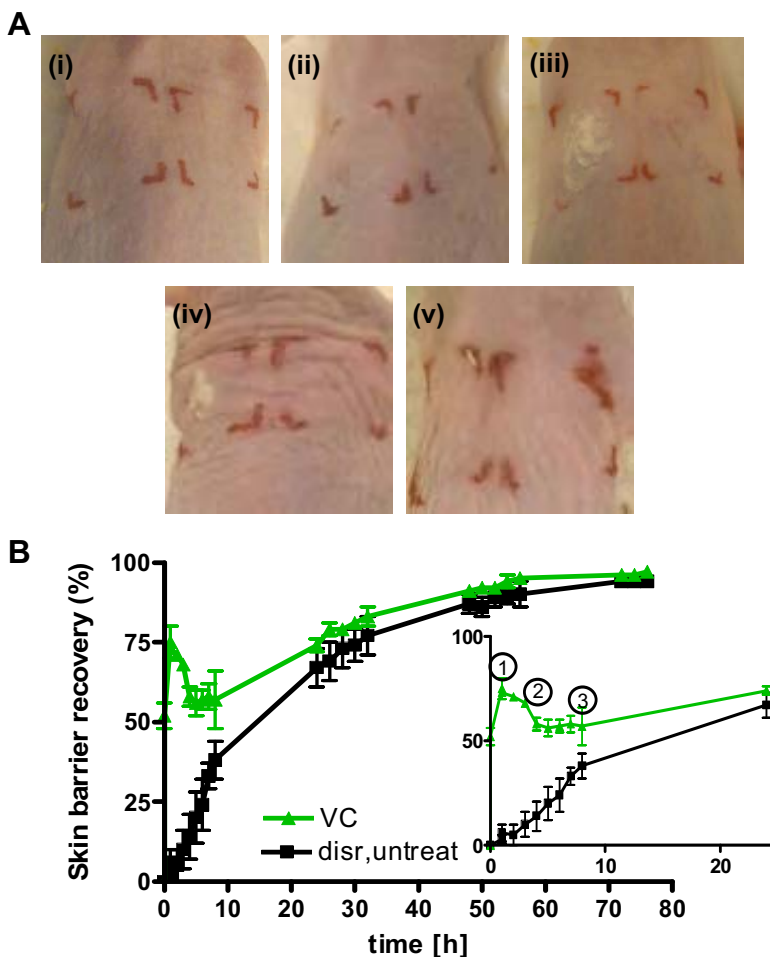


Figure 2. (A) Representative macroscopic observations of undisrupted skin (i), disrupted skin (model severe #3) directly after tape stripping (ii) and the effect of topical application of VC (iii, iv and v; 5 mg/cm²) on the disrupted skin after 1 min, 3 h and 8 h.

(B) Skin barrier recovery after tape stripping (barrier disruption model severe #3) as function of time: VC application (\blacktriangle ; 5 mg/cm²) and untreated, disrupted skin (\blacksquare). The inset shows the recovery of the first 24 h after disruption. In the initial phase (phase 1) VC is applied and covers the skin. VC disappears within 3 to 4 h (phase 2). As the skin is not fully recovered, skin barrier repair is further monitored (phase 3) until complete recovery. Data are shown as average \pm SD ($n = 6$).

Effect of treatment with VC on barrier recovery

To study the effect of VC on the recovery of tape stripped skin, both models, severe #3 and severe #4, were employed. Model severe #3 typically resembles the models previously described in literature that have a very fast recovery (i.e. several hours) [3, 8, 19, 20], whereas severe #4 is an innovative model with extensively damaged skin resulting in substantial slower recovery (i.e. 200h). Macroscopic observations of the VC application site of the damaged skin of model severe #3 are shown in figure 2A. Immediately after tape stripping, the skin was glistening and slightly red (Fig. 2A-ii). However, upon VC application, the redness disappeared within a few minutes (applied on left side; Fig. 2A-iii). Four hours after application, VC was not visible anymore at the skin surface and the skin had a normal appearance (Fig. 2A-iv and 2A-v). Although the untreated area (right side; Fig. 2A) was glistening and slightly red after tape stripping, the skin visually recovered within a few hours as well. The recovery of the skin was also monitored by TEWL measurements (Fig. 2B). Application of VC (5 mg/cm²) immediately increased barrier recovery (TEWL decreased from 73 ± 5 g/m²/h to 23 ± 1 g/m²/h after application of VC), indicated as phase 1 in figure 2B. Once applied, VC disappeared visually within 3 to 4h (phase 2, Fig. 2B). As the skin was not fully recovered a high TEWL was measured (36 ± 1 g/m²/h; barrier recovery of 58 ± 3%). Subsequently, skin barrier repair is monitored (phase 3, Fig. 2B) and complete recovery occurred within 72h. Since the disrupted, untreated skin of this severe #3 model also showed a recovery in 72h, application of VC predominantly influenced initial barrier recovery. Moreover, the application of a higher dose (i.e. 15 mg/cm²) of VC on the disrupted skin did not improve barrier recovery significantly (based on TEWL data; data not shown). Due to its fast recovery, this model is appropriate to study the effect of formulations in the initial recovery period, as described in literature [3, 8, 19, 20].

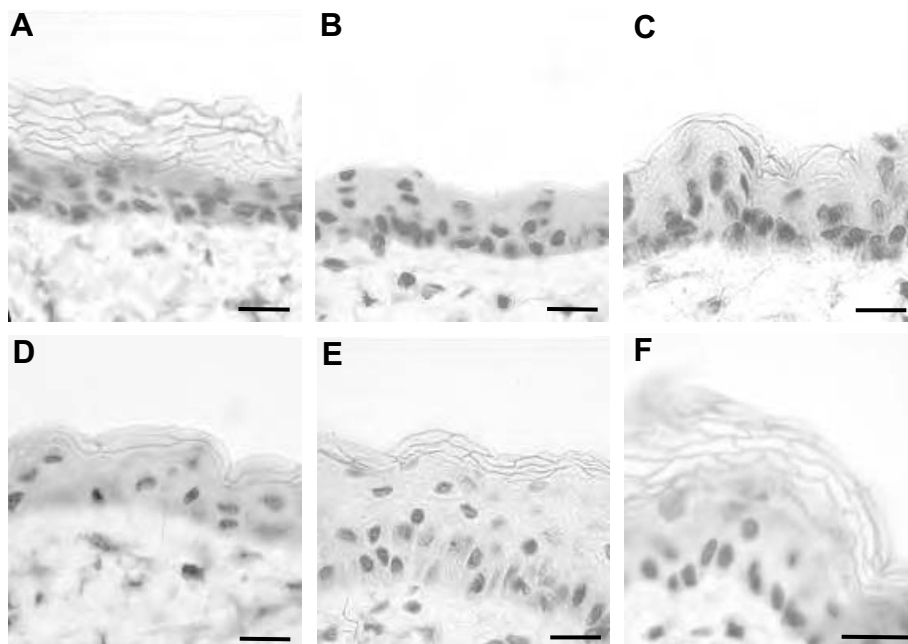


Figure 3. Cross-sections of undisrupted mouse skin (A), disrupted skin (model severe #3) directly after stripping (B) and the recovery of skin after 2 h, 6 h, 24 h and 72 h (C to F, respectively). Scale bars = 20 μ m.

In figure 3 light microscopic images of the damaged skin without treatment, collected at several time intervals, are depicted. Normal skin is characterized by stained nuclei of the viable epidermis cells while swollen corneocytes are also clearly visible (Fig. 3A). After complete barrier disruption (model severe #3) corneocytes were absent (Fig. 3B). During the recovery phase, cell layers of corneocytes gradually reappeared: after 2 h and 6 h one up to two corneocyte layers were observed (Fig. 3C and 3D). After one day, three corneocyte layers were present whereas a complete SC (4 to 6 cell layers) was observed again after 72 h of recovery (Fig. 3E and 3F, respectively). Upon application of VC, histological images did not differ from those of skin which was not treated with VC: an equal number of stratum corneum layers could be observed at the various time intervals (results not shown). As the barrier repair model severe #3 is merely appropriate to study the effect of formulations in the initial recovery period due to its fast recovery, the effect of VC treatment on a more extensively damaged skin (severe #4) was also evaluated.

Figure 4A shows that the skin was very red and glistening after tape stripping and subsequently a crust was formed within a few hours (Fig. 4A-ii-v, right side). This crust was still present 100 h (Fig. 4A-ix; right side) after stripping but was

fully absent within 168 h (Fig. 4A-x; right side), although some scars developed. However, when VC was applied directly after stripping (Fig. 4A-iii, the left side) the redness disappeared in a few minutes and no crust formation occurred (Fig. 4A-iv,v,vi left side). Furthermore, the skin recovered much faster (visually: ~72 h in stead of ~168 h; see Fig. 4A) and no scars were formed as compared to untreated skin (Fig. 4A-iv-ix). As seen in figure 4, disrupted skin treated with VC showed fast and complete recovery after approximately 100 h. Initially, the skin was covered with VC (phase 1, Fig. 4B) decreasing the TEWL from $79 \pm 6 \text{ g/m}^2/\text{h}$ to $29 \pm 2 \text{ g/m}^2/\text{h}$. Subsequently, VC disappeared visually within 3 to 4h (phase 2, Fig. 4B). As the skin was not fully recovered a TEWL of $57 \pm 5 \text{ g/m}^2/\text{h}$ was measured (barrier recovery of $37 \pm 5\%$). Next, the skin barrier repair was monitored (phase 3, Fig. 4B) and complete recovery occurred within 100 h.

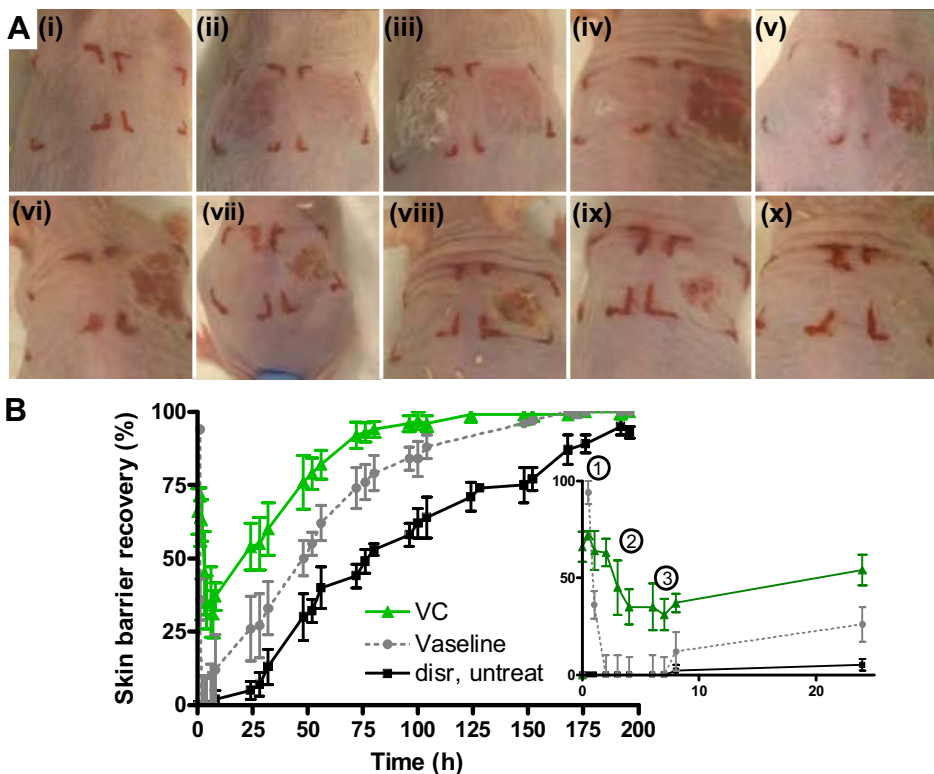


Figure 4. (A) Representative macroscopic observations of undisrupted skin (i), skin barrier disruption (model severe #4) immediately after tape stripping (ii) and the effect of topical application of VC after 1 min, 3 h, 5 h, 8 h, 24 h, 72 h, 100 h and 168 h (iii, iv, v, vi, vii, viii, ix and x, respectively) on the disrupted skin. (B) Skin barrier recovery of disrupted skin (model severe #4) as function of time: VC application (▲; 5 mg/cm^2), Vaseline (●; dashed line) and disrupted, untreated skin (■). The inset shows the recovery of the first 24h after disruption. Data are shown as average \pm SD ($n = 6$).

Neither application of a higher dose (i.e. 15 mg/cm²) nor multiple applications (i.e. twice 5 mg/cm²; second dose applied 4h after first dose) of VC did further accelerate the skin barrier recovery (based on TEWL data; data not shown) compared to a single application of 5 mg VC. VC was obtained from 3 different donors; VC from different donors were not pooled but was applied on different mice. However, no donor-to-donor variation was observed (based on TEWL data). Untreated, disrupted skin showed an initial lag time of 7 h after which barrier repair developed slowly and nearly complete recovery (~90 %) only occurred after 200 h. These observations not only confirm the ability of VC to enhance initial and long-term barrier recovery of extensively damaged skin[12], but they also suggest the potential use of this treatment clinically for wound healing purposes. To date, these wound healing properties of VC were only shown in adult patients with trophic ulcers [22]. One can speculate whether the suggested mechanism of action, i.e. the stimulation of tissue metabolism, is also valid for our study.

The effect of VC on the recovery of extensively disrupted skin was also histologically studied (Fig. 5). A number of corneocytes could already be perceived on the VC treated skin (Fig. 5A) 6 h after tape stripping, whereas no SC was visible on disrupted, untreated skin at the same time point (Fig. 5B). After 24 h even more corneocytes were present on the VC treated skin whereas the untreated damaged skin was still free from corneocytes (Fig. 5C and 5D, respectively). The SC was clearly visible (Fig. 5E) after 48h on disrupted, untreated skin and no major difference could be observed between VC treated and untreated skin (Fig. 5E and 5F, respectively). When the skin was fully recovered (after 8 days; Fig. 5G and 5H) the histology was similar to that prior to the disruption procedure. Hence, VC application promotes a fast recovery of the SC. When analyzing the dermal areas in the histological sections no abnormalities of the appearance, i.e. signs of inflammation, could be observed.

Vas already has been speculated to accelerate barrier recovery in mice [23]. Therefore the effect of Vas was investigated with model severe #4 and compared to VC. When Vas was applied directly after stripping, the treated site remained red (data not shown). Moreover, 3 days post application the disrupted treated site was still slightly red and minor crust formation was observed. These observations indicate an improved wound healing compared to disrupted, untreated skin (strong crust development), however less effective compared to VC treated skin (absence of crust). Application of Vas (5 mg/cm²) immediately restored the barrier function of the skin (indicated as phase 1 in Fig. 4B; TEWL decreased from 79 ± 6 g/m²/h to 3 ± 0.5 g/m²/h) demonstrating the occlusive properties of Vas.

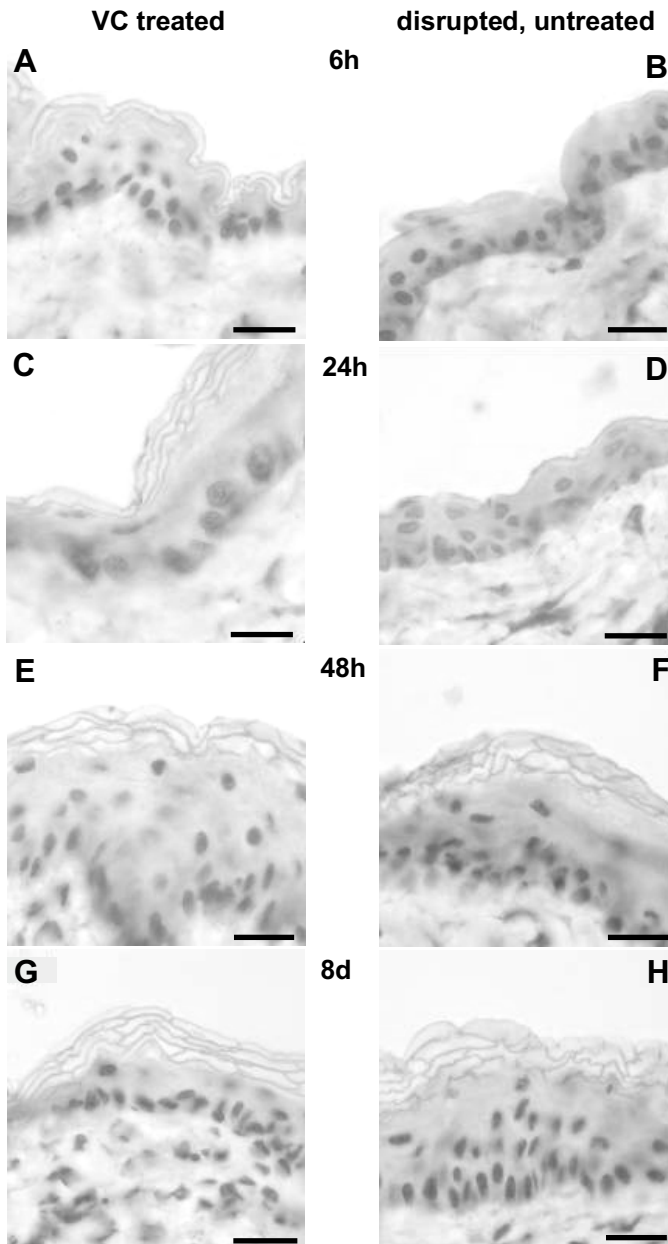


Figure 5. Representative histological cross-sections of mouse skin after disruption (model severe #4): with VC treatment (A, C, E, G) or without treatment (B, D, F, H) 6 h, 24 h, 48 h and 8 days after tape stripping, respectively. Scale bars = 20 μ m.

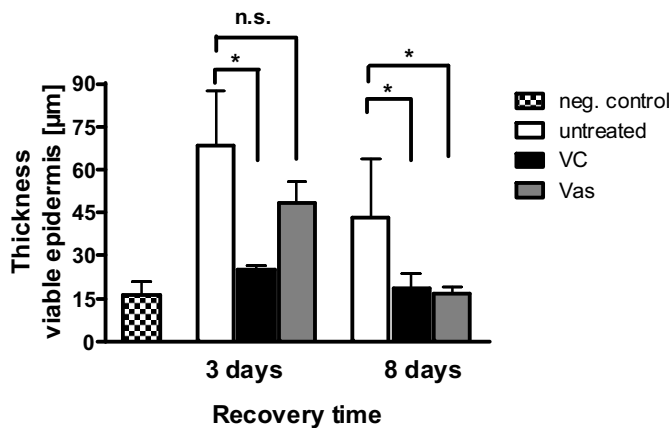


Figure 6. Thickness of viable epidermis of untreated, VC or Vas treated disrupted mouse skin after 3 or 8 days of recovery compared to undisrupted untreated skin (negative control). Per treatment, at least 18 different locations of the cross-sections were measured. The error bars show SD. * $P < 0.05$; n.s. = not significant

Vas disappeared visually within 2 h, which was associated with loss of its barrier function (phase 2, Fig. 4B). As a result, the TEWL rose again to $77 \pm 7 \text{ g/m}^2/\text{h}$, which is comparable to disrupted, untreated skin (i.e. $79 \pm 6 \text{ g/m}^2/\text{h}$). Subsequent monitoring of the skin barrier showed that complete recovery occurred within 150 h (phase 3, Fig. 4B). Since the disrupted, untreated skin showed nearly complete recovery within 200 h, application of Vas did enhance barrier recovery however to a lesser extent than VC (i.e. 100 h). A histological study of the effect of Vas on the recovery of extensively disrupted skin revealed a similar trend in SC recovery (data not shown) as was observed after VC treatment (Fig. 5). These results clearly indicate that occlusion of the skin (i.e. upon application of Vas) is not sufficient to elucidate the effect of VC. Hence, the water content of VC and/or the presence of specific groups of lipids/proteins may play a role in the favourable effects of VC on skin barrier recovery.

In addition, the occurrence of epidermal thickening was evaluated. Epidermal thickening has been partly associated with hyperproliferation [24] and is an indication for different skin diseases such as atopic dermatitis and psoriasis [5]. Figure 6 shows the thickness of the viable epidermis of untreated, VC or Vas treated disrupted mouse skin after 3 and 8 days of recovery in comparison to undisrupted, untreated skin. The thickness of the viable epidermis of undamaged and untreated hairless mouse skin is $16 \pm 6 \mu\text{m}$. 3 and 8 days after recovery the disrupted but untreated epidermis is $68 \pm 20 \mu\text{m}$ and $43 \pm 20 \mu\text{m}$, respectively. This is significantly thicker ($P < 0.05$) than the VC treated site after 3 and 8 days where the epidermis exhibited a thickness of $25 \pm 5 \mu\text{m}$ and $18 \pm 6 \mu\text{m}$, respectively, which is comparable to undamaged, untreated skin.

The Vas treated site, however, showed a thickened epidermis after 3 days ($48 \pm 10 \mu\text{m}$) similar to disrupted, untreated skin. Moreover, this is significantly different ($P < 0.05$) from the VC treated site. Eight days after treatment, the Vas treated skin showed a less thickened epidermis ($17 \pm 5 \mu\text{m}$), which is comparable to VC. Epidermal thickening of disrupted, untreated skin and of Vas treated skin after 3 days of recovery is likely due to hyperproliferation that is not observed on disrupted, VC treated areas. Therefore, application of VC not only accelerates barrier recovery but also effectively prevents epidermal thickening after severe barrier insults.

In conclusion, the present study demonstrates that sequential tape stripping is an efficient method to generate reliable models for skin barrier disruption and repair. By increasing the number of tape strips different models could be obtained with a disrupted skin varying from moderate to severe. Only extensively damaged skin (i.e. model severe #4) showed a rather slow recovery, whereas all other models resulted in a very fast skin barrier repair. It was observed that topical application of VC on severely disrupted skin (model severe #4) considerably increased the skin barrier recovery and was more efficient than Vas treatment. Moreover, VC application promoted a rapid formation of SC and prevented most effectively epidermal thickening. These observations not only confirm the ability of VC to enhance skin barrier recovery, but suggests its potential clinical use.

References

- [1] Madison KC. Barrier function of the skin: "la raison d'etre" of the epidermis. *J Invest Dermatol* 2003 Aug;121(2):231-41.
- [2] Breternitz M, Flach M, Prassler J, Elsner P, Fluhr JW. Acute barrier disruption by adhesive tapes is influenced by pressure, time and anatomical location: integrity and cohesion assessed by sequential tape stripping. A randomized, controlled study. *Br J Dermatol* 2007 Feb;156(2):231-40.
- [3] Yang L, Mao-Qiang M, Taljebini M, Elias PM, Feingold KR. Topical stratum corneum lipids accelerate barrier repair after tape stripping, solvent treatment and some but not all types of detergent treatment. *Br J Dermatol* 1995 Nov;133(5):679-85.
- [4] Uhoda E, Piérard-Franchimont C, Debatisse B, Wang X, Piérard G. Repair kinetics of the stratum corneum under repeated insults. *Exog Dermatol* 2004;3:7-11.
- [5] van de Kerkhof PC, de Mare S, Arnold WP, van Erp PE. Epidermal regeneration and occlusion. *Acta Derm Venereol* 1995 Jan;75(1):6-8.
- [6] Hachem JP, Houben E, Crumrine D, Man MQ, Schurer N, Roelandt T, Choi EH, Uchida Y, et al. Serine protease signaling of epidermal permeability barrier homeostasis. *J Invest Dermatol* 2006 Sep;126(9):2074-86.
- [7] Fluhr JW, Feingold KR, Elias PM. Transepidermal water loss reflects permeability barrier status: validation in human and rodent in vivo and ex vivo models. *Exp Dermatol* 2006 Jul;15(7):483-92.
- [8] Grubauer G, Elias PM, Feingold KR. Transepidermal water loss: the signal for recovery of barrier structure and function. *J Lipid Res* 1989 Mar;30(3):323-33.
- [9] Bautista MI, Wickett RR, Visscher MO, Pickens WL, Hoath SB. Characterization of vernix caseosa as a natural biofilm: comparison to standard oil-based ointments. *Pediatr Dermatol* 2000 Jul-Aug;17(4):253-60.
- [10] Moraille R, Pickens WL, Visscher MO, Hoath SB. A novel role for vernix caseosa as a skin cleanser. *Biol Neonate* 2005;87(1):8-14.
- [11] Hoeger PH, Schreiner V, Klaassen IA, Enzmann CC, Friedrichs K, Bleck O. Epidermal barrier lipids in human vernix caseosa: corresponding ceramide pattern in vernix and fetal skin. *Br J Dermatol* 2002 Feb;146(2):194-201.
- [12] Haubrich KA. Role of Vernix caseosa in the neonate: potential application in the adult population. *AACN Clin Issues* 2003 Nov;14(4):457-64.
- [13] Pickens WL, Warner RR, Boissy YL, Boissy RE, Hoath SB. Characterization of vernix caseosa: water content, morphology, and elemental analysis. *J Invest Dermatol* 2000 Nov;115(5):875-81.
- [14] Rissmann R, Groenink HW, Weerheim AM, Hoath SB, Ponec M, Bouwstra JA. New insights into ultrastructure, lipid composition and organization of vernix caseosa. *J Invest Dermatol* 2006;126:1823-33.
- [15] Rissmann R, Groenink HW, Gooris GS, Oudshoorn MHM, Hennink WE, Ponec M, Bouwstra JA. Temperature-Induced Changes in Structural and Physicochemical Properties of Vernix Caseosa. *J Invest Dermatol* 2008 Aug 2;128:292-9.
- [16] Akinbi HT, Narendran V, Pass AK, Markart P, Hoath SB. Host defense proteins in vernix caseosa and amniotic fluid. *Am J Obstet Gynecol* 2004 Dec;191(6):2090-6.
- [17] Pickens WL, Zhou Y, Wickett RR, Visscher MO, Hoath SB. Antioxidant defense mechanisms in vernix caseosa: potential role of endogenous vitamin E. *Pediatr Res* 2000;47:425A.
- [18] Visscher MO, Narendran V, Pickens WL, LaRuffa AA, Meinzen-Derr J, Allen K, Hoath SB. Vernix caseosa in neonatal adaptation. *J Perinatol* 2005 Jul;25(7):440-6.
- [19] Amano T, Takeda T, Yano H, Tamura T. Olopatadine hydrochloride accelerates the recovery of skin barrier function in mice. *Br J Dermatol* 2007 May;156(5):906-12.
- [20] Ikeyama K, Fuziwara S, Denda M. Topical application of neuronal nitric oxide synthase inhibitor accelerates cutaneous barrier recovery and prevents epidermal hyperplasia induced barrier disrupted. *J Invest Dermatol* 2007;127:1713-9.

- [21] Hoath SB, Pickens WL, Visscher MO. The biology of vernix caseosa. *Int J Cosmetic Sci* 2006;28:319-33.
- [22] Zhukov BN, Neverova EI, Nikitin KE, Kostiaev VE, Myshentsev PN. [A comparative evaluation of the use of vernix caseosa and solcoseryl in treating patients with trophic ulcers of the lower extremities]. *Vestn Khir Im I I Grek* 1992 Jun;148(6):339-41.
- [23] Ghadially R, Halkier-Sorensen L, Elias PM. Effects of petrolatum on stratum corneum structure and function. *J Am Acad Dermatol* 1992 Mar;26(3 Pt 2):387-96.
- [24] Porter RM, Reichelt J, Lunny DP, Magin TM, Lane EB. The relationship between hyperproliferation and epidermal thickening in a mouse model for BCIE. *J Invest Dermatol* 1998 Jun;110(6):951-7.