



Universiteit  
Leiden

The Netherlands

## Pharmacologic and clinical aspects of isolated hepatic perfusion (IHP) of liver metastases of solid tumours

Iersel, L. van

### Citation

Iersel, L. van. (2011, December 13). *Pharmacologic and clinical aspects of isolated hepatic perfusion (IHP) of liver metastases of solid tumours*.

Department of Clinical Oncology and Department of Surgery, Faculty of Medicine, Leiden University Medical Center (LUMC), Leiden University.

Retrieved from <https://hdl.handle.net/1887/18240>

Version: Corrected Publisher's Version

License: [Licence agreement concerning inclusion of doctoral thesis in the Institutional Repository of the University of Leiden](#)

Downloaded from: <https://hdl.handle.net/1887/18240>

**Note:** To cite this publication please use the final published version (if applicable).

# **Pharmacologic and clinical aspects of Isolated Hepatic Perfusion (IHP) of liver metastases of solid tumours**

**Liselot Valkenburg-van Iersel**



ISBN: 978-94-6169-165-1

Printed by Optima Grafische Communicatie, Rotterdam

Cover design: Ans van Iersel, Dongen, The Netherlands, ansjejoanna@gmail.com

Copyright © 2011 by L.B.J. Valkenburg-van Iersel, The Netherlands

# **Pharmacologic and clinical aspects of Isolated Hepatic Perfusion (IHP) of liver metastases of solid tumours**

Proefschrift

ter verkrijging van  
de graad van Doctor aan de Universiteit Leiden,  
op gezag van Rector Magnificus prof.mr. P.F. van der Heijden,  
volgens besluit van het College voor Promoties  
te verdedigen op dinsdag 13 december 2011

klokke 11:15 uur

door

Liselot Valkenburg-van Iersel

geboren te Tilburg

in 1978

## **Promotiecommissie:**

**Promotoren:** Prof. Dr. H. Gelderblom  
Prof. Dr. J.W.R. Nortier  
Prof. Dr. C.J.H. van de Velde

**Co-promotor:** Dr. P.J.K. Kuppen

**Overige leden:** Prof. Dr. J.H.M. Schellens  
Prof. Dr. J. Morreau  
Dr. C. Verhoef

Financial support for the publication of this thesis by Bronovo Research Foundation, SKOL, Amgen BV, Novartis Pharma BV, Pfizer BV, GlaxoSmithKline, AstraZenica BV, Sanofi-aventis BV, MSD BV, Bayer BV, Abbot BV and Roche Nederland BV is gratefully acknowledged.

## Contents

Chapter 1	General Introduction. <i>Silberman &amp; Silberman, Principles and Practice of Surgical Oncology, Second edition 2009; Ch. 48: p882-p891</i>	7
Chapter 2	Isolated hepatic perfusion with 200 mg melphalan for advanced noncolorectal liver metastases. <i>Ann Surg Oncol. 2008 Jul;15(7):1891-8</i>	23
Chapter 3	Hepatic artery infusion of high-dose melphalan at reduced flow during isolated hepatic perfusion for the treatment of colorectal metastases confined to the liver: A clinical and pharmacologic evaluation. <i>Eur J Surg Oncol. 2007 Sep;33(7):874-81</i>	39
Chapter 4	Isolated hepatic melphalan perfusion of colorectal liver metastases: outcome and prognostic factors in 154 patients. <i>Ann Oncol. 2008 Jun;19(6):1127-34</i>	57
Chapter 5	Management of isolated non-resectable liver metastases in colorectal cancer patients: a case-control study of isolated hepatic perfusion with melphalan versus systemic chemotherapy. <i>Ann Oncol. 2010 Aug;21(8):1662-7</i>	75
Chapter 6	In vitro schedule-dependent interaction between melphalan and oxaliplatin in human colorectal cancer cell lines. <i>J Surg Res 2009 doi:10.1016/j.jss.2009.07.007</i>	89
Chapter 7	Isolated hepatic perfusion with oxaliplatin combined with 100 mg melphalan: a phase I study. <i>Manuscript in preparation</i>	101
Chapter 8	The future of isolated hepatic perfusion for isolated liver metastases.	117
	Nederlandse Samenvatting	129
	Curriculum Vitae	135



---

# CHAPTER 1

## General introduction

Partly adapted from: L.B.J. van Iersel, H. Gelderblom,  
J.W.R. Nortier, C.J.H. van de Velde.

*Silberman & Silberman, Principles and Practice of Surgical Oncology,  
Second edition 2009; Ch. 48: p882-p891: Liver Tumors: Multi-modality  
treatment of hepatic metastases*

---





## Multimodality treatment of colorectal liver metastases

The most common origin of hepatic metastasis is colorectal cancer. Liver metastases are diagnosed in 10-25% of patients at the time of resection of their primary colorectal tumour and eventually up to 70 % of patients with colorectal cancer will develop liver metastases<sup>1</sup>. In approximately 30% of the patients the liver is the only site of metastatic disease<sup>2,3</sup>. If the metastases are confined to the liver there are several locoregional treatment options, including partial hepatic resection, local ablative therapy, administration of chemotherapy by hepatic artery infusion (HAI) and isolated hepatic perfusion (IHP) with high dose chemotherapy. Curative resection of colorectal cancer liver metastases is possible in less than 10 percent of patients due to the number, location or size of the metastases<sup>4,5</sup>. After neoadjuvant treatment with modern systemic chemotherapy regimens another 12-14% of colorectal cancer patients with liver metastases are suitable for hepatic resection<sup>6</sup>. If patients are ineligible for hepatic resection, palliative systemic chemotherapy is often the only treatment option for liver metastases. The role of locoregional treatment options other than resection is currently subject to much debate.

### Local ablative therapy

Several local ablative techniques are available for the treatment of liver metastases. Radiofrequency ablation (RFA) is most often applied. Other less frequently applied therapies include cryotherapy, hepatic artery embolization (HAE), percutaneous alcohol injection (PAI), microwave coagulation therapy (MCT), laser induced thermotherapy (LITT), photodynamic therapy (PTD) and radiotherapy. Local ablative therapies provide the possibility of local disease control without systemic toxicity.

#### *Radiofrequency ablation*

The major advantage of RFA is the selective destruction of tumour tissue without significant damage to normal liver tissue. In RFA, the needle electrodes cause hyperthermia, through the delivery of a high frequency alternating current, resulting in the destruction of proteins and cell membranes, inducing coagulative necrosis. Under optimal conditions current RFA devices can provide spherical lesions of up to 7cm in diameter<sup>7</sup>. RFA can be applied alone or in combination with surgical resection if surgical resection criteria are not fulfilled, widening the applicability of surgical resection. Most studies on RFA focus around colorectal liver metastases, neuroendocrine tumours and breast cancer. Results are often difficult to interpretate, because reports include different tumour types, treated with a variety of techniques and additional treatments such as chemotherapy obscure the primary effect of RFA treatment.

In colorectal cancer liver metastases, RFA has resulted in complete response rates of 52-95%, with a median survival time of approximately 30-34 months after diagnosis of liver metastases. Local recurrence rates (lesion-based) vary between 2.0-39% depending on which method is applied<sup>8-18</sup>. Several studies have shown local recurrence rates to be less if an open or laparoscopic technique is applied as compared to the percutaneous method<sup>19, 20</sup>. Over 90% of the recurrent disease occurs outside the treated area both intra- and extrahepatically, emphasizing the local nature of the treatment. Optimal results in RFA are achieved in an experienced centre, using an open technique, on 3 or less liver metastases, not located near any large vascular structures and less than 5cm in diameter<sup>18, 21, 22</sup>.

The possibility of curation and the large percentage of extrahepatic recurrences after RFA have resulted in the common practice of combining systemic treatment with RFA, even though the benefits of combining both treatments have not been thoroughly examined. The true value of RFA remains to be seen.

#### *Other ablative treatment modalities*

Cryoablation results in tumour destruction through the formation of intra- and extracellular ice crystals by repeated freezing and thawing, caused by inserting a probe with circulating liquid nitrogen. Cryoablation is most frequently applied in the treatment of hepatocellular carcinoma (HCC) and to a lesser extent in colorectal cancer liver metastases. In colorectal cancer patients a median survival of around 26 months after cryoablation has been published<sup>23-26</sup>. Cryotherapy has been replaced by other ablative treatment modalities, due to the high rates of local recurrences and complications<sup>27, 28</sup>.

Hepatic arterial ligation and (chemo)embolization are based on the principle that, liver metastases derive most of their blood supply from the hepatic artery, while healthy liver tissue is mainly supplied by the portal vein<sup>29, 30</sup>. Although ligation and embolization were considered promising treatments at introduction several decades ago, no studies have shown substantial benefit in the treatment of liver metastases<sup>31</sup>. Therefore many centres have abandoned this technique.

Percutaneous alcohol injection (PAI) is mainly applied in the treatment of HCC with tumour response rates up to 80%, but its role in the treatment of liver metastases seems limited<sup>32</sup>. As shown by the poor results of PAI in colorectal liver metastases, with no necrosis induced in a series of 22 colorectal tumours, the more solid aspect of colorectal liver metastases, can impair the adequate injection of sufficient volumes of alcohol in the tumour<sup>33</sup>.

Microwave coagulation therapy (MCT) and laser induced thermotherapy (LITT) resemble the RFA technique, as they are based on the generation of heat in the tumour and therefore considered thermal ablation techniques. In MCT heat is generated through a microwave-emitting needle, producing dielectric heat by stimulation of water molecules within cells. The rapid agitation of water molecules produces frictional heating and coagulative necrosis<sup>34</sup>. Like RFA and LITT, MCT can be performed percutaneously, laparoscopically or during an open procedure. The major drawback of MCT is it produces zones of only 10-25mm of coagulative necrosis, requiring multiple needle insertions for adequate treatment. Few studies have been performed using MCT as a treatment modality in liver metastases. In colorectal cancer liver metastases, studies have shown tumour response up to 87% with a mean survival of 27 months, but patient numbers are small<sup>35, 36</sup>. In LITT heat is not generated by high frequency current but by a laser applicator that delivers light energy through optical fibers inserted in the target tissue, leading to tumour destruction<sup>34</sup>. Mack *et al* reported the largest series of 705 patients, including 57% colorectal cancer patients, 18% breast cancer patients, 5% hepatocellular carcinoma patients and 20% other patients<sup>37-39</sup>. The rate of clinically relevant complications such as pleural effusion, intrahepatic abscess and intra-abdominal bleeding was 1.3%. The tumour response rate was 99.3% after 3 months, with a mean survival rate in respectively colorectal cancer and breast cancer patients of 41.8 and 51.6 months.

PDT, on the other hand, uses optical fibers and laser light. The antitumor effect in PDT is caused by reactive oxygen species, generated through a photosensitizing agent, which is administered systemically and will localize in tumour tissue<sup>40, 41</sup>. Illumination of the tumour by light of an appropriate wavelength will cause the photosensitizer to transform to an unstable higher energy level. The absorbed energy is transformed to oxygen, leading to the formation of reactive oxygen species, which are cytotoxic and cause direct tumour cell and vascular damage<sup>42</sup>. Results of a phase I trial in 24 patients show PDT to be feasible and a relatively safe and effective treatment of colorectal liver metastases<sup>43</sup>.

Application of external radiotherapy for the treatment of liver metastases has been limited by low tolerance of the normal liver parenchyma and absence of an obvious survival benefit in studies involving whole-liver irradiation<sup>44</sup>. Recently two alternative techniques to deliver radiation more selectively have been developed involving radioactive isotopes, i.e. SIR-spheres<sup>®</sup> and 3D planning software. In selective internal radiation therapy (SIRT) radioactive spheres are delivered selectively to the tumour through injection in the hepatic artery. Gray *et al* performed a randomized clinical trial in 74 colorectal cancer patients comparing a single administration of SIR-spheres<sup>®</sup> combined with hepatic artery infusion of FUDR with hepatic artery infusion of FUDR alone<sup>45</sup>. Treat-

ment with SIR-spheres® was associated with a significantly better response rate (44% vs. 17.6%,  $P = 0.01$ ) and median time to progression (15.9 vs. 9.7 months,  $P = 0.001$ ). Grade 3-4 treatment related toxicity was similar for both groups. In stereotactic radiotherapy improvements in positioning and 3D planning software have enabled treatment of a specific focus in the liver with a single high dose of radiotherapy with minimal damage to healthy liver tissue<sup>34,46</sup>. A phase I/II trial in 60 liver tumours of various origin, show the technique is safe and local tumour control was achieved in 98% of tumours<sup>47</sup>.

## Chemotherapy

### Systemic chemotherapy

Until recently, the standard treatment for metastatic colorectal cancer consisted of 5-FU based schedules, resulting in response rates around 15%, median time to progression of 5 months and overall survival of 12 months<sup>48</sup>. In the past decade several new agents have become available including oxaliplatin, irinotecan and the monoclonal antibodies bevacizumab and panitumumab/cetuximab<sup>49-56</sup>. Both irinotecan and oxaliplatin combined with 5-FU/leucovorin or capecitabine have shown an increase in terms of progression-free survival, overall survival and quality of life compared with 5-FU/leucovorin alone in first- and second-line therapy<sup>54, 56-61</sup>. Recently, several studies have been conducted investigating combination and sequential use of several new agents. Tournigand *et al* conducted a phase III cross-over study of first-line chemotherapy with in one arm 5-FU/leucovorin with oxaliplatin and in the other arm 5-FU/leucovorin with irinotecan resulting in maximum median survival of 21.5 months<sup>52</sup>. Even more recently Koopman *et al* showed that both combination treatment and sequential treatment with capecitabine, irinotecan and oxaliplatin yields similar results<sup>62</sup>. The introduction of bevacizumab, a monoclonal antibody directed against vascular endothelial growth factor (VEGF) has further improved treatment options in metastatic colorectal cancer. Hurwitz *et al* reported that the addition of bevacizumab to bolus irinotecan and 5-FU/leucovorin as a first-line treatment resulted in increased survival, response rate and duration of response<sup>53</sup>. Similarly, panitumumab/cetuximab, monoclonal antibodies against epidermal growth factor receptor (EGFR) have further improved survival in combination with either irinotecan or oxaliplatin, especially in patients without K-ras mutation<sup>49, 55</sup>. Now oncologists are faced with the challenge of choosing the optimal treatment schedule for advanced colorectal cancer for each individual patient. Currently, the combination of fluoropyrimidine-based chemotherapy with oxaliplatin and bevacizumab is considered standard first-line treatment in metastatic colorectal cancer. The addition of panitumumab or cetuximab to a schedule with bevacizumab increases toxicity without improving survival and thus should be reserved for second-line treatment<sup>63, 64</sup>.

### *Regional chemotherapy*

Hepatic artery infusion (HAI) is a therapeutic option for patients with isolated liver metastases not suitable for surgical resection or local ablation. Similar to hepatic arterial ligation and embolization, HAI of chemotherapy is based on the principle that, in contrast to normal liver parenchyma, liver metastases derive most of their blood supply from the hepatic artery<sup>29, 30</sup>. Subsequently, high drug concentrations can be achieved at the tumour site without damage to the healthy liver tissue. HAI has mainly been applied in colorectal cancer liver metastases and hepatocellular carcinoma. Early infusion trials administered chemotherapy using percutaneously placed catheters, requiring bed rest and hospitalization during infusion of the chemotherapy. When a totally implantable pump was introduced HAI chemotherapy changed into a more convenient ambulatory treatment. All techniques require an angiogram to assess vascular anatomy before catheter placement. Most studies show around 20-40% of patients cannot receive infusion treatment due to abnormal vasculature inhibiting perfusion of the entire liver<sup>65-67</sup>. Catheters and pumps can be placed through laparotomy or laparoscopy. Laparotomy enables assessment of extrahepatic metastases and ligation of arterial collaterals to decrease incidence of extrahepatic perfusion and chemical gastritis or duodenitis<sup>68, 69</sup>. Complications associated to catheter placement include death, hepatic misperfusion, catheter obstruction and hepatic artery thrombosis, with complications rates being less for implantable pumps as compared to ports<sup>68, 70, 71</sup>.

Fluorodeoxyuridine (FUDR) and 5-FU are the drugs most often used for hepatic arterial infusion. An ideal drug for HAI has to fulfil several criteria including a steep dose response curve, high total body clearance and minimal liver toxicity. Both FUDR and 5-FU have a steep dose response curve, but FUDR has a higher hepatic extraction rate when continuously infused (95% for FUDR vs. 19-90% for 5-FU )<sup>72</sup>. Although higher hepatic extraction rates lead to increased regional drug exposure, it also implies limited systemic exposure. Considering approximately 50% of patients treated with HAI have extrahepatic disease progression, some centres prefer HAI with 5-FU to obtain both local and systemic disease control<sup>73</sup>. Treatment-related toxicities include chemical hepatitis, biliary sclerosis and peptic ulceration. Kemeny *et al* reported an increase in response and survival rate and a decrease in hepatotoxicity if dexamethasone is added to FUDR<sup>74</sup>. Several randomized studies involving HAI with FUDR or 5-FU in colorectal cancer patients have reported significantly higher tumour response rates compared with systemic administration (HAI 41%, systemic 14%;  $p < 0.0001$ )<sup>65, 66, 75</sup>. In 1996, two meta-analyses combining the results of 10 randomized trials appeared, comparing HAI with either systemic treatment or best supportive care<sup>73, 76</sup>. The Meta-Analysis Group in Cancer studied 7 randomized trials and when combining the results of the 5 trials

comparing HAI with systemic treatment, concluded that although HAI showed superior response rates compared to systemic treatment (41% vs.14%) there was no significant survival benefit and treatment-related hepatotoxicity was considerable. Harmantas *et al* studied 6 randomized trials and reported a modest survival benefit for HAI over systemic treatment. These studies have two major drawbacks. First of all, in three of the analyzed randomized trials patients were allowed to cross-over from systemic treatment to HAI possibly obscuring any survival benefit. Secondly, the drug doses and schedules varied substantially between HAI and systemic treatment groups. A recent randomized study in which 290 colorectal cancer patients were included also did not show significant differences in tumour response, progression-free survival and overall survival between patients who had received 5-FU/leucovorin either systemically or by HAI, while the HAI group reported a worse quality of life compared with the systemically treated group <sup>77</sup>. On the other hand Kemeny *et al* published a trial in 135 colorectal cancer patients and reported a significant survival benefit (median overall survival 24.4 vs. 20 months, P= 0.0034) and increased physical functioning in patients receiving HAI compared to systemic treatment <sup>78</sup>.

Recently several new drugs like for example oxaliplatin and irinotecan have been safely introduced in HAI <sup>79-84</sup>. Results of a phase I/II study on biweekly HAI with oxaliplatin combined with systemic 5-FU en leucovorin according to the de Gramont schedule were recently reported by Ducreux *et al* <sup>85</sup>. A total of 28 previously untreated patients with colorectal cancer with isolated liver metastases were treated with this schedule, the objective response rate was 64% and the median overall survival was 27 months. Grade 3 or 4 neutropenia occurred in 10 patients and there were two treatment related deaths. Compared to local ablative treatments HAI of chemotherapy can offer the additional benefit of both local and systemic disease control. In colorectal cancer liver metastases meta-analysis and recent randomized trials show conflicting results, but most trial designs did not allow for correct comparison of both treatment groups. Moreover, recent developments in new systemic drugs like oxaliplatin, irinotecan, bevacizumab and cetuximab/panitumumab have improved results substantially in the systemic treatment over liver metastases. If these agents have a role in HAI remains to be investigated.

### *Isolated hepatic perfusion*

Isolated hepatic perfusion (IHP) involves complete vascular isolation of the liver to allow local treatment of the liver. During this procedure the blood circulation of the liver is temporarily isolated from the systemic circulation. Inflow catheters are inserted in the common hepatic artery and the portal vein and an outflow catheter in the infrahepatic caval vein while the suprahepatic caval vein is occluded by a surgical clamp. Subse-

quently the catheters are connected to heart-lung machine and the anticancer drug is administered in this isolated circuit. Leakage to the systemic circulation is monitored in order to prevent high systemic exposure. After perfusion of the liver with the drug for a certain period of time (1 hour in most IHP trials) the liver is flushed with clean perfusate to wash out the anticancer drug after which the natural blood circulation is restored <sup>86</sup>.

The major advantage of IHP is the ability to treat the liver with drug levels that would be toxic when administered systemically <sup>86</sup>. Moreover, agents which cannot be administered systemically because of their toxicity, such as tumour necrosis factor alpha (TNF- $\alpha$ ), can be used in IHP <sup>87, 88</sup>. Furthermore, hyperthermia, which is known to improve the anti-cancer effect of several drugs, can be applied by heating the perfusate solution <sup>89</sup>.

Most experience with IHP has been obtained with colorectal liver metastases, but several studies have reported the treatment of uveal melanoma and neuroendocrine cancer liver metastases <sup>87, 88, 90-94</sup>. Various drugs have been used in IHP studies, including 5-FU, mitomycin C, cisplatin and melphalan with or without TNF- $\alpha$ . Usually mild hyperthermia is applied up to 40°C during IHP, although one study investigates the efficacy of hyperthermia alone (42-42.5°C). Recent clinical studies have mainly applied melphalan in IHP. Two large trials have been reported in colorectal cancer patients. Bartlett *et al* have reported IHP in 51 patients with different treatment schedules, including IHP with high doses of melphalan alone and moderately high doses of melphalan combined with TNF- $\alpha$  or followed by monthly hepatic intra-arterial infusion of FUDR and leucovorin <sup>94</sup>. Results of these studies show response rates up to 74%, a median time to progression up to 14.5 months and a median survival of 27 months. Rothbarth *et al* performed a phase I/II trial in 73 colorectal cancer patients with high dose melphalan, achieving an overall response rate of 59%, median time to progression of 7.7 months and a median overall survival of 28.8 months <sup>93</sup>. In uveal melanoma patients, IHP has resulted in response rates of 50-62%, with a median overall survival of 9.9-12 months <sup>87, 90, 92</sup>. The nature and incidence of major complications was similar in all trials independent of primary origin of liver metastases. Mortality rate varied between 2-5% and major complications consisted of bleeding and hepatotoxicity including veno-occlusive disease.

Melphalan has been the only agent applied in major clinical trials over the past 10 years. Over the past few years new agents like irinotecan, oxaliplatin and bevacizumab, have been introduced in the systemic treatment of colorectal metastases, increasing response rates, disease free survival and overall survival <sup>51-53, 95</sup>. Ideally some of the development in the systemic treatment of colorectal cancer metastases can be incorporated in isolated hepatic perfusion. Despite encouraging results in recent trials, IHP should still be considered an experimental treatment. No prospective trials have been reported



comparing IHP to either systemic treatment or local ablative treatment and little is known about the role of adjuvant systemic treatment. Whether IHP will eventually become a standard treatment option is highly dependent on the introduction of new drugs in order to further increase effectiveness, as recently shown for systemic treatment, and the development of new techniques with less mortality and improved responses.

### **Outline of this thesis**

The aim of this thesis was to study the role of IHP in the treatment of liver metastases and to evaluate possible improvements to IHP.

In chapter 2, IHP is evaluated as a treatment option for liver metastases from non-colorectal origin. In chapter 3, the safety and efficacy of a new drug administration in IHP through infusion is assessed. While in chapter 4, possible prognostic factors for IHP are identified to further improve patient selection. To establish the role of IHP, we compared IHP with systemic treatment in colorectal cancer patients with liver metastases only in chapter 5. Chapters 6 and 7 report the results of our efforts to introduce the new agent oxaliplatin as a possible drug in IHP for colorectal cancer liver metastases.

## References

1. Jessup JM, McGinnis LS, Steele GD, Jr., Menck HR, Winchester DP. The National Cancer Data Base. Report on colon cancer. *Cancer* 1996;78(4):918-926.
2. Weiss L, Grundmann E, Torhorst J et al. Haematogenous metastatic patterns in colonic carcinoma: an analysis of 1541 necropsies. *J Pathol* 1986;150(3):195-203.
3. Welch JP, Donaldson GA. The clinical correlation of an autopsy study of recurrent colorectal cancer. *Ann Surg* 1979;189(4):496-502.
4. Ihse I, Persson B, Tibblin S. Neuroendocrine metastases of the liver. *World J Surg* 1995;19(1):76-82.
5. Scheele J, Stang R, Altendorf-Hofmann A, Paul M. Resection of colorectal liver metastases. *World J Surg* 1995;19(1):59-71.
6. Bismuth H, Adam R, Levi F et al. Resection of nonresectable liver metastases from colorectal cancer after neoadjuvant chemotherapy. *Ann Surg* 1996;224(4):509-520.
7. Feliberti EC, Wagman LD. Radiofrequency ablation of liver metastases from colorectal carcinoma. *Cancer Control* 2006;13(1):48-51.
8. Bilchik AJ, Rose DM, Allegra DP, Bostick PJ, Hsueh E, Morton DL. Radiofrequency ablation: a minimally invasive technique with multiple applications. *Cancer J Sci Am* 1999;5(6):356-361.
9. Jiao LR, Hansen PD, Havlik R, Mitry RR, Pignatelli M, Habib N. Clinical short-term results of radiofrequency ablation in primary and secondary liver tumors. *Am J Surg* 1999;177(4):303-306.
10. Oshowo A, Gillams A, Harrison E, Lees WR, Taylor I. Comparison of resection and radiofrequency ablation for treatment of solitary colorectal liver metastases. *Br J Surg* 2003;90(10):1240-1243.
11. Parikh AA, Curley SA, Fornage BD, Ellis LM. Radiofrequency ablation of hepatic metastases. *Semin Oncol* 2002;29(2):168-182.
12. Scaife CL, Curley SA. Complication, local recurrence, and survival rates after radiofrequency ablation for hepatic malignancies. *Surg Oncol Clin N Am* 2003;12(1):243-255.
13. Wood TF, Rose DM, Chung M, Allegra DP, Foshag LJ, Bilchik AJ. Radiofrequency ablation of 231 unresectable hepatic tumors: indications, limitations, and complications. *Ann Surg Oncol* 2000;7(8):593-600.
14. Curley SA, Izzo F, Delrio P et al. Radiofrequency ablation of unresectable primary and metastatic hepatic malignancies: results in 123 patients. *Ann Surg* 1999;230(1):1-8.
15. Bilchik AJ, Wood TF, Allegra D et al. Cryosurgical ablation and radiofrequency ablation for unresectable hepatic malignant neoplasms: a proposed algorithm. *Arch Surg* 2000;135(6):657-662.
16. Bleicher RJ, Allegra DP, Nora DT, Wood TF, Foshag LJ, Bilchik AJ. Radiofrequency ablation in 447 complex unresectable liver tumors: lessons learned. *Ann Surg Oncol* 2003;10(1):52-58.
17. de Baere T, Elias D, Dromain C et al. Radiofrequency ablation of 100 hepatic metastases with a mean follow-up of more than 1 year. *AJR Am J Roentgenol* 2000;175(6):1619-1625.
18. Solbiati L, Livraghi T, Goldberg SN et al. Percutaneous radio-frequency ablation of hepatic metastases from colorectal cancer: long-term results in 117 patients. *Radiology* 2001;221(1):159-166.
19. Mulier S, Ni Y, Jamart J, Ruers T, Marchal G, Michel L. Local recurrence after hepatic radiofrequency coagulation: multivariate meta-analysis and review of contributing factors. *Ann Surg* 2005;242(2):158-171.
20. Kuvshinov BW, Ota DM. Radiofrequency ablation of liver tumors: influence of technique and tumor size. *Surgery* 2002;132(4):605-611.
21. Berber E, Pelley R, Siperstein AE. Predictors of survival after radiofrequency thermal ablation of colorectal cancer metastases to the liver: a prospective study. *J Clin Oncol* 2005;23(7):1358-1364.

22. Sutherland LM, Williams JA, Padbury RT, Gotley DC, Stokes B, Maddern GJ. Radiofrequency ablation of liver tumors: a systematic review. *Arch Surg* 2006;141(2):181-190.
23. Neeleman N, Wobbes T, Jager GJ, Ruers TJ. Cryosurgery as treatment modality for colorectal liver metastases. *Hepatogastroenterology* 2001;48(38):325-329.
24. Ruers TJ, Joosten J, Jager GJ, Wobbes T. Long-term results of treating hepatic colorectal metastases with cryosurgery. *Br J Surg* 2001;88(6):844-849.
25. Sheen AJ, Poston GJ, Sherlock DJ. Cryotherapeutic ablation of liver tumours. *Br J Surg* 2002;89(11):1396-1401.
26. Sotsky TK, Ravikumar TS. Cryotherapy in the treatment of liver metastases from colorectal cancer. *Semin Oncol* 2002;29(2):183-191.
27. Adam R, Hagopian EJ, Linhares M et al. A comparison of percutaneous cryosurgery and percutaneous radiofrequency for unresectable hepatic malignancies. *Arch Surg* 2002;137(12):1332-1339.
28. Tait IS, Yong SM, Cuschieri SA. Laparoscopic in situ ablation of liver cancer with cryotherapy and radiofrequency ablation. *Br J Surg* 2002;89(12):1613-1619.
29. Sigurdson ER, Ridge JA, Kemeny N, Daly JM. Tumor and liver drug uptake following hepatic artery and portal vein infusion. *J Clin Oncol* 1987;5(11):1836-1840.
30. Wang LQ, Persson BG, Stenram U, Bengmark S. Influence of portal branch ligation on the outcome of repeat dearterializations of an experimental liver tumor in the rat. *J Surg Oncol* 1994;55(4):229-234.
31. Hunt TM, Flowerdew AD, Birch SJ, Williams JD, Mullee MA, Taylor I. Prospective randomized controlled trial of hepatic arterial embolization or infusion chemotherapy with 5-fluorouracil and degradable starch microspheres for colorectal liver metastases. *Br J Surg* 1990;77(7):779-782.
32. Livraghi T, Giorgio A, Marin G et al. Hepatocellular carcinoma and cirrhosis in 746 patients: long-term results of percutaneous ethanol injection. *Radiology* 1995;197(1):101-108.
33. Amin Z, Bown SG, Lees WR. Local treatment of colorectal liver metastases: a comparison of interstitial laser photocoagulation (ILP) and percutaneous alcohol injection (PAI). *Clin Radiol* 1993;48(3):166-171.
34. Izzo F. Other thermal ablation techniques: microwave and interstitial laser ablation of liver tumors. *Ann Surg Oncol* 2003;10(5):491-497.
35. Shibata T, Niinobu T, Ogata N, Takami M. Microwave coagulation therapy for multiple hepatic metastases from colorectal carcinoma. *Cancer* 2000;89(2):276-284.
36. Seki T, Wakabayashi M, Nakagawa T et al. Percutaneous microwave coagulation therapy for solitary metastatic liver tumors from colorectal cancer: a pilot clinical study. *Am J Gastroenterol* 1999;94(2):322-327.
37. Mack MG, Straub R, Eichler K et al. Percutaneous MR imaging-guided laser-induced thermotherapy of hepatic metastases. *Abdom Imaging* 2001;26(4):369-374.
38. Mack MG, Straub R, Eichler K, Sollner O, Lehnert T, Vogl TJ. Breast cancer metastases in liver: laser-induced interstitial thermotherapy--local tumor control rate and survival data. *Radiology* 2004;233(2):400-409.
39. Vogl TJ, Straub R, Eichler K, Sollner O, Mack MG. Colorectal carcinoma metastases in liver: laser-induced interstitial thermotherapy--local tumor control rate and survival data. *Radiology* 2004;230(2):450-458.
40. Boyle RW, Dolphin D. Structure and biodistribution relationships of photodynamic sensitizers. *Photochem Photobiol* 1996;64(3):469-485.
41. Bugelski PJ, Porter CW, Dougherty TJ. Autoradiographic distribution of hematoporphyrin derivative in normal and tumor tissue of the mouse. *Cancer Res* 1981;41(11 Pt 1):4606-4612.

42. Fingar VH. Vascular effects of photodynamic therapy. *J Clin Laser Med Surg* 1996;14(5):323-328.
43. van Duijnhoven FH, Rovers JP, Engelmann K et al. Photodynamic therapy with 5,10,15,20-tetrakis(m-hydroxyphenyl) bacteriochlorin for colorectal liver metastases is safe and feasible: results from a phase I study. *Ann Surg Oncol* 2005;12(10):808-816.
44. Russell AH, Clyde C, Wasserman TH, Turner SS, Rotman M. Accelerated hyperfractionated hepatic irradiation in the management of patients with liver metastases: results of the RTOG dose escalating protocol. *Int J Radiat Oncol Biol Phys* 1993;27(1):117-123.
45. Gray B, Van Hazel G, Hope M et al. Randomised trial of SIR-Spheres plus chemotherapy vs. chemotherapy alone for treating patients with liver metastases from primary large bowel cancer. *Ann Oncol* 2001;12(12):1711-1720.
46. Blomgren H, Lax I, Naslund I, Svanstrom R. Stereotactic high dose fraction radiation therapy of extracranial tumors using an accelerator. Clinical experience of the first thirty-one patients. *Acta Oncol* 1995;34(6):861-870.
47. Herfarth KK, Debus J, Lohr F et al. Stereotactic single-dose radiation therapy of liver tumors: results of a phase I/II trial. *J Clin Oncol* 2001;19(1):164-170.
48. Van Cutsem E, Twelves C, Cassidy J et al. Oral capecitabine compared with intravenous fluorouracil plus leucovorin in patients with metastatic colorectal cancer: results of a large phase III study. *J Clin Oncol* 2001;19(21):4097-4106.
49. Bokemeyer C, Bondarenko I, Makhson A et al. Fluorouracil, leucovorin, and oxaliplatin with and without cetuximab in the first-line treatment of metastatic colorectal cancer. *J Clin Oncol* 2009;27(5):663-671.
50. Saltz LB, Clarke S, Diaz-Rubio E et al. Bevacizumab in combination with oxaliplatin-based chemotherapy as first-line therapy in metastatic colorectal cancer: a randomized phase III study. *J Clin Oncol* 2008;26(12):2013-2019.
51. de Gramont A, Figer A, Seymour M et al. Leucovorin and fluorouracil with or without oxaliplatin as first-line treatment in advanced colorectal cancer. *J Clin Oncol* 2000;18(16):2938-2947.
52. Tournigand C, Andre T, Achille E et al. FOLFIRI followed by FOLFOX6 or the reverse sequence in advanced colorectal cancer: A randomized GERCOR study. *Journal of Clinical Oncology* 2004;22(2):229-237.
53. Hurwitz H, Fehrenbacher L, Novotny W et al. Bevacizumab plus irinotecan, fluorouracil, and leucovorin for metastatic colorectal cancer. *New England Journal of Medicine* 2004;350(23):2335-2342.
54. Saltz LB, Cox JV, Blanke C et al. Irinotecan plus fluorouracil and leucovorin for metastatic colorectal cancer. Irinotecan Study Group. *N Engl J Med* 2000;343(13):905-914.
55. Cunningham D, Humblet Y, Siena S et al. Cetuximab monotherapy and cetuximab plus irinotecan in irinotecan-refractory metastatic colorectal cancer. *N Engl J Med* 2004;351(4):337-345.
56. Douillard JY, Cunningham D, Roth AD et al. Irinotecan combined with fluorouracil compared with fluorouracil alone as first-line treatment for metastatic colorectal cancer: a multicentre randomised trial. *Lancet* 2000;355(9209):1041-1047.
57. Cunningham D, Pyrhonen S, James RD et al. Randomised trial of irinotecan plus supportive care versus supportive care alone after fluorouracil failure for patients with metastatic colorectal cancer. *Lancet* 1998;352(9138):1413-1418.
58. Rougier P, Van Cutsem E, Bajetta E et al. Randomised trial of irinotecan versus fluorouracil by continuous infusion after fluorouracil failure in patients with metastatic colorectal cancer. *Lancet* 1998;352(9138):1407-1412.

59. Becouarn Y, Ychou M, Ducreux M et al. Phase II trial of oxaliplatin as first-line chemotherapy in metastatic colorectal cancer patients. Digestive Group of French Federation of Cancer Centers. *J Clin Oncol* 1998;16(8):2739-2744.
60. de Gramont A, Figer A, Seymour M et al. Leucovorin and fluorouracil with or without oxaliplatin as first-line treatment in advanced colorectal cancer. *J Clin Oncol* 2000;18(16):2938-2947.
61. Giacchetti S, Perpoint B, Zidani R et al. Phase III multicenter randomized trial of oxaliplatin added to chronomodulated fluorouracil-leucovorin as first-line treatment of metastatic colorectal cancer. *J Clin Oncol* 2000;18(1):136-147.
62. Koopman M, Antonini NF, Douma J et al. Sequential versus combination chemotherapy with capecitabine, irinotecan, and oxaliplatin in advanced colorectal cancer (CAIRO): a phase III randomised controlled trial. *Lancet* 2007;370(9582):135-142.
63. Hecht JR, Mitchell E, Chidiac T et al. A randomized phase III trial of chemotherapy, bevacizumab, and panitumumab compared with chemotherapy and bevacizumab alone for metastatic colorectal cancer. *J Clin Oncol* 2009;27(5):672-680.
64. Tol J, Koopman M, Cats A et al. Chemotherapy, bevacizumab, and cetuximab in metastatic colorectal cancer. *N Engl J Med* 2009;360(6):563-572.
65. Kemeny N, Daly J, Reichman B, Geller N, Botet J, Oderman P. Intrahepatic or systemic infusion of fluorodeoxyuridine in patients with liver metastases from colorectal carcinoma. A randomized trial. *Ann Intern Med* 1987;107(4):459-465.
66. Lorenz M, Muller HH. Randomized, multicenter trial of fluorouracil plus leucovorin administered either via hepatic arterial or intravenous infusion versus fluorodeoxyuridine administered via hepatic arterial infusion in patients with nonresectable liver metastases from colorectal carcinoma. *J Clin Oncol* 2000;18(2):243-254.
67. O'Connell MJ, Nagorney DM, Bernath AM et al. Sequential intrahepatic fluorodeoxyuridine and systemic fluorouracil plus leucovorin for the treatment of metastatic colorectal cancer confined to the liver. *J Clin Oncol* 1998;16(7):2528-2533.
68. Curley SA, Chase JL, Roh MS, Hohn DC. Technical considerations and complications associated with the placement of 180 implantable hepatic arterial infusion devices. *Surgery* 1993;114(5):928-935.
69. Daly JM, Kemeny N, Oderman P, Botet J. Long-term hepatic arterial infusion chemotherapy. Anatomic considerations, operative technique, and treatment morbidity. *Arch Surg* 1984;119(8):936-941.
70. Campbell KA, Burns RC, Sitzmann JV, Lipsett PA, Grochow LB, Niederhuber JE. Regional chemotherapy devices: effect of experience and anatomy on complications. *J Clin Oncol* 1993;11(5):822-826.
71. Burke D, Fordy C, Earlam SA, Allen-Mersh TG. Hepatic arterial cannulation for regional chemotherapy is safe in patients with a liver metastasis volume of less than 1 litre. *Br J Cancer* 1997;75(8):1213-1216.
72. Barber FD, Mavligit G, Kurzrock R. Hepatic arterial infusion chemotherapy for metastatic colorectal cancer: a concise overview. *Cancer Treat Rev* 2004;30(5):425-436.
73. Reappraisal of hepatic arterial infusion in the treatment of nonresectable liver metastases from colorectal cancer. Meta-Analysis Group in Cancer. *J Natl Cancer Inst* 1996;88(5):252-258.
74. Kemeny N, Seiter K, Niedzwiecki D et al. A randomized trial of intrahepatic infusion of fluorodeoxyuridine with dexamethasone versus fluorodeoxyuridine alone in the treatment of metastatic colorectal cancer. *Cancer* 1992;69(2):327-334.

75. Rougier P, Laplanche A, Huguier M et al. Hepatic arterial infusion of floxuridine in patients with liver metastases from colorectal carcinoma: long-term results of a prospective randomized trial. *J Clin Oncol* 1992;10(7):1112-1118.
76. Harmantas A, Rotstein LE, Langer B. Regional versus systemic chemotherapy in the treatment of colorectal carcinoma metastatic to the liver. Is there a survival difference? Meta-analysis of the published literature. *Cancer* 1996;78(8):1639-1645.
77. Kerr DJ, McArdle CS, Ledermann J et al. Intrahepatic arterial versus intravenous fluorouracil and folinic acid for colorectal cancer liver metastases: a multicentre randomised trial. *Lancet* 2003;361(9355):368-373.
78. Kemeny NE, Niedzwiecki D, Hollis DR et al. Hepatic arterial infusion versus systemic therapy for hepatic metastases from colorectal cancer: a randomized trial of efficacy, quality of life, and molecular markers (CALGB 9481). *J Clin Oncol* 2006;24(9):1395-1403.
79. Fiorentini G, Rossi S, Dentico P et al. Irinotecan hepatic arterial infusion chemotherapy for hepatic metastases from colorectal cancer: a phase II clinical study. *Tumori* 2003;89(4):382-384.
80. Fiorentini G, Lucchi SR, Giovanis P, Cantore M, Guadagni S, Papiiani G. Irinotecan hepatic arterial infusion chemotherapy for hepatic metastases from colorectal cancer: results of a phase I clinical study. *Tumori* 2001;87(6):388-390.
81. Fiorentini G, Rossi S, Dentico P et al. Oxaliplatin hepatic arterial infusion chemotherapy for hepatic metastases from colorectal cancer: a phase I-II clinical study. *Anticancer Res* 2004;24(3b):2093-2096.
82. Kern W, Beckert B, Lang N et al. Phase I and pharmacokinetic study of hepatic arterial infusion with oxaliplatin in combination with folinic acid and 5-fluorouracil in patients with hepatic metastases from colorectal cancer. *Ann Oncol* 2001;12(5):599-603.
83. Guthoff I, Lotspeich E, Fester C et al. Hepatic artery infusion using oxaliplatin in combination with 5-fluorouracil, folinic acid and mitomycin C: oxaliplatin pharmacokinetics and feasibility. *Anticancer Res* 2003;23(6D):5203-5208.
84. Mancuso A, Giuliani R, Accettura C et al. Hepatic arterial continuous infusion (HACI) of oxaliplatin in patients with unresectable liver metastases from colorectal cancer. *Anticancer Res* 2003;23(2C):1917-1922.
85. Ducreux M, Ychou M, Laplanche A et al. Hepatic arterial oxaliplatin infusion plus intravenous chemotherapy in colorectal cancer with inoperable hepatic metastases: a trial of the gastrointestinal group of the Federation Nationale des Centres de Lutte Contre le Cancer. *J Clin Oncol* 2005;23(22):4881-4887.
86. Vahrmeijer AL, van Dierendonck JH, Keizer HJ et al. Increased local cytostatic drug exposure by isolated hepatic perfusion: a phase I clinical and pharmacologic evaluation of treatment with high dose melphalan in patients with colorectal cancer confined to the liver. *Br J Cancer* 2000;82(9):1539-1546.
87. Alexander HR, Libutti SK, Bartlett DL, Puhlmann M, Fraker DL, Bachenheimer LC. A phase I-II study of isolated hepatic perfusion using melphalan with or without tumor necrosis factor for patients with ocular melanoma metastatic to liver. *Clin Cancer Res* 2000;6(8):3062-3070.
88. Alexander HR, Jr., Bartlett DL, Libutti SK, Fraker DL, Moser T, Rosenberg SA. Isolated hepatic perfusion with tumor necrosis factor and melphalan for unresectable cancers confined to the liver. *J Clin Oncol* 1998;16(4):1479-1489.
89. van der ZJ, Kroon BB, Nieweg OE, van de Merwe SA, Kampinga HH. Rationale for different approaches to combined melphalan and hyperthermia in regional isolated perfusion. *Eur J Cancer* 1997;33(10):1546-1550.

90. Alexander HR, Jr., Libutti SK, Pingpank JF et al. Hyperthermic isolated hepatic perfusion using melphalan for patients with ocular melanoma metastatic to liver. *Clin Cancer Res* 2003;9(17):6343-6349.
91. Grover AC, Libutti SK, Pingpank JF, Helsabeck C, Beresnev T, Alexander HR, Jr. Isolated hepatic perfusion for the treatment of patients with advanced liver metastases from pancreatic and gastrointestinal neuroendocrine neoplasms. *Surgery* 2004;136(6):1176-1182.
92. Noter SL, Rothbarth J, Pijl ME et al. Isolated hepatic perfusion with high-dose melphalan for the treatment of uveal melanoma metastases confined to the liver. *Melanoma Res* 2004;14(1):67-72.
93. Rothbarth J, Pijl ME, Vahrmeijer AL et al. Isolated hepatic perfusion with high-dose melphalan for the treatment of colorectal metastasis confined to the liver. *Br J Surg* 2003;90(11):1391-1397.
94. Bartlett DL, Libutti SK, Figg WD, Fraker DL, Alexander HR. Isolated hepatic perfusion for unresectable hepatic metastases from colorectal cancer. *Surgery* 2001;129(2):176-187.
95. Douillard JY. Irinotecan and high-dose fluorouracil/leucovorin for metastatic colorectal cancer. *Oncology (Williston Park)* 2000;14(12 Suppl 14):51-55.

---

# CHAPTER 2

## Isolated hepatic perfusion with 200 mg melphalan for advanced noncolorectal liver metastases

Liselot B.J. van Iersel<sup>1</sup>, Ellen J. Hoekman<sup>1</sup>, Hans Gelderblom<sup>1</sup>,  
Alexander L. Vahrmeijer<sup>2</sup>, Els L. van Persijn van Meerten<sup>3</sup>,  
Fred G.J. Tijl<sup>4</sup>, Henk H. Hartgrink<sup>2</sup>, Peter J.K. Kuppen<sup>2</sup>,  
Johan W.R. Nortier<sup>1</sup>, Rob A.E.M. Tollenaar<sup>2</sup>  
and Cornelis J.H. van de Velde<sup>2</sup>

Department of Clinical Oncology<sup>1</sup>, Surgery<sup>2</sup>, Radiology<sup>3</sup> and  
Extra Corporal Circulation<sup>4</sup> Leiden University Medical Center,  
Albinusdreef 2, 2333 ZA Leiden, The Netherlands

*Ann Surg Oncol.* 2008 Jul;15(7):1891-8

---



## Abstract

The liver is one of the most common sites for metastatic solid tumours. If the liver is the only site of metastatic disease, regional treatment options can offer the benefit of high local exposure with limited systemic toxicity, especially for patients without (further) systemic treatment options. We report the results of our experience with isolated hepatic perfusion (IHP) in patients with isolated liver metastases from a variety of primary tumours.

Nineteen patients with isolated unresectable liver metastases from a variety of tumours (13 uveal melanomas, 2 neuroendocrine carcinomas, 2 gastrointestinal stromal tumours, 1 hepatocellular carcinoma and 1 high grade sarcoma) were treated with a 60-minute IHP using 200 mg melphalan. Patients were monitored for toxicity, response according to RECIST criteria and survival.

One melanoma patient was not perfused due to insufficient isolation of the liver. There was no treatment-related mortality. Reversible grade 3 to 4 hepatotoxicity occurred in 10 (56%) patients, while veno-occlusive disease occurred in 4 (22%) patients. Of the twelve uveal melanoma patients who were perfused, 4 (33%) patients had a partial hepatic response, 6 (50%) patients had stable hepatic disease and 2 (17%) patients were immediately progressive. Median disease-free survival was 6.6 months with a median overall survival of 10.0 months. Fifty percent of other primary tumours showed at least partial remission, including 1 complete remission in a high grade sarcoma patient.

IHP with melphalan shows activity in patients with liver metastases from a variety of primary tumours, but other or additional drugs may improve therapeutical outcome.

## Introduction

The liver is one of the most common sites for metastatic disease and is involved in approximately 40% of adult patients with primary extrahepatic malignant disease who undergo an autopsy. The most common origin of hepatic metastasis confined to the liver is colorectal cancer. Neuroendocrine tumours and uveal melanomas, although rare, are the second most common origin of metastases confined to the liver<sup>1</sup>. Gastrointestinal neuroendocrine tumours are predominantly carcinoids (55%), consisting mainly of midgut carcinoids (50-70%) which have the greatest potential for metastasizing to the liver<sup>2,3</sup>. Uveal melanoma is the most common primary intraocular tumour in adults, with an incidence of 5-7 per 1 million per year in the Western population<sup>4</sup>. Nearly up to 50% of patients will ultimately develop metastases, of which more than 60% is confined to the liver<sup>5,6</sup>. Other primary tumours that may initially metastasize exclusively to the liver include gastrointestinal stromal tumours (GIST) and even more rarely renal cell carcinoma, Wilms' tumour and breast cancer. Although liver metastases from primary tumours such as cancers of the lung, breast, stomach and cutaneous melanoma may occur more frequently, dissemination usually occurs simultaneously to other visceral locations.

If the metastases are confined to the liver several locoregional treatment options can be considered, including partial hepatic resection, radiofrequency ablation (RFA), administration of chemotherapy by hepatic artery infusion (HAI) and isolated hepatic perfusion (IHP) with high dose chemotherapy. Curative resection is possible in only a small fraction of patients due to the number, location or size of the metastases<sup>7,8</sup>. RFA is mainly suitable for patients with a limited number of liver metastases that are not located near any large vascular structures and less than 5cm in diameter<sup>9-11</sup>. Compared to HAI, IHP offers the benefits of high local drug exposure with limited systemic toxicity<sup>12</sup>. Various studies have been published on IHP for colorectal liver metastases<sup>13-15</sup>, but only a few studies have been reported on IHP for liver metastases from other primary tumours<sup>16-20</sup>.

In this study we present our experience with 19 patients with a variety of primary tumours other than colorectal cancer, including uveal melanoma, high grade sarcoma and GIST, who underwent IHP at the Leiden University Medical Center.

## Patients and methods

### Patient Eligibility

Between May 1995 and May 2006, 19 patients with liver metastases of uveal melanoma (13), GIST (2), hepatocellular carcinoma (1), neuroendocrine carcinoma (2) and high grade sarcoma (1) were treated with IHP with 200mg melphalan according to a study protocol approved by the local ethics committee. Using the same melphalan dose, during the accrual period, IHP was performed in 105 patients with colorectal cancer hepatic metastases<sup>13,15,21</sup>, indicating feasibility and our experience with this procedure. Informed consent was obtained from all patients. The tumour response of 8 uveal melanoma patients has been previously reported<sup>16</sup>. Eligibility criteria included a WHO performance status of 0 or 1, leukocyte count  $\geq 3.0 \times 10^9/L$ , platelet count  $\geq 100 \times 10^9/L$ , maximum serum creatinine level 135  $\mu\text{mol/L}$ , maximum bilirubin level 17  $\mu\text{mol/L}$  and minimum albumin level 40 g/L. Exclusion criteria were age over 70 years, life expectancy of less than 4 months, more than 60 percent hepatic replacement by tumour tissue as estimated from the preoperative abdominal CT scan, coagulation disorders and evidence of extrahepatic metastatic disease. All patients had a preoperative chest and abdominal computer tomography (CT), full blood count, liver function tests, and determination of lactate dehydrogenase, albumin and creatinine and electrolytes.

### IHP technique

Briefly, the liver was mobilized from the diaphragm through a transverse abdominal incision. The common hepatic artery (8-Fr 77008 one-piece pediatric arterial cannula; Medtronic, Minneapolis, Minnesota, USA) and the portal vein (12-Fr perfex perfusion catheter CH12; B. Braun Medical, Oss, The Netherlands) were cannulated and connected to a heart-lung machine which consisted of two independent roller pumps (model 10-30-00; Cobe/Stöckert, Munich, Germany). For 14 patients both the hepatic artery and portal vein were used for inflow of melphalan in the isolated circuit, because this technique was used in our previously reported phase I<sup>15</sup> and II<sup>13</sup> study. Although there is no established benefit from drug delivery by using the portal vein during our IHP procedure oxygenated blood is perfused through the portal vein and this may possibly prevent hypoxia induced damage to the liver. Moreover, by using our technique, the MTD of melphalan is much higher than reported by other groups who only used the hepatic artery for drug delivery. For 5 patients we used hepatic artery infusion at reduced flow as reported in a recent publication<sup>22</sup>. The inferior vena cava (IVC) was cross-clamped above the hepatic veins and cannulated proximal of the renal veins (Polystan 36 Fr, straight, A/S, Værlöse, Denmark) to allow undisturbed blood flow from the hepatic veins through

the IVC towards the heart-lung machine. To isolate the hepatic circuit, tourniquets were secured around the hepatic artery, portal vein and IVC.

For the extracorporeal venovenous bypass, the right femoral vein (22-Fr cannula DI-ITF022L; Edwards Lifesciences, Irvine, California, USA) and the portal vein (17-Fr perfex perfusion catheter CH17; B. Braun) (proximal to the tourniquet) were cannulated and connected to the right axillary vein (18-Fr 7326 perfusion cannula; Lifestream International, The Woodlands, Texas, USA). The venovenous bypass was supported by a centrifugal pump (Medtronic BIO-Medicus, Eden Prairie, Minnesota, USA) and primed with 700 mL 0.9 % saline. The perfusion medium consisted of intrahepatically trapped blood and 1250 mL Gelofusine® (Vifor Medical, Sempach, Switzerland) plus 2500 units heparin (Leo Pharma, Breda, The Netherlands) to yield a final volume of approximately 2 litres. Throughout the 1-h perfusion interval, the perfusate was kept at a temperature of 39.5 °C by a heat exchanger and oxygenated using an oxygenator (Cobe VPCML; Cobe Cardiovascular, Arvada, Colorado, USA) except for the last 3 patients who were oxygenated using a different oxygenator (Dideco D901, SORIN group Italia, Mirandola, Italy). After perfusion, the liver was flushed for approximately 10 minutes with 3 liters Gelofusine®. All cannulas and clamps were removed, and the incisions were closed. To prevent possible melphalan induced cholecystitis, cholecystectomy was performed.

## Melphalan

Melphalan 200mg (Alkeran®, GlaxoSmithKline, Zeist, The Netherlands) was first dissolved in 40 mL Wellcome Diluent (a 60/40 (v/v) mixture of proylene glycol containing 5.2% (v/v) ethanol and 0.068 mol/l sodium citrate), which was subsequently diluted with 60 mL sterile saline. Melphalan was administered as a bolus in the isolated hepatic circuit (13,15) and in the last 5 patients through 20 minute infusion using an infusion pump (Pilote Anesthesie; Fresenius, Brezins, France) connected to the hepatic artery line of the isolated hepatic circuit<sup>22</sup>.

## Leakage Detection

Leakage of perfusate into the systemic circuit was monitored by adding 10 MBq <sup>99m</sup>Tc-pertechnetate to the isolated circuit with subsequent measurement of the level of radioactivity in both the systemic and isolated circuit, as described previously<sup>23,24</sup>. If no leakage was detected, melphalan was administered: If leakage was calculated to exceed 10% during the perfusion period, the procedure was stopped and the liver was flushed just before this level was reached.

## **Postoperative Care**

All patients received a daily subcutaneous dose of 480 µg granulocyte colony-stimulating factor (G-CSF) (Filgrastim/Neupogen®; Amgen, Breda, The Netherlands) starting the day after the operation until the nadir in leukocyte count was reached and the count had risen to more than  $1.0 \times 10^9/L$ . Patients were monitored in the intensive care unit for at least 1 day after IHP. Liver and renal function tests and full blood counts were carried out daily in the first week and henceforth as indicated by their respective levels. Antibiotics in a combination of cefuroxim and metronidazol were given to all patients for 5 days after IHP.

## **Toxicity**

Systemic and regional toxicity data were collected prospectively and graded retrospectively according to the National Cancer Institute Common Toxicity Criteria version 2.0. Hepatic toxicities were considered melphalan related if elevations in liver function persisted beyond 7 days after perfusion, as previously suggested<sup>25</sup>.

## **Response evaluation**

Objective tumour response measurements were obtained by follow up CT scans of the liver and remaining abdomen at 3-month intervals after treatment and at 6-month intervals after 1 year. Additional imaging was performed if clinically indicated. All Ct scans were revised using RECIST criteria to determine response rates. For the RECIST criteria lesions were only considered measurable if  $\geq 10\text{mm}$ , complete response was defined as disappearance of all known disease, partial response as a reduction in the sum of maximal diameters of  $\geq 30\%$ , stable disease as a reduction of  $<30\%$  or an increase of  $<20\%$  and progressive disease as an increase of  $\geq 20\%$  or the appearance of new intra- or extrahepatic lesions<sup>26</sup>. Disease-free survival was calculated from the date of IHP until the date of local and/or systemic recurrence or death from any cause.

## **Statistical analysis**

All data were analysed with SPSS statistical software (version 14.0. for Windows, SPSS, Chicago, IL, USA). The analyses of time to progression and survival were carried out by the Kaplan–Meier method. If patients died before hepatic progression had occurred, date of death was taken as date of progression.

## Results

### Patient and treatment characteristics

Patient and tumour characteristics are listed in Table 1. A total of 19 patients with unresectable liver disease and no evidence of extrahepatic disease were considered eligible for IHP. Thirteen patients presented with an uveal melanoma as primary tumour, 2 patients with a GIST, 2 patients with a neuroendocrine carcinoma, 1 patient with a hepatocellular carcinoma (HCC) and 1 patient with a high grade sarcoma. Sixteen patients presented with metachronous liver metastases. The mean number of liver metastases was 24 (range 1 to >100) with a mean estimated hepatic replacement of 23% (range 5% to 50%). Mean time from diagnosis of liver metastases to IHP was 4.3 months (range 0.7 to 13.7 months). Five patients received chemotherapy prior to IHP.

All 19 patients underwent IHP, but in 1 patient the procedure failed due to failure to obtain sufficient isolation of the liver and this patient was excluded from further analyses. Treatment characteristics of the remaining 18 patients are similar to our previous experience with colorectal cancer patients and are listed in Table 2<sup>13</sup>. The median operating time was 8 hours and 7 minutes, with a median blood loss of 3.5 liters (range 1-8 L). The median hospital stay was 11 days (range 7-25 days). Median follow up was 74 months (range 4 to 137 months).

**Table 1** Patient and tumour characteristics

Characteristic	n (%)
No. of patients	19
Sex	
Male	6 (32)
Female	13 (68)
Primary tumour	
Uveal melanoma	13
Neuroendocrine tumour	2
GIST	2
HCC	1
High grade sarcoma	1
Median age in years [range]	51.4 [29 to 69]
Liver metastases	
Synchronous	3 (15.8)
Metachronous	16 (84.2)
Mean % of hepatic replacement [range]	23.4 [5 to 50]
Median no. of metastases [range]	12 [1 to >100]
Median time of diagnoses of hepatic metastases to IHP	2 [0.7 to 13.7]

**Table 2** Treatment parameters

Parameter	Mean $\pm$ SD
Flow rate hepatic artery (mL/min)	290.4 $\pm$ 100
Flow rate portal vein (mL/min)	230.8 $\pm$ 97.3
Pressure hepatic artery (mm/Hg)	118.1 $\pm$ 24.6
Pressure portal vein (mm/Hg)	36.5 $\pm$ 9.3
Percentage leakage during perfusion	2.6 $\pm$ 4.9
Blood loss (L)	3.9 $\pm$ 2
Operative time (hr)	8.9 $\pm$ 1.3
Hospital stay (days)	12.7 $\pm$ 4.8

### Toxicity and complications

Ten patients experienced grade 3-4 toxicity of one or more liver enzymes one week after IHP as shown in Table 3. This hepatotoxicity was transient and only persisted in the 4 patients that developed veno-occlusive disease (VOD). Major complications occurred in 5 patients; as previously mentioned, 4 patients developed signs of VOD and 1 other patient experienced a lung embolism. Neutropenia was rare and no neutropenic infections occurred. Give the low leakage rate G-CSF, which was common practice since early development of this procedure in phase I, is deemed unnecessary in future patients. All patients left the hospital within 4 weeks.

### Tumour response, progression-free and overall survival

The patients with uveal melanoma and the patients with liver metastases from other primary tumours were analyzed separately. The details on tumour responses, progression-free survival and overall survival details of the 6 patients with primary tumours

**Table 3** Toxicity according to National Cancer Institute Common Toxicity Criteria version 2.0 ( $n=18$ )

	Grade 0	Grade 1	Grade 2	Grade 3	Grade 4
Leukocyte nadir	63.2% (12)	10.5% (2)	5.3% (1)	5.3% (1)	10.5% (2)
Bilirubin	23.3% (5)	21.1% (4)	36.8% (7)	0% (0)	10.5% (2)
Alkaline phosphatase	5.3% (1)	42.1% (8)	21.1% (4)	26.3% (5)	0% (0)
ALAT	15.8% (3)	26.3% (5)	26.3% (5)	21.1% (4)	5.3% (1)
ASAT	5.3% (1)	42.1% (8)	21.1% (4)	21.1% (4)	5.3% (2)

other than uveal melanoma are given in Table 4. The high grade sarcoma patient had a complete response for 27.1 months while 1 neuroendocrine tumor patient had a partial response for 33.4 months and was still alive at the end of follow up.

Of the 12 uveal melanoma patients, 4 (33%) patients had a partial hepatic response, 6 (50%) patients had prolonged stable hepatic disease and 2 (17%) patients were immediately progressive. Progressive disease occurred in all patients during follow up. Six (50%) patients had hepatic progression, 3 (25%) had extrahepatic progression and 3 (25%) were both hepatic and extrahepatic progressive. Progression-free and overall survival curves for uveal melanoma patients are shown in Figure 1. The median time to hepatic progression was 8.2 months (range 1.7 to 17.1 months), while median time to overall progression after IHP was 6.6 months (range 1.7 to 17.1 months). All but 1 patient died during follow up. The median overall survival after IHP was 10 months (range 4.8 to 47.6 months), with a median overall survival from diagnosis of liver metastasis of 12.2 months (range 8.7 to 49.6 months).

## Discussion

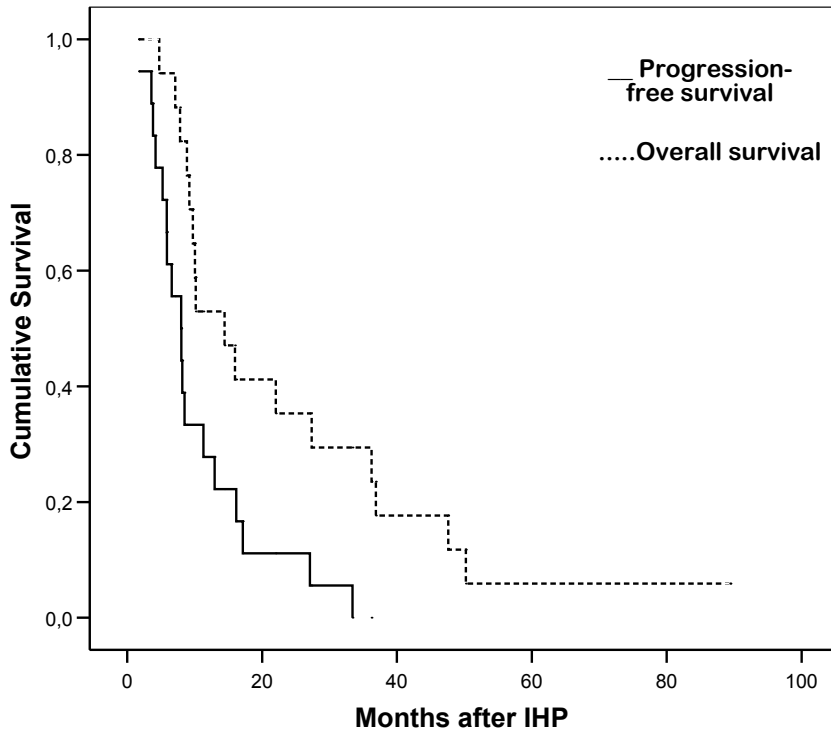
This study shows that IHP with 200mg melphalan shows activity in patients with liver metastases of primary tumours other than colorectal cancer. Transient grade 3 to 4 hepatotoxicity was observed in 56% of patients, similar to the results of previous studies <sup>19</sup>.

**Table 4** Treatment results of IHP with 200mg melphalan in patients with isolated liver metastases of primary tumours other than uveal melanoma

Patient	Primary tumour	Hepatic response	Location progression	Time to progression (months)	Overall survival after IHP (months)	Survival after diagnosis of liver metastases (months)
1	Neuroendocrine tumour	Stable disease	Extrahepatic	5.9	8.9	18
2	Neuroendocrine tumour (carcinoid)	Partial remission	Extrahepatic	33.4	89.4 <sup>a</sup>	95.3 <sup>a</sup>
3	GIST	Stable disease	Extrahepatic	8	36.2	36.9
4	GIST	Stable disease	Hepatic	13	22	23.8
5	HCC	Partial remission	Hepatic	5.9	14.4	26.8
6	High grade sarcoma	Complete remission	Both	27.1	50.2	52

<sup>a</sup> Patient was still alive at the end of follow up. Data is censored at the end of follow up.





**Fig. 1.** Overall and progression-free survival curves for uveal melanoma patients. Of the 13 uveal melanoma patients, 12 patients were treated with IHP and included in the progression-free and overall survival analysis.

<sup>27</sup>. The incidence of VOD (4/18) was relatively high compared to the results in colorectal cancer patients. VOD is thought to result from cumulative exposure to chemotherapeutic agents, but only 5 patients in this study received chemotherapy prior to IHP and none of them developed VOD <sup>28</sup>. The patients with VOD showed similar characteristics as compared to the patients without VOD, except for the fact that the incidence of VOD was higher (2 out of 5) in the patients treated with hepatic artery infusion at reduced flow, a technique that was recently abandoned by us because of limited response rates and hepatotoxicity . This leaves 3 VODs out of 13 patients treated with with melphalan through hepatic artery and portal vein inflow, which is considered acceptable toxicity. Of note, 5% underwent a major laparotomy, but could not be perfused: this was due to extrahepatic disease that was not observed on CT-scanning. In order to reduce the incidence of unexpected extrahepatic disease on laparotomy, optimal staging with PET-scanning is being introduced in future patients. Response rates, disease-free and overall survival remain difficult to interpret due to small numbers and should be evaluated in view of the lack of other treatment options in patients with the tumours that were included in this study.

For the treatment of metastatic uveal melanoma no standard systemic agent currently exists. Several studies have reported response rates of less than 10% to conventional systemic chemotherapy<sup>29,30</sup>. Results with immunotherapy, as for example interferon- $\alpha$  and interleukin-2, are equally disappointing with no or only minor responses<sup>31,32</sup>. Peters *et al* reported the use of HAI with fotemustine, an alkylating agent, in 101 uveal melanoma patients with liver metastases<sup>33</sup>. Fotemustine was infused in the hepatic artery for a 4-week induction period followed by a maintenance treatment every three weeks until disease progression. A median of 8 infusions per patient were delivered. Catheter related complications occurred in 23% of patients. The overall response rate was 36%, with a median overall survival of 15 months and a 2-year survival rate of 29%. Although the response rate of fotemustine infusion is similar to our results with IHP in uveal melanoma patients, the overall survival of 15 months seems superior to our observed 10 months. The difference could be explained by a difference in hepatic tumour load, but numbers estimating the tumour burden are not reported. The improved survival could also be attributed to the combination with debulking surgery in 38 patients undergoing HAI with fotemustine.

Alexander *et al* reported the results of IHP with 1.5mg/kg melphalan in 29 uveal melanoma patients. Hepatic response rate was 62% with a progression-free survival of 8 months and an overall survival of 12.1 months. In our patients the response rate was less; only 33%, but 50% of patients did show stable disease with a median time to progression of 6.6 months and an overall survival of 10 months similar to the results of Alexander *et al*. Although these results may seem disappointing as compared to IHP in other primary tumors, there is a survival benefit compared to a median survival of 2 months in uveal melanoma patients with liver metastases without antitumour treatment<sup>34</sup>. Moreover, currently we have no accepted alternative treatment options for uveal melanoma patients with irresectable isolated liver metastases.

Treatment of neuroendocrine liver metastases is aimed at improvement of the hormonal symptoms through reduction of tumour burden. Results of systemically administered agents have been disappointing in neuroendocrine cancer metastases with response rates around 6-40% for cytostatic drugs and 11% for interferon- $\alpha$ <sup>35-38</sup>. Symptomatic improvement can be achieved in up to 70% of patients with somatostatin analogs such as octreotide, but objective tumour response occurs in less than 10% and drug resistance can develop in 3-12 months<sup>39-42</sup>. Recently attention has shifted to the development of radiolabeled somatostatin analogs. Valkema *et al* reported the response after peptide receptor radionuclide therapy with [<sup>90</sup>Y-DOTA<sup>0</sup>, Tyr<sup>3</sup>] octreotide in 56 patients with advanced neuroendocrine tumours<sup>43</sup>. Overall, 58% of patients experienced improvement of symptoms, the median progression free survival was 29 months with a median overall

survival of nearly 37 months. Several studies have been reported on the use of RFA for neuroendocrine liver metastases<sup>44-46</sup>. In the largest published study the laparoscopic ablation of 234 hepatic lesions in 34 patients is reported<sup>47</sup>. Symptoms were relieved in 95% of the patients, with a significant or complete symptom control in 80% of them for a mean duration of 10 months. New liver metastases developed in 28% of these patients, new extrahepatic disease in 25% and local liver recurrence in 13%, at a mean follow-up of 1.6 years. Grover *et al* reported an overall response rate of 50% with IHP in 13 neuroendocrine tumours with a median progression free survival of 7 months<sup>17</sup>. Although we treated only two patients with neuroendocrine tumours, one patient with a carcinoid showed a partial response for 33.4 months. In neuroendocrine carcinoid tumours caution should be taken to block hormone secretion, because systemic complications have been reported during RFA of carcinoids<sup>48</sup>.

Imatinib has become the standard first line systemic treatment for advanced GIST. GISTs have characteristic gain-of-function mutations in the KIT-oncogene that results in overexpression of the KIT-protein (CD117)<sup>49</sup>. Imatinib is a potent, specific KIT/PDGFR-small molecule tyrosine kinase inhibitor with a patient benefit rate (prolonged stable disease and response) of up to 90% and median progression free survival of 2,5-3years<sup>50, 51</sup>. Second-line treatment with sunitinib, an oral multitargeted receptor tyrosine kinase inhibitor, can add a median of 8 months in about 60% of patients<sup>52</sup>. Before the imatinib/sunitinib era no systemic treatment options existed for metastatic GIST. Hepatic arterial chemoembolization was one of the options for patients with hepatic metastasis derived from GIST resulting in a mean survival of 9,5- 11.4 months.<sup>53, 54</sup> The addition of RFA to transcatheter arterial chemoembolization could increase survival to up to 25 months<sup>55</sup>. To our knowledge there have been no reports published on IHP for GIST. In our study two patients with GIST were included and showed stable disease with a disease-free survival of 8 and 13 months respectively and an overall survival of 36.2 and 22 months respectively. Both patients were treated prior to the imatinib/sunitinib-era. The above mentioned local treatment options, including IHP, can thus be considered in patients refractory to imatinib and sunitinib with progressive liver lesions without further extrahepatic progression.

In recent studies with IHP, melphalan with or without TNF- $\alpha$ , has been the only chemotherapeutic agent used. Melphalan is an alkylating-agent that is mainly used in the systemic treatment for multiple myeloma, isolated limb, lung and liver perfusion. Little is known about the effectiveness of systemic melphalan treatment in the tumours described above. If IHP is considered as serious treatment option for patients with a variety of primary tumours other tumour-specific agents need to be studied to improve tumour response. Ideally, tumour-specific IHP agents should be developed. A wide range of

agents is possible because, for example IHP offers the additional advantage that as long as agents are specific to the tissue of origin of the primary tumour, they do not have to differentiate between malignant and healthy tissue due to the local exposure in the liver.

In conclusion, IHP appears to be feasible in patients with liver metastases from a variety of primary tumours. To improve responses in IHP, the role of new agents tailored to specific tumour types needs to be assessed.

## References

1. Sutcliffe R, Maguire D, Ramage J, Rela M, Heaton N. Management of neuroendocrine liver metastases. *Am J Surg* 2004;187(1):39-46.
2. Shebani KO, Soubra WW, Finkelstein DM et al. Prognosis and survival in patients with gastrointestinal tract carcinoid tumors. *Ann Surg* 1999;229(6):815-821.
3. MOERTEL CG, SAUER WG, DOCKERTY MB, BAGGENSTOSS AH. Life history of the carcinoid tumor of the small intestine. *Cancer* 1961;14:901-912.
4. Egan KM, Seddon JM, Glynn RJ, Gragoudas ES, Albert DM. Epidemiologic aspects of uveal melanoma. *Surv Ophthalmol* 1988;32(4):239-251.
5. Rajpal S, Moore R, Karakousis CP. Survival in metastatic ocular melanoma. *Cancer* 1983;52(2):334-336.
6. Assessment of metastatic disease status at death in 435 patients with large choroidal melanoma in the Collaborative Ocular Melanoma Study (COMS): COMS report no. 15. *Arch Ophthalmol* 2001;119(5):670-676.
7. Ihse I, Persson B, Tibblin S. Neuroendocrine metastases of the liver. *World J Surg* 1995;19(1):76-82.
8. Scheele J, Stang R, Altendorf-Hofmann A, Paul M. Resection of colorectal liver metastases. *World J Surg* 1995;19(1):59-71.
9. Solbiati L, Livraghi T, Goldberg SN et al. Percutaneous radio-frequency ablation of hepatic metastases from colorectal cancer: long-term results in 117 patients. *Radiology* 2001;221(1):159-166.
10. Berber E, Pelley R, Siperstein AE. Predictors of survival after radiofrequency thermal ablation of colorectal cancer metastases to the liver: a prospective study. *J Clin Oncol* 2005;23(7):1358-1364.
11. Sutherland LM, Williams JA, Padbury RT, Gotley DC, Stokes B, Maddern GJ. Radiofrequency ablation of liver tumors: a systematic review. *Arch Surg* 2006;141(2):181-190.
12. Marinelli A, van de Velde CJ, Kuppen PJ, Franken HC, Souverijn JH, Eggermont AM. A comparative study of isolated liver perfusion versus hepatic artery infusion with mitomycin C in rats. *Br J Cancer* 1990;62(6):891-896.
13. Rothbarth J, Pijl ME, Vahrmeijer AL et al. Isolated hepatic perfusion with high-dose melphalan for the treatment of colorectal metastasis confined to the liver. *Br J Surg* 2003;90(11):1391-1397.
14. Alexander HR, Libutti SK, Bartlett DL, Puhlmann M, Fraker DL, Bachenheimer LC. A phase I-II study of isolated hepatic perfusion using melphalan with or without tumor necrosis factor for patients with ocular melanoma metastatic to liver. *Clin Cancer Res* 2000;6(8):3062-3070.
15. Vahrmeijer AL, van Dierendonck JH, Keizer HJ et al. Increased local cytostatic drug exposure by isolated hepatic perfusion: a phase I clinical and pharmacologic evaluation of treatment with high dose melphalan in patients with colorectal cancer confined to the liver. *Br J Cancer* 2000;82(9):1539-1546.
16. Noter SL, Rothbarth J, Pijl ME et al. Isolated hepatic perfusion with high-dose melphalan for the treatment of uveal melanoma metastases confined to the liver. *Melanoma Res* 2004;14(1):67-72.
17. Grover AC, Libutti SK, Pingpank JF, Helsabeck C, Beresnev T, Alexander HR, Jr. Isolated hepatic perfusion for the treatment of patients with advanced liver metastases from pancreatic and gastrointestinal neuroendocrine neoplasms. *Surgery* 2004;136(6):1176-1182.
18. Feldman ED, Wu PC, Beresneva T et al. Treatment of patients with unresectable primary hepatic malignancies using hyperthermic isolated hepatic perfusion. *J Gastrointest Surg* 2004;8(2):200-207.
19. Alexander HR, Jr., Libutti SK, Pingpank JF et al. Hyperthermic isolated hepatic perfusion using melphalan for patients with ocular melanoma metastatic to liver. *Clin Cancer Res* 2003;9(17):6343-6349.

20. Alexander HR, Libutti SK, Bartlett DL, Puhlmann M, Fraker DL, Bachenheimer LC. A phase I-II study of isolated hepatic perfusion using melphalan with or without tumor necrosis factor for patients with ocular melanoma metastatic to liver. *Clin Cancer Res* 2000;6(8):3062-3070.
21. van Iersel LB, Gelderblom H, Vahrmeijer AL et al. Isolated hepatic melphalan perfusion of colorectal liver metastases: outcome and prognostic factors in 154 patients. *Ann Oncol* 2008.
22. van Iersel LB, Verlaan MR, Vahrmeijer AL et al. Hepatic artery infusion of high-dose melphalan at reduced flow during isolated hepatic perfusion for the treatment of colorectal metastases confined to the liver: a clinical and pharmacologic evaluation. *Eur J Surg Oncol* 2007;33(7):874-881.
23. Marinelli A, de Brauw LM, Beerman H et al. Isolated liver perfusion with mitomycin C in the treatment of colorectal cancer metastases confined to the liver. *Jpn J Clin Oncol* 1996;26(5):341-350.
24. Runia RD, de Brauw LM, Kothuis BJ, Pauwels EK, van de Velde CJ. Continuous measurement of leakage during isolated liver perfusion with a radiotracer. *Int J Rad Appl Instrum B* 1987;14(2):113-118.
25. Alexander HR, Jr., Bartlett DL, Libutti SK, Fraker DL, Moser T, Rosenberg SA. Isolated hepatic perfusion with tumor necrosis factor and melphalan for unresectable cancers confined to the liver. *J Clin Oncol* 1998;16(4):1479-1489.
26. Therasse P, Arbuck SG, Eisenhauer EA et al. New guidelines to evaluate the response to treatment in solid tumors. European Organization for Research and Treatment of Cancer, National Cancer Institute of the United States, National Cancer Institute of Canada. *J Natl Cancer Inst* 2000;92(3):205-216.
27. Grover AC, Libutti SK, Pingpank JF, Helsabeck C, Beresnev T, Alexander HR, Jr. Isolated hepatic perfusion for the treatment of patients with advanced liver metastases from pancreatic and gastrointestinal neuroendocrine neoplasms. *Surgery* 2004;136(6):1176-1182.
28. King PD, Perry MC. Hepatotoxicity of chemotherapeutic and oncologic agents. *Gastroenterol Clin North Am* 1995;24(4):969-990.
29. Bedikian AY, Legha SS, Mavligit G et al. Treatment of uveal melanoma metastatic to the liver: a review of the M. D. Anderson Cancer Center experience and prognostic factors. *Cancer* 1995;76(9):1665-1670.
30. Flaherty LE, Unger JM, Liu PY, Mertens WC, Sondak VK. Metastatic melanoma from intraocular primary tumors: the Southwest Oncology Group experience in phase II advanced melanoma clinical trials. *Am J Clin Oncol* 1998;21(6):568-572.
31. Agarwala SS, Hellstrand K, Gehlsen K, Naredi P. Immunotherapy with histamine and interleukin 2 in malignant melanoma with liver metastasis. *Cancer Immunol Immunother* 2004;53(9):840-841.
32. Bedikian AY. Metastatic uveal melanoma therapy: current options. *Int Ophthalmol Clin* 2006;46(1):151-166.
33. Peters S, Voelter V, Zografos L et al. Intra-arterial hepatic fotemustine for the treatment of liver metastases from uveal melanoma: experience in 101 patients. *Ann Oncol* 2006;17(4):578-583.
34. Gragoudas ES, Egan KM, Seddon JM et al. Survival of patients with metastases from uveal melanoma. *Ophthalmology* 1991;98(3):383-389.
35. Kulke MH, Wu B, Ryan DP et al. A phase II trial of irinotecan and cisplatin in patients with metastatic neuroendocrine tumors. *Dig Dis Sci* 2006;51(6):1033-1038.
36. MOERTEL CG, Kvols LK, O'Connell MJ, Rubin J. Treatment of neuroendocrine carcinomas with combined etoposide and cisplatin. Evidence of major therapeutic activity in the anaplastic variants of these neoplasms. *Cancer* 1991;68(2):227-232.
37. Rivera E, Ajani JA. Doxorubicin, streptozocin, and 5-fluorouracil chemotherapy for patients with metastatic islet-cell carcinoma. *Am J Clin Oncol* 1998;21(1):36-38.

38. Oberg K. Interferon in the management of neuroendocrine GEP-tumors: a review. *Digestion* 2000;62 Suppl 1:92-97.
39. Kvols LK, MOERTEL CG, O'Connell MJ, Schutt AJ, Rubin J, Hahn RG. Treatment of the malignant carcinoid syndrome. Evaluation of a long-acting somatostatin analogue. *N Engl J Med* 1986;315(11):663-666.
40. Oberg K. Endocrine tumors of the gastrointestinal tract: systemic treatment. *Anticancer Drugs* 1994;5(5):503-519.
41. Oberg K, Norheim I, Theodorsson E. Treatment of malignant midgut carcinoid tumours with a long-acting somatostatin analogue octreotide. *Acta Oncol* 1991;30(4):503-507.
42. Vinik A, Moattari AR. Use of somatostatin analog in management of carcinoid syndrome. *Dig Dis Sci* 1989;34(3 Suppl):145-275.
43. Valkema R, Pauwels S, Kvols LK et al. Survival and response after peptide receptor radionuclide therapy with [90Y-DOTA0,Tyr3]octreotide in patients with advanced gastroenteropancreatic neuroendocrine tumors. *Semin Nucl Med* 2006;36(2):147-156.
44. Hellman P, Ladjevardi S, Skogseid B, Akerstrom G, Elvin A. Radiofrequency tissue ablation using cooled tip for liver metastases of endocrine tumors. *World J Surg* 2002;26(8):1052-1056.
45. Henn AR, Levine EA, McNulty W, Zagoria RJ. Percutaneous radiofrequency ablation of hepatic metastases for symptomatic relief of neuroendocrine syndromes. *AJR Am J Roentgenol* 2003;181(4):1005-1010.
46. Wessels FJ, Schell SR. Radiofrequency ablation treatment of refractory carcinoid hepatic metastases. *J Surg Res* 2001;95(1):8-12.
47. Berber E, Flesher N, Siperstein AE. Laparoscopic radiofrequency ablation of neuroendocrine liver metastases. *World J Surg* 2002;26(8):985-990.
48. Wettstein M, Vogt C, Cohnen M et al. Serotonin release during percutaneous radiofrequency ablation in a patient with symptomatic liver metastases of a neuroendocrine tumor. *Hepatogastroenterology* 2004;51(57):830-832.
49. Hirota S, Isozaki K, Moriyama Y et al. Gain-of-function mutations of c-kit in human gastrointestinal stromal tumors. *Science* 1998;279(5350):577-580.
50. Demetri GD, von Mehren M, Blanke CD et al. Efficacy and safety of imatinib mesylate in advanced gastrointestinal stromal tumors. *N Engl J Med* 2002;347(7):472-480.
51. van Oosterom AT, Judson I, Verweij J et al. Safety and efficacy of imatinib (STI571) in metastatic gastrointestinal stromal tumours: a phase I study. *Lancet* 2001;358(9291):1421-1423.
52. Demetri GD, van Oosterom AT, Garrett CR et al. Efficacy and safety of sunitinib in patients with advanced gastrointestinal stromal tumour after failure of imatinib: a randomised controlled trial. *Lancet* 2006;368(9544):1329-1338.
53. Patel SR, Benjamin RS. Management of peritoneal and hepatic metastases from gastrointestinal stromal tumors. *Surg Oncol* 2000;9(2):67-70.
54. Tarazov PG. Transcatheter therapy of gastric cancer metastatic to the liver: preliminary results. *J Gastroenterol* 2000;35(12):907-911.
55. Bloomston M, Binitie O, Fraiji E et al. Transcatheter arterial chemoembolization with or without radiofrequency ablation in the management of patients with advanced hepatic malignancy. *Am Surg* 2002;68(9):827-831.

.....

# CHAPTER 3

## Hepatic artery infusion of high-dose melphalan at reduced flow during isolated hepatic perfusion for the treatment of colorectal metastases confined to the liver: A clinical and pharmacologic evaluation

L.B.J. van Iersel<sup>1</sup>, M.R. Verlaan<sup>2</sup>, A.L. Vahrmeijer<sup>2</sup>,  
E.L. van Persijn van Meerten<sup>3</sup>, F.G.J. Tijl<sup>4</sup>, R.W. Sparidans<sup>5</sup>,  
H. Gelderblom<sup>1</sup>, P.J.K. Kuppen<sup>2</sup>, R.A.E.M. Tollenaar<sup>2</sup>  
and C.J.H. van de Velde<sup>2</sup>

Department of Clinical Oncology<sup>1</sup>, Surgery<sup>2</sup>, Radiology<sup>3</sup> and  
Extra Corporal Circulation<sup>4</sup> Leiden University Medical Center,  
Albinusdreef 2, 2333 ZA Leiden, The Netherlands  
Faculty of Science, Department of Pharmaceutical Sciences,  
Section of Biomedical Analysis, Division of Drug Toxicology,  
Sorbonnelaan 16, 3584 CA Utrecht, The Netherlands<sup>5</sup>

*Eur J Surg Oncol. 2007 Sep;33(7):874-81*

.....



## **Abstract**

Isolated hepatic perfusion (IHP) offers the advantage of high local drug exposure with limited systemic toxicity. To increase local drug exposure, we administered melphalan at a reduced flow in the hepatic artery during IHP (Hepatic artery Infusion, Hepatic artery-Portal vein Perfusion, HI-HPP).

Between December 2001 and December 2004, 30 patients with colorectal cancer liver metastases underwent HI-HPP with 200mg melphalan. Samples of the perfusate were taken for pharmacokinetic analysis. Patients were monitored for response, toxicity and survival.

Perfusion was aborted prematurely in 2 patients due to leakage. During melphalan administration in the hepatic inflow cannula a mean flow rate of 121.3 mL/min and mean pressure of 62.5 mm Hg was achieved. One patient died within 30 days after HI-HPP. Four patients developed veno-occlusive disease (VOD), while 2 patients showed signs of VOD. Twelve patients showed hepatic response, with a median duration of response of 11.5 months, according to WHO criteria.

Although HI-HPP results in high perfusate melphalan concentration levels, it is associated with a relatively high level of hepatotoxicity and a limited response rate. We believe the low flow and pressure rates found in this study can result in reduced drug penetration of the tumour and thus limited tumour response.

## Introduction

Liver metastases are diagnosed in 10-25% of colorectal cancer patients at the time of resection of their primary tumour and eventually up to 70 % of patients with colorectal cancer develop liver metastases<sup>1</sup>. In approximately 30% of the patients the liver is the only site of metastatic disease<sup>2,3</sup>. Hepatic resection is considered the treatment of choice for colorectal cancer liver metastases with 5-year survival rates ranging from 25-51%, while 5-year survival after systemic treatment alone remains <1%, emphasizing the importance of aggressive liver-directed treatment<sup>4-6</sup>. Unfortunately curative resection of liver metastases is only possible in less than 10 percent of patients due to the number, location or size of the metastases<sup>4</sup>, warranting the necessity for other liver-directed therapies. Although recent studies have shown improved survival with the introduction of oxaliplatin, irinotecan, bevacizumab and cetuximab in the systemic treatment of colorectal metastases<sup>7-12</sup>, regional treatment options can offer the potential benefit of both aggressive local treatment and limited systemic toxicity. Several regional therapies have been developed including radiofrequency ablation, hepatic artery infusion (HAI) and isolated hepatic perfusion (IHP). In both HAI and IHP high drug concentrations can be achieved at the tumour site with relatively low systemic drug exposure. HAI is based on the principle that liver metastases derive most of their blood supply from the hepatic artery. As a result high drug concentrations can be achieved at the tumour site, while the liver parenchyma is relatively spared<sup>13,14</sup>. The systemic exposure in HAI mainly depends on the rate of hepatic extraction and metabolization. IHP, on the other hand, involves complete vascular isolation of the liver, which allows the use of high dosages that would cause fatal complications if delivered systemically. Marinelli *et al.* showed that in a rat model bolus administration of the maximally tolerated doses of melphalan in HAI (6 mg kg<sup>-1</sup>) and IHP (12 mg kg<sup>-1</sup>) resulted in four times higher concentrations in both liver and tumour tissue of the IHP treated rats<sup>15</sup>. Furthermore, effective anti-tumour compounds which can not be administered systemically due to their toxicity, such as tumour necrosis factor alpha (TNF- $\alpha$ ), can be used in IHP. At our institution a phase I/II trial was performed in 73 colorectal cancer patients with bolus administration high dose melphalan, achieving an overall response rate of 59%, with a median progression-free survival of 7.7 months and a median overall survival of 28.8 months, similar to the results at other institutions<sup>16-19</sup>. Pharmacokinetic analysis of these patients showed that the concentration of bolus administered melphalan rapidly declines in the first 5-10 minutes of circulation<sup>20</sup>. Theoretically, infusing melphalan directly into the hepatic artery over a certain period would lead to more selective tumour exposure and prolonged exposure of the tumour to high concentrations of melphalan, which can be expected to improve antitumour efficacy of IHP. Based on the above we developed a Hepatic artery Infusion, Hepatic artery-Portal vein perfusion (HI-HPP). In this report, we present the results of

30 colorectal cancer patients with irresectable liver metastases treated with isolated hepatic perfusion with a 20 minute infusion of melphalan.

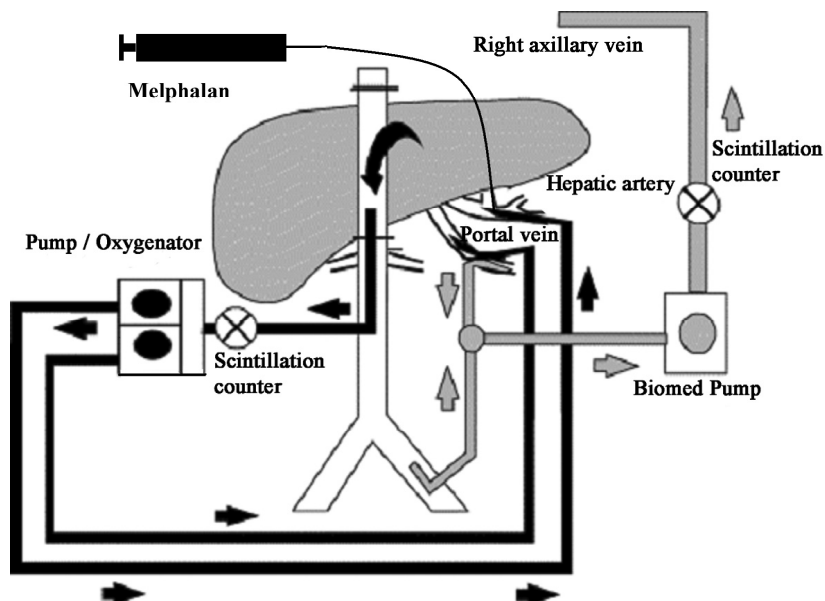
## **Patients and methods**

### **Patient Eligibility**

Between December 2001 and December 2004, 30 patients with colorectal cancer confined to the liver were treated with HI-HPP with 200mg melphalan. The study protocol was approved by the medical ethical committee of the Leiden University Medical Center and informed consent was obtained from all patients. All patients had measurable, irresectable colorectal metastases confined to the liver. Liver metastases were deemed irresectable based on number, size and localization. Standard staging studies were performed including CT scan of the chest and abdomen. Additional MRI or PET scans were performed if clinically indicated. Eligibility criteria included a WHO performance status of 0 or 1, leukocyte count  $\geq 3.0 \times 10^9/L$ , platelet count  $\geq 100 \times 10^9/L$ , maximum serum creatinine level 135  $\mu\text{mol/L}$ , maximum bilirubin level 17  $\mu\text{mol/L}$  and minimum albumin level 40 g/L. Exclusion criteria were age over 70 years, life expectancy of less than 4 months, more than 60 per cent hepatic replacement by tumour tissue as estimated from the preoperative abdominal CT scan, coagulation disorders and evidence of extrahepatic metastatic disease. The interval between resection of the primary colorectal tumour and perfusion had to be at least 6 weeks.

### **IHP technique**

All patients were treated with HI-HPP, consisting of an extracorporeal venovenous bypass (see figure 1), as described previously<sup>17</sup>. Briefly, the liver was mobilized from the diaphragm through a transverse abdominal incision. The common hepatic artery (8-Fr 77008 one-piece pediatric arterial cannula; Medtronic, Minneapolis, Minnesota, USA) and the portal vein (12-Fr perfex perfusion catheter CH12; B. Braun Medical, Oss, The Netherlands) were cannulated and connected to a heart-lung machine which consisted of two independent roller pumps (model 10-30-00; Cobe/Stöckert, Munich, Germany). The inferior vena cava (IVC) was cross-clamped above the hepatic veins and cannulated proximal of the renal veins (Polystan 36 Fr, straight, A/S, Värölse, Denmark) to allow undisturbed blood flow from the hepatic veins through the IVC towards the heart-lung machine. To isolate the hepatic circuit, tourniquets were secured around the hepatic artery, portal vein and IVC.



**Figure 1.** Isolated hepatic perfusion circuit with infusion of melphalan in the hepatic artery (HI-HPP).

For the extracorporeal venovenous bypass, the right femoral vein (22-Fr cannula DI-ITF022L; Edwards Lifesciences, Irvine, California, USA) and the portal vein (17-Fr perfex perfusion catheter CH17; B. Braun) (proximal to the tourniquet) were cannulated and connected to the right axillary vein (18-Fr 7326 perfusion cannula; Lifestream International, The Woodlands, Texas, USA). The venovenous bypass was supported by a centrifugal pump (Medtronic BIO-Medicus, Eden Prairie, Minnesota, USA) and primed with 700 mL 0.9 % saline. The perfusate consisted of intrahepatically trapped blood and 1250 mL Gelofusine® (Vifor Medical, Sempach, Switzerland) plus 2500 units heparin (Leo Pharma, Breda, The Netherlands) to yield a final volume of approximately 2 litres. Throughout the 1-h perfusion interval, the perfusate was kept at a temperature of 39.5 °C by a heat exchanger and oxygenated using an oxygenator (Cobe VPCML; Cobe Cardiovascular, Arvada, Colorado, USA) except for the last patient who was oxygenated using a different oxygenator (Dideco D901, SORIN group Italia, Mirandola, Italy). After perfusion, the liver was flushed for approximately 10 minutes with 3 liters Gelofusine®. All cannulas and clamps were removed, and the incisions were closed. To prevent possible postoperative cholecystitis, cholecystectomy was performed.

## Melphalan

Melphalan 200mg (Alkeran®, GlaxoSmithKline, Zeist, The Netherlands) was first dissolved in 40 mL Wellcome Diluent (a 60/40 (v/v) mixture of proylene glycol containing 5.2%

(v/v) ethanol and 0.068 mol/l sodium citrate), which was subsequently diluted with 60 mL sterile saline. Melphalan was administered through 20 minute infusion using an infusion pump (Pilote Anesthésie; Fresenius, Brezins, France) connected to the hepatic artery line of the isolated hepatic circuit.

### **Leakage Detection**

Leakage of perfusate into the systemic circuit was monitored by adding 10 MBq  $^{99m}\text{Tc}$ -pertechnetate to the isolated circuit with subsequent measurement of the level of radioactivity in both the systemic and isolated circuit, as described previously <sup>21, 22</sup>. If no leakage was detected, melphalan was administered; however, if leakage exceeded 10% during the perfusion period, the procedure was immediately aborted and the liver flushed.

### **Postoperative Care**

All patients received a daily subcutaneous dose of 480 µg granulocyte colony-stimulating factor (G-CSF) (Filgrastim/Neupogen<sup>®</sup>; Amgen, Breda, The Netherlands) starting the day after the operation until the nadir in leukocyte count was reached and the count had risen to more than  $1.0 \times 10^9/\text{L}$ . Patients were monitored in the intensive care unit for at least 1 day after IHP. Liver and renal function tests and full blood counts were carried out daily in the first week and henceforth as indicated by their respective levels. Antibiotics in a combination of cefuroxim and metronidazol were given to all patients for 5 days after IHP.

### **Toxicity**

Systemic and regional toxicity were graded according to the National Cancer Institute Common Toxicity Criteria version 2.0. Hepatic toxicities were considered melphalan related if elevations in liver function persisted beyond 7 days after perfusion, as previously suggested <sup>18</sup>. Nonhepatic toxicities were defined as all toxicities that are not reversed within 24 hours after perfusion.

### **Melphalan levels**

Heparinized samples of four patients were taken from the perfusion medium at the inflow of the hepatic artery and at the outflow of the inferior caval vein, at 10 different time intervals (t=0, 5, 10, 15, 20, 25, 30, 40, 50, 60 minutes). Samples were stored at -80 °C until analysis. All samples were analyzed by a HPLC assay as previously described <sup>23</sup>. The

areas under the concentration-time curves (AUC) were calculated with the trapezoidal rule.

## **Response evaluation**

Objective tumour response measurements were obtained by follow up CT scans of the liver and remaining abdomen at 3-month intervals after treatment and at 6-month interval after 1 year. Additional imaging was performed if clinically indicated. Both WHO and RECIST criteria were used to determine response rates. Hepatic response and overall response were measured separately, in view of the local nature of the treatment. According to the WHO criteria the size of all measurable lesions was determined, complete response was defined as disappearance of all known disease, partial response as a reduction in the sum of the product of maximal diameter x longest perpendicular diameter of all measurable metastases of  $\geq 50\%$ , stable disease as a reduction of  $< 50\%$  or an increase of  $< 25\%$  and progressive disease as an increase of  $\geq 25\%$  or the appearance of new intra- or extrahepatic lesions<sup>24</sup>. For the RECIST criteria lesions were only considered measurable if  $\geq 10\text{mm}$ , complete response was defined as disappearance of all known disease, partial response as a reduction in the sum of maximal diameters of  $\geq 30\%$ , stable disease as a reduction of  $< 30\%$  or an increase of  $< 20\%$  and progressive disease as an increase of  $\geq 20\%$  or the appearance of new intra- or extrahepatic lesions<sup>25</sup>. Metastases were localized according to the Bismuth classification<sup>26</sup>.

Serum carcinoembryonic antigen (CEA) levels were determined prior to treatment and at all follow-up visits.

## **Statistics**

All data were analyzed using SPSS (version 12.0) software and presented as mean  $\pm$  SD or median followed by the range. All survival and disease progression analysis was performed by using Kaplan-Meier statistics.

## **Results**

### **Patient and treatment characteristics**

Demographics and tumour characteristics of the patient population are listed in Table 1. In total, 30 colorectal cancer patients with unresectable liver disease and no evidence of extrahepatic disease were treated with HI-HPP: 8 women and 22 men with a mean

**Table 1** Patient and tumor characteristics

Characteristic	n
No. of patients	30
Sex ratio (F:M)	8 : 22
Mean age (years), [range]	55 [36-67]
Liver metastases synchronous : metachronous	17 : 13
Median no. of metastases [range]	9 [2-20]
Pretreatment CEA level	
Normal ( $\leq 3.0$ $\mu\text{g/mL}$ )	6
Raised ( $> 3.0$ $\mu\text{g/mL}$ )	23
Unknown	1
Chemotherapy prior to IHP, directed at:	
Primary tumor	5
Liver metastases	16

age of 56 years (range 37 to 69 years). Seventeen patients presented with synchronous liver metastases, whereas 13 had metachronous liver metastases. Median time between diagnosis of liver metastases and perfusion was 5 months (range 1.5 to 19.8 months). Nineteen patients received treatment directed at their liver metastases prior to enrolment in this trial, including systemic chemotherapy in 16 patients, chemoembolization in 2 patients and metastasectomy in 1 patient. Seven of the 16 patients who received chemotherapy prior to IHP showed progressive disease under therapy. Tumour burden varied among patients, the median number of metastatic lesions was 9, but ranged from 2 to more than 20 lesions. The lesions ranged in size as measured by greatest diameter from 2mm to 131mm with a mean diameter of 22mm. The estimated percentage of hepatic replacement ranged from 5% to 40% with a mean replacement of 14%. Carcinoembryonic antigen (CEA) levels were elevated ( $> 3.0$   $\mu\text{g/mL}$ ) in 23 patients prior to perfusion.

Treatment parameters are shown in Table 2. All 30 patients underwent HI-HPP. In two patients the HI-HPP was prematurely aborted (after 25 and 30 minutes respectively), because the calculated maximum tolerated leakage for the entire procedure of 10% would be exceeded. Median operative time was 8.8 hours (range 7.0 to 12.8 hours) with a median blood and fluid loss of 4.0 L (range 1.3 to 14.0 L). Median hospital stay was 10 days (range 7 to 27 days). Mean flow rate in the hepatic artery during the 20-minute melphalan infusion was 121.3 mL/min (range 100.0 to 290.0 mL/min) and climbed to 270.7 mL/min (range 100.0 to 400.0 mL/min) after melphalan administration. Corresponding pressures in the hepatic artery during infusion ranged from 33.0 to 140.0 mm Hg (mean

**Table 2** Isolated hepatic perfusion parameters HI-HPP

	HI-HPP during infusion (20min)	HI-HPP during perfusion (40min)
flow rate hepatic artery (mL/min)	121 ± 41	270 ± 95
flow rate portal vein (mL/min)	246 ± 56	253 ± 52
pressure hepatic artery (mm/Hg)	64 ± 32	93 ± 30
pressure portal vein (mm/Hg)	34 ± 8	35 ± 8
Mean % leakage during perfusion (range)		1.2 (0-7)

Values are mean ± s.d.

63.5 mm Hg) rising to 40.0 to 160.0 mm Hg (mean 93.2 mm Hg) after melphalan administration. Actual leakage ranged between 0 and 7.0%.

### Toxicity and complications

One patient died perioperatively as a result of a progressive liver failure. Major complications are listed in Table 3. Venous-occlusive disease occurred in 4 patients, while 2 other patients showed clear signs of portal hypertension not present prior to therapy, including oesophageal varices on post-perfusion imaging. One of these patients died 11 months after perfusion of massive haematemesis. Despite limited leakage and postoperative administration of G-CSF, 3 patients developed a grade 3-4 leucopenia. Regional toxicity data are presented in Table 4. Grade 4 hepatotoxicity was present in 5 patients and consisted of elevated levels of bilirubin in 1 patient, elevated transaminases in 1 patient, elevated gamma-glutamyl transpeptidase in 2 patients and both elevated gamma-glutamyl transpeptidase and bilirubin in another patient. The hepatotoxicity was transient in most patients, although some elevation persisted in the patients with either VOD or portal hypertension.

**Table 3** Number of patients with major complications

Major complications	HI-HPP
Toxic hepatitis	1
Bleeding requiring re-operation	1
VOD	4
Portal hypertension	2
Infection	2
Pulmonary embolism	1
Serious delirium	1

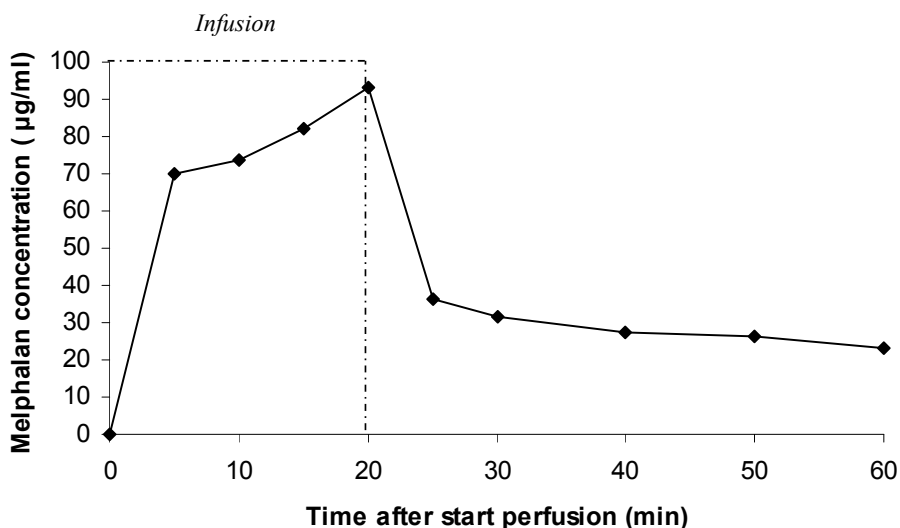


**Table 4** Toxicity according to National Cancer Institute Common Toxicity Criteria (n=30)

	Grade 0	Grade 1	Grade 2	Grade 3	Grade 4
Leukocyte nadir	20	3	4	1	2
Bilirubin	13	6	6	3	2
Alkaline phosphatase	0	7	16	7	0
GGT	0	1	8	18	3
ALAT	2	10	11	6	1
ASAT	2	16	8	3	1

### Melphalan pharmacokinetics

Figure 2 shows a typical example of a drug concentration-versus-time curve of HI-HPP. During the 20-minute infusion the melphalan concentration rapidly increases to remain at a constant high level (peak concentration of 93.2 $\mu\text{g}/\text{mL}$ ) for approximately 18 minutes. The melphalan concentration gradually increases during the first 20 minutes as a result of recirculation. After the end of the infusion the melphalan concentration declines rapidly to approximately 30  $\mu\text{g}/\text{mL}$  followed by a gradual elimination of melphalan.

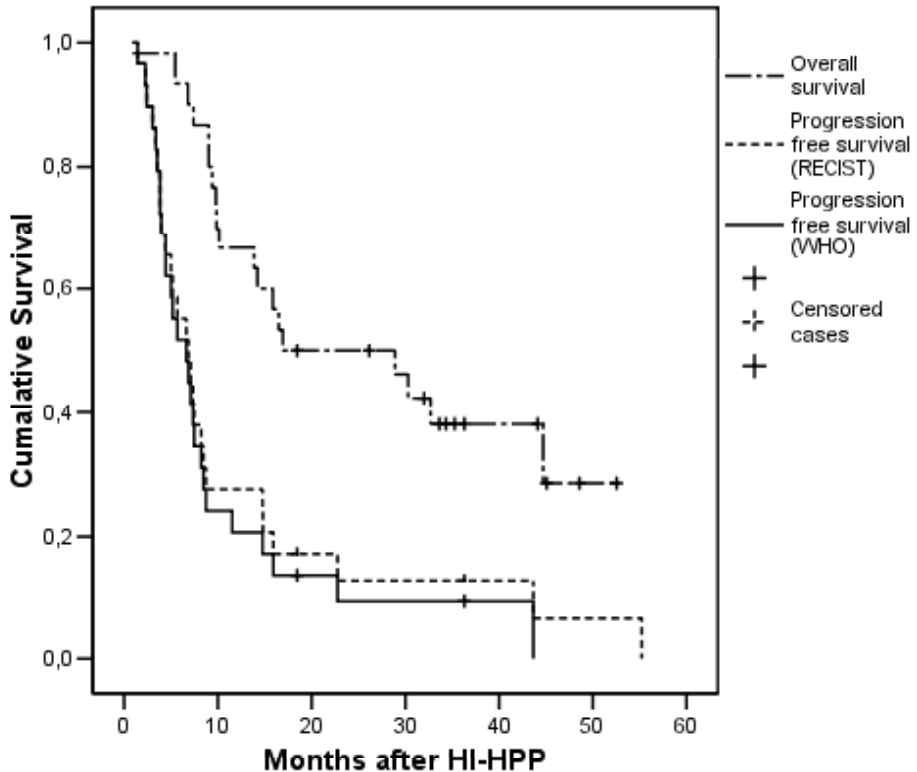


**Figure 2.** A typical example of a concentration-time curve of melphalan in perfusate during HI-HPP. A constant high level of melphalan is maintained for up to 20 minutes. The peak concentration of 93.2 $\mu\text{g}/\text{mL}$  is achieved after 20 minutes. The area under the concentration-versus-time curve (AUC) was calculated for the entire procedure: 2841,6  $\mu\text{g} \times \text{min}/\text{mL}$ .

## **Tumour response and patient survival**

The median follow up time was 44.6 months (range 18.5 to 55.3 months). Nineteen patients of the 23 patients with previously elevated CEA levels experienced a normalization or reduction of 50% or more 1 to 3 months after perfusion with a median duration of response of 4.4 months (range 1.5 to 18.5 months).

Hepatic and overall treatment responses were measured by comparing follow-up CT scans to the pre-treatment scan, according to both WHO and RECIST criteria. As 1 patient died postoperatively, 29 patients were eligible for measurement of tumour response. Twelve patients showed hepatic response according to WHO criteria, as compared to 15 patients according to the RECIST criteria, with no complete responses. Nine patients showed stable disease according to the WHO criteria, while 6 patients showed stable disease according to the RECIST criteria. Eight patients immediately showed progressive disease for both criteria on the first follow up CT scan. The median duration of hepatic response (partial remission) was 11.5 months (range 4.4 to 48.6 months) for WHO criteria and 9.1 months (range 5.2 to 48.6 months) for RECIST criteria. In 3 patients hepatic progression has not occurred at respectively 18.5, 36.3 and 48.6 months. Two patients with hepatic stable disease and 1 patient with hepatic partial remission, according to WHO criteria, showed extrahepatic disease on the first follow up scan, resulting in an overall response in 11 patients. For the RECIST criteria, 2 patients with hepatic partial remissions and 1 patient with stable disease, showed extrahepatic disease on the first follow up scan, resulting in an overall response 13 patients. The time to overall progression (hepatic and/or extrahepatic) and overall survival curves are shown in figure 3. Progression occurred in 27 of the 29 patients, 15 of these patients showed hepatic progression, 5 patients extrahepatic and 7 patients had both hepatic and extrahepatic progression. In retrospect, two patients with extrahepatic progression had extrahepatic disease pre-operatively. Median time to progression (hepatic and/or extrahepatic) was 6.6 months (range 1.4 to 43.7 months) for both WHO and RECIST criteria. The median overall survival after perfusion was 16.9 months (range 0.9 to 52.5 months) with 7 patients still alive. The median overall survival after diagnosis of liver metastases was 27.8 months (range 5.2 to 64.6 months). Twenty-one patients received therapy after perfusion, including adjuvant systemic treatment in 1 patient, systemic treatment for metastatic disease in 19 patients and metastasectomy of pulmonary metastases in 1 patient.



**Figure 3.** Overall and progression free (hepatic and/or extrahepatic) survival curves for WHO and RECIST criteria after HI-HPP. For the survival analysis all 30 patients were included. For the progression free survival (both RECIST and WHO) 29 patients were evaluable, as 1 patient died perioperatively. At a median follow up of 44.6 months 11 patients remain alive and progression has not occurred in 2 patients.

## Discussion

Isolated hepatic perfusion is based on the principle of high regional drug exposure with limited systemic toxicity. By means of a 20 minute hepatic artery infusion of 200mg melphalan followed by a 40 minutes perfusion, we wanted to achieve a selective tumour exposure to an increased concentration of melphalan, as compared to conventional perfusion circuits with a drug bolus administration. Previous studies have shown a rapid decline of melphalan in the perfusate, as measured 5 tot 15 minutes after bolus administration with mean peak concentrations ranging between 18.1 to 38.6  $\mu\text{g}/\text{mL}$  <sup>17,27</sup>. This study in 30 colorectal cancer patients demonstrated that HI-HPP with 200mg melphalan results in high local concentrations of melphalan, with a maximum peak concentration of 93.2 $\mu\text{g}/\text{mL}$ , for up to 20 minutes. However, toxicity was considerable and increased selective drug exposure did not improve response rates and survival compared to previous studies <sup>18,27</sup>.

Veno-occlusive disease (VOD) was present in 4 patients, while 2 other patients developed portal hypertension, possibly as a result of VOD. Several other studies have reported cases of VOD after IHP, but only incidentally<sup>18,27-29</sup>. A phase II trial at our institution with bolus administration of the same dose of melphalan resulted in VOD, only in 4 out of 71 patients<sup>16</sup>. VOD is thought to result from accumulative exposure to chemotherapeutic agents, but the patients in this study were exposed to similar amounts of chemotherapy as compared to previous studies<sup>30</sup>. A similar trend was observed in grade 4 biliary toxicity, which occurred in as many as 5 out of 30 patients and 1 patient died of progressive liver failure. The toxicity data from this clinical study are in line with the results of an animal study, previously performed at our institution. In an *in vivo* rat model for liver tumours we studied the difference in tumour and liver uptake as well as an antitumour effect and hepatotoxicity of 5 and 20 minute arterial infusion of a fixed melphalan dose<sup>31</sup>. No difference in melphalan content of tumour/liver tissue and tumour response was found between the two infusion schedules. Hepatotoxicity, on the other hand, was strongly affected by infusion duration and hence melphalan concentration. Severe cholangiofibrosis occurred in 8 of 9 rats treated with 5 minute infusion, but in only 1 of 8 rats treated with a 20 minute infusion, hence we considered a 20 minute infusion in humans to be safe. Liver toxicity appears to have a steep concentration-toxicity curve, independent of the total dose of melphalan

This study shows a hepatic response rate of 40% (according to WHO criteria) with a median duration of hepatic response of 11.5 months. Bartlett *et al* reported the results of IHP with 1.5mg/kg melphalan in 51 colorectal cancer and 1mg TNF- $\alpha$  in a subset of 32 patients, with a local response rate of 76% with a median duration of 10.5 months<sup>27</sup>, similar to our own experience<sup>16</sup>. Contrary to toxicity, response seems to be determined by the total dose of melphalan, not by melphalan concentration levels. Although this might explain the absence of improved response it does not explain the actual reduction in response.

One of the major drawbacks of HI-HPP is the low pressure and flow in the perfusion circuit. In a regular IHP setup mean flow rates ranging between 502 to 844 mL/min and associated pressures of 159 to 164 mm Hg can be achieved<sup>17,18</sup>. In this study we achieved a mean flow rate of 121.3 mL/min (mean pressure 63.5 mm Hg) during infusion and 270.0 mL/min (mean pressure 93.17 mm Hg) during perfusion. Efficacy of chemotherapeutic agents in the treatment of solid tumours is, on top of the development of drug resistance of cancer cells, dependent upon the drug delivery and penetration within the tumour. Impaired transport of cytostatic agents into the tumour has been attributed to changes in the extracellular matrix, deformed tumour vasculature and pathologically increased interstitial fluid pressure (IFP)<sup>32-34</sup>. Less *et al* measured the IFP in colorectal

liver metastases and found a mean IFP of 10 times above the IFP of normal liver tissue<sup>35</sup>. In animal models, lowering of the IFP, through for example prostaglandin E1 (PGE<sub>1</sub>), resulted in an improved drug penetration<sup>36,37</sup>. It has even been argued that the increase in disease-free survival seen in phase III trials of conventional chemotherapy combined with a monoclonal antibody against vascular endothelial growth factor, is partly attributable to the IFP lowering effect of bevacizumab<sup>38</sup>. It seems likely that a reduction of more than 50% in flow rate and pressure during perfusion would lead to decreased melphalan penetration and hence tumour response. Healthy liver and biliary tract tissue, on the other hand, with a normal IFP is penetrated by the melphalan, resulting in the previously described toxicity. Ideally, decreased penetration of melphalan in the tumour is determined by detecting melphalan levels in liver biopsies taken during and after perfusion. However, in our experience this would increase morbidity considerably due to haemorrhage as a result of heparinization.

The current IHP technique is an expensive, demanding and technically difficult procedure with considerable morbidity and mortality, which is not amenable to repetition, therefore attention has shifted to the development of a less complicated percutaneous technique. Several phase I studies, using a variety of percutaneous approaches with variable results, have been published so far<sup>39,40</sup>. Savier *et al* reported treatment of 4 patients with 3 successive courses of chemotherapy by IHP, in which the first course was given at laparotomy and the next two courses percutaneously<sup>29</sup>. Percutaneous isolation of the liver was achieved by placing an occlusion catheter in the portal vein according to the transhepatic Seldinger technique and a double-balloon catheter in the retrohepatic caval vein through the saphenous vein. Finally, the HA was occluded by traction of a silicon-lined nylon thread that was positioned around the common hepatic artery during previous laparotomy. Although isolated perfusion was achieved by this method, considerable leakage to the systemic circulation occurred during IHP and the flow rate was limited to 200-300mL/min. Phase II trials need to be performed for a sensible determination of response rates. Nevertheless, in view of our findings response rates could be disappointing, considering the limited flow rate due to catheter size in a percutaneous technique.

In summary, we have demonstrated that HI-HPP with 200mg melphalan results in high perfusate melphalan concentration levels, but is associated with a relatively high level of hepatotoxicity and a limited response rate. We believe that the low flow rates and pressures found in this study can result in reduced drug penetration of the tumour and thus limited tumour response. This could prove to be an important consideration in the development of future percutaneous isolated hepatic perfusion techniques. We will abandon HI-HPP and are currently focusing on the introduction of new tumour-specific

agents in an isolated hepatic perfusion system capable of producing adequate flow and pressure rates.

## References

1. Jessup JM, McGinnis LS, Steele GD, Jr., Menck HR, Winchester DP. The National Cancer Data Base. Report on colon cancer. *Cancer* 1996;78(4):918-926.
2. Weiss L, Grundmann E, Torhorst J et al. Haematogenous metastatic patterns in colonic carcinoma: an analysis of 1541 necropsies. *J Pathol* 1986;150(3):195-203.
3. Welch JP, Donaldson GA. The clinical correlation of an autopsy study of recurrent colorectal cancer. *Ann Surg* 1979;189(4):496-502.
4. Scheele J, Stang R, Altendorf-Hofmann A, Paul M. Resection of colorectal liver metastases. *World J Surg* 1995;19(1):59-71.
5. Nordlinger B, Guiguet M, Vaillant JC et al. Surgical resection of colorectal carcinoma metastases to the liver. A prognostic scoring system to improve case selection, based on 1568 patients. *Association Francaise de Chirurgie. Cancer* 1996;77(7):1254-1262.
6. Yamamoto J, Shimada K, Kosuge T, Yamasaki S, Sakamoto M, Fukuda H. Factors influencing survival of patients undergoing hepatectomy for colorectal metastases. *Br J Surg* 1999;86(3):332-337.
7. Cunningham D, Humblet Y, Siena S et al. Cetuximab monotherapy and cetuximab plus irinotecan in irinotecan-refractory metastatic colorectal cancer. *N Engl J Med* 2004;351(4):337-345.
8. de Gramont A, Figer A, Seymour M et al. Leucovorin and fluorouracil with or without oxaliplatin as first-line treatment in advanced colorectal cancer. *J Clin Oncol* 2000;18(16):2938-2947.
9. Douillard JY, Cunningham D, Roth AD et al. Irinotecan combined with fluorouracil compared with fluorouracil alone as first-line treatment for metastatic colorectal cancer: a multicentre randomised trial. *Lancet* 2000;355(9209):1041-1047.
10. Hurwitz H, Fehrenbacher L, Novotny W et al. Bevacizumab plus irinotecan, fluorouracil, and leucovorin for metastatic colorectal cancer. *New England Journal of Medicine* 2004;350(23):2335-2342.
11. Saltz LB, Cox JV, Blanke C et al. Irinotecan plus fluorouracil and leucovorin for metastatic colorectal cancer. *Irinotecan Study Group. N Engl J Med* 2000;343(13):905-914.
12. Tournigand C, Andre T, Achille E et al. FOLFIRI followed by FOLFOX6 or the reverse sequence in advanced colorectal cancer: A randomized GERCOR study. *Journal of Clinical Oncology* 2004;22(2):229-237.
13. Wang LQ, Persson BG, Stenram U, Bengmark S. Influence of portal branch ligation on the outcome of repeat dearterializations of an experimental liver tumor in the rat. *J Surg Oncol* 1994;55(4):229-234.
14. Sigurdson ER, Ridge JA, Kemeny N, Daly JM. Tumor and liver drug uptake following hepatic artery and portal vein infusion. *J Clin Oncol* 1987;5(11):1836-1840.
15. Marinelli A, van Dierendonck JH, van Brakel GM et al. Increasing the effective concentration of melphalan in experimental rat liver tumours: comparison of isolated liver perfusion and hepatic artery infusion. *Br J Cancer* 1991;64(6):1069-1075.
16. Rothbarth J, Pijl ME, Vahrmeijer AL et al. Isolated hepatic perfusion with high-dose melphalan for the treatment of colorectal metastasis confined to the liver. *Br J Surg* 2003;90(11):1391-1397.
17. Vahrmeijer AL, van Dierendonck JH, Keizer HJ et al. Increased local cytostatic drug exposure by isolated hepatic perfusion: a phase I clinical and pharmacologic evaluation of treatment with high dose melphalan in patients with colorectal cancer confined to the liver. *Br J Cancer* 2000;82(9):1539-1546.

18. Alexander HR, Jr., Bartlett DL, Libutti SK, Fraker DL, Moser T, Rosenberg SA. Isolated hepatic perfusion with tumor necrosis factor and melphalan for unresectable cancers confined to the liver. *J Clin Oncol* 1998;16(4):1479-1489.
19. Alexander HR, Libutti SK, Bartlett DL, Puhlmann M, Fraker DL, Bachenheimer LC. A phase I-II study of isolated hepatic perfusion using melphalan with or without tumor necrosis factor for patients with ocular melanoma metastatic to liver. *Clin Cancer Res* 2000;6(8):3062-3070.
20. Vahrmeijer AL, Snel CA, Steenvoorden DP et al. Lack of glutathione conjugation of melphalan in the isolated in situ liver perfusion in humans. *Cancer Res* 1996;56(20):4709-4714.
21. Marinelli A, de Brauw LM, Beerman H et al. Isolated liver perfusion with mitomycin C in the treatment of colorectal cancer metastases confined to the liver. *Jpn J Clin Oncol* 1996;26(5):341-350.
22. Runia RD, de Brauw LM, Kothuis BJ, Pauwels EK, van de Velde CJ. Continuous measurement of leakage during isolated liver perfusion with a radiotracer. *Int J Rad Appl Instrum B* 1987;14(2):113-118.
23. Sparidans RW, Silvertand L, Dost F et al. Simple high-performance liquid chromatographic assay for melphalan in perfusate, rat liver and tumour tissue. *Biomed Chromatogr* 2003;17(7):458-464.
24. Miller AB, Hoogstraten B, Staquet M, Winkler A. Reporting results of cancer treatment. *Cancer* 1981;47(1):207-214.
25. Therasse P, Arbuck SG, Eisenhauer EA et al. New guidelines to evaluate the response to treatment in solid tumors. European Organization for Research and Treatment of Cancer, National Cancer Institute of the United States, National Cancer Institute of Canada. *J Natl Cancer Inst* 2000;92(3):205-216.
26. Bismuth H. Surgical anatomy and anatomical surgery of the liver. *World J Surg* 1982;6(1):3-9.
27. Bartlett DL, Libutti SK, Figg WD, Fraker DL, Alexander HR. Isolated hepatic perfusion for unresectable hepatic metastases from colorectal cancer. *Surgery* 2001;129(2):176-187.
28. Oldhafer KJ, Lang H, Frerker M et al. First experience and technical aspects of isolated liver perfusion for extensive liver metastasis. *Surgery* 1998;123(6):622-631.
29. Savier E, Azoulay D, Huguet E, Lokiec F, Gil-Delgado M, Bismuth H. Percutaneous isolated hepatic perfusion for chemotherapy: a phase 1 study. *Arch Surg* 2003;138(3):325-332.
30. King PD, Perry MC. Hepatotoxicity of chemotherapeutic and oncologic agents. *Gastroenterol Clin North Am* 1995;24(4):969-990.
31. Rothbarth J, Woutersen RA, Sparidans RW, van de Velde CJ, Mulder GJ. Melphalan antitumor efficacy and hepatotoxicity: the effect of variable infusion duration in the hepatic artery. *J Pharmacol Exp Ther* 2003;305(3):1098-1103.
32. Carmeliet P, Jain RK. Angiogenesis in cancer and other diseases. *Nature* 2000;407(6801):249-257.
33. Netti PA, Berk DA, Swartz MA, Grodzinsky AJ, Jain RK. Role of extracellular matrix assembly in interstitial transport in solid tumors. *Cancer Res* 2000;60(9):2497-2503.
34. Heldin CH, Rubin K, Pietras K, Ostman A. High interstitial fluid pressure - an obstacle in cancer therapy. *Nat Rev Cancer* 2004;4(10):806-813.
35. Less JR, Posner MC, Boucher Y, Borochovit D, Wolmark N, Jain RK. Interstitial hypertension in human breast and colorectal tumors. *Cancer Res* 1992;52(22):6371-6374.
36. Salnikov AV, Iversen VV, Koisti M et al. Lowering of tumor interstitial fluid pressure specifically augments efficacy of chemotherapy. *FASEB J* 2003;17(12):1756-1758.
37. Pietras K, Ostman A, Sjoquist M et al. Inhibition of platelet-derived growth factor receptors reduces interstitial hypertension and increases transcapillary transport in tumors. *Cancer Res* 2001;61(7):2929-2934.



38. Tong RT, Boucher Y, Kozin SV, Winkler F, Hicklin DJ, Jain RK. Vascular normalization by vascular endothelial growth factor receptor 2 blockade induces a pressure gradient across the vasculature and improves drug penetration in tumors. *Cancer Res* 2004;64(11):3731-3736.
39. Pingpank JF, Libutti SK, Chang R et al. Phase I study of hepatic arterial melphalan infusion and hepatic venous hemofiltration using percutaneously placed catheters in patients with unresectable hepatic malignancies. *J Clin Oncol* 2005;23(15):3465-3474.
40. van Etten B, Brunstein F, van IJken MG et al. Isolated hypoxic hepatic perfusion with orthograde or retrograde flow in patients with irresectable liver metastases using percutaneous balloon catheter techniques: a phase I and II study. *Ann Surg Oncol* 2004;11(6):598-605.

---

# CHAPTER 4

## Isolated hepatic melphalan perfusion of colorectal liver metastases: outcome and prognostic factors in 154 patients

Liselot B.J. van Iersel<sup>1</sup>, Hans Gelderblom<sup>1</sup>,  
Alexander L. Vahrmeijer<sup>2</sup>, Els L. van Persijn van Meerten<sup>3</sup>,  
Fred G.J. Tijn<sup>4</sup>, Hein Putter<sup>5</sup>, Henk H. Hartgrink<sup>2</sup>,  
Peter J.K. Kuppen<sup>2</sup>, Johan W.R. Nortier<sup>1</sup>, Rob A.E.M. Tollenaar<sup>2</sup>  
and Cornelis J.H. van de Velde<sup>2</sup>

Department of Clinical Oncology<sup>1</sup>, Surgery<sup>2</sup>, Radiology<sup>3</sup>,  
Extra Corporal Circulation<sup>4</sup> and Medical Statistics and  
Bioinformatics<sup>5</sup>, Leiden University Medical Center, Albinusdreef  
2, 2333 ZA Leiden, The Netherlands

*Ann Oncol.* 2008 Jun;19(6):1127-34

---

## **Abstract**

The aim of this study was to identify prognostic factors for local and systemic failure after isolated hepatic perfusion (IHP) with 200 mg melphalan in patients with colorectal liver metastases.

Hundredandfifty-four patients were selected for IHP and underwent laparotomy. Patients were monitored for response, toxicity and survival. Univariate and multivariate analyses were performed to identify prognostic factors for hepatic response, progression-free and overall survival.

Hepatic response rate was 50% with a median progression free and overall survival of respectively 7.4 months and 24.8 months. In multivariate analyses, absence of ability to perfuse through the hepatic artery ( $P=.003$ ), severe postoperative complications ( $P=.048$ ) and more than 10 liver metastases ( $P=.006$ ) adversely influenced overall survival and no adjuvant chemotherapy adversely influenced progression-free survival.

This is the first study to report prognostic factors for survival after IHP. Possibly, overall and disease-free survival can increase if preoperative screening is improved. In future studies on IHP, adjuvant chemotherapy should be considered.

## Introduction

In approximately 30% of colorectal cancer patients the liver is the only site of metastatic disease<sup>1,2</sup>. Complete surgical resection is considered the treatment of choice with 5-year survival rates ranging from 25-51%. However metastasectomy is only possible in less than 10 percent of patients due to the number, location or size of the metastases<sup>3-5</sup>. The management of irresectable colorectal liver metastases remains a challenge for both medical oncologists and surgeons. Recent studies have shown improved survival with the introduction of oxaliplatin, irinotecan, bevacizumab and cetuximab in the systemic treatment of colorectal metastases<sup>6-11</sup>. Regional treatment options however, can offer the potential benefit of both aggressive local treatment and limited systemic toxicity. Several regional therapies have been developed including radiofrequency ablation (RFA) and isolated hepatic perfusion (IHP). Phase II studies involving IHP in colorectal cancer patients have shown hepatic response rates up to 74% with a median time to hepatic progression up to 14.5 months, a median overall survival of 27 months and 5 year survival of 9%, establishing its value in the treatment of colorectal liver metastases<sup>12-15</sup>. While several studies have been published on prognostic factors in RFA, little is known about prognostic factors in IHP<sup>16,17</sup>. Most IHP studies focus on local response rate and recurrence, but the at least equally important systemic (i.e. extrahepatic) failure is scarcely reported. The aim of this study was to evaluate both local and systemic failure after IHP with 200mg melphalan and identify possible prognostic factors in colorectal cancer patients.

## Patients and methods

### Patient Eligibility

In the 10-year period from August 1994 and December 2004, 179 patients with liver metastases were considered for treatment with 200mg melphalan, according to a study protocol approved by the medical ethical committee of the Leiden University Medical Center, as previously published<sup>12,18</sup>. The data were obtained from a prospectively collected database and analyzed retrospectively. In 25 patients the primary tumor was of non-colorectal origin and these patients were excluded, leaving 154 patients for further analysis. Informed consent was obtained from all patients. All patients had measurable, irresectable colorectal metastases confined to the liver. Standard staging studies were performed including CT scan of the chest and abdomen. Additional MRI or PET scans were performed if clinically indicated. Eligibility criteria included a WHO performance status of 0 or 1, leukocyte count  $\geq 3.0 \times 10^9/L$ , platelet count  $\geq 100 \times 10^9/L$ , maximum

serum creatinine level 135  $\mu\text{mol/L}$ , maximum bilirubin level 17  $\mu\text{mol/L}$  and minimum albumin level 40 g/L. Exclusion criteria were age over 70 years, life expectancy of less than 4 months, more than 60 percent hepatic involvement of tumour tissue as estimated from the preoperative abdominal CT scan, coagulation disorders and evidence of extrahepatic metastatic disease. The interval between resection of the primary colorectal tumour and perfusion had to be at least 6 weeks.

## **IHP technique**

Briefly, the liver was mobilized from the diaphragm through a transverse abdominal incision. The common hepatic artery (8-Fr 77008 one-piece pediatric arterial cannula; Medtronic, Minneapolis, Minnesota, USA) and the portal vein (12-Fr perfex perfusion catheter CH12; B. Braun Medical, Oss, The Netherlands) were cannulated and connected to a heart-lung machine which consisted of two independent roller pumps (model 10-30-00; Cobe/Stöckert, Munich, Germany). The inferior vena cava (IVC) was cross-clamped above the hepatic veins and cannulated proximal of the renal veins (Polystan 36 Fr, straight, A/S, Værløse, Denmark) to allow undisturbed blood flow from the hepatic veins through the IVC towards the heart-lung machine. To isolate the hepatic circuit, tourniquets were secured around the hepatic artery, portal vein and IVC.

For the extracorporeal venovenous bypass, the right femoral vein (22-Fr cannula DI-ITF022L; Edwards Lifesciences, Irvine, California, USA) and the portal vein (17-Fr perfex perfusion catheter CH17; B. Braun) (proximal to the tourniquet) were cannulated and connected to the right axillary vein (18-Fr 7326 perfusion cannula; Lifestream International, The Woodlands, Texas, USA). The venovenous bypass was supported by a centrifugal pump (Medtronic BIO-Medicus, Eden Prairie, Minnesota, USA) and primed with 700 mL 0.9 % saline. The perfusion medium consisted of intrahepatically trapped blood and 1250 mL Gelofusine® (Vifor Medical, Sempach, Switzerland) plus 2500 units heparin (Leo Pharma, Breda, The Netherlands) to yield a final volume of approximately 2 liters. Throughout the 1-h perfusion interval, the perfusate was kept at a temperature of 39.5 °C by a heat exchanger and oxygenated using an oxygenator (Cobe VPCML; Cobe Cardiovascular, Arvada, Colorado, USA) except for the last patient who was oxygenated using a different oxygenator (Dideco D901, SORIN group Italia, Mirandola, Italy). After perfusion, the liver was flushed for approximately 10 minutes with 3 liters Gelofusine®. All cannulas and clamps were removed, and the incisions were closed. To prevent possible postoperative cholecystitis, cholecystectomy was performed.

## Melphalan

Melphalan 200mg (Alkeran<sup>®</sup>, GlaxoSmithKline, Zeist, The Netherlands) was first dissolved in 40 mL Wellcome Diluent (a 60/40 (v/v) mixture of proylene glycol containing 5.2% (v/v) ethanol and 0.068 mol/l sodium citrate), which was subsequently diluted with 60 mL sterile saline. Melphalan was administered as a bolus in the isolated hepatic circuit and in the last 30 patients through 20 minute infusion using an infusionpump (Pilote Anesthésie; Fresenius, Brezins, France) connected to the hepatic artery line of the isolated hepatic circuit.

## Leakage Detection

Leakage of perfusate into the systemic circuit was monitored by adding 10 MBq <sup>99m</sup>Tc-pertechnetate to the isolated circuit with subsequent measurement of the level of radioactivity in both the systemic and isolated circuit, as described previously <sup>19,20</sup>. If no leakage was detected, melphalan was administered; if leakage was calculated to exceed 10% during the perfusion period, the procedure was stopped and the liver was flushed just before this level was reached.

## Postoperative Care

All patients received a daily subcutaneous dose of 480 µg granulocyte colony-stimulating factor (G-CSF) (Filgrastim/Neupogen<sup>®</sup>; Amgen, Breda, The Netherlands) starting the day after the operation until the nadir in leukocyte count was reached and the count had risen to more than  $1.0 \times 10^9/L$ . Patients were monitored in the intensive care unit for at least 1 day after IHP. Liver and renal function tests and full blood counts were carried out daily in the first week and henceforth as indicated by their respective levels. Antibiotics in a combination of cefuroxim and metronidazol were given to all patients for 5 days after IHP.

## Toxicity

Systemic and regional toxicity were graded according to the National Cancer Institute Common Toxicity Criteria version 2.0. Hepatic toxicities were considered melphalan related, if elevations in liver function persisted beyond 7 days after perfusion, as previously suggested <sup>13</sup>.

## **Response evaluation**

Objective tumour response measurements were obtained by follow up CT scans of the liver and remaining abdomen at 3-month intervals after treatment and at 6-month intervals after 1 year. Additional imaging was performed if clinically indicated. All CT scans were reviewed using RECIST criteria to determine response rates. According to RECIST criteria lesions were only considered measurable if  $\geq 10$ mm, complete response was defined as disappearance of all known disease, partial response as a reduction in the sum of maximal diameters of measurable lesions of  $\geq 30\%$ , stable disease as a reduction of  $< 30\%$  or an increase of  $< 20\%$  and progressive disease as an increase of  $\geq 20\%$  or the appearance of new intra- or extrahepatic lesions<sup>21</sup>. Disease-free survival was calculated from the date of IHP until the date of local and/or systemic recurrence or death from any cause.

Serum carcinoembryonic antigen (CEA) levels were determined prior to treatment and at all follow-up visits.

## **Statistics**

All data were analyzed using SPSS (version 14.0) software and presented as mean  $\pm$  SD or median followed by the range. Survival was measured from the day of surgery until death or until the last day of follow up. Postoperative mortality was included in the response and survival analysis. For discrete variables univariate analysis was performed with the  $\chi^2$  test. Factors with  $P < 0.10$  in univariate analysis were entered in the multivariate analysis using logistic regression. Odds ratios are reported with 95 percent confidence intervals. Overall survival and disease progression analysis was analyzed using Kaplan-Meier curves, the log-rank test was used to identify differences in survival between groups. Factors with  $P < 0.10$  in univariate analysis were entered in the multivariate analysis using Cox's proportional hazards model. Hazard ratios are shown with 95 percent confidence intervals. All reported P values are two sided.

## **Results**

### **Patient and treatment characteristics**

Of the total of 154 colorectal cancer patients with unresectable liver metastases considered suitable for IHP, 105 (68%) were actually treated with IHP. At surgery 34 patients showed signs of extrahepatic disease not detected previously on imaging, 8 patients

showed more than 60 percent hepatic involvement of tumour tissue, 2 patients could not be treated due to a vascular anomaly and in 5 patients an isolated circuit could not be achieved due to excessive hemorrhage. After a median follow up of 85.4 months this group non-IHP patients showed a median overall survival of 10.1 months (range 1.6 – 66.2 months). They were excluded from further analysis. Demographics and tumour characteristics of the patients treated with IHP are listed in Table 1. Treatment parameters are

**Table 1** Patient and tumour characteristics

Characteristic	n (%)
No. of patients	105
Sex	
Male	78 (74)
Female	27 (26)
Age	
<60 years	70 (67)
≥60 years	35 (33)
Liver metastases	
Synchronous	67 (64)
Metachronous	38 (36)
No. of metastases	
<10	71 (68)
≥10	34 (32)
Estimated % of viable liver tissue	
≥90%	56 (53)
<90% and >60%	34 (33)
≤60%	15 (14)
Localization of primary tumour	
Right sided colon	13 (12)
Left sided colon and rectum	92 (88)
Pretreatment CEA level	
Normal (≤3.0 µg/mL)	15 (14)
Raised (>3.0 µg/mL)	89 (85)
Unknown	1 (1)
Median duration from diagnosis of liver metastases to IHP (months), [range]	4.8 [0.9-34.4]
Prior treatment directed at liver metastases	51 (48.6)
Chemotherapy <sup>a</sup>	
– Single agent 5FU based regimens	44 (78.6)
– Oxaliplatin based regimens	9 (16.1)
– Irinotecan based regimens	3 (5.9)
Hepatic Surgery	4 (3.8)

<sup>a</sup> In total 56 lines of chemotherapy were given to a total of 51 patients.



shown in Table 2. In 10 patients the perfusion did not take place for the full 60 minutes due to leakage. Two patients were perfused for 50 minutes, 1 for 45 minutes, 4 for 30 minutes, 1 for 25 minutes and two for 10 minutes. Between August 1997 and December 2000 patients received standard advice to undergo adjuvant systemic treatment, which at that time was standard protocol for all local treatments of liver metastases at our center. Whether patients did actually undergo adjuvant systemic treatment depended upon patient wishes and if referred to other centers, local policy. Seventeen (16%) patients received adjuvant chemotherapy after IHP. Fourteen patients received 5-FU/leucovorin based schedules, 2 patients received raltitrexed, while 1 patient was treated with irinotecan. Median follow up was 85.4 months (range 21.9 to 147.7 months).

### Toxicity and complications

Six patients died within 30 days after IHP because of progressive liver failure and multi-organ failure and 1 more patient died 3 months after IHP due to a liver abscess, resulting in an operative mortality of 7%. Major complications are listed in Table 2. Systemic toxicities are listed in Table 3. Grade 3 or 4 hepatotoxicity was present in 41 (39%) patients.

**Table 2** Treatment parameters

Parameter	Mean ± SD	n (%)
Perfusion		105
Hepatic artery and portal vein		99 (94)
Portal vein		6 (6)
Flow rate hepatic artery (mL/min)	337 ± 103	
Flow rate portal vein (mL/min)	294 ± 92	
pressure hepatic artery (mm/Hg)	105 ± 31	
pressure portal vein(mm/Hg)	33 ± 9	
Percentage leakage during perfusion	1.6 ± 2.3	
Blood loss (L)	5.7 ± 4.2	
Operative time (hr)	9.5 ± 1.5	
Hospital stay (days)	13 ± 7	
Perioperative mortality		7 (7)
Major complications		39 (37)
Veno-occlusive disease		9
Hepatic artery obstruction		2
Spleen rupture		3
Sepsis		2
Portal hypertension		2
Re-operation		11
Bleeding		9
Abscess		1
Ileus		1

**Table 3** Toxicity according to National Cancer Institute Common Toxicity Criteria version 2.0 (n=105)

	Grade 0	Grade 1	Grade 2	Grade 3	Grade 4
Leukocyte nadir	71.4% (75)	8.6% (9)	8.6% (9)	3.3% (1)	6.7% (2)
Bilirubin	39% (41)	32.4% (34)	10.5% (11)	11.4% (12)	6.7% (7)
Alkaline phosphatase	1.9% (2)	36.2% (38)	46.7% (49)	15.2% (16)	0% (0)
Alanine aminotransferase (ALAT)	13.3% (14)	38.1% (40)	28.6% (30)	18.1% (19)	1.9% (2)
Asparate aminotransferase (ASAT)	14.3% (15)	59% (62)	17.1% (18)	7.6% (8)	1.9% (2)

Sixteen (15%) patients experienced more than one grade 3 or 4 hepatotoxicity. Although some elevation persisted in the patients with either VOD or portal hypertension, the hepatotoxicity was transient in most patients. There was no significant difference in grade 3 or 4 hepatotoxicity between patients with or without chemotherapeutic prior to IHP (44.9% v 56%;  $P=0.44$ ).

### Tumour response

Seventy-two (81%) of the 89 patients with previously elevated CEA levels experienced a normalization or reduction of 50% or more 1 to 3 months after perfusion with a median duration of response of 6.3 months (range 1.6 to 107.8 months).

Hepatic and overall treatment responses were measured by comparing follow-up CT scans to the pretreatment scan, according to RECIST criteria. As 7 patients died postoperatively and 1 patient died within 3 months of progressive bone metastases, 97 patients were eligible for measurement of tumour response. Hepatic response rate (complete and partial remission) was 50% ( $N=52/105$ ) including 3 complete responses. Twenty-three patients (22%) had stable disease, whereas 22 patients (21%) immediately showed progressive disease. The median duration of hepatic response (complete and partial remission) was 11.4 months (range 5.2 to 108 months). Table 4 shows the results of univariate analysis for prognostic factors of hepatic response (complete or partial remission). Univariate analysis revealed that positive prognostic factors for hepatic response to IHP were female sex and adjuvant chemotherapy. Multivariate analysis confirmed the positive effect of adjuvant chemotherapy (odds ratio for complete or partial remission, 5.91; 95% CI, 1.54 to 22.6;  $P=0.009$ ), the effect of female sex was borderline significant (odds ratio for complete or partial remission, 2.65; 95% CI, 0.98 to 7.15;  $P=.05$ ).

**Table 4** Prognostic factors evaluated in univariate analysis in this study

Parameter	Hepatic Response		Progression-free survival (months)		Overall survival (months)	
	%	P	Median	P	median	P
Sex		.09		.86		.62
Male	49		7.3		24.8	
Female	68		7.7		21.3	
Age		.55		.10		.06
<60 years	52		7.6		26	
≥60 years	58		7.1		17.8	
Localization primary tumour		.11		.50		.17
Right sided	30		5		13.9	
Left sided	56		7.5		26	
No. of metastases		.35		.15		.01
<10	57		7.5		26.6	
≥10	47		6.9		17.2	
Estimated % of viable liver tissue		.38		.55		.08
≥90%						
<90% and >60%	58		7.3		30.3	
≤60%	44		5.7		19	
	62		7.8		20.6	
Chemotherapy directed at liver metastases prior to IHP		.63		.09		.44
Yes	56		6.9		22.7	
No	51		7.7		28.1	
Perfusion technique		.88		.61		.002
Hepatic artery and portal vein perfusion	54		7.4		25	
No hepatic artery perfusion	50		3.3		5.9	
Postoperative complications		.86		.42		.03
Yes	53		6.9		16.9	
No	54		7.7		27.4	
Adjuvant chemotherapy		.01		.01		.23
Yes	82		13.6		33	
No	48		6.8		24.5	
Extrahepatic metastases prior to IHP		.30		-		.008
Yes						
No	33		-		13.2	
	55		-		25	

Factors with P < 0.10 in univariate analysis were entered in the multivariate analysis using logistic regression.

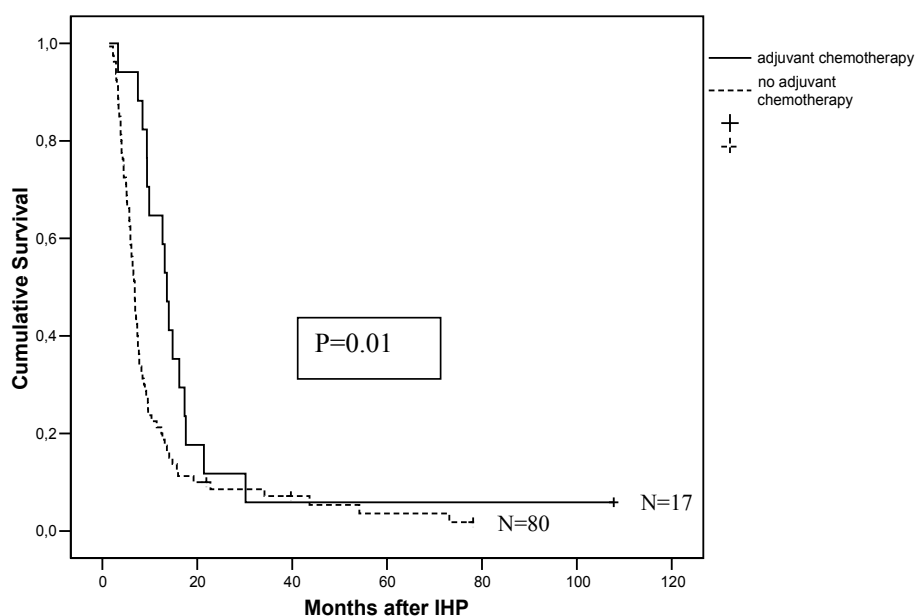
### Local and systemic failure

One patient died 8 months after IHP of progressive cholestasis before progression occurred. As seven patients died postoperatively, 97 patients were available for response evaluation. All patients, except 4, showed progressive disease during follow up. The

median progression-free survival was 7.4 months (range 1.4 to 107.8 months). Of the progressive patients, 63 (68%) showed hepatic progression, 13 (14%) extrahepatic progression and 17 (18%) a combination of both hepatic and extrahepatic progression. Of the hepatic progressive patients, 14 (17%) showed new hepatic lesions, 27 (34%) showed an increase of preexistent hepatic lesions and 39 (49%) showed a combination of both. Extrahepatic progression occurred mainly in the lungs (43%), intra-abdominal lymph nodes (27%) and cerebrum (10%). Other locations included bones, mediastinal lymph nodes and abdominal wall. In retrospect 7 (7%) patients showed extrahepatic disease prior to IHP. Univariate analysis revealed that positive prognostic factors for progression-free survival were: no chemotherapy prior to IHP and adjuvant chemotherapy following IHP ( $P=.09$  and  $P=.01$ , respectively; Table 4). Median progression-free survival was 13.6 months in the patients who received adjuvant chemotherapy, as compared to 6.8 months in the patients who were not treated with adjuvant chemotherapy (Figure 1). Cox multivariate analysis confirmed a statistically significant positive effect of adjuvant chemotherapy on progression-free survival ( $P=.039$ ; Table 5)

### Overall survival

Ten patients were still alive at the end of follow up. Seventy-nine (75%) patients received treatment directed at their metastases after progression following IHP. In total 73 (70%)



**Fig 1.** Progression-free survival after IHP with and without adjuvant chemotherapy. As patients were not randomized for adjuvant treatment, the difference, although remarkable could be due to selection bias.

**Table 5** Multivariate Cox proportional hazards model for progression-free survival

Parameter	OR	95%CI	P
Chemotherapy directed at liver metastases prior to IHP			.30
No	1		
Yes	1.3	0.82 to 1.93	
Adjuvant chemotherapy			.039
No	1		
Yes	0.55	0.32 to 0.97	

patients received cytostatic treatment. Three patients underwent a combined resection and ablation of their metastases, 6 patients received ablative treatment for their liver metastases, 4 patients underwent a hepatic resection and in 1 patient lung metastases were resected. The median overall survival was 24.8 months (range 0.3 to 108 months) with an observed 3-year and 5-year survival rate of 26% and 8% respectively. Patients with a complete or partial hepatic response to IHP showed a median overall survival of 32.7 months, as compared to 16.2 months for the non-responders ( $P < .0001$ ). The median survival since diagnosis of hepatic metastases was 31.8 months (range 1.83 to 110.7 months). Univariate analysis revealed a negative effect of increasing age and limited viable liver tissue, but only increasing number of metastases, absence of hepatic artery perfusion, postoperative complications and retrospective extrahepatic metastasis prior to IHP reached statistical significance ( $P = .01$ ,  $P = .002$ ,  $P = .03$  and  $P = .008$ , respectively; Table 4). Risk of death by Cox proportional hazards model was 1.5 for patients of 60 years and older, 1.9 for 10 or more liver metastases, 4 for absence of hepatic artery perfusion, 1.6 for the presence of postoperative complications and 2.2 for extrahepatic metastases prior to IHP ( $P = .058$ ,  $P = .006$ ,  $P = .002$ ,  $P = .048$  and  $P = .059$ , respectively; Table 6).

## Discussion

This study reports the results of IHP with 200 mg melphalan in 105 colorectal cancer patients. Hepatic response rate was 50% with a median progression free survival of 7.4 months and a median overall survival of 24.8 months. Although these results are promising little is known about the appropriate timing of IHP in the treatment of liver metastases of colorectal cancer patients and whether in this selected group of patients similar results could be achieved with systemic therapy alone. Recently Alexander *et al* showed IHP with melphalan to be safe and efficacious after irinotecan-based therapy<sup>14</sup>. In 25 patients progressive after irinotecan-based therapy the median time to progression after IHP was 5 months, while the median overall survival was 12 months. In our study 51 patients received chemotherapy prior to IHP, mainly 5FU-based monotherapy schedules, with some patients having received either irinotecan or oxaliplatin. Hepa-

**Table 6** Multivariate Cox proportional hazards model for overall survival

Parameter	OR	95%CI	P
Age			.058
<60 years	1		
≥60 years	1.52	0.99 to 2.36	
No. of metastases			.006
<10	1		
≥10	1.95	1.21 to 3.12	
Estimated % of viable liver tissue			.25
≥90%	1		
<90% and >60%	1.4	0.87 to 2.26	
≤60%	1.54	0.80 to 2.94	
Perfusion technique			.003
Hepatic artery and portal vein perfusion	1		
No hepatic artery perfusion	4.15	1.68 to 10.27	
Postoperative complications			.048
No	1		
Yes	1.54	1 to 2.36	
Extrahepatic metastases prior to IHP			.059
No	1		
Yes	2.23	0.97 to 5.11	

toxicity and hepatic response rate did not differ between patients who were pretreated with chemotherapy or not, suggesting IHP is an option for both first and second line treatment of colorectal liver metastases. The past decade, as our trial was conducted, the application of liver resection has widened, by downstaging liver metastases through neoadjuvant chemotherapy, further complicating the role and timing of IHP<sup>22</sup>. In view of the above, different treatment algorithms seem possible, patients could first receive systemic treatment to see if downstaging is possible and receive IHP in case of treatment failure. However, patients with a poor response to chemotherapy often show a performance status unsuitable for IHP. Therefore, in a selected group of patients, IHP could also be considered first line treatment followed by liver resection if downstaging occurs. In our study, only 4 patients underwent hepatic resection after IHP, limiting the results on efficacy and toxicity, warranting further investigation.

The recent increasing success in the development of systemic treatment of colorectal cancer patients has caused a shift in interest away from regional treatment options. Nevertheless IHP, contrary to systemic treatment, has been shown to result in long-term survival with an actual 5-year survival rate of approximately 9%<sup>12</sup>. Although regional treatments offer the benefit of limited systemic toxicity, they are often associated with operative morbidity and even in some cases mortality. Recent studies show perioperative mortality rates around 5% in IHP<sup>12,13,15</sup>. Ideally patients should be selected who will benefit most from this procedure. Several studies have focused on the effect of age,

tumor size, number of metastases and extrahepatic disease on disease-free and overall survival after resection cryoablation and RFA<sup>17, 23-25</sup>, while to our knowledge no such studies exist concerning IHP. Berber *et al* examined the prognostic factors after RFA in 135 colorectal cancer patients<sup>17</sup>. They identified number and size of liver metastases, serum CEA level as prognostic factors for overall survival in univariate analysis and tumour size in multivariate analysis. Thirty-three percent of their patients had extrahepatic disease prior to RFA, remarkably this did not effect overall survival. In our study we determined parameters that identified the patients with superior results after IHP for colorectal cancer liver metastases. We found absence of hepatic artery perfusion, postoperative complications, number of metastases, age and presence of extrahepatic disease prior to IHP as evaluated retrospectively, of prognostic significance for overall survival in univariate analysis. In multivariate analysis only the first three remained statistically significant. Although the presence of extrahepatic disease prior to IHP did not reach significance ( $P=.059$ ) for overall survival in multivariate analysis, a clear trend could be observed.

Elias *et al* reported the results 506 colorectal cancer patients who underwent a laparotomy and then a resection for liver metastases<sup>26</sup>. Prior to laparotomy CT scan and liver ultrasonography were performed. Unsuspected metastases were discovered in 209 (41.3%) patients; extrahepatic metastases in 82 (16.2%) patients, additional liver metastases in 152 (30%) patients and both in 25 (4.9%) patients.

Patients in our study were subjected to a spiral CT scan of both abdomen and thorax prior to enrollment and CT AP. Nevertheless, similarly to the results of Elias *et al*, 34 (22%) in our study were found to have extrahepatic disease preoperatively and did not undergo IHP. Recently percutaneous IHP procedures have been developed to enable a less invasive and repeatable procedure<sup>27,28</sup>. A percutaneous approach would inhibit preoperative detection of these extrahepatic metastases and could lead to the unnecessary treatment with IHP. The preoperative detection modality of colorectal metastases has been the subject of much debate<sup>29-31</sup>. Truant *et al* reported a prospective double-blind comparison of FDG-PET and thoracoabdominal CT scan in 53 patients with potentially resectable liver metastases from colorectal cancer<sup>31</sup>. The sensitivity of PET was equivalent to that of CT (both 79%), but was superior for extrahepatic abdominal sites (63% and 25% respectively). PET, on the other hand, falsely upstaged three patients. Selzner *et al* reported the results of a prospective comparison between contrast-enhanced CT scan and FDG-PET in 76 colorectal cancer patients evaluated for liver resection<sup>29</sup>. CT and PET provided comparable sensitivity for the detection of intrahepatic metastases. However, extrahepatic disease was missed in one third of the cases using CT (sensitivity 64%), while PET failed to detect extrahepatic lesions in only 11% of the cases (sensitivity 89%). The introduction of a standard PET scan in our pre-IHP work up would probably reduce

the number of patients undergoing unnecessary laparotomies. On the other hand both the number of false positive patients and imaging-associated costs would increase substantially. Nevertheless, to decrease both the number of patients treated with IHP with extrahepatic disease (associated with significantly reduced overall survival) and the number of unnecessary laparotomies, preoperative work up needs to be improved. Possibly a selection of patients with an increased a priori chance of extrahepatic metastases should undergo PET-scanning prior to IHP.

Yan *et al* studied the prognostic factors for progression-free survival in 135 colorectal cancer patients treated with cryoablation with or without resection<sup>32</sup>. Pre- and post-operative CEA, size and number of metastases were prognostic factors for progression free survival. In our study tumor load as estimated by remaining percentage of viable liver tissue and number of metastases did not influence progression-free survival. Adjuvant chemotherapy, on the other hand, did influence progression free survival in both univariate and multivariate analysis. However, this therapy was not randomized and partially given based on the personal opinion of patients respective medical oncologists. A recent meta-analysis of seven randomized controlled trials comparing resection or RFA with observation to resection or RFA with adjuvant hepatic artery chemotherapy could not detect a survival benefit for the chemotherapy group<sup>33</sup>. Portier *et al* reported the results of a randomized control trial of adjuvant systemic 5FU and folinic acid compared with surgery alone after resection of colorectal liver metastases<sup>34</sup>. In a multicenter trial 173 patients with R0 resected hepatic metastases were randomly assigned to surgery alone or to surgery followed by 6 months of systemic adjuvant chemotherapy with a 5-fluorouracil and folinic acid monthly regimen. The 5-year progression-free survival rate was 33.5% for patients in the chemotherapy group and 26.7% for the patients in the control group ( $P=0.028$ ). A trend towards increased overall survival for the chemotherapy group was observed, but did not reach statistical significance. Although our study was not designed to compare IHP alone to IHP with adjuvant systemic treatment the difference in disease-free survival for the 17 patients who received adjuvant treatment was remarkable. Nonetheless selection bias can not be excluded, therefore studies with adjuvant chemotherapy after IHP should be considered.

In conclusion, the results of this study are encouraging and add to the currently available data on IHP. This is the first study to identify prognostic factors in patients who are treated with IHP. More than 10 liver metastases, absence of the ability to perfuse through the hepatic artery and postoperative complications adversely influence the overall survival, while adjuvant chemotherapy improves the hepatic response and progression-free survival. An improvement of overall and disease-free survival after IHP is likely if preoperative screening is improved and adjuvant chemotherapy is administered.



## References

1. Weiss L, Grundmann E, Torhorst J et al. Haematogenous metastatic patterns in colonic carcinoma: an analysis of 1541 necropsies. *J Pathol* 1986;150(3):195-203.
2. Welch JP, Donaldson GA. The clinical correlation of an autopsy study of recurrent colorectal cancer. *Ann Surg* 1979;189(4):496-502.
3. Scheele J, Stang R, Altendorf-Hofmann A, Paul M. Resection of colorectal liver metastases. *World J Surg* 1995;19(1):59-71.
4. Nordlinger B, Guiguet M, Vaillant JC et al. Surgical resection of colorectal carcinoma metastases to the liver. A prognostic scoring system to improve case selection, based on 1568 patients. Association Francaise de Chirurgie. *Cancer* 1996;77(7):1254-1262.
5. Yamamoto J, Shimada K, Kosuge T, Yamasaki S, Sakamoto M, Fukuda H. Factors influencing survival of patients undergoing hepatectomy for colorectal metastases. *Br J Surg* 1999;86(3):332-337.
6. Cunningham D, Humblet Y, Siena S et al. Cetuximab monotherapy and cetuximab plus irinotecan in irinotecan-refractory metastatic colorectal cancer. *N Engl J Med* 2004;351(4):337-345.
7. de Gramont A, Figer A, Seymour M et al. Leucovorin and fluorouracil with or without oxaliplatin as first-line treatment in advanced colorectal cancer. *J Clin Oncol* 2000;18(16):2938-2947.
8. Douillard JY, Cunningham D, Roth AD et al. Irinotecan combined with fluorouracil compared with fluorouracil alone as first-line treatment for metastatic colorectal cancer: a multicentre randomised trial. *Lancet* 2000;355(9209):1041-1047.
9. Hurwitz H, Fehrenbacher L, Novotny W et al. Bevacizumab plus irinotecan, fluorouracil, and leucovorin for metastatic colorectal cancer. *New England Journal of Medicine* 2004;350(23):2335-2342.
10. Saltz LB, Cox JV, Blanke C et al. Irinotecan plus fluorouracil and leucovorin for metastatic colorectal cancer. Irinotecan Study Group. *N Engl J Med* 2000;343(13):905-914.
11. Tournigand C, Andre T, Achille E et al. FOLFIRI followed by FOLFOX6 or the reverse sequence in advanced colorectal cancer: A randomized GERCOR study. *Journal of Clinical Oncology* 2004;22(2):229-237.
12. Rothbarth J, Pijl ME, Vahrmeijer AL et al. Isolated hepatic perfusion with high-dose melphalan for the treatment of colorectal metastasis confined to the liver. *Br J Surg* 2003;90(11):1391-1397.
13. Alexander HR, Jr., Bartlett DL, Libutti SK, Fraker DL, Moser T, Rosenberg SA. Isolated hepatic perfusion with tumor necrosis factor and melphalan for unresectable cancers confined to the liver. *J Clin Oncol* 1998;16(4):1479-1489.
14. Alexander HR, Jr., Libutti SK, Pingpank JF, Bartlett DL, Helsabeck C, Beresneva T. Isolated hepatic perfusion for the treatment of patients with colorectal cancer liver metastases after irinotecan-based therapy. *Ann Surg Oncol* 2005;12(2):138-144.
15. Bartlett DL, Libutti SK, Figg WD, Fraker DL, Alexander HR. Isolated hepatic perfusion for unresectable hepatic metastases from colorectal cancer. *Surgery* 2001;129(2):176-187.
16. Solbiati L, Livraghi T, Goldberg SN et al. Percutaneous radio-frequency ablation of hepatic metastases from colorectal cancer: long-term results in 117 patients. *Radiology* 2001;221(1):159-166.
17. Berber E, Pelley R, Siperstein AE. Predictors of survival after radiofrequency thermal ablation of colorectal cancer metastases to the liver: a prospective study. *J Clin Oncol* 2005;23(7):1358-1364.
18. van Iersel LB, Verlaan MR, Vahrmeijer AL et al. Hepatic artery infusion of high-dose melphalan at reduced flow during isolated hepatic perfusion for the treatment of colorectal metastases confined to the liver: A clinical and pharmacologic evaluation. *Eur J Surg Oncol* 2007;33(7):874-881.

19. Marinelli A, de Brauw LM, Beerman H et al. Isolated liver perfusion with mitomycin C in the treatment of colorectal cancer metastases confined to the liver. *Jpn J Clin Oncol* 1996;26(5):341-350.
20. Runia RD, de Brauw LM, Kothuis BJ, Pauwels EK, van de Velde CJ. Continuous measurement of leakage during isolated liver perfusion with a radiotracer. *Int J Rad Appl Instrum B* 1987;14(2):113-118.
21. Therasse P, Arbuck SG, Eisenhauer EA et al. New guidelines to evaluate the response to treatment in solid tumors. European Organization for Research and Treatment of Cancer, National Cancer Institute of the United States, National Cancer Institute of Canada. *J Natl Cancer Inst* 2000;92(3):205-216.
22. Bismuth H, Adam R, Levi F et al. Resection of nonresectable liver metastases from colorectal cancer after neoadjuvant chemotherapy. *Ann Surg* 1996;224(4):509-520.
23. Mulier S, Ni Y, Jamart J, Ruers T, Marchal G, Michel L. Local recurrence after hepatic radiofrequency coagulation: multivariate meta-analysis and review of contributing factors. *Ann Surg* 2005;242(2):158-171.
24. van Duijnhoven FH, Jansen MC, Junggeburst JM et al. Factors influencing the local failure rate of radiofrequency ablation of colorectal liver metastases. *Ann Surg Oncol* 2006;13(5):651-658.
25. Fong Y, Fortner J, Sun RL, Brennan MF, Blumgart LH. Clinical score for predicting recurrence after hepatic resection for metastatic colorectal cancer: analysis of 1001 consecutive cases. *Ann Surg* 1999;230(3):309-318.
26. Elias D, Sideris L, Pocard M et al. Incidence of unsuspected and treatable metastatic disease associated with operable colorectal liver metastases discovered only at laparotomy (and not treated when performing percutaneous radiofrequency ablation). *Ann Surg Oncol* 2005;12(4):298-302.
27. van Etten B, Brunstein F, van IJken MG et al. Isolated hypoxic hepatic perfusion with orthograde or retrograde flow in patients with irresectable liver metastases using percutaneous balloon catheter techniques: a phase I and II study. *Ann Surg Oncol* 2004;11(6):598-605.
28. Pingpank JF, Libutti SK, Chang R et al. Phase I study of hepatic arterial melphalan infusion and hepatic venous hemofiltration using percutaneously placed catheters in patients with unresectable hepatic malignancies. *J Clin Oncol* 2005;23(15):3465-3474.
29. Selzner M, Hany TF, Wildbrett P, McCormack L, Kadry Z, Clavien PA. Does the novel PET/CT imaging modality impact on the treatment of patients with metastatic colorectal cancer of the liver? *Ann Surg* 2004;240(6):1027-1034.
30. Arulampalam TH, Francis DL, Visvikis D, Taylor I, Ell PJ. FDG-PET for the pre-operative evaluation of colorectal liver metastases. *Eur J Surg Oncol* 2004;30(3):286-291.
31. Truant S, Huglo D, Hebban M, Ernst O, Steinling M, Pruvot FR. Prospective evaluation of the impact of [18F]fluoro-2-deoxy-D-glucose positron emission tomography of resectable colorectal liver metastases. *Br J Surg* 2005;92(3):362-369.
32. Yan TD, Nunn DR, Morris DL. Recurrence after complete cryoablation of colorectal liver metastases: analysis of prognostic features. *Am Surg* 2006;72(5):382-390.
33. Nelson R, Freels S. Hepatic artery adjuvant chemotherapy for patients having resection or ablation of colorectal cancer metastatic to the liver. *Cochrane Database Syst Rev* 2006;(4):CD003770.
34. Portier G, Elias D, Bouche O et al. Multicenter randomized trial of adjuvant fluorouracil and folinic acid compared with surgery alone after resection of colorectal liver metastases: FFCD ACHBTH AURC 9002 trial. *J Clin Oncol* 2006;24(31):4976-4982.



---

# CHAPTER 5

## **Management of isolated non-resectable liver metastases in colorectal cancer patients: a case-control study of isolated hepatic perfusion with melphalan versus systemic chemotherapy**

L.B.J. van Iersel<sup>1</sup>, M. Koopman<sup>2</sup>, C.J.H. van de Velde<sup>3</sup>, L. Mol<sup>4</sup>,  
E.L. van Persijn van Meerten<sup>5</sup>, H.H. Hartgrink<sup>3</sup>, P.J.K. Kuppen<sup>3</sup>,  
A.L. Vahrmeijer<sup>3</sup>, J.W.R. Nortier<sup>1</sup>, R.A.E.M. Tollenaar<sup>3</sup>, C. Punt<sup>2</sup>,  
H. Gelderblom<sup>1</sup>

Department of Clinical Oncology<sup>1</sup>, Radiology<sup>5</sup> and Surgery<sup>3</sup>,  
Leiden University Medical Center, P.O. Box 9600, 2300 RC,  
Leiden, The Netherlands

Department of Medical Oncology<sup>2</sup>, Radboud University  
Nijmegen Medical Center, P.O. Box 9101, 6500 HB, Nijmegen,  
The Netherlands

Comprehensive Cancer Centre East (IKO)<sup>4</sup>, Nijmegen,  
The Netherlands

*Ann Oncol.* 2010 Aug;21(8):1662-7

---

## Abstract

To compare the median overall survival of patients with isolated non-resectable liver metastases in comparable groups of patients treated with either isolated hepatic perfusion (IHP) with melphalan or systemic chemotherapy

All patients with isolated liver metastases from colorectal cancer origin, who underwent IHP with 200mg melphalan between August 1994 and December 2004, through both the portal vein and hepatic artery, were included in this study. The control group consisted of a subgroup of colorectal cancer patients with liver metastases only, who were enrolled in the randomized CApecitabine, IRinotecan, Oxaliplatin (CAIRO) phase III study between January 2003 and December 2004.

Ninety-nine patients were treated with IHP, and 111 patients were included in the control group. All patient characteristics were comparable except for age. Median follow up was 78.1 months for IHP versus 54.7 months in the control group. Median overall survival was 25.0 (95% CI 19.4-30.6) months for IHP and 21.7 (95% CI 19.6-23.8) months for systemic treatment ( $P=0.29$ ). Overall survival was not influenced by gender, age, LDH, location of primary tumor, timing of liver metastases and adjuvant treatment of the primary tumor and was only influenced by metastasectomy after study treatment ( $P<0.001$ ). However, the number of patients in whom metastasectomy was performed did not differ significantly between the two groups. Treatment-related mortality was 2% for the systemic treatment and 6% for IHP ( $P=0.11$ ).

Compared to a patient group with comparable characteristics treated with systemic chemotherapy, IHP does not provide a benefit in overall survival in patients with isolated non-resectable colorectal liver metastases. Currently the use of IHP cannot be advocated outside the scope of clinical studies.

## Introduction

The treatment of patients with metastatic colorectal cancer is with palliative intent, and with standard cytotoxic drugs median overall survival times of approx. 17 months can be achieved, which may be further improved by the use of targeted agents<sup>1</sup>. Long-term survival and sometimes cure may be achieved in the subset of patients in whom a radical resection of metastases can be performed. The liver is the only site of metastatic disease in approximately 30% of colorectal cancer patients<sup>2,3</sup>. Although complete surgical resection is considered the treatment of choice, with 5-year survival rates ranging from 25-51%, metastasectomy is only possible in less than 10 percent of patients, due to the number, location or size of the metastases<sup>4,6</sup>. The treatment of non-resectable colorectal liver metastases remains a challenge for both medical oncologists and surgeons. Down-sizing of metastases by chemotherapy may allow secondary resections in a minority of patients, but the clinical benefit is uncertain due to the lack of prospective randomized studies<sup>1</sup>. Regional cytotoxic treatment options can offer the potential benefit of both aggressive local treatment and limited systemic toxicity. Phase II studies involving isolated hepatic perfusion (IHP) in colorectal cancer patients have shown hepatic response rates up to 74% with a median time to hepatic progression up to 14.5 months, a median overall survival of 27 months and 5 year survival of 9%<sup>7-11</sup>. Currently, new techniques and agents are applied to further improve the results of IHP<sup>12,13</sup>. Although these results seem promising, so far the definite role of IHP has not been established. Possibly, in this selected group of patients, similar results can be achieved with systemic therapy alone. Since a randomized controlled trial comparing IHP, a complex surgical procedure with considerable mortality, with systemic treatment appears not feasible as well as possibly unethical, we performed a case-control study. In this study, we compared the overall survival after IHP treatment and systemic treatment in comparable patient groups. Our results on IHP were obtained in a time period in which targeted therapy was not yet implemented, and therefore we selected a control group that also had not been exposed to these agents. Since the overall survival of patients with metastatic colorectal cancer correlates with the exposure of patients to all three effective cytotoxic drugs (i.e. a fluoropyrimidine, oxaliplatin and irinotecan)<sup>14</sup>, we chose our control group from a prospective study in which the use of all these drugs was a prospective part of the study design<sup>15</sup>.

## Patients and methods

### IHP

Between August 1994 and December 2004, 179 patients with liver metastases were considered suitable for IHP treatment with 200mg melphalan, according to a study protocol approved by the medical ethical committee of the Leiden University Medical Center, as previously published <sup>7, 16, 17</sup>. Of the 105 of the 179 consecutive patients with colorectal cancer who were actually treated with IHP, 6 patients were excluded because they were treated with IHP with vena porta perfusion only, a technique which has been abandoned <sup>17</sup>. Therefore 99 patients were included in this analysis. The data were obtained from a prospectively collected database and analyzed retrospectively. All IHP patients had measurable, irresectable colorectal metastases confined to the liver. Standard staging procedures were performed including CT scan of the chest and abdomen. Additional MRI or PET scans were performed if clinically indicated. Eligibility criteria included a WHO performance status < 2, leukocyte count  $\geq 3.0 \times 10^9/L$ , platelet count  $\geq 100 \times 10^9/L$ , maximum serum creatinine level 135  $\mu\text{mol/L}$ , maximum serum bilirubin level 17  $\mu\text{mol/L}$  and minimum serum albumin level 40 g/L. Exclusion criteria were age over 70 years, life expectancy of less than 4 months, more than 60 percent hepatic involvement of tumor tissue as estimated from the preoperative abdominal CT scan, coagulation disorders and evidence of extrahepatic metastatic disease. The interval between resection of the primary colorectal tumor and perfusion had to be at least 6 weeks.

### Systemic treatment

Between January 2003 and December 2004, 803 patients were enrolled in the CApecitabine, IRinotecan, Oxaliplatin (CAIRO) study of the Dutch Colorectal Cancer Group (DCCG): a phase III randomized controlled trial comparing sequential versus combination chemotherapy with capecitabine, irinotecan and oxaliplatin in advanced colorectal cancer patients <sup>15</sup>. Patients aged over 18 years were eligible if they had histologically proven advanced colorectal cancer that was in an advanced stage and not amenable to curative surgery, together with measurable or assessable disease parameters, and no previous systemic treatment for advanced disease. Previous adjuvant chemotherapy was allowed provided that the last administration was given at least 6 months before randomization. Further study details have been presented <sup>15</sup>. The primary result of the CAIRO study showed no significant overall survival benefit for combination versus sequential treatment. Therefore patients from both treatment arms were considered eligible for the control group of this study. Exact details on percentage of liver involvement, as was necessary for IHP, were not obtained.

## **Comparison IHP and systemic treatment**

The following patients were included from the CAIRO study for comparison with IHP patients with liver metastases only, WHO performance status < 2, age ≤ 70 years, and previous resection of the primary tumor. A total of 111 patients of the CAIRO study fulfilled these criteria and were included for the current analysis.

### **IHP treatment**

The IHP technique was applied as described in the previously published articles <sup>7, 16, 17</sup>. In summary: melphalan 200mg (Alkeran<sup>®</sup>, GlaxoSmithKline, Zeist, The Netherlands) was first dissolved in 40 mL Wellcome Diluent (a 60/40 (v/v) mixture of proylene glycol containing 5.2% (v/v) ethanol and 0.068 mol/l sodium citrate), which was subsequently diluted with 60 mL sterile saline. Melphalan was administered as a bolus in the isolated hepatic circuit and in the last 30 patients through 20 minute infusion using an infusionpump (Pilote Anesthésie; Fresenius, Brezins, France) connected to the hepatic artery line of the isolated hepatic circuit. Leakage of perfusate into the systemic circuit was monitored by adding 10 MBq <sup>99m</sup>Tc-pertechnetate to the isolated circuit with subsequent measurement of the level of radioactivity in both the systemic and isolated circuit, as described previously <sup>18, 19</sup>. If no leakage was detected, melphalan was administered; if leakage was calculated to exceed 10% during the perfusion period, the procedure was stopped and the liver was flushed just before this level was reached. Postoperatively, all patients received a daily subcutaneous dose of 480 µg granulocyte colony-stimulating factor (G-CSF) (Filgrastim/Neupogen<sup>®</sup>; Amgen, Breda, The Netherlands) starting the day after the operation until the nadir in leukocyte count was reached and the count had risen to more than  $1.0 \times 10^9/L$ . Liver and renal function tests and full blood counts were carried out daily in the first week and henceforth as indicated by their respective levels. Antibiotics in a combination of cefuroxim and metronidazol were given to all patients for 5 days after IHP.

### **Systemic treatment**

Eligible patients were randomly assigned to either sequential or combination treatment in a 1:1 ratio, as described previously <sup>15</sup>. All treatment cycles were administered at intervals of 3 weeks. In the sequential treatment group, first-line treatment consisted of capecitabine (1250 mg/m<sup>2</sup> twice daily) for 14 days, second-line treatment of irinotecan (350 mg/m<sup>2</sup>) on day 1, and third-line treatment of capecitabine (1000 mg/m<sup>2</sup> twice daily) for 14 days plus oxaliplatin (130 mg/m<sup>2</sup>) on day 1. Patients assigned to combination treatment received capecitabine (1000 mg/m<sup>2</sup> twice daily) for 14 days plus irinotecan



(250 mg/m<sup>2</sup>) on day 1 as first-line treatment, and capecitabine (1000 mg/m<sup>2</sup>) twice daily for 14 days plus oxaliplatin (130 mg/m<sup>2</sup>) on day 1 as second-line treatment.

## Statistics

All data were analyzed using SPSS (version 16.0) software and presented as mean +/- SD or median followed by the range. Survival was measured from the day of surgery or randomization until death or until the last day of follow up. Postoperative mortality was included in survival analysis. For discrete variables univariate analysis was performed with the  $\chi^2$  test. Overall survival and disease progression analysis was analyzed using Kaplan-Meier curves, the log-rank test was used to identify differences in survival between groups. All tests were two-sided and p values of less than 0.05 were deemed to be significant.

## Results

### Patient and treatment characteristics

In total 99 patients were treated with IHP and 111 patients were treated with systemic treatment. The median duration of follow up was significantly shorter in the systemic treatment patients compared to the IHP patients, 54.7 (95% CI 48.5-60.9) versus 78.1 (95% CI 52.1-104.2) months (P=0.004). Patient characteristics, shown in table 1, were similar in both treatment groups, except for age. The systemic treatment patients were significantly older than IHP patients (P<0.01). Serum LDH, a known prognostic factor, did not differ between both groups (P=0.43). The number of patients who received previous adjuvant chemotherapy did not differ significantly (P=0.78) from those who did not receive adjuvant treatment. Chemotherapy directed at liver metastases prior to IHP was offered to 49 patients.

Details on IHP treatment are shown in table 2. Blood loss, operative time and duration of hospital stay in the IHP group were similar to previous reports<sup>16, 17</sup>. Perioperative mortality was 6%, which is lower than previously published by our group, due to the exclusion of portal vein perfusions. Overall response rate in the IHP group was 47%. , and the median time to disease progression was 7.3 (95% CI 6.5-8.0) months. Sixteen IHP patients received adjuvant systemic treatment after IHP, while 72 patients received systemic treatment directed at progressive metastases after IHP. None of the patients received bevacizumab and only one patient received cetuximab as part of the treatment.

**Table 1.** Patient characteristics

Parameter	IHP N=99 (%)	SYSTEMIC TREATMENT CONTROL GROUP N=111(%)	P
Age			P<0.01
<50 years	26 (26)	12 (11)	
≥50-<60 years	42 (43)	38 (34)	
≥60 years	31 (31)	61 (55)	
Sex			P=0.58
male	73 (74)	78 (70)	
female	26 (26)	33 (30)	
Site of primary tumor			P=0.05
Rectum	38 (38)	26 (23)	
Rectosigmoid	8 (8)	8 (8)	
Colon	53 (54)	77 (69)	
LDH prior to start treatment			P=0.43
Normal	59 (60)	72 (65)	
Abnormal	40 (40)	39 (35)	
Liver metastases			P=0.72
Synchronous	84 (85)	94 (85)	
Metachronous	15 (15)	17 (15)	
Previous adjuvant treatment *			P=0.78
No	92 (93)	102 (92)	
Yes	7 (7)	9 (8)	

\* Previous systemic treatment was only allowed in the IHP group. In total 49 patients in the IHP group received systemic treatment prior to IHP.

Details on systemic treatment in the control group of CAIRO patients are shown in table 3. Sixty patients had been randomized to combination treatment (first-line treatment capecitabine plus irinotecan and second-line capecitabine plus oxaliplatin), and 51 patients to sequential treatment (first-line treatment with capecitabine, second-line irinotecan, and third-line capecitabine plus oxaliplatin). In the combination treatment group 68% of patients received both first- and second-line treatment. In the sequential treatment group 55% of patients received all three lines of chemotherapy. Overall response rate of first-line treatment was 41%. All except four patients showed progressive disease during follow-up. The median time to disease progression upon first-line treatment was 7.9 (95% CI 6.8–8.9) months. Of the progressive patients,

26 patients showed new lesions, 44 showed an increase in preexistent lesions, 23 showed a combination of the above, 1 showed local recurrence and in 13 patients, the location of progression was unknown.

**Table 2.** Details of IHP treatment (N=99)

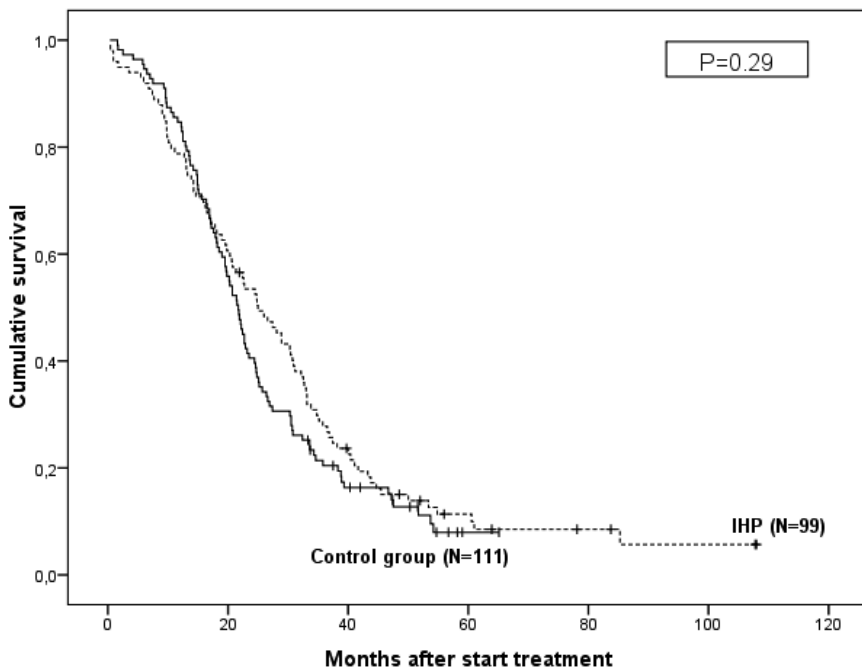
Parameter	Mean ± SD	N(%)
Blood loss (l)	5.7 ± 4.3	
Operative time (h)	9.5 ± 1.4	
Hospital stay (days)	12.7 ± 6.9	
Perioperative mortality		6 (6)
Major complications		35 (35)
Grade 3-4 toxicities		
Liver function		37 (37)
Hematological		10 (10)
Median duration of follow up (months), (95% CI)	78.1 (52.1-104.2)	
Overall response (RECIST)		
Complete		3 (3)
Partial		44 (44)
Stable		22 (22)
Progressive		24 (24)
Median time to progression (months), (95% CI)	7.3 (6.5-8.0)	

**Table 3.** Details of systemic treatment in control group (N=111)

Parameter	Mean ± SD	N(%)
Systemic treatment		
Combination treatment		60 (54)
First-line		60 (100)
Second-line		41 (68)
Sequential treatment		51 (46)
First-line		51 (100)
Second-line		40 (78)
Third-line		28 (55)
Median number of cycles per patients		
First-line	9.7 ± 7.4	
Second-line	7.2 ± 4.8	
Third-line	5.1 ± 2.2	
Grade 3-4 toxicities		58 (52)
Median duration of follow up (months) (95% CI)	54.7 (48.5-60.9)	
Overall response first-line (RECIST)		
Complete		9 (8)
Partial		32 (29)
Stable		45 (41)
Progressive		17 (15)
Median time to progression after first-line treatment (months) (95% CI)	7.9 (6.8-8.9)	

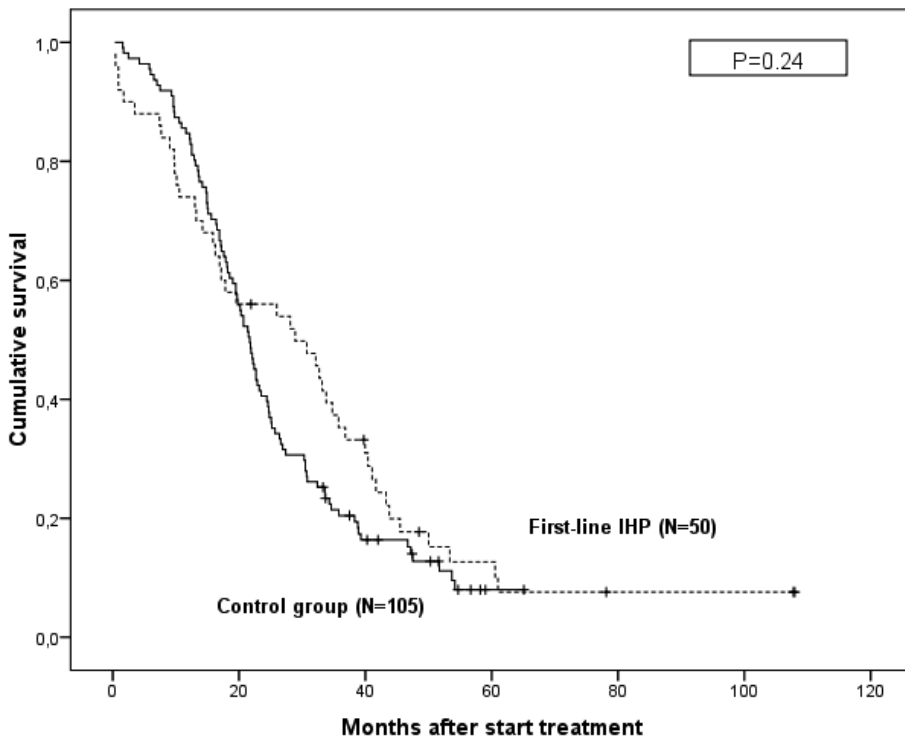
## Overall survival

Overall survival curves are shown in figure 1. Median overall survival was 25.0 (95% CI 19.4-30.6) months for the patients who were treated with IHP and 21.7 (95% CI 19.6-23.8) months for the patients who were treated with systemic chemotherapy only. Comparison of Kaplan-Meier curves by the log-rank test showed no significant difference between the two treatment groups ( $P=0.29$ ). Overall survival of both treatment groups was not influenced by gender, age, LDH, location of primary tumor, timing of liver metastases and adjuvant treatment of the primary tumor ( $P=0.28$ ;  $P=0.31$ ;  $P=0.26$ ;  $P=0.88$ ;  $P=0.74$ ;  $P=0.36$ , respectively). Overall survival was only influenced by metastasectomy after study treatment. Median overall survival in the patients who underwent metastasectomy was 47.2 (95% CI 29.5-64.9) months compared to 21.5 (95% CI 19.6-23.4) months in the patients who did not undergo metastasectomy ( $P<0.001$ ). Metastasectomy, however was evenly distributed over IHP and systemic treatment arms, 6 and 9 patients respectively ( $P=0.57$ ). Treatment-related mortality was 2% for the systemic treatment and 6% for IHP ( $P=0.11$ ).



**Figure 1.** Overall survival curves of patients with liver metastases only treated with either IHP or systemic treatment.

A subgroup analysis was performed of the IHP patients (N=50) who received IHP as first-line treatment (figure 2), to exclude any survival disadvantage due to earlier treatment and diagnosis of liver metastases in this group of patients. Median overall survival in this subgroup increased to 28.9 (95% CI 14.2-43.6) months, but was not significantly different as compared to systemic treatment (P=0.24). As the two groups have different lengths of follow up a statistical error could arise when comparing the actuarial survival only. Therefore the actual 2-, 3- and 4-year survival rates were also calculated and compared. The 2-, 3- and 4-year survival rates for IHP patients were 53%, 28% and 14% respectively. The 2-, 3- and 4-year survival rates for the systemic treatment patients were 41%, 19% and 10% and did not differ significantly from the IHP survival rates (P=0.11; P=0.20; P=0.25, respectively). Similar to the actuarial survival, the 2-, 3- and 4-year survival rates were only influenced by metastasectomy.



**Figure 2.** Overall survival of IHP patients who did not receive systemic treatment prior to IHP compared to control group.

## Discussion

Over the past decade, several regional treatment options like hepatic artery infusion (HAI), radiofrequency ablation (RFA) and IHP have been studied extensively for the treatment of irresectable colorectal liver metastases. IHP has never been compared to systemic treatment and its definite role in the treatment of isolated liver metastases has not yet been established. To our knowledge this is the first attempt to compare the outcome of IHP with standard systemic treatment. Our study shows no significant survival benefit for IHP over systemic treatment with capecitabine, irinotecan and oxaliplatin.

Obviously, our study design shows several limitations. Firstly, the survival analysis is based on a nonrandomized case-control study. However, since it is hardly feasible to evaluate IHP in a prospective randomized study this approach is the best that is available. Secondly, although patient characteristics, apart from age, were evenly distributed between both groups, clinically relevant differences may still exist. In this respect it should be noted that IHP patients were more extensively evaluated by imaging for both hepatic (<60% hepatic involvement) and extrahepatic disease load. Although the serum LDH level was equally distributed between both groups, it cannot be excluded that the control group may have had extrahepatic disease upon a similar pretreatment evaluation. Thirdly, overall survival was calculated from the date of IHP or date of randomization for systemic treatment in the control group, not from the date of diagnosis of liver metastases. As IHP patients were allowed to receive systemic treatment prior to IHP, median time from diagnosis of liver metastases to start of treatment is likely to be longer. To exclude any survival disadvantage a subgroup analysis was performed of the IHP patients who received IHP as first-line treatment (N=50). Although median overall survival was increased in this subgroup to 28.9 months, this remained non-significant compared to the survival in the control group.

One of the major drawbacks of IHP is the hepatotoxicity with its associated morbidity, largely attributable to veno-occlusive disease (VOD). In the patient cohort treated at our center with IHP, VOD occurred in 9-14% of patients depending on the IHP technique which was used<sup>7,16,17</sup>. Previous phase I studies have demonstrated that VOD is the main dose limiting toxicity<sup>11,18</sup>. Another factor which limits the possible application of IHP is the associated perioperative mortality. Several efforts have been undertaken to develop a minimal invasive technique to reduce mortality and increase efficacy by enabling repetition, but with only limited success. A few studies have been described involving chemofiltration under complete hepatic venous isolation after infusion of drugs, allowing administration of high doses of intrahepatic chemotherapy<sup>20-22</sup>.

Pingpank *et al.* reported a phase I study using chemofiltration and demonstrated that treatment with highdose melphalan is feasible, but complete extraction of

melphalan by charcoal hemoperfusion is not possible, limiting the maximum tolerated dose<sup>23</sup>. Complete isolation of the liver using minimally invasive techniques has been demonstrated to be technically feasible, but recently carried out phase I trials have shown disappointing results<sup>24,25</sup>. In our own center, we developed a minimal invasive technique using an animal model but refrained from translating this model to the clinical because of doubts about the safety of the required percutaneous catheters<sup>26</sup>.

Another option to improve current results of IHP is to incorporate some of the newly developed drugs for systemic treatment of colorectal cancer metastases. Zeh *et al.* published a phase I study of IHP with oxaliplatin in colorectal cancer patients<sup>13</sup>. Dose-limiting veno-occlusive disease was observed at 60 mg/m<sup>2</sup>. In this study, IHP was combined with HAI, thereby complicating the interpretation of both toxicity and response rates. Moreover, the perfusate consisted of oxaliplatin monotherapy, while in systemic therapy combination therapy has been shown more beneficial<sup>27</sup>. We are currently performing a phase I/II trial with IHP using a combination of both melphalan and oxaliplatin.

In conclusion, our study demonstrates no survival benefit for IHP with melphalan over systemic treatment with capecitabine, irinotecan and oxaliplatin. IHP should currently not be considered as standard treatment for patients with non-resectable colorectal cancer liver metastases, and should only be administered within prospective clinical studies.

## References

1. Punt CJ. New options and old dilemmas in the treatment of patients with advanced colorectal cancer. *Ann Oncol* 2004;15(10):1453-1459.
2. Weiss L, Grundmann E, Torhorst J et al. Haematogenous metastatic patterns in colonic carcinoma: an analysis of 1541 necropsies. *J Pathol* 1986;150(3):195-203.
3. Welch JP, Donaldson GA. The clinical correlation of an autopsy study of recurrent colorectal cancer. *Ann Surg* 1979;189(4):496-502.
4. Scheele J, Stang R, Altendorf-Hofmann A, Paul M. Resection of colorectal liver metastases. *World J Surg* 1995;19(1):59-71.
5. Nordlinger B, Guiguet M, Vaillant JC et al. Surgical resection of colorectal carcinoma metastases to the liver. A prognostic scoring system to improve case selection, based on 1568 patients. *Association Francaise de Chirurgie. Cancer* 1996;77(7):1254-1262.
6. Yamamoto J, Shimada K, Kosuge T, Yamasaki S, Sakamoto M, Fukuda H. Factors influencing survival of patients undergoing hepatectomy for colorectal metastases. *Br J Surg* 1999;86(3):332-337.
7. Rothbarth J, Pijl ME, Vahrmeijer AL et al. Isolated hepatic perfusion with high-dose melphalan for the treatment of colorectal metastasis confined to the liver. *Br J Surg* 2003;90(11):1391-1397.
8. Alexander HR, Jr., Bartlett DL, Libutti SK, Fraker DL, Moser T, Rosenberg SA. Isolated hepatic perfusion with tumor necrosis factor and melphalan for unresectable cancers confined to the liver. *J Clin Oncol* 1998;16(4):1479-1489.
9. Alexander HR, Jr., Libutti SK, Pingpank JF, Bartlett DL, Helsabeck C, Beresneva T. Isolated hepatic perfusion for the treatment of patients with colorectal cancer liver metastases after irinotecan-based therapy. *Ann Surg Oncol* 2005;12(2):138-144.
10. Bartlett DL, Libutti SK, Figg WD, Fraker DL, Alexander HR. Isolated hepatic perfusion for unresectable hepatic metastases from colorectal cancer. *Surgery* 2001;129(2):176-187.
11. Vahrmeijer AL, van Dierendonck JH, Keizer HJ et al. Increased local cytostatic drug exposure by isolated hepatic perfusion: a phase I clinical and pharmacologic evaluation of treatment with high dose melphalan in patients with colorectal cancer confined to the liver. *Br J Cancer* 2000;82(9):1539-1546.
12. Verhoef C, de Wilt JH, Brunstein F et al. Isolated hypoxic hepatic perfusion with retrograde outflow in patients with irresectable liver metastases; a new simplified technique in isolated hepatic perfusion. *Ann Surg Oncol* 2008;15(5):1367-1374.
13. Zeh HJ, III, Brown CK, Holtzman MP et al. A phase I study of hyperthermic isolated hepatic perfusion with oxaliplatin in the treatment of unresectable liver metastases from colorectal cancer. *Ann Surg Oncol* 2009;16(2):385-394.
14. Grothey A, Sargent D, Goldberg RM, Schmoll HJ. Survival of patients with advanced colorectal cancer improves with the availability of fluorouracil-leucovorin, irinotecan, and oxaliplatin in the course of treatment. *J Clin Oncol* 2004;22(7):1209-1214.
15. Koopman M, Antonini NF, Douma J et al. Sequential versus combination chemotherapy with capecitabine, irinotecan, and oxaliplatin in advanced colorectal cancer (CAIRO): a phase III randomised controlled trial. *Lancet* 2007;370(9582):135-142.
16. van Iersel LB, Verlaan MR, Vahrmeijer AL et al. Hepatic artery infusion of high-dose melphalan at reduced flow during isolated hepatic perfusion for the treatment of colorectal metastases confined to the liver: A clinical and pharmacologic evaluation. *Eur J Surg Oncol* 2007;33(7):874-881.



17. van Iersel LB, Gelderblom H, Vahrmeijer AL et al. Isolated hepatic melphalan perfusion of colorectal liver metastases: outcome and prognostic factors in 154 patients. *Ann Oncol* 2008.
18. Marinelli A, de Brauw LM, Beerman H et al. Isolated liver perfusion with mitomycin C in the treatment of colorectal cancer metastases confined to the liver. *Jpn J Clin Oncol* 1996;26(5):341-350.
19. Runia RD, de Brauw LM, Kothuis BJ, Pauwels EK, van de Velde CJ. Continuous measurement of leakage during isolated liver perfusion with a radiotracer. *Int J Rad Appl Instrum B* 1987;14(2):113-118.
20. Curley SA, Byrd DR, Newman RA et al. Reduction of systemic drug exposure after hepatic arterial infusion of doxorubicin with complete hepatic venous isolation and extracorporeal chemofiltration. *Surgery* 1993;114(3):579-585.
21. Ravikumar TS, Pizzorno G, Bodden W et al. Percutaneous hepatic vein isolation and high-dose hepatic arterial infusion chemotherapy for unresectable liver tumors. *J Clin Oncol* 1994;12(12):2723-2736.
22. Ku Y, Iwasaki T, Fukumoto T et al. Percutaneous isolated liver chemoperfusion for treatment of unresectable malignant liver tumors: technique, pharmacokinetics, clinical results. *Recent Results Cancer Res* 1998;147:67-82.
23. Pingpank JF, Libutti SK, Chang R et al. Phase I study of hepatic arterial melphalan infusion and hepatic venous hemofiltration using percutaneously placed catheters in patients with unresectable hepatic malignancies. *J Clin Oncol* 2005;23(15):3465-3474.
24. Savier E, Azoulay D, Huguet E, Lokiec F, Gil-Delgado M, Bismuth H. Percutaneous isolated hepatic perfusion for chemotherapy: a phase 1 study. *Arch Surg* 2003;138(3):325-332.
25. van EB, Brunstein F, van Ijken MG et al. Isolated hypoxic hepatic perfusion with orthograde or retrograde flow in patients with irresectable liver metastases using percutaneous balloon catheter techniques: a phase I and II study. *Ann Surg Oncol* 2004;11(6):598-605.
26. Rothbarth J, Pijl ME, Tollenaar RA et al. An experimental minimally invasive perfusion technique for the treatment of liver metastases. *Eur J Surg Oncol* 2003;29(9):757-763.
27. Rothenberg ML, Oza AM, Bigelow RH et al. Superiority of oxaliplatin and fluorouracil-leucovorin compared with either therapy alone in patients with progressive colorectal cancer after irinotecan and fluorouracil-leucovorin: Interim results of a phase III trial. *Journal of Clinical Oncology* 2003;21(11):2059-2069.

---

# CHAPTER 6

## ***In vitro* schedule-dependent interaction between melphalan and oxaliplatin in human colorectal cancer cell lines**

L.B.J. van Iersel<sup>1</sup>, M.M. Koudijs<sup>2</sup>, E.J. Hoekman<sup>1</sup>,  
C.M. Janssen-van Rhijn<sup>2</sup>, A.L. Vahrmeijer<sup>2</sup>, J.W.R. Nortier<sup>1</sup>,  
C.J.H. van de Velde<sup>2</sup>, H. Gelderblom<sup>1</sup>P.J.K. Kuppen<sup>2</sup>

Department of Clinical Oncology<sup>1</sup>, Surgery<sup>2</sup>, Leiden University  
Medical Center, Albinusdreef 2, 2333 ZA Leiden,  
The Netherlands

*J Surg Res* 2009 doi:10.1016/j.jss.2009.07.007

---

## **Abstract**

In order to determine the applicability of oxaliplatin in isolated liver perfusion, we identified the interaction between combinations of oxaliplatin and melphalan in 13 human colorectal cancer cell lines.

Cytotoxic activity was determined by the MTT-assay. Three different administration schedules of the two drugs were compared and median effect isobologram analysis was applied to the results to determine the presence of synergism, additive effects or antagonism as described by Chou and Talalay.

Resistance to melphalan did not correspond to resistance to oxaliplatin. All combinations of melphalan and oxaliplatin showed synergistic or additive interaction in the majority of the cell lines. One hour of oxaliplatin followed by 1 hour of melphalan showed the lowest percentage of cell viability, with synergy in 10 out of 13 cell lines at 50% cell viability. Simultaneous treatment showed the highest cell viability, with antagonism in 6 cell lines, additivity in 2 cell lines, synergism in 5 cell lines at 50% cell viability. One hour of melphalan followed by 1 hour of oxaliplatin showed synergy in 6 cell lines, antagonism in another 6 and additivity in 1 cell line.

Our findings suggest a schedule-dependent synergistic interaction between melphalan and oxaliplatin. Therefore, oxaliplatin should be considered as a new potentially valuable additional agent to the currently commonly used melphalan in isolated hepatic perfusion in colorectal cancer patients.

## Introduction

Liver metastases are diagnosed in 10-25% of patients<sup>1</sup> at the time of resection of the primary colorectal tumor. Eventually up to 70 % of patients with colorectal cancer develop liver metastases. In approximately 30% of the patients the liver is the only site of metastatic disease<sup>2,3</sup>. Surgical resection is considered the standard treatment since complete resection can lead to curation in 25-45% of cases. However resection is only possible in the minority of patients due to the number, location or size of the metastases<sup>4-6</sup>. Isolated hepatic perfusion (IHP) is a therapeutic option for irresectable liver-only metastatic disease although randomized trials versus systemic therapy are lacking. The theoretical advantage of IHP versus systemic therapy is that IHP allows the use of high therapeutic dosages that would cause fatal complications if delivered systemically. Several drugs have been applied in IHP including 5-FU<sup>2,3</sup>, mitomycin C<sup>9,10</sup>, cisplatin<sup>7</sup> and melphalan<sup>7,10-12</sup>, but in the past 10 years melphalan has been the only drug used in major clinical studies<sup>4,5</sup>.

In the past few years various new agents such as irinotecan, oxaliplatin, panitumumab/cetuximab and bevacizumab, have been introduced in the systemic treatment of colorectal cancer, improving response rates, disease free survival and overall survival<sup>14-21</sup>. To improve the current standard of IHP, some of the newly developed drugs for systemic treatment of colorectal cancer metastases should be considered to be used. For successful application in IHP such a drug has to fulfill several conditions. Firstly, as IHP is a regional treatment, the drug should be in the active form or can be transformed to its active agent in the liver. Secondly, increased concentrations of the drug, as compared to systemic treatment, should lead to an increased tumor response. Thirdly, as IHP is a short treatment with usually a 1 hour treatment time, the administered drug should cause rapid irreversible tumor cell cytotoxicity. Finally, liver toxicity should be minimal. Based on these assumptions we considered all registered drugs for colorectal cancer. First, irinotecan is not an ideal candidate for IHP, since it is a prodrug and the bioactivation to its active metabolite SN-38 is slow<sup>6</sup>. The monoclonal antibody bevacizumab may not be suitable either, considering it is not directly cytotoxic and has been shown to impair wound healing<sup>23</sup>. Similar to bevacizumab, cetuximab/panitumumab are not directly cytotoxic.

Oxaliplatin was selected as the most promising new candidate for IHP based on the following observations Oxaliplatin is rapidly absorbed by cells and transformed by non-enzymatic pathways to its biologically active species. Substantial dose-dependent DNA adduct formation occurs within one hour<sup>24,25</sup>. Previous studies have shown that in systemic administration of oxaliplatin, neurotoxicity, hematological toxicity and

nephrotoxicity are dose limiting, while hepatotoxicity is rarely mentioned<sup>26</sup>. Phase III trials have shown the inferiority of oxaliplatin monotherapy versus oxaliplatin combination therapy<sup>27,28</sup>, suggesting a role for the possible application of a combination of oxaliplatin and melphalan in IHP.

Therefore, we investigated the interaction between melphalan and oxaliplatin using 13 human colorectal cancer cell lines.

## **Materials and methods**

### **Cell culture**

The human colon cancer cell lines Caco-2, Colo320, CO115, DLD-1, HCT81, HT29, Lovo, Ls180, Ls411n, SW480, SW48 and T84 were cultured in Hepes-buffered RPMI-1640 culture medium supplemented with glutamine (2mM), penicillin (50U/ml), streptomycin (50µg/ml) and 10% (v/v) fetal calf serum (all Gibco/BRL, Paisley, UK).

### **Drugs**

Oxaliplatin (L-OHP) was a gift from Sanofi-Aventis (Gouda, The Netherlands). Stock solutions of oxaliplatin were prepared by dissolving 50mg of oxaliplatin in 10ml fetal calf serum-free RPMI. Melphalan (L-PAM) was purchased from Sigma-Aldrich (St. Louis, MO, USA). A melphalan stock solution was prepared by dissolving 50mg melphalan in 10ml distilled water with 0.09% hydrochloric acid.

### **Cytotoxicity assay**

Drug concentrations that inhibit 50% of cell growth ( $IC_{50}$ ) were determined using the MTT-assay, an assay designed for the spectrophotometric quantification of cell growth and cell viability<sup>7</sup>. The cells were seeded in a 96-well microtiter-plate (Greiner, Alphen a/d Rijn, The Netherlands) in 200 µl culture medium at different densities per cell line, depending on adhesion and growth qualities (Caco-2 4000 cells/well, Colo320 2000 cells/well, CO115 1000 cells/well, DLD-1 750 cells/well, HCT81 500 cells/well, HT29 500 cells/well, Lovo 3000 cells/well, Ls180 3000 cells/well, Ls411n 2000 cells/well, RKO 2000 cells/well, SW480 4000 cells/well, SW48 4000 cells/well and T84 3000 cells/well). After 96 hours, cells were treated with 100µl of nine graded concentrations of oxaliplatin (3.75-960µM, 5.9-1500µM and 5.3-1360µM) and/or melphalan (2.3-600µM, 3.1-800µM and 4.7-1200µM) for 1 hour, based on drug sensitivity as found in preliminary experiments

Schedule A		L-PAM	L-OHP	
Schedule B		L-OHP + L-PAM		
Schedule C		L-OHP	L-PAM	
	-96h Plating	0-1h Start treatment	1-2h	72 h MTT-assay

**Figure 1** The three combination schedules of treatment of the cell lines with oxaliplatin (L-OHP) and melphalan (L-PAM) using a MTT assay.

(unpublished data). The three combined treatment schedules of both drugs consisted of simultaneous, 1 hour oxaliplatin followed by 1 hour melphalan and 1 hour melphalan followed by 1 hour oxaliplatin drug exposure (figure 1). When combined, the drugs were tested at a constant concentration ratio for a given cell line. Combination ratios were determined by the  $IC_{25}$  of each drug and then grouped according to the sensitivity spectrum into 6 groups. The following ratios were used 0.88 for Caco-2, HT29, SW480, HCT81 and Ls180; 0.27 for CO115 and RKO; 0.59 for Ls411n and T84; 0.63 for DLD-1; 0.20 for Colo320; 0.83 for Lovo and SW48. After drug exposure cells were washed twice with 100 $\mu$ l medium and 200 $\mu$ l fresh culture medium was added. Cells were left to grow for 72 hours, after which culture medium was removed and cells were incubated for 4 hours with 100 $\mu$ l fresh medium and 10  $\mu$ l MTT (5 mg/ml)(Sigma-Aldrich, St. Louis, MO, USA) labeling agent. Subsequently, 100 $\mu$ l solubilization solution (10% v/v in 0.01 M HCL) (Bio-Rad, Hemel Hempstead, UK) was added and cells were left overnight for incubation. The absorbance at 590 nm was measured by microtiter-plate reader (BioRad Laboratories B.V., Veenendaal, The Netherlands). Wells containing untreated cells of the respective cell lines were used as controls. Each experiment was performed using three replicate wells. Results were expressed as the relative percentage of absorbance compared with controls without drug. The results were based on at least 3 independent experiments.

### Analysis of combination effects

On the basis of the growth inhibition curve for each single drug, we analyzed the effects of different treatment schedules according to the method as described by Chou and Talalay<sup>8</sup>, using the Calcsyn software program for automated analysis (Biosoft, Cambridge, UK). The effect of combining the two drugs was evaluated by comparing the results of the sequential assays with the assays involving simultaneous oxaliplatin and melphalan treatment. The combination effect was evaluated by determination of the respective combination indexes. The combination index (CI) can be extrapolated from the various concentrations (C) and is defined as follows:  $CI = \frac{C_{\text{oxaliplatin in combination}}}{C_{\text{oxaliplatin}} + \frac{C_{\text{melphalan in combination}}}{\alpha} \times \frac{C_{\text{oxaliplatin in combination}} \times C_{\text{melphalan in combination}}}{C_{\text{oxaliplatin}} \times C_{\text{melphalan}}}}$  for the same effect (where  $\alpha$  is the parameter with value 0 when both drugs are mutually

exclusive and 1 when both drugs are mutually non-exclusive. The CI indicated synergism if  $<1.0$ , antagonism if  $>1.0$  and additivity if  $1.0$ .

## Results

### Single-agent experiments

The cytotoxicity of melphalan and oxaliplatin was tested individually on all 13 cell lines. The cells were exposed to each drug for 1 hour. The  $IC_{50}$  values ( $\pm$  SD) are summarized in Table 1. For melphalan, SW48 cells were most sensitive ( $41 \mu\text{M}$ ) and Caco-2 cells were most resistant ( $806 \mu\text{M}$ ). SW48 cells were also the most sensitive to oxaliplatin ( $36 \mu\text{M}$ ), CO115 cells were the least sensitive ( $3119 \mu\text{M}$ ). Resistance to melphalan did not necessarily imply resistance to oxaliplatin, as shown by Ls411n cells.

### Combination experiments

Melphalan and oxaliplatin were tested in different combination schedules to determine the most effective schedule. Three different schedules were tested as shown in fig. 1. The combination indexes (CI) at 50 % and 25 % cell viability, approximating 50 % and 75% cell death are given in table 2 for all treatment schedules. Simultaneous treatment with the two drugs resulted in antagonistic interaction in 6 cell lines, additivity in 2 cell lines

**Table 1** Cell line characteristics

Cell line	Melphalan $IC_{50}$ (mean value, $\mu\text{M}$ )	Oxaliplatin $IC_{50}$ (mean value, $\mu\text{M}$ )
Caco-2	806 +/- 290	562 +/- 185
CO115	592 +/- 180	3119 +/- 1777
Ls411n	576 +/- 313	298 +/- 133
HT29	316 +/- 166	548 +/- 144
SW480	190 +/- 177	947 +/- 547
T84	171 +/- 85	241 +/- 92
RKO	132 +/- 65	1381 +/- 667
DLD-1	95 +/- 40	245 +/- 86
HCT81	65 +/- 20	256 +/- 121
Ls180	61 +/- 32	200 +/- 143
Colo320	61 +/- 18	541 +/- 203
Lovo	53 +/- 28	51 +/- 18
SW48	41 +/- 33	36 +/- 39

The  $IC_{50}$  values of melphalan and oxaliplatin are the means  $\pm$  SD of at least three independent experiments.

**Table 2** Combination indexes for the different drug combinations

Cell line	Schedule A CI (+/-SD)	Schedule B CI (+/-SD)	Schedule C CI (+/-SD)
<b>Caco-2</b>			
- 50% cell viability	1.2 +/- 0.74	0.52 +/- 0.17 <sup>†</sup>	0.77 +/- 0.29 <sup>†</sup>
- 25% cell viability	1.3 +/- 0.47	0.64 +/- 0.13 <sup>†</sup>	0.75 +/- 0.21 <sup>†</sup>
<b>Colo320</b>			
- 50% cell viability	0.71 +/- 0.49 <sup>†</sup>	0.85 +/- 0.24 <sup>†</sup>	0.65 +/- 0.37 <sup>†</sup>
- 25% cell viability	0.60 +/- 0.28 <sup>†</sup>	0.84 +/- 0.38 <sup>†</sup>	0.65 +/- 0.27 <sup>†</sup>
<b>CO115</b>			
- 50% cell viability	0.23 +/- 0.25 <sup>†</sup>	0.49 +/- 0.37 <sup>†</sup>	0.30 +/- 0.22 <sup>†</sup>
- 25% cell viability	0.38 +/- 0.15 <sup>†</sup>	0.44 +/- 0.33 <sup>†</sup>	0.34 +/- 0.16 <sup>†</sup>
<b>DLD-1</b>			
- 50% cell viability	0.65 +/- 0.77 <sup>†</sup>	1.81 +/- 1.65	0.72 +/- 0.40 <sup>†</sup>
- 25% cell viability	0.49 +/- 0.47 <sup>†</sup>	1.06 +/- 0.63	0.61 +/- 0.20 <sup>†</sup>
<b>HCT81</b>			
- 50% cell viability	1.17 +/- 0.80	1.01 +/- 0.50	0.96 +/- 0.54 <sup>†</sup>
- 25% cell viability	0.82 +/- 0.23 <sup>†</sup>	1.09 +/- 0.34	0.69 +/- 0.28 <sup>†</sup>
<b>HT29</b>			
- 50% cell viability	1.25 +/- 0.84	2.51 +/- 1.86	0.68 +/- 0.50 <sup>†</sup>
- 25% cell viability	0.99 +/- 0.54 <sup>†</sup>	2.67 +/- 1.30	0.64 +/- 0.40 <sup>†</sup>
<b>Lovo</b>			
- 50% cell viability	1.75 +/- 1.45	1.03 +/- 0.35	1.42 +/- 1.35
- 25% cell viability	1.62 +/- 1.19	1.20 +/- 0.35	1.47 +/- 0.98
<b>Ls180</b>			
- 50% cell viability	1.79 +/- 2.18	3.18 +/- 3.22	0.68 +/- 0.36 <sup>†</sup>
- 25% cell viability	1.35 +/- 1.37	2.18 +/- 1.90	0.65 +/- 0.38 <sup>†</sup>
<b>Ls411n</b>			
- 50% cell viability	0.88 +/- 0.53 <sup>†</sup>	1.33 +/- 0.95	0.58 +/- 0.28 <sup>†</sup>
- 25% cell viability	0.84 +/- 0.60 <sup>†</sup>	1.36 +/- 0.96	0.53 +/- 0.23 <sup>†</sup>
<b>RKO</b>			
- 50% cell viability	0.98 +/- 0.73 <sup>†</sup>	1.35 +/- 0.69	0.80 +/- 0.23 <sup>†</sup>
- 25% cell viability	0.98 +/- 0.72 <sup>†</sup>	1.28 +/- 0.73	0.71 +/- 0.22 <sup>†</sup>
<b>SW48</b>			
- 50% cell viability	2.74 +/- 3.51	1.28 +/- 0.79	1.14 +/- 0.79
- 25% cell viability	1.37 +/- 0.94	1.15 +/- 0.57	0.78 +/- 0.27 <sup>†</sup>
<b>SW480</b>			
- 50% cell viability	0.91 +/- 0.36 <sup>†</sup>	0.66 +/- 0.25 <sup>†</sup>	1.10 +/- 0.60
- 25% cell viability	1.18 +/- 0.24	0.59 +/- 0.08 <sup>†</sup>	1.38 +/- 0.58
<b>T84</b>			
- 50% cell viability	1.01 +/- 0.41	0.95 +/- 0.70 <sup>†</sup>	0.89 +/- 0.40 <sup>†</sup>
- 25% cell viability	0.93 +/- 0.33 <sup>†</sup>	0.91 +/- 0.42 <sup>†</sup>	0.86 +/- 0.33 <sup>†</sup>

Values are mean combination indexes (CI) of at least three independent experiments. Treatment A is 1 hour melphalan followed by 1 hour oxaliplatin. Treatment B is melphalan and oxaliplatin simultaneously. Treatment C is 1 hour oxaliplatin followed by 1 hour melphalan. The CI indicates synergism if <1.0, antagonism if >1.0 and additivity if 1.0. <sup>†</sup>Correspond to synergistic interactions.



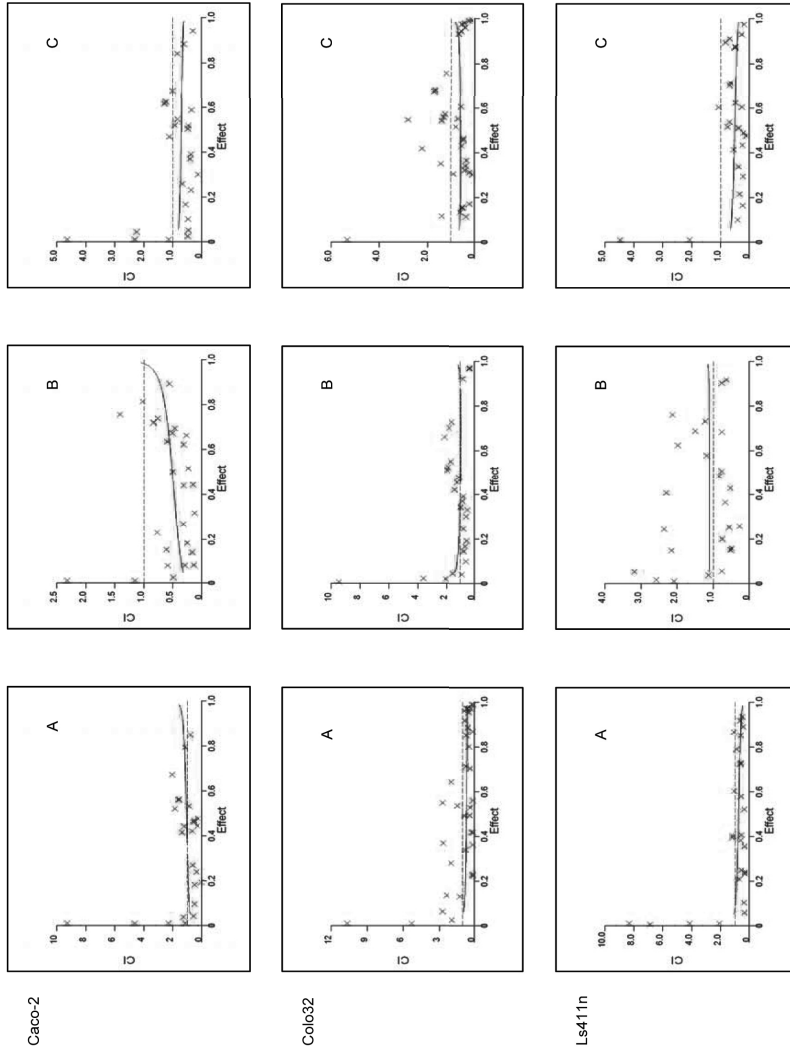
and synergistic interaction in 5 cell lines at 50% cell viability. Sequential treatment with oxaliplatin followed by melphalan resulted in synergistic interaction in 10 cell lines and antagonistic interaction in the other three cell lines in nearly all ranges of cell kill fraction. Sequential treatment with melphalan followed by oxaliplatin resulted in antagonistic interaction in 6 cell lines, synergism in 6 cell lines and additive interaction in 1 cell line at 50% cell viability. Typical examples for CI/fractional effect curves are given in figure 2.

## Discussion

Oxaliplatin has been successfully introduced in the treatment of metastatic colorectal cancer. Although oxaliplatin monotherapy has shown limited activity, the combination with 5-FU/leucovorin resulted in tumor responses in 50% of patients and a median time to progression of 9.0 months<sup>16</sup>. IHP has proven a suitable treatment option for patients with liver-only colorectal metastases, who are not eligible for other locoregional treatment options<sup>12,13</sup>. Over the past 10 years melphalan (with or without TNF) has been the major drug applied in IHP. To our knowledge the addition of new, modern agents to melphalan in IHP has not been investigated. Recently Herbert *et al* published a phase I study of hyperthermic isolated hepatic perfusion with oxaliplatin in the treatment of unresectable liver metastases<sup>9</sup>. In our opinion a major drawback of this study is the application of oxaliplatin monotherapy, since oxaliplatin monotherapy has shown only limited efficacy in the systemic treatment of colorectal cancer patients.

We examined the interaction between oxaliplatin and melphalan in a panel of 13 colorectal cancer cell lines *in vitro*. The drug sensitivity spectrum of our cell lines showing resistance to melphalan did not necessarily correspond to resistance to oxaliplatin, suggesting different mechanisms of resistance for both agents. IHP melphalan monotherapy experience at our institution in 154 colorectal cancer patients showed an overall response rate of 50% on CT examinations<sup>10</sup>, suggesting resistance to melphalan in 50% patients. We hypothesized that this percentage can be reduced through the addition of oxaliplatin.

Addition of oxaliplatin to melphalan resulted in synergistic or additive interaction in the majority of our cell lines for all the treatment schedules. Various other *in vitro* studies have shown a schedule-dependent interaction between oxaliplatin and other cytostatic agents<sup>33-36</sup>. Our experiments showed synergy especially when the cell lines were treated sequentially when compared to simultaneous treatment. A possible explanation is the competitive uptake of both agents. The uptake of melphalan is dependent on active carrier-mediated transport<sup>11</sup>. In myeloma cell lines down regulation of CD98



**Figure 2** Typical combination index/fractional effect curve as derived from the Chou and Talalay model for three cell lines Caco-2, Colo32 and Ls411n. Each point represents the CWI at a dose effect as determined in our experiments. The dotted line indicates additivity, the area under the dotted line synergy and the area above the dotted line antagonism. Cells were treated with (A) melphalan followed by oxaliplatin, (B) melphalan and oxaliplatin simultaneously and (C) oxaliplatin followed by melphalan.

(L-phenylalanine transporter) was associated with increased resistance to and reduced uptake of melphalan<sup>38</sup>. Little is known about the transport mechanisms of oxaliplatin. Some studies suggest the role of organic copper-transporters in the uptake of oxaliplatin<sup>12-14</sup>. As simultaneous treatment with both drugs resulted in the highest cell viability corresponding to the least cell death, melphalan and oxaliplatin may share a common (competitive) transporter.

Our results also suggest that treatment with oxaliplatin, followed by treatment with melphalan is superior to treatment with melphalan followed by treatment with oxaliplatin. It is possible that the schedule-dependent synergistic interaction of oxaliplatin and melphalan would be due to inhibition by melphalan of the oxaliplatin-induced Pt-adducts repair mechanisms. Further experiments are necessary to identify these mechanisms underlying the interaction between melphalan and oxaliplatin.

In conclusion, a synergistic interaction was observed between melphalan and oxaliplatin. All treatment schedules showed synergistic interaction, but the best results were obtained if oxaliplatin treatment was followed by melphalan treatment, although the mechanisms of interaction remain unknown. These *in vitro* findings provide an important basis for a future clinical trial of the combination of oxaliplatin and melphalan in isolated hepatic perfusion. At our institution we are currently performing a phase I/II trial with IHP with a combination of oxaliplatin directly followed by melphalan.

## References

1. Jessup JM, McGinnis LS, Steele GD, Jr., Menck HR, Winchester DP. The National Cancer Data Base. Report on colon cancer. *Cancer* 1996;78(4):918-926.
2. Hafstrom LR, Holmberg SB, Naredi PL et al. Isolated hyperthermic liver perfusion with chemotherapy for liver malignancy. *Surg Oncol* 1994;3(2):103-108.
3. Aigner K, Walther H, Tonn JC et al. [Isolated liver perfusion with 5-fluorouracil (5-FU) in the human]. *Chirurg* 1982;53(9):571-573.
4. Rothbarth J, Pijl ME, Vahrmeijer AL et al. Isolated hepatic perfusion with high-dose melphalan for the treatment of colorectal metastasis confined to the liver. *Br J Surg* 2003;90(11):1391-1397.
5. Alexander HR, Jr., Bartlett DL, Libutti SK, Fraker DL, Moser T, Rosenberg SA. Isolated hepatic perfusion with tumor necrosis factor and melphalan for unresectable cancers confined to the liver. *J Clin Oncol* 1998;16(4):1479-1489.
6. Chabot GG, Abigerges D, Catimel G et al. Population Pharmacokinetics and Pharmacodynamics of Irinotecan (Cpt-11) and Active Metabolite Sn-38 During Phase-I Trials. *Annals of Oncology* 1995;6(2):141-151.
7. Mosmann T. Rapid colorimetric assay for cellular growth and survival: application to proliferation and cytotoxicity assays. *J Immunol Methods* 1983;65:55-63.
8. Chou TC, Talalay P. Quantitative analysis of dose-effect relationships: the combined effects of multiple drugs or enzyme inhibitors. *Adv Enzyme Regul* 1984;22:27-55.
9. Zeh HJ, III, Brown CK, Holtzman MP et al. A Phase I Study of Hyperthermic Isolated Hepatic Perfusion with Oxaliplatin in the Treatment of Unresectable Liver Metastases from Colorectal Cancer. *Ann Surg Oncol* 2008.
10. van Iersel LB, Gelderblom H, Vahrmeijer AL et al. Isolated hepatic melphalan perfusion of colorectal liver metastases: outcome and prognostic factors in 154 patients. *Ann Oncol* 2008.
11. Goldenberg GJ, Lam HY, Begleiter A. Active carrier-mediated transport of melphalan by two separate amino acid transport systems in LPC-1 plasmacytoma cells in vitro. *J Biol Chem* 1979;254(4):1057-1064.
12. Safaei R. Role of copper transporters in the uptake and efflux of platinum containing drugs. *Cancer Lett* 2006;234(1):34-39.
13. Larson CA, Blair BG, Safaei R, Howell SB. The role of the mammalian copper transporter 1 in the cellular accumulation of platinum-based drugs. *Mol Pharmacol* 2009;75(2):324-330.
14. Yokoo S, Masuda S, Yonezawa A, Terada T, Katsura T, Inui K. Significance of organic cation transporter 3 (SLC22A3) expression for the cytotoxic effect of oxaliplatin in colorectal cancer. *Drug Metab Dispos* 2008;36(11):2299-2306.



---

# CHAPTER 7

## Isolated hepatic perfusion with oxaliplatin combined with 100 mg melphalan: a phase I study

L.B.J. van Iersel<sup>1</sup>, A.L.Vahrmeijer<sup>2</sup>, F.G.J. Tijl<sup>3</sup>, J. den Hartigh<sup>4</sup>,  
P.J.K. Kuppen<sup>2</sup>, H.H. Hartgrink<sup>2</sup>, H. Gelderblom<sup>1</sup>, J.W.R. Nortier<sup>1</sup>,  
R.A.E.M. Tollenaar<sup>2</sup> and C.J.H. van de Velde<sup>2</sup>

Department of Clinical Oncology<sup>1</sup>, Surgery<sup>2</sup>, Extra Corporal  
Circulation<sup>3</sup> and Clinical Pharmacy and Toxicology<sup>4</sup> Leiden  
University Medical Center, Albinusdreef 2, 2333 ZA Leiden,  
The Netherlands

*Manuscript in preparation*

---

## **Abstract**

To improve IHP, we performed a phase I dose-escalation study to determine oxaliplatin dose in combination with a fixed melphalan dose.

Between June 2007 and July 2008, 11 patients, consisting of 8 colorectal cancer and 3 uveal melanoma patients with isolated liver metastases, were treated with IHP with escalating doses of oxaliplatin combined with 100mg melphalan. Samples of blood and perfusate were taken for pharmacokinetic analysis and patients were monitored for toxicity, response and survival.

Dose limiting sinusoidal obstruction syndrome (SOS) occurred at 150mg oxaliplatin. The areas under the concentration-time curves (AUC) of oxaliplatin at the maximal tolerated dose (MTD) of 100mg oxaliplatin ranged from 11.9 mg/L x h to 16.5 mg/L x h. All 4 patients treated at the MTD showed progressive disease 3 months after IHP.

The MTD of oxaliplatin in combination with 100mg melphalan in IHP was reached at 100mg oxaliplatin. We think that, in view of similar and even higher doses of oxaliplatin applied in both systemic treatment and hepatic artery infusion (HAI), applying this dose in IHP will not improve treatment results in patients with isolated hepatic metastases.

## Introduction

Liver metastases are diagnosed in 10-25% of colorectal cancer patients at the time of primary tumour resection, while up to 70 % of patients with colorectal cancer will at some stage of their disease develop liver metastases<sup>1-3</sup>. Surgical resection is considered the golden standard for isolated hepatic metastases, with 10-year survival rates as high as 17%<sup>4</sup>. Recently, the number of patients suitable for resection has increased to up to 60% with the introduction of new neoadjuvant systemic treatment regimens<sup>5-9</sup>. Nonetheless, a significant number of patients still remain unsuitable for resection. Isolated hepatic perfusion (IHP) is a possible therapeutic option for irresectable liver metastases, but recent developments in systemic treatment in colorectal cancer have limited the role of IHP<sup>10</sup>. For IHP to remain a treatment option response rates and overall survival need to increase, by improving both the procedure and drugs applied in IHP.

Several drugs have been applied in IHP including 5-FU<sup>11,12</sup>, mitomycin C<sup>13,14</sup>, cisplatin<sup>11</sup> and melphalan<sup>11,14-16</sup>, but in the past 10 years melphalan has been the main drug used in clinical trials<sup>16,17</sup>. To improve the current standard of IHP, we considered some of the newly developed drugs for systemic treatment of colorectal cancer for application in IHP. As IHP is a regional treatment, the drug should be in the active form or easily transformed to its active agent in the liver. Preferably, this drug shows a steep dose-response curve. Moreover, IHP is a short treatment of usually 1 hour, therefore the drug should cause rapid irreversible tumor cell cytotoxicity. Finally, liver toxicity should be minimal. We evaluated all registered drugs for colorectal cancer, taking into account the considerations above. Irinotecan is not an ideal candidate for IHP, since it is a pro-drug and the bioactivation to its active metabolite SN-38 is slow<sup>18</sup>. The monoclonal antibodies bevacizumab, cetuximab and panitumumab may not be suitable either, because they are not directly cytotoxic. Therefore oxaliplatin was selected as the most promising new candidate for IHP. Phase III trials have shown the inferiority of oxaliplatin monotherapy versus oxaliplatin combination therapy<sup>19,20</sup>, suggesting a role for the possible application of a combination of oxaliplatin and melphalan in IHP. In vitro results showed a synergistic schedule dependent interaction between melphalan and oxaliplatin<sup>21</sup>.

In this report we present the results of a phase I trial with IHP with escalating doses of oxaliplatin combined with a fixed dose of 100mg melphalan.



## **Patients and methods**

### **Patient Eligibility**

Between June 2007 and July 2008, 11 patients with isolated liver metastases were treated with IHP with escalating doses of oxaliplatin combined with 100mg melphalan. The study protocol was approved by the medical ethical committee of the Leiden University Medical Center and informed consent was obtained from all patients. All patients had measurable, irresectable metastases confined to the liver. Standard staging studies were performed including CT scan of the chest and abdomen. Additional MRI or PET scans were performed if clinically indicated. Eligibility criteria included a WHO performance status of 0 or 1, leukocyte count  $\geq 3.0 \times 10^9/L$ , platelet count  $\geq 100 \times 10^9/L$ , minimum creatinine clearance level of 40 ml/min and maximum bilirubin level 17  $\mu\text{mol/L}$ . Exclusion criteria were biological age over 65 years, more than 60% hepatic replacement by tumour tissue as estimated from the preoperative abdominal CT scan, coagulation disorders or evidence of extrahepatic metastatic disease. The interval between resection of the primary colorectal tumour and perfusion had to be at least 6 weeks.

### **IHP technique**

All patients were treated with IHP, consisting of an extracorporeal venovenous bypass, as described previously<sup>15</sup>.

### **Leakage Detection**

Leakage of perfusate into the systemic circuit was monitored by adding 10 MBq <sup>99m</sup>Tc-pertechnetate to the isolated circuit with subsequent measurement of the level of radioactivity in both the systemic and isolated circuit, as described previously<sup>22, 23</sup>. If no leakage was detected, oxaliplatin was administered. During the one hour treatment leakage was constantly monitored, if leakage exceeded 10% during the perfusion period, the procedure was immediately aborted and the liver flushed.

### **Postoperative Care**

All patients received a daily subcutaneous dose of 480  $\mu\text{g}$  granulocyte colony-stimulating factor (G-CSF) (Filgrastim/Neupogen<sup>®</sup>; Amgen, Breda, The Netherlands) starting the day after the operation until the nadir in leukocyte count was reached and the count had risen to more than  $1.0 \times 10^9/L$ . Patients were monitored in the intensive care unit for at least 1 day after IHP. Liver and renal function tests and full blood counts were

carried out daily in the first week and henceforth as indicated by their respective levels. Antibiotics in a combination of cefuroxim and metronidazol were given to all patients for 5 days after IHP.

### **Oxaliplatin and melphalan**

Oxaliplatin (Sanofi-Aventis, Gouda, The Netherlands) was obtained as a ready-made solution and administered as a bolus in the isolated hepatic circuit. Melphalan 100mg (Alkeran®, GlaxoSmithKline, Zeist, The Netherlands) was dissolved in 40 mL Wellcome Diluent (a 60/40 (v/v) mixture of proylene glycol containing 5.2% (v/v) ethanol and 0.068 mol/l sodium citrate), which was subsequently diluted with 60 mL sterile saline. The melphalan was administered as a bolus in the isolated hepatic circuit 30 minutes after the oxaliplatin was administered.

### **Dose escalation**

Dose escalation depended on toxicities at the prior dose level. At least 3 patients were treated at each dose level. If 1 of 3 patients experienced dose limiting toxicity (DLT), 3 additional patients were entered at that dose level. DLT was defined as grade 4 thrombopenia or neutropenia for more than 7 days or febrile neutropenia or irreversible grade 3/4 liver toxicity or other grade 3/4 non-hematological toxicity other than nausea and vomiting without adequate treatment. The maximal tolerated dose (MTD) was defined as the dose level below that, which induced DLT in at least one-third of the patients. (i.e.,  $\geq 2$  of 3 or 6 patients). Melphalan was kept at a constant dose of 100 mg, because this was considered standard treatment in several phase II trials<sup>24-26</sup>. Oxaliplatin was escalated with 50mg at a time. Oxaliplatin was administered 30 minutes prior to melphalan based on *in vitro* findings, suggesting a schedule dependent interaction between melphalan and oxaliplatin<sup>21</sup>.

### **Toxicity**

Systemic and regional toxicity were graded according to the National Cancer Institute Common Toxicity Criteria version 3.0. Hepatic toxicities were considered melphalan-related if elevations in liver function persisted beyond 7 days after perfusion, as previously suggested<sup>16</sup>. Nonhepatic toxicities were defined as all toxicities that were not reversed within 24 hours after perfusion.

## **Melphalan and oxaliplatin pharmacokinetics**

Heparinized samples of all patients were taken from the perfusion medium at hepatic inflow and outflow tracts and from the systemic circulation, at 15 different time intervals ( $t=0, 1, 5, 10, 15, 20, 25, 30, 31, 33, 35, 40, 45, 50, 60$  minutes). Samples were stored at  $-80^{\circ}\text{C}$  until analysis. All samples were analyzed by a HPLC assay as previously described<sup>27</sup>. The areas under the concentration-time curves (AUC) were calculated with the trapezoidal rule.

## **Response evaluation**

Objective tumour response measurements were obtained by follow up CT scans of the liver and remaining abdomen at 3-month intervals after treatment and at 6-month interval after 1 year. Additional imaging was performed if clinically indicated. RECIST criteria were used to determine response rates. For the RECIST criteria lesions were only considered measurable if  $\geq 10\text{mm}$ . Complete response was defined as disappearance of all known disease, partial response as a reduction in the sum of maximal diameters of  $\geq 30\%$ , stable disease as a reduction of  $<30\%$  or an increase of  $<20\%$  and progressive disease as an increase of  $\geq 20\%$  or the appearance of new intra- or extrahepatic lesions<sup>28</sup>. Metastases were localized according to the Bismuth classification<sup>29</sup>. Serum carcinoembryonic antigen (CEA) levels were determined prior to treatment and at all follow-up visits.

## **Statistics**

All data were analyzed using SPSS (version 12.0) software and presented as mean  $\pm$  SD or median followed by the range. All survival and disease progression analysis was performed by using Kaplan-Meier statistics.

## **Results**

### **Patient characteristics**

Demographics and tumour characteristics of the patient population are listed in Table 1. In total 11 patients were treated with escalating doses of oxaliplatin. The liver metastases originated from uveal melanoma in 3 patients and from colorectal cancer in the other 8 patients. Three women were treated and 8 men with a mean age of 57.9 years (range 40-64 years). One patient was included (patient no. 5) who in retrospect

**Table 1.** Characteristics of 11 patients treated with IHP with oxaliplatin and melphalan

Patient No.	Sex	Age (Y)	Primary tumour	Dose Melphalan (mg)	Dose Oxaliplatin (mg)	AUC Hepatic inflow Melphalan (mg/L x h)	AUC Hepatic inflow Oxaliplatin (mg/L x h)	Response	Duration response (months)	Overall survival (months)
1	F	51	Uveal melanoma	100	50	9.6	4.1	partial	7.6	22.1 <sup>α</sup>
2	M	64	Colorectal cancer	100	50	2.8	6.2	progressive	-	21.9 <sup>α</sup>
3	M	54	Uveal melanoma	100	50	7.3	6.9	progressive	-	18.7
4	M	59	Colorectal cancer	100	100	6.4	12.6	progressive	-	4.9
5 <sup>+</sup>	F	40	Colorectal cancer	100	100	15.4	16.5	-	-	5.5
6	F	61	Uveal melanoma	100	100	10.3	16.5	progressive	-	7.8
7	M	63	Colorectal cancer	100	100	2.8	11.9	progressive	-	18.2 <sup>α</sup>
8	M	63	Colorectal cancer	100	150	6.7	19.6	partial	6.5	12.0 <sup>α</sup>
9	M	63	Colorectal cancer	100	150	4.8	16.7	partial	11.1	13.9 <sup>α</sup>
10 <sup>*</sup>	M	57	Colorectal cancer	100	150	9.9	20.6	-	-	0.5
11 <sup>*</sup>	M	62	Colorectal cancer	100	150	6.5	18.2	-	-	1.0

+ In retrospect patient showed extrahepatic metastases prior to IHP, which were immediately progressive after IHP.

\* Both patients died perioperatively. Patient no. 10 due to excessive bleeding and patient no. 11 due to hepatotoxicity.

α Patients were still alive at the end of follow up.

showed extrahepatic disease prior to IHP. Therefore 1 extra patient was included at this dose-level.

### Treatment characteristics

Treatment characteristics are shown in Table 2. Operative time, blood loss, hospital stay and hepatic artery and portal vein flow rates and pressures are similar to the previous reports<sup>17,30</sup>. None of the patients showed more than 1 percent leakage during the entire procedure.

**Table 2** Treatment parameters

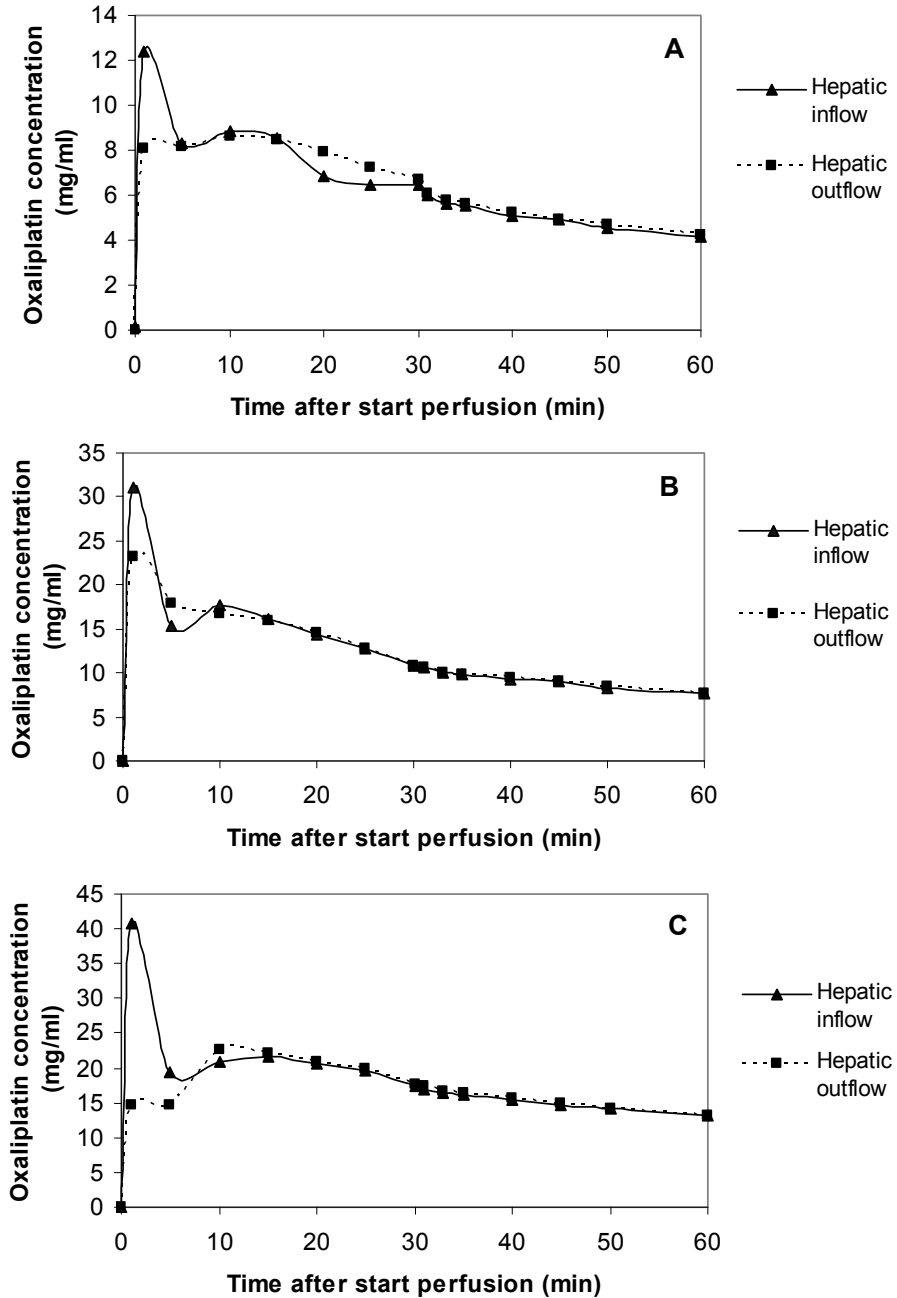
<i>Parameter</i>	<i>Mean ± SD</i>	<i>n</i>
Flow rate hepatic artery (mL/min)	293.9 ± 68.1	
Flow rate portal vein (mL/min)	312.8 ± 31.3	
Pressure hepatic artery (mm/Hg)	129.4 ± 20.0	
Pressure portal vein(mm/Hg)	49.1 ± 4.0	
Percentage leakage during perfusion	0.4 ± 0.5	
Blood loss (L)	5.5 ± 5.8	
Operative time (hr)	8.4 ± 1.6	
Hospital stay (days)	16.8 ± 10.5	
Perioperative mortality		2
Major complications		4
Sinusoidal obstruction syndrome		1
Hepatic artery obstruction		1
Wound infection		1
Re-operation due to bleeding		1

## Pharmacokinetics

Samples for pharmacokinetic analysis were successfully collected from each patient. Individual data of the AUC of both melphalan and oxaliplatin are shown in table 1. Escalating doses of oxaliplatin corresponded to an increasing AUC, with the maximum of 20.6 mg/L x h achieved at the highest dose level of 150mg oxaliplatin. The maximum peak concentration of oxaliplatin was 40.8 mg/L and was achieved in patient no 9, also at the highest dose level. Little difference was observed between the oxaliplatin concentrations in the hepatic inflow and outflow tract, as shown in figure 1, suggesting only limited hepatic extraction of oxaliplatin.

## Toxicity and complications

Major complications occurred in 4 patients of which 2 patients died perioperatively. One perioperative death was due to massive blood loss, while the other perioperative death was due to hepatotoxicity as a result of sinusoidal obstruction syndrome (SOS). The perioperative death due to massive blood loss was attributed to the procedure and not toxicity. Therefore another patient was included at this dose-level. Toxicity levels according to dose-level are shown in Table 3. Reversible grade 3-4 hepatotoxicity occurred in 7 patients. DLT consisted of irreversible grade 4 hepatotoxicity requiring hepatic-replacement therapy due to SOS and was reached at 150mg oxaliplatin combined with 100mg melphalan.



**Figure 1.** Typical examples of concentration time curves of oxaliplatin for each dose-level (A= 50mg oxaliplatin, B= 100mg oxaliplatin, C=150mg oxaliplatin). Increasing dose-levels show increasing peak concentrations of oxaliplatin. All concentration curves show a gradual decline over time.

**Table 3** Toxicity according to National Cancer Institute Common Toxicity Criteria version 3.0 (*n=11*)

	Grade 0	Grade 1	Grade 2	Grade 3	Grade 4
<b>Leukocyte nadir</b>					
- Dose level I	3	0	0	0	0
- Dose level II	4	0	0	0	0
- Dose level III	4	0	0	0	0
<b>Bilirubin</b>					
- Dose level I	2	1	0	0	0
- Dose level II	2	0	0	1	1
- Dose level III	0	0	0	2	2
<b>Alkaline phosphatase</b>					
- Dose level I	1	2	0	0	0
- Dose level II	0	1	2	0	1
- Dose level III	0	2	2	0	0
<b>Alanine aminotransferase (ALAT)</b>					
- Dose level I	2	0	0	1	0
- Dose level II	1	1	1	0	1
- Dose level III	0	1	2	0	1
<b>Asparate aminotransferase (ASAT)</b>					
- Dose level I	0	1	2	0	0
- Dose level II	0	2	0	2	0
- Dose level III	0	1	1	1	1

## Tumour response and patient survival

Of the 5 patients with colorectal cancer with an elevated CEA prior to IHP, three showed 50% or more reduction in CEA after IHP. Only 8 patients were available for response evaluation of which 3 patients showed a partial response according to the RECIST criteria. After a median follow up of only 18.2 months (95% CI; 10.5-26.0 months), median overall survival was 18.7 months (95% CI; 1.7-35.7 months) including 3 uveal melanoma patients..

## Discussion

In this study we evaluated escalating doses of oxaliplatin combined with a fixed dose of 100mg melphalan in an isolated hepatic perfusion circuit for patients with metastatic

disease limited to the liver. DLT, consisting of SOS, occurred at a relatively low dose level of 150mg oxaliplatin.

In previous IHP studies DLT also consisted of SOS as one of the main limitations of IHP with melphalan<sup>15, 16</sup>. Nonetheless, we did not expect DLT to occur at such a low dose of oxaliplatin, especially considering the 50% reduction in melphalan compared to our previous trials<sup>17, 31</sup>. At the time of development of this study protocol, oxaliplatin was considered a non-hepatotoxic drug, with only limited hepatotoxicity reported in both systemic and hepatic arterial infusion (HAI) trials<sup>32-36</sup>. This observation combined with the synergistic interaction between melphalan and oxaliplatin, as demonstrated by our previously published *in vitro* data, was the foundation of the development of this study protocol<sup>37</sup>. More recently however, after development of our study protocol, an increasing number of studies have reported on the hepatotoxicity, especially the risk of SOS, after treatment with oxaliplatin prior to hepatectomy of colorectal liver metastases. Incidence rates of SOS have been reported of up to 59% and oxaliplatin-based chemotherapy has been shown an independent risk factor for complications associated with hepatectomy with conflicting data concerning impact on both morbidity and mortality<sup>38-42</sup>. In view of the above, the addition of a cytostatic agent with a high incidence of SOS to a procedure with already a high risk of SOS, can explain the occurrence of DLT at only 150mg of oxaliplatin.

Similarly to our study, Zeh *et. al.* published a phase I study of IHP with oxaliplatin, but instead of oxaliplatin combination therapy, the perfusate consisted of oxaliplatin monotherapy, while in systemic therapy combination therapy has been shown more effective<sup>19, 43</sup>. Dose-limiting toxicity, also consisting of SOS, was observed at only 60 mg/m<sup>2</sup>, again indicating the high potential of inducing SOS if oxaliplatin is applied in isolated hepatic perfusion circuit, irrespective of combination with other agents. This study reported an overall response rate of 66%, but IHP was combined with HAI, complicating the interpretation of both toxicity and response rates. In our study meaningful interpretation of the response rate is complicated because of the phase I design and the inclusion of both uveal melanoma and colorectal cancer patients. Of the 8 colorectal cancer patients included, only two patients showed a partial response, both were treated at the highest dose level of 150mg oxaliplatin. All patients treated at the MTD of 100mg oxaliplatin showed progressive disease 3 months after IHP. Considering the dose of oxaliplatin used in regular systemic combination treatment in colorectal cancer patients of over 100mg/m<sup>2</sup> per treatment cycle, conducting a phase II IHP trial based on the MTD dose of 100mg oxaliplatin seems hardly beneficial.



Although the C<sub>max</sub> in our study was higher than the C<sub>max</sub> reported after a 2-hour infusion of oxaliplatin 130mg/m<sup>2</sup> in systemic trials, the AUC of oxaliplatin at the MTD in our study ranging from 11.9 mg/L x h to 16.5 mg/L x h was similar to the AUC reported in systemic trials<sup>44</sup>. A possible survival benefit for IHP over systemic treatment can only be achieved at this dose if response to oxaliplatin therapy is concentration- rather than dose-dependent. Our previous experience with melphalan showed that an increase in melphalan concentration did not increase response rates, but did increase toxicity<sup>31</sup>. Moreover, current HAI study protocols already apply a dose of oxaliplatin of up to 150mg/m<sup>2</sup><sup>32-36</sup>. Similarly to IHP, HAI offers the advantage of high concentrations of the cytostatic agent in the liver, but contrary to IHP, HAI is a minimally invasive procedure and is suitable for repetitive treatment, further limiting the possible role of oxaliplatin in IHP.

In conclusion, we have established the MTD of oxaliplatin in combination with 100mg melphalan in IHP at 100mg. Further escalation is limited by the occurrence of SOS. In view of similar and even higher doses of oxaliplatin applied in both systemic treatment and HAI, applying this dose in IHP will not result in further improvement of treatment of patients with isolated hepatic metastases.

## **Acknowledgements**

We kindly thank Prof. J.H.M. Schellens of The Netherlands Cancer Institute for his advisory role during the development of this study protocol.

## References

1. Jessup JM, McGinnis LS, Steele GD, Jr., Menck HR, Winchester DP. The National Cancer Data Base. Report on colon cancer. *Cancer* 1996;78(4):918-926.
2. Weiss L, Grundmann E, Torhorst J et al. Haematogenous metastatic patterns in colonic carcinoma: an analysis of 1541 necropsies. *J Pathol* 1986;150(3):195-203.
3. Welch JP, Donaldson GA. The clinical correlation of an autopsy study of recurrent colorectal cancer. *Ann Surg* 1979;189(4):496-502.
4. Tomlinson JS, Jarnagin WR, DeMatteo RP et al. Actual 10-year survival after resection of colorectal liver metastases defines cure. *J Clin Oncol* 2007;25(29):4575-4580.
5. Nordlinger B, Van CE, Rougier P et al. Does chemotherapy prior to liver resection increase the potential for cure in patients with metastatic colorectal cancer? A report from the European Colorectal Metastases Treatment Group. *Eur J Cancer* 2007;43(14):2037-2045.
6. Bismuth H, Adam R, Levi F et al. Resection of nonresectable liver metastases from colorectal cancer after neoadjuvant chemotherapy. *Ann Surg* 1996;224(4):509-520.
7. Adam R, Wicherts DA, de Haas RJ et al. Patients with initially unresectable colorectal liver metastases: is there a possibility of cure? *J Clin Oncol* 2009;27(11):1829-1835.
8. Alberts SR, Horvath WL, Sternfeld WC et al. Oxaliplatin, fluorouracil, and leucovorin for patients with unresectable liver-only metastases from colorectal cancer: a North Central Cancer Treatment Group phase II study. *J Clin Oncol* 2005;23(36):9243-9249.
9. Folprecht G, Gruenberger T, Bechstein WO et al. Tumour response and secondary resectability of colorectal liver metastases following neoadjuvant chemotherapy with cetuximab: the CELIM randomised phase 2 trial. *Lancet Oncol* 2010;11(1):38-47.
10. van Iersel LB, Koopman M, van de Velde CJ et al. Management of isolated nonresectable liver metastases in colorectal cancer patients: a case-control study of isolated hepatic perfusion with melphalan versus systemic chemotherapy. *Ann Oncol* 2010;21(8):1662-1667.
11. Hafstrom LR, Holmberg SB, Naredi PL et al. Isolated hyperthermic liver perfusion with chemotherapy for liver malignancy. *Surg Oncol* 1994;3(2):103-108.
12. Aigner K, Walther H, Tonn JC et al. [Isolated liver perfusion with 5-fluorouracil (5-FU) in the human]. *Chirurg* 1982;53(9):571-573.
13. Marinelli A, de Brauw LM, Beerman H et al. Isolated liver perfusion with mitomycin C in the treatment of colorectal cancer metastases confined to the liver. *Jpn J Clin Oncol* 1996;26(5):341-350.
14. Oldhafer KJ, Lang H, Frerker M et al. First experience and technical aspects of isolated liver perfusion for extensive liver metastasis. *Surgery* 1998;123(6):622-631.
15. Vahrmeijer AL, van Dierendonck JH, Keizer HJ et al. Increased local cytostatic drug exposure by isolated hepatic perfusion: a phase I clinical and pharmacologic evaluation of treatment with high dose melphalan in patients with colorectal cancer confined to the liver. *Br J Cancer* 2000;82(9):1539-1546.
16. Alexander HR, Jr., Bartlett DL, Libutti SK, Fraker DL, Moser T, Rosenberg SA. Isolated hepatic perfusion with tumor necrosis factor and melphalan for unresectable cancers confined to the liver. *J Clin Oncol* 1998;16(4):1479-1489.
17. Rothbarth J, Pijl ME, Vahrmeijer AL et al. Isolated hepatic perfusion with high-dose melphalan for the treatment of colorectal metastasis confined to the liver. *Br J Surg* 2003;90(11):1391-1397.
18. Chabot GG, Abigerges D, Catimel G et al. Population Pharmacokinetics and Pharmacodynamics of Irinotecan (Cpt-11) and Active Metabolite Sn-38 During Phase-I Trials. *Annals of Oncology* 1995;6(2):141-151.

19. Rothenberg ML, Oza AM, Bigelow RH et al. Superiority of oxaliplatin and fluorouracil-leucovorin compared with either therapy alone in patients with progressive colorectal cancer after irinotecan and fluorouracil-leucovorin: Interim results of a phase III trial. *Journal of Clinical Oncology* 2003;21(11):2059-2069.
20. Ramanathan RK, Clark JW, Kemeny NE et al. Safety and toxicity analysis of oxaliplatin combined with fluorouracil or as a single agent in patients with previously treated advanced colorectal cancer. *J Clin Oncol* 2003;21(15):2904-2911.
21. van Iersel LB, Koudijs TM, Hoekman EJ et al. In vitro Schedule-Dependent Interaction Between Melphalan and Oxaliplatin in Human Colorectal Cancer Cell Lines. *J Surg Res* 2009.
22. Marinelli A, de Brauw LM, Beerman H et al. Isolated liver perfusion with mitomycin C in the treatment of colorectal cancer metastases confined to the liver. *Jpn J Clin Oncol* 1996;26(5):341-350.
23. Runia RD, de Brauw LM, Kothuis BJ, Pauwels EK, van de Velde CJ. Continuous measurement of leakage during isolated liver perfusion with a radiotracer. *Int J Rad Appl Instrum B* 1987;14(2):113-118.
24. Alexander HR, Libutti SK, Bartlett DL, Puhlmann M, Fraker DL, Bachenheimer LC. A phase I-II study of isolated hepatic perfusion using melphalan with or without tumor necrosis factor for patients with ocular melanoma metastatic to liver. *Clin Cancer Res* 2000;6(8):3062-3070.
25. Alexander HR, Jr., Libutti SK, Pingpank JF et al. Hyperthermic isolated hepatic perfusion using melphalan for patients with ocular melanoma metastatic to liver. *Clin Cancer Res* 2003;9(17):6343-6349.
26. Bartlett DL, Libutti SK, Figg WD, Fraker DL, Alexander HR. Isolated hepatic perfusion for unresectable hepatic metastases from colorectal cancer. *Surgery* 2001;129(2):176-187.
27. Sparidans RW, Silvertand L, Dost F et al. Simple high-performance liquid chromatographic assay for melphalan in perfusate, rat liver and tumour tissue. *Biomed Chromatogr* 2003;17(7):458-464.
28. Therasse P, Arbuck SG, Eisenhauer EA et al. New guidelines to evaluate the response to treatment in solid tumors. European Organization for Research and Treatment of Cancer, National Cancer Institute of the United States, National Cancer Institute of Canada. *J Natl Cancer Inst* 2000;92(3):205-216.
29. Bismuth H. Surgical anatomy and anatomical surgery of the liver. *World J Surg* 1982;6(1):3-9.
30. van Iersel LB, Gelderblom H, Vahrmeijer AL et al. Isolated hepatic melphalan perfusion of colorectal liver metastases: outcome and prognostic factors in 154 patients. *Ann Oncol* 2008.
31. van Iersel LB, Verlaan MR, Vahrmeijer AL et al. Hepatic artery infusion of high-dose melphalan at reduced flow during isolated hepatic perfusion for the treatment of colorectal metastases confined to the liver: a clinical and pharmacologic evaluation. *Eur J Surg Oncol* 2007;33(7):874-881.
32. Kern W, Beckert B, Lang N et al. Phase I and pharmacokinetic study of hepatic arterial infusion with oxaliplatin in combination with folinic acid and 5-fluorouracil in patients with hepatic metastases from colorectal cancer. *Ann Oncol* 2001;12(5):599-603.
33. Ducreux M, Ychou M, Laplanche A et al. Hepatic arterial oxaliplatin infusion plus intravenous chemotherapy in colorectal cancer with inoperable hepatic metastases: a trial of the gastrointestinal group of the Federation Nationale des Centres de Lutte Contre le Cancer. *J Clin Oncol* 2005;23(22):4881-4887.
34. Fiorentini G, Rossi S, Dentico P et al. Oxaliplatin hepatic arterial infusion chemotherapy for hepatic metastases from colorectal cancer: a phase I-II clinical study. *Anticancer Res* 2004;24(3b):2093-2096.

35. Guthoff I, Lotspeich E, Fester C et al. Hepatic artery infusion using oxaliplatin in combination with 5-fluorouracil, folinic acid and mitomycin C: oxaliplatin pharmacokinetics and feasibility. *Anticancer Res* 2003;23(6D):5203-5208.
36. Mancuso A, Giuliani R, Accettura C et al. Hepatic arterial continuous infusion (HACI) of oxaliplatin in patients with unresectable liver metastases from colorectal cancer. *Anticancer Res* 2003;23(2C):1917-1922.
37. van Iersel LB, Koudijs TM, Hoekman EJ et al. In vitro Schedule-Dependent Interaction Between Melphalan and Oxaliplatin in Human Colorectal Cancer Cell Lines. *J Surg Res* 2009.
38. Soubrane O, Brouquet A, Zalinski S et al. Predicting high grade lesions of sinusoidal obstruction syndrome related to oxaliplatin-based chemotherapy for colorectal liver metastases: correlation with post-hepatectomy outcome. *Ann Surg* 2010;251(3):454-460.
39. Vauthey JN, Pawlik TM, Ribero D et al. Chemotherapy regimen predicts steatohepatitis and an increase in 90-day mortality after surgery for hepatic colorectal metastases. *J Clin Oncol* 2006;24(13):2065-2072.
40. Aloia T, Sebah M, Plasse M et al. Liver histology and surgical outcomes after preoperative chemotherapy with fluorouracil plus oxaliplatin in colorectal cancer liver metastases. *J Clin Oncol* 2006;24(31):4983-4990.
41. Nakano H, Oussoultzoglou E, Rosso E et al. Sinusoidal injury increases morbidity after major hepatectomy in patients with colorectal liver metastases receiving preoperative chemotherapy. *Ann Surg* 2008;247(1):118-124.
42. Tamandl D, Klinger M, Eipeldauer S et al. Sinusoidal obstruction syndrome impairs long-term outcome of colorectal liver metastases treated with resection after neoadjuvant chemotherapy. *Ann Surg Oncol* 2011;18(2):421-430.
43. Zeh HJ, III, Brown CK, Holtzman MP et al. A phase I study of hyperthermic isolated hepatic perfusion with oxaliplatin in the treatment of unresectable liver metastases from colorectal cancer. *Ann Surg Oncol* 2009;16(2):385-394.
44. Graham MA, Lockwood GF, Greenslade D, Brienza S, Bayssas M, Gamelin E. Clinical pharmacokinetics of oxaliplatin: a critical review. *Clin Cancer Res* 2000;6(4):1205-1218.



---

# **CHAPTER 8**

## **The future of isolated hepatic perfusion for isolated liver metastases**

L.B.J. van Iersel, H. Gelderblom, J.W.R. Nortier,  
C.J.H. van de Velde

---



## Introduction

Worldwide colorectal cancer is the third most common cause of cancer related deaths with approximately 639000 deaths each year (WHO fact sheet 297). In approximately 30% of colorectal cancer patients the liver is the only site of metastatic disease<sup>1, 2</sup>. Complete surgical resection is considered the best treatment with 5-year survival rates ranging from 25-51%. Unfortunately, surgical resection is only possible in less than 10 percent of patients due to the number, location or size of the metastases<sup>3-5</sup>. Recently, neoadjuvant chemotherapy has been introduced, rendering another 10 to 30 % of patients resectable<sup>6</sup>. The management of irresectable colorectal liver metastases, on the other hand, remains a challenge for all cancer specialists. Recent studies have shown improved survival with the introduction of oxaliplatin, irinotecan, bevacizumab and cetuximab in the systemic treatment of colorectal metastases<sup>7-12</sup>. Regional treatment options however, can offer the potential benefit of both aggressive local treatment and limited systemic toxicity. Several regional therapies have been developed including isolated hepatic perfusion (IHP). IHP, a technique which involves complete vascular isolation of the liver, allows for high local drug exposure. Phase II studies involving IHP in colorectal cancer patients have shown hepatic response rates up to 74% with a median time to hepatic progression up to 14.5 months, a median overall survival of 27 months and 5 year survival of 9%<sup>13-17</sup>.

## Advancing role of systemic treatment

When IHP was first introduced, the standard treatment for metastatic colorectal cancer consisted of 5-FU based schedules, resulting in response rates around 15%, median time to progression of 5 months and overall survival of 12 months<sup>18</sup>. Recently, several new agents have become available including oxaliplatin, irinotecan and the monoclonal antibodies bevacizumab and panitumumab/cetuximab<sup>8-12, 19-21</sup>. The introduction of irinotecan and oxaliplatin combined with 5-FU/leucovorin or capecitabine has increased median progression free survival and overall survival from approximately 5 and 12 months to approximately 9 and 17 months, respectively<sup>9, 11, 22-26</sup>. If both treatment schedules are combined even better results have been reported. Tournigand *et al* conducted a phase III cross-over study of first-line chemotherapy with in one arm 5-FU/leucovorin with oxaliplatin and in the other arm 5-FU/leucovorin with irinotecan resulting in maximum median survival after both treatments of 21.5 months<sup>12</sup>. Koopman *et al* showed that both combination treatment and sequential treatment with capecitabine, irinotecan and oxaliplatin yields similar results<sup>27</sup>. Even more recently, the monoclonal antibodies have been introduced for the treatment of colorectal cancer. Hurwitz *et al* reported that the



addition of bevacizumab, a monoclonal antibody directed against vascular endothelial growth factor (VEGF), to bolus irinotecan and 5-FU/leucovorin as a first-line treatment resulted in increase of progression free survival to 10.6 months and overall survival to 20.3 months<sup>10</sup>. Similarly, panitumumab/cetuximab, monoclonal antibodies against epidermal growth factor receptor (EGFR), have also improved survival in combination with either irinotecan or oxaliplatin, especially in patients without K-ras mutations<sup>19,21</sup>. At the moment the combination of fluoropyrimidine-based chemotherapy with oxaliplatin and bevacizumab is considered standard first-line treatment in metastatic colorectal cancer, while irinotecan should be reserved for second-line treatment and panitumumab or cetuximab for third-line treatment for patients with wild type K-ras<sup>28,29</sup>.

Most treatment schedules described above can be given safely prior to and after IHP without increasing the toxicity of IHP (**Chapter 4**), rendering IHP both a possible first-line or second- and even third-line treatment option after systemic treatment. The question remains whether systemic treatment alone can achieve similar or even better results in the selected group of patients with liver metastases only, eligible for IHP. We compared IHP in 99 patients with 105 patients who received a combination of capecitabine, oxaliplatin and irinotecan (**Chapter 5**). There was no significant difference in overall survival between IHP and systemic treatment (25.0 months vs. 21.7 months;  $p=0.29$ ). However, this study was complicated by several drawbacks. Overall survival was calculated from the date of randomization for systemic treatment and date of surgery for IHP, but not from the date of diagnosis of liver metastases. Contrary to the systemic treatment patients, the IHP patients were allowed to receive systemic treatment prior to the start of the study treatment. Therefore, it is likely the IHP patients suffered from a relative survival disadvantage as compared to the systemic treatment patients. We attempted to exclude some of this disadvantage by performing a subgroup analysis of the IHP patients who received IHP as first-line treatment. Although overall survival increased to 28.9 months, still no significant difference in survival could be demonstrated. Probably, the lack of a statistically different survival advantage can be mainly attributed to the high mortality in the first few months after IHP.

For IHP to remain a treatment option for isolated liver metastases, perioperative mortality needs to be reduced or new agents with better responses need to be introduced. Possibly, in view of the developments in systemic treatment, IHP should be abandoned completely for the treatment of colorectal liver metastases and the application of IHP in metastases from various other origins further explored.

## Improving the technique, reducing the mortality

The IHP procedure, as currently performed at our center, is a difficult technique with a relatively high mortality and considerable morbidity. Several efforts have been undertaken to develop minimally invasive procedures for IHP, but with only limited success. Chemofiltration has been used to allow for high doses of intrahepatic chemotherapy without systemic toxicity<sup>30-32</sup>. After the drug is infused in the hepatic artery, the hepatic venous blood is bypassed to a charcoal hemoperfusion filter for extracorporeal drug elimination before it returns to the patients' systemic circulation. A phase I study using the technique described above, demonstrated that treatment with high-dose melphalan is feasible. Nevertheless, complete extraction of melphalan by charcoal hemoperfusion is not possible, limiting the maximum tolerated dose<sup>33</sup>. At our center, we demonstrated complete isolation of the liver using minimally invasive techniques to be technically feasible in pigs, but recently performed phase I trials at other centers have shown disappointing results<sup>34,35</sup>. Savier *et al.* reported a repetitive IHP procedure, in which the first course was given at laparotomy and the next two courses with the new percutaneous technique<sup>36</sup>. At the initial laparotomy a catheter in the gastroduodenal artery was inserted which during subsequent percutaneous treatment was used to administer the melphalan. Although they achieved an isolated hepatic perfusion circuit, considerable leakage to the systemic circulation occurred during IHP. Another study published by van Etten *et al* reported a phase I-II study in 18 patients<sup>37</sup>. In the first 8 patients vascular isolation was attempted through occlusion of the portal vein with outflow through the hepatic veins into an intracaval double-balloon catheter, resulting in on average 56% leakage. The following 10 patients were treated with a different technique using retrograde outflow perfusion, with a triple balloon blocking outflow into the caval vein and allowing outflow via the portal vein. The last technique resulted in less leakage, but retrograde perfusion was still complicated by 35% leakage on average, limiting the possible applications of this technique. Recently Verhoef *et al.* published a study on an alternative simplified technique for IHP.<sup>38</sup> A new technique using a retrograde hepatic flow in an isolated hypoxic hepatic perfusion was applied. In total 24 patients were treated with irresectable liver metastases of various origin. Operation time and blood loss were considerably less as compared to classical IHP and no perioperative mortality was observed. Although the method described above was open procedure not suitable for repetition it seems the most promising of the recent developments, considering the leakage control and reduction in mortality.

## Introducing new agents

The past decade melphalan has been the main drug applied in IHP. The application of new agents in IHP might improve response rates and increase overall survival. Before, we examined new agents, we tried to improve efficacy by changing the administration of melphalan (**Chapter 3**). To achieve high local concentrations, we administered 200 mg of melphalan through a 20-minute infusion in the hepatic artery, instead of the previously performed bolus administration. Although we achieved high local concentrations in 30 patients for an increased period of time, toxicity increased without improvement of survival or response rates. We concluded that while response is probably dose-dependent, toxicity is mainly concentration-dependent. Therefore we abandoned this technique and directed our efforts towards exploring new agents.

New agents for IHP have to fulfil at least three conditions. Firstly, the drug has to cause rapid tumour cell destruction, due to the 1-hour nature of the procedure. Secondly, the drug has to be a direct working agent and thirdly, ideally the agent has a steep dose-response curve. Of the drugs recently introduced for the systemic treatment of colorectal cancer, only oxaliplatin fulfils all these conditions. Zeh *et al.* published a phase I study of IHP with oxaliplatin in colorectal cancer patients<sup>39</sup>. Dose-limiting veno-occlusive disease was observed at 60mg/m<sup>2</sup>. In this study, however IHP was combined with HAI complicating the interpretation of both toxicity and response rates. Moreover, the perfusate consisted of oxaliplatin monotherapy, while in systemic therapy combination therapy has been shown more beneficial<sup>40</sup>. Therefore, we studied the combination of oxaliplatin with melphalan. In vitro results show a schedule dependent synergistic interaction between these two agents (**Chapter 6**). Recently, we performed a phase I trial in 11 patients with IHP with escalating doses of oxaliplatin followed by 100mg melphalan (**Chapter 7**). Dose-limiting-toxicity, consisting of sinusoidal obstruction syndrome (SOS), was achieved at only 150mg oxaliplatin combined with 100mg melphalan. Currently, the dose of oxaliplatin used in regular systemic combination treatment in colorectal cancer patients exceeds 100mg/m<sup>2</sup> per treatment cycle. Therefore conducting a phase II IHP trial based on the MTD dose of 100mg oxaliplatin seems hardly beneficial. Moreover, HAI study protocols already apply a dose of oxaliplatin of up to 150mg/m<sup>2</sup> and contrary to IHP the procedure is suitable for repetition<sup>41-45</sup>. In view of this we believe that further exploration of the application of oxaliplatin in IHP will not improve treatment results.

## Finding new applications

While the application of IHP in colorectal cancer patients has been thoroughly explored, little is known about the application in liver metastases from other primary tumours. Possibly a new role can be found for IHP in isolated liver metastases from a variety of tumours. Neuroendocrine tumours and uveal melanomas, although rare, are the second most common origin of metastases confined to the liver<sup>46</sup>.

In neuroendocrine cancer metastases results of systemically administered agents have been disappointing with response rates around 30-40% for cytostatic drugs and 11% for interferon- $\alpha$ <sup>47-49</sup>. Symptomatic relief can be achieved through somastatin analogs such as octreotide. Symptomatic improvement occurs in up to 70% of patients, but objective tumour response is less than 10% and drug resistance can develop in 3-12 months<sup>50-53</sup>. Grover *et al.* reported the experience with IHP in 13 neuroendocrine cancer patients with a overall response rate of 50% and median progression free survival of 7 months<sup>54</sup>. The nature and incidence of major complications and mortality was similar to other trials independent of primary origin of liver metastases. At our center we have only treated two patients with liver metastases from neuroendocrine carcinoma, one patients showed stable disease, while the other patient showed a partial response for 33.4 months (**Chapter 2**).

For the treatment of metastatic uveal melanoma no standard systemic agent currently exists. Several studies have reported response rates of less than 10% to conventional systemic chemotherapy<sup>55,56</sup>. Results with immunotherapy, as for example interferon- $\alpha$  and interleukin-2, are equally disappointing with no or only minor responses<sup>57,58</sup>. Alexander *et al* reported the results of IHP with 1.5mg/kg melphalan in 29 uveal melanoma patients. Hepatic response rate was 62% with a progression-free survival of 8 months and an overall survival of 12.1 months. In our patients the response rate was less; only 33%, but 50% of patients did show stable disease with a median time to progression of 6.6 months and an overall survival of 10 months similar to the results of Alexander *et al.* (**Chapter 2**). Although these results may seem disappointing as compared to IHP in other primary tumours, there is a survival benefit compared to a median survival of 2 months in uveal melanoma patients with liver metastases without antitumour treatment<sup>59</sup>. Moreover, we have no accepted alternative treatment options for uveal melanoma patients with irresectable isolated liver metastases. Recently, at the 2010 ASCO annual meeting Pingpank *et al.* presented a phase III study in 92 malignant melanoma patients with hepatic metastases randomly assigned to either percutaneous hepatic perfusion with melphalan or standard of care. Median hepatic progression free survival was 245 days for the perfusion group and 49 days for the standard care group ( $p < 0.001$ ). Cur-

rently we are looking into the application of new agents in IHP for uveal melanoma patients. Peters *et al* reported the use of HAI with fotemustine, an alkylating agent, in 101 uveal melanoma patients with liver metastases<sup>60</sup>. Fotemustine was infused in the hepatic artery for a 4-week induction period followed by a maintenance treatment every three weeks until disease progression. The overall response rate was 36%, with a median overall survival of 15 months and a 2-year survival rate of 29%. Although the response rate of fotemustine infusion is similar to our results with IHP in uveal melanoma patients, the overall survival of 15 months seems superior to our observed 10 months. Possibly, in future IHP trials fotemustine can be introduced.

## **Conclusion**

Although IHP made a promising start in the early 90s, currently it is faced by many challenges. In view of recent developments in systemic treatment, the absence of significant improvement of the technique and the lack of new applicable agents, IHP should not be considered a standard treatment option for colorectal cancer patients with isolated liver metastases. Possibly, a role still exists for IHP in the treatment of liver metastases from non-colorectal cancer origin. Whether under these circumstances, IHP can still attract the interest of both clinical and surgical oncologists necessary for further improvements, remains the question.

## References

1. Weiss L, Grundmann E, Torhorst J et al. Haematogenous metastatic patterns in colonic carcinoma: an analysis of 1541 necropsies. *J Pathol* 1986;150(3):195-203.
2. Welch JP, Donaldson GA. The clinical correlation of an autopsy study of recurrent colorectal cancer. *Ann Surg* 1979;189(4):496-502.
3. Scheele J, Stang R, Altendorf-Hofmann A, Paul M. Resection of colorectal liver metastases. *World J Surg* 1995;19(1):59-71.
4. Nordlinger B, Guiguet M, Vaillant JC et al. Surgical resection of colorectal carcinoma metastases to the liver. A prognostic scoring system to improve case selection, based on 1568 patients. *Association Francaise de Chirurgie. Cancer* 1996;77(7):1254-1262.
5. Yamamoto J, Shimada K, Kosuge T, Yamasaki S, Sakamoto M, Fukuda H. Factors influencing survival of patients undergoing hepatectomy for colorectal metastases. *Br J Surg* 1999;86(3):332-337.
6. Nordlinger B, Van CE, Rougier P et al. Does chemotherapy prior to liver resection increase the potential for cure in patients with metastatic colorectal cancer? A report from the European Colorectal Metastases Treatment Group. *Eur J Cancer* 2007;43(14):2037-2045.
7. Cunningham D, Humblet Y, Siena S et al. Cetuximab monotherapy and cetuximab plus irinotecan in irinotecan-refractory metastatic colorectal cancer. *N Engl J Med* 2004;351(4):337-345.
8. de Gramont A, Figer A, Seymour M et al. Leucovorin and fluorouracil with or without oxaliplatin as first-line treatment in advanced colorectal cancer. *J Clin Oncol* 2000;18(16):2938-2947.
9. Douillard JY, Cunningham D, Roth AD et al. Irinotecan combined with fluorouracil compared with fluorouracil alone as first-line treatment for metastatic colorectal cancer: a multicentre randomised trial. *Lancet* 2000;355(9209):1041-1047.
10. Hurwitz H, Fehrenbacher L, Novotny W et al. Bevacizumab plus irinotecan, fluorouracil, and leucovorin for metastatic colorectal cancer. *New England Journal of Medicine* 2004;350(23):2335-2342.
11. Saltz LB, Cox JV, Blanke C et al. Irinotecan plus fluorouracil and leucovorin for metastatic colorectal cancer. *Irinotecan Study Group. N Engl J Med* 2000;343(13):905-914.
12. Tournigand C, Andre T, Achille E et al. FOLFIRI followed by FOLFOX6 or the reverse sequence in advanced colorectal cancer: A randomized GERCOR study. *Journal of Clinical Oncology* 2004;22(2):229-237.
13. Rothbarth J, Pijl ME, Vahrmeijer AL et al. Isolated hepatic perfusion with high-dose melphalan for the treatment of colorectal metastasis confined to the liver. *Br J Surg* 2003;90(11):1391-1397.
14. Alexander HR, Jr., Bartlett DL, Libutti SK, Fraker DL, Moser T, Rosenberg SA. Isolated hepatic perfusion with tumor necrosis factor and melphalan for unresectable cancers confined to the liver. *J Clin Oncol* 1998;16(4):1479-1489.
15. Alexander HR, Jr., Libutti SK, Pingpank JF, Bartlett DL, Helsabeck C, Beresneva T. Isolated hepatic perfusion for the treatment of patients with colorectal cancer liver metastases after irinotecan-based therapy. *Ann Surg Oncol* 2005;12(2):138-144.
16. Bartlett DL, Libutti SK, Figg WD, Fraker DL, Alexander HR. Isolated hepatic perfusion for unresectable hepatic metastases from colorectal cancer. *Surgery* 2001;129(2):176-187.
17. van Iersel LB, Gelderblom H, Vahrmeijer AL et al. Isolated hepatic melphalan perfusion of colorectal liver metastases: outcome and prognostic factors in 154 patients. *Ann Oncol* 2008.

18. Van Cutsem E, Twelves C, Cassidy J et al. Oral capecitabine compared with intravenous fluorouracil plus leucovorin in patients with metastatic colorectal cancer: results of a large phase III study. *J Clin Oncol* 2001;19(21):4097-4106.
19. Bokemeyer C, Bondarenko I, Makhson A et al. Fluorouracil, leucovorin, and oxaliplatin with and without cetuximab in the first-line treatment of metastatic colorectal cancer. *J Clin Oncol* 2009;27(5):663-671.
20. Saltz LB, Clarke S, Diaz-Rubio E et al. Bevacizumab in combination with oxaliplatin-based chemotherapy as first-line therapy in metastatic colorectal cancer: a randomized phase III study. *J Clin Oncol* 2008;26(12):2013-2019.
21. Cunningham D, Humblet Y, Siena S et al. Cetuximab monotherapy and cetuximab plus irinotecan in irinotecan-refractory metastatic colorectal cancer. *N Engl J Med* 2004;351(4):337-345.
22. Cunningham D, Pyrhonen S, James RD et al. Randomised trial of irinotecan plus supportive care versus supportive care alone after fluorouracil failure for patients with metastatic colorectal cancer. *Lancet* 1998;352(9138):1413-1418.
23. Rougier P, Van Cutsem E, Bajetta E et al. Randomised trial of irinotecan versus fluorouracil by continuous infusion after fluorouracil failure in patients with metastatic colorectal cancer. *Lancet* 1998;352(9138):1407-1412.
24. Becouarn Y, Ychou M, Ducreux M et al. Phase II trial of oxaliplatin as first-line chemotherapy in metastatic colorectal cancer patients. Digestive Group of French Federation of Cancer Centers. *J Clin Oncol* 1998;16(8):2739-2744.
25. de Gramont A, Figer A, Seymour M et al. Leucovorin and fluorouracil with or without oxaliplatin as first-line treatment in advanced colorectal cancer. *J Clin Oncol* 2000;18(16):2938-2947.
26. Giacchetti S, Perpoint B, Zidani R et al. Phase III multicenter randomized trial of oxaliplatin added to chronomodulated fluorouracil-leucovorin as first-line treatment of metastatic colorectal cancer. *J Clin Oncol* 2000;18(1):136-147.
27. Koopman M, Antonini NF, Douma J et al. Sequential versus combination chemotherapy with capecitabine, irinotecan, and oxaliplatin in advanced colorectal cancer (CAIRO): a phase III randomised controlled trial. *Lancet* 2007;370(9582):135-142.
28. Hecht JR, Mitchell E, Chidiac T et al. A randomized phase III trial of chemotherapy, bevacizumab, and panitumumab compared with chemotherapy and bevacizumab alone for metastatic colorectal cancer. *J Clin Oncol* 2009;27(5):672-680.
29. Tol J, Koopman M, Cats A et al. Chemotherapy, bevacizumab, and cetuximab in metastatic colorectal cancer. *N Engl J Med* 2009;360(6):563-572.
30. Curley SA, Byrd DR, Newman RA et al. Reduction of systemic drug exposure after hepatic arterial infusion of doxorubicin with complete hepatic venous isolation and extracorporeal chemofiltration. *Surgery* 1993;114(3):579-585.
31. Ravikumar TS, Pizzorno G, Bodden W et al. Percutaneous hepatic vein isolation and high-dose hepatic arterial infusion chemotherapy for unresectable liver tumors. *J Clin Oncol* 1994;12(12):2723-2736.
32. Ku Y, Iwasaki T, Fukumoto T et al. Percutaneous isolated liver chemoperfusion for treatment of unresectable malignant liver tumors: technique, pharmacokinetics, clinical results. *Recent Results Cancer Res* 1998;147:67-82.
33. Pingpank JF, Libutti SK, Chang R et al. Phase I study of hepatic arterial melphalan infusion and hepatic venous hemofiltration using percutaneously placed catheters in patients with unresectable hepatic malignancies. *J Clin Oncol* 2005;23(15):3465-3474.

34. Rothbarth J, Pijl ME, Tollenaar RA et al. An experimental minimally invasive perfusion technique for the treatment of liver metastases. *Eur J Surg Oncol* 2003;29(9):757-763.
35. van IJken MG, de Bruijn EA, de Boeck G, ten Hagen TL, van dS, Jr., Eggermont AM. Isolated hypoxic hepatic perfusion with tumor necrosis factor-alpha, melphalan, and mitomycin C using balloon catheter techniques: a pharmacokinetic study in pigs. *Ann Surg* 1998;228(6):763-770.
36. Savier E, Azoulay D, Huguet E, Lokiec F, Gil-Delgado M, Bismuth H. Percutaneous isolated hepatic perfusion for chemotherapy: a phase 1 study. *Arch Surg* 2003;138(3):325-332.
37. van Etten B, Brunstein F, van IJken MG et al. Isolated hypoxic hepatic perfusion with orthograde or retrograde flow in patients with irresectable liver metastases using percutaneous balloon catheter techniques: a phase I and II study. *Ann Surg Oncol* 2004;11(6):598-605.
38. Verhoef C, de Wilt JH, Brunstein F et al. Isolated hypoxic hepatic perfusion with retrograde out-flow in patients with irresectable liver metastases; a new simplified technique in isolated hepatic perfusion. *Ann Surg Oncol* 2008;15(5):1367-1374.
39. Zeh HJ, III, Brown CK, Holtzman MP et al. A phase I study of hyperthermic isolated hepatic perfusion with oxaliplatin in the treatment of unresectable liver metastases from colorectal cancer. *Ann Surg Oncol* 2009;16(2):385-394.
40. Rothenberg ML, Oza AM, Bigelow RH et al. Superiority of oxaliplatin and fluorouracil-leucovorin compared with either therapy alone in patients with progressive colorectal cancer after irinotecan and fluorouracil-leucovorin: Interim results of a phase III trial. *Journal of Clinical Oncology* 2003;21(11):2059-2069.
41. Kern W, Beckert B, Lang N et al. Phase I and pharmacokinetic study of hepatic arterial infusion with oxaliplatin in combination with folinic acid and 5-fluorouracil in patients with hepatic metastases from colorectal cancer. *Ann Oncol* 2001;12(5):599-603.
42. Guthoff I, Lotspeich E, Fester C et al. Hepatic artery infusion using oxaliplatin in combination with 5-fluorouracil, folinic acid and mitomycin C: oxaliplatin pharmacokinetics and feasibility. *Anticancer Res* 2003;23(6D):5203-5208.
43. Mancuso A, Giuliani R, Accettura C et al. Hepatic arterial continuous infusion (HACI) of oxaliplatin in patients with unresectable liver metastases from colorectal cancer. *Anticancer Res* 2003;23(2C):1917-1922.
44. Fiorentini G, Rossi S, Dentico P et al. Oxaliplatin hepatic arterial infusion chemotherapy for hepatic metastases from colorectal cancer: a phase I-II clinical study. *Anticancer Res* 2004;24(3b):2093-2096.
45. Ducreux M, Ychou M, Laplanche A et al. Hepatic arterial oxaliplatin infusion plus intravenous chemotherapy in colorectal cancer with inoperable hepatic metastases: a trial of the gastrointestinal group of the Federation Nationale des Centres de Lutte Contre le Cancer. *J Clin Oncol* 2005;23(22):4881-4887.
46. Sutcliffe R, Maguire D, Ramage J, Rela M, Heaton N. Management of neuroendocrine liver metastases. *Am J Surg* 2004;187(1):39-46.
47. MOERTEL CG, Kvols LK, O'Connell MJ, Rubin J. Treatment of neuroendocrine carcinomas with combined etoposide and cisplatin. Evidence of major therapeutic activity in the anaplastic variants of these neoplasms. *Cancer* 1991;68(2):227-232.
48. Rivera E, Ajani JA. Doxorubicin, streptozocin, and 5-fluorouracil chemotherapy for patients with metastatic islet-cell carcinoma. *Am J Clin Oncol* 1998;21(1):36-38.
49. Oberg K. Interferon in the management of neuroendocrine GEP-tumors: a review. *Digestion* 2000;62 Suppl 1:92-97.



50. Kvols LK, MOERTEL CG, O'Connell MJ, Schutt AJ, Rubin J, Hahn RG. Treatment of the malignant carcinoid syndrome. Evaluation of a long-acting somatostatin analogue. *N Engl J Med* 1986;315(11):663-666.
51. Oberg K. Endocrine tumors of the gastrointestinal tract: systemic treatment. *Anticancer Drugs* 1994;5(5):503-519.
52. Oberg K, Norheim I, Theodorsson E. Treatment of malignant midgut carcinoid tumours with a long-acting somatostatin analogue octreotide. *Acta Oncol* 1991;30(4):503-507.
53. Vinik A, Moattari AR. Use of somatostatin analog in management of carcinoid syndrome. *Dig Dis Sci* 1989;34(3 Suppl):14S-27S.
54. Grover AC, Libutti SK, Pingpank JF, Helsabeck C, Beresnev T, Alexander HR, Jr. Isolated hepatic perfusion for the treatment of patients with advanced liver metastases from pancreatic and gastrointestinal neuroendocrine neoplasms. *Surgery* 2004;136(6):1176-1182.
55. Bedikian AY, Legha SS, Mavligit G et al. Treatment of uveal melanoma metastatic to the liver: a review of the M. D. Anderson Cancer Center experience and prognostic factors. *Cancer* 1995;76(9):1665-1670.
56. Flaherty LE, Unger JM, Liu PY, Mertens WC, Sondak VK. Metastatic melanoma from intraocular primary tumors: the Southwest Oncology Group experience in phase II advanced melanoma clinical trials. *Am J Clin Oncol* 1998;21(6):568-572.
57. Agarwala SS, Hellstrand K, Gehlsen K, Naredi P. Immunotherapy with histamine and interleukin 2 in malignant melanoma with liver metastasis. *Cancer Immunol Immunother* 2004;53(9):840-841.
58. Bedikian AY. Metastatic uveal melanoma therapy: current options. *Int Ophthalmol Clin* 2006;46(1):151-166.
59. Gragoudas ES, Egan KM, Seddon JM et al. Survival of patients with metastases from uveal melanoma. *Ophthalmology* 1991;98(3):383-389.
60. Peters S, Voelter V, Zografos L et al. Intra-arterial hepatic fotemustine for the treatment of liver metastases from uveal melanoma: experience in 101 patients. *Ann Oncol* 2006;17(4):578-583.

.....

## **Nederlandse samenvatting**

.....



## Nederlandse samenvatting

Colorectale kanker (kanker aan de dikke darm of endeldarm) is de belangrijkste oorzaak van uitzaaiingen (metastasen) naar de lever. Uiteindelijk ontwikkelt 70% van de patiënten met colorectale kanker uitzaaiingen naar de lever. Echter, bij slechts 30% van de patiënten zijn deze uitzaaiingen beperkt tot alleen de lever. Bij deze laatste groep patiënten is genezing in theorie mogelijk, indien de uitzaaiingen operatief worden verwijderd. Helaas is dit bij de meeste patiënten niet mogelijk aangezien de locatie, grootte of aantallen van de uitzaaiingen dit onmogelijk maakt. Gelukkig zijn er de laatste jaren verschillende behandelingen ontwikkeld om zowel de kwaliteit als de duur van het leven van patiënten met leveruitzaaiingen van colorectale kanker te verbeteren.

In **hoofdstuk 1** beschrijven we de verschillende behandelingsmogelijkheden voor levermetastasen van colorectale kanker. Naast chemotherapie in de algemene bloedbaan (systemisch) bestaan er verschillende locale behandelingsmogelijkheden waaronder de geïsoleerde leverperfusie (IHP). IHP is een techniek waarbij de aan- en afvoerende vaten van de lever tijdelijk afgesloten worden, opdat een gesloten circuit ontstaat. De afscheiding van de lever van de algemene bloedbaan maakt het mogelijk om lokaal een hoge dosis chemotherapie toe te dienen. Gedurende deze procedure wordt de lever van zuurstof voorzien door een pomp met een oxygenator en wordt de lekkage van het chemotherapeuticum naar de algemene bloedbaan geregistreerd. Na rondpompen van het chemotherapeuticum, meestal gedurende 1 uur, wordt de lever gespoeld met schoon kunstbloed. Uiteindelijk wordt de oorspronkelijke vaatvoorziening weer hersteld. IHP wordt sinds een aantal jaren in een beperkt aantal centra in de wereld toegepast. In het Leids Universitair Medisch Centrum (LUMC) is al bijna twintig jaar ervaring met deze techniek en zijn meer dan 130 patiënten behandeld met IHP. Na een fase I studie van IHP, waarbij een dosisescalatie studie is gedaan met melfalan is in 1994 een fase II studie gestart. Evaluatie van de eerste 66 patiënten van de fase II studie lieten bij meer dan 50% van de patiënten een gedeeltelijk of zelfs compleet verdwijnen van de metastasen zien. Echter, IHP is een ingrijpende procedure met veel complicaties die zelfs bij 5-6% van de patiënten leidt tot de dood. Aanvankelijk, toen IHP werd ontwikkeld was er slechts beperkte systemische behandeling van levermetastasen mogelijk. De laatste 10 jaar zijn er verschillende nieuwe chemotherapeutica geïntroduceerd voor de behandeling van levermetastasen van colorectale kanker, met goed resultaat. Gezien deze ontwikkelingen is het de vraag of IHP in zijn huidige hoedanigheid nog een plek verdient binnen de behandeling van patiënten met levermetastasen. Mogelijk kan de positie van IHP verbeterd worden door een verbetering van de techniek, de introductie van nieuwe chemotherapeutica of het ontdekken van nieuwe toepassingen.

In **hoofdstuk 2** beschrijven we de toepassing van IHP met melfalan bij een nieuwe groep patiënten. In het totaal zijn 19 patiënten met leveruitzaaiingen niet afkomstig van colorectale kanker behandeld met IHP. Dertien patiënten hadden uitzaaiingen van ooglaneloom, 2 patiënten van neuroendocriene tumoren, 2 patiënten van gastro-intestinale stromale tumoren, 1 patiënt van weke delen kanker en 1 patiënt had leverkanker. Van de ooglaneloom patiënten reageerde 33% op de behandeling gedurende gemiddeld 6.6 maanden. De gemiddelde overleving was 10 maanden. Hoewel deze cijfers teleurstellend lijken dient in ogenschouw genomen te worden dat het natuurlijk beloop van ooglaneloom veel slechter is dan dat van colorectale kanker en dat in tegenstelling tot colorectale kanker er geen alternatieve behandelingsmogelijkheden zijn. Van de overige patiënten reageerde 50% op de behandeling, waarbij opgemerkt dient te worden dat bij de patiënt met weke delen kanker bij beeldvorming helemaal geen uitzaaiingen meer zichtbaar waren. Mogelijk kunnen deze resultaten nog verbeterd worden indien een ander middel wordt gebruikt dan melfalan, specifiek voor deze vormen van kanker.

In **hoofdstuk 3** worden de resultaten beschreven van een nieuwe IHP techniek waarbij het chemotherapeuticum niet in één keer aan het gesloten circuit wordt toegediend, maar geleidelijk via de slagader de lever wordt ingespoten. Uit eerdere studies weten we dat indien melfalan in één keer aan het systeem wordt toegediend er slechts voor korte tijd een hoge concentratie wordt bereikt. Door het geleidelijk aan toedienen van melfalan werd getracht een hoge concentratie voor langere tijd te bereiken, om de effectiviteit van de behandeling te vergroten. In het totaal zijn 30 patiënten met levermetastasen van colorectale kanker behandeld met deze nieuwe techniek. Farmacokinetische analyses lieten inderdaad een hoge concentratie gedurende een wel 2 keer zo lange tijd als bij de reguliere perfusies zien. Echter, veel meer patiënten hadden complicaties in vergelijking tot de reguliere procedure, terwijl bij minder patiënten de levermetastasen reageerden op de behandeling. Hoogstwaarschijnlijk worden de gezonde levercellen eerder beschadigd door de hoge concentratie dan de kankercellen. Daarnaast kunnen bij deze procedure door de technische beperkingen slechts lage drukken worden bereikt, mogelijk dat een hogere druk (zoals bij de reguliere procedure) nodig is om bij de kankercellen te komen.

In **hoofdstuk 4** worden de resultaten van alle patiënten met colorectale kanker beschreven die tussen augustus 1994 en december 2004 behandeld zijn met IHP in het LUMC. Gekeken werd of er prognostische factoren geïdentificeerd konden worden die een betere patiëntselectie mogelijk maakt. In het totaal werden in deze periode 105 patiënten behandeld door middel van IHP. De perioperatieve mortaliteit was 7%. De uitzaaiingen in de lever werden kleiner of verdwenen bij 50% van de patiënten voor gemiddeld 7.4 maanden. De gemiddelde overleving na de leverperfusie was 24.8 maanden.

den. De patiënten met meer dan 10 levermetastasen, postoperatieve complicaties of bij wie het technisch niet gelukt was om zowel de ader als de slagader te gebruiken voor de perfusie overleefden significant korter. Bovendien viel op dat in retrospect, bij 7% van de patiënten ook uitzaaingen buiten de lever aanwezig waren voor IHP, wat mogelijk voorkomen had kunnen worden door betere beeldvorming voor de IHP.

Hoewel al jaren onderzoek wordt verricht naar de geïsoleerde leverperfusie, is het onduidelijk of in deze kleine, geselecteerde groep patiënten vergelijkbare resultaten behaald kunnen worden met alleen chemotherapie. In **hoofdstuk 5** vergelijken we de resultaten van een controle groep van 111 patiënten met alleen levermetastasen die chemotherapeutische behandeling heeft ondergaan met een groep van 99 patiënten die een leverperfusie heeft ondergaan. De groepen patiënten waren vergelijkbaar met betrekking tot geslacht, performance status, LDH en lokalisatie van primaire tumor. Echter de IHP groep was significant jonger dan de groep patiënten met alleen systemische behandeling. Bovendien was er een verschil in voorbehandeling van beide patiëntgroepen; de helft van de leverperfusie patiënten was voorbehandeld met chemotherapie terwijl in de controlegroep geen enkele patiënt voorbehandeld was. De algemene gemiddelde overleving was 21.7 maanden voor systemische behandeling en 25 maanden voor de leverperfusie, maar er was geen sprake van een statisch significant verschil. Ondanks de methodologische beperkingen van deze studie, kan geconcludeerd worden dat de leverperfusie geen extra overlevingsvoordeel biedt ten op zichten van alleen chemotherapeutische behandeling. Overigens, dient er een gerandomiseerde trial verricht te worden, indien men deze conclusie definitief zou willen bevestigen, maar dit lijkt zowel onethisch als praktisch moeilijk realiseerbaar.

In **hoofdstuk 6** worden de resultaten beschreven van onderzoek naar de combinatie van melfalan met oxaliplatin in 13 verschillende colorectale kanker cellijnen. Er werd gekeken naar celdood bij verschillende concentraties van melfalan tegelijk toegediend met oxaliplatin, oxaliplatin gevolgd door melfalan en melfalan gevolgd door oxaliplatin. De resistentie voor melfalan kwam niet noodzakelijkerwijs overeen met de resistentie voor oxaliplatin. Indien oxaliplatin voor melfalan wordt toegevoegd versterken beide middelen elkaar in 11 van de 13 cellijnen bij 75% celdood. Er blijkt dus een schemaafhankelijke positieve interactie te zijn tussen melfalan en oxaliplatin.

In **hoofdstuk 7** wordt een klinische studie beschreven waarin de resultaten uit hoofdstuk 7 worden toegepast. In het totaal zijn 11 patiënten behandeld met leverperfusie met een oplopende dosis van oxaliplatin gevolgd door een vaste dosis melfalan. Dosisbeperkende toxiciteit werd reeds gevonden bij 150mg oxaliplatin gevolgd door 100mg melfalan.

**Hoofdstuk 8** vat kort de ontwikkelingen samen op het gebied van de geïsoleerde leverperfusie. Geconcludeerd wordt dat gezien het ontbreken van overlevingswinst van IHP ten op zichten van de huidige chemotherapeutische behandeling het maar zeer de vraag is of er een toekomst is voor IHP. Indien IHP een effectieve bijdrage wil leveren aan de behandeling van patiënten met geïsoleerde levermetastasen dan dienen zowel de procedure als de toegepaste middelen verder te worden verbeterd.

.....

# Curriculum Vitae

.....





## Curriculum Vitae

Liselot Valkenburg-van Iersel werd geboren op 25 maart 1978 te Tilburg. In 1996, na het behalen van haar Internationaal Baccalaureaat aan het United World College of the Atlantic te Wales, heeft zij gewerkt als vrijwilliger voor The Adventurers, Nature School in India. In 1999 behaalde zij het propedeutisch examen van de studie Bedrijfskunde aan de Erasmus Universiteit Rotterdam en in dat najaar startte zij met de studie Geneeskunde aan de Universiteit van Leiden. Haar doctoraal examen behaalde zij in 2004 cum laude en in november 2005 behaalde zij haar artsexamen. Hierna startte zij met het promotieonderzoek in het Leids Universitair Medisch Centrum onder begeleiding van Prof. J.W.R. Nortier, Prof. C.J.H. van de Velde, Prof. H. Gelderblom en Dr. P.J.K. Kuppen. De resultaten hiervan staan in dit proefschrift beschreven. In januari 2007 startte zij met de opleiding interne geneeskunde in het Bronovo ziekenhuis te Den Haag om vervolgens in 2009 haar opleiding voort te zetten aan Leids Universitair Medisch Centrum (opleiders dr. J.W. van 't Wout en Prof. Dr. J.W.A. Smit). De auteur van dit proefschrift is in 2007 getrouwd met Olivier Valkenburg en samen hebben zij twee kinderen, Tiemon en Halle.

