



Universiteit
Leiden

The Netherlands

Ultrasonographic features of children presenting with abdominal pain : normal versus abnormal

Wiersma, F.

Citation

Wiersma, F. (2009, September 10). *Ultrasonographic features of children presenting with abdominal pain : normal versus abnormal*. Retrieved from <https://hdl.handle.net/1887/13972>

Version: Corrected Publisher's Version

License: [Licence agreement concerning inclusion of doctoral thesis in the Institutional Repository of the University of Leiden](#)

Downloaded from: <https://hdl.handle.net/1887/13972>

Note: To cite this publication please use the final published version (if applicable).

6

Enlarged mesenteric lymph nodes in children with recurrent abdominal pain: Is there an association with intestinal parasitic infections?

Fraukje Wiersma
Carolien F. M. Gijsbers
Herma C. Holscher

Submitted

Abstract

Introduction:

Mesenteric lymph nodes (MLNs) are depicted frequently in children with recurrent abdominal pain (RAP). One cause of RAP in children is parasitic infections. The purpose of this study was to assess if the presence of enlarged MLNs is associated with parasitic intestinal infection in children with RAP. And to determine the prevalence of ultrasonographic organic abnormalities.

Materials and Methods:

Between 2002 and 2008, we prospectively included 224 children with RAP, who underwent abdominal ultrasound and stool analysis. The presence and size of MLNs were noted. Additional ultrasonographic organic abnormalities were noted.

Results:

MLNs were depicted in all children. MLNs were enlarged in 6 (2.7%) children. Parasitic infection was present in 56 (25.0%) children. There was no statistical difference in the presence of parasitic infections between children with and children without enlarged MLNs ($p = 0.7$). Organic abnormalities were depicted in 11 (4.9%) patients.

Conclusion:

The presence of enlarged MLNs at ultrasound is no predictor of parasitic intestinal infection in children with RAP. In less than 5% of the children organic abnormalities were depicted.

Introduction

Recurrent abdominal pain (RAP) in children is still a diagnostic challenge for many general practitioners and pediatricians. An extensive list of entities is known to cause chronic abdominal pain. Parasitic intestinal infections are one of these. Abdominal ultrasound (US) is one of the diagnostic tools in the work-up of children with RAP. Organic abnormalities are detected by means of US in only a very small fraction of children with RAP [1-3]. The etiology of RAP remains unclear. It is unknown if there is an association between parasitic gastrointestinal infections and the presence of (enlarged) mesenteric lymph nodes in children with RAP.

Therefore, we evaluated the prevalence and the size of mesenteric lymph nodes at US in children with RAP in relation to the frequency of parasitic infections in these children, in order to assess if the presence of enlarged lymph nodes can be associated with intestinal parasitic infection in children with RAP.

Materials and methods

Patients

From February 2002 to March 2008, we prospectively included 224 pediatric patients with RAP, who were referred to the department of radiology by a pediatric gastroenterologist for abdominal US examination. The study included 89 boys and 135 girls with a mean age of 9.0 yrs (age range, 2.8-16.6 yrs). Inclusion criteria were abdominal pain with three or more episodes for more than 3 months and affecting the daily life of the child [4]. Exclusion criteria were incomplete data set (no abdominal US and/or no fecal analysis for parasites) and acute abdominal pain.

Ultrasonography

Abdominal US was performed by a pediatric radiologist using an ATL HDI 5000 scanner with a curved-array (2-5 MHz) and a linear-array transducer (7-12 MHz) (ATL HDI 5000; Philips Medical Systems). All abdominal organs were evaluated, including the presence of mesenteric lymph nodes in the abdomen. Mesenteric lymph nodes were considered to be enlarged when their short-axis was 8 mm or more [5]. Graded compression technique was used to examine the right lower part of the abdomen [6] and organic abnormalities were noted. All findings were recorded on clinical record forum (CRF). Final diagnoses were made during clinical follow-up of the patients. Body mass index (BMI) was calculated in patients with a steatotic liver at US.

Statistical analysis

Fisher's exact test was used to analyse any statistical difference in the presence of parasitic intestinal infections between patients with enlarged and non-enlarged mesenteric lymph nodes. For statistical reasons, patients with lymph nodes measuring 5 – 7 mm and those measuring 8

mm or more were joined together. Odds Ratio was determined as well. A p value less than 0.05 was considered to indicate statistically significant difference.

Results

In all 224 patients small (< 5 mm) mesenteric lymph nodes were depicted at US examination. All mesenteric lymph nodes were smaller than 5 mm in 193 patients (86.1%). Mesenteric lymph nodes between 5 and 7 mm were depicted in 25 children (11.2%). Enlarged (8 mm) mesenteric lymph nodes were seen in six patients (2.7%) (Figures 1 and 2). In one of these six patients there was mild hepatic enlargement depicted, the other five patients had no organic abnormalities at abdominal US, except for their enlarged lymph nodes.

Parasitic infection (*Giardia lamblia*, *Dientamoeba fragilis*, *Blastocystis hominis*) was present in 56 (25.0%) patients. Parasitic infection was present in nine (29.0%) patients of the 31 patients with lymph nodes with a short axis of 5 mm or more. None of the patients with parasitic infection had enlarged lymph nodes. In the 193 children with small mesenteric lymph nodes parasitic infection was present in 47 (24.4%). Parasitic infection was not significantly more present in children with lymph nodes of 5 mm or more than in those with lymph nodes less than 5 mm in the abdomen ($p = 0.7$). Odds Ratio was 0.8 (Confidence interval 0.34 to 1.82%).

Among the 224 children with RAP there were 11 (4.9%) organic abnormalities seen at US (Table 1). The abdominal pain could reasonably be explained by the ultrasonographic findings in six of these patients. In one patient, a non-compressible appendix with a maximal diameter of 6.5 mm was depicted, containing an appendicolith and surrounded by some inflamed mesenteric fat. No enlarged mesenteric lymph nodes were seen. Treatment was expectative. Reexamination after two months showed normalization of the surrounding fat, the appendix was well compressible. In a second patient mild thickening of the ileocecal wall and distal part of the terminal ileum was depicted. Maximum size of the lymph nodes was 5 mm. Clinical diagnosis was ileocectitis, although no bacteria were found at fecal analysis. At follow-up, no signs of Crohn disease were found. In two patients, mild thickening of small bowel wall without the presence of enlarged mesenteric lymph nodes was diagnosed as infectious gastroenteritis. In another two patients there was severe thickening of the terminal ileum with inflammation of the surrounding mesenteric fat, ultrasonographically suspicious of Crohn disease. This was confirmed by histology.

The abdominal pain was judged as unrelated in five patients; hepatic enlargement ($n = 2$), steatotic liver at US in two obese children (Body Mass Index >25) and echogenic particles in the bladder lumen of one patient. This patient had recurrent abdominal pain with idiopathic hematuria in the previous months. Urine analysis showed no infection and the patient had no catheterisation previously.

Table 1 Ultrasonographic results in 224 patients with RAP

Ultrasound diagnosis	Total (n = 224)
Hepatic steatosis ^a	2
Ileocectitis	1
Echogenic particles in bladder ^{a,b}	1
Suspected appendicitis	1
Mild thickening of the small bowel walls	2
Hepatic enlargement ^a	2
Abnormal terminal ileum, Crohn disease ^c	2
Normal findings	213

^aNo relation with RAP, ^bUrine analysis showed no signs of infection, ^cCrohn disease confirmed by histology.

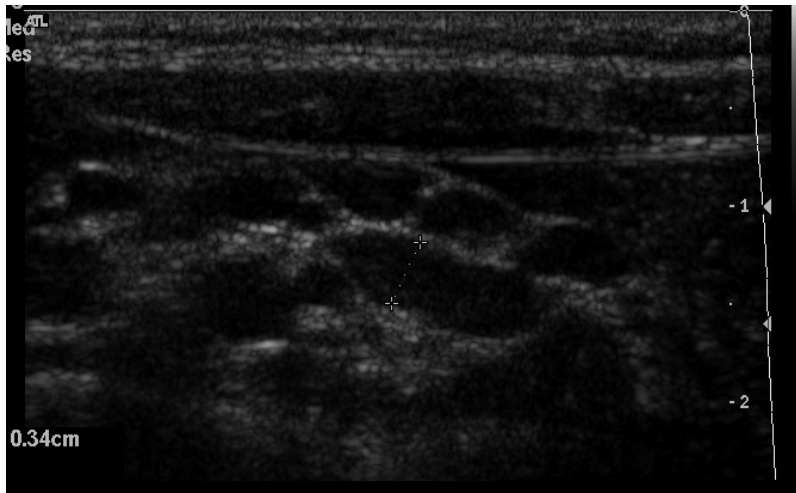


Figure 1.

Small mesenteric lymph nodes in a pediatric patient with chronic abdominal pain.

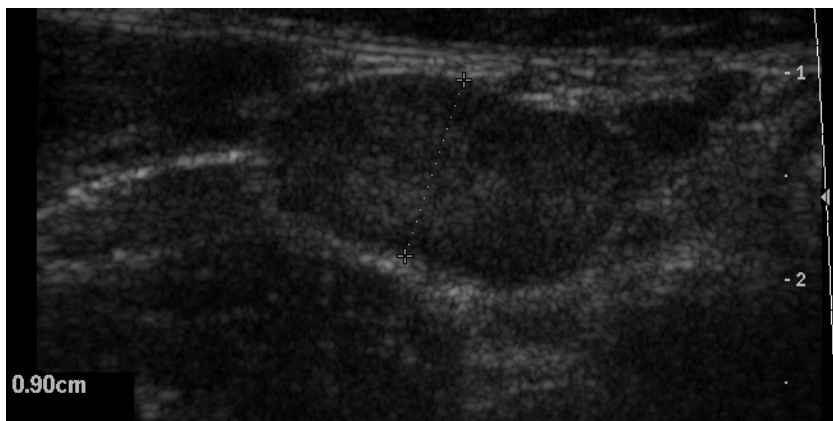


Figure 2.

Enlarged mesenteric lymph node in the right lower quadrant of the abdomen in a pediatric patient with chronic abdominal pain.

Discussion

In the current study mesenteric lymph nodes were depicted at US in all children. In only 6 (2.7%) of 224 patients we depicted enlarged (8 mm or more) mesenteric lymph nodes. In 25 (11.2%) patients the short axis diameter was between 5 and 7 mm.

The percentage of parasitic in this study population was 25.0%. Parasitic infections were not substantially more present in children with lymph nodes of 5 mm or more, than in those children with lymph nodes smaller than 5 mm. There was no relation with parasitic intestinal infection and the presence of enlarged lymph nodes in the abdomen. In only one study it was reported that enlargement of mesenteric lymph nodes was caused by parasitic infections (toxoplasmosis and giardiasis) in 9.3% [7]. However, in our study there was no tendency that the presence of intestinal parasites caused enlargement of the mesenteric lymph nodes.

In only 11 (4.9%) of 224 patients an organic abnormality was seen at US. This low percentage of abnormalities found at abdominal US is comparable to other studies [3, 8].

In six of these 11 patients, the chronic abdominal pain could be explained by the abnormalities found at US. In two patients, US findings were suspicious of Crohn disease. In a third patient, an ultrasonographic inflamed appendix was depicted (normal at follow-up US after two months). Recurrent appendicitis, an accepted phenomenon in children, can be one of the causes of RAP [9, 10]. Mild thickening of the bowel wall was seen by means of US in two children. Studies have shown that inflammatory changes, seen in children with RAP during endoscopy, are suggestive of an intestinal origin of RAP [11, 12]. Mostly, ileocectitis is noted as appendicitis-mimicking syndrome, however the presentation in ileocectitis is often more mild than in acute appendicitis [13]. The pain in ileocectitis can be intermittent, as was probably the case in one of the patients in the current study.

Compared to the only US study [8], which analyzed the presence of mesenteric lymph nodes in children with RAP, our percentage of enlarged (short-axis diameter 8mm or more) lymph nodes in this study is low. Vayner et al. [8] concluded that lymph nodes were found to be enlarged (short axis 4 mm or more) in 61.4% of the patients with RAP. Perhaps small closely clustered lymph nodes seemed to be one or more enlarged lymph node(s) with the lower spatial resolution of US machines in earlier years.

Several US studies have been performed in asymptomatic children to assess the presence of mesenteric lymph nodes. In literature, presence of lymph nodes (larger than 4 mm, short-axis) varied from 4% [14] to 29% [15] or even 64% [16] in asymptomatic children. In symptomatic children (acute or chronic abdominal pain) the percentage of mesenteric lymph nodes with a short-axis of 4 mm or more varied from 14% [14] to 61.4% [8] or even 83.3% [16]. Thus, lymph nodes (enlarged or not) are seen in all children; asymptomatic children, in those with acute abdominal pain or acute gastroenteritis and in those with chronic abdominal pain. There is a tendency that lymph nodes increase more in size in patients with acute abdominal pain than in those without [14, 17]. Therefore, we think that the presence of mesenteric lymph nodes

(enlarged or not, without additional US findings), as the only finding in children with RAP, has no clinical significance. Additionally, there is no association between lymph node enlargement and parasitic infection in children with RAP.

For several years in literature, enlargement of mesenteric lymph nodes was defined as a short axis of 4 mm or 5 mm or more in the short axis [8, 14, 15] or 10 mm or more in the longitudinal axis [17]. Due to technical improvement of US machines, resolution in particular, it is now possible to depict lymph nodes of only a few mm's large. Mesenteric lymph nodes are nowadays depicted much more often with US and computed tomography (CT), even in children without abdominal complaints. A recent CT-study confirmed the experience that 'enlarged' lymph nodes are seen frequently in the absence of clinical symptoms [5]. This study reported that using a threshold of short axis of 5 mm or more for enlarged mesenteric lymph nodes yields an high percentage of false-positive results. According to Karmazyn et al. [5], a short-axis diameter of 8 mm or more would be more appropriate.

Following the results of this latter study, we set our definition of lymph node enlargement at 8 mm (short-axis). However, we found only six patients who met this criterion of lymph node enlargement. Maybe, graded compression by the transducer shortened the short-axis diameter of the lymph nodes. This might not apply to CT examinations. Therefore, we did consider mesenteric lymph nodes with a short-axis of 5 – 7 mm to be enlarged in the statistical analysis. Abdominal US is performed in children with RAP, because it is a relative quick, low-cost and non-invasive tool, which can depict organic causes of recurrent abdominal pain. But more important, it can be helpful in the reassurance of worried parents [2, 8].

In conclusion, mesenteric lymph nodes are no indicators of parasitic gastrointestinal infection. In less than 5% of the children with RAP US depicts an organic cause of RAP.

References

1. Van der Meer SB, Forget PP, Arends JW, Kuijten RH, van Engelshoven JMA. Diagnostic value of ultrasound in children with recurrent abdominal pain. *Pediatr Radiol* 1990; 20:501-503
2. Wewer V, Strandberg A, Pærregaard A, Krasilnikoff PA. Abdominal ultrasonography in the diagnostic work-up in children with recurrent abdominal pain. *Eur J Pediatr* 1997; 156:787-788
3. Yip WCL, Ho TF, Yip YY, Chan KY. Value of abdominal sonography in the assessment of children with abdominal pain. *J Clin Ultrasound* 1998; 26:397-400
4. Apley J, Naish N. Recurrent abdominal pains: a field survey of 1000 school children. *Arch Dis Childhood* 1958; 33:165-170
5. Karmazyn B, Werner EA, Rejaie B, Applegate KE. Mesenteric lymph nodes in children: what is normal? *Pediatr Radiol* 2005; 35:774-777
6. Puylaert JBCM. Acute appendicitis: US evaluation using graded compression. *Radiology* 1986; 158:355-360
7. Sikorska-Wiśniewska G, Liberek A, Góra-Gebka M, Bako W, Marek A, Szlagatys-Sidorkiewicz A, Jankowska A. Mesenteric lymphadenopathy - a valid health problem in children. *Med Wieku Rozwoj* 2006; 10:453-462
8. Vayner N, Coret A, Polliack G, Weiss B, Hertz M. Mesenteric lymphadenopathy in children examined by US for chronic and/or recurrent abdominal pain. *Pediatr Radiol* 2003; 33: 864-867
9. Stroh C, Rauch J, Schramm H. Is there a chronic appendicitis in childhood? Analysis of pediatric surgical patients from 1993-1997. *Zentralbl Chir* 1999; 124:1098-1102
10. Seidman JD, Andersen DK, Ulrich S, Hoy GR, Chun B. Recurrent abdominal pain due to chronic appendiceal disease. *South Med J* 1991; 84:913-916
11. van der Meer SB, Forget PP, Arends JW. Abnormal small bowel permeability and duodenitis in recurrent abdominal pain. *Arch Dis Child* 1990; 65:1311-1314
12. Mavromichalis I, Zaramboukas T, Richman PI, Slavin G. Recurrent abdominal pain of gastrointestinal origin. *Eur J Pediatr* 1992; 151:560-563
13. Puylaert JBCM, Van der Zant EM, Mutsaers JAEM. Infectious ileocectitis caused by *Yersinia*, *Campylobacter* and *Salmonella*: clinical, radiological and US findings. *Eur Radiol* 1997; 7:3-9
14. Sivit CJ, Newman KD, Chandra RS. Visualization of enlarged mesenteric lymph nodes at US examination. *Pediatr Radiol* 1993; 23:471-475
15. Rathaus V, Shapiro M, Grunebaum M, Zissin R. Enlarged mesenteric lymph nodes in asymptomatic children: the value of the finding in various imaging modalities. *Br J Radiol* 2005; 78:30-33
16. Simanovsky N, Hiller N. Importance of sonographic detection of enlarged abdominal lymph nodes in children. *J Ultrasound Med* 2007; 26:581-584
17. Watanabe M, Ishii E, Hirowatari Y, Hayashida Y, Koga T, Akazawa K, Miyazaki S. Evaluation of abdominal lymphadenopathy in children by ultrasonography. *Pediatr Radiol* 1997; 27:860-864