



Universiteit  
Leiden  
The Netherlands

## **Ultrasonographic features of children presenting with abdominal pain : normal versus abnormal**

Wiersma, F.

### **Citation**

Wiersma, F. (2009, September 10). *Ultrasonographic features of children presenting with abdominal pain : normal versus abnormal*. Retrieved from <https://hdl.handle.net/1887/13972>

Version: Corrected Publisher's Version

License: [Licence agreement concerning inclusion of doctoral thesis in the Institutional Repository of the University of Leiden](#)

Downloaded from: <https://hdl.handle.net/1887/13972>

**Note:** To cite this publication please use the final published version (if applicable).

# **Ultrasonographic features in children presenting with abdominal pain: normal versus abnormal**



# **Ultrasonographic features in children presenting with abdominal pain: normal versus abnormal**

**Proefschrift**

ter verkrijging van  
de graad van Doctor aan de Universiteit Leiden,  
op gezag van Rector Magnificus prof. mr. P.F. van der Heijden,  
volgens het besluit van het College voor Promoties  
te verdedigen op donderdag 10 september 2009  
klokke 16.15 uur

door

Fraukje Wiersma  
geboren te 's-Gravenhage  
in 1980

## **Promotiecommissie**

Promotor	Prof. Dr. J.L. Bloem
Co-Promotor	Dr. H.C. Holscher
Commissie-leden	Prof. Dr. H.A. Delemarre-van de Waal Prof. Dr. H.A. Heij (AMC Universiteit van Amsterdam/ VU Medisch Centrum) Dr. J.B.C.M. Puylaert (MC Haaglanden)



ISBN: 978-94-90122-41-6

Layout and printing: Gildeprint Drukkerijen - Enschede, The Netherlands  
Cover illustration by Loes Wiersma-Deijl

## **Ultrasonographic features in children presenting with abdominal pain: normal versus abnormal**

© 2009, F. Wiersma, The Netherlands.

All rights reserved. No parts of this publication may be reproduced or transmitted in any form or by any means, electronic or mechanical, including photocopy, recording, or any information storage and retrieval system, without prior written permission of the author.

Publication of this thesis was financially supported by Guerbet Nederland B.V., MEDRAD B.V., Toshiba Medical Systems Nederland and Leuwico Nederland B.V.

## Contents

Chapter 1	Introduction	7
	General	
	Purpose of the thesis	
	Outline of the thesis	
Chapter 2	US features of the normal appendix and surrounding area in children.	15
Chapter 3	US examination of the appendix in children with suspected appendicitis: The additional value of secondary signs.	27
Chapter 4	Increased echogenicity of renal cortex: a transient feature in acutely ill children.	39
Chapter 5	Ileoileal intussusception in children: ultrasonographic differentiation from ileocolic intussusception.	49
Chapter 6	Enlarged mesenteric lymph nodes in children with recurrent abdominal pain: Is there an association with intestinal parasitic infections?	59
Chapter 7	Summary and conclusions	67
Chapter 8	Samenvatting en conclusies	73
	Curriculum vitae	79



# 1

## **Introduction**





Nowadays, ultrasonography is the most important imaging tool in many diagnostic processes of children with acute or chronic abdominal pain. In addition to the relative low cost, the speed and the non-invasive character, ultrasound has advantages compared to other imaging modalities for several reasons: First of all, ultrasonographic examination allows direct communication with the child and the parents. The ultrasonographic search for answers to the clinical questions can be more specific with the information obtained by the additional interview of the patient or the parents during the ultrasonographic examination.

Secondly, ultrasonography is a dynamic examination with real time imaging, which can visualize peristalsis.

Thirdly, in patients with a normal habitus (as still most pediatric patients in Europe have) and with the use of the graded compression technique the target organ, for example the appendix or kidney, can be examined very closely with a high-frequency transducer.

And fourth, the greatest advantage of ultrasonography is the absence of ionizing radiation. This is especially important in the pediatric patient population with their increased life time risk of developing cancer from ionizing radiation with the worldwide increasing use of computed tomography [1]. Thus further improvements of our knowledge of ultrasonographic (ab)normal findings of abdominal organs, structures or pathologic entities are desirable in order to reduce the use of ionizing modalities in the evaluation of children with acute or recurrent abdominal pain.

## **Vermiform appendix**

The vermiform appendix, an intestinal diverticulum, arises from the posteromedial aspect of the cecum inferior to the ileocecal junction. The position of the appendix is variable; the appendix is most commonly located in the classical position above the iliac vessels in the right lower quadrant of the abdomen, in the paracolic gutter or retroceally. The role of this assumed rudimentary structure is controversial. Some authors believe there is no function for this structure at all, but more recent papers suggest that the appendix is of major importance in the human immune system [2, 3]. Unfortunately, the appendix is also one of the most common causes of acute abdominal pain in children and adults. One has a life time risk of approximately 7% of developing acute appendicitis [4]. Therefore, the appendix has been and is still subject of study. The primary imaging modality of choice in assessing the appendix is ultrasonography. Several studies reported the features of the inflamed appendix in both children and adults. With the ongoing technical improvement of ultrasound machines, and resolution in particular, it is now possible to visualize not only the enlarged, inflamed appendix, but the normal appendix as well. The possibility to distinguish a normal appendix from an inflamed one is very important in the diagnostic process of a child with acute abdominal pain.

## Acute appendicitis

When a normal appendix, in his total length, has been depicted by means of ultrasound, acute appendicitis can be ruled out. On the other hand, ultrasonographic visualization of an enlarged, non-compressible, tender appendix confirms the clinical suspicion of acute appendicitis.

However, there is still a considerable large population in whom the appendix can not be visualized by means of ultrasonography for several reasons. Overlying bowel loops filled with gas, retrocecal position or appendiceal perforation can all hamper visualization of the appendix [5, 6]. Mostly, there are so called secondary signs of acute appendicitis in the right lower quadrant of the abdomen. These include increased echogenicity of the mesentery (indicating inflammation of the mesenteric fat), local rounded fluid collection (indicating the presence of an abscess) or dilation of a small bowel loop (indicating focal peritonitis).

Especially in those settings where the ultrasonographic visualization rate of the appendix is moderate in comparison to specialised hospitals, these secondary signs can be helpful to establish the diagnosis without the need of additional imaging. These secondary signs might be useful in splitting up the group of patients, in whom the appendix could not be visualized, into a diagnosis positive or negative for acute appendicitis.

## Hyperechogenic kidneys

In the early eighties of the twentieth century the first papers concerning ultrasonographic features of the kidney appeared. From then on these organs were studied extensively. The complex internal architecture of the kidneys reveals a variety of internal echogenicities. The central renal sinus is composed of fibrofatty tissue that appears echogenic on ultrasound. The renal vessels and collecting ducts can be detected as hypoechoic structures at ultrasound. The pyramids are hypoechoic, and the echogenicity of the renal cortex is slightly more than that of the pyramids. Furthermore, the echogenicity of the renal cortex should be less than that of the adjacent liver parenchyma in healthy persons. Increased renal echogenicity is associated with the presence of renal disease [7]. Only in neonates increased echogenicity of the renal parenchyma was found to be normal [8]. The echogenicity gradually decreases in this specific age group until it reaches the adult pattern at one or two years of age [9].

Hyperechogenicity of the renal cortex in children (2 years of age and older) is considered abnormal [7]. Despite the fact that this finding has a low sensitivity and specificity, it is still considered to be an indicator of renal disease. However, increased echogenicity of the renal cortex can be seen in acutely ill children without renal disease, as well.

## **Intussusception**

Intussusception was first described by Barbette in 1674 [10]. Since then many studies have been performed on intussusceptions. Intussusception occurs when a proximal part of the intestine (the intussusceptum) telescopes into the adjacent distal intestine (the intussusciens). Most of the intussusceptions diagnosed are ileocolic, however ileoileal intussusceptions occur much more than detected. Because of the transient nature of most small bowel intussusceptions, they are already resolved before imaging takes place.

Furthermore, small bowel intussusceptions are often asymptomatic and detected by incidence as intussusceptions that 'come and go' during abdominal ultrasonography performed for other reasons [11]. But a small percentage of small bowel intussusceptions persist during abdominal ultrasonographic examination.

Treatment of ileocolic and ileoileal intussusceptions differs greatly; the first type of intussusceptions are treated with enema and sometimes surgery while the latter one resolves spontaneously in the majority of cases [12]. Therefore, a good differentiation between these two types is needed.

Clinical presentation of intussusception is not very specific. The classic triad of vomiting, palpable abdominal mass and current jelly, bloody stool is present in less than 50% of the cases and clinical presentation does not differentiate between the two types of intussusception [13]. Therefore abdominal imaging is needed. Sometimes plain abdominal radiography is suggestive of intussusception, but differentiation between the types of intussusception is not possible. Ultrasonography can be of more use and provides the radiologist with additional and more detailed information of the intussusceptions.

## **Recurrent abdominal pain**

Recurrent abdominal pain (RAP), first defined by Apley in 1959 [14], is referred to as three or more episodes of abdominal pain for more than three months and severe enough to interfere with daily activities of the child. RAP is a common problem in school-aged children, affecting 8-15% of the children [15]. Various authors have tried to determine the etiology of RAP. Multiple causes, for example parasitic intestinal infection, are mentioned as possible cause of chronic abdominal pain in children [16]. However, most pediatric patients with RAP do not have an identifiable cause for their pain [14, 16]. An organic cause is only detected in less than 10% of all children with RAP at abdominal ultrasonographic examination [14, 15, 17].

Intestinal parasites are present in 10%-30% of the children with RAP [18-20]. Reactive response of mesenteric lymph nodes to parasitic infection, similar to that seen in bacterial infection, is likely. At abdominal ultrasound examination, mesenteric lymph nodes are depicted frequently in children with RAP [21]. Perhaps, there is an association between depicted (enlarged) mesenteric lymph nodes and the presence of parasitic intestinal infection in children with RAP.

## **Purpose of the thesis**

- a. to determine the frequency of depiction with ultrasonography of the appendix in children without clinical suspicion of acute appendicitis, and to evaluate the ultrasonographic appearance of the normal appendix and surrounding area.
- b. to evaluate the additional value of secondary signs in diagnosing appendicitis by means of ultrasonography in children.
- c. to assess the frequency of the assumed transient increased renal echogenicity in children with acute (abdominal) illness.
- d. to describe and compare the ultrasonographic features of both ileoileal and ileocolic intussusceptions.
- e. to assess if the presence of enlarged lymph nodes is associated with parasitic intestinal infection in children with recurrent abdominal pain. And to evaluate the frequency of ultrasonographic organic abnormalities.

## **Outline of the thesis**

In chapter 2, the ultrasonographic features of the normal appendix and surrounding area, as well as the frequency of depiction of the appendix at ultrasonography are described.

Chapter 3 reports about the additional value of ultrasonographic secondary signs of acute appendicitis in children with suspected appendicitis.

In chapter 4, the increased renal cortex echogenicity as a transient finding in children with acute abdominal illness are described.

Chapter 5 provides an ultrasonographic differentiation of an ileoileal from an ileocolic intussusception in the pediatric population.

Chapter 6 discusses whether the presence of enlarged mesenteric lymph nodes is associated or not associated with parasitic intestinal infection in children with recurrent abdominal pain.

The frequency of depicted organic abnormalities by means of ultrasound is described as well.

Chapter 7 presents the summary and the conclusions.

Chapter 8 presents the Dutch summary and conclusions.

## References

1. Brenner DJ, Elliston CD, Hall EJ, Berdon WE. Estimated risks of radiation-induced fatal cancer from pediatric CT. *AJR Am J Roentgenol* 2001; 176:289-296
2. Bazar KA, Lee PY, Joon Yun A. An “eye” in the gut: the appendix as a sentinel sensory organ of the immune intelligence network. *Med Hypotheses* 2004; 63:752-758
3. Zahid A. The vermiform appendix: not a useless organ. *J Coll Physicians Surg Pak* 2004; 14:256-258
4. Addiss DG, Shaffer N, Fowler BS, et al. The epidemiology of appendicitis and appendectomy in the United States. *Am J Epidemiol* 1992; 132:910-925
5. Puig S, Hörmann M, Rebhandl W, Felder-Puig R, Prokop M, Paya K. US as a primary diagnostic tool in relation to negative appendectomy: six years experience. *Radiology* 2003; 226:101-104
6. Kaiser S, Frenckner B, Jorulf HK. Suspected appendicitis in children: US and CT- a prospective randomized study. *Radiology* 2002; 223:633-638
7. Kraus RA, Gaisie G, Young LW. Increased renal parenchymal echogenicity: causes in pediatric patients. *Radiographics* 1990; 10:1009-1018
8. Haller JO, Berdon WE, Friedman AP. Increased renal cortex echogenicity: A normal finding in neonates and infants. *Radiology* 1982; 142:173-174
9. Hayden CK, Santa-Cruz FR, Amparo EG, Brouhard B, Swischuk LE, Ahrendt DK. Ultrasonographic evaluation of the renal parenchyma in infancy and childhood. *Radiology* 1984; 152:413-417
10. Barbette P. *Oeuvres Chirurgiques at Anatomiques*. Geneva: Francois Miegé, 1674.
11. Munden MM, Bruzzi JF, Coley BD, Munden RF. Sonography of pediatric small-bowel intussusception: differentiating surgical from nonsurgical cases. *AJR Am J Roentgenol* 2007; 188:275-279
12. Kim JH. US features of transient small bowel intussusception in pediatric patients. *Korean J Radiol* 2004; 5:178-184
13. Daneman A, Alton DJ. Intussusception: issues and controversies in related to the diagnosis and reduction. *Radiol Clin N Am* 1996; 34:743-756
14. Apley J, Naish N. Recurrent abdominal pains: a field survey of 1000 school children. *Arch Dis Childhood* 1958; 33:165-170
15. Hayes R. Abdominal pain: general imaging strategies. *Eur Radiol* 2004; 14:123-137
16. Van der Meer SB, Forget PP, Arends JW, Kuijten RH, van Engelshoven JMA. Diagnostic value of ultrasound in children with recurrent abdominal pain. *Pediatr Radiol* 1990; 20:501-503
17. Strouse PJ. Imaging and the child with abdominal pain. *Singapore Med J* 2003; 44: 312-322
18. Balani B, Patwari AK, Bajaj P, Diwan N, Anand VK. Recurrent abdominal pain-A reappraisal. *Indian Pediatrics* 2000; 37:876-881
19. Gupta R, Gupta RK. Recurrent abdominal pain in preschool children. *JK Science* 2004; 6:31-33

20. Stumpel OFB, Tolboom JJM, Warris A, PJA Beckers, Draaisma JMTh. Dientamoeba fragilis, mostly pathogenous in children? Tijdschrift voor Infectieziekten 2006; 1:155-159
21. Vayner N, Coret A, Polliack G, Weiss B, Hertz M. Mesenteric lymphadenopathy in children examined by US for chronic and/or recurrent abdominal pain. Pediatr Radiol 2003; 33: 864-867

# 2

**Ultrasonographic features of the  
normal appendix and surrounding  
area in children.**

Fraukje Wiersma  
Alexandr Šrámek  
Herma C. Holscher

*Published (Radiology 2005)*



## Abstract

### Introduction:

The purpose of this study is to evaluate prospectively the frequency of depiction with ultrasonography (US) of the appendix in children without a clinical suspicion of acute appendicitis and to evaluate the US appearance of the normal appendix.

### Materials and Methods:

Between March 2003 and July 2003, 146 consecutive patients (62 boys and 84 girls; mean age, 7 years; age range, 2-15 years) without clinical suspicion of acute appendicitis were examined with US. Patients with cystic fibrosis and those with acute abdominal pain were excluded from the study. Outer diameters, mural thickness, and color Doppler flow were measured. Appendiceal lumen and surroundings of the appendix were determined. The overall diameter and mural thickness of the appendix were examined for relationship to age, weight, or height of the patient. For the statistical analysis, the Mann-Whitney test, Student *t* test, and linear regression analysis were applied.

### Results:

In 120 (82%) children, the appendix was depicted with US; in 26 (18%) children, this was not possible. In 114 (95%) of the depicted appendices, the position was classical; we observed six (5%) retrocecal appendices. All appendices were compressible. Mean diameter of the appendix was 0.39 cm (range, 0.21-0.64 cm) and the mean mural thickness was 0.18 cm (range, 0.11-0.27 cm). The appendiceal lumen was empty in 74 (62%) children. The others were filled with fecal material, gas, or both. In 75 (51%) of the 146 children, lymph nodes were present in the right lower quadrant of the abdomen. We found no relation between the age, weight, or height of the examined child and the overall diameter or wall of the appendix.

### Conclusion:

The results of this study show that a normal appendix can be depicted with US in 82% of asymptomatic children.

## **Introduction**

In 1986, graded-compression ultrasonography (US) was reported to have been used in the diagnosis of acute appendicitis in children and adults [1]. Because of technical limitations of the US machines used in those days, the only criterion for acute appendicitis was mere depiction of the appendix with US. A normal appendix that was not inflamed, however, would not be depicted. US machines in general and resolution in particular have improved dramatically since then; now, both inflamed and normal appendices can be depicted with US.

To discriminate an inflamed from a normal appendix, several additional criteria for appendicitis were established, such as the outer diameter of the appendix, compressibility of the appendix, shape of the appendix, and absence of gas in the appendiceal lumen [2-4]. These criteria have been investigated in the adult population. Less is known, however, about the US appearance of the normal appendix in the pediatric population without clinical suspicion of acute appendicitis. Thus, the purpose of our study was to evaluate prospectively the frequency of depiction with US of the appendix in children without clinical suspicion of acute appendicitis and to evaluate the US appearance of the normal appendix.

## **Materials and Methods**

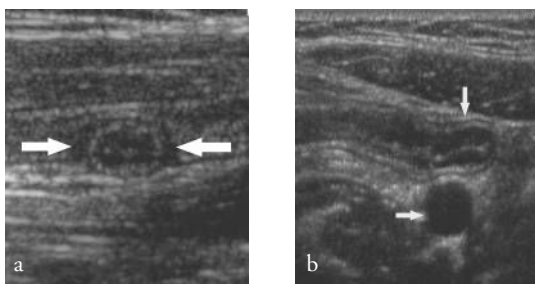
### *Patients*

From March 2003 to July 2003, consecutive patients aged 2-15 years referred to the department of radiology of the Juliana Children's Hospital to undergo US were included in our study. The majority of the patients were referred for examination of the urinary tract or because of chronic abdominal pain. Patients who were referred because of acute abdominal pain were excluded from the study. Children with cystic fibrosis were also excluded from this study because in a recent study, an enlarged appendix was found in children with cystic fibrosis but without clinical signs of acute appendicitis [5]. Patients younger than 2 years were excluded because of difficulty in performing the examination; these patients are very active, and sometimes they are reluctant to undergo an extensive examination. Furthermore, the incidence of acute appendicitis in such a young age group is low. Patients who had undergone previous appendectomy were also excluded. From a total of 482 abdominal US examinations performed at our department, 146 patients with a mean age of 7 years (age range, 2-15 years) were included in our investigation. The mean age for girls was 7.3 years (age range, 2-14 years), and the mean age for boys was 6.5 years (age range, 2-15 years). Additional US evaluation of the right lower quadrant of the abdomen was performed. The patient population consisted of 62 boys and 84 girls. Informed consent was obtained from each patient and/or his or her parents, as per the rules of our country. Institutional review board approval was obtained for our study. For each patient, the weight (measured in kilograms) and height (measured in meters) were recorded in order to calculate the body mass index (BMI).

### *Measurements*

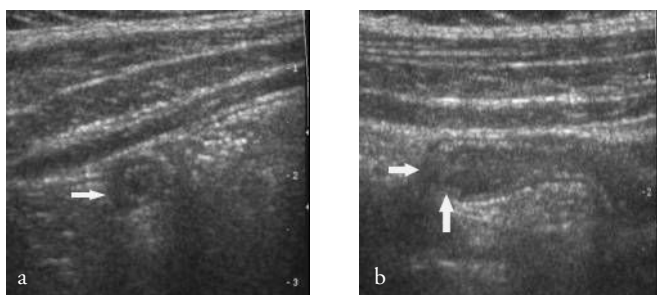
Transverse and longitudinal images of the appendix were obtained by using an HDI 5000 scanner (ATL HDI 5000, Philips Medical Systems) with a 7-12 MHz linear-array transducer. The US examinations were performed by a pediatric radiologist (H.C.H.) or an experienced resident of radiology. The radiologist has 12 years of experience in pediatric abdominal US. The three residents were in the third year of their education, and they each had about 6 months of specific experience.

The maximum time to depict the appendix was set at 15 minutes. If 15 minutes were not enough, the examination was concluded, and the appendix was considered unable to be depicted on the basis of our prior experience. We labeled a structure as a normal appendix when it appeared as a blind-ending lamellated structure without peristalsis (Figure 1). The depiction of the appendix was subdivided into partial or complete (including the tip of the appendix). The position of the appendix was determined (i.e., classical or retrocecal). The classical position above the iliac vessels pointing in the direction of the bladder and the position of the appendix above the colon in the paracolic gutter were both set as classical (Figure 2). Subsequently, the overall diameter with and without compression was measured. For measurement of the diameter with compression, we used the graded compression technique described by Puylaert [1]. To measure diameters, the electronic calipers were placed between the outer borders of the hypoechoic tunica muscularis. The outer diameters were measured in the transverse plane of the appendix. The mural thickness of the appendix was defined as the distance from the hyperechoic luminal interface to the outer hyperechoic line. Subsequently, the content of the appendiceal lumen was determined. The content was classified either as empty or as filled with gas, fecal material, or both (Figure 3). Furthermore, the blood flow in the appendiceal wall was determined by color Doppler US. The criteria for blood flow were classified as follows: no detectable flow, a single vessel within the appendiceal wall, and multiple vessels in the appendiceal wall. Finally, we examined the area surrounding the appendix for the presence of fluid, inflamed fat and/or mesenteric lymph nodes. We labeled tissue as inflamed fat when it was recognized with US as hyperechoic, non-compressible intraabdominal fatty tissue around the appendix [6]. All the measurements and findings were noted immediately after imaging.



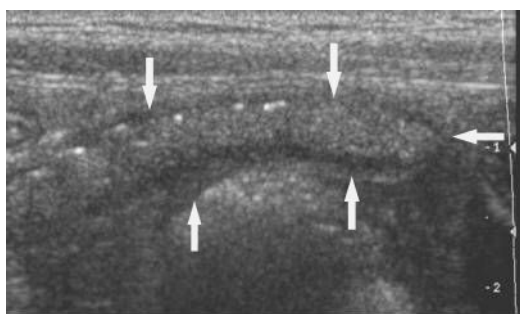
**Figure 1.**

US image of the normal appendix. (a) Round transverse section of the proximal part of a normal appendix (arrows). (b) Longitudinal section of a normal appendix (vertical arrow) in the classical position above the iliac artery (horizontal arrow).



**Figure 2.**

US images of the normal appendix show (a) transverse and (b) longitudinal section of the appendix in the paracolic gutter (arrows).



**Figure 3.**

US image shows the longitudinal section of a normal appendix. The appendiceal cavity is filled with gas and fecal material (arrows).

### *Statistical Analysis*

The distributions of the continuous variables were tested for normality by using the Kolmogorov-Smirnov test. The upper limit of the normal range of the continuous variables was set at the mean plus two times the standard deviation or the 95th percentile for variables that were not normally distributed. The results that concern discrete variables were expressed as frequencies. For the comparison of subgroups, the Student  $t$  test or the Mann-Whitney test for nonnormally distributed subgroups was used. Linear regression analysis was performed by analyzing one variable at a time and was used to examine whether the overall diameter or the thickness of the appendiceal wall is related to age, weight, or height of the examined child. The regression coefficient of the continuous variable indicates the increase or decrease of the diameter or mural thickness of the appendix for every unit increase in the studied continuous variables (e.g., age and weight). A  $p$  value of less than 0.05 was considered to indicate a statistically significant difference (F.W., A.Š.).

## **Results**

### *General Characteristics*

The general characteristics of the study population are shown in Table 1. Of the 482 patients referred to our department for abdominal US, 146 were included in our study. Reasons for exclusions were cystic fibrosis ( $n = 3$ ), age younger than 2 years ( $n = 141$ ) and acute abdominal pain or a medical history of appendectomy ( $n = 192$ ). The mean age for boys and girls were 6.50 and 7.30 years, respectively. There was no significant difference in age between boys and girls ( $p = 0.1$ ). The mean BMI of the study population was 17. The children in whom the appendix was not depicted (BMI of 19) did not have a significantly higher mean BMI than those in whom the appendix was depicted (BMI of 17) (Mann-Whitney test;  $p = 0.4$ ).

**Table 1** Patient Characteristics

Characteristics	Data
Sex	
Girl	84
Boy	62
Age (y)*	7 ± 3.3
Weight (kg)*	28.5 ± 13.2
Length (m)*	1.3 ± 0.2
BMI*	17 ± 3.9
Indication	
Urinary tract problems	66
Chronic abdominal pain	63
Other reasons <sup>a</sup>	17

Note.—Unless otherwise indicated, data are number of patients.

\* Data are mean ± standard deviation

<sup>a</sup> The other reasons consisted of gynecologic disorders, liver disorders, gastric carcinoma, inguinal hernia, umbilical hernia, coccygeal pain, rupture of the spleen and chronic vomiting.

### *Appendiceal Appearance*

In 118 (81%) patients, the appendix was depicted completely (Table 2), whereas in 26 (18%) patients, it was not depicted at all. Of the 26 patients in whom the appendix could not be depicted, eight (31%) had urinary tract problems, 14 (54%) had chronic abdominal pain, and four (15%) had other indications. In two (1%) patients, the appendix was only partial visible. There was a difference in depiction between children with urinary tract problems and chronic abdominal pain (difference, 10%; 95% confidence interval: -3%, 23%). In children with chronic abdominal pain, the appendix was depicted less frequently than in children with urinary tract problems. Results of the measurements of the anteroposterior, left-to-right diameter, and appendiceal mural thickness are summarized in Table 2. The position of the appendix was classical in 114 (95%) patients and retrocecal in six (5%). All of the depicted appendices were compressible (Table 3). The appendiceal lumen was empty in 74 (62%) of the patients. In 14 (12%) of the patients, the appendix was filled with gas, and in 29 (24%), the appendix was filled with fecal material. Two appendices were filled with gas and fecal material. Two appendices exhibited a sparse flow. None of the depicted appendices contained an appendicolith.

**Table 2** Appendiceal diameter and mural thickness

Diameter and thickness		Range (cm)	Mean (cm)	Standard deviation (cm)	Two standard deviations (cm)
Diameter					
	Anteroposterior	0.21-0.64	0.39	0.08	0.55
	Left to right	0.28-0.85	0.56	0.11	0.78
	Anteroposterior with compression*	0.16-0.64	0.38	0.09	0.56
	Left to right with compression	0.24-0.85	0.57	0.11	0.79
Mural thickness*		0.11-0.27	0.18		0.30 <sup>a</sup>

Note.—Results are in the 120 children with depicted appendix out of 146 studied.

\* Nonnormal distribution.

<sup>a</sup> 95% confidence interval: 0.17, 0.19

**Table 3** Appendiceal appearance and environment

Appearance and environment		Frequency	Percentage
Compressibility	Yes	120	100
	No	0	0
Lumen content	Empty	74	62
	Gas	14	12
	Fecal material	29	24
	Gas and fecal material	3	2
Color Doppler flow	None or normal	118	98
	Increased	2	2
Surrounding area*	No fat, fluid, or lymph nodes	68	47
	Inflamed fat	3	2
	Lymph nodes	75	51
Lymph nodes (<1 cm)*	None	71	49
	<5	40	27
	>5	35	24

Note.—Results are in the 120 children with depicted appendix out of 146 studied.

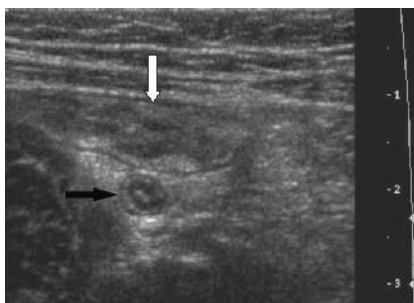
\* Results are in the 146 children studied.

### *Surrounding environment*

In three patients, we detected inflamed fat in the right lower quadrant of the abdomen. One of these patients later proved to have Crohn disease and had a terminal ileitis (Figure 4). In the remaining two patients, the appearance of fat had returned to normal by the time follow-up examinations were performed. The cause of the inflamed fat cannot be clarified. This might possibly be due to a local self-limiting infection.

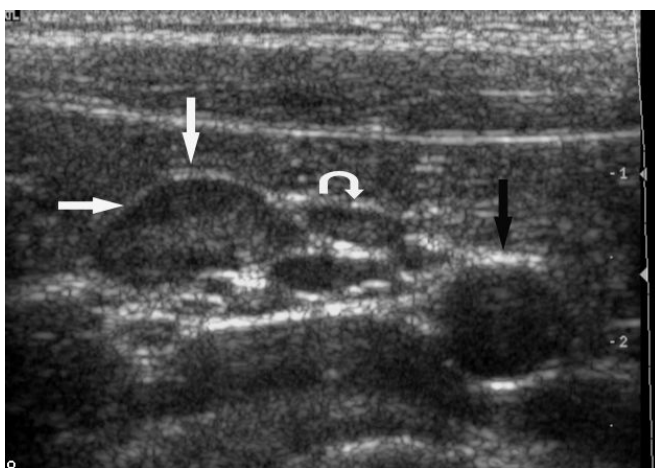In 75 (51%) of the 146 patients, lymph nodes were present in the right lower quadrant of the abdomen (Figure 5). In 35 (24%) of the patients, we observed more than five nodes. There was no significant difference ( $p = 0.1$ ) in presence of lymph nodes between children who were referred for urologic problems and children with chronic abdominal problems.

Regression analysis showed no evidence of a relationship between age, weight, and height of the examined child and the diameter or mural thickness of the appendix. Although there may be a relationship between these variables, the present study with 120 patients had 90% power to depict correlations of more than 0.3. Results of this analysis are shown in Table 4.



**Figure 4.**

US image shows the transverse section of a normal appendix (black arrow) surrounded with inflamed fat. Note the thickened wall of the terminal ileum (white arrow).



**Figure 5.**

US image shows mesenteric lymph nodes in the right lower quadrant of the abdomen. A lymph node (anteroposterior; diameter, 5 mm) (straight arrows) with a slightly echogenic center is noted lateral to the iliac artery (black arrow). A very small lymph node is noted next to this node (curved arrow).



**Table 4** Regression analysis

		Diameter (AP) <sup>a</sup> (cm)	Diameter (LR) <sup>b</sup> (cm)	Mural thickness (cm)
Age	Regression coefficient	0.02	-4.5 <sup>-0.5</sup>	0.02
	95% Confidence Interval	-0.03, 0.07	-0.01, 0.01	0.00, 0.04
Weight	Regression coefficient	-0.004	-0.004	0.003
	95% Confidence Interval	-0.002, 0.001	-0.003, 0.002	0.000, 0.001
Height	Regression coefficient	0.22	0.26	0.25
	95% Confidence Interval	-0.06, 0.11	-0.08, 0.14	-0.01, 0.6

Note.—Results are in the 120 children with depicted appendix out of 146 studied.

<sup>a</sup> AP=anteroposterior, <sup>b</sup> LR=left-right.

## Discussion

In this study, we analyzed how frequently the normal appendix could be depicted in children. We found that 82% of appendices were depicted. Šimonovský [7] found that 49% of appendices were depicted in a group of patients in whom clinical appendicitis was not suspected. In our study, we analyzed only pediatric patients (age range, 2-15 years), while Šimonovský included patients from all age groups (age range, 1-84 years). In a later study, Šimonovský [8] found that 58% of appendices were depicted in asymptomatic patients (age range, 1-82 years).

The difference in size between the diameter with and without compression was small. Our explanation for this finding was that an appendix is usually depicted only when compression is applied during the US examination. With maximal pressure, most appendices could be compressed more.

To our knowledge, only Šimonovský [8] had investigated one characteristic of the appendix in a pediatric population. He analyzed the difference in mean appendiceal mural thickness between children and adults. He found a significant difference in mural thickness between infants (1-6 years of age) and adolescents and adults (16-82 years of age); mural thickness was 0.19 cm in infants and 0.21 cm in adults. In our investigation, we found a mean mural thickness of 0.18 cm. Moreover, we found no relation between the age of the examined child and the mural thickness of the appendix. An explanation for this finding might be the presence of some lymphoid hyperplasia of the appendix in children, independent of age.

Only 13.5% of the depicted appendices contained intraluminal gas. Rettenbacher et al. [2] showed that presence of gas in the appendix is useful in the exclusion of appendicitis, while the absence of gas helps in proving appendicitis. Our results are supported by the results of Rao et al. [9]. They conclude that intraluminal gas is not a diagnostic finding in patients who undergo imaging for clinical suspicion of appendicitis. Air is seen in both inflamed appendices and normal

appendices. Intraluminal air cannot be presumed to indicate that the appendix is normal [9]. We were able to depict the appendix with US in 120 (82%) of 146 patients. In 26 (18%) patients, the appendix was not depicted. An explanation could be the size of the patient. In several studies, obesity is given as a major reason for not depicting the appendix [4, 10]. We too assumed that the appendix was more difficult to depict in obese children than in patients with a normal BMI; however, we found no significant difference in BMI between children in whom the appendix was not depicted and children in whom the appendix was depicted. Our subjects are thinner than average American children. Obesity is a bigger problem in the United States than it is in Europe [11, 12].

Another explanation for not depicting the appendix with US is the position of the appendix. Puig et al. [10] suggested that a retrocecal position of the appendix could be an explanation. In a report by Rettenbacher et al. [4], the retrocecal position is a reason for not depicting the appendix. Ceres et al. [13] found that 28% of the examined children had a retrocecal appendix. In our study, only six (5%) children had a retrocecal appendix. A retrocecal appendix might be a reason for failure to depict the appendix in our investigation.

In eight (12%) of the 66 patients with urinary tract problems and 14 (22%) of the 63 patients with chronic abdominal pain (difference, 10%; 95% confidence interval: -3%, 23%), the appendix could not be observed. This difference in depiction might be due to the fact that in populations with chronic abdominal pain, constipation is a more frequent symptom. Depiction of the appendix is made more difficult by intestines filled with fecal material and air.

A prominent finding in our study was the high percentage of children in which mesenteric lymph nodes smaller than 1 cm were observed in the right lower quadrant of the abdomen. In almost 53% of the patients, we found lymph nodes in this region of the abdomen. In nearly 25% of these patients, we observed more than five lymph nodes. Because there was no difference between children with urinary tract problems and children with chronic abdominal complaints, we may assume that the presence of lymph nodes at US in the abdomen of a child is a nonspecific finding with no clinical importance. In the current literature, little is known about this.

There are some limitations in this study. First, there was a lack of comparison with pediatric patients in whom appendicitis was clinically suspected. We indeed had no pathologic proof that the examined patients actually had a normal appendix. Another limitation was the potential operator experience because of the three residents.

The results of this study show that in 82% of the children without clinical suspicion of appendicitis, the normal appendix can be depicted with US. A mean diameter of 0.39 cm and 0.38 cm with compression and a mural thickness of 0.18 cm might be considered normal in this population. The lumen of the appendices in most of the children was empty, and in more than half of the children lymph nodes were present at US. We did not find any relationship between the overall diameter or mural thickness and the age, weight, or length of the examined child. Furthermore, our results indicate that the presence of mesenteric lymph nodes smaller than 1 cm in the abdomen of a child is a nonspecific finding.

## References

1. Puylaert JBCM. Acute appendicitis: US evaluation using graded compression. *Radiology* 1986; 158:355-360
2. Rettenbacher T, Hollerweger A, Macheiner P, et al. Presence or absence of gas in the appendix: Additional criteria to rule out or confirm acute appendicitis- Evaluation with US. *Radiology* 2000; 214:183-187
3. Rettenbacher T, Hollerweger A, Macheiner P, et al. Outer diameter of the vermiform appendix as a sign of acute appendicitis: Evaluation at US. *Radiology* 2001; 218:757-762
4. Rettenbacher T, Hollerweger A, Macheiner P, et al. Ovoid shape of the vermiform appendix: A criterion to exclude acute appendicitis- Evaluation with US. *Radiology* 2003; 226:95-100
5. Lardenoye SW, Puylaert JBCM, Smit MJ, Holscher HC. Appendix in children with cystic fibrosis: US features. *Radiology* 2004; 232:187-189
6. Puylaert JBCM. Ultrasonography of the acute abdomen: gastrointestinal conditions. *Radiol Clin North Am* 2003; 41:1227-1242
7. Šimonovský V. Sonographic detection of normal and abnormal appendix. *Clin Radiol* 1999; 54:533-539
8. Šimonovský V. Normal appendix: Is there any significant difference in the maximal mural thickness at US between pediatric and adult populations? *Radiology* 2002; 224:333-337
9. Rao PM, Rhea JT, Novelline RA. Appendiceal and peri-appendiceal air at CT: prevalence, appearance and clinical significance. *Clin Radiol* 1997; 52:750-754
10. Puig S, Hörmann M, Rebhandl W, et al. US as a primary diagnostic tool in relation to negative appendectomy: Six years experience. *Radiology* 2003; 226:101-104
11. Vincent SD, Pangrazi RP, Raustrop A, et al. Activity levels and body mass index of children in the United States, Sweden, and Australia. *Med Sci Sports Exerc.* 2003; 35:1367-1373
12. Mathus-Vliegen EM. Overweight. I. Prevalence and trends. *Ned Tijdschr Geneesk* 1998; 142:1982-1987
13. Ceres L, Alonso I, Lopez P, Parra G, Echeverry J. Ultrasound study of acute appendicitis in children with emphasis upon the diagnosis of retrocecal appendicitis. *Pediatric Radiol* 1990; 20:258-261

# 3

**US examination of the appendix in children with suspected appendicitis: The additional value of secondary signs.**

Fraukje Wiersma  
Boudewijn R. Toorenvliet  
Johan L. Bloem  
Jan Hein Allema  
Herma C. Holscher

*Published (European Radiology 2009)*

## Abstract

### Introduction:

This study evaluates the additional value of secondary signs in the diagnosing of appendicitis in children with ultrasound.

### Materials and Methods:

From May 2005 to June 2006, 212 consecutive pediatric patients with suspected appendicitis were examined. Ultrasonographic depiction of the appendix was classified into four groups: 1, normal appendix; 2, appendix not depicted, no secondary signs of appendicitis; 3, appendix not depicted with one of the following secondary signs: hyperechoic mesenteric fat, fluid collection, local dilated small bowel loop; 4, depiction of inflamed appendix.

### Results:

We classified 96 patients in group 1, 41 in group 2, 13 in group 3, and 62 in group 4. Prevalence of appendicitis was 71/212 (34%). Negative predictive values of groups 1 and 2 were 99% and 100%, respectively. Positive predictive values of groups 3 and 4 were 85% and 95%, respectively. In groups 3 and 4, hyperechoic mesenteric fat was seen in 73/75 (97.3%), fluid collections and dilated bowel loops were seen in 12/75 (16.0%) and 5/75 (6.6%), respectively.

### Conclusion:

This study shows that in case of non-visualization of the appendix without secondary signs, appendicitis can be safely ruled out. Furthermore, secondary signs of appendicitis alone are a strong indicator of acute appendicitis.

## Introduction

Acute appendicitis remains a clinical diagnosis [1], but ultrasound (US) proved to be a helpful imaging tool in the evaluation of children with clinically suspected appendicitis [2-5]. Several studies show that additional computed tomography (CT) after a negative or equivocal US can increase the accuracy in the diagnosis of appendicitis [6-8]. In literature, overall, the sensitivity and specificity of CT in diagnosing appendicitis is higher than sensitivity and specificity of US [9]. However, many studies are concerned about the long-term risk of ionizing radiation of CT, especially in the pediatric population [9, 10]. US findings in diagnosing acute appendicitis are historically divided into three groups; negative, equivocal and appendicitis. Evaluation of secondary signs of appendicitis in absence of the depiction of the appendix, might be of use in splitting the equivocal group into a negative or positive US diagnosis of acute appendicitis, using secondary signs as an additional finding. In this study, we applied a new four-part classification of the results of the abdominal US in diagnosing or excluding appendicitis. Therefore, the purpose of this study was to evaluate the additional value of the evaluation of secondary signs of acute appendicitis in children with suspected appendicitis by means of US.

## Materials and Methods

### *Patients*

From May 2005 to June 2006, 212 consecutive children with acute abdominal pain (acute onset, less than 2 days) who were clinically suspected of having appendicitis and referred by the resident of surgery or the pediatric surgeon in our community-based children's teaching hospital to the department of radiology for abdominal US were included in our prospective study. Clinical suspicion of appendicitis included a positive history, acute pain in the right lower quadrant of the abdomen, abdominal guarding and elevated C-reactive protein and leucocyte levels. The study population ( $n = 212$ ) included 129 boys and 83 girls with a mean age of 10 years (age range, 2-15 years). Informed consent was obtained from each patient and/or his or her parents. Institutional review board approval was obtained for our study.

### *Measurements*

The abdomen was examined by using an ATL HDI 5000 US system (ATL HDI 5000; Philips Medical Systems). The entire abdomen was examined with a curved-array 2- to 5-MHz transducers, and the right lower quadrant of the abdomen with a 7- to 12-MHz linear-array transducer. The US examinations were performed by a pediatric radiologist with 14 years of experience in pediatric abdominal US (60% of all the US examinations), a staff radiologist (adult-orientated) during non-working hours with 6-30 years of experience (altogether they performed 22% of all the US examinations) or a resident of radiology in the third or fourth year of their

education with about 6 months of specific experience in pediatric abdominal US (altogether they performed 18% of all the examinations).

All abdominal organs were examined with special attention to the appendix, using the graded compression technique [11]. The examiner classified the results of the abdominal US in four groups: 1, normal appendix; 2, appendix not depicted without secondary signs of appendicitis; 3, appendix not depicted with one of the following secondary signs of appendicitis: hyperechogenic mesenteric fat, fluid collection, local dilated small bowel loop; 4, appendicitis with depiction of an inflamed appendix. The normal appendix was defined as a compressible blind-ending lamellated structure without peristalsis. The diameter of the normal appendix is less than 6 mm [12]. Criteria for an inflamed appendix were a non-compressible appendix with a diameter of 6 mm or more with or without the presence of an appendicolith. Secondary signs of appendicitis were increased echogenicity of the surrounding area of the appendix suggesting inflammation of mesenteric fat, local fluid collection suggesting an appendicular abscess, or local dilatation of the thin bowel without peristalsis indicating focal peritonitis. We labelled tissue as inflamed fat when it was recognized with US as hyperechoic, noncompressible intraabdominal mesenteric tissue.

Alternative diagnoses found in patients of group 1 or 2 during US examination causing abdominal pain were recorded. These were defined as infectious ileocectitis if diffuse thickening of the (sub-) mucosa of the terminal ileum and cecum was depicted, as mesenteric lymphadenitis if enlarged (short axis, 8 mm or more), hypervascular mesenteric lymph nodes (three or more) were depicted [13], as diffuse bowel wall thickening as seen in the clinical diagnosis gastro-enteritis and as colitis or Crohn disease when bowel wall thickening of segments of the colon [13] was depicted. Intussusception was defined as a hyperechoic rim of homogenous thickness and contour with a central hyperechoic core at the axial images, also referred to as the 'doughnut-sign' [14]. US diagnosis was negative of acute appendicitis in groups 1 and 2. In groups 3 and 4, US diagnosis was positive for acute appendicitis. Patients in US classification groups 3 and 4 were treated surgically and patients in groups 1 and 2 were given expectant treatment (i.e. observation or "wait and see") or conservative treatment for the alternative diagnosis found by US. The US results were correlated with the pathological findings of those patients who had been operated on and with one year clinical follow-up for children who were treated non-surgically. Perforation of the appendix noted at surgery and/or pathological examination was recorded. Clinical data were reviewed of all patients (not-operated) which were given re-evaluation appointments at the outpatient clinic after one year for complications (i.e. missed appendicitis) and recurrence of a new episode of abdominal complaints diagnosed as appendicitis within 3 months after the first visit. Surgical data of hospitals in the surrounding area were reviewed to determine whether patients visited another hospital after their primary visit to our hospital.

### Statistical analysis

Data analysis was performed using SPSS (SPSS for Windows, version 12.0, SPSS, Chicago, Ill.). Predictive values, sensitivity and specificity of US examination in diagnosing appendicitis were calculated according to standard epidemiologic methods. To evaluate the distribution of perforated appendices in groups 3 and 4, the Fisher's exact test was used (The subgroups were too small to apply the chi-square test). A *p* value of less than 0.05 was considered to indicate a statistically significant difference.

## Results

Prevalence of appendicitis, proven by surgery and/or pathology, in this study was 34% (71/212). The US diagnosis of acute appendicitis was true positive in 70 patients, false positive in five patients (2/13 patients in group 3 and 3/62 patients in group 4), false negative in one patient and true negative in 136 patients. The sensitivity of this US classification method was 99%; the specificity of the imaging strategy was 97%. Negative predictive values (NPVs) of groups 1 and 2 were 99% and 100%, respectively. Positive predictive values (PPVs) of groups 3 and 4 were 85% and 95%, respectively. Outcome results and predictive values of the classification are summarized in Table 1.

**Table 1** Predictive values of US (*n* = 212)

	Classification US (%)
Sensitivity	99 (70/71)
Specificity	97 (136/141)
PPV	93 (70/75)
NPV	99 (136/137)
Accuracy	97 (206/212)

A normal appendix was seen in 96 (45%) of 212 patients, all of whom were in group 1 (Figure 1). No abnormalities were found in 63 of these patients. The alternative diagnoses in this subgroup were mesenteric lymphadenitis (*n* = 18); infectious ileocectitis (*n* = 11); thickening of the sigmoid wall (*n* = 1, this patient was clinically diagnosed as having Crohn disease); diffuse thickening of the bowel wall as seen in the clinical diagnosis of gastroenteritis (*n* = 1); colitis (*n* = 1); and in one case, a patient had an abnormally located kidney in the pelvis.

Group 2 contained all the patients whose appendix could not be depicted in the absence of secondary signs of appendicitis (*n* = 41, 20%). In 32 patients no abnormalities were found ultrasonographically. The alternative diagnoses were mesenteric lymphadenitis (*n* = 7), infectious ileocectitis (*n* = 1) and ileocolic intussusception (*n* = 1).



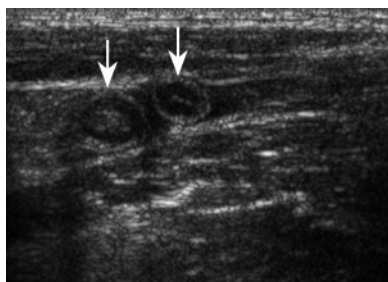
In 13 patients (6%), the appendix was not depicted, but US did indicate secondary signs of appendicitis (Figure 2). These patients were included in group 3 and their US diagnosis was appendicitis. Present secondary signs were hyperechoic mesenteric fat (13/13), fluid collection (7/13) and local dilated small bowel loop (5/13).

Group 4 contained 62 patients (29%) who met the ultrasonographic criteria of acute appendicitis (Figure 3). Secondary signs were depicted in 60 (97%) patients of this group. In one of the two cases without secondary signs, pathology confirmed acute appendicitis of the paracolic appendix. In the other, pathology showed lymphoid hyperplasia of the appendiceal wall. Present secondary signs were hyperechoic mesenteric fat (60/62), fluid collection (5/62) and there was no dilation of small bowel loops.

In total, the appendix (normal or inflamed) was depicted in 158 (75%) of all 212 patients. Hyperechoic mesenteric fat was depicted in 97.2% (69/71) of the patients with proven appendicitis. In patients with acute appendicitis, local fluid collections and dilated small bowel loops were depicted in 16.9% (12/71) and 7.0% (5/71), respectively. US classification and pathological correlation are summarized in Table 2.

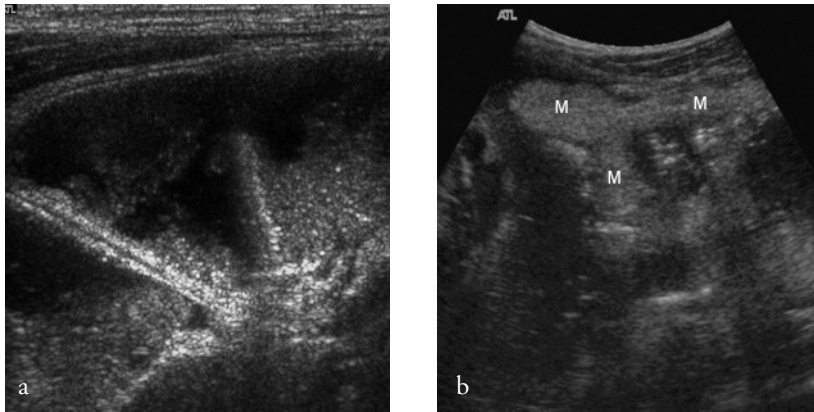
**Table 2** US and pathological results

Pathological result	US findings ( <i>n</i> = 212)			
	Normal appendix ( <i>n</i> = 96)	No depiction of appendix, no secondary signs ( <i>n</i> = 41)	No depiction of appendix with secondary signs ( <i>n</i> = 13)	Appendicitis ( <i>n</i> = 62)
	Group 1	Group 2	Group 3	Group 4
No appendectomy	95	41	0	1
Appendicitis	1	0	11	59
Lymphoid hyperplasia	0	0	0	1
Negative appendectomy	0	0	2	1
	96	41	13	62



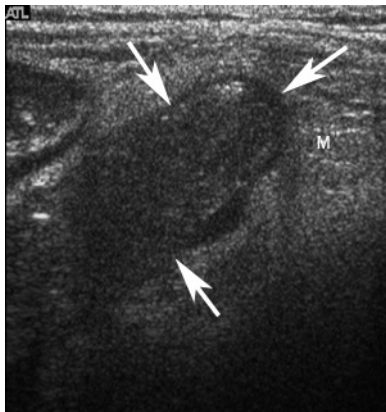
**Figure 1.**

US image showing a transverse section of a normal appendix twice due to its curved position (white arrows). The patient was included in group 1.



**Figure 2.**

US image (a) showing a dilated small bowel loop in a patient with secondary signs, but without the depiction of the appendix itself. (b) Increased echogenicity of the mesenteric fat in the right lower quadrant of the abdomen in the same patient. The patient was included in group 3 (*M* inflamed mesenteric fat).



**Figure 3.**

US image shows longitudinal section of an enlarged appendix (white arrows). Note the surrounding echogenic mesenteric fat. Patient was included in group 4. Pathology proved acute appendicitis (*M* inflamed mesenteric fat).

Seventy-five children went to surgery: one patient of group one (the false negative case) (1/96), all 13 patients of group 3 (13/13), and 61 patients of group 4 (61/62). Pathological results proved appendicitis in 71 of the 75 children, yielding a negative appendectomy rate of 5%. In 22 cases the appendix was perforated; the total perforation rate was 31%. The perforation rate in group 3 was 54% (7/13). In group 4 the appendix was perforated in 24% (15/62) patients. Appendiceal perforation was statistically significant more common in group 3 than in group 4 ( $p = 0.046$ ).

As mentioned above, the diagnosis was false positive for five patients: two patients of group 3, and three patients of group 4. Four normal appendices were removed surgically. One patient (group 4) was treated conservatively despite the protocol, based on mild clinical presentation. US examination revealed that the origin of the appendix was normal, more distally non-compressible and enlarged (outer diameter 8 mm with local loss of wall structure), but the tip was normal. No appendectomy has been performed for this patient since then.

In one patient there was a non-compressible appendix depicted with a maximal outer diameter of 6 mm. Surgery was performed and pathology showed lymphoid hyperplasia of the appendiceal wall. For another patient, US showed a clearly inflamed appendix and the surgical report stated resection of an inflamed appendix, but pathology results indicated a normal appendix with some lipomatosis. The other two surgically removed normal appendices were not depicted by US, but there were secondary signs of appendicitis. During surgery free pus was clearly visible in the abdomen of one patient; culture of the pus showed presence of *Streptococcus pneumoniae*. The other patient had an enlarged, macroscopically necrotic, enlarged lymph node. Pathology showed acute inflammation in the lymph node and a normal appendix.

US diagnosis was false negative in one instance; the first US examination in this case showed a normal appendix and symmetrically thickening of the terminal ileum and cecum. Primary diagnosis was thought to be infectious ileocectitis. Abdominal pain worsened in ten days, however, whereupon US revealed a large abscess above the right psoas muscle suspected to indicate complicated appendicitis. CT was performed to delineate the size of the abscess, and pathology proved appendicitis.

None of the other patients with a normal appendix or with a non-visualized appendix without secondary signs did have appendicitis during re-evaluation at the out-patient clinic or went to another hospital in the surrounding area during the follow-up period of one year.

## Discussion

This paper has demonstrated that when US yields equivocal findings in children with clinically suspected appendicitis, the use of ancilliary signs may help in securing a definitive positive or negative diagnosis. This is especially important as, in this study population, the appendix itself was not depicted, nor were there any secondary signs of acute appendicitis in 20% ( $n = 41$ ) of the 212 patients. As yet, none of these patients developed acute appendicitis. So, when secondary signs are absent (with or without visualization of the normal appendix) at US examination, the diagnosis of acute appendicitis can be ruled out safely. In a CT study of the appendix, Nikolaidis et al. [15] found similar findings; non-visualization of the appendix and absence of secondary signs of acute appendicitis at CT excludes acute appendicitis.

Secondary signs were depicted in 73 of 75 children with the ultrasonographic diagnosis of appendicitis (groups 3 and 4). Pathology proved the diagnosis of acute appendicitis in 70 (96%) of these 73 children with secondary signs. In only 2 patients (of group 4, i.e. patients with an appendix which met the ultrasonographic criteria of acute appendicitis) there were no secondary signs present upon US examination. The appendix of one patient with proven appendicitis was located paracolically; perhaps the development of secondary signs is limited by its location. In the case of the second patient, pathology showed lymphoid hyperplasia of the appendiceal wall and was regarded as one of the false positive cases in this study. The presence of secondary signs (with or without the depiction of the appendix) in the right lower quadrant of the abdomen, therefore, was a strong indicator of appendicitis in this study population.

Fluid collections, solely or in combination with hyperechogenic mesenteric fat or dilated small bowel loops, were suggestive findings of acute appendicitis in this study population. But most frequently, hyperechogenicity of the mesenteric fat in the right lower quadrant of the abdomen was depicted by US as secondary sign of acute appendicitis. In absence of a visualized appendix, this finding strongly suggest appendicitis in this specific patient population. However, Gracey et al. [16] mentioned that a significant proportion of the false-positive scans were based solely on the presence of secondary signs of appendicitis in their study. This was not the case in our study. Appendiceal perforation was noted statistically significant more in group 3 than in group 4. An explanation of this difference, is the fact that perforation of the appendix is one of the causes of nonvisualisation of the appendix [17]. According to Sivit et al. [17] the appendix is visible in only 40-60% of the patients with perforation of the appendix. The secondary signs noted in group 3, like local fluid collections, are suggestive of rupture of the appendix.

In the absence of depiction of the appendix itself, secondary signs can be very helpful in establishing the right diagnosis. However, hyperechoic mesenteric fat can be seen in ileocecal Crohn disease as well. Then, an erroneous diagnosis of acute appendicitis could be made. US differentiation between the two different diagnoses might be possible.

In case of ileocecal Crohn disease, there is always mural thickening of all layers of the non-compressible ileum surrounded by inflamed mesenteric fat and enlarged, hypovascular lymph nodes. Mural thickening of the ileum can be seen secondary to acute appendicitis as well. However, in acute appendicitis wall layers stay intact, while in Crohn disease the layer structure is disturbed locally. In addition to the abnormal ileum there is often prestenotic dilation, abscess or fistula formation in ileocecal Crohn disease [13].

Despite the high sensitivity and specificity of this classification method, a few false-positive and one false-negative US diagnoses were made. This was probably because there are some pitfalls in diagnosing appendicitis with US [13]. First of all, there are several abdominal entities that can mimic the clinical presentation of appendicitis [13]. In two patients, where ultrasonographic findings showed secondary signs of appendicitis and no depiction of the appendix, pathology proved that there was no appendicitis. In one of these patients, an enlarged, acutely inflamed mesenteric lymph node was resected, and the other patient had primary peritonitis [18, 19].

Secondly, there are also entities that are known to give the appendix an abnormal appearance; for example, lymphoid hyperplasia in the appendix (one patient in this study) [3, 13]. Additionally, in the majority of patients with underlying cystic fibrosis, the outer diameter of the appendix is also increased [20, 21]. Another pitfall is the overlooked distal inflamed appendix, when the appendix is normal at its origin, as was the case in the only false-negative US diagnosis in this study [5, 13]. Finally, another possible trap in diagnosing appendicitis with US is the occurrence of spontaneously resolving appendicitis, as was probably the case in one patient in this current study [13, 22] who was not operated on.

Visualization of the appendix can be hampered by abdominal tenderness, its (retrocecal) position, overlying bowel loops filled with gas or obesity of the patient [23-26]. Furthermore, US is operator-dependent. Therefore, there is a difference among different centres in depicting the appendix by means of US [27]. Our institute is quite comparable with non-specialized community-based centres; the staff radiologists and the residents, together, performed almost 40% of the US examinations. Therefore, the high visualization score of the appendix in this study is not only explained by the presence of a dedicated pediatric radiologist.

The results of this ultrasonographic approach in diagnosing or excluding appendicitis in the pediatric population is of high value because of the greater lifetime radiation risk as a consequence of the increasing use of CT for this population [10]. Despite the fact that patient populations are never completely the same, the sensitivity, specificity and negative appendectomy rate found in this study, as mentioned above, are similar to the sensitivity, specificity and negative appendectomy rate of CT in other studies [3, 23, 28-32]. We think, therefore, that the sensitivity, the specificity and the predictive values of our US classification are high enough to avoid unnecessary radiation of CT in children, even in equivocal cases, without increasing the morbidity as a consequence of missed appendicitis.

Besides the radiation risk, CT is also less desirable in children because of their lack of abdominal fat. Fat stranding is difficult to recognize and the appendix is difficult to distinguish from surrounding bowels due to the absence of body fat [33].

Furthermore, CT, in contrast to US, is more expensive, more invasive with the use of oral, intravenous or rectal contrast, needs sedation in some children and brings additional risks with contrast agents, as well [34].

This study was limited by the lack of pathological proof in those patients for whom no appendectomy was performed. We considered an US that did not suggest appendicitis (i.e. groups 1 and 2) as true negative when patients complaints resolved at the re-evaluation at the out-patient clinic or if patients did not go to another hospital during follow up and/or successful response to conservative treatment of an alternative diagnosis.

In conclusion, this study shows that in case of non-visualization of the appendix without secondary signs, appendicitis can be safely ruled out. The presence of secondary signs of appendicitis without depiction of the appendix itself is a strong indicator of acute appendicitis.

## References

1. Klein MD. Clinical approach to a child with abdominal pain who might have appendicitis. *Pediatr Radiol* 2007; 37:11-14
2. Dille A, Wesson D, Munden M et al. The impact of ultrasound examinations on the management of children with suspected appendicitis: a 3-year analysis. *J Pediatr Surg* 2001; 36:303-308
3. Hahn HB, Hoepner FU, Kalle T et al. Sonography of acute appendicitis in children: 7 years experience. *Pediatr Radiol* 1998; 28:147-151
4. Rioux M. Sonographic detection of the normal and abnormal appendix. *AJR Am J Roentgenol* 1992; 158:773-778
5. Sivit CJ, Newman KD, Boenning DA et al. Appendicitis: Usefulness of US in diagnosis in a pediatric population. *Radiology* 1992; 185:549-552
6. Garcia Peña BM, Mandl KD, Kraus SJ et al. Ultrasonography and limited computed tomography in the diagnosis and management of appendicitis on children. *JAMA* 1999; 282:1041-1046
7. Rao PM, Rhea JT, Novelline RA, Mostafavi AA, McCabe CJ. Effect of computed tomography of the appendix on treatment of patients and use of hospital resources. *N Engl J Med* 1998; 338:141-146
8. Wilson EB, Cole JC, Nipper ML, Cooney DR, Smith RW. Computed tomography and ultrasonography in the diagnosis of appendicitis: when are they indicated? *Arch Surg* 2001; 136:670-675
9. Doria AS, Moineddin R, Kellenberger CJ et al. US or CT for diagnosis of appendicitis in children and adults? A meta-analysis. *Radiology* 2006; 241:83-94
10. Brenner DJ, Elliston CD, Hall EJ, Berdon WE. Estimated risks of radiation-induced fatal cancer from pediatric CT. *AJR Am J Roentgenol* 2001; 176:289-296
11. Puylaert JBCM. Acute appendicitis: US evaluation using graded compression. *Radiology* 1986; 158:355-360
12. Wiersma F, Šrámek A, Holscher HC. US features of the normal appendix and surrounding area in children. *Radiology* 2005; 235:1018-1022
13. Puylaert JBCM. Ultrasonography of the acute abdomen: gastrointestinal conditions. *Radiol Clin North Am* 2003; 41:1227-1242
14. Verschelden P, Filiatrault D, Garel L et al. Intussusception in children: reliability of US in diagnosis – A prospective study. *Radiology* 1992; 184:741-744
15. Nikolaidis P, Hwang CM, Miller FH, Papanicolaou N. The nonvisualized appendix: incidence of acute appendicitis when secondary inflammatory changes are absent. *AJR Am J Roentgenol* 2004; 183:889-892
16. Gracey D, McClure MJ. The impact of ultrasound in suspected acute appendicitis. *Clin Radiol* 2007; 62:573-578
17. Sivit CJ, Siegel MJ, Applegate KE, Newman KD. When appendicitis is suspected in children. *Radiographics* 2001; 21:247-262

18. Dann PH, Amodio JB, Rivera R, Fefferman NR. Primary bacterial peritonitis in otherwise healthy children: imaging findings. *Pediatr Radiol* 2005; 35:198-201
19. Kimber CP, Hutson JM. Primary peritonitis in children. *Aust N Z J Surg* 1996; 66:169-170
20. Lardenoye SW, Puylaert JB, Smit MJ, Holscher HC. Appendix in children with cystic fibrosis: US features. *Radiology* 2004; 232:187-189
21. Menten R, Lebecque P, Saint-Martin C, Clapuyt P. Outer diameter of the vermiform appendix: not a valid sonographic criterion for acute appendicitis in patients with cystic fibrosis. *AJR Am J Roentgenol* 2005; 184:1901-1903
22. Migraine S, Atri M, Bret PM, Lough JO, Hinchey JE. Spontaneously resolving acute appendicitis: clinical and sonographic documentation. *Radiology* 1997; 205:55-58
23. Puig S, Hörmann M, Rebhandl W, Felder-Puig R, Prokop M, Paya K. US as a primary diagnostic tool in relation to negative appendectomy: six years experience. *Radiology* 2003; 226:101-104
24. Karakas SP, Guelfguat M, Leonidas JC, Springer S, Singh SP. Acute appendicitis in children: comparison of clinical diagnosis with ultrasound and CT imaging. *Pediatr Radiol* 2000; 30:94-98
25. Hörmann M, Scharitzer M, Stadler A, Pokieser P, Puig S, Helbich T. Ultrasound of the appendix in children: Is the child too obese? *Eur Radiol* 2003; 13:1428-1431
26. Ang, A, Chong NK, Daneman A. Pediatric appendicitis in "real-time": The value of sonography in diagnosis and treatment. *Pediatr Emerg Care* 2001; 17:334-340
27. Peletti AB, Baldiserotto M. Optimizing US examination to detect the normal and abnormal appendix in children. *Pediatr Radiol* 2006; 36:1171-1176
28. Kaiser S, Frenckner B, Jorulf HK. Suspected appendicitis in children: US and CT- a prospective randomized study. *Radiology* 2002; 223:633-638
29. Kosloske AM, Love CL, Rohrer JE, Goldthorn JF, Lacey SR. The diagnosis of appendicitis in children: Outcomes of a strategy based on pediatric surgical evaluation. *Pediatrics* 2004; 113:29-34
30. Applegate KE, Sivit CJ, Salvator AE et al. Effect of cross-sectional imaging on negative appendectomy and perforation rates in children. *Radiology* 2001; 220:103-107
31. Hernandez JA, Swischuk LE, Angel CA, Chung D, Chandler R, Lee S. Imaging of acute appendicitis: US as the primary imaging modality. *Pediatr Radiol* 2005; 35:392-395
32. Poortman P, Lohle PNM, Schoemaker CMC et al. Comparison of CT and sonography in the diagnosis of acute appendicitis: a blinded prospective study. *AJR Am J Roentgenol* 2003; 181:1355-1359
33. Friedland JA, Siegel MJ. CT appearance of acute appendicitis in childhood. *AJR Am J Roentgenol* 1997; 168:439-442
34. Kwok MY, Kim MK, Gorelick MH. Evidence-based approach to the diagnosis of appendicitis in children. *Pediatr Emerg Care* 2004; 20:690-698

# 4

## **Increased echogenicity of renal cortex: a transient feature in acutely ill children.**

Fraukje Wiersma  
Boudewijn R. Toorenvliet  
Madelon Ruige  
Herma C. Holscher

*Published (AJR American Journal of Roentgenology 2008)*



## Abstract

### Introduction:

The purpose of our study was to determine the frequency of hyperechogenicity of renal parenchyma in children with acute abdominal illness and to evaluate the assumed transient feature of this hyperechogenicity.

### Materials and methods:

Between January 2005 and February 2006, 189 consecutive patients (112 boys and 77 girls; mean age, 10 years) presenting with acute abdominal pain were examined with ultrasonography. Patients with a known history of renal disease and those with acute urinary tract infection were excluded from the study. Echogenicity of renal cortex in comparison with adjacent liver was recorded. Renal cortex echogenicity was divided into three groups; group 1, renal cortex echogenicity less than liver parenchyma echogenicity; group 2, renal cortex echogenicity similar to that of liver parenchyma; and group 3, renal cortex echogenicity greater than that of liver parenchyma. Patients with hyperechogenicity were reexamined with ultrasonography after 2 weeks or more. The final ultrasonographic diagnosis and clinical outcome were noted.

### Results:

Renal cortex echogenicity was equal to or greater than that of liver parenchyma in 18% ( $n = 34$ ) of 189 patients. Increased echogenicity of the renal cortex returned to normal in two or more weeks time in all patients. Three patients had no follow-up. Clinical diagnoses were idiopathic acute abdominal pain ( $n = 74$ ), appendicitis ( $n = 83$ ), mesenteric lymphadenitis ( $n = 15$ ), ileocectitis ( $n = 7$ ), gastroenteritis ( $n = 7$ ), Crohn disease ( $n = 1$ ), intussusception ( $n = 1$ ), and pneumonia ( $n = 1$ ). No concurrent renal disease was diagnosed.

### Conclusion:

Increased echogenicity of renal parenchyma in children with acute illness is a transient feature and does not necessarily indicate renal disease.

## **Introduction**

Ultrasonography (US) is an important diagnostic tool in the evaluation of acute abdominal illness in pediatric patients [1, 2]. In most cases, patients do not have an established diagnosis at the time of the ultrasonographic examination. The clinical differential diagnosis is extensive. Evaluation of the kidneys is a routine part of abdominal US. The normal renal cortex in older infants, children, and adults should be less echogenic than the liver parenchyma [3-7]. Only in neonates and infants is increased echogenicity of the renal parenchyma a normal finding [6]. Increased renal echogenicity of infants changes gradually in the adult pattern [7]. Several reports have stated that increased echogenicity of the renal parenchyma is an indicator of renal disease [3, 4]. However, we have encountered increased echogenicity in patients with various abdominal diseases but no concurrent renal disease.

The purpose of this study was to determine the frequency of hyperechogenicity of the renal cortex in children with acute abdominal illness, but no history of renal abnormalities, and to assess the assumed transient feature of this finding.

## **Materials and methods**

### *Patients*

From January 2005 to February 2006, all consecutive pediatric patients with acute abdominal illness (acute abdominal pain of < 8 days, with or without nausea, fever, vomiting, or diarrhea) were referred by the pediatric surgeon or a pediatrician of the emergency department to the department of radiology for an abdominal ultrasonographic examination. None of the patients was resuscitated before the examination. Only one patient was not hemodynamically stable during the examination. No medication was given before the ultrasonographic examination.

All patients with a history of renal disease (including recent acute pyelonephritis or glomerulonephritis, acute fungal infections, stasis nephropathy, hemolytic-uremic syndrome and renal artery or renal vein thrombosis), renal neoplasms, kidney transplantation, solitary kidney or other renal anomalies, multicystic dysplastic kidney disease, urologic surgery or vesicoureteral reflux were excluded from the study ( $n = 4$ ). Patients with concurrent use of diuretics were excluded. All patients younger than two years old were also excluded from the study ( $n = 8$ ) because the renal cortex in normal neonates and infants can be hyperechoic [6, 7]. Of a total of 201 patients with acute abdominal illness who were referred for abdominal US, 189 patients with a mean age of 10 years (age range, 2-15 years) were included in our study. Final diagnoses after US and after additional US or CT if necessary as well as findings of clinical or pathological evaluation were noted. Serum creatinine was tested and urine analysis performed for 17 and 23 patients, respectively, with increased renal cortex echogenicity. After 1 year, records of patients with increased echogenicity of the renal parenchyma records were evaluated for renal disease.

Informed consent was obtained from each patient or his or her parents in conformance with the rules of our country. Institutional review board approval was obtained for our observational study.

### *Imaging observations*

All children underwent comprehensive abdominal US. The images were obtained by using a HDI 5000 scanner (ATL HDI 5000; Philips Medical Systems) with a curved array (2-5 MHz) transducer. The ultrasonographic examinations were performed by a pediatric radiologist, a staff radiologist, or a resident in radiology. The radiologists had 6-14 years of experience in pediatric abdominal US. The residents were in the third or fourth year of their medical training and had about 6 months of specific experience.

Transverse and longitudinal images of the kidneys were obtained. The renal parenchyma was analyzed for diffuse renal cortex echogenicity. Renal cortex echogenicity of the right kidney was compared with echogenicity of the liver parenchyma and classified into three groups: group 1, in which renal cortex echogenicity was less than liver echogenicity; group 2, in which renal cortex echogenicity was equal to liver echogenicity; and group 3, in which renal cortex echogenicity was greater than liver echogenicity. Renal cortex echogenicity was determined by the radiologist during the examination.

Almost all patients with increased renal cortex echogenicity (i.e., patients in groups 2 and 3) were reexamined after 2 weeks. At the time of reexamination, the acute abdominal complaints had resolved (range until reexamination, 1 day-1 year). Three patients were not reexamined.

### *Statistical analysis*

The chi-square test was used for the comparison of subgroups. A  $p$  value of less than 0.05 was considered to indicate a statistical difference.

## **Results**

### *General Characteristics*

Final ultrasonographic diagnoses in the 189 included patients were normal findings ( $n = 74$ ), appendicitis ( $n = 84$ ), mesenteric lymphadenitis ( $n = 15$ ), ileocectitis ( $n = 7$ ), bowel wall thickening (as in colitis, Crohn disease and the clinical diagnosis of infectious gastroenteritis) ( $n = 8$ ) and intussusception ( $n = 1$ ). No concurrent renal disease or urinary tract infection was diagnosed in the study population. Table 1 shows the ultrasonographic diagnosis and the final clinical diagnosis (after the ultrasonographic examination and, if necessary, additional chest radiography, US, or CT, as well as clinical and pathological results). Serum creatinine and urine sediment were normal in all tested patients in groups 2 and 3. None of the patients with increased renal cortex echogenicity had a renal disorder after 1 year of clinical follow-up.

**Table 1** Ultrasonographic and final clinical diagnoses in 189 children who underwent abdominal US

Finding	Ultrasonographic diagnosis	Clinical diagnosis <sup>a</sup>
Normal findings	74	NA
Idiopathic abdominal pain	NA	74
Appendicitis <sup>b</sup>	84	83
Mesenteric adenitis	15	15
Ileocectitis	7	7
Thickening of bowel wall <sup>c</sup>	8	NA
Gastroenteritis	NA	7
Crohn disease	NA	1
Intussusception	1	1
Pneumonia	NA	1
Total	189	189

Note—NA= not applicable

<sup>a</sup> Based on radiological, clinical and pathological results.

<sup>b</sup> One patient with positive US findings of appendicitis underwent negative appendectomy, clinical diagnosis was idiopathic abdominal pain.

<sup>c</sup> As seen in colitis, Crohn disease, and in patients with the clinical diagnosis gastroenteritis.

### *Imaging findings*

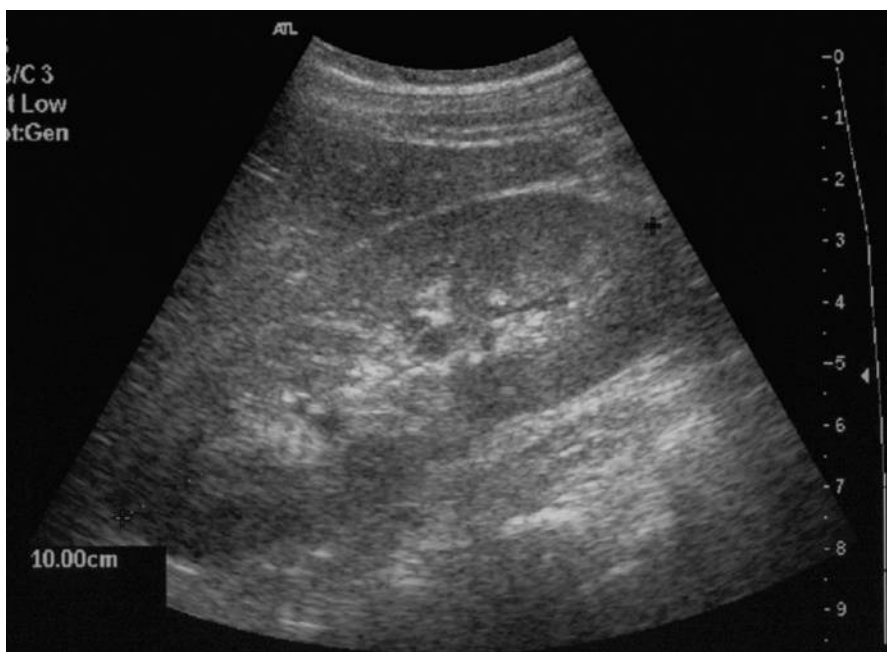
In 34 (18%) of the 189 patients, echogenicity of the renal cortex was increased in comparison with that of the adjacent liver. In 15 (8%) patients, the renal echogenicity was equal to the liver (group 2), and in 19 (10%) patients renal echogenicity was greater than the liver (group 3).

Figures 1 and 2a show the hyperechogenicity of the renal cortex in two patients with appendicitis. Renal cortex echogenicity was increased in patients with appendicitis, gastroenteritis, mesenteric lymphadenitis, ileocectitis, Crohn disease and pneumonia. Table 2 shows the type of recorded renal cortex echogenicity and the final clinical diagnosis of all patients. Clinical diagnosis was based on ultrasonographic, clinical and pathological results.

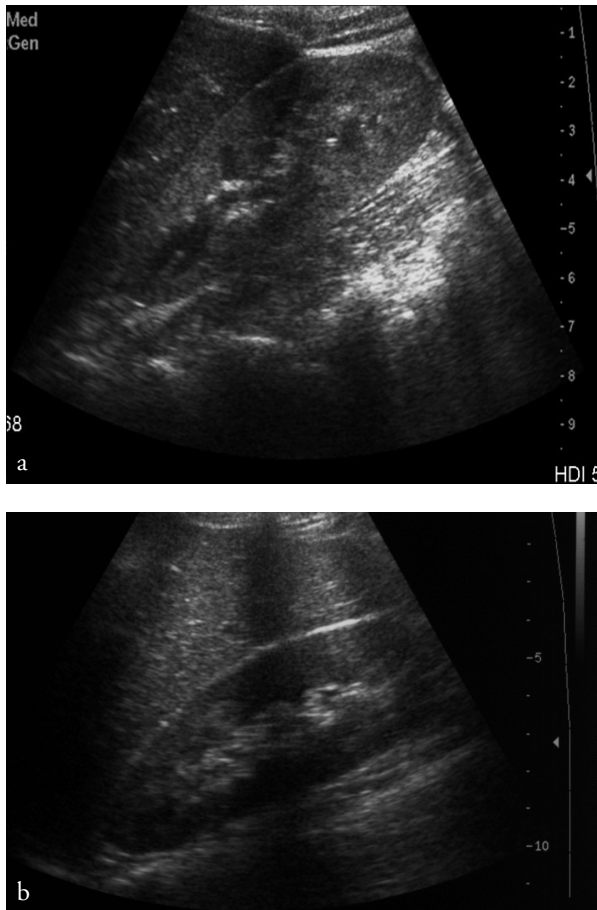
In the subgroup ( $n = 83$ ) with appendicitis, the echogenicity of the renal cortex was equal to liver parenchyma in 12 cases, and in 14 cases the renal cortex echogenicity was more than the liver parenchyma in children with appendicitis. Prevalence of appendicitis in this study population was 44% (83/189). In total, 26 (31%) of the 83 patients with appendicitis had hyperechogenicity of the renal cortex. Three of these 26 patients had a perforated appendix or an appendicular abscess. Renal cortex echogenicity returned to normal in all reexamined patients, as shown in Figure 2b. In one patient, the increased echogenicity returned to normal in 1 day, detected coincidentally during screening for persistent pain after surgical resection of an acutely inflamed appendix.

**Table 2** Renal cortex echogenicity correlated with clinical diagnosis

Clinical diagnoses	Renal cortex echogenicity			Total
	Less than liver	Equal to liver	Greater than liver	
Idiopathic abdominal pain	73	0	1	74
Appendicitis	57	12	14	83
Mesenteric adenitis	14	0	1	15
Ileocectitis	6	1	0	7
Gastroenteritis	4	1	2	7
Crohn disease	0	0	1	1
Intussuception	1	0	0	1
Pneumonia	0	1	0	1
Total	155	15	19	189

**Figure 1.**

10 year-old boy with appendicitis. Ultrasound of right kidney in longitudinal plane shows renal cortex echogenicity equal to that of liver parenchyma.



**Figure 2.** 13 year old girl with appendicitis. Ultrasound (a) shows renal cortex echogenicity is higher than that of liver parenchyma. After appendectomy, follow-up ultrasound (b) shows renal cortex echogenicity has returned to normal.

#### *Statistical analysis*

Renal cortex echogenicity was not significantly ( $p = 0.66$ ) greater in patients with a perforated appendix or a periappendicular abscess than in patients with uncomplicated appendicitis. However, renal cortex echogenicity was statistically significantly ( $p = 0.000033$ ) greater in children with appendicitis (both uncomplicated and complicated) than in children with abdominal pain not diagnosed as appendicitis.

## **Discussion**

In this study of 189 children with acute abdominal pain, 34 (18%) had increased echogenicity of the renal cortex. In contrast to previous studies [4, 8, 9], we did not find this hyperechogenicity to be an indicator of renal disease in this specific patient population. None of these patients had a history of renal disease, nor did they develop a renal disorder after one year follow-up. Because previous articles [3, 5] have shown that in healthy pediatric subjects (neonates and infants excluded) echogenicity of the renal parenchyma is not increased, we believe that hyperechogenicity of renal parenchyma can be a nonspecific finding, a sign of (abdominal) illness varying from appendicitis to ileocectitis, infectious gastroenteritis or otherwise, rather than an indicator of renal disease. Only one study reported that renal echogenicity equal to the liver parenchyma is a nonspecific finding and does not suggest renal disease; that study, however, included only adults [10].

The cause of increased renal cortex echogenicity remains unclear. Manley and O'Neill [11], believed that renal cortex echogenicity can be influenced by the state of diuresis or hydration. Those authors reported that echogenicity is greater in well-hydrated healthy patients. Although we have no proof, we believe, contrary to Manley and O'Neill, that increased renal cortex echogenicity can be explained by a less hydrated state of the patients rather than a more hydrated state. In our study, patients tended to have decreased hydration as a consequence of their acute abdominal illness due to vomiting, diarrhea, and decreased intake. An explanation might be the increase of acoustic interfaces as a consequence of swelling of interstitial renal parenchyma. However, this is not evidence-based. Unfortunately, routine evaluation of blood parameters in the emergency department includes no electrolyte evaluation or serum creatinine, urea or liver function parameters. However, serum creatinine was normal in all tested cases. This finding is in accordance with the findings of Kasap et al. [9], who found no significant difference in blood parameters (serum creatinine) in children with a renal cortex echogenicity equal to that of the liver or in those children with renal cortex echogenicity more than that of the liver parenchyma. A limitation of this study was the subjectivity of the evaluation of the cortical echogenicity. Few reports have stated that densitometric measurement of echogenicity is more reliable than naked eye evaluations [10, 12, 13]. However, in our institute these measurements are not made in regular practice.

Another limitation was that the echogenicity of liver parenchyma was used as an internal standard in determining renal cortex echogenicity. Changes in the liver could influence the ratio of the renal cortex echogenicity in the absence of changes in the structure of the kidney. No studies are available that support a change in liver echotexture in acutely ill children. In a study on hepatic echogenicity, however, Samad et al. [14] detected no statistically significant difference in echogenicity of the liver in children with hepatic dysfunction and children in a control group. We think, therefore, that comparison with liver parenchyma can be used as a reliable method.

According to most studies of echogenicity of the renal parenchyma, right kidney echogenicity is best compared with the echogenicity of the adjacent liver [3, 11, 13, 14].

Care should always been taken, however, in interpreting the estimates of renal cortex echogenicity [15]. According to Vehmas and Kaukiainen [16], the optimum method for evaluating renal cortex echogenicity in daily practice remains to be clarified.

This study was limited by lack of a control group. At the outset, we thought that a control group would be redundant because previous studies had already proven that renal cortex echogenicity in normal healthy patients is less than that of the adjacent liver parenchyma [3, 5].

In conclusion, the results of this study show that increased echogenicity of the renal cortex in children with acute abdominal illness is a nonspecific finding and does not necessarily indicate true renal disease. Increased echogenicity of the renal cortex is a transient phenomenon in this clinical setting. Hyperechogenicity of the renal cortex in children with acute abdominal illness should alert the radiologist to search the abdomen more thoroughly for a cause of the acute abdominal illness, such as appendicitis.



## References

1. Babcock DS. Sonography of the acute abdomen in the pediatric patient. *J Ultrasound Med* 2002; 21:887-899
2. Vasavada P. Ultrasound evaluation of acute abdominal emergencies in infants and children. *Radiol Clin North Am* 2004; 42:445-456
3. Hayden CK, Santa-Cruz FR, Amparo EG, Brouhard B, Swischuk LE, Ahrendt DK. Ultrasonographic evaluation of the renal parenchyma in infancy and childhood. *Radiology* 1984; 152:413-417
4. Krensky AM, Reddish JM, Teele RL. Causes of increased renal echogenicity in pediatric patients. *Pediatrics* 1983; 72:840-846
5. Han BK, Babcock DS. Sonographic measurements and appearance of normal kidneys in children. *AJR Am J Roentgenol* 1985; 145:611-616
6. Haller JO, Berdon WE, Friedman AP. Increased cortical echogenicity: a normal finding in neonates and infants. *Radiology* 1982; 142:173-174
7. Vade A, Lau P, Smick J, Harris V, Ryva J. Sonographic parameters as related to age. *Pediatr Radiol* 1987; 17:212-215
8. Kraus RA, Gaisie G, Young LW. Increased renal parenchymal echogenicity: causes in pediatric patients. *Radiographics* 1990; 10:1009-1018
9. Kasap B, Soylu A, Türkmen M, Kavukcu S. Relationship of increased renal cortical echogenicity with clinical and laboratory findings in pediatric renal disease. *J Clin Ultrasound* 2006; 34:339-342
10. Platt JF, Rubin JM, Bowerman RA, Marn CS. The inability to detect kidney disease on the basis of echogenicity. *AJR Am J Roentgenol* 1988; 151:317-319
11. Manley JA, O'Neill C. How echogenic is echogenic? Quantitative acoustics of the renal cortex. *Am J Kidney Dis* 2001; 37:706-711
12. Tsau YK, Lee PI, Chang LY, Chen CH. Correlation of quantitative renal cortical echogenicity with renal function in pediatric renal diseases. *Zhonghua Min Guo Xiao Er Ke Yi Xue Hui Za Zhi* 1997; 38:276-281
13. Eggert P, Debus F, Kreller-Laugwitz G, Opperman HC. Densiometric measurement of renal echogenicity in infants and naked eye evaluation: a comparison. *Pediatr Radiol* 1991; 21:111-113
14. Samad A, Hayashibara H, Utsunomiya Y, Shiraki K. A study on echogenic changes of the kidney-spleen and liver-spleen contrasts with age in infants and children. *Yonago Acta Med* 1997; 40:31-42
15. Lamont AC, Graebe AC, Pelmore JM, Thompson JR. Ultrasound assessment of renal cortical brightness in infants: Is naked eye evaluation reliable? *Invest Radiol* 1990; 25:250-253
16. Vehmas T, Kaukiainen A. Factors associated with renal cortical echogenicity. *Ultrasound Med Biol* 2006; 32:1151-1155

# 5

## **Ileoileal intussusception in children: Ultrasonographic differentiation from ileocolic intussusception.**

Fraukje Wiersma  
Jan Hein Allema  
Herma C. Holscher

*Published (Pediatric Radiology 2006)*

## Abstract

### Introduction:

The treatment of ileoileal intussusception in children differs from that of ileocolic intussusception. The purpose of this study was to identify ultrasonographic differences between ileoileal intussusception and ileocolic intussusception.

### Materials and methods:

We reviewed the clinical and ultrasonographic findings in 27 cases of intussusception between September 2003 and July 2005. For statistical analysis the Mann-Whitney test was applied.

### Results:

Regarding ileoileal intussusceptions, 11 were documented in ten patients (7 boys, 3 girls; mean age, 3.1 years). Symptoms suggestive of intussusception were present in nine patients. Mean diameter was 1.5 cm (range, 1.1-2.5 cm) and length 2.5 cm (range, 1.5-6.0 cm). The intussusceptions were located in the paraumbilical region ( $n = 6$ ), the right upper quadrant ( $n = 2$ ), the right lower quadrant ( $n = 2$ ) and the left lower quadrant ( $n = 1$ ).

Regarding ileocolic intussusceptions, 16 were documented in 14 patients (13 boys, 1 girl; mean age, 1.9 years). All patients had symptoms suggestive of intussusception. The mean diameter was 3.7 cm (range, 3.0-5.5 cm) and mean length was 8.2 cm (range, 5.0-12.5 cm). All intussusceptions were located in the right side of the abdomen. The difference in diameter and length between ileoileal and ileocolic intussusception was statistically significant ( $p < 0.05$ ).

### Conclusion:

When the diameter is more than 2.5 cm and the length is more than 5.0 cm, the intussusception is most likely to be ileocolic.

## **Introduction**

Intussusception is diagnosed by ultrasonography (US) in a quick, simple and non-invasive way with a high sensitivity (98%-100%) and specificity (88%-100%) [1, 2]. The components of an intussusception produce characteristic appearances on US images. According to the literature, in the majority of pediatric cases the intussusception is located in the ileocolic part of the bowel. However, a small percentage of the intussusceptions are located in the small bowel [1-4].

The treatment of ileocolic and ileoileal intussusceptions is different. The first type of intussusception requires invasive treatment: enema and in some cases surgery. In contrast, in ileoileal intussusception a 'wait-and-see' policy is considered appropriate in patients without an indication for surgery such as peritonitis or ileus. It is therefore necessary to differentiate between ileocolic and ileoileal intussusceptions. There are several reports concerning the typical ultrasonographic appearances of intussusceptions, for example the doughnut or sandwich signs [1, 5]. However, less is known about the ultrasonographic differentiation between ileoileal and ileocolic intussusception using criteria such as mean diameter, length and blood flow of the intussusception. Therefore, we describe and compare the ultrasonographic features of both ileoileal and ileocolic intussusceptions.

## **Materials and methods**

### *Patients*

We retrospectively reviewed the clinical records and US imaging findings of all children in whom an ileocolic or an ileoileal intussusception was diagnosed by US between September 2003 and July 2005. A total of 24 children with 27 intussusceptions were included in our study. We divided the study population into two groups. Group 1 included all patients with an ileoileal intussusception that persisted throughout the ultrasonographic examination. This group comprised seven boys and three girls with a mean age of 3.1 years (range, 8 months to 4 years). Group 2 included 14 patients (13 boys and 1 girl; mean age, 1.9 years; range, 1 month to 7 years) with an ileocolic intussusception. Transient (i.e. existing for only seconds or minutes) ileoileal intussusceptions during sonographic examination were excluded. The durations of the examinations ranged from 15 to 30 min.

We reviewed the age, clinical findings at presentation and medical history for known conditions associated with intussusception. Symptoms suggestive of an intussusception were abdominal pain, palpable mass, vomiting and/or rectal bleeding. Recurrence of the intussusception was documented, as was the need for surgery and the final outcome. Institutional review board approval was obtained for our study.

### *Ultrasonography*

All patients underwent an abdominal US scan. The ultrasonographic examination included routine evaluation of the entire abdomen (liver, gallbladder, pancreas, spleen, kidneys, bladder and bowel). The graded compression technique following the method of Puylaert [6] was used to depict the intussusception. The examinations were carried out by a pediatric radiologist (H.C.H.) and a staff radiologist using a 2-5 curved-array transducer and a 7-12 MHz linear-array transducer (ATL HDI 5000, Philips Medical Systems). The pediatric radiologist had at the start of the study period 12 years of experience in pediatric abdominal US. The staff radiologists had a mean specific experience in pediatric abdominal US of 10 years. We considered intussusceptions to be in the small bowel (a) because of their diameter (ileoileal intussusceptions are smaller than ileocolic intussusceptions), (b) because of their length (ileoileal intussusceptions are shorter than ileocolic intussusceptions) and (c) from the location (ileoileal intussusceptions are located mostly in the paraumbilical region and sometimes in the left upper quadrant, right upper quadrant or lower quadrant).

The location of the intussusception was documented (paraumbilical region, left or right lower or upper quadrant of the abdomen), and the diameter and length of the intussusception were measured. The diameters were measured by placing electronic calipers on the outer border of the outer hypoechoic rim. We determined if there was blood flow in the intussusception with color Doppler US. A lead point, if present, was noted. The presence of mesenteric lymph nodes in the intussusception or in the surrounding area was noted. All children were reexamined with US after several hours (when there were continuing symptoms or signs) or the next day.

### *Statistical analysis*

For the comparison of the diameter and length (both non-normally distributed) of ileoileal and ileocolic intussusceptions the Mann-Whitney test was applied. *P* values of less than 0.05 were considered to indicate statistically significant differences.

## **Results**

### *Clinical symptoms*

In the first group (ileoileal intussusception), nine patients presented with one or more symptoms suggestive of intussusception (abdominal pain  $n = 6$ , palpable abdominal mass  $n = 1$ , vomiting  $n = 3$ , and rectal bleeding  $n = 2$ ). One patient had a predisposing medical history of cystic fibrosis. The final clinical diagnoses included gastrointestinal infection ( $n = 5$ ), cystic fibrosis ( $n = 1$ ), Burkitt lymphoma ( $n = 1$ ) and idiopathic intussusception ( $n = 4$ ). One patient had a recurrent ileoileal intussusception. Only the patient with Burkitt lymphoma required surgery because of the large mass and additional ileus.

In the second group (ileocolic intussusception), all patients had one or more symptoms suggestive of intussusception (abdominal pain  $n = 10$ , palpable abdominal mass  $n = 1$ , vomiting  $n = 4$ , and rectal bleeding  $n = 3$ ). There were no predisposing medical histories. In 12 patients the ileocolic intussusception was successfully reduced with a hydrostatic enema. Two patients had a recurrence of ileocolic intussusception. In total, four patients needed surgery. Two patients were operated on immediately because of absence of blood flow in the intussuscepted bowel wall on color Doppler US. Two other patients required surgery; one because of irreducibility with hydrostatic enema and the other patient because of recurrence of the intussusception shortly after the first intussusception and suspicion of a lead point.

#### *Ultrasonographic features of ileoileal intussusception*

Results of the US features of ileoileal and ileocolic intussusceptions are summarized in Table 1. The ileoileal intussusceptions were located in the paraumbilical region ( $n = 6$ ), the right upper quadrant ( $n = 2$ ), the right lower quadrant ( $n = 2$ ) and the left lower quadrant of the abdomen ( $n = 1$ ). The mean diameter was 1.5 cm (range, 1.1-2.5 cm) and mean length was 2.5 cm (range, 1.5-6.0 cm). The shortest bowel segment involved in the ileoileal intussusceptions measured only 1.5 cm. The longest ileoileal intussusception measured 6 cm. Blood flow in the intussuscepted bowel wall was present in all ileoileal intussusceptions. Classic US imaging signs of ileoileal intussusception are depicted in Figure 1.

Only one lead point was depicted on US: an enlarged mesenteric lymph node with a short axis diameter of 3 cm in the mesentery in close approximation to the intussusception. Pathologic diagnosis of this lymphoid tissue was Burkitt lymphoma. Nine patients had several lymph nodes spread throughout the mesentery with a mean short axis diameter of 7.4 mm (range, 5.0-10.0 mm). Follow-up US in all patients, several hours to one or more days after the first US examination, showed no recurrence of intussusception.

#### *Ultrasonographic features of ileocolic intussusception*

All ileocolic intussusceptions were located in the right side of the abdomen. One ileocolic intussusception extended to the left lower quadrant, this intussusception had the greatest length (12.5 cm). Mean diameter was 3.7 cm (range, 3.0-5.5 cm) and mean length was 8.2 cm (range, 5.0-12.5 cm). The intussuscepted bowel wall showed no blood flow by color Doppler US in two patients. These patients were operated on immediately. During surgery, necrotic bowel wall was found in those patients without blood flow in the intussusception on color Doppler US. Mesenteric lymph nodes with a short axis diameter of  $\leq 5$  mm were seen in the intussusception in 14 patients with an ileocolic intussusception. No other lead points were depicted on US. Figure 2 shows an ileocolic intussusception in the axial and longitudinal planes.

One intussusception was wrongly documented as ileocolic at presentation. On enema there was no ileocolic intussusception and during review of the US images the findings were reinterpreted as an ileoileal intussusception. This had resolved spontaneously by the time of the follow-up

US scan. This misdiagnosis was caused by thickening of the cecal and terminal ileal wall as a consequence of infection with *Campylobacter*. This patient was included in the first group.

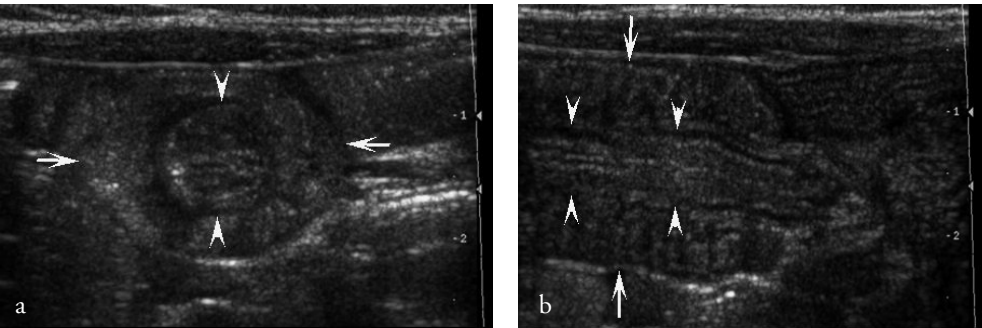
# *Statistical analysis*

The Mann-Whitney test revealed statistically significant differences ( $p < 0.05$ ) in diameter and length between ileoileal and ileocolic intussusceptions.

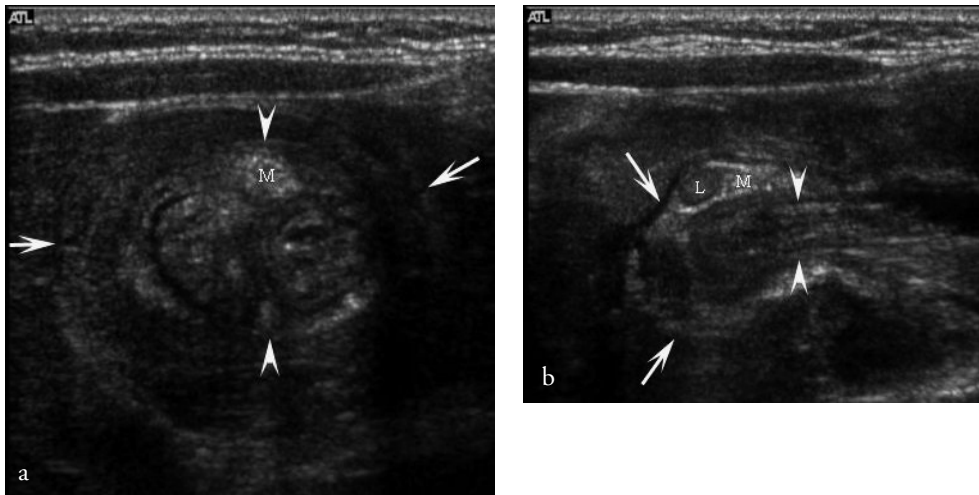
**Table 1** Ultrasonographic appearance of ileoileal and ileocolic intussusception

	Ileoileal intussusception ( $n = 11$ )	Ileocolic intussusception ( $n = 16$ )
Location ( $n$ ):		
para-umbilical	6	0
right lower or upper quadrant	4	16
left lower quadrant	1	1 <sup>a</sup>
Mean diameter (cm)	1.5	3.7
Mean length (cm)	2.5	8.2
Blood flow present ( $n$ )	11	14
Lead point in intussusception ( $n$ )	0	14

<sup>a</sup> One ileocolic intussusception extended to the left lower quadrant; this intussusception had the greatest length (12.5 cm)



**Figure 1.** Ileoileal intussusception. Axial (a) and longitudinal (b) US scans show the typical crescent-in-doughnut sign (a) and hay-fork sign (b).



**Figure 2.**

Ileocolic intussusception. Axial (a) and longitudinal (b) US scans (arrowheads intussuscepted ileum, white arrows colon wall, *L* lymph node within the intussusception, *M* mesenteric fat within the intussusception).

## Discussion

In this study we determined the US imaging features of ileoileal intussusception in children and differentiated these from those of ileocolic intussusception. The mean age at presentation of patients with ileoileal intussusception was 3.1 years and of patients with ileocolic intussusception was 1.9 years. Ileoileal intussusception is more common in neonates and older children (>5 years old). The age at presentation of the patient plays an important role in differentiating type and pathology of the intussusception. Small bowel intussusceptions are more common in older patients and the ileoileal location is a frequent finding in intussusception in adults [3]. The mean age of children with small bowel intussusception ranged from 4 to 11 years in several studies [3, 4, 7, 8]. Idiopathic intussusception is more common in children between 6 months and 2 years of age [1]. The percentage of intussusceptions due to a lead point, other than normal small mesenteric lymph nodes, increases with age, from 5% in children aged 0-11 months to 60% in those aged 5-14 years. Intussusceptions in neonates and older children are more likely to have a lead point. However, the incidence of lead points before 5 years of age is still high because more intussusceptions occur below 5 years of age [9].

The findings concerning clinical symptoms in our study showed that ileoileal and ileocolic intussusceptions could not be differentiated on the basis of clinical presentation. The vast majority of ileoileal and ileocolic intussusceptions presented with nonspecific symptoms such as vomiting and abdominal pain. Even the classic current jelly bloody stool was equally distributed in both groups: 18% ( $n = 2$ ) of the 11 ileoileal and 19% ( $n = 3$ ) of the 16 ileocolic intussusceptions.



Of the patients with ileoileal intussusception, 90% were symptomatic (i.e. they had abdominal complaints). However, Kornecki et al. [8] found that 65% of the small bowel intussusceptions were in asymptomatic children. An explanation for this difference might be that Kornecki et al. included all patients with small bowel intussusceptions, even those that come and go during ultrasonographic examination (transient intussusceptions). The latter intussusceptions were not included in our study. Transient (i.e. existing for only several seconds or minutes) ileoileal intussusceptions are commonly seen in our institution. These intussusceptions are usually recorded as an incidental finding.

The location of the ileoileal intussusception differed from that of the ileocolic intussusceptions. The ileocolic intussusceptions were located in the right upper or lower quadrant of the abdomen; the ileoileal intussusceptions were located mostly in the paraumbilical region. This finding is similar to the findings of Ko et al. [4] and Kornecki et al. [8].

There are fewer reports of the diameter of small bowel intussusceptions determined by US. Ko et al. [4] state that the mean diameter of small bowel intussusceptions is 2.9 cm. However, we found a much smaller mean diameter (1.5 cm) of ileoileal intussusceptions. The widest intussusception in our series had a diameter of 2.5 cm. Our findings agree with the results (mean diameter 1.5 cm) of Kim [10]. Strouse et al. [7] found a mean short-axis diameter of 2.1 cm (range, 1.5-3.0 cm) for small bowel intussusceptions identified on CT. In our study the mean short-axis diameter of the ileocolic intussusceptions was 3.7 cm. There was a statistically significant difference in short-axis diameter between ileoileal and ileocolic intussusception, although the subpopulations were small (group 1,  $n = 11$ ; group 2,  $n = 16$ ).

According to previous studies ileoileal intussusceptions tend to be shorter than ileocolic intussusceptions [7, 8]. In our study the mean lengths of the ileoileal and ileocolic intussusceptions were 2.5 cm (range, 1.5-6.0 cm) and 8.2 cm (range, 5.0-12.5 cm), respectively. Kornecki et al. [8] stated that only a short bowel segment (less than 5 cm) was involved in small bowel intussusceptions. One ileoileal intussusception, however, had a length of 6 cm on US. The ranges of the length of the intussuscepted structures overlapped. Length alone was therefore not enough to specify the type of intussusception. The mean length determined by US is in accordance with that determined by CT (2.2 cm) reported by Strouse et al. [7]. However, when the lengths of the two types of intussusceptions were compared without inclusion of the patient with Burkitt lymphoma, there was no overlap in the ranges of length of the intussuscepted bowel wall. The length of the ileoileal intussusception in the patient with lymphoma was 6.0 cm. The mean length excluding this patient was 2.1 cm (range, 1.5-3.0 cm) compared with 2.5 cm (range, 1.5-6.0 cm).

Small bowel intussusceptions in children are uncommon. They may be idiopathic, but several pathologic entities are predisposing factors. These include infections, Meckel diverticulum, cystic fibrosis and previous abdominal surgery [7]. Only one lead point (Burkitt lymphoma) was depicted during ultrasonographic examination of the ileoileal intussusceptions in our study. Lymphoma is uncommon in children, but is well known as a predisposing factor for intussusception [1]. One

of our patients had cystic fibrosis and five had gastrointestinal infections. In four children the intussusceptions were idiopathic.

Apart from hypertrophied lymphoid tissue, no other anatomical abnormality was identified on ultrasonography or laparotomy in the children with an ileocolic intussusception. These mesenteric lymph nodes were depicted at US in the ileocolic intussusception. The lymphoid tissue probably functioned as a lead point. This differed from the findings in ileoileal intussusception. Although enlarged mesenteric lymph nodes surrounded the ileoileal intussusceptions, no lymph nodes were depicted inside the intussusceptions.

The vast majority (91%) of the ileoileal intussusceptions in our study required no invasive therapy; they had resolved spontaneously on follow-up US. Kornecki et al. [8] have previously described this phenomenon. In their study, small bowel intussusceptions resolved spontaneously or through pressure of the probe or hand of the examiner. We excluded this transient type of intussusception, and only included intussusceptions that persisted throughout the ultrasonographic examination. Despite exclusion of this transient type of small bowel intussusception, our included ileoileal intussusceptions had also resolved without invasive therapy after several hours or by the next day. It is important to correctly recognize the type of intussusception from its ultrasonographic features, such as diameter and length, and location of the involved bowel, in order that unnecessary enema can be avoided. Most ileoileal intussusceptions resolve spontaneously and ileoileal intussusceptions cannot be treated by enema. In our series ileoileal intussusception was wrongly diagnosed in one patient at presentation as ileocolic intussusception. Enema showed no ileocolic intussusception and following review of the ultrasonographic findings the intussuscepted structure was reinterpreted as an ileoileal intussusception. It showed spontaneous resolution on follow-up US.

This study was limited by the lack of pathologic correlation in most ileoileal intussusceptions because of their spontaneous resolving nature making surgery unnecessary. Patients with ileoileal intussusception only require surgery when there is clinical suspicion of peritonitis, ileus or absent blood flow in the intussuscepted bowel wall on US.

In conclusion, ultrasonographic features, especially diameter and length, can differentiate ileoileal intussusception from ileocolic intussusception. The mean diameter of ileoileal intussusception was 1.5 cm and mean length was 2.5 cm, compared with 3.7 cm and 8.2 cm, respectively, for ileocolic intussusception. Ileoileal intussusceptions resolve spontaneously, invasive treatment is unnecessary when no lead point is depicted by US. Clinical and ultrasonographic follow-up are recommended.

## References

1. del-Pozo G, Albillos JC, Tejedor D et al. Intussusception in children: current concepts in diagnosis and enema reduction. *Radiograph* 1999; 19:299-319
2. Verschelden P, Filiatrault D, Garel L, et al. Intussusception in children: reliability of US in diagnosis-a prospective study. *Radiology* 1992; 184:741-744
3. Özgüner İF, Savaş Ç, Baykal B. Ileoileal invagination without obstruction in a four-year-old-boy. *J Pediatr Surg* 2004; 39:1595-1596
4. Ko S-F, Lee T-Y, Ng S-H, et al. Small bowel intussusception in symptomatic patients: experience with 19 surgically proven cases. *World J Surg* 2002; 26:438-443
5. del-Pozo, Abillos JC, Tejedor D. Intussusception: US findings with pathologic correlation- The crescent-in-doughnut sign. *Radiology* 1996; 199:688-692
6. Puylaert JB. Acute appendicitis: US evaluation using graded compression. *Radiology* 1986; 158:355-360
7. Strouse PJ, DiPietro MA, Saez F. Transient small-bowel intussusception in children on CT. *Pediatr Radiol* 2003; 33:316-320
8. Kornecki A, Daneman A, Navarro O, Connolly B, Manson D, Alton DJ. Spontaneous reduction of intussusception: clinical spectrum, management and outcome. *Pediatr Radiol* 2000; 30:58-63
9. Navarro O, Dugougeat F, Kornecki A, Shuckett B, Alton DJ, Daneman A. The impact of imaging in the management of intussusception owing to pathologic lead points in children. A review of 43 cases. *Pediatr Radiol* 2000; 30:594-603
10. Kim JH. US features of transient small bowel intussusception in pediatric patients. *Korean J Radiol* 2004; 5:178-184

# 6

**Enlarged mesenteric lymph nodes in children with recurrent abdominal pain: Is there an association with intestinal parasitic infections?**

Fraukje Wiersma  
Carolien F. M. Gijsbers  
Herma C. Holscher

*Submitted*

## Abstract

### Introduction:

Mesenteric lymph nodes (MLNs) are depicted frequently in children with recurrent abdominal pain (RAP). One cause of RAP in children is parasitic infections. The purpose of this study was to assess if the presence of enlarged MLNs is associated with parasitic intestinal infection in children with RAP. And to determine the prevalence of ultrasonographic organic abnormalities.

### Materials and Methods:

Between 2002 and 2008, we prospectively included 224 children with RAP, who underwent abdominal ultrasound and stool analysis. The presence and size of MLNs were noted. Additional ultrasonographic organic abnormalities were noted.

### Results:

MLNs were depicted in all children. MLNs were enlarged in 6 (2.7%) children. Parasitic infection was present in 56 (25.0%) children. There was no statistical difference in the presence of parasitic infections between children with and children without enlarged MLNs ( $p = 0.7$ ). Organic abnormalities were depicted in 11 (4.9%) patients.

### Conclusion:

The presence of enlarged MLNs at ultrasound is no predictor of parasitic intestinal infection in children with RAP. In less than 5% of the children organic abnormalities were depicted.

## **Introduction**

Recurrent abdominal pain (RAP) in children is still a diagnostic challenge for many general practitioners and pediatricians. An extensive list of entities is known to cause chronic abdominal pain. Parasitic intestinal infections are one of these. Abdominal ultrasound (US) is one of the diagnostic tools in the work-up of children with RAP. Organic abnormalities are detected by means of US in only a very small fraction of children with RAP [1-3]. The etiology of RAP remains unclear. It is unknown if there is an association between parasitic gastrointestinal infections and the presence of (enlarged) mesenteric lymph nodes in children with RAP.

Therefore, we evaluated the prevalence and the size of mesenteric lymph nodes at US in children with RAP in relation to the frequency of parasitic infections in these children, in order to assess if the presence of enlarged lymph nodes can be associated with intestinal parasitic infection in children with RAP.

## **Materials and methods**

### *Patients*

From February 2002 to March 2008, we prospectively included 224 pediatric patients with RAP, who were referred to the department of radiology by a pediatric gastroenterologist for abdominal US examination. The study included 89 boys and 135 girls with a mean age of 9.0 yrs (age range, 2.8-16.6 yrs). Inclusion criteria were abdominal pain with three or more episodes for more than 3 months and affecting the daily life of the child [4]. Exclusion criteria were incomplete data set (no abdominal US and/or no fecal analysis for parasites) and acute abdominal pain.

### *Ultrasonography*

Abdominal US was performed by a pediatric radiologist using an ATL HDI 5000 scanner with a curved-array (2-5 MHz) and a linear-array transducer (7-12 MHz) (ATL HDI 5000; Philips Medical Systems). All abdominal organs were evaluated, including the presence of mesenteric lymph nodes in the abdomen. Mesenteric lymph nodes were considered to be enlarged when their short-axis was 8 mm or more [5]. Graded compression technique was used to examine the right lower part of the abdomen [6] and organic abnormalities were noted. All findings were recorded on clinical record form (CRF). Final diagnoses were made during clinical follow-up of the patients. Body mass index (BMI) was calculated in patients with a steatotic liver at US.

### *Statistical analysis*

Fisher's exact test was used to analyse any statistical difference in the presence of parasitic intestinal infections between patients with enlarged and non-enlarged mesenteric lymph nodes. For statistical reasons, patients with lymph nodes measuring 5 – 7 mm and those measuring 8

mm or more were joined together. Odds Ratio was determined as well. A  $p$  value less than 0.05 was considered to indicate statistically significant difference.

## Results

In all 224 patients small (< 5 mm) mesenteric lymph nodes were depicted at US examination. All mesenteric lymph nodes were smaller than 5 mm in 193 patients (86.1%). Mesenteric lymph nodes between 5 and 7 mm were depicted in 25 children (11.2%). Enlarged (8 mm) mesenteric lymph nodes were seen in six patients (2.7%) (Figures 1 and 2). In one of these six patients there was mild hepatic enlargement depicted, the other five patients had no organic abnormalities at abdominal US, except for their enlarged lymph nodes.

Parasitic infection (*Giardia lamblia*, *Dientamoeba fragilis*, *Blastocystis hominis*) was present in 56 (25.0%) patients. Parasitic infection was present in nine (29.0%) patients of the 31 patients with lymph nodes with a short axis of 5 mm or more. None of the patients with parasitic infection had enlarged lymph nodes. In the 193 children with small mesenteric lymph nodes parasitic infection was present in 47 (24.4%). Parasitic infection was not significantly more present in children with lymph nodes of 5 mm or more than in those with lymph nodes less than 5 mm in the abdomen ( $p = 0.7$ ). Odds Ratio was 0.8 (Confidence interval 0.34 to 1.82%).

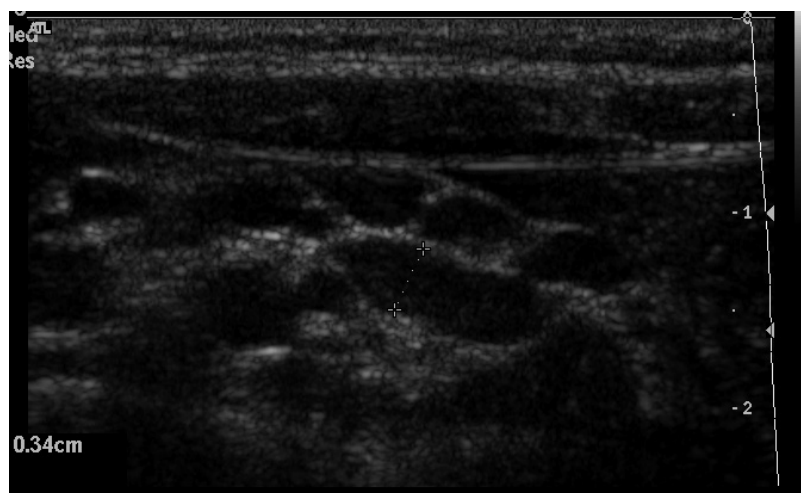
Among the 224 children with RAP there were 11 (4.9%) organic abnormalities seen at US (Table 1). The abdominal pain could reasonably be explained by the ultrasonographic findings in six of these patients. In one patient, a non-compressible appendix with a maximal diameter of 6.5 mm was depicted, containing an appendicolith and surrounded by some inflamed mesenteric fat. No enlarged mesenteric lymph nodes were seen. Treatment was expectative. Reexamination after two months showed normalization of the surrounding fat, the appendix was well compressible. In a second patient mild thickening of the ileocecal wall and distal part of the terminal ileum was depicted. Maximum size of the lymph nodes was 5 mm. Clinical diagnosis was ileocectitis, although no bacteria were found at fecal analysis. At follow-up, no signs of Crohn disease were found. In two patients, mild thickening of small bowel wall without the presence of enlarged mesenteric lymph nodes was diagnosed as infectious gastroenteritis. In another two patients there was severe thickening of the terminal ileum with inflammation of the surrounding mesenteric fat, ultrasonographically suspicious of Crohn disease. This was confirmed by histology.

The abdominal pain was judged as unrelated in five patients; hepatic enlargement ( $n = 2$ ), steatotic liver at US in two obese children (Body Mass Index >25) and echogenic particles in the bladder lumen of one patient. This patient had recurrent abdominal pain with idiopathic hematuria in the previous months. Urine analysis showed no infection and the patient had no catheterisation previously.

**Table 1** Ultrasonographic results in 224 patients with RAP

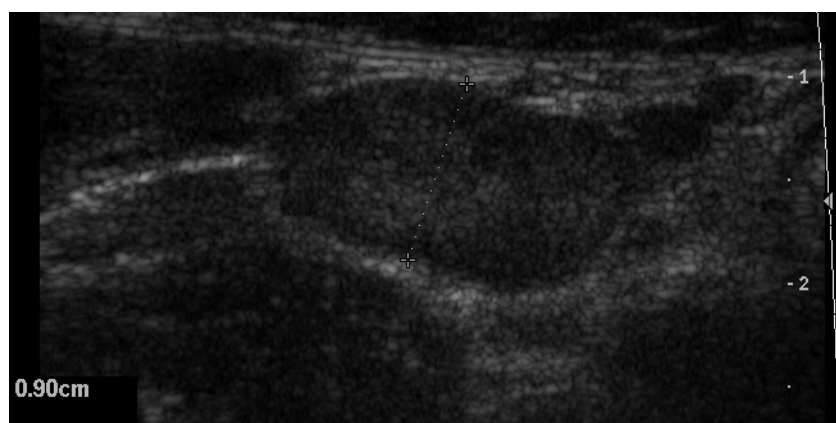
Ultrasound diagnosis	Total (n = 224)
Hepatic steatosis <sup>a</sup>	2
Ileocectitis	1
Echogenic particles in bladder <sup>a,b</sup>	1
Suspected appendicitis	1
Mild thickening of the small bowel walls	2
Hepatic enlargement <sup>a</sup>	2
Abnormal terminal ileum, Crohn disease <sup>c</sup>	2
Normal findings	213

<sup>a</sup>No relation with RAP, <sup>b</sup>Urine analysis showed no signs of infection, <sup>c</sup>Crohn disease confirmed by histology.



**Figure 1.**

Small mesenteric lymph nodes in a pediatric patient with chronic abdominal pain.



**Figure 2.**

Enlarged mesenteric lymph node in the right lower quadrant of the abdomen in a pediatric patient with chronic abdominal pain.



## Discussion

In the current study mesenteric lymph nodes were depicted at US in all children. In only 6 (2.7%) of 224 patients we depicted enlarged (8 mm or more) mesenteric lymph nodes. In 25 (11.2%) patients the short axis diameter was between 5 and 7 mm.

The percentage of parasitic in this study population was 25.0%. Parasitic infections were not substantially more present in children with lymph nodes of 5 mm or more, than in those children with lymph nodes smaller than 5 mm. There was no relation with parasitic intestinal infection and the presence of enlarged lymph nodes in the abdomen. In only one study it was reported that enlargement of mesenteric lymph nodes was caused by parasitic infections (toxoplasmosis and giardiasis) in 9.3% [7]. However, in our study there was no tendency that the presence of intestinal parasites caused enlargement of the mesenteric lymph nodes.

In only 11 (4.9%) of 224 patients an organic abnormality was seen at US. This low percentage of abnormalities found at abdominal US is comparable to other studies [3, 8].

In six of these 11 patients, the chronic abdominal pain could be explained by the abnormalities found at US. In two patients, US findings were suspicious of Crohn disease. In a third patient, an ultrasonographic inflamed appendix was depicted (normal at follow-up US after two months). Recurrent appendicitis, an accepted phenomenon in children, can be one of the causes of RAP [9, 10]. Mild thickening of the bowel wall was seen by means of US in two children. Studies have shown that inflammatory changes, seen in children with RAP during endoscopy, are suggestive of an intestinal origin of RAP [11, 12]. Mostly, ileocectitis is noted as appendicitis-mimicking syndrome, however the presentation in ileocectitis is often more mild than in acute appendicitis [13]. The pain in ileocectitis can be intermittent, as was probably the case in one of the patients in the current study.

Compared to the only US study [8], which analyzed the presence of mesenteric lymph nodes in children with RAP, our percentage of enlarged (short-axis diameter 8mm or more) lymph nodes in this study is low. Vayner et al. [8] concluded that lymph nodes were found to be enlarged (short axis 4 mm or more) in 61.4% of the patients with RAP. Perhaps small closely clustered lymph nodes seemed to be one or more enlarged lymph node(s) with the lower spatial resolution of US machines in earlier years.

Several US studies have been performed in asymptomatic children to assess the presence of mesenteric lymph nodes. In literature, presence of lymph nodes (larger than 4 mm, short-axis) varied from 4% [14] to 29% [15] or even 64% [16] in asymptomatic children. In symptomatic children (acute or chronic abdominal pain) the percentage of mesenteric lymph nodes with a short-axis of 4 mm or more varied from 14% [14] to 61.4% [8] or even 83.3% [16]. Thus, lymph nodes (enlarged or not) are seen in all children; asymptomatic children, in those with acute abdominal pain or acute gastroenteritis and in those with chronic abdominal pain. There is a tendency that lymph nodes increase more in size in patients with acute abdominal pain than in those without [14, 17]. Therefore, we think that the presence of mesenteric lymph nodes

(enlarged or not, without additional US findings), as the only finding in children with RAP, has no clinical significance. Additionally, there is no association between lymph node enlargement and parasitic infection in children with RAP.

For several years in literature, enlargement of mesenteric lymph nodes was defined as a short axis of 4 mm or 5 mm or more in the short axis [8, 14, 15] or 10 mm or more in the longitudinal axis [17]. Due to technical improvement of US machines, resolution in particular, it is now possible to depict lymph nodes of only a few mm's large. Mesenteric lymph nodes are nowadays depicted much more often with US and computed tomography (CT), even in children without abdominal complaints. A recent CT-study confirmed the experience that 'enlarged' lymph nodes are seen frequently in the absence of clinical symptoms [5]. This study reported that using a threshold of short axis of 5 mm or more for enlarged mesenteric lymph nodes yields an high percentage of false-positive results. According to Karmazyn et al. [5], a short-axis diameter of 8 mm or more would be more appropriate.

Following the results of this latter study, we set our definition of lymph node enlargement at 8 mm (short-axis). However, we found only six patients who met this criterion of lymph node enlargement. Maybe, graded compression by the transducer shortened the short-axis diameter of the lymph nodes. This might not apply to CT examinations. Therefore, we did consider mesenteric lymph nodes with a short-axis of 5 – 7 mm to be enlarged in the statistical analysis. Abdominal US is performed in children with RAP, because it is a relative quick, low-cost and non-invasive tool, which can depict organic causes of recurrent abdominal pain. But more important, it can be helpful in the reassurance of worried parents [2, 8].

In conclusion, mesenteric lymph nodes are no indicators of parasitic gastrointestinal infection. In less than 5% of the children with RAP US depicts an organic cause of RAP.

## References

1. Van der Meer SB, Forget PP, Arends JW, Kuijten RH, van Engelshoven JMA. Diagnostic value of ultrasound in children with recurrent abdominal pain. *Pediatr Radiol* 1990; 20:501-503
2. Wewer V, Strandberg A, Pærregaard A, Krasilnikoff PA. Abdominal ultrasonography in the diagnostic work-up in children with recurrent abdominal pain. *Eur J Pediatr* 1997; 156:787-788
3. Yip WCL, Ho TF, Yip YY, Chan KY. Value of abdominal sonography in the assessment of children with abdominal pain. *J Clin Ultrasound* 1998; 26:397-400
4. Apley J, Naish N. Recurrent abdominal pains: a field survey of 1000 school children. *Arch Dis Childhood* 1958; 33:165-170
5. Karmazyn B, Werner EA, Rejaie B, Applegate KE. Mesenteric lymph nodes in children: what is normal? *Pediatr Radiol* 2005; 35:774-777
6. Puylaert JBCM. Acute appendicitis: US evaluation using graded compression. *Radiology* 1986; 158:355-360
7. Sikorska-Wiśniewska G, Liberek A, Góra-Gebka M, Bako W, Marek A, Szlagatys-Sidorkiewicz A, Jankowska A. Mesenteric lymphadenopathy - a valid health problem in children. *Med Wieku Rozwoj* 2006; 10:453-462
8. Vayner N, Coret A, Polliack G, Weiss B, Hertz M. Mesenteric lymphadenopathy in children examined by US for chronic and/or recurrent abdominal pain. *Pediatr Radiol* 2003; 33: 864-867
9. Stroh C, Rauch J, Schramm H. Is there a chronic appendicitis in childhood? Analysis of pediatric surgical patients from 1993-1997. *Zentralbl Chir* 1999; 124:1098-1102
10. Seidman JD, Andersen DK, Ulrich S, Hoy GR, Chun B. Recurrent abdominal pain due to chronic appendiceal disease. *South Med J* 1991; 84:913-916
11. van der Meer SB, Forget PP, Arends JW. Abnormal small bowel permeability and duodenitis in recurrent abdominal pain. *Arch Dis Child* 1990; 65:1311-1314
12. Mavromichalis I, Zaramboukas T, Richman PI, Slavin G. Recurrent abdominal pain of gastrointestinal origin. *Eur J Pediatr* 1992; 151:560-563
13. Puylaert JBCM, Van der Zant EM, Mutsaers JAEM. Infectious ileoceitis caused by *Yersinia*, *Campylobacter* and *Salmonella*: clinical, radiological and US findings. *Eur Radiol* 1997; 7:3-9
14. Sivit CJ, Newman KD, Chandra RS. Visualization of enlarged mesenteric lymph nodes at US examination. *Pediatr Radiol* 1993; 23:471-475
15. Rathaus V, Shapiro M, Grunebaum M, Zissin R. Enlarged mesenteric lymph nodes in asymptomatic children: the value of the finding in various imaging modalities. *Br J Radiol* 2005; 78:30-33
16. Simanovsky N, Hiller N. Importance of sonographic detection of enlarged abdominal lymph nodes in children. *J Ultrasound Med* 2007; 26:581-584
17. Watanabe M, Ishii E, Hirowatari Y, Hayashida Y, Koga T, Akazawa K, Miyazaki S. Evaluation of abdominal lymphadenopathy in children by ultrasonography. *Pediatr Radiol* 1997; 27:860-864

# 7

## **Summary and conclusions**



Chapter 1 provides a general introduction to this thesis focused on the use of ultrasound (US) in children with abdominal problems. The literature on the US appearance of the normal and diseased appendix in children is summarized. Subsequently, the literature on issues that are often a problem in assessing children with abdominal problems, in particular echogenicity of kidneys, intussusception, and enlarged lymph nodes, is also summarized. In relation to this, the goals of this thesis are to determine the ultrasonographic features of the normal appendix in asymptomatic children; to evaluate a new ultrasonographic classification of acute appendicitis with emphasis on secondary signs; to determine the frequency of increased echogenicity of the renal cortex in acutely ill children and to evaluate the assumed transient nature of this increased echogenicity; to evaluate the possibility to differentiate, based on clinical and/or ultrasonographic findings, between ileoileal and ileocolic intussusceptions in children; and to evaluate the significance of the presence of mesenteric lymph nodes in children with chronic abdominal pain and their possible association with intestinal parasitic infection.

In chapter 2, the US appearance of the appendix in children without clinical suspicion of acute appendicitis was prospectively evaluated. Between March 2003 and July 2003, 146 consecutive patients (62 boys and 84 girls; mean age, 7 years; age range, 2-15 years) without clinical suspicion of acute appendicitis were examined with US. Patients with cystic fibrosis and those with acute abdominal pain were excluded from the study. Outer diameters, mural thickness, and color Doppler flow were measured. Appendiceal lumen and surroundings of the appendix were determined. The overall diameter and mural thickness of the appendix were examined for relationship to age, weight, or height of the patient. For statistical analysis, the Mann-Whitney test, Student *t* test, and linear regression analysis were applied. In 120 (82%) children, the appendix was depicted with US; in 26 (18%) children, this was not possible. In 114 (95%) of the depicted appendices, the position was classical; we observed six (5%) retrocecal appendices. All appendices were compressible. Mean diameter of the appendix was 0.39 cm (range, 0.21-0.64 cm), and the mean mural thickness was 0.18 cm (range, 0.11-0.27 cm). The appendiceal lumen was empty in 74 (62%) children. The others were filled with fecal material, gas, or both. In 75 (51%) of the 146 children, lymph nodes were present in the right lower quadrant of the abdomen. We found no relation between the age, weight, or height of the examined child and the overall diameter or wall of the appendix.

This chapter shows that a normal appendix can be depicted with US in 82% of the asymptomatic children. Lymph nodes (smaller than 1.0 cm) are a nonspecific finding in this study population.

In chapter 3, we evaluated the additional value of secondary signs in the diagnosing of appendicitis in children using US. From May 2005 to June 2006, 212 consecutive pediatric patients with suspected appendicitis were examined. Ultrasonographic depiction of the appendix was classified into four groups: 1, normal appendix; 2, appendix not depicted, no secondary signs of appendicitis; 3, appendix not depicted with one of the following secondary signs: hyperechoic

mesenteric fat, fluid collection, local dilated small bowel loop; 4, depiction of inflamed appendix. We classified 96 patients in group 1, 41 in group 2, 13 in group 3, and 62 in group 4. Prevalence of appendicitis was 71/212 (34%). Negative predictive values of groups 1 and 2 were 99% and 100%, respectively. Positive predictive values of groups 3 and 4 were 85% and 95%, respectively. In groups 3 and 4, hyperechoic mesenteric fat was seen in 73/75 (97.3%), fluid collections and dilated bowel loops were seen in 12/75 (16.0%) and 5/75 (6.6%), respectively. None of the patients in whom the appendix could not be depicted and without secondary signs, developed acute appendicitis in one year follow-up. Thus, when the appendix can not be visualized at US and secondary signs of appendicitis are absent, one can safely rule out the diagnosis of acute appendicitis. On the other hand, when secondary signs are present in the right lower quadrant of the abdomen, even in cases of non-visualization of the appendix, the diagnosis is acute appendicitis.

In chapter 4, we determined the frequency of hyperechogenicity of renal parenchyma in children with acute abdominal illness and we evaluated the assumed transient feature of this hyperechogenicity. Between January 2005 and February 2006, 189 consecutive patients (112 boys and 77 girls; mean age, 10 years) presenting with acute abdominal pain were examined with US. Patients with a known history of renal disease and those with acute urinary tract infection were excluded from the study. Echogenicity of the renal cortex in comparison with adjacent liver was recorded. Renal cortex echogenicity was divided into three groups; group 1, renal cortex echogenicity less than liver parenchyma echogenicity; group 2, renal cortex echogenicity similar to that of liver parenchyma; and group 3, renal cortex echogenicity greater than that of liver parenchyma. Patients with hyperechogenicity were reexamined with US after 2 weeks or more. The final US diagnosis and clinical outcome were noted. Renal cortex echogenicity was equal to or greater than that of the liver parenchyma in 18% ( $n = 34$ ) of 189 patients. Increased echogenicity of the renal cortex returned to normal in 2 or more weeks in all patients. Three patients had no follow-up. Clinical diagnoses were idiopathic acute abdominal pain ( $n = 74$ ), appendicitis ( $n = 83$ ), mesenteric lymphadenitis ( $n = 15$ ), ileocectitis ( $n = 7$ ), gastroenteritis ( $n = 7$ ), Crohn disease ( $n = 1$ ), intussusception ( $n = 1$ ), and pneumonia ( $n = 1$ ). No concurrent renal disease was diagnosed. Hypothetically, the increased echogenicity of the renal cortex could be caused by the believed dehydrated state as a consequence of the acute illness. There is, however, no evidence for this. Increased echogenicity of the renal cortex in children with acute abdominal illness is a transient feature and does not indicate renal disease. When seeing increased renal cortex echogenicity, the radiologist should look thoroughly for non-renal abnormality such as acute appendicitis.

In chapter 5, we assessed the US features of ileoileal and ileocolic intussusceptions. The treatment of ileoileal intussusception in children differs from that of ileocolic intussusception.

We reviewed the clinical and US findings of 27 cases with intussusception between September 2003 and July 2005. For statistical analysis the Mann-Whitney test was applied. Regarding ileoileal intussusceptions, 11 were documented in ten patients (7 boys, 3 girls; mean age, 3.1 years). Symptoms suggestive of intussusception were present in nine patients. The mean diameter was 1.5 cm (range, 1.1-2.5 cm) and length 2.5 cm (range, 1.5-6.0 cm). The intussusceptions were located in the paraumbilical region ( $n = 6$ ), the right upper quadrant ( $n = 2$ ), the right lower quadrant ( $n = 2$ ), and the left lower quadrant ( $n = 1$ ). Regarding ileocolic intussusceptions, 16 were documented in 14 patients (13 boys, 1 girl; mean age, 1.9 years). All patients had symptoms suggestive of intussusception. The mean diameter was 3.7 cm (range, 3.0-5.5 cm) and mean length was 8.2 cm (range, 5.0-12.5 cm). All intussusceptions were located in the right side of the abdomen. The difference in diameter and length between ileoileal and ileocolic intussusceptions was statistically significant ( $p < 0.05$ ). US features, like diameter and length, are the main criteria for differentiation between the two types intussusception. When the diameter is more than 2.5 cm and the length is more than 5.0 cm, the intussusception is most likely to be ileocolic. Ileoileal intussusceptions resolve spontaneously, while ileocolic intussusception must be treated with enema or in rare cases with surgery. Clinical and ultrasonographic follow-up of the ileoileal intussusception is recommended.

The relation between mesenteric lymph nodes and parasitic intestinal infections in 224 children (89 boys, 135 girls; mean age, 9.0 years) with recurrent abdominal pain (RAP) are discussed in chapter 6. The children included in this study were subjected to an abdominal US and stool analysis. The presence of mesenteric lymph nodes and their size were evaluated. Lymph nodes were considered to be enlarged when they measured 8 mm or more. Organic abnormalities at abdominal US were noted. Fecal analysis was performed to detect the presence of parasitic infection. Mesenteric lymph nodes were depicted in all children. Lymph nodes were enlarged in only 6 (2.7%) of 224 patients. Parasitic infections were present in 56 (25.0%) of 224 patients with RAP. Enlarged mesenteric lymph nodes were not associated with the presence of parasitic intestinal infections in these children. Organic abnormalities (hepatic steatosis  $n = 2$ , mild ileocectitis  $n = 1$ , echogenic particles in the bladder  $n = 1$ , suspected appendicitis  $n = 1$ , mild thickening of small bowel walls  $n = 2$ , hepatic enlargement  $n = 2$ , abnormal terminal ileum (suspected Crohn disease)  $n = 2$ ) were seen in only 11 patients (4.8%) of the patient population, and in only half of these patients these organic abnormalities could be related to their chronic abdominal pain. This study showed, that there is no association between (enlarged) mesenteric lymph nodes and parasitic intestinal infection in children with RAP. And, in less than 5% of these children with RAP organic abnormalities can be depicted with US.



## Conclusions

The following conclusions can be drawn:

1. The normal appendix can be depicted with ultrasonography in 82% of asymptomatic children (aged 2-15 years).
2. The normal appendix has a transversal diameter smaller than 0.6 cm in asymptomatic children.
3. The presence of mesenteric lymph nodes smaller than 1.0 cm is a non-specific finding in children without abdominal pain.
4. In the absence of secondary signs, acute appendicitis can be safely ruled out, even when the appendix is not depicted.
5. The presence of secondary signs of acute appendicitis in the right lower quadrant of the abdomen strongly indicates the presence of acute appendicitis in children with clinically suspected appendicitis.
6. Increased echogenicity of the renal cortex in children with acute illness is a transient finding, not associated with renal disease. In the majority of these patients abnormalities can be found in the abdomen using ultrasonography.
7. Ileoileal and ileocolic intussusceptions can be differentiated using ultrasonography. Diameter and length are the main criteria.
8. The presence of (enlarged) mesenteric lymph nodes is not associated with parasitic intestinal infections in children with recurrent abdominal pain. Organic abnormalities were depicted at abdominal ultrasonography in less than 5% of the patients.

# 8

## **Samenvatting en conclusies**



Hoofdstuk 1 geeft een algemene inleiding op dit proefschrift. De belangrijkste doelen van dit proefschrift waren achtereenvolgens: het beschrijven van de echografische kenmerken van de normale appendix in asymptomatische kinderen; een evaluatie van een echografische classificatie van acute appendicitis met de nadruk op secundaire tekenen van appendicitis; het vaststellen van de frequentie van toegenomen echogeniciteit van het nierparenchym en de evaluatie van het vooronderstelde tijdelijke karakter van deze toegenomen echogeniciteit; de evaluatie van de mogelijkheid tot differentiatie tussen ileoileale en ileocolische invaginaties op basis van klinische en/of echografische bevindingen; en de evaluatie van de betekenis van de aanwezigheid van mesenteriale lymfklieren bij kinderen met chronische buikpijn en de mogelijke relatie van de mesenteriale lymfklieren met een parasitaire darminfectie.

In hoofdstuk 2 beschrijven wij prospectief de echografische kenmerken van de appendix in kinderen zonder buikpijn. Tussen maart 2003 en juli 2003, werden 146 achtereenvolgende kinderen (62 jongens, 84 meisjes; gemiddelde leeftijd, 7 jaar; range, 2-15 jaar) zonder buikklasten echografisch onderzocht. Patiënten met cystic fibrosis en kinderen met acute buikpijn werden uitgesloten van deelname aan de studie. Buitenste diameters en wanddiktes werden gemeten. Color Doppler flow werd eveneens bepaald. Het lumen van de appendix en de omgeving van de appendix werden bepaald. Een eventuele relatie tussen de totale diameter en de wanddikte van de appendix en leeftijd, gewicht of lengte van de patiënt werd onderzocht. Voor statistische analyse werd gebruik gemaakt van de Mann-Whitney test, Student *t* test en lineaire regressie analyse. De normale appendix werd gevisualiseerd in 120 kinderen (82% van de onderzochte groep). Een normale appendix was goed comprimeerbaar, had een gemiddelde diameter van 0,39 cm en een gemiddelde wanddikte van 0,18 cm. Het lumen van 74 (62%) appendices was leeg. Bij 46 kinderen was het lumen van de appendix gevuld met lucht ( $n = 14$ , 12%), faecaal materiaal ( $n = 29$ , 24%) of beide ( $n = 3$ , 2%). Bij 75 (51%) van alle 146 kinderen werden lymfklieren (kleiner dan 1 cm) gezien rechts onder in de buik. Een relatie tussen leeftijd, gewicht of lengte van het onderzochte kind, en de totale diameter of wanddikte van de appendix werd niet gevonden. Dit hoofdstuk laat zien dat de normale appendix echografisch gevisualiseerd kan worden in 82% van de kinderen. Als nevenbevinding wordt in deze studie beschreven, dat aanwezigheid van mesenteriale lymfklieren kleiner dan 10 mm een aspecifieke bevinding is bij kinderen zonder acute buikpijn.

In hoofdstuk 3 wordt de aanvullende waarde van echografische secundaire tekenen van acute appendicitis geëvalueerd. Van mei 2005 tot juni 2006 werden 212 achtereenvolgende pediatrie patiënten (129 jongens, 83 meisjes; gemiddelde leeftijd, 10 jaar, range 2-15 jaar) echografisch onderzocht. De echografische bevindingen werden in vier groepen verdeeld: 1 normale appendix, 2 appendix niet à vue zonder secundaire tekenen, 3 appendix niet à vue met secundaire tekenen (zoals hyperechogeniciteit van mesenteriaal vet, vochtcollectie of gedilateerde dunne darmlussen) en 4 een ontstoken appendix. In groep 1 werden 96 kinderen geïncludeerd, 41 in groep 2, 13

in groep 3 en 62 in groep 4. Prevalentie van appendicitis in deze studie bedroeg 34% (71/212). Negatief voorspellende waarden van groep 1 en 2 waren respectievelijk 99% en 100%. Positief voorspellende waarden van groep 3 en 4 waren respectievelijk 85% en 95%. In de groepen 3 en 4 werd hyperechogeen mesenteriaal vet rechts onder in de buik gevisualiseerd in 73 van de 75 kinderen (97,3%), vochtcollecties in 12 van de 75 van kinderen (16,0%) en gedilateerde darmlussen in 5 van de 75 kinderen (6,6%). Geen van de kinderen, bij wie de appendix niet gevisualiseerd werd en waarbij secundaire tekenen ontbraken, ontwikkelde alsnog appendicitis gedurende 1 jaar follow-up. Wanneer de appendix echografisch onvindbaar is en secundaire tekenen van acute appendicitis ontbreken, kan acute appendicitis worden uitgesloten als diagnose. Maar wanneer er wel secundaire tekenen aanwezig zijn rechts onder in de buik, is de echografische diagnose appendicitis acuta.

In hoofdstuk 4 beschrijven wij de frequentie van verhoogde echogeniciteit van het nierparenchym bij kinderen (112 jongens, 77 meisjes; gemiddelde leeftijd 10 jaar; range, 2-15 jaar) met acute buikpijn (acute buikpijn korter dan acht dagen, met of zonder misselijkheid, braken, koorts of diarree). Daarnaast evalueren wij in dit hoofdstuk het veronderstelde tijdelijke karakter van deze bevinding. De echogeniciteit van de renale cortex werd vergeleken met de echogeniciteit van de aanliggende lever. De echogeniciteit van de renale cortex werd als volgt geclassificeerd: groep 1, de renale cortex echogeniciteit is minder dan die van de aanliggende lever; groep 2, renale echogeniciteit is gelijk aan die van de lever en groep 3, renale cortex echogeniciteit is hoger dan de echogeniciteit van het leverparenchym. Patiënten met verhoogde echogeniciteit van de renale cortex werden na twee weken opnieuw echografisch beoordeeld. De echogeniciteit van de renale cortex was verhoogd in 34 (18%) van de 189 acuut zieke kinderen. Geen van de kinderen had op het moment van de onderzoeksperiode een nieraandoening of een nieraandoening in de medische voorgeschiedenis. Deze toegenomen echogeniciteit normaliseerde na behandeling van de oorzaak van het acute ziek zijn (appendicitis acuta  $n = 16$ , lymfadenitis mesenterica  $n = 1$ , ileocoecitis  $n = 1$ , gastroenteritis  $n = 3$ , morbus Crohn  $n = 1$  en pneumonie  $n = 1$ ). Hypothetisch gesproken, zou de verhoogde echogeniciteit van de renale cortex veroorzaakt kunnen worden door de meer gedehydrateerde toestand van de kinderen als gevolg van hun ziek zijn. Echter, dit is nog niet bewezen. Verhoogde echogeniciteit van de renale cortex bij acuut zieke kinderen is een tijdelijk verschijnsel en wijst niet noodzakelijkerwijs op een nieraandoening. De radioloog moet zich bij het aanschouwen van verhoogde echogeniciteit van het nierparenchym bij een acuut ziek kind aangespoord voelen het abdomen goed verder te onderzoeken om een verklaring te vinden voor de afwijkende echogeniciteit van de renale cortex, zoals bijvoorbeeld appendicitis acuta.

In hoofdstuk 5 beschrijven wij een groep kinderen verzameld in een periode van bijna 2 jaar met een ileoileale of ileocolische invaginatie. In dit hoofdstuk worden de verschillende klinische en echografische bevindingen van 27 ileoileale en ileocolische invaginaties geëvalueerd, omdat de therapie van ileoileale invaginaties verschilt van de therapie van ileocolische invaginaties.

In totaal waren er 11 ileoileale invaginaties gedocumenteerd in 10 patiënten (7 jongens, 3 meisjes; gemiddelde leeftijd 3,1 jaar). Symptomen, suggestief voor een invaginatie (buikpijn, palpabele massa, overgeven en/of rectaal bloedverlies) waren aanwezig bij negen kinderen. De ileoileale invaginatie heeft een gemiddelde diameter van 1,5 cm (range, 1,1-2,5 cm) en een gemiddelde lengte van 2,5 cm (range 1,5-6,0 cm). Dit type invaginatie bevond zich in zes gevallen paraumbilicaal, tweemaal rechts boven in de buik, tweemaal rechts onder in de buik en éénmaal links onder in de buik. Ileocolische invaginaties werden 16 maal gedocumenteerd in 14 patiënten (13 jongens, 1 meisje; gemiddelde leeftijd, 1,9 jaar). Alle 14 kinderen hadden symptomen suggestief voor invaginatie. De ileocolische invaginatie had een gemiddelde diameter en lengte van 3,7 cm (range, 3,0-3,5 cm) en 8,2 cm (range, 5,0-12,5 cm), respectievelijk. Alle ileocolische invaginaties bevonden zich in de rechter onderbuik. Er was een statistisch significant verschil ( $p < 0,05$ ) in diameter en lengte tussen ileoileale en ileocolische invaginaties. De diameter en de lengte van de invaginatie zijn de belangrijkste criteria voor het onderscheid. Een invaginatie met een diameter groter dan 2,5 cm en lengte meer dan 5,0 cm is meest waarschijnlijk van het ileocolische type. Ileoileale invaginaties verdwijnen over het algemeen spontaan. Ileocolische invaginaties, daarentegen, hebben een invasieve aanpak nodig; repositie middels colon-inloop of soms chirurgisch. Wel is het van belang de ileoileale invaginaties klinisch en echografisch te vervolgen om spontaan herstel te kunnen vaststellen.

In hoofdstuk 6 evalueren wij de aanwezigheid van mesenteriale lymfklieren bij kinderen met chronische buikpijn (89 jongens, 135 meisjes; gemiddelde leeftijd 9,0 jaar) en de potentiële relatie met parasitaire intestinale infecties. Alleen kinderen, die een abdominale echografie en faeces-analyse hebben ondergaan, namen deel aan deze studie. De aanwezigheid en de grootte van mesenteriale lymfklieren werd geëvalueerd. Lymfklieren met een korte as van 8 mm of meer werden beschouwd als vergroot. Ook afwijkingen aan abdominale organen bij echografisch onderzoek werden genoteerd. Analyse van faeces werd verricht om parasitaire infecties aan te tonen. Echografisch werden bij alle kinderen mesenteriale lymfklieren gezien, echter slechts bij 6 (2,7%) van de 224 kinderen waren de klieren vergroot. Parasitaire infecties werden gevonden bij 56 (25,0%) van 224 kinderen met chronische buikpijn. Een associatie tussen vergrote mesenteriale lymfklieren en parasitaire intestinale infectie ontbrak in deze studiepopulatie. Bij 11 kinderen (4,8%) werd echografisch een “organische” afwijking in de buik gedetecteerd. De organische afwijkingen waren; steatosis hepatis ( $n = 2$ ), milde ileocoecitis ( $n = 2$ ), hepatomegalie ( $n = 2$ ), hyperechogene partikels in blaas ( $n = 1$ ) en een abnormaal terminaal ileum (verdenking morbus Crohn,  $n = 2$ ). Slechts bij zes kinderen kon die afwijking als verklaring worden beschouwd als oorzaak voor de chronische buikpijn klachten. Deze studie toonde geen associatie tussen (vergrote) mesenteriale lymfklieren en parasitaire infecties in kinderen met chronische buikpijn. Organische afwijkingen werden in minder dan 5% van de onderzochte kinderen gezien middels echografie.

## Conclusies

Uit dit proefschrift worden de volgende conclusies getrokken:

1. De normale appendix kan gevisualiseerd worden, middels echografie, in 82% van kinderen (2-15 jaar oud) zonder buikklachten.
2. Een transversale diameter van de normale appendix is kleiner dan 0.6 cm in kinderen zonder buikklachten.
3. De aanwezigheid van mesenteriale lymfklieren kleiner dan 1 cm in het abdomen van een kind (zonder buikklachten) kan beschouwd worden als een niet specifieke bevinding.
4. In afwezigheid van secundaire tekenen van appendicitis kan bij non-visualisatie van de appendix gedurende het echografisch onderzoek appendicitis worden uitgesloten.
5. De echografische aanwezigheid van secundaire tekenen van appendicitis rechts onder in de buik, ook bij non-visualisatie van de appendix, is zeer suspect voor de diagnose appendicitis acuta bij kinderen met klinische verdenking op appendicitis.
6. Verhoogde echogeniciteit van de renale cortex is bij acuut zieke kinderen een non-specifieke bevinding van voorbijgaande aard en duidt niet op onderliggend nierlijden.
7. Echografie maakt onderscheid tussen ileoileale en ileocolische invaginaties mogelijk. Diameter en lengte van het invaginaat zijn de belangrijkste criteria.
8. Vergrote mesenteriale lymfklieren zijn niet geassocieerd met de aanwezigheid van parasitaire intestinale infecties bij kinderen met chronische buikpijn. In minder dan 5% van de abdominale echo's bij kinderen met chronische buikpijn worden organische afwijkingen aangetoond.

## **Curriculum vitae**





## **Curriculum Vitae**

De auteur van dit proefschrift werd geboren op 5 oktober 1980 te 's-Gravenhage. Zij behaalde in 1998 het Gymnasium diploma aan het Christelijk Scholengemeenschap Zandvliet te 's-Gravenhage. In hetzelfde jaar startte zij met de studie Geschiedenis aan de Universiteit van Leiden. Na het behalen van de propedeuse werd de studierichting in 1999 gewijzigd in Geneeskunde, eveneens aan de universiteit van Leiden. Deze studie werd afgesloten met het doctoraal examen in 2003 en aansluitend het artsexamen in 2005. In datzelfde jaar ving zij aan met de opleiding Radiologie (opleider Drs. W.M.C. Mallens) in het HagaZiekenhuis, locatie Leyweg. Deze opleiding werd gecombineerd met onderzoek, wat heeft geleid tot dit proefschrift (projectleiders Prof. dr. J.L. Bloem en Dr. H.C. Holscher).





