



Universiteit
Leiden
The Netherlands

Cardiovascular magnetic resonance imaging techniques in hypertension and diabetes

Brandts, A.

Citation

Brandts, A. (2011, March 10). *Cardiovascular magnetic resonance imaging techniques in hypertension and diabetes*. Retrieved from <https://hdl.handle.net/1887/16582>

Version: Corrected Publisher's Version

License: [Licence agreement concerning inclusion of doctoral thesis in the Institutional Repository of the University of Leiden](#)

Downloaded from: <https://hdl.handle.net/1887/16582>

Note: To cite this publication please use the final published version (if applicable).

Anne Brandts
Matteo Bertini
Evert-Jan van Dijk
Victoria Delgado
Nina Ajmone Marsan
Rob J. van der Geest
Hans-Marc J. Siebelink
Albert de Roos
Jeroen J. Bax
Jos J.M. Westenberg

Chapter 09

Diastolic Function Assessment from Three-Dimensional Three-Directional Velocity-Encoded MRI

J Magn Reson Imaging, accepted

Abstract

Purpose

To compare parameters describing left ventricular (LV) diastolic function obtained with 3-dimensional (3D) three-directional velocity-encoded (VE) MRI with retrospective valve tracking and 2-dimensional (2D) one-directional VE MRI in patients with ischemic heart failure. Secondly, to compare classification of LV diastolic function, and in particular for discriminating restrictive filling patterns, with both MRI techniques versus Doppler echocardiography.

Materials and Methods

3D and 2D VE MRI early (E) and atrial (A) peak flow rate indices, determined from transmitral waveform analyses, were compared. Also, net forward flow volume per cycle and transmitral regurgitation fraction were determined. Agreement in classifying diastolic filling patterns between 3D and 2D VE MRI versus Doppler echocardiography was evaluated using kappa statistics.

Results

3D three-directional VE MRI with retrospective valve tracking was statistically significantly different from 2D one-directional VE MRI for net forward flow volume and regurgitation fraction through the mitral valve and all parameters describing the diastolic waveform filling pattern, except for the E deceleration time and E/A filling ratio. Kappa-agreement between 3D three-directional VE MRI with retrospective valve tracking and echocardiography for classifying diastolic filling patterns was superior to 2D one-directional VE MRI and echocardiography (i.e. $\kappa=0.91$ versus $\kappa=0.79$ respectively).

Conclusion

3D three-directional VE MRI with retrospective valve tracking better describes LV diastolic function as compared to 2D one-directional VE MRI in patients with ischemic heart failure.

Introduction

Left ventricular (LV) diastolic dysfunction refers to abnormal LV diastolic distensibility, filling, or relaxation, regardless of whether the ejection fraction is normal or abnormal and whether the patient is symptomatic or asymptomatic (1,2). Moreover, restrictive transmitral flow assessed with Doppler echocardiography is an important prognostic factor for cardiac mortality, especially in heart failure patients (3). LV diastolic function can be studied from transmitral flow velocity recordings using Doppler echocardiography or transmitral flow rate graphs assessed by 2-dimensional (2D) one-directional velocity-encoded (VE) magnetic resonance imaging (MRI). Good correlation between VE MRI and Doppler echocardiography has been described (4-6).

Recently, it has been shown that 3-dimensional (3D) three-directional VE MRI with retrospective valve tracking describes more accurately net transmitral flow volumes and regurgitation fraction in patients with ischemic cardiomyopathy, as compared to 2D one-directional VE MRI (7). With 3D three-directional VE MRI, the acquisition plane is retrospectively adapted to the continuously changing position and angulation of the mitral valve, whereas with 2D one-directional VE MRI, the acquisition plane remains fixed during the cardiac cycle and is positioned at the mitral valve at moment of end-systole and therefore data is mainly acquired at a position below the valve inside the left ventricle. The adaption of the acquisition plane to the continuously changing position of the mitral valve, perpendicular to the inflow direction, throughout the cardiac cycle determines the accuracy of transmitral flow assessment.

Comparison between 3D three-directional VE MRI with retrospective valve tracking and 2D one-directional VE MRI has been limited to net forward flow volumes and regurgitation volumes only. LV diastolic function assessment by waveform analysis of the transmitral flow rate graph, assessed from this 3D VE MRI-approach in comparison to 2D one-directional VE MRI, has not been studied. Our hypothesis is that 3D three-directional VE MRI with retrospective valve tracking also provides a more accurate assessment of LV diastolic function. Therefore, the purpose of this study was twofold: first, to compare 3D three-directional VE MRI with retrospective valve tracking with 2D one-directional VE MRI for assessment of parameters obtained from the transmitral flow rate graphs in patients with ischemic heart failure; secondly, to compare classification of LV diastolic function based on these transmitral flow rate indices obtained with both MRI techniques versus Doppler echocardiography, to evaluate the clinical value of VE MRI for LV diastolic function assessment.

Materials and Methods

Patients

This prospective study was approved by the local institutional review board and patients gave informed consent for participation. A total of 47 consecutive patients (35 men and 12 women; mean age was 61 ± 13 years and 59 ± 11 years, respectively; overall mean age 60 years ± 12) with ischemic heart failure underwent 3D- and 2D VE MRI between July 2006 and July 2007. Part of this patient cohort (29 patients) has been reported in a previous publication by Roes et al. (8).

MRI Protocol

MRI was performed on a 1.5-T MRI (Intera, release 11 and 12; Philips Medical Systems, Best, the Netherlands) with 33 mT/m amplitude, 100 mT/m/ms slew rate, and 0.33-ms rise time. A five-element cardiac coil placed on the chest was used for signal reception. Total examination time for planning and performing 2D one-directional VE MRI and 3D three-directional VE MRI with retrospective valve tracking procedures never exceeded 30 minutes.

After acquisition of a series of thoracic scout images that were used for planning purposes, a two chamber view of the left ventricle and a four chamber view acquisition were obtained with a steady state free precession sequence (Figure 1). LV diastolic function was studied from the transmitral flow rate graphs, assessed with both 3D three-directional and 2D one-directional VE MRI as previously described (Figure 1)(7,9-11). Acquisition parameters for 3D three-directional MRI were: repetition time (TR) ms / echo time (TE) ms 7.5 / 4.3; flip angle (FA), 10°; field of view (FOV), 370 mm; 3D volume imaging with 48-mm slab thickness reconstructed into 12×4 mm sections; in-plane acquisition resolution 2.9×3.8 mm, reconstructed to 1.4×1.4 mm; one signal acquired; retrospective gating with 10%-acceptance window, with 30 phases reconstructed during one average cardiac cycle (the effective temporal resolution of the flow graph is defined by the heart beat interval and the number of reconstructed phases: for a heartbeat of 60 beats/min: 33 ms; the true temporal resolution is defined by the TR and the number of velocity encoding acquisition plus one velocity compensated acquisition: 30 ms ($4 \times TR$ (7.5 ms)); 150 cm/s maximal velocity encoding in all three directions; free-breathing was allowed. Echo planar imaging with a factor of five was used to reduce scan time (7).

Scan parameters for the 2D one-directional through-plane VE MRI sequence were: TR 8.3 ms / TE 5.2 ms, FA 20°, FOV 350 mm, slice thickness 8 mm, acquisition voxel $2.7 \times 3.4 \times 8$ mm³, reconstruction voxel $1.4 \times 1.4 \times 8$ mm³, two signals acquired, with 30 phases reconstructed during one average cardiac cycle (identical effective temporal resolution as for 3D VE MRI; true temporal resolution: 16ms ($2 \times TR$ (8.3 ms)); 150 cm/s maximal velocity encoding, with the encoding direction perpendicular to the acquisition plane; free-breathing was allowed.




Figure 1. Assessment of mitral valvular flow with 3D and 2D VE MRI. A MRI four-chamber cine scout view (a) is used for planning purposes of VE MRI and for the retrospective valve tracking procedure. On the resulting flow velocity images (b and c), the contour around the mitral annulus is manually segmented in each of the phases of the cardiac cycle for both 3D and 2D VE MRI, with through-plane motion correction from the velocity of the myocardium taken into account (one diastolic phase is shown for both 3D and 2D VE MRI (b and c, respectively)). Integration of the velocity over the mitral annulus after subtraction by the through-plane velocity acquired in the myocardium, results in the flow rate values for each cardiac phase, which can be represented in a flow graph (d and e).

VE MRI data processing

Transmitral flow rate graphs were determined for both 3D three-directional with retrospective valve tracking and 2D one-directional VE MRI as previously described (Figure 1) (7). For 3D three-directional VE MRI with retrospective valve tracking, transmitral flow was first reformatted from the 3D volume acquisition of the blood flow vector velocity field at the base of the heart, using the in-house developed software package MASS. The location and angulation of the mitral valve was also indicated manually by placing a line in each of the phases of the cardiac cycle in the 2- and 4-chamber views. Then, through-plane velocities in the mitral valve were reconstructed (Figure 1). Figure 1 indicates the flow graph, resulting from the integration of the velocities over the annulus, subtracted by the through-plane velocity acquired in the myocardial wall at the location of the annulus.

The 2D one-directional VE MR images were analyzed using in-house-developed software package FLOW. For both 3D- and 2D VE MRI acquisitions, through-plane-motion correction in combination with correction for local phase offset errors was performed as suggested by Kayser et al. (9) from the velocity determined in a region placed in the myocardium in the lateral wall near the annulus (Figure 1).

From the resulting transmitral flow rate-graphs, the following LV diastolic function parameters were determined: early (E) acceleration peak (ml/s^2), E filling rate (ml/s), E deceleration peak (ml/s^2), E deceleration time (ms), late atrial (A) peak acceleration peak (ml/s^2), A filling rate (ml/s), A deceleration peak (ml/s^2) and the E/A filling ratio (12,13). Also, the net forward flow

volume per cycle and the regurgitation fraction through the mitral valve were determined. The reformatting procedure (i.e. the retrospective valve tracking) for 3D three-directional VE MRI took approximately 5 minutes per study and the subsequent image analysis with contour segmentation also took 5 minutes. Image analysis and manual contour segmentation was performed by a senior researcher, with 15 years of experience in cardiac MRI.

Echocardiography

All patients were imaged in the left lateral decubitus position with a commercially available system (Vingmed Vivid 7, General Electric-Medical Systems, Milwaukee, Wisconsin, USA) equipped with a 3.5-MHz transducer. Standard 2-dimensional images and Doppler and color-Doppler data acquired from the parasternal and apical views (2-, 3-, and 4-chamber) were digitally stored in cine-loop format; analyses were subsequently performed offline using EchoPAC version 108.1.5 (General Electric-Medical Systems). LV end-diastolic (EDV) and end-systolic (ESV) volumes were measured according to the Simpson's biplane method and LV ejection fraction was calculated as $[(EDV-ESV)/EDV] \times 100\%$ (14). Spectral Doppler velocities were measured from the apical 4-chamber view using a 2 mm sample volume positioned at the mitral leaflet tips. Peak E and A wave mitral velocities, E/A ratio, and the E wave deceleration time were obtained (15). Transmitral flow velocity patterns were classified as normal, impaired relaxation, pseudo-normal and restrictive according to the current guidelines (15).

Diastolic filling pattern

Patients were classified into two groups according to LV diastolic filling pattern: group 1 included patients with normal, impaired relaxation and pseudo-normal diastolic filling patterns whereas group 2 included patients with restrictive diastolic filling patterns (16). For both 3D and 2D VE MRI acquisitions, LV diastolic function was graded following the classification based on Doppler echocardiography using the transmitral flow rate graphs, from the E/A ratio and the E wave deceleration time (ms) (16): patients in group 2 (restrictive LV filling pattern) had an E/A ratio > 2 and E wave deceleration time < 160 ms. Classification for MRI and Doppler echocardiography was performed in a blinded manner by an imaging cardiologist with more than 10 years of experience in cardiac Doppler echocardiography imaging.

Statistical Analyses

Data are expressed as mean \pm standard deviation (sd) unless stated otherwise. The difference between the 2D and 3D VE MR acquisitions for assessment of LV diastolic function parameters was tested by using the paired-sampled t-tests. Mean signed differences, standard deviations (sd) and 95% confidence intervals (95% CI) were reported. The intraclass correlation coefficient (ICC) for absolute agreement was calculated. ICC was classified as excellent (ICC > 0.85), good (ICC = 0.70 to 0.85), or moderate (ICC > 0.70). The approach described by Bland and Altman was used to study systematic differences between parameters obtained from the transmitral

flow rate graphs, assessed with 3D three-directional VE MRI with retrospective valve tracking and 2D one-directional VE MRI (17). Multivariate linear regression analysis was performed to identify independent correlation between E/A ratio with Doppler echocardiography and with 3D and 2D VE MRI. Agreement in classifying LV diastolic filling pattern with both VE MRI techniques versus Doppler echocardiography was assessed using kappa (κ) weighted statistics (18). Furthermore, sensitivity, specificity and positive and negative predictive value were obtained to express the clinical value of the techniques when used for classifying the diastolic filling pattern. All paired t-tests were 2-sided and a p-value (p) < 0.05 was considered statistically significant. Statistical analysis was performed by using SPSS for Windows (version 17.0; SPSS, Chicago, Ill).

Results

Patient characteristics

The general characteristics of the patient population are reported in Table 1. All patients had dilated left ventricles (mean LVEDV 195 ± 79 ml; mean LVESV 139 ± 71 ml) with LV systolic dysfunction (mean LV ejection fraction 31 ± 10 %) and moderate to severe mitral regurgitation was found in 18 patients (38%).

Table 1. Patient characteristics (left ventricular characteristics assessed with Doppler echocardiography).

Characteristics	Patients (n=47)
Age (years)	60 \pm 12
Gender (male/female)	35/12
LV end diastolic volume (ml)	195 \pm 79
LV end systolic volume (ml)	139 \pm 71
LV ejection fraction (%)	31 \pm 10
Moderate to severe mitral regurgitation, n (%)	18 (38%)
E peak (cm/s)	74 \pm 22
A peak (cm/s)	61 \pm 25*
E/A filling ratio	1.5 \pm 1.1*
E deceleration time (ms)	162 \pm 52

LV: left ventricular; A: atrial peak; E: early peak. * n=44, as 3 patients presented with monophasic transmitral flow velocity graphs with absent A peak.

Transmitral flow rate assessment with VE MRI

The parameters obtained from transmitral flow rate graphs, assessed with 3D three-directional VE MRI with retrospective valve tracking and 2D one-directional VE MRI, are presented in Table 2. The mean differences of parameters describing the E wave were statistically significantly different between both VE MRI techniques, except for the E deceleration time (i.e. mean difference \pm sd, p-value; E acceleration peak: -3.5 ± 2.7 ml/s², $p < 0.01$; E filling

Table 2. Comparison 3D and 2D velocity-encoded MRI for assessment of diastolic function analyses.

Patients (N = 47)	Mean difference \pm sd					
	mean \pm sd	3D VE MRI – 2D VE MRI	95% CI	p-value	ICC	p-value
E acceleration peak (ml/s²)						
3D VE MRI	5.6 \pm 2.7					
2D VE MRI	9.1 \pm 0.1	-3.5 \pm 2.7	-4.3 to -2.7	<0.01*	0.58	<0.01*
E filling rate (ml/s)						
3D VE MRI	356 \pm 142					
2D VE MRI	461 \pm 161	-105 \pm 76	-127 to -82	<0.01*	0.83	<0.01*
E deceleration peak (ml/s²)						
3D VE MRI	-3.3 \pm 2.1					
2D VE MRI	-4.6 \pm 2.8	1.3 \pm 1.3	0.9 to 1.6	<0.01*	0.86	<0.01*
E deceleration time (ms)						
3D VE MRI	144 \pm 66					
2D VE MRI	144 \pm 70	-0.2 \pm 41	-12 to 12	0.97	0.90	<0.01*
A acceleration peak (ml/s²)[#]						
3D VE MRI	3.9 \pm 1.8					
2D VE MRI	5.4 \pm 2.7	-1.5 \pm 1.9	-2.0 to -0.9	<0.01*	0.71	<0.01*
A filling rate (ml/s)[#]						
3D VE MRI	284 \pm 119					
2D VE MRI	348 \pm 157	-68 \pm 95	-96.5 to -38.9	<0.01*	0.83	<0.01*
A deceleration peak (ml/s²)[#]						
3D VE MRI	-5.4 \pm 2.4					
2D VE MRI	-6.6 \pm 3.1	1.2 \pm 2.0	0.6 to 1.8	<0.01*	0.82	<0.01*
E/A filling ratio[†]						
3D VE MRI	1.9 \pm 2.1					
2D VE MRI	2.0 \pm 2.0	-0.1 \pm 1.3	-0.5 to 0.3	0.65	0.88	<0.01*
Net forward flow (ml)						
3D VE MRI	64.0 \pm 20.4					
2D VE MRI	84.4 \pm 23.9	-20.4 \pm 14.3	-24.6 to -16.2	<0.01*	0.72	<0.01*
Regurgitation fraction (%)						
3D VE MRI	12 \pm 9					
2D VE MRI	4 \pm 8	8 \pm 10	5 to 11	<0.01*	0.31	0.04*

E: early peak; A: atrial peak; sd: standard deviation; 95% CI: 95% confidence interval; ICC: Intra-class-correlation; [#]N=44 patients because in three patients only monophasic tranmitral flow curves with absent A peak were obtained * p-value<0.05 was considered statistically significant.

rate: -105 \pm 76 ml/s, p < 0.01; E deceleration peak: 1.3 \pm 1.3 ml/s², p < 0.01). Overall, E peak values were lower when measured with 3D three-directional VE MRI with retrospective valve tracking as compared to 2D one-directional VE MRI. Good to excellent correlation was found between both techniques with good agreement as demonstrated by the ICCs for E

peak measurements, except for the E acceleration peak. ICCs were highest for E filling rate, E deceleration peak and E deceleration time (0.83, 0.86 and 0.90 respectively). Scatter diagram and Bland-Altman plot of E deceleration time is given in Figure 2a. No significant trend was detected.

Calculations for the A filling rate indices were performed in 44 patients (i.e. 94% of patients). In 3 patients out of the original 47 patients, only monophasic transmitral flow rate graphs with absent A-peak were obtained with both 3D three-directional VE MRI with retrospective valve tracking and 2D one-directional VE MRI. The mean differences of parameters describ-

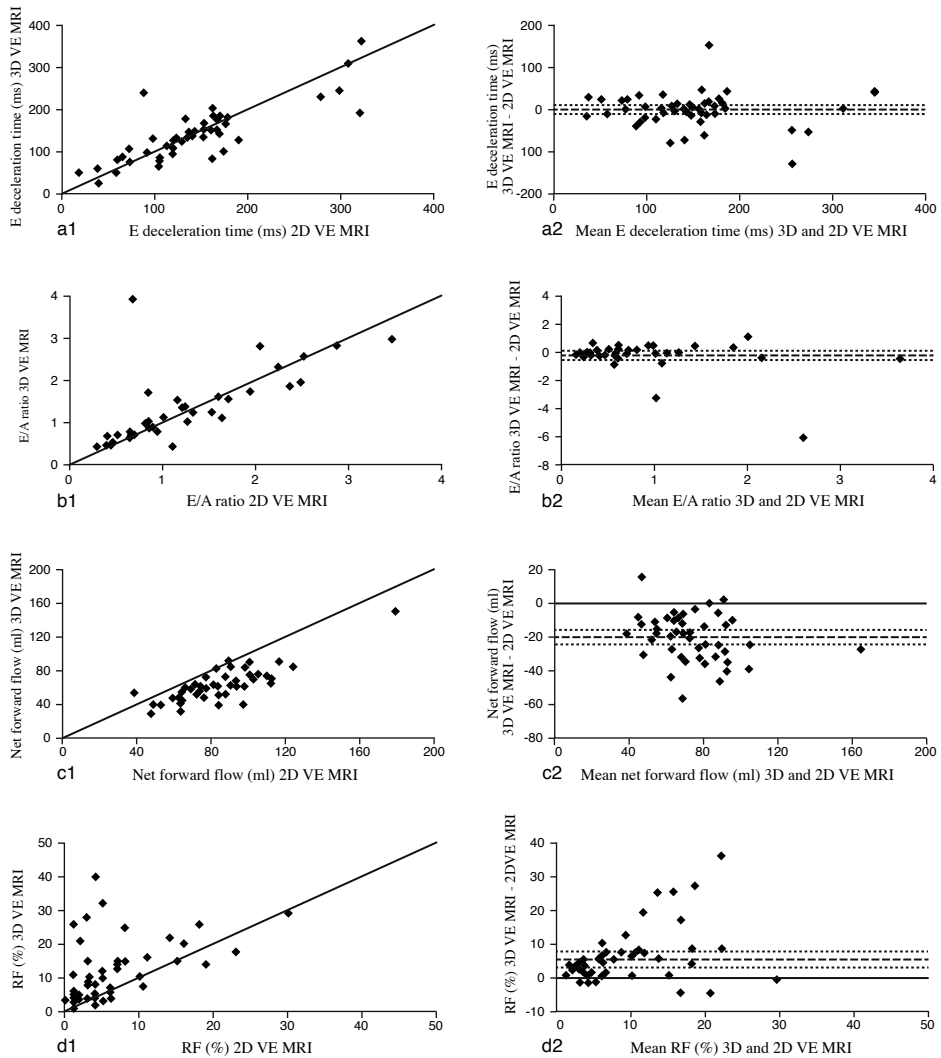


Figure 2. Scatter diagrams (1) and Bland-Altman (2) plots for early (E) and atrial (A) peak parameters, E/A filling ratio, net forward flow volume and regurgitation fraction obtained from the transmitral flow rate graphs, assessed with 3D three-directional VE MRI and 2D one-directional VE MRI. a: E deceleration time; b: E/A filling ratio; c: net forward flow volume; d: regurgitation fraction.

ing the A peak were statistically significantly different between both VE MRI techniques (i.e. mean difference \pm sd, p-value; A acceleration peak: -1.5 ± 1.9 ml/s², $p < 0.01$; A filling rate: -68 ± 95 ml/s, $p < 0.01$; A deceleration peak: 1.2 ± 2.0 ml/s², $p < 0.01$). Measurements for A peak indices performed by 3D three-directional VE MRI with retrospective valve tracking proved to be lower than obtained by 2D one-directional VE MRI. ICCs concerning A peak flow showed good correlation for all A peak flow indices (A acceleration peak: 0.71; A filling rate: 0.83; A deceleration peak: 0.82).

The E/A filling ratio was not statistically different between both methods and a high ICC was found (ICC = 0.88). Scatter diagram and Bland-Altman plot of the E/A filling ratio is presented in Figure 2b and no significant trend was detected.

The regurgitation fraction and net forward flow volume across the mitral valve measured by 3D three-directional VE MRI with retrospective valve tracking were significantly different from 2D one-directional VE MRI measurements. With the 3D VE MRI-approach, higher values for the regurgitation fraction were found as compared to 2D one-directional VE MRI. ICCs concerning net forward flow volume and regurgitation fraction were 0.72 and 0.31, respectively. Scatter diagrams and Bland-Altman plots of net forward flow volume and regurgitation fraction are presented in Figure 2c and 2d. From these plots, no significant trends were detected.

Left ventricular diastolic function classification with VE MRI versus Doppler echocardiography

In Tables 3 and 4, cross tables are presented describing the kappa agreement between 3D three-directional VE MRI with retrospective valve tracking and echocardiography and 2D one-directional VE MRI and echocardiography, respectively, for classifying patients according to diastolic filling pattern: restrictive filling (group 2) or other LV filling patterns (group 1). For both 3D and 2D VE MRI acquisitions, good agreement was found with echo Doppler, with 3D three-directional VE MRI with retrospective valve tracking showing superior agreement compared to 2D one-directional VE MRI. ($\kappa = 0.91$ versus 0.79 respectively). Furthermore, after multivariate linear regression analysis, only E/A filling ratio measured with 3D three-directional VE MRI with retrospective valve tracking was independently related to E/A ratio measured with Doppler echocardiography ($\beta = 0.57$, $p = 0.001$). In contrast, E/A filling ratio measured with 2D one-directional VE MRI was not significantly related to E/A ratio measured with Doppler echocardiography ($\beta = 0.28$; $p = \text{NS}$). E deceleration time was not introduced in the model because of high multicollinearity between 2D and 3D VE MRI.

Finally, a high sensitivity (91%) and specificity (100%) for 3D three-directional VE MRI with retrospective valve tracking versus echocardiography was found with a positive predictive value of 100% and a negative predictive value of 92%. For 2D one-directional VE MRI versus echocardiography, sensitivity amounted to 87%, specificity 92%, positive predictive value 91% and negative predictive value 88%.

Table 3. Cross table for classification of diastolic filling pattern with 3D three-directional VE MRI versus Doppler echocardiography (Echo).

	<i>Echo</i>	<i>Group 1</i>	<i>Group 2</i>	<i>Total</i>
<i>3D VE MRI</i>				
Group 1		24	2	26 (55%)
Group 2		0	21	21 (45%)
Total		24 (51%)	23 (49%)	47 (100%)

Weighted Kappa = 0.91

Standard error = 0.06

Table 4. Cross table for classification of diastolic filling pattern with 2D one-directional VE MRI versus Doppler echocardiography (Echo).

	<i>Echo</i>	<i>Group 1</i>	<i>Group 2</i>	<i>Total</i>
<i>2D VE MRI</i>				
Group 1		22	3	25 (53%)
Group 2		2	20	22 (47%)
Total		24 (52%)	23 (49%)	47 (100%)

Weighted Kappa = 0.79

Standard error = 0.09

Discussion

The main findings of the current study are as follows:

1. 3D three-directional VE MRI with retrospective valve tracking and 2D one-directional VE MRI demonstrated to be significantly different for assessing parameters that describe the transmitral flow rate graph in patients with ischemic heart failure. In particular, all flow rate parameters determined with 3D three-directional VE MRI with retrospective valve tracking were systematically lower than when assessed with 2D one-directional VE MRI, except for E/A filling ratio and E deceleration time, which were not significantly different.

2. The excellent agreement between 3D three-directional VE MRI with retrospective valve tracking and Doppler echocardiography in classifying LV diastolic filling patterns was superior to the agreement between 2D one-directional VE MRI and Doppler echocardiography.

3D three-directional VE MRI with retrospective valve tracking has been validated and compared with 2D one-directional VE MRI for assessment of flow volumes across the mitral valve by Westenberg et al (7). Their study, performed in 20 patients with ischemic heart disease, demonstrated that using 2D one-directional VE MRI resulted in approximately 15% overestimation in net forward flow volume across the mitral valve as compared to 3D three-directional VE MRI with retrospective valve tracking. Furthermore, a statistically significantly higher transmitral regurgitation fraction was found in the patients with heart failure when using 3D VE MRI with retrospective valve tracking. These results are in line with our study, where 12% mean regurgitation fraction was found in patients with heart failure (N=47) with the 3D VE MRI-approach as compared to 4% mean regurgitation fraction with 2D one-directional VE MRI. Roes et al. applied the same 3D VE MRI-technique in 29 patients with ischemic heart

disease and suspicion of valvular regurgitation (these patients were also part of the cohort that is included in the current study) to determine the flow rate across all four heart valves, but mitral flow volumes and regurgitation fraction assessed with 3D three-directional VE MRI with retrospective valve tracking were not compared to 2D one-directional VE MRI (18).

In another study by Roes et al, 3D three-directional VE MRI with retrospective valve tracking was applied to determine LV diastolic function in subjects with and without metabolic syndrome (19). However, no comparison between 3D three-directional VE MRI with retrospective valve tracking and 2D one-directional VE MRI for evaluating absolute LV diastolic function assessment was performed and neither comparison with Doppler echocardiography was reported.

In the current study, a statistically significant difference was found between 3D three-directional VE MRI with retrospective valve tracking and 2D one-directional VE MRI for all indices describing the transmitral flow rate graph and subsequently, the LV diastolic function, except for E/A filling ratio and E deceleration time. With 3D VE MRI, a 3D volume acquisition is performed of the velocity vector field at the base of the heart. In retrospect, the reformatted mitral valvular plane is adapted to the continuously changing position and angulation of the mitral valve and the direction of the blood flow. With conventional 2D one-directional VE MRI, the acquisition plane remains fixed during the cardiac cycle and is positioned at the mitral valve at moment of end-systole. This implies that during most part of the cardiac cycle, the velocity is acquired inside the left ventricle and not at the mitral valve itself, resulting in a systematically overestimation by 2D one-directional VE MRI of net forward inflow volume and absolute diastolic flow rate parameters, whereas the regurgitation fraction will be underestimated.

With MRI, and also in this study, LV diastolic function indices are generally obtained from the transmitral flow rate instead of the transmitral flow velocity as is done with Doppler echocardiography. Direct comparison of velocities between echo and MRI has been done for 2D one-directional VE MRI by Ajmone Marsan et al. (11). They reported a small, non-significant difference between both techniques, but with wide limits of agreement (i.e. -14 cm/s to 13 cm/s). Using the transmitral flow rate graph in the MRI approach will be less noise-sensitive than the use of maximal flow velocity. Echocardiography is more suitable to report the maximal transmitral flow velocity than MRI, as the sample volume is small compared to MRI acquisition and the flow velocity graph is sampled with a much higher temporal resolution. On the other hand, with Doppler echocardiography, sampling is also performed on a fixed location in the inflow area close to the mitral valve and no adaptation to the moving annulus nor through-plane motion correction is undertaken. Still, Doppler echocardiography is used in clinical research as a reference standard for classification of LV diastolic function.

When using transmitral flow rate graphs, restrictive diastolic LV filling patterns can be discriminated from other diastolic filling patterns. Preliminary studies have shown good correlation between Doppler echocardiography and 2D one-directional VE MRI for estimation

of LV diastolic function (4-6). In the present study, the agreement in identifying the diastolic LV filling patterns between Doppler echocardiography and 3D three-directional VE MRI with retrospective valve tracking was superior (i.e. κ -agreement = 0.91) to the agreement between Doppler echocardiography and 2D one-directional VE MRI (i.e. κ -agreement = 0.79), resulting also in higher values for sensitivity, specificity, positive predictive value and negative predictive value. This finding underscores that both 3D three-directional VE MRI with retrospective valve tracking and 2D one-directional VE MRI can be used to evaluate LV diastolic function in heart failure patients. However, the precision in classifying LV diastolic function from the transmitral flow rate graph obtained with 3D three-directional VE MRI with retrospective valve tracking appears to agree better with echocardiography than when obtained with 2D one-directional VE MRI.

Restrictive transmitral flow has been shown to be an important prognostic factor for cardiac mortality in advanced heart failure patients (3). Based on the current findings, 3D three-directional VE MRI with retrospective valve tracking not only provides more accurately transmitral flow volumes and regurgitation fraction as compared to 2D one-directional VE MRI, but the 3D VE MRI-approach also better discriminates restrictive transmitral flow when Doppler echocardiography is used as the reference standard. This is important for the clinical evaluation of symptoms, optimization of therapy, and prediction of prognosis in heart failure patients (15,20).

The present study has some limitations. First, all patients presented with heart failure and no healthy subjects with normal LV diastolic function were included. To further evaluate the value of LV diastolic function assessment with 3D three-directional VE MRI with retrospective valve tracking, patients with various pathologies and healthy volunteers need to be examined as well.

In addition, the present study did not include invasive measurements of LV filling pressures. However, echocardiography is a widely used and validated method to assess LV volumes, systolic and diastolic function and therefore, it may be a valuable reference method. Furthermore, 3D three-directional VE MRI with retrospective valve tracking was performed with an Echo Planar Imaging factor of five, whereas 2D one-directional VE MRI was performed without acceleration. This results in a lower signal-to-noise-ratio for 3D three-directional VE MRI with retrospective valve tracking. However, Westenberg et al. reported previously that the lower signal-to-noise ratio did not hamper accurate image analysis for assessment of flow across the mitral valve (7). Furthermore, acceleration with Echo Planar Imaging can be switched off although it may result in longer scan times. Both with 3D three-directional VE MRI with retrospective valve tracking and 2D one-directional VE MRI, a limited temporal sampling resolution of the flow rate graph was obtained (i.e. 30 phases reconstructed per cardiac cycle; actual temporal resolution is determined by the number of velocity encoding and velocity-compensated acquisitions and the repetition time: for 2D one-directional VE MRI, temporal resolution was $2 \times TR = 18\text{ms}$ while for 3D three-directional VE MRI with retrospec-

tive valve tracking, temporal resolution was $4 \times TR = 30\text{ms}$). Temporal resolution for sampling transmitral velocity graphs with echocardiography is far superior (i.e. 0.8 ms). Also, the spatial resolution of the sampling volume of echocardiography is superior to MRI. This potentially limits accurate depiction of the true maximum E filling rate and A filling rate as well as the peak acceleration and deceleration rate in the flow rate graphs. Although the resolution of echocardiography cannot be reached, increased temporal and spatial sampling resolution in both MRI scan sequences is feasible, however, at the penalty of additional acquisition time and image processing time.

Finally, the true spatial resolution (i.e. $2.9 \times 3.8\text{ mm}$) used in 3D VE MRI may also have hampered a clear visualization of the mitral valvular border because of partial volume effects. However, the spatial resolution used with 3D three-directional VE MRI was comparable to the resolution used on 2D one-directional VE MRI (i.e. $2.7 \times 3.4\text{ mm}$).

In conclusion, 3D three-directional VE MRI with retrospective valve tracking is significantly different from 2D one-directional VE MRI in assessing indices describing the transmitral flow rate graph. Furthermore, this 3D VE MRI-approach is superior to 2D one-directional VE MRI in characterizing diastolic filling pattern when compared to Doppler echocardiography as independent standard method.

Measurement of transmitral flow with 3D three-directional VE MRI with retrospective valve tracking seems to be particularly promising for quantitative LV diastolic function analyses and further investigation of LV diastolic function with this 3D VE MRI-technique is now warranted.

References

1. Gaasch WH, Zile MR. Left ventricular diastolic dysfunction and diastolic heart failure. *Annu Rev Med* 2004;55:373-394.
2. Aurigemma GP, Gaasch WH. Clinical practice. Diastolic heart failure. *N Engl J Med* 2004;351:1097-1105.
3. Xie GY, Berk MR, Smith MD, Gurley JC, Demaria AN. Prognostic value of Doppler transmitral flow patterns in patients with congestive heart failure. *J Am Coll Cardiol* 1994;24:132-139.
4. Karwatowski SP, Brecker SJ, Yang GZ, Firmin DN, Sutton MS, Underwood SR. Mitral valve flow measured with cine MR velocity mapping in patients with ischemic heart disease: comparison with Doppler echocardiography. *J Magn Reson Imaging* 1995;5:89-92.
5. Mohiaddin RH, Gatehouse PD, Henien M, Firmin DN. Cine MR Fourier velocimetry of blood flow through cardiac valves: comparison with Doppler echocardiography. *J Magn Reson Imaging* 1997;7:657-663.
6. Paelinck BP. Feasibility of tissue magnetic resonance imaging: A pilot study in comparison with tissue Doppler imaging and invasive measurement. *J Am Coll Cardiol* 2005;45:1109-1116.
7. Westenberg JJ, Roes SD, Ajmone MN, et al. Mitral valve and tricuspid valve blood flow: accurate quantification with 3D velocity-encoded MR imaging with retrospective valve tracking. *Radiology* 2008;249:792-800.
8. Roes SD, Hammer S, van der Geest RJ, et al. Flow assessment through four heart valves simultaneously using 3-dimensional 3-directional velocity-encoded magnetic resonance imaging with retrospective valve tracking in healthy volunteers and patients with valvular regurgitation. *Invest Radiol* 2009;44:669-675.
9. Kayser HW, Stoel BC, Van der Wall EE, van der Geest RJ, de Roos A. MR velocity mapping of tricuspid flow: correction for through-plane motion. *J Magn Reson Imaging* 1997;7:669-673.
10. Paelinck BP, Lamb HJ, Bax JJ, Van der Wall EE, de Roos A. Assessment of diastolic function by cardiovascular magnetic resonance. *Am Heart J* 2002;144:198-205.
11. Marsan NA, Westenberg JJ, Tops LF, et al. Comparison between tissue Doppler imaging and velocity-encoded magnetic resonance imaging for measurement of myocardial velocities, assessment of left ventricular dyssynchrony, and estimation of left ventricular filling pressures in patients with ischemic cardiomyopathy. *Am J Cardiol* 2008;102:1366-1372.
12. van der Geest RJ, de Roos A, van der Wall EE, Reiber JH. Quantitative analysis of cardiovascular MR images. *Int J Card Imaging* 1997;13:247-258.
13. Lamb HJ, Beyerbach HP, van der Laarse A, et al. Diastolic dysfunction in hypertensive heart disease is associated with altered myocardial metabolism. *Circulation* 1999;99:2261-2267.
14. Lang RM, Bierig M, Devereux RB, et al. Recommendations for chamber quantification: a report from the American Society of Echocardiography's Guidelines and Standards Committee and the Chamber Quantification Writing Group, developed in conjunction with the European Association of Echocardiography, a branch of the European Society of Cardiology. *J Am Soc Echocardiogr* 2005;18:1440-1463.
15. Nagueh SF, Appleton CP, Gillebert TC, et al. Recommendations for the evaluation of left ventricular diastolic function by echocardiography. *J Am Soc Echocardiogr* 2009;22:107-133.
16. Lester SJ, Tajik AJ, Nishimura RA, Oh JK, Khandheria BK, Seward JB. Unlocking the mysteries of diastolic function: deciphering the Rosetta Stone 10 years later. *J Am Coll Cardiol* 2008;51:679-689.
17. Bland JM, Altman DG. Statistical methods for assessing agreement between two methods of clinical measurement. *Lancet* 1986;1:307-310.

18. Ludbrook J. Statistical techniques for comparing measurers and methods of measurement: a critical review. *Clin Exp Pharmacol Physiol* 2002;29:527-536.
19. Roes D, Alizadeh DR, Westenberg JJ, et al. Assessment of Aortic Pulse Wave Velocity and Cardiac Diastolic Function in Subjects With and Without the Metabolic Syndrome. *Diabetes Care* 2008;31:1442-1444.
20. Garcia MJ, Thomas JD, Klein AL. New Doppler echocardiographic applications for the study of diastolic function. *J Am Coll Cardiol* 1998;32:865-875.