



Universiteit  
Leiden  
The Netherlands

## Soft tissue tumors: perfusion and diffusion-weighted MR imaging

Rijswijk, Catharina van

### Citation

Rijswijk, C. van. (2005, June 30). *Soft tissue tumors: perfusion and diffusion-weighted MR imaging*. Retrieved from <https://hdl.handle.net/1887/4284>

Version: Corrected Publisher's Version

License: [Licence agreement concerning inclusion of doctoral thesis in the Institutional Repository of the University of Leiden](#)

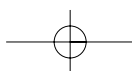
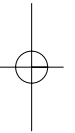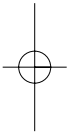
Downloaded from: <https://hdl.handle.net/1887/4284>

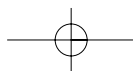
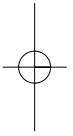
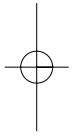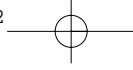
**Note:** To cite this publication please use the final published version (if applicable).



# **Soft tissue tumors:**

## **perfusion and diffusion-weighted MR imaging**







# **Soft tissue tumors: perfusion and diffusion-weighted MR imaging**

PROEFSCHRIFT

ter verkrijging van  
de graad Doctor aan de Universiteit Leiden,  
op gezag van de Rector Magnificus Dr. D.D. Breimer,  
hoogleraar in de faculteit der Wiskunde en  
Natuurwetenschappen en die der Geneeskunde,  
volgens besluit van het College voor Promoties  
te verdedigen op donderdag 30 juni 2005  
te klokke 14:15 uur

door

Catharina Stoffelina Pieterella van Rijswijk  
geboren te Haarlem  
in 1973

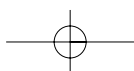
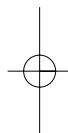
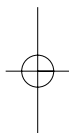


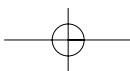
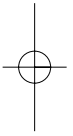
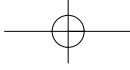
## **PROMOTIECOMMISSIE**

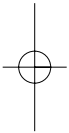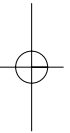
**Promotores:** Prof. dr. J.L. Bloem  
Prof. dr. A.H.M. Taminiau

**Referent:** Prof. dr. A.M. De Schepper (Universiteit Antwerpen, België)

**Overige leden:** Prof. dr. P.C.W. Hogendoorn  
Prof. dr. R.A.E.M. Tollenaar  
Dr. F. van Coevorden  
Prof. dr. B.B.R. Kroon  
Dr. M.J.A. Smid-Geirnaerd







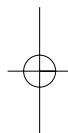
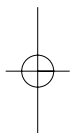
© C.S.P. van Rijswijk, Leiden, The Netherlands. All rights preserved. No parts of this publication may be reproduced or transmitted in any form or by any means, electronic or mechanical, including photocopy, recording, or any information storage and retrieval system, without prior written permission of the author.

Printed by De Kempnaer, Oegstgeest.

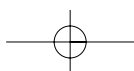
ISBN 9-9019576-9

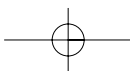
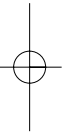
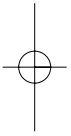
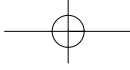
Publication of this thesis was financially supported by Stichting Imago and Schering Nederland B.V.





*Aan mijn ouders*





**CONTENTS**

Chapter 1	General introduction	11
Chapter 2	Imaging techniques for soft tissue sarcomas: emphasis on the role in differential diagnosis, tumor grading and monitoring therapy effects	17
Chapter 3	Synovial sarcoma: dynamic contrast-enhanced MR imaging features	29
Chapter 4	Value of dynamic contrast-enhanced MR imaging in diagnosing and classifying peripheral vascular malformations	41
Chapter 5	Soft tissue tumors: value of static and dynamic Gd-DTPA-enhanced MR imaging in predicting malignancy	59
Chapter 6	Diffusion-weighted MR imaging in the characterization of soft tissue tumors	85
Chapter 7	Dynamic contrast-enhanced MR imaging in monitoring response to isolated limb perfusion in high-grade soft tissue sarcoma - preliminary results	99
Chapter 8	Surveillance imaging of soft tissue sarcoma and aggressive fibromatosis	118
Chapter 9	Summary and General conclusion Samenvatting en Algemene conclusie Curriculum Vitae	135

