



Universiteit  
Leiden

The Netherlands

## Acute myocardial infarction treatment : from prehospital care to secondary prevention

Atary, J.Z.

### Citation

Atary, J. Z. (2011, September 22). *Acute myocardial infarction treatment : from prehospital care to secondary prevention*. Retrieved from <https://hdl.handle.net/1887/17856>

Version: Corrected Publisher's Version

License: [Licence agreement concerning inclusion of doctoral thesis in the Institutional Repository of the University of Leiden](#)

Downloaded from: <https://hdl.handle.net/1887/17856>

**Note:** To cite this publication please use the final published version (if applicable).

# Impact of sirolimus-eluting stent implantation compared to bare-metal stent implantation for acute myocardial infarction on coronary plaque composition at 9 months follow-up: A virtual histology intravascular ultrasound analysis. Results from the Leiden MISSION! intervention study.

Jael Z. Atary<sup>1</sup>, Sandrin C. Bergheanu<sup>1</sup>, Bas L. van der Hoeven<sup>1</sup>, Douwe E. Atsma<sup>1</sup>, Marianne Bootsma<sup>1</sup>, Frank van der Kley<sup>1</sup>, Katja Zeppenfeld<sup>1</sup>, J. Wouter Jukema<sup>1,2</sup>, Martin J. Schalij<sup>1</sup>

<sup>1</sup>Department of cardiology, Leiden University Medical Center, Leiden, the Netherlands.

<sup>2</sup>Eindhoven Laboratory for Experimental Vascular Medicine, Leiden University Medical Center, the Netherlands.



**ABBREVIATIONS**

AMI	Acute myocardial infarction
BMS	Bare-metal stent
CRP	C-reactive protein
CSA	Cross-sectional area
EEM	External elastic membrane
IVUS	Intravascular ultrasound
Mean LD	Mean lumen diameter
MLD	Minimum lumen diameter
PTCA	Percutaneous transluminal coronary angioplasty
QCA	Quantitative Coronary Angiography
SES	Sirolimus-eluting stent
STEMI	ST-segment elevation myocardial infarction
VH-IVUS	Virtual histology intravascular ultrasound

## ABSTRACT

### Aims

To evaluate effects of sirolimus-eluting stents (SES) compared to bare-metal stents (BMS) at stent edges in patients with acute myocardial infarction (AMI).

### Methods and Results

Clinical, angiographic, intravascular ultrasound (IVUS) and virtual histology (VH)-IVUS results were obtained and analyzed in 20 SES and 20 BMS AMI patients at the index procedure and at 9 months follow-up. Quantitative angiography and IVUS showed a trend toward decreases in mean lumen diameter, vessel volume, minimum lumen area and mean lumen area at both stent edges of BMS, and at the proximal edge of SES. At the distal stent edge, a significant difference between BMS and SES treated patients in mean lumen area was found ( $\Delta -0.8 \pm 1.6 \text{mm}^2$  versus  $\Delta 0.2 \pm 0.8 \text{mm}^2$  respectively,  $p = 0.04$ ). Furthermore, in-stent SES had a larger lumen volume (SES:  $167.7 \pm 59.2 \text{mm}^3$  versus BMS:  $125.1 \pm 43.8 \text{mm}^3$ ;  $p = 0.02$ ) and less neointima volume ( $7.3 \pm 9.1 \text{mm}^3$  versus  $53.2 \pm 35.1 \text{mm}^3$ ;  $p < 0.001$ ). Neither SES nor BMS demonstrated a significant effect on plaque composition at follow-up VH-IVUS analysis.

### Conclusion

A significant difference between SES and BMS treated patients was observed with respect to mean lumen diameter distal to the stented segment which suggests a downstream effect of sirolimus elution.

## INTRODUCTION

The treatment of patients with acute myocardial infarction (AMI) changed significantly over the last decades. Early pharmacological and more recently mechanical reperfusion strategies improved the prognosis of AMI patients further supported by optimal medical treatment (including antiplatelet therapy, ACE inhibitors, betablockers and statins) and life style changes in the chronic phase after the acute event. Procedural outcome also improved due to improved operator experience, continuous refinement of catheter and balloon technology, and the introduction of intracoronary stents. More recently drug eluting stents (DES) have been introduced. Although the efficacy of DES is proven in patients with stable coronary artery disease the role of DES in AMI patients is still under debate.<sup>1-4</sup> Despite the positive effects of DES on restenosis, the increased risk of subacute thrombosis tempered the initial enthusiasm as subacute stent thrombosis is a devastating event associated with high mortality rates and myocardial infarction.<sup>5-9</sup> In AMI patients the initial event is caused by disruption or erosion of a vulnerable plaque<sup>10-12</sup> leading to acute thrombosis. The increased risk of stent thrombosis associated with DES is caused by incomplete/delayed neointimal coverage and may be prevented to some extent in most patients with stable coronary artery disease by prolonged dual antiplatelet therapy. Although after implantation of a stent the ruptured plaque will be covered it is unclear what happens proximal and distal to the stent segments. Some studies suggest that the eluted drug in case of a DES may not only have an effect on the stented segment but also on adjacent segments.<sup>13-15</sup> It is therefore of interest to study these segments during the initial procedure and during follow-up. In this study we evaluated the effects of DES compared to bare-metal stents (BMS) on the proximal and distal segments using Intravascular Ultrasound imaging (IVUS) in AMI patients at baseline and at 9 months follow-up. Although IVUS allows cross-sectional imaging of coronary arteries and provides a comprehensive assessment of the atherosclerotic plaque, it cannot provide detailed data about its tissue components. Detecting changes in tissue components may increase our comprehension of in vivo development of potentially vulnerable plaque. Therefore, additionally Virtual histology (VH-) IVUS using spectral analysis of the radiofrequency ultrasound backscatter signals to analyze plaque composition and morphology was used. VH-IVUS allows identification of four different components of atherosclerotic plaques: fibrous, fibro-fatty, dense calcium, and necrotic core.<sup>16</sup>

## METHODS

### Study design and population

Patients for this substudy were selected from the randomized MISSION! intervention study (Current Controlled Trials number, ISRCTN62825862,<sup>4</sup>). The original MISSION! study was

designed to compare the outcome of the sirolimus coated Cypher stent (Cypher Select™, Cordis Corp., Miami Lakes, Florida) with the bare-metal Vision stent (Multilink Vision™, Guidant Corp., Indianapolis, Indiana) in patients with AMI.<sup>4</sup> The study was approved by the institutional ethical committee. Written informed consent was obtained from all patients before enrollment and before the follow-up catheterization at 9 months. The study protocol, inclusion and exclusion criteria, endpoint definition and main outcomes of the study were published previously.<sup>4</sup>

For this substudy, a group of consecutive patients were included for whom not only clinical, angiographic and IVUS data were performed, but for which also Virtual Histology analysis was performed from both the index procedure and the 9 months follow-up study. Throughout the study period all patients were treated according to the institutional STEMI protocol which included standardized out-patient follow-up.<sup>17</sup> In brief, all patients had symptoms of STEMI that started <9 hours before arrival at the catheterization laboratory and an ECG that demonstrated a STEMI (ST segment elevation  $\geq 0.2$ mV in  $\geq 2$  contiguous precordial leads [V1-V4], or  $\geq 0.1$ mV ST elevation in other leads, or a new left bundle branch block).

Key exclusion criteria were age <18 years or >80 years; the presence of a left main lesion of  $\geq 50\%$  stenosis; triple vessel disease, defined as  $\geq 50\%$  stenosis in three major epicardial vessels; previous percutaneous coronary intervention or bypass grafting of the culprit vessel; failed thrombolytic therapy for the index infarction; reference diameter of the culprit lesion of less than 2.25mm or larger than 3.75mm; and lesion length  $\geq 24$ mm.

### Procedure protocol

Before the index procedure all patients received 300mg of aspirin, 300-600mg of clopidogrel, and an intravenous bolus of abciximab (25 $\mu$ g/kg), followed by a continuous infusion of 100 $\mu$ g/kg for 12 hours. At the start of the procedure 5000IU of heparin was administered. Coronary lesions were treated according to current interventional practice. If more than one stent was required, the additional stent was of the same assigned study type.

After intervention IVUS imaging was performed to document angiographic result. Each angiogram and ultrasound sequence was preceded by 200-300 $\mu$ g of intracoronary nitroglycerin.

After the procedure aspirin (100mg/day) was prescribed indefinitely and clopidogrel (75mg/day) for 12 months. During follow-up, patients were treated with beta-blockers, statins and ACE-inhibitors or ATII-blockers, according to current guidelines.<sup>17</sup> Patients were seen at the out-patient clinic at 30 days, 3, 6, and 12 months. Follow-up angiography and (VH-) IVUS image acquisition was performed at 9 months follow-up.

## Quantitative coronary angiography (QCA)

Coronary angiograms obtained at baseline and at 9 months follow-up were digitally recorded and analyzed blinded to the assigned treatment.

The analysis was performed using automated edge-detection software (CMS version 6.0, Medis Medical Imaging Systems, Leiden, The Netherlands) at a single projection showing the most severe stenosis. The same projection was used at follow-up. The proximal and distal edges were evaluated up to 5mm from the stent.

## IVUS analysis

IVUS imaging was performed with motorized pull-back (0.5mm/s) starting at least 10mm distal to the stent, ending at the coronary ostium. A 2.9F 20MHz catheter and a dedicated IVUS console (Eagle Eye, Volcano Corp. Rancho Cordova, California, USA) were used.<sup>18</sup> Before imaging, 200-300µg of intracoronary nitroglycerin were administered. Analysis was performed by analysts that were blinded to the assigned treatment using customized software (QCU-CMS 4.14, Medis, Leiden, The Netherlands) for analysis of the quantitative grayscale data.

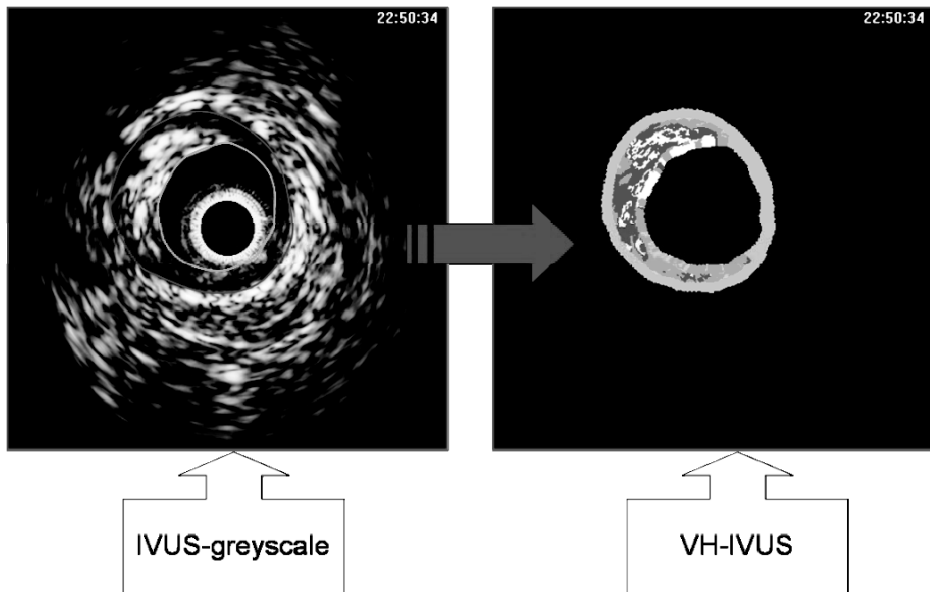
External elastic membrane (EEM) cross sectional area (CSA) and lumen CSA of segments 5mm proximal and distal to the stent were determined per frame and vessel volume, mean lumen area and minimal lumen area for these segments were compared to the same parameters at follow-up.

## Virtual histology analysis

VH images were generated simultaneously during motorized pull-back (figure 1). Images were acquired at every R-peak during continuous ECG registration. Data were stored digitally on CD for off-line analysis. Atherosclerotic coronary lesions were characterized by classification trees based on mathematical autoregressive spectral analysis of IVUS backscattered data (pcVH software version 2.2, Volcano Therapeutics). Fibrous areas were marked in green, fibro-fatty in yellow, dense calcium in white and necrotic core in red on the reconstructed color-coded tissue map. The area and volumes of each plaque component were calculated automatically by the pcVH software. PcVH analysis software is commercially available image analysis software developed by Volcano Therapeutics and the technique has been validated in past histopathological validation studies of VH-IVUS.<sup>19,20</sup>

Measurements were made for the region of interest, which was defined as the segment of minimal 5mm to maximal 10mm distal and proximal to the stented segment. This range was chosen instead of the conventional 5mm distance because: 1) it was unclear, assuming that there would be a downstream effect of the drug on plaque composition, how far the effect would reach and 2) as it was expected that these effects were likely to be small, it was considered preferable to include as much potentially affected longitudinal distance as





**Figure 1.** Illustration of creating an image with virtual histology intravascular ultrasound. IVUS = intravascular ultrasound; VH-IVUS = virtual histology intravascular ultrasound.

possible. Catheterization images of the index procedure and of 9 months follow-up were analyzed side-by-side to ensure that the same segments were studied.

Although the volumetric analysis of the software could not be adjusted for repeated frames (implicating that the volume analysis of the same segment at different points of time could slightly differ) this problem was solved by using relative plaque volumes for final analysis (percentage of total plaque). Repeated frames were caused by the catheter getting stuck during pullback. In the 40 cases presented in this study only a small number of such frames were observed. Nevertheless, to minimize their influence on results for absolute plaque areas, repeated frames were ignored during this analysis.

### Statistical analysis

Continuous data are reported throughout this text and in the tables as mean  $\pm$  standard deviation. Evenly distributed continuous data were analyzed by utilizing the independent sample t-test. Unevenly distributed continuous data were analyzed using an equivalent non-parametric test and the Mann-Whitney U test. For comparison to follow-up, analysis of continuous data at different points in time was performed by the paired Student's t-test. Categorical data are summarized as proportions and were compared with Pearson's  $\chi^2$  -test or Fisher exact test in case of one or more cells in the contingency table with expectation less than 5, as appropriate. All tests were two-sided, a p-value of  $<0.05$  was considered significant.

## RESULTS

Forty patients who received a SES (n=20) or BMS (n=20) during a primary PTCA were included in this substudy. There were no significant differences in baseline patient characteristics between the two patient groups (Table 1).

**Table 1.** Baseline characteristics.

	BMS (n=20)	DES (n=20)	p-value
Male	18 (90)	13 (65)	0.130
Mean age	62 (41-79)	59 (29-75)	0.418
Cardiovascular risk factors:			
Hypertension	5 (25)	7 (35)	0.731
Hyperlipidemia	5 (25)	4 (20)	1.000
Smoking	12 (60)	15 (75)	0.501
Diabetes Mellitus	1 (5)	5 (25)	0.184
Prior MI	3 (15)	1 (5)	0.598
Family History of CAD	8 (40)	13 (65)	0.205
Medication at discharge:			
Aspirin	20 (100)	20 (100)	1.000
Statin	20 (100)	20 (100)	1.000
$\beta$ -Blocker	20 (100)	20 (100)	1.000
Clopidogrel	20 (100)	20 (100)	1.000
ACE/AT2-inhibitor	19 (95)	20 (100)	1.000
Anticoagulant	0	0	
Medication at 12 months:			
Aspirin	20 (100)	17 (85)	0.230
Statin	20 (100)	20 (100)	1.000
$\beta$ -Blocker	19 (95)	19 (95)	1.000
Clopidogrel	20 (100)	17 (85)	0.230
ACE/AT2-inhibitor	19 (95)	19 (95)	1.000
Anticoagulant	0	3 (15)	0.230
Target vessel:			
LAD	9 (45)	11 (55)	0.752
RCA	8 (40)	2 (10)	0.065
LCX	3 (15)	7 (35)	0.273
No. of vessels diseased:			
1	9 (45)	8 (40)	1.000
2	9 (45)	10 (50)	1.000
3	2 (10)	2 (10)	1.000

Values are expressed as number (%) or as age (min-max).

BMS = bare-metal stent; CAD = coronary artery disease; MI = myocardial infarction; LAD = left anterior descending artery; RCA = right coronary artery; LCX = left circumflex artery; SES = sirolimus-eluting stent.

Hyperlipidemia= Total cholesterol  $\geq$ 190 mg/dl or previous pharmacological treatment.

Hypertension = Blood pressure  $\geq$ 140/90 mm Hg or previous pharmacological treatment.

## Angiographic results

Index-procedure and follow-up QCA-results for minimum lumen area and mean lumen diameters are reported in table 2. In BMS patients both minimum and mean lumen diameter decreased at both sides of the stent at follow-up though this did not reach statistical significance at the distal stent edges (MLD proximal edge: from  $2.76 \pm 0.42\text{mm}$  to  $2.62 \pm 0.46\text{mm}$ ;  $p = 0.03$  and Mean LD proximal edge: from  $3.05 \pm 0.48\text{mm}$  to  $2.94 \pm 0.46\text{mm}$ ;  $p = 0.03$ , MLD distal edge: from  $2.43 \pm 0.48\text{mm}$  to  $2.21 \pm 0.67\text{mm}$ ;  $p = 0.10$  and Mean LD from  $2.65 \pm 0.55\text{mm}$  to  $2.48 \pm 0.69\text{mm}$ ;  $p = 0.19$ ).

In SES patients a similar (although non-significant) decline in lumen area was observed at the proximal stent edge, the distal MLD and Mean LD however tended to increase (MLD) or remained unchanged (Mean LD) during follow-up (MLD proximal edge: from  $2.74 \pm 0.37\text{mm}$  to  $2.68 \pm 0.46\text{mm}$ ;  $p = 0.40$  and Mean LD from  $3.04 \pm 0.57\text{mm}$  to  $2.94 \pm 0.57\text{mm}$ ;  $p = 0.09$ , MLD distal edge: from  $2.38 \pm 0.39\text{mm}$  to  $2.44 \pm 0.53\text{mm}$ ;  $p = 0.41$  and Mean LD from  $2.61 \pm 0.37\text{mm}$  to  $2.61 \pm 0.5\text{mm}$ ;  $p = 0.97$ ).

**Table 2.** Results of Quantitative Coronary Angiography at baseline and at follow-up.

	BMS			SES		
	Baseline	Follow-up	p-value	Baseline	Follow-up	p-value
Proximal stent edge:						
Minimal lumen diameter (mm)	$2.8 \pm 0.4$	$2.6 \pm 0.5$	0.03*	$2.7 \pm 0.4$	$2.7 \pm 0.5$	0.40
Mean lumen diameter (mm)	$3.1 \pm 0.5$	$2.9 \pm 0.5$	0.03*	$3.0 \pm 0.6$	$2.9 \pm 0.6$	0.09
Distal stent edge:						
Minimal lumen diameter (mm)	$2.4 \pm 0.5$	$2.2 \pm 0.7$	0.10	$2.4 \pm 0.4$	$2.4 \pm 0.5$	0.41
Mean lumen diameter (mm)	$2.7 \pm 0.6$	$2.5 \pm 0.7$	0.19	$2.6 \pm 0.4$	$2.6 \pm 0.5$	0.97

Data expressed as lumen diameters (mm)  $\pm$  standard deviation. \* $p < 0.05$

BMS = bare-metal stent; SES = sirolimus-eluting stent.

## IVUS grayscale results

Quantitative post procedural and follow-up IVUS data are summarized in tables 3 and 4. At the proximal stent edge, vessel volume and lumen areas decreased in both BMS and SES patients at 9 months follow-up (BMS: -3.6% and -0.5% and SES: -7.2% and -8.2%). The mean lumen area decreases significantly in the SES group at the proximal stent edges ( $p = 0.03$ ).

At follow-up, vessel volume and mean lumen area of the distal stent edge of the BMS group tended to decline (overall decrease of -5.0% and -6.3% respectively,  $p = \text{ns}$ ), while they increased in the SES group (vessel volume increase of 1.5% and mean lumen area increase of 3.4%,  $p = \text{ns}$ ). There were no significant differences between BMS and SES groups in vessel volume and mean lumen area changes except for mean lumen area at the distal stent edge ( $\Delta -0.8 \pm 1.6\text{mm}^2$  versus  $\Delta 0.2 \pm 0.8\text{mm}^2$  respectively,  $p = 0.04$ ; table 4). Within the stented segment however, the SES group demonstrated a significantly larger

**Table 3.** Results of Coronary Ultrasound at stent edges at baseline and at follow-up

	BMS			SES		
	Baseline	Follow-up	p-value	Baseline	Follow-up	p-value
Proximal stent edge:						
Vessel volume (mm <sup>3</sup> )	83.2 ± 27.6	80.7 ± 25.6	0.54	76.0 ± 34.5	66.7 ± 37.9	0.22
Minimal lumen area (mm <sup>2</sup> )	6.9 ± 2.7	6.3 ± 2.5	0.14	6.5 ± 1.7	6.6 ± 1.6	0.82
Mean lumen area (mm <sup>2</sup> )	8.5 ± 3.1	8.0 ± 3.6	0.24	8.6 ± 2.3	7.9 ± 2.3	0.03*
Distal stent edge:						
Vessel volume (mm <sup>3</sup> )	72.6 ± 29.7	67.1 ± 26.0	0.09	54.3 ± 22.2	56.1 ± 20.3	0.21
Minimal lumen area (mm <sup>2</sup> )	6.3 ± 2.7	5.7 ± 2.5	0.11	5.3 ± 1.7	5.5 ± 1.7	0.52
Mean lumen area (mm <sup>2</sup> )	7.8 ± 3.5	7.0 ± 3.0	0.07	6.5 ± 1.6	6.7 ± 1.7	0.34

Data expressed as volumes (mm<sup>3</sup>) or as areas (mm<sup>2</sup>) ± standard deviation.

\*p= <0.05.

Abbreviations as in table 2.

**Table 4.** Results of Coronary Ultrasound for the stented segment and stent edges at 9 months follow-up

	BMS	SES	p-value
Stented length	24.5 ± 7.0	23.4 ± 7.1	0.65
Mean number of stents	1.4 ± 0.5	1.3 ± 0.5	0.42
Stented segment			
Area (mm <sup>2</sup> )			
Minimal stent area	6.1 ± 1.1	6.0 ± 1.5	0.72
Mean stent area	7.3 ± 1.0	7.5 ± 1.7	0.59
Volume (mm <sup>3</sup> )			
Stent volume	178.4 ± 56.3	175.1 ± 59.0	0.87
Lumen volume	125.1 ± 43.8	167.7 ± 59.2	0.02*
Neointimal volume	53.2 ± 35.1	7.3 ± 9.1	<0.001*
Percentage neointimal volume	30.0 ± 14.8	4.6 ± 5.6	<0.001*
Proximal stent edge:			
Δ Vessel volume (mm <sup>3</sup> )	-2.5 ± 14.7	-9.4 ± 27.1	0.42
Δ Minimal lumen area (mm <sup>2</sup> )	-0.6 ± 1.4	0.1 ± 1.1	0.17
Δ Mean lumen area (mm <sup>2</sup> )	-0.5 ± 1.4	-0.7 ± 1.1	0.66
Distal stent edge			
Δ Vessel volume (mm <sup>3</sup> )	-5.6 ± 12.5	0.5 ± 3.9	0.08
Δ Minimal lumen area (mm <sup>2</sup> )	-0.6 ± 1.5	0.2 ± 1.3	0.09
Δ Mean lumen area (mm <sup>2</sup> )	-0.8 ± 1.6	0.2 ± 0.8	0.04*

Data expressed as volumes (mm<sup>3</sup>) or as areas (mm<sup>2</sup>) ± standard deviation.

\*p= <0.05.

Δ = alteration in volume (mm<sup>3</sup>) or area (mm<sup>2</sup>) from baseline.

Abbreviations as in table 2.

lumen volume (SES:  $167.7 \pm 59.2 \text{mm}^3$  versus BMS:  $125.1 \pm 43.8 \text{mm}^3$ ;  $p = 0.02$ ) at follow-up. Also in SES, less neointima volume ( $7.3 \pm 9.1 \text{mm}^3$  versus  $53.2 \pm 35.1 \text{mm}^3$ ;  $p < 0.001$ ) and lower percentage neointimal volume ( $4.6 \pm 5.6\%$  versus  $30.0 \pm 14.8\%$ ;  $p < 0.001$ ) were found at follow-up when compared to BMS.

**Table 5.** Results of Virtual Histology Analysis for relative plaque volume per component at baseline and at follow-up.

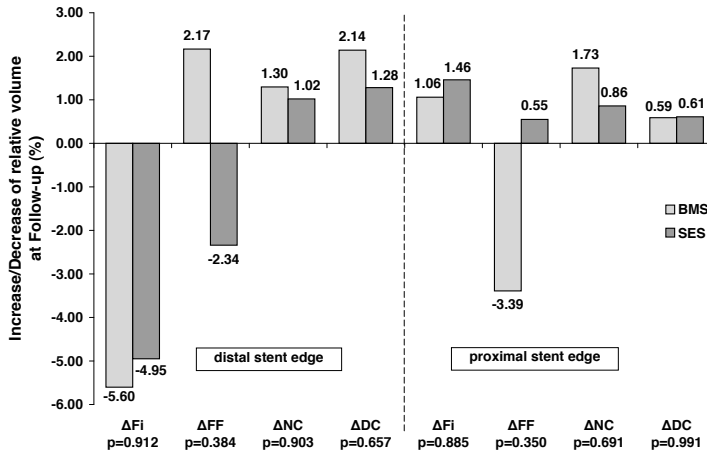
	BMS			SES		
	Baseline	Follow-up	p-value	Baseline	Follow-up	p-value
Proximal segment						
Fibrous (%)	$56.3 \pm 7.2$	$57.3 \pm 7.3$	0.56	$57.0 \pm 8.9$	$58.4 \pm 7.7$	0.49
Fibro-fatty (%)	$31.1 \pm 12.4$	$27.7 \pm 8.0$	0.18	$31.0 \pm 15.4$	$31.6 \pm 14.9$	0.87
Necrotic core (%)	$9.0 \pm 7.8$	$10.7 \pm 5.2$	0.36	$8.4 \pm 7.3$	$9.2 \pm 7.9$	0.46
Dense Calcium (%)	$3.6 \pm 3.4$	$4.2 \pm 3.3$	0.44	$3.7 \pm 4.5$	$4.3 \pm 4.8$	0.40
Distal Segment						
Fibrous (%)	$62.8 \pm 9.7$	$57.2 \pm 12.4$	0.05*	$57.7 \pm 20.7$	$52.8 \pm 24.1$	0.35
Fibro-fatty (%)	$25.0 \pm 14.3$	$27.2 \pm 12.8$	0.41	$25.0 \pm 12.9$	$22.7 \pm 13.9$	0.60
Necrotic core (%)	$8.9 \pm 6.2$	$10.2 \pm 8.4$	0.40	$5.7 \pm 5.3$	$6.7 \pm 6.2$	0.55
Dense Calcium (%)	$3.3 \pm 3.9$	$5.5 \pm 10.5$	0.25	$1.6 \pm 1.8$	$2.9 \pm 3.6$	0.09

Data expressed as relative proportions of plaque volume (%)  $\pm$  standard deviation. \* $p = < 0.05$   
Abbreviations as in table 2.

## Virtual Histology results

Post procedural and follow-up VH-IVUS results for relative volumes of the different plaque components are reported in table 5. The relative increase and decrease of each plaque component volume is illustrated in figure 2. Except for a significant decrease of the fibrous plaque component volume of the distal edge segment of BMS ( $p = 0.05$ ), plaque composition did not change significantly in either group. The data for mean areas at baseline and follow-up are summarized in table 6 and the relative increase/decrease of mean area of every plaque component at follow-up is depicted in figure 3. Again, no significant difference in mean area of the four plaque components is discernable between follow-up and baseline in either group.

As it was considered possible that by using the calculated means of data from the edge segments any differences between baseline and follow-up in both stent type groups may have been obscured, it was decided to perform an additional VH-IVUS analysis of the frame just distal from the stent edge at baseline and at follow-up for all 40 cases. However, this analysis too revealed no significant differences for plaque composition areas between post-intervention and follow-up and between the two stent types (not shown).



**Figure 2.** Relative volume changes over 9 months time ( $\Delta\%$ ).

Measurements for BMS are set out next to SES. P-values are reported to indicate statistical significance of differences in plaque component changes between BMS and SES. None are significant.

BMS = Bare-metal stents; SES = Sirolimus-eluting stents;  $\Delta$  = change in relative volume of mentioned plaque component; Fi = fibrous; FF = fibro-fatty; DC = dense calcium; NC = necrotic core.

**Table 6.** Results of Virtual Histology Analysis for relative plaque area per component at baseline and at follow-up

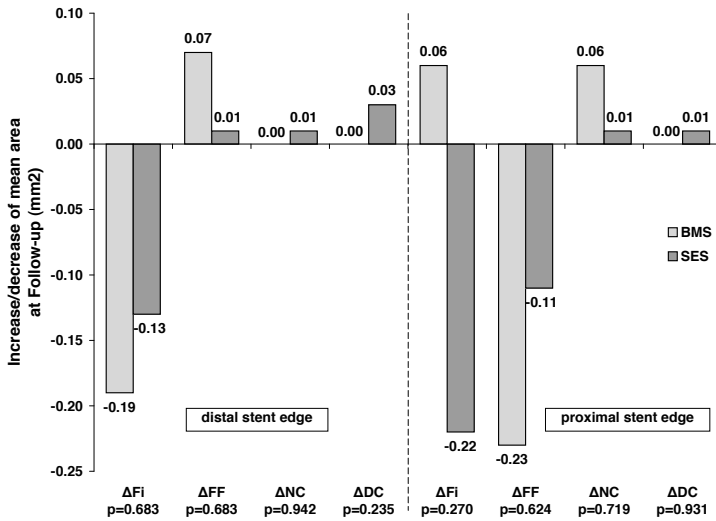
	Bare-metal stent			SES		
	Baseline	Follow-up	p-value	Baseline	Follow-up	p-value
Proximal segment						
Fibrous (mm <sup>2</sup> )	3.2 ± 1.3	3.2 ± 1.3	0.76	3.6 ± 2.0	3.4 ± 1.8	0.15
Fibro-fatty (mm <sup>2</sup> )	1.7 ± 1.1	1.5 ± 0.7	0.27	1.6 ± 0.9	1.5 ± 1.0	0.43
Necrotic core (mm <sup>2</sup> )	0.6 ± 0.6	0.6 ± 0.4	0.64	0.6 ± 0.7	0.7 ± 0.8	0.94
Dense Calcium (mm <sup>2</sup> )	0.3 ± 0.3	0.3 ± 0.3	0.93	0.3 ± 0.4	0.3 ± 0.4	0.81
Distal Segment						
Fibrous (mm <sup>2</sup> )	2.1 ± 1.1	1.9 ± 1.0	0.06	1.0 ± 1.5	0.9 ± 1.1	0.27
Fibro-fatty (mm <sup>2</sup> )	0.9 ± 0.6	1.0 ± 0.7	0.56	0.4 ± 0.5	0.4 ± 0.7	0.89
Necrotic core (mm <sup>2</sup> )	0.3 ± 0.2	0.3 ± 0.3	0.96	0.1 ± 0.2	0.1 ± 0.3	0.68
Dense Calcium (mm <sup>2</sup> )	0.1 ± 0.2	0.1 ± 0.2	0.92	0.1 ± 0.1	0.1 ± 0.2	0.16

Data expressed as mean areas of the plaque components (mm<sup>2</sup>) ± standard deviation.

Abbreviations as in table 2.

## Clinical outcome

One BMS patient and one SES patient underwent a target lesion revascularization due to restenosis. No patient died during the follow-up period of 12 months. Three BMS patients and two SES patients underwent revascularization of a vessel other than the culprit vessel at different points of time within a 12 months follow-up period. Adherence to medication was high (table 1), no sub-acute thrombosis was observed.



**Figure 3.** Mean area changes over 9 months time.

Measurements for BMS are set out next to SES. P-values are reported to indicate statistical significance of differences in plaque component changes between BMS and SES. None are significant.

$\Delta$  mm<sup>2</sup> = change in mean area of mentioned plaque component; Other abbreviations as in figure 2.

## DISCUSSION

To our knowledge, this is the first follow-up study that compares vascular plaque composition and remodeling at stent edges between BMS and SES treated patients. The main findings of this study are: (1) at distal and proximal stent edges in BMS patients there is a trend towards negative vascular remodeling while there is a trend towards positive remodeling at the distal stent edges in SES treated patients resulting in a significant difference between the two groups; (2) plaque composition at the stent edges did not change significantly during the 9 months follow-up in either SES or BMS patients.

Sirolimus-eluting stent implantation results in a significant reduction of restenosis compared to the results obtained with bare-metal stents in patients with stable and unstable angina.<sup>14;21</sup> However, inconsistent and limited data have been presented about their safety and efficacy in patients with acute myocardial infarction.<sup>1-4</sup> Sirolimus is a potent anti-inflammatory, immunosuppressive and antiproliferative drug effective in inhibiting in-stent neointimal hyperplasia.<sup>22</sup> These potent antiproliferative effects can also induce positive remodeling and stent malapposition and may cause deleterious local phenomena such as necrosis or apoptosis.<sup>4;13;22</sup> These effects may potentially affect plaque composition behind the stent, the vessel wall, and as a result of downstream effects of the eluted drug may also affect plaque composition at the distal stent edge.

Clinical data support the hypothesis of drug elution distal to the stent. In recent trials, SES implantation resulted in higher restenosis rates at the proximal edge of the stent compared to the distal edge.<sup>14</sup> One expects the concentration and therefore the effects of the drug to be strongest in the direction of the blood flow. This seems to be confirmed by a study by Degertekin et al. showing a trend towards positive remodeling only at the distal stent edge but not at the proximal edge.<sup>13</sup> Comparative results have been found in several other studies. Investigators of the RAVEL trial reported a trend toward larger lumen areas at distal edge which was thought to be due to higher downstream effect of the drug. A study from Jimenez-Quevedo et al further confirmed these findings by reporting a significant increase in lumen dimensions at stent edges of SES compared to lumen reduction at stent edges in BMS in patients with diabetes.<sup>22;23</sup> Our findings are in agreement with this, as we observed a trend towards positive remodeling at the distal stent edges in SES patients, though, similar to Degertekin et al, not statistically significant.

Several studies reported that stent edge burden is an important periprocedural predictor of stent edge restenosis after BMS and SES implantations.<sup>24-26</sup> In the present study population the stent edge plaque burden may have been too small to be affected significantly by the drug.

Thus far, effects of sirolimus on proximal and distal stent edges have not been fully evaluated. Serruys et al reported a vascular response at the proximal and distal stent edges after paclitaxel-eluting stent implantation.<sup>15</sup> The paclitaxel-eluting stent induced positive remodeling 1mm proximal and 3 to 4mm distal to the stent edges which resulted in less late luminal loss compared to BMS.

Little is known about the effects of sirolimus on the plaque composition at the proximal and distal stent edges. Our findings suggest that plaque composition at the stent edges was not affected by the drug since no significant differences could be detected between BMS and SES patients at follow-up. This is interesting given that an effect of sirolimus on vascular lumen dimensions was clearly present distal to the stent as well as a detectable effect on neointima volume inside the stent as demonstrated by the IVUS grayscale data. As expected, within the stented segment, SES was associated with significantly less neointimal hyperplasia when compared to BMS, a well known effect.<sup>4;22</sup> At the stent edges however, a decrease in local drug delivery may have occurred, which may have caused the drug to be ineffective in inducing changes in plaque composition at stent edges. However, changes in plaque composition caused by the drug may be subtle and missed by the VH-IVUS technique.

Similar data were observed in a study from Aoki et al who reported in a long-term follow-up study of 23 event-free patients treated with SES that no significant changes in plaque echogenicity at the distal stent edges (5mm) had taken place across multiple time points of follow up.<sup>27</sup> At the same time investigators did see a change of plaque echogenicity behind the stent struts between 2 years and 4 years of follow up. This is interesting as this suggests that alterations in plaque composition take place very late (>2 years) after stent



implantation and that they are very localized, therefore possibly not involving a measurable downstream edge effect.

It may be that the remodeling effect on the vessel at the distal stent edge is a general effect that is caused merely by a delayed healing response. Caramori et al. demonstrated persistent vasomotor dysfunction distal to coronary stents implanted 6 months earlier.<sup>28</sup> The anti-proliferative effect of sirolimus may merely cause a prolonged healing response with concomitant delayed recovery of endothelial function as suggested by Hofma et al.<sup>29</sup> It has been suggested before that delayed vascular healing may cause positive remodeling and incomplete stent apposition.<sup>30,31</sup>

In addition, past studies suggested that sirolimus or the polymer might induce apoptosis or necrosis.<sup>32,33</sup> It was suggested that the strong hydrophobic property of the compound partitions highly into arterial tissue resulting in drug concentrations that exceed the applied bulk concentration.<sup>33,34</sup> This highly concentrated local delivery of a potent drug may lead to increased vascular toxicity which in turn may lead to an inflammatory response. Pires et al, investigated histopathological effects of sirolimus- and paclitaxel-eluting cuffs in a murine model for restenosis on underlying diseased atherosclerotic arteries.<sup>33</sup> While paclitaxel significantly increased apoptosis, internal lamina elastic disruption, and decreased medial and intimal smooth muscle cells and collagen, vascular histopathological analysis revealed that sirolimus had no significant adverse effects on vascular pathology. This further supports our finding of unaffected plaque composition in SES.

## Limitations

This study is limited by the fact that it was a single-center study and that, due to the complex nature of the study design, the patient sample size for which all the above mentioned imaging modalities were available was relatively small.<sup>4</sup> Nonetheless, though it may not be possible to firmly conclude that no difference of effect on plaque composition exists between SES and BMS on stent edges after 9 months of follow up, the data indicates that these differences are possibly of smaller magnitude than anticipated. The relatively short follow-up of 9 months may have been a possible limitation, as changes in plaque composition may take much longer to develop than was presumed. Larger and longer follow-up studies of well-matched patient populations will be able to tell just how much of a difference there truly is.

Secondly, using VH-IVUS analysis at the index procedure made the border detection a more complex process.<sup>35,36</sup> Inaccurate detection of borders shared by thrombus, plaque and lumen might have caused measurement errors of plaque composition.

## CONCLUSION

This study demonstrates a trend towards positive remodeling at the distal stent edges in SES patients and a significant inhibition of neointimal hyperplasia within the stented segment at follow-up as compared to BMS treated patients. The effect on the distal stent edge suggests a downstream effect of sirolimus elution despite the fact that an effect on plaque composition was not observed.

## REFERENCES

1. Menichelli M, Parma A, Pucci E et al. Randomized trial of Sirolimus-Eluting Stent Versus Bare-Metal Stent in Acute Myocardial Infarction (SESAMI). *J Am Coll Cardiol* 2007;49:1924-1930.
2. Newell MC, Henry CR, Sigakis CJ et al. Comparison of safety and efficacy of sirolimus-eluting stents versus bare metal stents in patients with ST-segment elevation myocardial infarction. *Am J Cardiol* 2006;97:1299-1302.
3. Spaulding C, Henry P, Teiger E et al. Sirolimus-eluting versus uncoated stents in acute myocardial infarction. *N Engl J Med* 2006;355:1093-1104.
4. van der Hoeven BL, Liem SS, Jukema JW et al. Sirolimus-eluting stents versus bare-metal stents in patients with ST-segment elevation myocardial infarction: 9-month angiographic and intravascular ultrasound results and 12-month clinical outcome results from the MISSION! Intervention Study. *J Am Coll Cardiol* 2008;51:618-626.
5. Camenzind E, Steg PG, Wijns W. Stent thrombosis late after implantation of first-generation drug-eluting stents: a cause for concern. *Circulation* 2007;115:1440-1455.
6. Daemen J, Wenaweser P, Tsuchida K et al. Early and late coronary stent thrombosis of sirolimus-eluting and paclitaxel-eluting stents in routine clinical practice: data from a large two-institutional cohort study. *Lancet* 2007;369:667-678.
7. Katritsis DG, Karvouni E, Ioannidis JP. Meta-analysis comparing drug-eluting stents with bare metal stents. *Am J Cardiol* 2005;95:640-643.
8. Nordmann AJ, Briel M, Bucher HC. Mortality in randomized controlled trials comparing drug-eluting vs. bare metal stents in coronary artery disease: a meta-analysis. *Eur Heart J* 2006;27:2784-2814.
9. Pfisterer M, Brunner-La Rocca HP, Buser PT et al. Late clinical events after clopidogrel discontinuation may limit the benefit of drug-eluting stents: an observational study of drug-eluting versus bare-metal stents. *J Am Coll Cardiol* 2006;48:2584-2591.
10. Fuster V, Badimon L, Badimon JJ, Chesebro JH. The pathogenesis of coronary artery disease and the acute coronary syndromes (2). *N Engl J Med* 1992;326:310-318.
11. Fuster V, Badimon L, Badimon JJ, Chesebro JH. The pathogenesis of coronary artery disease and the acute coronary syndromes (1). *N Engl J Med* 1992;326:242-250.
12. Mizuno K, Satomura K, Miyamoto A et al. Angioscopic evaluation of coronary-artery thrombi in acute coronary syndromes. *N Engl J Med* 1992;326:287-291.
13. Degertekin M, Regar E, Tanabe K et al. Evaluation of coronary remodeling after sirolimus-eluting stent implantation by serial three-dimensional intravascular ultrasound. *Am J Cardiol* 2003;91:1046-1050.
14. Moses JW, Leon MB, Popma JJ et al. Sirolimus-eluting stents versus standard stents in patients with stenosis in a native coronary artery. *N Engl J Med* 2003;349:1315-1323.
15. Serruys PW, Degertekin M, Tanabe K et al. Vascular responses at proximal and distal edges of paclitaxel-eluting stents: serial intravascular ultrasound analysis from the TAXUS II trial. *Circulation* 2004;109:627-633.
16. Nair A, Kuban BD, Tuzcu EM, Schoenhagen P, Nissen SE, Vince DG. Coronary plaque classification with intravascular ultrasound radiofrequency data analysis. *Circulation* 2002;106:2200-2206.
17. Liem SS, van der Hoeven BL, Oemrawsingh PV et al. MISSION!: optimization of acute and chronic care for patients with acute myocardial infarction. *Am Heart J* 2007;153:14-11.
18. Oemrawsingh PV, Mintz GS, Schaliq MJ, Zwinderman AH, Jukema JW, van der Wall EE. Intravascular ultrasound guidance improves angiographic and clinical outcome of stent implantation

for long coronary artery stenoses: final results of a randomized comparison with angiographic guidance (TULIP Study). *Circulation* 2003;107:62-67.

19. Nair A, Margolis M, Kuban B, Vince D. Automated coronary plaque characterisation with intravascular ultrasound backscatter: ex vivo validation. *Eurointervention* 3, 113-120. 2007.
20. Nasu K, Tsuchikane E, Katoh O et al. Accuracy of in vivo coronary plaque morphology assessment: a validation study of in vivo virtual histology compared with in vitro histopathology. *J Am Coll Cardiol* 2006;47:2405-2412.
21. Morice MC, Serruys PW, Sousa JE et al. A randomized comparison of a sirolimus-eluting stent with a standard stent for coronary revascularization. *N Engl J Med* 2002;346:1773-1780.
22. Serruys PW, Degertekin M, Tanabe K et al. Intravascular ultrasound findings in the multicenter, randomized, double-blind RAVEL (RAndomized study with the sirolimus-eluting VELOCITY balloon-expandable stent in the treatment of patients with de novo native coronary artery Lesions) trial. *Circulation* 2002;106:798-803.
23. Jimenez-Quevedo P, Sabate M, Angiolillo DJ et al. Vascular effects of sirolimus-eluting versus bare-metal stents in diabetic patients: three-dimensional ultrasound results of the Diabetes and Sirolimus-Eluting Stent (DIABETES) Trial. *J Am Coll Cardiol* 2006;47:2172-2179.
24. Asano T, Kobayashi Y, Mintz GS et al. Effect of plaque volume on subsequent vessel remodeling at edges of sirolimus-eluting stents. *Am J Cardiol* 2006;98:1041-1044.
25. Hoffmann R, Mintz GS, Kent KM et al. Serial intravascular ultrasound predictors of restenosis at the margins of Palmaz-Schatz stents. *Am J Cardiol* 1997;79:951-953.
26. Sakurai R, Ako J, Morino Y et al. Predictors of edge stenosis following sirolimus-eluting stent deployment (a quantitative intravascular ultrasound analysis from the SIRIUS trial). *Am J Cardiol* 2005;96:1251-1253.
27. Aoki J, Abizaid AC, Serruys PW et al. Evaluation of four-year coronary artery response after sirolimus-eluting stent implantation using serial quantitative intravascular ultrasound and computer-assisted grayscale value analysis for plaque composition in event-free patients. *J Am Coll Cardiol* 2005;46:1670-1676.
28. Caramori PR, Lima VC, Seidelin PH, Newton GE, Parker JD, Adelman AG. Long-term endothelial dysfunction after coronary artery stenting. *J Am Coll Cardiol* 1999;34:1675-1679.
29. Hofma SH, van der Giessen WJ, van Dalen BM et al. Indication of long-term endothelial dysfunction after sirolimus-eluting stent implantation. *Eur Heart J* 2006;27:166-170.
30. Virmani R, Guagliumi G, Farb A et al. Localized hypersensitivity and late coronary thrombosis secondary to a sirolimus-eluting stent: should we be cautious? *Circulation* 2004;109:701-705.
31. Virmani R, Farb A, Guagliumi G, Kolodgie FD. Drug-eluting stents: caution and concerns for long-term outcome. *Coron Artery Dis* 2004;15:313-318.
32. Curcio A, Torella D, Cuda G et al. Effect of stent coating alone on in vitro vascular smooth muscle cell proliferation and apoptosis. *Am J Physiol Heart Circ Physiol* 2004;286:H902-H908.
33. Pires NM, Eefting D, de Vries MR, Quax PH, Jukema JW. Sirolimus and paclitaxel provoke different vascular pathological responses after local delivery in a murine model for restenosis on underlying atherosclerotic arteries. *Heart* 2007;93:922-927.
34. Creel CJ, Lovich MA, Edelman ER. Arterial paclitaxel distribution and deposition. *Circ Res* 2000;86:879-884.
35. Frutkin AD, Mehta SK, McCrary JR, Marso SP. Limitations to the use of virtual histology-intravascular ultrasound to detect vulnerable plaque. *Eur Heart J* 2007;28:1783-1784.
36. Surmely JF, Nasu K, Fujita H et al. Coronary plaque composition of culprit/target lesions according to the clinical presentation: a virtual histology intravascular ultrasound analysis. *Eur Heart J* 2006;27:2939-2944.

