



Universiteit
Leiden
The Netherlands

The injured liver: management and hepatic injuries in the traumapatient
Hommes, M.

Citation

Hommes, M. (2016, April 29). *The injured liver: management and hepatic injuries in the traumapatient*. Retrieved from <https://hdl.handle.net/1887/39153>

Version: Not Applicable (or Unknown)

License: [Licence agreement concerning inclusion of doctoral thesis in the Institutional Repository of the University of Leiden](#)

Downloaded from: <https://hdl.handle.net/1887/39153>

Note: To cite this publication please use the final published version (if applicable).

Cover Page



Universiteit Leiden



The handle <http://hdl.handle.net/1887/39153> holds various files of this Leiden University dissertation.

Author: Hommes, M.

Title: The injured liver : management and hepatic injuries in the traumapatient

Issue Date: 2016-04-29

Management of biliary complications following damage control surgery for liver trauma

Hommel M, Kazemier G, Schep NWL, Kuipers EJ, Schipper IB
Eur J Trauma Emerg Surg 2013

ABSTRACT

Background: The liver is the most frequently injured solid intra-abdominal organ. The major cause of early death following severe liver trauma is exsanguination. Although perihepatic packing improves survival in severe liver trauma, this leaves parenchymal damage untreated, often resulting in post-traumatic biliary leakage and a subsequent rise in morbidity. The aim of this study was to analyze the incidence and treatment of biliary leakage following the operative management of liver trauma.

Methods: Patients presenting between 2000 and 2009 to Erasmus University Medical Centre with traumatic liver injury were identified. Data from 125 patients were collected and analyzed. Sixty-eight (54 %) patients required operation. All consecutive patients with post-operative biliary complications were analyzed. Post-operative biliary complications were defined as biloma, biliary fistula, and bilhemia.

Results: Ten (15 %) patients were diagnosed with postoperative biliary leakage following liver injury. Three patients with a biloma were treated with percutaneous drainage, without further intervention. Seven patients with significant biliary leakage were managed by endoscopic stenting of the common bile duct to decompress the internal biliary pressure. One patient had a relaparotomy and right hemihepatectomy to control biliary leakage and injury of the right hepatic duct.

Conclusion: Biliary complications continue to occur frequently following damage control surgery for liver trauma. The majority of biliary complications can be managed without an operation. Endoscopic retrograde cholangiopancreatography (ERCP) and internal stenting represent a safe strategy to manage post-operative biliary leakage and bilhemia in patients following liver trauma. Minor biliary leakage should be managed by percutaneous drainage alone.

INTRODUCTION

Liver injury is common in patients with abdominal trauma¹. Early deaths in patients with liver trauma are often related to uncontrolled bleeding and associated injuries. Later deaths are predominantly related to septic complications. In the majority of patients with blunt abdominal trauma, hepatic bleeding stops spontaneously or can be stopped with abdominal packing². This perihepatic packing is a safe damage control maneuver which improves survival³⁻⁷. However, it leaves parenchymal damage untreated and may lead to persistent low-volume hemorrhage, abscesses, hemobilia, and bile leaks⁸. Three types of acute complications following biliary

trauma are biloma, biliary fistula, and bilhemia. The incidence of post-traumatic biliary complications vary from 4 to 22 %⁸⁻¹⁰. Bilhemia occurs in 1 % of liver trauma patients^{11, 12}. Some bile duct injuries will be obvious intra-operatively, with significant bile staining and a visible disrupted bile duct. However, it may be difficult to diagnose the presence of traumatic bile leak during operation¹³. Many persistent fistulae may manifest from smaller peripheral bile ducts, which retract into the liver parenchyma and are not visualized intra-operatively¹⁴. Subsequent peritonitis caused by bile leakage can give rise to substantial morbidity, leading to prolonged hospital stay^{9, 15, 16}. Reduction of the pressure gradient between the bile duct and duodenum by endoscopic retrograde cholangiopancreatography (ERCP) has been reported to be successful in the cessation of bile leakage and may prevent relaparotomies to control biliary leakage^{14, 15, 17-19}. The aim of this study was to analyze the incidence and treatment of biliary leakage following the operative management of liver trauma.

METHODS

All consecutive patients, 16 years and older with blunt or penetrating liver injuries presented between 2000 and 2009 at a major level 1 trauma center and a tertiary referral center for hepatobiliary surgery and liver transplantation in the Netherlands, were identified from the trauma registration database. The electronic records and imaging studies of all patients, diagnosed a liver injury during laparotomy or on computed tomography (CT) scan, were reviewed. All liver trauma patients who subsequently underwent damage control surgery and developed a post-operative biliary leak were included.

Operative management. Initial management of the injured patient was carried out according the guidelines of the Advanced Trauma Life Support (ATLS)²⁰. Hemodynamic instability and signs of peritonitis were indications for an exploratory laparotomy according to the algorithm and guidelines for abdominal trauma¹⁹. Initially, the injured liver was compressed manually to control the bleeding and subsequent packs were

placed above and below the liver temporarily. Whenever the bleeding was controlled after temporarily packing, the packs were removed at the initial operation. Nevertheless, patients with prolonged hemodynamic instability, hypothermia, severe acidosis, onset of coagulopathy, and massive transfusion requirement were managed following a damage control surgery strategy²¹. This strategy included perihepatic packing to control bleeding, spillage control, temporary abdominal closure, resuscitation in an intensive care environment, if feasible and necessary angioembolization, and planned reoperation for definitive treatment after 24–48 h^{4–7}. In general, in the damage control setting, the falciform ligament is transected and dry packs were placed above the liver to restore the anatomical

relationship. Thereafter, the liver is cautiously retracted in the caudocephalad direction to the pack below, while being aware of the risks of too much traction on the vena cava inferior²². If necessary, an acute partial liver resection was performed as part of the damage control procedure. Other techniques of packing the liver as described in the literature (i.e., mesh wraps or omental flaps) were not used in this series²³. Following an explorative laparotomy and in case of suspected ongoing bleeding post-operatively, an on-demand angiogram was performed, including subsequent selective angioembolization. Classification of liver injuries and complications The localization and extent of the liver injuries were classified according to the segmental and functional anatomy described by Couinaud²⁴. The severity of all liver injuries was graded according to the Organ Injury Scale (OIS) of the American Association for the Surgery of Trauma (AAST) (Table 1)²⁵. Post-operative biliary leakage was subdivided into biloma, biliary fistula, or bilhemia. A biloma was defined as an intra-abdominal collection of bile, diagnosed with ultrasound or CT scan. A biliary fistula was defined as leakage of bile via the surgical wound, gunshot wound opening, stab wound opening or percutaneous drain of more than 50 mL/day for 2 weeks or more than 400 cc daily, confirmed by a bilirubin fluid level

Table 1 The liver Organ Injury Scale (OIS) of the American Association for the Surgery of Trauma (AAST)

| Grade of liver injury | Type of injury | Description of injury |
|-----------------------|----------------|-------------------------------------------------------------------------------------------------------|
| I | Haematoma | Subcapsular, <10 % surface area |
| | Laceration | Capsular tear, <1 cm parenchymal depth |
| II | Haematoma | Subcapsular, 10–50 % surface area |
| | Laceration | Intraparenchymal, <10 cm in diameter |
| III | Haematoma | 1–3 cm parenchymal depth, <10 cm length |
| | Haematoma | Subcapsular, >50 % surface area or expanding. Ruptured subcapsular or parenchymal haematoma |
| IV | Laceration | Intraparenchymal haematoma >10 cm or expanding |
| | Laceration | >3 cm parenchymal depth |
| V | Laceration | Parenchymal disruption involving 25–75 % hepatic lobe or 1-3 Couinaud's segments in a single lobe |
| | Laceration | Parenchymal disruption involving >75 % of hepatic lobe or >3 Couinaud's segments within a single lobe |
| VI | Vascular | Juxtahepatic venous injuries, i.e., retrohepatic vena cava/central major hepatic veins |
| | Vascular | Hepatic avulsion |

exceeding the normal bilirubin serum level²⁶. Bilhemia was defined by a communication between intrahepatic bile ducts and the hepatic venous system, clinically characterized by jaundice and increased serum bilirubin level. All patients with a biloma were initially managed by percutaneous drainage. Patients with biliary fistulae and significant leakage of bile and patients with bilhemia were treated endoscopically. An endoscopic retrograde cholangiogram was performed within 24 h after diagnosis. If the bile leak was localized and confirmed on cholangiography, internal transpapillary stenting, using 7- or 10-Fr plastic stents, was performed with or without a sphincterotomy. The intention was to maintain all patients on enteral nutrition. The primary outcome was the success rate of controlling biliary leakage. This was defined as the cessation of bile leakage following internal stenting or percutaneous drainage alone. Follow-up continued until 6 months after discharge. Failure of percutaneous or endoscopic treatment was defined as the need for surgical intervention, such as a relaparotomy with partial liver resection to control biliary leakage.

Statistics Data were analyzed using the Statistical Package for the Social Sciences (SPSS) version 16.0. Normality of continuous data was tested with the Shapiro–Wilk and Kolmogorov–Smirnov tests and by inspecting the frequency distributions (histograms). Homogeneity of variances was tested using Levene’s test. Descriptive analysis was performed to assess the patient characteristics. For continuous data, the mean \pm standard deviation (SD) (parametric data) or medians and percentiles (non-parametric data) were calculated. For categorical data, frequencies were calculated.

RESULTS

General study group.

A total of 125 liver trauma patients were identified from the trauma database. The mean age was 33 years (range 16–81). Sixty-three percent of the liver injuries were caused by blunt trauma. The median Injury Severity Score (ISS) of these patients was 22 (interquartile range 17–34). The median length of hospital stay was 10 days (interquartile range 4–18). Sixty-eight (54 %) of the 125 liver trauma patients needed operative management of their abdominal traumatic injuries (Fig. 1). The mechanism of trauma was blunt in 53 %. The median ISS was 26 (interquartile range 17–42). Associated intra-abdominal injuries in the operative group of 68 patients were lacerations of the spleen, stomach, small bowel, and colon (Table 2). The median length of hospital stay was 11 days (interquartile range 6–36). Thirteen of the 125 liver trauma patients (10 %) died because of exsanguination or associated injuries within 48 h (early deaths). Ten of the 125 liver trauma patients (1 %) developed post-traumatic biliary complications (Table 3).

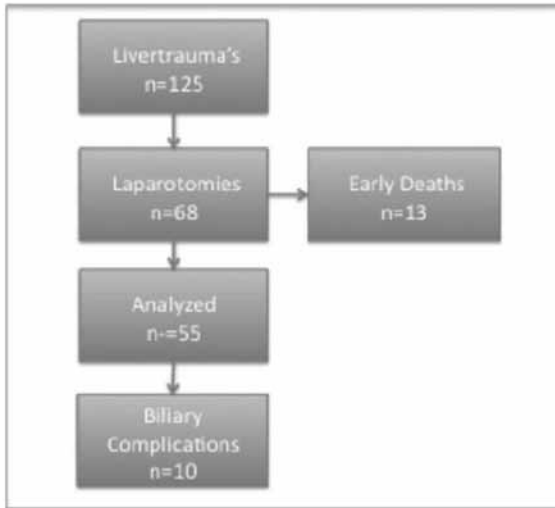


Fig. 1 Sixty-eight patients needed operative management. Thirteen patients died because of exsanguinations or associated injuries within 48 h. Ten patients developed post-traumatic biliary leakage

Table 2 Associated intra-abdominal injured organs, diagnosed peri-operatively

| Organ | <i>n</i> |
|-------------|----------|
| Diaphragm | 6 |
| Stomach | 9 |
| Duodenum | 2 |
| Gallbladder | 2 |
| Small bowel | 9 |
| Colon | 8 |
| Spleen | 10 |
| Pancreas | 3 |
| Kidney | 4 |
| Vascular | 5 |

Biliary complications.

Ten patients presented with biliary leakage, biloma ($n = 3$), biliary fistula ($n = 6$), and bilhemia ($n = 1$), and were further analyzed in this study. Their mean age was 36 years (range 20–55). The mechanism of injury was blunt trauma in five patients and penetrating trauma in the other five. The median ISS was 19 (interquartile range 17–25). Initial operative management consisted of perihepatic packing ($n = 7$), resections and packing

(n = 2), intra-operative placement of an endovascular juxtahepatic stent (n = 1) [12], and adjuvant embolization of the proper hepatic artery in the angiosuite following exploratory laparotomy (n = 1). Nine out of the ten patients with post-traumatic biliary leakage were diagnosed as high-grade liver injuries, with grades V and IV (Table 3). Time of diagnosis, length of hospital stay, and mortality. At a mean of 8 days (range 1–15 days) after removal of the packs and secondary resuscitation in the intensive care unit (ICU), patients were diagnosed with biliary complications. Three patients were diagnosed with non-significant biliary leakage (<50 mL/day for 2 weeks or <400 cc daily) and six patients were diagnosed with significant biliary leakage. One patient was diagnosed with bilhemia on day 10. The median length of hospital stay was 50 days (interquartile range 21–61, there was no late mortality, and all patients were discharged home or for rehabilitation.

Table 3 Ten patients with post-traumatic biliary leakage following the operative management of liver trauma

| No. | Trauma mechanism | Associated injuries | Segments | Grade | Surgical management | Adjuvant radiological intervention | Bile leak | Management biliary complications | Outcome |
|-----|------------------|----------------------------------------|------------|-------|-------------------------------|------------------------------------|--------------------|----------------------------------|-----------------------|
| 1 | Blunt | Pneumothorax | 5, 6, 7, 8 | 4 | Packing | – | Fistula | ERCP | Successful |
| 2 | Penetrating | Cardiac, thoracic spine | 3, 7 | 3 | Temporary packing | Embolizing proper hepatic artery | Fistula | ERCP | Successful |
| 3 | Penetrating | Colon | 4, 5, 6 | 5 | Packing | – | Fistula | ERCP | Successful |
| 4 | Blunt | Spleen, vena cava inferior | 5, 6, 7, 8 | 5 | Packing | – | Fistula | ERCP | Successful |
| 5 | Blunt | – | 5, 8 | 4 | Packing | – | Fistula | ERCP | Right hemihepatectomy |
| 6 | Penetrating | – | 2, 3, 4 | 4 | Packing | – | Fistula | ERCP | Successful |
| 7 | Penetrating | Humerus left | 5, 8 | 5 | Packing/deep liver suture | Stenting juxtahepatic vein | Bilovenous fistula | ERCP | Successful |
| 8 | Penetrating | Kidney, gallbladder, vena portae | 2, 3, 4 | 5 | Packing | – | Fistula | Percutaneous drainage | Successful |
| 9 | Blunt | Spleen, pelvic, traumatic brain injury | 5, 6, 7, 8 | 5 | Right hemihepatectomy/packing | – | Biloma | Percutaneous drainage | Successful |
| 10 | Blunt | – | 1, 2, 3 | 4 | Left hemihepatectomy/packing | – | Biloma | Percutaneous drainage | Successful |

Trauma mechanism, associated injuries, segments involved, liver injury grade, initial surgical management, adjuvant radiological management, type of bile leak, management of biliary complications [endoscopic retrograde cholangiopancreatography (ERCP) or percutaneous drainage], and outcome are presented in this table

Management of biliary complications.

Three patients were managed with percutaneous drainage only. The bile leakage resolved spontaneously without the need for internal decompression. Two of these patients had been initially managed by performing a partial liver resection and subsequent perihepatic packing. Seven patients were managed endoscopically by stenting with or without sphincterotomy, after demonstration of the defect on the cholangiogram (Fig. 2). In six patients, biliary leakage was controlled after internal decompression with a 7- or 10-Fr

plastic stent and sphincterotomy. Internal stents were placed to reduce the pressure gradient and not with the intention to bridge the defect in the bile duct. Persistent bile leakage from the right intrahepatic duct was present in one patient, despite bridging of the defect by means of a 10-Fr stent. In this patient, a right hemihepatectomy was performed after 8 weeks to successfully control biliary leakage.

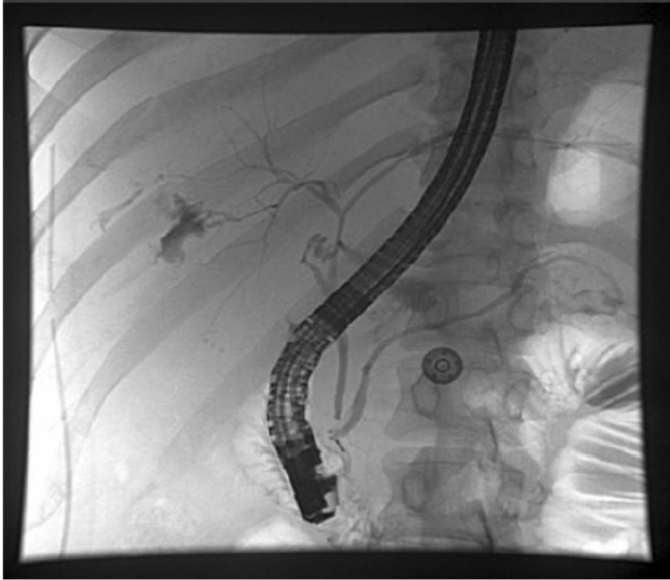


Fig. 2 Endoscopic retrograde cholangiopancreatography (ERCP) reveals biliary leakage from the right intrahepatic bile system

DISCUSSION

In this series, the overall biliary complications rate was 1%. The incidence of biliary leakage in the operative group was 15%. Eighty-five percent of the patients with biliary complications after liver trauma were managed successfully by ERCP or percutaneous drainage. Biliary leakage was not related to post-operative mortality in this series. Previous series documented an incidence of overall biliary fistulas in about 4–22% of the patients^{9–18}. In the current study, the incidence of biliary leakage in the operative group was 15%. Earlier studies also showed that the majority of complications following liver trauma can be successfully managed with non-operative techniques in up to 85% of the patients⁹. The role and safety of endoscopic management for bile leaks following complex hepatic trauma was analyzed in a previous report. Eleven patients underwent biliary sphincterotomy and stent insertion, leading to complete resolution of all bile leaks without the need for a relaparotomy¹⁰. Previous reports on the management of

post-traumatic biliary leakage following liver trauma are limited and series are small. The results documented in the current study and those found in the literature recommend ERCP and internal stenting as a safe and effective strategy for the management of bile leaks following blunt and penetrating liver trauma^{9–14, 17, 18}. One patient in this series has been reported earlier in this journal and presented with intravascular biliary leakage following penetrating trauma and implantation of an endovascular stent in the juxtahepatic vena cava as adjuvant to perihepatic packing, and was successfully treated with stenting of the bile duct¹².

In this series, two patients had, during the procedure of damage control surgery, a partial liver resection as initial surgical therapy. Nowadays, acute hepatic resection is controversial in the management of hepatic injury, because of the high mortality and better survival following perihepatic packing only^{4–8}. In our two cases, clinical judgement and partial liver resection was performed by an experienced hepatobiliary surgeon. These two patients presented with minor bile leaks and could be managed with percutaneous drainage alone. In this series of patients, finger fracture technique or hepatotomy in combination with intermittent inflow control by performing a Pringle maneuver²⁷ were not used routinely in order to ligate lacerated bile ducts and eventually lower risk for post-operative bile leaks. Non-operative techniques as percutaneous drainage and ERCP represent to be successful in the management of post-traumatic biliary leakage. Although biliary leakage did not directly attribute to mortality, the mean length of ICU stay was 18.3 days (range 4–30) and the mean length of hospital stay was 52.3 days (range 20–115), reflecting a substantial morbidity and a considerable demand on hospital facilities [emergency room (resuscitation), operating theater facilities (damage control surgery), ICU (secondary resuscitation), intervention radiology unit, and ERCP facilities]. The consequential chance that liver trauma will develop biliary leakage after damage control surgery should be taken into account by the treating physicians and discussed with the patients and their relatives postoperatively. In this series, an angiography was performed in only three patients. One patient was managed successfully nonoperatively without the development of liver related complications such as hepatic necrosis or biliary leakage. Two patients in the operatively treated group underwent an angiography, of which one patient was positive. This patient underwent angioembolization of the right hepatic artery. This patient developed a bile leak. To what extent angioembolization of the proper hepatic artery and subsequent risk of biliary ischemic events attributed to an increased morbidity and a complicated follow-up such as the development of a biliary fistula is difficult to determine. Nevertheless, in this case, angioembolization was successful in controlling the bleeding in addition to operative management.

The retrospective character limits this study, i.e., the small number of patients included and the lack of a standardized protocol for the management of post-traumatic biliary leakage during the study period. Further research should be undertaken with

preferably a multicenter study design with standardized protocols in order to overcome these limitations.

In conclusion, post-operative biliary leakage following liver trauma is a significant problem. Endoscopic sphincterotomy and internal stenting represent a successful strategy to manage significant post-operative biliary leakage and bilhemia in patients following liver trauma. Minor biliary leakage should be managed by percutaneous drainage alone.

REFERENCES

1. Feliciano DV. Surgery for liver trauma. *Surg Clin North Am.* 1989;69:273–84.
2. Meredith JW, Ditesheim JA, Stonehouse S, Wolfman N. Computed tomography and diagnostic peritoneal lavage. Complementary roles in blunt trauma. *Am Surg.* 1992;58:44–8.
3. Beal SL. Fatal hepatic hemorrhage: an unresolved problem in the management of complex liver injuries. *J Trauma.* 1990;30:163–9.
4. Feliciano DV, Mattox KL, Burch JM, Bitondo CG, Jordan GL Jr. Packing for control of hepatic hemorrhage: 58 consecutive patients. *J Trauma.* 1986;26:738–43.
5. Krige JE, Bornman PC, Terblanche J. Therapeutic perihepatic packing in complex liver trauma. *Br J Surg.* 1992;79:43–6.
6. Caruso DM, Battistella FD, Owings JT, Lee SL, Samaco RC. Perihepatic packing of major liver injuries: complications and mortality. *Arch Surg.* 1999;134:958–62.
7. Nicol AJ, Hommes M, Primrose R, Navsaria PH, Krige JEJ. Packing for control of hemorrhage in major liver trauma. *World J Surg.* 2007;31:569–74.
8. Hollands MJ, Little JM. Post-traumatic bile fistulae. *J Trauma.* 1991;31:117–20.
9. Howdieshell TR, Purvis J, Bates WB, Teeslink CR. Biloma and biliary fistula following hepatorrhaphy for liver trauma: incidence, natural history, and management. *Am Surg.* 1995;61:165–8.
10. Asensio JA, Demetriades D, Chahwan S, et al. Approach to the management of complex hepatic injuries. *J Trauma.* 2000;48: 66–9.
11. Clemens M, Wittrin G. Bilhaemie und Hamobilie nach Reitunfall. Hamburg: Tagung Nordwestdeutscher Chirurgen; 1975. Vortrag 166.
12. Hommes M, Kazemier G, van Dijk LC, et al. Complex liver trauma with bilhemia treated with perihepatic packing and endovascular stent in the vena cava. *J Trauma.* 2009;67(2):E51–3.
13. Kozar RA, Moore FA, Cothren CC, et al. Risk factors for hepatic morbidity following nonoperative management: multicenter study. *Arch Surg.* 2006;141(5):451–8; discussion 458–9.
14. Moore EE, Feliciano DV, Mattox KL, editors. *Trauma.* 5th ed. New York: McGraw-Hill; 2004. Chapter 31: liver and biliary trauma. p. 653.
15. Goldman R, Zilkoski M, Mullins R, Mayberry J, Deveney C, Trunkey D. Delayed celiotomy for the treatment of bile leak, compartment syndrome, and other hazards of nonoperative management of blunt liver injury. *Am J Surg.* 2003;185(5):492–7.
16. Carrillo EH, Reed DN Jr, Gordon L, Spain DA, Richardson JD. Delayed laparoscopy facilitates the management of biliary peritonitis in patients with complex liver injuries. *Surg Endosc.* 2001;15(3):319–22.
17. Lubezky N, Konikoff FM, Rosin D, Carmon E, Kluger Y, Ben-Haim M. Endoscopic sphincterotomy and temporary internal stenting for bile leaks following complex hepatic trauma. *Br J Surg.* 2006;93:78–81.
18. Bridges A, Wilcox CM, Varadarajulu S. Endoscopic management of traumatic bile leaks. *Gastrointest Endosc.* 2007;65(7):1081–5.
19. Thomson BNJ, Nardino B, Gumm K, et al. Management of blunt and penetrating biliary tract trauma. *J Trauma.* 2012;72(6):1620–5.
20. American College of Surgeons Committee on Trauma. *Advanced Trauma Life Support (ATLS) Student Course Manual.* 7th ed.
21. Ku J, Brasel KJ, Baker CC, Rutherford EJ. Triangle of death: hypothermia, acidosis, and coagulopathy. *New Horiz.* 1999;7:61–72.
22. American College of Surgeons Committee on Trauma. *Advanced Trauma Operative Management: Surgical Strategies for Penetrating Trauma.* 2nd ed. 2010.
23. Parks RW, Chrysos E, Diamond T. Management of liver trauma. *Br J Surg.* 1999;86(9):1121–35.

24. Couinaud C. Lobes et segments hepaticques: notes sur l'architecture anatomique et chirurgicale du foie. *Press Med.* 1954;62: 709–12.
25. Croce MA, Fabian TC, Kudsk KA, et al. AAST organ injury scale: correlation of CT-graded liver injuries and operative findings. *J Trauma.* 1991;31(6):806–12.
26. Cogbill TH, Moore EE, Jurkovich GJ, Feliciano DV, Morris JA, Mucha P. Severe hepatic trauma: a multi-center experience with 1,335 liver injuries. *J Trauma.* 1988;28:1433–8.
27. Pringle JH. V. Notes on the arrest of hepatic hemorrhage due to trauma. *Ann Surg.* 1908;48(4):541–9.

