



Universiteit  
Leiden  
The Netherlands

## Ocular inflammation in age-related eye diseases

Vu, T.H.K.

### Citation

Vu, T. H. K. (2019, June 27). *Ocular inflammation in age-related eye diseases*. Retrieved from <https://hdl.handle.net/1887/74440>

Version: Not Applicable (or Unknown)

License: [Leiden University Non-exclusive license](#)

Downloaded from: <https://hdl.handle.net/1887/74440>

**Note:** To cite this publication please use the final published version (if applicable).

Cover Page



Universiteit Leiden




The handle <http://hdl.handle.net/1887/74440> holds various files of this Leiden University dissertation.

**Author:** Vu, T.H.K.

**Title:** Ocular inflammation in age-related eye diseases

**Issue Date:** 2019-06-27



## **GENERAL INTRODUCTION**



## **AGING AND THE MANIFESTATION OF AGE-RELATED EYE DISEASES**

Aging has been a worldwide phenomenon since the mid-twentieth century. Aging is defined as the progressive accumulation of changes with time that are associated with or responsible for an increasing susceptibility to disease.<sup>2</sup> The percentage of the elderly, defined as age 60 and over, in the world population increased from 9.2% in 1990 to 11.7% in 2013 and is expected to continue to grow, reaching 21% by 2050.<sup>1</sup> Among the diseases associated with aging, ocular changes are prevalent. The most well-known ocular condition related to aging is cataract, but many other eye diseases may occur as a result of aging, such as tumors and degenerative diseases such as age-related macular degeneration and glaucoma. As the eyes age, they undergo a number of structural and functional changes that are associated with degeneration including the loss of cells in the ganglion cell layer, loss of retinal pigment epithelial (RPE) cells and photoreceptors, decreased retinal thickness, changes in the optic nerve and the ocular vasculature.<sup>3-8</sup> In parallel, age-related alterations in visual function have been described, as retinal and cortical processing of visual information is significantly different in healthy elderly individuals compared to young adults.<sup>9</sup>

### ***Age-related Macular Degeneration***

A classical example of an ocular condition that is typically found in the elderly is age-related macular degeneration (AMD). Among those aged 50-54, there is a 0.4% prevalence of advanced AMD, which increases dramatically to 11.8% in those over 80.<sup>10</sup> AMD is the leading cause of permanent, irreversible, central blindness in patients over the age of 50 in Europe and North America.<sup>11</sup> Age-related changes in the RPE are a central element in the pathogenesis of AMD. One of the most important functions of the RPE is the renewal of photoreceptors through phagocytosis of metabolic waste products and cellular debris.<sup>12</sup> As the number of RPE cells diminishes with age, phototoxic waste products and debris accumulate in the RPE, which imposes an ever-increasing burden on the remaining RPE cells. Further impairment with age causes the accumulation of debris in the cytosol of these cells, and in individuals over 80, this debris can occupy one fifth of the total RPE cell volume.<sup>3,12,13</sup> These byproducts damage DNA and cell membranes and cause chronic inflammation and apoptosis of RPE cells, which is the first step in the pathogenesis of AMD. According to these findings, the presence of inflammation is an essential component, with a detrimental effect.

### **Primary Open Angle Glaucoma**

Another ocular age-related condition is primary open angle glaucoma (POAG). Similar to the trend seen in AMD, there is a 0.7% prevalence of glaucoma in individuals 40-49 years of age, which increases to 7.9% in individuals over 80.<sup>14</sup> In 2020, an estimated 79.6 million people worldwide will be affected by glaucoma, and of these, 74% will have POAG and 5.9 million patients with POAG will present with bilateral blindness.<sup>15</sup> Glaucoma, the second leading cause of blindness in the world, is a group of ocular diseases characterized by damage to the optic nerve and degeneration of retinal ganglion cells (RGCs), which leads to progressive and permanent vision loss.<sup>15,16</sup> Elevation of intraocular pressure (IOP) and older age are considered major risk factors for the onset and development of POAG.<sup>17,18</sup> It has been reported that the mean reduction in retinal nerve fiber layer thickness is 3  $\mu\text{m}$  per decade, corresponding with a loss of approximately 60,000 RGCs.<sup>19</sup> The significant loss of neurons in the inner retina during normal aging might explain why age is a significant factor for the development of visual defects associated with glaucomatous neuropathy.<sup>20,21</sup> For example, on average the number of RGCs in the retina of a 25-year old is twice that of a 95-year old.<sup>19</sup> This large neural reserve observed in young individuals could explain why the aging population is more susceptible to glaucomatous damage. It is possible that clinically significant visual field defects occur when the sum of pathologic (e.g. elevated IOP, ischemia, etc.) and non-pathologic (e.g. aging) neuronal losses reaches a critical level. Age-related changes in neuronal susceptibility to damage have indeed been reported, in which older animals show faster loss of RGCs following axonal damage compared to younger animals.<sup>22</sup> Other structural changes seen with aging are a decrease in the mechanical compliance of the lamina cribrosa<sup>4,23</sup> and increased resistance in the trabecular outflow tract<sup>24</sup> which is in part due to alterations in the distribution and amount of connective tissue and extracellular matrix components.<sup>23,24</sup> In addition, vessel density and diameters of the choriocapillaries and retinal arterioles and venules decrease with increasing age, independent of other risk factors.<sup>25</sup> These changes are consistent with a reduction in ocular blood flow with advancing age in retrobulbar, choroidal and optic nerve vascular beds, leading to impairment of oxygen supply and metabolic exchange, and ultimately to ischemic conditions of the eye.<sup>7,26</sup> Burgoyne and Downs<sup>27</sup> have described that age-related alterations in the biomechanics of the optic nerve head (ONH) underlie the susceptibility of the aged ONH to glaucomatous damage. They suggest, that non-IOP related insults, such as inflammation or reduced ocular blood flow, damage the connective tissue and

axons of the ONH, making the optic nerve vulnerable to secondary damage, e.g. through elevated IOP.<sup>7,27</sup>

### ***Uveal Melanoma***

Not only are neurodegenerative diseases more prevalent in the aging eye, but also ocular malignancies demonstrate a strong correlation with the aging process. Uveal melanoma is a tumor that can develop in the iris, the ciliary body, or the choroid and the most common primary intraocular malignancy in adults with an estimated annual incidence of 6 to 10 cases per million per year in Caucasian populations, with a median age at diagnosis of 62 years.<sup>28,30,31</sup> The incidence rate of uveal melanomas progressively increases from 3.9 cases per million in males and 2.4 cases per million in females aged 40-44 years to a peak of 24.5 cases per million in males and 17.8 cases per million in females aged 70-74.<sup>28-30</sup> Up to 50% of patients with uveal melanoma may die from metastatic disease, and metastasis may still develop after 10-15 years, and even 35 years after diagnosis.<sup>32,33</sup> Over the past decades, patient survival has not improved, despite progress in the diagnosis of melanocytic lesions and successful treatment of the intraocular melanoma.<sup>28,34,35</sup>

The term “inflammatory phenotype” has been proposed to describe a combination of inflammatory markers in uveal melanoma with an poor prognosis, including high numbers of tumor-associated macrophages and lymphocytes, and high levels of HLA class I and II expression. These tumors are further characterized by the presence of epithelioid cells and a high vascular density, as well as an association with the loss of one copy of chromosome 3.<sup>33,36</sup> Loss of expression of a specific gene on chromosome 3, BAP1, is strongly correlated with the influx of lymphocytes in primary uveal melanoma and metastasis.<sup>37-40</sup>

## **THE IMMUNE SYSTEM: UNDERSTANDING THE M1/M2 - T<sub>H</sub>1/T<sub>H</sub>2 PARADIGM**

### ***M1 and M2 macrophages***

Although specific pathogenic mechanisms are involved in the initiation and progression of different types of age-related eye diseases, it is believed that inflammation is an important component which contributes to the pathogenesis of many of these diseases.<sup>41</sup> However, to fully understand and elucidate the altered inflammatory responses seen in aged individuals,

it is important to first realize that there are functionally different types of macrophages and immune effector cells. Mantovani described two subsets of macrophages, the classically-activated (M1) and the alternatively-activated (M2) macrophage.<sup>42-44</sup> Bacterial products such as lipopolysaccharide (LPS) and IFN- $\gamma$  produced by other immune cells polarize macrophages toward the M1 phenotype, which gain immunostimulatory functions, anti-bactericidal activity and release pro-inflammatory (e.g. IL-12, TNF- $\alpha$ ) cytokines. These cells have a higher expression of major histocompatibility (MHC) class II and costimulatory molecules, and function as antigen-presenting cells (APCs) to stimulate T and B cell-adaptive immune responses against infectious agents.<sup>42,43</sup> In contrast, M2 polarization occurs when other immune cells produce IL-4 and IL-13.<sup>45,46</sup> M2 macrophages are mainly involved in the dampening of inflammation, the promotion of tissue remodeling and repair, angiogenesis, tumor progression and immunoregulatory functions.<sup>42,47</sup>

### ***T<sub>H</sub>1 and T<sub>H</sub>2 cells***

Mirroring M1 and M2 polarization, CD4<sup>+</sup>T helper cells can also differentiate into one of the two divergent pathways, resulting in functionally polarized T<sub>H</sub>1 and T<sub>H</sub>2 cells.<sup>48,49</sup> T<sub>H</sub>1 cells secrete IL-2, IFN- $\gamma$  and lymphotoxin, which are potent pro-inflammatory cytokines while T<sub>H</sub>2 cells secrete IL-4, IL-5, IL-6, and IL-10.<sup>48,49</sup> In addition, there are T suppressor (regulatory) cells (Treg), which can regulate other T cells, macrophages and APCs.<sup>48</sup> M1 or M2- dominant macrophage responses can influence whether an T<sub>H</sub>1 or T<sub>H</sub>2 response occurs via their expression of certain cytokines and chemokines.<sup>50</sup> In response, T<sub>H</sub>1, T<sub>H</sub>2 or Treg cells can integrate M1 and M2 macrophages in circuits of amplification and regulation of polarized T-cell responses.<sup>42,43</sup> Vice versa, T cells can also control the type of immune responses generated by the profile of cytokines they secrete. In particular, immune responses induced by T<sub>H</sub>1 cell-derived IFN- $\gamma$  cause macrophage activation, whereas IL-4, IL-5, and IL-10 produced by T<sub>H</sub>2 cells inhibit macrophage activation.<sup>50</sup>



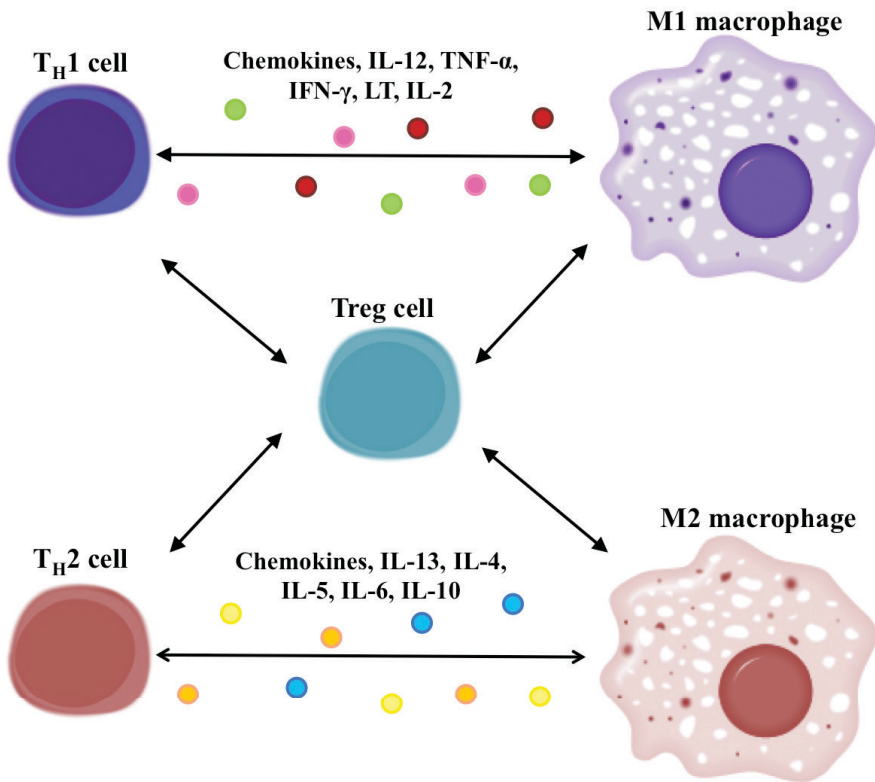


Figure 1. A simplified view of the orchestration of macrophage-T cell activation and polarization.

## INFLAMMATION IN THE AGING EYE

### *An immune-privileged site*

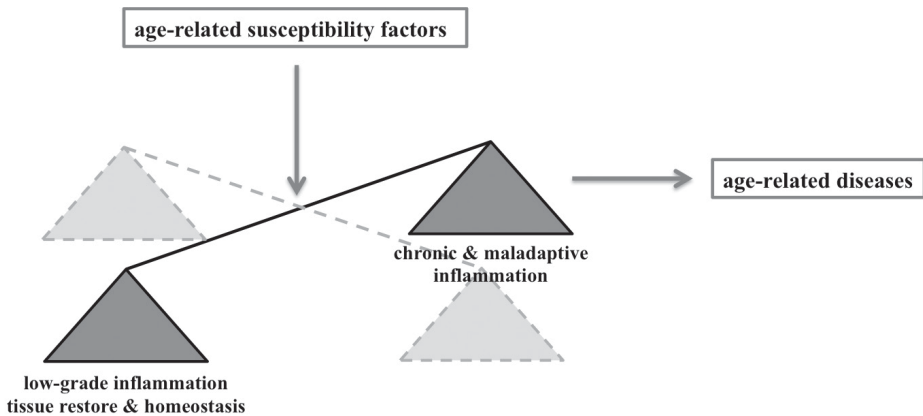
Traditionally, the eye has been considered an immune-privileged site<sup>48,51</sup>, which assumedly allows it to be protected from the potentially destructive effects of a local inflammatory immune response. This protection is created by passive and active contributors. Passive contributors include the blood-ocular barrier and the presence of specific immunosuppressive cytokines, neuropeptides and growth factors in the ocular fluids.<sup>48</sup> Dysfunction of the blood-ocular barrier due to injury or disease can cause loss of immune privilege which in turn results in destruction of neural tissue in the eye.<sup>52</sup> Active contributors to the ocular eye-induced immunosuppression have been identified through the study

of ACAID (anterior chamber associated immune deviation). Uptake of an antigen in the anterior chamber by an APC that was simultaneously incubated in immunosuppressive cytokines such as TGF- $\beta$ , and subsequent transport to the spleen leads to a systemic downregulation of antigen-specific immune responses.<sup>48</sup>

Currently, the retina is known to have an endogenous immune system that is coordinated by immunocompetent cells, such as microglia and dendritic cells.<sup>53,54</sup> In addition, the pigment epithelial cells lining the iris, ciliary body, and retina exhibit immunomodulatory functions through the production of cell-surface and soluble inhibitory molecules.<sup>55-58</sup> More importantly, resident retinal microglia, RPE cells, and choroidal macrophages/dendritic cells are major players in mounting the immune response which deals with stress or malfunction of the retina in several pathologic conditions.<sup>41</sup> In fact, an immune response, when controlled, is an adaptive response to restore tissue homeostasis and to monitor tissue malfunction. However, when alterations occur secondary to aging, metabolic abnormalities, altered vascular perfusion or degenerative conditions may initiate various inflammatory cascades leading to a prolonged, deregulated and pathogenic immune response.<sup>59</sup>

### ***Para-inflammation***

Medzhitov<sup>60</sup> first introduced a concept called “para-inflammation,” later supported by Forrester<sup>41</sup>. The physiological purpose of para-inflammation is to restore tissue functionality and homeostasis. This type of inflammatory response is likely to be more common but of lower magnitude than the classic inflammatory response induced by infection or injury. Aging is one of the main factors that can lead to chronic para-inflammation and increased tissue stress and malfunction.<sup>2,61</sup> Retinal cells encounter progressive amounts of oxidative and metabolic stress during the aging process. “The free radical theory of aging” described by Harman<sup>2</sup> implicates that reactive free radicals are formed endogenously via normal oxygen-utilizing metabolic processes and that tissue damage induced by free-radicals is progressively accumulated during aging.<sup>2,41,61</sup> As a result, the magnitude of this (low-grade) para-inflammation may increase and evolve into a chronic (maladaptive) classical inflammatory response which contributes to the initiation and progression of age-related diseases.<sup>41</sup>



**Figure 2. The premise of inflammation in age-related diseases.**

1

### ***Aging and inflammation in animal models***

Gene expression studies in animals have shown that retinal aging is accompanied by activation of genes linked to immune responses and to tissue stress/injury responses, which mainly involves the innate immune system.<sup>62</sup> More interestingly, animal studies indicate an age-related decline in the secretion of macrophage-derived pro-inflammatory cytokines and chemokines.<sup>63-66</sup> Renshaw et al.<sup>66</sup> have shown that splenic and activated peritoneal macrophages from aged mice express significantly lower levels of all Toll-like receptors (TLRs). Moreover, macrophages from aged mice secrete significantly lower levels of pro-inflammatory cytokines (IL-6 and TNF- $\alpha$ ) and chemokines (MIP-1 $\alpha$  and CCL5) when stimulated with known ligands for TLR2, TLR4, TLR5 and TLR9 compared with those from young mice.<sup>66</sup>

In the normal aging retina and choroid of rats, the level of prostaglandin E2 (PGE2) is highly increased accompanied by decreased protein levels of TNF- $\alpha$ .<sup>64</sup> It appears that activated macrophages from old mice produce more PGE2 than those from young mice.<sup>67</sup> PGE2 has several effects on the immune system and contributes to dysfunctional immune responses in the elderly. It suppresses IL-12 secretion, decreases MHC class II expression on APCs and enhances IL-10 secretion, resulting in diminished activated T cell-function.<sup>41,65,67</sup>

Aging also results in altered expression of growth factors, including increased expression of vascular endothelial growth factor (VEGF, which mediates vascular remodeling),

and decreased expression of pigment epithelium-derived factor (PEDF, an inhibitor of angiogenesis) in the choroid of aged rats.<sup>68</sup> The above findings of decreased secretion of macrophage pro-inflammatory cytokines/chemokines (IL-6, IL-12, TNF- $\alpha$ , MIP-1 $\alpha$ , CCL5) and increased proangiogenic factors (VEGF) suggest an anti-inflammatory and a proangiogenic profile, which contributes to dysfunctional immune responses in the elderly.

With regard to the different types of macrophage responses, the eyes of young and old naïve mice have been analyzed for a range of inflammation-associated markers.<sup>69</sup> The common macrophage marker F4/80 was expressed at a higher level in the eyes of old mice compared to young mice: especially M2 markers (CD163, PPARG) were highly increased in aged mice. Immunohistological analysis showed large amounts of M2 type macrophages (F4/80<sup>+</sup> and CD163<sup>+</sup> cells) in the anterior eye of old mice, with fewer cells seen in eyes of young mice.<sup>69</sup> In addition, the proangiogenic genes VEGF and TIE-2, which are associated with the angiogenic effector functions of M2 macrophages, were expressed at higher levels in aged mice compared to young mice.<sup>69</sup> These findings suggest that normal eyes in old animals show an increased basal level of inflammation and repair processes that will more easily give rise to angiogenesis and chronic inflammation.

Although the pathogenesis of AMD, uveal melanoma, and glaucoma differ and various genetic and environmental factors are involved, low-grade chronic inflammation (para-inflammation) is a common process which is involved in all three of these age-related eye diseases in the elderly population.

## **INFLAMMATION IN AGE-RELATED EYE DISEASES**

### ***Age-related Macular Degeneration***

With aging, oxidative stress in retinal and choroidal tissues may trigger a tissue-adaptive response, in which cells of the innate immune system mount a low-grade inflammatory response in order to restore tissue homeostasis.<sup>6,12,41</sup> In AMD, however the balance between the stress-induced damage and para-inflammation-related tissue repair is disturbed due to either sustained/increased injury (aging, smoking), or an altered/decreased repair ability of the immune system (aging, genetic susceptibility).<sup>41</sup> Injured RPE cells release cytokines and chemokines that recruit and activate macrophages and dendritic cells, which

in turn may amplify the inflammatory process via cell-to-cell contact, immune complex formation, and complement activation, leading to additional RPE cell damage.<sup>70</sup> Kelly et al. have shown that the function of choroidal macrophages changes with age.<sup>71</sup> Following laser injury to the retina, IL-10 was upregulated and Fas ligand (FasL), IL-12, and TNF- $\alpha$  were downregulated in ocular macrophages of old mice, suggesting an alternatively-activated macrophage phenotype.<sup>44,71</sup> These IL-10 producing M2 type macrophages of old mice alter the growth of abnormal blood vessels, and therefore the initiation and progression of choroidal neovascularization (CNV), the major vision-threatening complication of AMD.<sup>71</sup> Others have also reported the role of macrophages in angiogenesis in models of intraocular CNV.<sup>72,73</sup> After laser treatment of the retina in mice, CNV develops, which is accompanied by massive infiltration of macrophages. More importantly, laser treatment in young mice leads to limited neoangiogenesis, while in old mice, massive neovascularization develops.<sup>71,72</sup> Depletion of macrophages or inhibition of their effector functions diminishes CNV in old mice.<sup>73</sup> Thus, in AMD, M2 type macrophages play an essential role in regulating angiogenesis at the site of tissue injury, thereby determining the outcome of disease progression.

### ***Uveal Melanoma***

As discussed above, the development of uveal melanoma is also related to age. Important clinical prognostic factors are tumor size and location of the tumor (e.g. involvement of the ciliary body) in the eye, whereas others are related to the tumor characteristics (cell type, antigen expression, and karyotype).<sup>35,36</sup> One of the most important factors that correlates strongly with metastatic disease and survival in uveal melanoma is the loss of one copy of chromosome 3 (i.e. monosomy 3), which occurs in more than 50% of all uveal melanoma.<sup>35,74-78</sup> Other important parameters associated with prognosis include immunological determinants such as increased HLA class I and II expression, and infiltration of macrophages and lymphocytes into the tumor.<sup>79-84</sup> Maat et al.<sup>36</sup> have shown that tumors with a poor prognosis do not only exhibit monosomy of chromosome 3, but also the inflammatory phenotype as well. In addition, others have also shown that a high number of tumor-infiltrating CD68<sup>+</sup> macrophages are related to a poor prognosis and are associated with an increased microvascular density.<sup>83,85</sup> As mentioned before, the role of macrophages in angiogenesis has been observed previously in models of intraocular choroidal neovascularization after laser treatment of the retina. These combined findings demonstrate that age influences blood vessel growth, which has

considerable consequence for diseases, such as AMD and cancer, in which angiogenesis plays an essential role.<sup>33</sup> Tumor-associated macrophages can stimulate the formation of new vessels, helping tumors to survive by supplementing nutrients and creating a route for cancer cells to disseminate hematogenously.<sup>86-88</sup> This may clarify why an increased presence of tumor-infiltrating macrophages in unfavorable uveal melanoma is associated with a high microvascular density. Based on these findings, Ly et al.<sup>69</sup> studied whether macrophages are similarly involved in intraocular melanoma, as they are in laser-induced neovascularization. As already mentioned above, eyes of old mice expressed higher levels of macrophages and angiogenesis markers than eyes of young mice, corresponding to the phenomenon known as para-inflammation in the elderly.<sup>41</sup> Furthermore, in aged mice, tumor progression depended on the presence of macrophages, as local depletion of these cells prevented tumor outgrowth, indicating that macrophages in old mice have a strong tumor-promoting role. Further analysis showed that these macrophages in tumors of aged mice carried M2-type characteristics such as increased expression of CD163, PPARG, and angiogenic genes (VEGF, TIE-2).<sup>69</sup> Thus, naïve as well as tumor-containing eyes of old mice have more proangiogenic and tumor-promoting M2-type macrophages than comparable eyes of young mice, which carry macrophages that are probably polarized toward an immunostimulatory, tumor-suppressing M1-type macrophage.

In order to gain more profound insights into the interplay between the different subsets of immune cells in uveal melanoma and their influence on the clinical outcome of disease, we studied the presence of different functional phenotypes of tumor-infiltrating macrophages and lymphocytes, and compared them with the tumor characteristics and genetic background of 43 primary uveal melanomas (Chapter 2). Traditional treatment of uveal melanoma was enucleation, however, a shift to more eye-saving approaches occurred as the COMS study showed that outcomes were similar in small to medium-sized tumors for both therapies.<sup>89</sup> Local radiotherapy is often able to preserve eye and sight, and is less mutilating than enucleation. In spite of that, secondary enucleation may be required when tumor recurrence occurs. Because primarily-enucleated uveal melanoma that have monosomy 3 contain more inflammatory cells, and tumor recurrence may perhaps especially occur in tumors that have similarly lost one copy of chromosome 3, we also analyzed the presence of inflammatory cells in tumors enucleated after prior irradiation (Chapter 3).

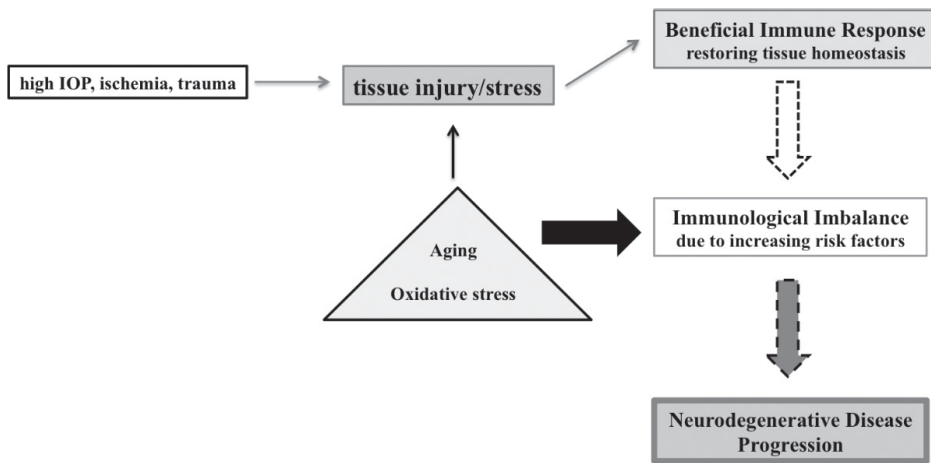
**Glaucoma**

As mentioned before, glaucoma is a highly prevalent ocular degenerative disease in which age is one of the main risk factors.<sup>18</sup> The current prevailing view is that glaucoma pathogenesis is multifactorial with a complex interplay of IOP-induced events and genetic/epigenetic/aging-related susceptibility factors which contribute to neurodegeneration.<sup>90</sup> The increased age-related oxidative stress occurs especially at the level of the neuroretina leading to para-inflammatory responses, which includes microglial activation and chemokine/cytokine production.<sup>41</sup> Microglial cells are specialized tissue macrophages in the brain and retina, and are the main cells responsible for immune surveillance involved in clearing and shielding of stressed or injured tissue.<sup>91</sup> Due to their extreme plasticity, microglia can respond to tissue injury/stress in a short period of time without causing immunological imbalance under normal aging conditions.<sup>41,92</sup> Under normal physiological circumstances, the immune-regulatory functions of microglia do not cause immunological imbalance, and promote immune privilege rather than neurodegenerative immune responses. However, in the presence of accumulating tissue stress/injury and risk factors associated with aging, chronic microglial activation in the neuroretina may result in dysfunction of their regulatory activity leading to innate and adaptive cytotoxicity.<sup>93</sup>

In addition to having innate immune activities, microglial cells also play a role in the initiation of adaptive immune responses in glaucoma and other neurodegenerative diseases.<sup>94,95</sup> For example, Tezel et al.<sup>95</sup> have shown that following exposure to reactive oxygen species/oxidative stress, microglial cells, derived from the rat retina and ONH, upregulated MHC class II molecules, and became potent inducers of T cell activation, as assessed by T cell proliferation and TNF- $\alpha$  secretion. An increasing number of studies have provided clinical evidence of an abnormal activity of the adaptive immune system in glaucoma patients.<sup>96</sup> For example, abnormal T-cell subsets and increased production of serum autoantibodies against optic nerve and retinal antigens were observed in many glaucoma patients.<sup>97-103</sup> Increased autoantibodies in the serum of glaucoma patients include heat shock proteins (HSPs), such as HSP27 and HSP60<sup>104</sup>, which are highly expressed in the glaucomatous retina and optic nerve head<sup>105</sup>. Furthermore, significant alterations of serum T<sub>H</sub>1 and T<sub>H</sub>2 cytokines are associated with glaucoma.<sup>106</sup> It is possible that peripapillary chorioretinal atrophy areas and splinter hemorrhages seen in glaucoma patients represent the areas of breakdown of the blood ocular barrier, thereby providing contact with the systemic

immune system, facilitating access of T cells and autoantibodies into the retina and optic nerve head.<sup>107,108</sup>

There is no doubt that the immune response is initially beneficial and necessary to maintain neuronal homeostasis and promote tissue repair (para-inflammation) without causing an autoimmune neurodegenerative disease. However, alterations in the immune response due to accumulating risk factors (e.g. high IOP, ischemia, trauma) along with age-related oxidative stress may impair the physiological equilibrium, and switch the protective immunity to a neuroinflammatory degenerative process.<sup>41,109</sup>



**Figure 3. Switching from protective immunity to neurodegenerative immunity**

In Chapter 4, we summarize the current concepts and insights in the role of the host immune response in glaucomatous neurodegeneration, proposing a unifying scheme of cellular processes at the level of the neuroretina, integrating risk factors, antigenic stimuli, glial activation responses, and T cell participation with the altered regulation of immune responses in glaucoma.

Although there is increasing interest in the possibility that glaucoma may act as an autoimmune disease or has an autoinflammatory component, the evidence supporting this assumption is not conclusive. While it can be imagined that inflammation plays an



important role in the damaging effects of high IOP or any type of tissue insult (e.g. ischemia, traumatic optic nerve injury), the definite evidence to support a role for autoimmune pathogenesis in glaucoma is currently lacking. Therefore, in Chapter 5 we describe a study which examines the role of CD4+ T cell responses in inducible and genetic mouse models of glaucoma in combination with immunodeficient or germ-free mice and adoptive T cell transfer. Furthermore, in Chapter 6 we describe how immune responses play a role in degenerative conditions, such as acutely elevated IOP leading to ischemia of the retina. We focus especially on the role of the adaptive immune system after the initial tissue insult has occurred. In addition, we studied the effect of suppressing CD4+T cell-mediated immune response in ischemic eyes.

1

## **IN SHORT**

Although the pathogenesis of macular degeneration, uveal melanoma and glaucoma differs and various genetic and environmental factors are involved, it is believed that these three ocular diseases share two unifying elements: 1) they are diseases of the aging population; and 2) they involve low-grade chronic inflammation (para-inflammation) in the aging eye. Therefore, the main focus of this thesis is to describe the role of the host immune system in the initiation and progression of age-related eye disease, focusing on uveal melanoma and glaucoma.

## REFERENCES

1. Nations, U. World Population Ageing 2013. (2013).
2. Harman, D. The aging process. *Proceedings of the National Academy of Sciences of the United States of America* 78, 7124-7128 (1981).
3. Akpek, E.K. & Smith, R.A. Overview of age-related ocular conditions. *The American journal of managed care* 19, S67-75 (2013).
4. Kotecha, A., Izadi, S. & Jeffery, G. Age-related changes in the thickness of the human lamina cribrosa. *The British journal of ophthalmology* 90, 1531-1534 (2006).
5. Da Pozzo, S., Iacono, P., Marchesan, R., Minutola, D. & Ravalico, G. The effect of ageing on retinal nerve fibre layer thickness: an evaluation by scanning laser polarimetry with variable corneal compensation. *Acta ophthalmologica Scandinavica* 84, 375-379 (2006).
6. Gao, H. & Hollyfield, J.G. Aging of the human retina. Differential loss of neurons and retinal pigment epithelial cells. *Investigative ophthalmology & visual science* 33, 1-17 (1992).
7. Ehrlich, R., *et al.* Age-related ocular vascular changes. *Graefe's archive for clinical and experimental ophthalmology = Albrecht von Graefes Archiv fur klinische und experimentelle Ophthalmologie* 247, 583-591 (2009).
8. Cavallotti, C., Artico, M., Pescosolido, N., Leali, F.M. & Feher, J. Age-related changes in the human retina. *Canadian journal of ophthalmology. Journal canadien d'ophtalmologie* 39, 61-68 (2004).
9. Trick, L.R. Age-related alterations in retinal function. *Documenta ophthalmologica. Advances in ophthalmology* 65, 35-43 (1987).
10. Institute, N.E. 2010 U.S. Age-Specific Prevalence Rates for AMD by Age and Race/Ethnicity. (2010).
11. Klein, R., Peto, T., Bird, A. & Vannewkirk, M.R. The epidemiology of age-related macular degeneration. *American journal of ophthalmology* 137, 486-495 (2004).
12. de Jong, P.T. Age-related macular degeneration. *The New England journal of medicine* 355, 1474-1485 (2006).
13. Feeney-Burns, L., Hilderbrand, E.S. & Eldridge, S. Aging human RPE: morphometric analysis of macular, equatorial, and peripheral cells. *Investigative ophthalmology & visual science* 25, 195-200 (1984).
14. Institute, N.E. 2010 U.S. Age-Specific Prevalence Rates for Glaucoma by Age and Race/Ethnicity. (2010).
15. Quigley, H.A. & Broman, A.T. The number of people with glaucoma worldwide in 2010 and 2020. *The British journal of ophthalmology* 90, 262-267 (2006).
16. Sommer, A. Doyné Lecture. Glaucoma: facts and fancies. *Eye* 10 ( Pt 3), 295-301 (1996).
17. Hovding, G. & Aasved, H. Prognostic factors in the development of manifest open angle glaucoma. A long-term follow-up study of hypertensive and normotensive eyes. *Acta ophthalmologica* 64, 601-608 (1986).
18. Coleman, A.L. & Miglior, S. Risk factors for glaucoma onset and progression. *Survey of ophthalmology* 53 Suppl1, S3-10 (2008).
19. Harwerth, R.S., Wheat, J.L. & Rangaswamy, N.V. Age-related losses of retinal ganglion cells and axons. *Investigative ophthalmology & visual science* 49, 4437-4443 (2008).
20. Leung, C.K., *et al.* Retinal nerve fiber layer imaging with spectral-domain optical coherence tomography: a prospective analysis of age-related loss. *Ophthalmology* 119, 731-737 (2012).
21. Patel, N.B., Lim, M., Gajjar, A., Evans, K.B. & Harwerth, R.S. Age-associated changes in the retinal nerve fiber layer and optic nerve head. *Investigative ophthalmology & visual science* 55, 5134-5143 (2014).

22. Wang, A.L., Yuan, M. & Neufeld, A.H. Age-related changes in neuronal susceptibility to damage: comparison of the retinal ganglion cells of young and old mice before and after optic nerve crush. *Annals of the New York Academy of Sciences* 1097, 64-66 (2007).
23. Albon, J., Purslow, P.P., Karwatowski, W.S. & Easty, D.L. Age related compliance of the lamina cribrosa in human eyes. *The British journal of ophthalmology* 84, 318-323 (2000).
24. Tektas, O.Y. & Lutjen-Drecoll, E. Structural changes of the trabecular meshwork in different kinds of glaucoma. *Experimental eye research* 88, 769-775 (2009).
25. Leung, H., et al. Relationships between age, blood pressure, and retinal vessel diameters in an older population. *Investigative ophthalmology & visual science* 44, 2900-2904 (2003).
26. Ravalico, G., Toffoli, G., Pastori, G., Croce, M. & Calderini, S. Age-related ocular blood flow changes. *Investigative ophthalmology & visual science* 37, 2645-2650 (1996).
27. Burgoyne, C.F. & Downs, J.C. Premise and prediction-how optic nerve head biomechanics underlies the susceptibility and clinical behavior of the aged optic nerve head. *Journal of glaucoma* 17, 318-328 (2008).
28. Singh, A.D. & Topham, A. Incidence of uveal melanoma in the United States: 1973-1997. *Ophthalmology* 110, 956-961 (2003).
29. Virgili, G., et al. Incidence of uveal melanoma in Europe. *Ophthalmology* 114, 2309-2315 (2007).
30. Singh, A.D., Turell, M.E. & Topham, A.K. Uveal melanoma: trends in incidence, treatment, and survival. *Ophthalmology* 118, 1881-1885 (2011).
31. Bergman, L., et al. Incidence of uveal melanoma in Sweden from 1960 to 1998. *Investigative ophthalmology & visual science* 43, 2579-2583 (2002).
32. Kujala, E., Makitie, T. & Kivela, T. Very long-term prognosis of patients with malignant uveal melanoma. *Investigative ophthalmology & visual science* 44, 4651-4659 (2003).
33. Jager, M.J., Ly, L.V., El Filali, M. & Madigan, M.C. Macrophages in uveal melanoma and in experimental ocular tumor models: Friends or foes? *Progress in retinal and eye research* 30, 129-146 (2011).
34. Damato, B. Does ocular treatment of uveal melanoma influence survival? *British journal of cancer* 103, 285-290 (2010).
35. Singh, A.D., Shields, C.L. & Shields, J.A. Prognostic factors in uveal melanoma. *Melanoma research* 11, 255-263 (2001).
36. Maat, W., et al. Monosomy of chromosome 3 and an inflammatory phenotype occur together in uveal melanoma. *Investigative ophthalmology & visual science* 49, 505-510 (2008).
37. van Essen, T.H., et al. Prognostic parameters in uveal melanoma and their association with BAP1 expression. *The British journal of ophthalmology* 98, 1738-1743 (2014).
38. Gezgin, G., et al. Genetic evolution of uveal melanoma guides the development of an inflammatory microenvironment. *Cancer Immunol Immunother* 66, 903-912 (2017).
39. Harbour, J.W., et al. Frequent mutation of BAP1 in metastasizing uveal melanomas. *Science* 330, 1410-1413 (2010).
40. Robertson, A.G., et al. Integrative Analysis Identifies Four Molecular and Clinical Subsets in Uveal Melanoma. *Cancer Cell* 33, 151 (2018).
41. Xu, H., Chen, M. & Forrester, J.V. Para-inflammation in the aging retina. *Progress in retinal and eye research* 28, 348-368 (2009).
42. Biswas, S.K. & Mantovani, A. Macrophage plasticity and interaction with lymphocyte subsets: cancer as a paradigm. *Nature immunology* 11, 889-896 (2010).

43. Mantovani, A., Sozzani, S., Locati, M., Allavena, P. & Sica, A. Macrophage polarization: tumor-associated macrophages as a paradigm for polarized M2 mononuclear phagocytes. *Trends in immunology* 23, 549-555 (2002).
44. Gordon, S. & Taylor, P.R. Monocyte and macrophage heterogeneity. *Nature reviews. Immunology* 5, 953-964 (2005).
45. Raes, G., et al. Macrophage galactose-type C-type lectins as novel markers for alternatively activated macrophages elicited by parasitic infections and allergic airway inflammation. *Journal of leukocyte biology* 77, 321-327 (2005).
46. Loke, P., et al. IL-4 dependent alternatively-activated macrophages have a distinctive in vivo gene expression phenotype. *BMC immunology* 3, 7 (2002).
47. Sica, A., et al. Macrophage polarization in tumour progression. *Seminars in cancer biology* 18, 349-355 (2008).
48. Streilein, J.W. Immunoregulatory mechanisms of the eye. *Progress in retinal and eye research* 18, 357-370 (1999).
49. Romagnani, S. T-cell subsets (Th1 versus Th2). *Annals of allergy, asthma & immunology : official publication of the American College of Allergy, Asthma, & Immunology* 85, 9-18; quiz 18, 21 (2000).
50. Mills, C.D., Kincaid, K., Alt, J.M., Heilman, M.J. & Hill, A.M. M-1/M-2 macrophages and the Th1/Th2 paradigm. *Journal of immunology* 164, 6166-6173 (2000).
51. Medawar, P.B. Immunity to homologous grafted skin; the fate of skin homografts transplanted to the brain, to subcutaneous tissue, and to the anterior chamber of the eye. *British journal of experimental pathology* 29, 58-69 (1948).
52. Klaassen, I., Van Noorden, C.J. & Schlingemann, R.O. Molecular basis of the inner blood-retinal barrier and its breakdown in diabetic macular edema and other pathological conditions. *Progress in retinal and eye research* 34, 19-48 (2013).
53. Xu, H., Dawson, R., Forrester, J.V. & Liversidge, J. Identification of novel dendritic cell populations in normal mouse retina. *Investigative ophthalmology & visual science* 48, 1701-1710 (2007).
54. Karlstetter, M., et al. Retinal microglia: Just bystander or target for therapy? *Progress in retinal and eye research* (2014).
55. Sugita, S. Role of ocular pigment epithelial cells in immune privilege. *Archivum immunologiae et therapeuticae experimentalis* 57, 263-268 (2009).
56. Wenkel, H. & Streilein, J.W. Evidence that retinal pigment epithelium functions as an immune-privileged tissue. *Investigative ophthalmology & visual science* 41, 3467-3473 (2000).
57. Yoshida, A., et al. Differential chemokine regulation by Th2 cytokines during human RPE-monocyte coculture. *Investigative ophthalmology & visual science* 42, 1631-1638 (2001).
58. Usui, Y., et al. Functional expression of B7H1 on retinal pigment epithelial cells. *Experimental eye research* 86, 52-59 (2008).
59. Whitcup, S.M., Nussenblatt, R.B., Lightman, S.L. & Hollander, D.A. Inflammation in retinal disease. *International journal of inflammation* 2013, 724648 (2013).
60. Medzhitov, R. Origin and physiological roles of inflammation. *Nature* 454, 428-435 (2008).
61. Rattan, S.I. Theories of biological aging: genes, proteins, and free radicals. *Free radical research* 40, 1230-1238 (2006).
62. Chen, M., Muckersie, E., Forrester, J.V. & Xu, H. Immune activation in retinal aging: a gene expression study. *Investigative ophthalmology & visual science* 51, 5888-5896 (2010).
63. Higashimoto, Y., et al. The effects of aging on the function of alveolar macrophages in mice. *Mechanisms of ageing and development* 69, 207-217 (1993).

64. Steinle, J.J., Sharma, S., Smith, C.P. & McFayden-Ketchum, L.S. Normal aging involves modulation of specific inflammatory markers in the rat retina and choroid. *The journals of gerontology. Series A, Biological sciences and medical sciences* 64, 325-331 (2009).
65. Plowden, J., Renshaw-Hoelscher, M., Engleman, C., Katz, J. & Sambhara, S. Innate immunity in aging: impact on macrophage function. *Aging cell* 3, 161-167 (2004).
66. Renshaw, M., et al. Cutting edge: impaired Toll-like receptor expression and function in aging. *Journal of immunology* 169, 4697-4701 (2002).
67. Hayek, M.G., et al. Enhanced expression of inducible cyclooxygenase with age in murine macrophages. *Journal of immunology* 159, 2445-2451 (1997).
68. Steinle, J.J., Sharma, S. & Chin, V.C. Normal aging involves altered expression of growth factors in the rat choroid. *The journals of gerontology. Series A, Biological sciences and medical sciences* 63, 135-140 (2008).
69. Ly, L.V., et al. In aged mice, outgrowth of intraocular melanoma depends on proangiogenic M2-type macrophages. *Journal of immunology* 185, 3481-3488 (2010).
70. Hageman, G.S., et al. An integrated hypothesis that considers drusen as biomarkers of immune-mediated processes at the RPE-Bruch's membrane interface in aging and age-related macular degeneration. *Progress in retinal and eye research* 20, 705-732 (2001).
71. Kelly, J., Ali Khan, A., Yin, J., Ferguson, T.A. & Apte, R.S. Senescence regulates macrophage activation and angiogenic fate at sites of tissue injury in mice. *The Journal of clinical investigation* 117, 3421-3426 (2007).
72. Apte, R.S., Richter, J., Herndon, J. & Ferguson, T.A. Macrophages inhibit neovascularization in a murine model of age-related macular degeneration. *PLoS medicine* 3, e310 (2006).
73. Espinosa-Heidmann, D.G., et al. Macrophage depletion diminishes lesion size and severity in experimental choroidal neovascularization. *Investigative ophthalmology & visual science* 44, 3586-3592 (2003).
74. Horsman, D.E., Sroka, H., Rootman, J. & White, V.A. Monosomy 3 and isochromosome 8q in a uveal melanoma. *Cancer genetics and cytogenetics* 45, 249-253 (1990).
75. Sisley, K., et al. Cytogenetic findings in six posterior uveal melanomas: involvement of chromosomes 3, 6, and 8. *Genes, chromosomes & cancer* 2, 205-209 (1990).
76. Patel, K.A., et al. Prediction of prognosis in patients with uveal melanoma using fluorescence in situ hybridisation. *The British journal of ophthalmology* 85, 1440-1444 (2001).
77. Prescher, G., et al. Prognostic implications of monosomy 3 in uveal melanoma. *Lancet* 347, 1222-1225 (1996).
78. Scholes, A.G., et al. Monosomy 3 in uveal melanoma: correlation with clinical and histologic predictors of survival. *Investigative ophthalmology & visual science* 44, 1008-1011 (2003).
79. Blom, D.J., et al. Human leukocyte antigen class I expression. Marker of poor prognosis in uveal melanoma. *Investigative ophthalmology & visual science* 38, 1865-1872 (1997).
80. Dithmar, S., Crowder, J., Jager, M.J., Vigniswaran, N. & Grossniklaus, H.E. [HLA class I antigen expression correlates with histological cell type in uveal melanoma]. *Der Ophthalmologe: Zeitschrift der Deutschen Ophthalmologischen Gesellschaft* 99, 625-628 (2002).
81. Ericsson, C., et al. Association of HLA class I and class II antigen expression and mortality in uveal melanoma. *Investigative ophthalmology & visual science* 42, 2153-2156 (2001).
82. de Waard-Siebinga, I., Hilders, C.G., Hansen, B.E., van Delft, J.L. & Jager, M.J. HLA expression and tumor-infiltrating immune cells in uveal melanoma. *Graefe's archive for clinical and experimental ophthalmology = Albrecht von Graefes Archiv fur klinische und experimentelle Ophthalmologie* 234, 34-42 (1996).

83. Makitie, T., Summanen, P., Tarkkanen, A. & Kivela, T. Tumor-infiltrating macrophages (CD68(+) cells) and prognosis in malignant uveal melanoma. *Investigative ophthalmology & visual science* 42, 1414-1421 (2001).
84. de la Cruz, P.O., Jr., Specht, C.S. & McLean, I.W. Lymphocytic infiltration in uveal malignant melanoma. *Cancer* 65, 112-115 (1990).
85. Toivonen, P., Makitie, T., Kujala, E. & Kivela, T. Microcirculation and tumor-infiltrating macrophages in choroidal and ciliary body melanoma and corresponding metastases. *Investigative ophthalmology & visual science* 45, 1-6 (2004).
86. Moldovan, N.I. Role of monocytes and macrophages in adult angiogenesis: a light at the tunnel's end. *Journal of hematology & stem cell research* 11, 179-194 (2002).
87. Folkman, J. Tumor angiogenesis: therapeutic implications. *The New England journal of medicine* 285, 1182-1186 (1971).
88. Folkman, J. How is blood vessel growth regulated in normal and neoplastic tissue? G.H.A. Clowes memorial Award lecture. *Cancer research* 46, 467-473 (1986).
89. Collaborative Ocular Melanoma Study, G. The COMS randomized trial of iodine 125 brachytherapy for choroidal melanoma: V. Twelve-year mortality rates and prognostic factors: COMS report No. 28. *Archives of ophthalmology* 124, 1684-1693 (2006).
90. Moalem, G., et al. Autoimmune T cells protect neurons from secondary degeneration after central nervous system axotomy. *Nature medicine* 5, 49-55 (1999).
91. Nimmerjahn, A., Kirchhoff, F. & Helmchen, F. Resting microglial cells are highly dynamic surveillants of brain parenchyma in vivo. *Science* 308, 1314-1318 (2005).
92. Gehrmann, J., Matsumoto, Y. & Kreutzberg, G.W. Microglia: intrinsic immune effector cell of the brain. *Brain research. Brain research reviews* 20, 269-287 (1995).
93. Ransohoff, R.M. & Perry, V.H. Microglial physiology: unique stimuli, specialized responses. *Annual review of immunology* 27, 119-145 (2009).
94. Stoll, G. & Jander, S. The role of microglia and macrophages in the pathophysiology of the CNS. *Progress in neurobiology* 58, 233-247 (1999).
95. Tezel, G., et al. Mechanisms of immune system activation in glaucoma: oxidative stress-stimulated antigen presentation by the retina and optic nerve head glia. *Investigative ophthalmology & visual science* 48, 705-714 (2007).
96. Tezel, G. & Wax, M.B. Glaucoma. *Chemical immunology and allergy* 92, 221-227 (2007).
97. Tezel, G., Edward, D.P. & Wax, M.B. Serum autoantibodies to optic nerve head glycosaminoglycans in patients with glaucoma. *Archives of ophthalmology* 117, 917-924 (1999).
98. Wax, M.B. & Tezel, G. Immunoregulation of retinal ganglion cell fate in glaucoma. *Experimental eye research* 88, 825-830 (2009).
99. Wax, M.B., et al. Anti-Ro/SS-A positivity and heat shock protein antibodies in patients with normal-pressure glaucoma. *American journal of ophthalmology* 125, 145-157 (1998).
100. Yang, J., Patil, R.V., Yu, H., Gordon, M. & Wax, M.B. T cell subsets and sIL-2R/IL-2 levels in patients with glaucoma. *American journal of ophthalmology* 131, 421-426 (2001).
101. Yang, J., Tezel, G., Patil, R.V., Romano, C. & Wax, M.B. Serum autoantibody against glutathione S-transferase in patients with glaucoma. *Investigative ophthalmology & visual science* 42, 1273-1276 (2001).
102. Romano, C., Barrett, D.A., Li, Z., Pestronk, A. & Wax, M.B. Anti-rhodopsin antibodies in sera from patients with normal-pressure glaucoma. *Investigative ophthalmology & visual science* 36, 1968-1975 (1995).

103. Maruyama, I., Ohguro, H. & Ikeda, Y. Retinal ganglion cells recognized by serum autoantibody against gamma-enolase found in glaucoma patients. *Investigative ophthalmology & visual science* 41, 1657-1665 (2000).
104. Tezel, G., Seigel, G.M. & Wax, M.B. Autoantibodies to small heat shock proteins in glaucoma. *Investigative ophthalmology & visual science* 39, 2277-2287 (1998).
105. Tezel, G., Hernandez, R. & Wax, M.B. Immunostaining of heat shock proteins in the retina and optic nerve head of normal and glaucomatous eyes. *Archives of ophthalmology* 118, 511-518 (2000).
106. Huang, P., *et al.* Serum cytokine alteration is associated with optic neuropathy in human primary open angle glaucoma. *Journal of glaucoma* 19, 324-330 (2010).
107. Wax, M.B., Tezel, G. & Edward, P.D. Clinical and ocular histopathological findings in a patient with normal-pressure glaucoma. *Archives of ophthalmology* 116, 993-1001 (1998).
108. Grieshaber, M.C. & Flammer, J. Does the blood-brain barrier play a role in Glaucoma? *Survey of ophthalmology* 52 Suppl 2, S115-121 (2007).
109. Tezel, G. The immune response in glaucoma: a perspective on the roles of oxidative stress. *Experimental eye research* 93, 178-186 (2011).

