



Universiteit
Leiden
The Netherlands

Structure and function of the cerebral cortex in Huntington's disease

Coppen, E.M.

Citation

Coppen, E. M. (2019, June 5). *Structure and function of the cerebral cortex in Huntington's disease*. Retrieved from <https://hdl.handle.net/1887/74010>

Version: Not Applicable (or Unknown)

License: [Leiden University Non-exclusive license](#)

Downloaded from: <https://hdl.handle.net/1887/74010>

Note: To cite this publication please use the final published version (if applicable).

Cover Page



Universiteit Leiden



The following handle holds various files of this Leiden University dissertation:

<http://hdl.handle.net/1887/74010>

Author: Coppen, E.M.

Title: Structure and function of the cerebral cortex in Huntington's disease

Issue Date: 2019-06-05


5



The visual cortex and visual cognition in Huntington's disease: an overview of current literature

Emma M. Coppen, Jeroen van der Grond, Ellen P. Hart,
Egbert A.J.F. Lakke, Raymund A.C. Roos

Behavioural Brain Research. 2018 May;351:63-74



ABSTRACT

The processing of visual stimuli from retina to higher cortical areas has been extensively studied in the human brain. In Huntington's disease (HD), an inherited neurodegenerative disorder, it is suggested that visual processing deficits are present in addition to more characteristic signs such as motor disturbances, cognitive dysfunction, and behavioral changes. Visual deficits are clinically important because they influence overall cognitive performance and have implications for daily functioning.

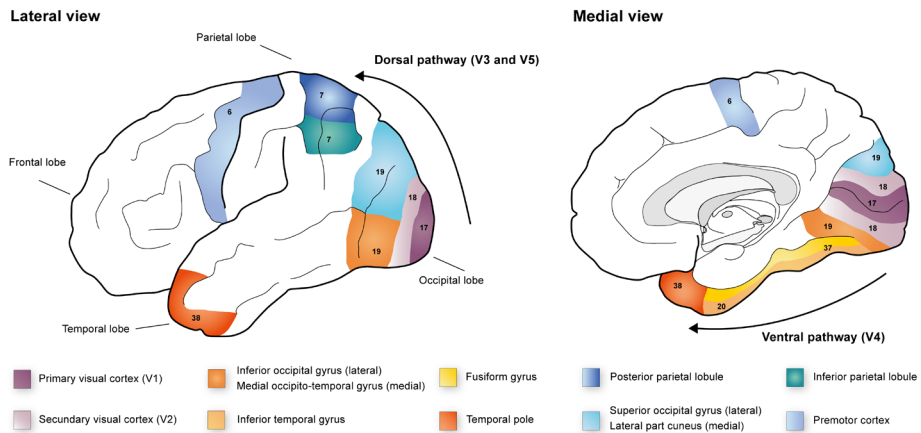
The aim of this review is to summarize current literature on clinical visual deficits, visual cognitive impairment, and underlying visual cortical changes in HD patients. A literature search was conducted using the electronic database of PubMed/Medline.

This review shows that changes of the visual system in patients with HD were not the primary focus of currently published studies. Still, early atrophy and alterations of the posterior cerebral cortex was frequently observed, primarily in the associative visual cortical areas such as the lingual and fusiform gyri, and lateral occipital cortex. Changes were even present in the premanifest phase, before clinical onset of motor symptoms, suggesting a primary region for cortical degeneration in HD. Although impairments in visuospatial processing and visual perception were reported in early disease stages, heterogeneous cognitive batteries were used, making a direct comparison between studies difficult. The use of a standardized battery of visual cognitive tasks might therefore provide more detailed information regarding the extent of impairments in specific visual domains. Further research could provide more insight into clinical, functional, and pathophysiological changes of the visual pathway in HD.

1. INTRODUCTION

Many regions of the human brain are involved in processing visual stimuli, from the retina to cortical brain areas. The organization and function of the visual cortex has been extensively studied in primates, both in macaques and healthy human adults.^{1,2} Visual field mapping using functional Magnetic Resonance Imaging (fMRI) showed that approximately 20-30% of the human brain is directly or indirectly involved in visual processing.^{3,4} Incoming visual stimuli are transmitted from the retina through the afferent visual pathway via the optic nerve and optic tract, to the lateral geniculate nucleus in the thalamus.⁵ Then, via the optic radiation, signals reach the primary visual cortex in the occipital lobe and eventually the associative (secondary and tertiary) visual cortices for further processing.⁵

FIGURE 1 Visual cortex in human brain



Schematic lateral and medial overview of cortical regions involved in the processing of visual stimuli in the human brain. Stimuli pass the retina via the optic tract to the primary visual cortex (V1) and secondary visual cortex (V2) for basic processing (i.e. shape and contrast). Although there are no clear demarcations among the regions of the posterior cortex, it is clear that higher-level visual processing occurs in the regions surrounding the primary visual cortex, which are divided into visual areas V3, V4 and V5. The ventral pathway runs through the medial part of Brodmann area 19, located in the anterior medial occipito-temporal gyrus, towards Brodmann area 37 (or V4) which is located in the caudal two-thirds of the lateral occipito-temporal gyrus (e.g. fusiform gyrus). V4 projects to Brodmann area 20, located in the inferior temporal gyrus, to Brodmann area 38, located in the anterior temporal pole, and to the limbic system. The dorsal pathway (V3 and V5) conveys visual information to the posterior parietal cortex (Brodmann area 7) and the premotor cortex (Brodmann area 6). In general, the ventral pathway in the temporal-occipital region is involved in object recognition and color processing, whereas the dorsal pathway processes depth and movement perception. Numbers in each cortical region depict corresponding Brodmann areas.

The primary visual cortex (also known as V1, striate cortex or Brodmann area 17) is located around the edges of the calcarine fissures on the medial and dorsolateral surface of the occipital lobe.^{3,6} The visual association areas (also known as the extra-striate cortices) are responsible for the interpretation of the visual input, such as color discrimination, motion perception, depth, and contrast.³ The secondary visual cortex (V2 or Brodmann area 18) processes basic visual characteristics such as color perception and orientation.^{2,7} On the medial occipital lobe surface, V2 is located in the cuneus above V1 and in the medial occipito-temporal gyrus (e.g. lingual gyrus) below V1, whereas on the lateral surface, V2 is located in the occipital gyrus anterior to V1.² From V2 onwards, visual processing proceeds along two parallel pathways, the ventral (occipito-temporal) pathway, and the dorsal (occipito-parietal) pathway.⁸ The ventral stream is also known as the 'what' visual pathway, and is involved in the recognition of objects, faces and shapes and color processing.^{2,7} The dorsal stream is known as the 'where' visual pathway and it is suggested that this area is necessary for depth (three-dimensional vision) and movement perception in relation to objects in space in the frontal eye fields.^{1,2,9,10} A summary of the visual cortical areas and their function is presented in Table 1 and Figure 1.

TABLE 1 Visual cortex and higher visual function

Visual area	Brodmann area	Cortex	Function
V1	17	Calcarine fissure Occipital pole	Mapping and processing visual stimuli
V2	18	Cuneus Lingual gyrus	Color discrimination
V4	19 (medial) / 37 20	Fusiform gyrus Inferior temporal gyrus	<i>Ventral 'what' pathway:</i> Object recognition
V3	19	Lateral part of cuneus	<i>Dorsal 'where' pathway:</i>
V5	19 (lateral) / 7	Superior occipital gyrus Posterior parietal cortex	Movement and spatial perception

Any alteration in the visual pathway may result in clinical visual deficits and changes in cognitive performance. In Huntington's disease (HD), a hereditary neurodegenerative disorder, cortical degeneration of visual brain regions is suggested to be present in early disease stages, in addition to striatal atrophy.¹¹⁻¹³ HD is autosomal dominantly inherited and caused by a cytosine-adenine-guanine (CAG) repeat mutation of the Huntingtin (HTT) gene on chromosome 4.¹⁴ The estimated prevalence of the disease is 5-10 per 100.000 in the Caucasian population.¹⁵ The manifest phase of the disease is generally characterized by progressive motor disturbances, cognitive decline, and behavioral changes.¹⁵ However, clinical signs can vary considerably among patients during the course of the disease as well as time of disease onset. Typically, the mean age of disease onset is between 30 and 50 years (range from 2 to 85 years) and the mean disease duration is between 17 to 20 years.¹⁵

Most reported behavioral and psychiatric symptoms in HD include apathy, depression, irritability, and obsessive-compulsive behavior.¹⁶ Visual hallucinations or other psychotic symptoms are rarely seen in HD patients. In a study of 1,993 HD gene mutation carriers, mild psychosis was only observed in 2.9% of the study population and only 1.2% scored moderate to severe psychosis, but no visual hallucinations were reported.¹⁶

Early cognitive deficits in HD mainly involve impairments in executive functioning, such as attention and planning difficulties, and cognitive inflexibility, which gradually progresses over time and eventually results in dementia.^{15,17} Executive dysfunction can already be present in the premanifest phase, before motor symptoms occur.^{17,18} Although deficits in visual acuity or visual dysfunction are not typical clinical features of HD, visuospatial deficits are reported in HD patients. Such visuospatial deficits are of clinical importance because they can influence overall cognitive performance and may have major functional implications, for example the impact on driving a car or using electronic devices such as mobile phones and computers. Also, visual deficits should be taken into account when conceptualizing cognitive assessments for measuring drug efficacy in clinical trials. By providing an overview regarding the brain structure and function of the visual cortex in patients with HD, we propose to provide novel information on disease progression and cortical degeneration. Therefore, the aim of this review is to summarize the current literature regarding visual cognitive impairment and identify the posterior cortical changes that occur in HD patients.

2. METHODS

A review of the existing literature on visual impairment in HD was conducted using the electronic database of PubMed/Medline. All literature published before August 2017 was critically reviewed. The following search terms were used in several combinations to identify the available literature: "Huntington", "Huntington's disease", "visual", "visual cognition", "visual processing", "visuospatial", "atrophy", "occipital cortex", "cerebral blood flow", "visual pathway", and "visual system". In addition, potential eligible studies were also screened using the reference lists of the studies found. Only original research papers and review articles written in English were considered for further review. Animal model studies, letters to editors and editorial comments were excluded. Articles that examined the visual cortex and/or assessed visual cognition in manifest and premanifest HD gene carriers were included for further evaluation.

3. RESULTS

3.1. Search results

Of the 1,406 articles that were identified by the initial database search, 85 articles were selected for further review based on the abstract. Twenty-two studies were included for this review as these studies specifically investigated visual function in HD. Of these 22 studies, one post-mortem brain study and six neuroimaging studies addressed changes of the visual cortex in HD gene carriers, and 15 neuropsychological studies assessed visual cognitive functioning in HD. We will first focus on the structural and functional changes of the visual cortex reported in manifest and premanifest HD gene carriers in paragraphs 3.2.1 and 3.2.2. An overview of the literature regarding changes of the visual cortex is also provided in Table 2. In paragraph 3.2.3, we will discuss the findings of studies investigating visual cognition in HD using the following cognitive domains: visual perception, visuospatial processing, visual working memory, visuoconstruction and visuomotor function. These visual cognitive domains and their associated neuropsychological tasks are summarized in Table 3. Furthermore, a summary of the current literature on visual cognition in HD is given in Table 4. Besides the 22 studies that investigated visual function in HD, another 26 articles were additionally reviewed, of which 24 articles assessing whole brain changes in HD, and two articles examining an extensive neuropsychological assessment battery in HD. These studies did not specifically aim to focus on the visual system, but did report relevant findings on the visual pathway in HD and will therefore be discussed in the corresponding paragraphs.

3.2. The visual cortex in Huntington's disease

Neuropathological alterations in HD are primarily found in the striatum, especially in the caudate nucleus and putamen, due to loss of striatal medium-sized spiny neurons.¹⁹ Although striatal atrophy is considered to be the origin of choreiform movements seen in HD patients, it is suggested that other symptoms of HD are related to cortical degeneration, as extensive neuronal loss is seen throughout the cerebral cortex when the disease progresses.²⁰⁻²²

3.2.1. Structure of the cerebral cortex

A post-mortem brain study showed a 32% reduction of nerve cells in the primary visual area (Brodmann area 17) in brains of 7 HD patients in advanced disease stages compared to 7 controls.²³ The authors conclude that damage to the primary visual area contributes to the pathogenesis of visual dysfunction.²³ This study, however, only examined nerve cells in Brodmann area 17 in the occipital lobe and did not assess other brain regions, which is contrary to another study that examined the patterns of neuronal cell loss in the frontal, parietal, temporal, and occipital lobes in post-mortem brains of 14 end stage HD patients.²¹ Compared to controls, HD patients showed the highest difference in pyramidal neuron cells in the secondary visual cortex (42% decrease), whereas no significant pyramidal cell differences was observed in the primary visual cortex (3% decrease).²¹ In comparison, a 27-34% reduction in pyramidal cell number was found in HD patients compared to controls for the superior frontal, middle temporal, superior parietal, and primary sensory cortices.²¹ Between HD patients, there was additionally more neuronal loss in the secondary visual cortex (36% loss) than in the primary visual cortex (12% loss), suggesting that mainly associative visual regions are impaired in HD.²¹ These latter findings were confirmed by a MRI study that observed reduced cortical thickness of the lingual gyrus and lateral occipital cortex in premanifest gene carriers close to disease onset (n=58) and early stage HD patients (n=40) that was associated with worse visuospatial task and visual working memory performance measured with the Map Search task, Spot the change task and the Trail Making Test part A.¹³ No associations were found between cognitive performance and thickness of the cuneus. This implies a distinct association between higher-level cognitive performance and cortical occipital degeneration.¹³ An additional MRI study examined structural posterior brain changes in relation to visuospatial attention in premanifest (n=119) and early stage manifest HD (n=104), and found associations between poorer visuospatial performance (measured using the Map Search and mental rotation tasks) and volume loss in the cuneus, lingual, fusiform gyri, and motor regions in manifest HD compared to controls.²⁴ Another study focused on the link between visuomotor

performance and prefrontal cortex atrophy, but additionally found focal volume loss in the occipital cortex and associations between this volume loss and poorer visuomotor performance (measured using the 15-Object test, a visuomotor integration task).²⁵ Yet, another study examining visuomotor function using the Circle Tracing task and cortical volume loss did not find any significant association between visuomotor task performance and the visual and motor cortices,²⁶ but this might be explained by the fact that in these studies different cognitive assessments were used to evaluate visuomotor function.

In studies focusing on whole brain cortical changes and associations with clinical impairments, reduced cortical thickness of the cuneus,^{12,27} and volume loss of the occipital lobe,^{11,28-31} and parietal lobe¹² were observed in both premanifest and early manifest disease stages compared to controls.

In conclusion, volumetric changes of posterior cortical regions can already be detected in early stages of the disease, even in the premanifest phase, while frontal and temporal regions remain largely unaffected.

3.2.2. Cortical brain function

It is thought that clinical manifestations of HD not only depend on brain atrophy, but are also influenced by neuronal dysfunction and loss in neuronal network structure.³²

Functional MRI (fMRI) can be used to study neural function. Several fMRI studies in HD gene carriers showed changes in multiple functional brain networks before brain atrophy or clinical symptoms were present.^{32,33}

Only one functional imaging study focused on the visual system in 20 early HD patients using resting-state fMRI.³⁴ Resting-state fMRI assesses overall brain connectivity that is not related to task performance. Reduced fusiform cortex activity in HD patients was found after correcting for whole brain atrophy compared to controls.³⁴ The authors therefore conclude that activation differences in the occipital cortex could not sufficiently be explained by regional brain volume loss alone. Another study reported reduced brain connectivity using whole brain resting-state fMRI in the occipital cortices in both premanifest and manifest HD gene carriers compared to controls.³⁵ However, decline in brain connectivity over time in the occipital region was not confirmed in longitudinal resting-state fMRI studies.^{36,37}

It is suggested that visual stimulation results in an increase in glucose uptake in the brain and cerebral blood flow.³⁸ Therefore, a ³¹phosphorus nuclear magnetic resonance (NMR) spectroscopy study used a basic visual stimulation task to activate the occipital cortex and measure metabolite concentrations for the assessment of brain energy deficits in manifest HD (n=15) compared to controls (n=15).³⁹ An increase in metabolite

concentrations was observed in controls, whereas HD patients did not show any response to brain activation, indicating impaired mitochondrial function in the visual cortex.³⁹ In addition, two small task-based fMRI studies demonstrated reduced neural activity of the occipital cortex, during a Porteus Maze task in 3 premanifest individuals,⁴⁰ and during a serial reaction time task in early and premanifest HD patients (n=8).⁴¹ These studies also showed reduced activation in the caudate, parietal and sensorimotor cortices,⁴⁰ and in the middle frontal gyri and precuneus.⁴¹ As these tasks were examined in small patient groups and involve a combination of basic and higher visual processing, motor speed, and spatial functioning, a direct conclusion cannot be drawn regarding neural dysfunction of the occipital cortex alone.

3.2.3. Cerebral metabolism

With positron emission tomography (PET) imaging, functional or metabolic changes in HD can be studied using a radioactive labeled tracer that binds to specific structures within the brain. Several reviews have recently discussed the developments of PET imaging in HD.⁴²⁻⁴⁴ Overall, there is increasing evidence of reduced glucose metabolism in the striatum, and frontal and temporal cortices, which seem to be reliable predictors of disease progression in HD.⁴²⁻⁴⁴ There have been no PET studies performed to date that specifically focused on the glucose metabolism of the visual cortex in HD patients. However, an interesting finding was observed by a study group that examined spatial covariance patterns between different networks of regions with altered glucose metabolism using PET imaging.^{45,46} A relative increase in glucose metabolism was found in thalamic, motor, occipital and cerebellar regions, in association with a decrease in striatal metabolism in HD patients compared to healthy controls.^{45,46} A recent study reports similar findings of striatal hypometabolism in combination with hypermetabolism in the cerebellum, thalamus, and occipital cortex.⁴⁷ Here, hypermetabolism in the cuneus and lingual gyrus was negatively correlated with hypokinetic motor scores. These findings suggest that a decrease in glucose metabolism might be linked to clinical disease onset, whereas an increase in glucose metabolism indicates a compensatory mechanism for neuronal loss and/or motor disturbances.^{46,47} As neuronal loss is indirectly measured using functional MRI, the reduced brain activity in the occipital cortex of HD patients found in previous fMRI studies might indeed explain the hypermetabolism found in these PET studies.

Another approach to assess alterations in metabolism is by measuring cerebral blood flow (CBF) or cerebral blood volume (CBV) using transcranial Doppler (TCD) ultrasonography, PET imaging or arterial spin labeling MRI.⁴⁸

Reductions in cerebral blood flow and elevations in cerebral blood volume were primarily observed in frontal cortical regions in premanifest HD gene carriers.^{49,50} In manifest HD, hypoperfusion was additionally observed in the fronto-parietal regions and anterior cingulate cortex during a word generation task,⁵¹ motor task,⁵² and executive functioning tasks,^{53,54} but no alterations in cerebral perfusion were detected in the posterior cortex during task performance. One study reported heterogeneous regional CBF reductions in rest in 17 early manifest HD extending to the sensorimotor, paracentral, inferior temporal and lateral occipital regions, with normal CBF in the thalamus, postcentral gyrus, insula, and medial occipital areas.⁵⁵ However, the degree of cortical thinning exceeded CBF reductions in the temporal and occipital cortices, and in the striatum, suggesting that structural and vascular alterations might originate from different underlying pathologic mechanisms.⁵⁵ More studies are necessary to evaluate the manner of perfusion changes over the course of the disease but hypoperfusion seems to play a role in the pathophysiology of neuronal dysfunction in HD.

In conclusion, although the visual system has not been the main focus in many imaging studies in HD to date, atrophy (i.e. volume loss and cortical thinning), reduced neural activity and functional connectivity, and changes in glucose metabolism of the posterior cerebral cortex have been reported in both early stage HD patients and premanifest gene carriers. This suggests that the posterior cerebral cortex might be one of the first cortical regions to undergo pathological and functional changes.

3.3. Visual cognition in Huntington's disease

Many studies investigated the progression of cognitive impairment in different HD disease stages.¹⁷ Here, we will focus on studies assessing cognitive deficits in HD that involve a visual component. Visual cognitive functioning can be divided into different domains of visual processing, however, the terminology that is used to define visual cognition widely differs among the current literature. Also, many neuropsychological assessments that are used to evaluate visual cognitive function often require a combination of several domains, such as visual attention, spatial orientation and working memory. Additionally, in HD patients, possible influence of a motor component on cognitive performances should also be considered. Below, we will discuss the reviewed studies using the following domains: visual perception, visuospatial processing, visual working memory, visuoconstruction and visuomotor function (Table 3).

In general, color, patterns, depth, motion perception, and the recognition of facial expressions of emotions are usually classified as visual perceptual skills. Visuospatial processing or visual scanning and attention are needed to visually perceive objects and assess the spatial distance and relationship among items or objects. Visual working

TABLE 2 Overview of current literature on the visual cortex in HD

	Study population	Clinical HD disease stage	Study design	Assessments	Main significant finding
Gomez-Anson et al., 2009 ²⁵	Controls n = 21 PreHD n = 20	YTO: not available PreHD1: n = 12 (UHDRS-TMS = 0) PreHD2: n = 8 (UHDRS-TMS = 8)	Structural MRI	15-Objects test	Volume loss in cerebellum, prefrontal and posterior temporal cortices. Correlation with visuomotor task performance and prefrontal and occipital cortices.
Say et al., 2011 ²⁶	Controls n = 122 PreHD n = 119 HD n = 120	PreHD-A n = 62, YTO: 14.1 years PreHD-B n = 57, YTO: 8.7 years HD1 n = 75 HD2 n = 45 Disease duration: not available	Structural MRI (TRACK-HD)	Circle tracing task (direct and indirect)	No associations of task performance and loss of volume in visual and motor cortices. Only slower performance of indirect task was associated with lower grey matter volume in somatosensory cortex.
Mochel et al., 2012 ³⁹	Controls n = 15 HD n = 15	HD1 n = 15 Disease duration: not available	³¹ phosphorus NMR spectroscopy	Visual stimulation checkerboard	Unchanged metabolic concentrations during and after visual stimulation in HD.
Wolf et al., 2014 ³⁴	Controls n = 20 HD n = 20	HD1/2 n = 20 Disease duration: 3.2 years	Resting-state fMRI	SDMT VOSP	Decreased activity of left fusiform cortex, associated with lower scores on SDMT and higher disease burden in HD.
Johnson et al., 2015 ¹³	Controls n = 97 PreHD n = 109 HD n = 69	PreHD-A n = 51, YTO > 10.8 years PreHD-B n = 58, YTO < 10.8 years HD1 n = 40 HD2 n = 29 Disease duration: not available	Structural MRI (TRACK-HD)	SDMT Stroop Word Reading TMT A Map Search Mental Rotation Spot the change	Reduced occipital cortical thickness in preHD and HD patients. Except for mental rotation, poor performance on all cognitive tests was associated with thinner cortex for lingual and lateral occipital cortices in HD.
Rüb et al., 2015 ²³	Controls n = 7 HD n = 7	Age at death: 52.43 years Age at disease onset: 40.57 years Disease duration: 11.86 years	Post-mortem neuropathological study	N/A	A 32% reduction of estimated absolute nerve cell number in Brodmann area 17 in HD patients compared to controls.
Labuschagne et al., 2016 ²⁴	Controls n = 110 PreHD n = 119 HD n = 104	PreHD-A n = 55, YTO > 10.8 years PreHD-B n = 64, YTO < 10.8 years HD1 n = 59 HD2 n = 45 Disease duration: not available	Structural MRI (TRACK-HD)	Map Search Mental Rotation	Cognitive performance was associated with parieto-occipital (cuneus, calcarine, lingual) and temporal (posterior fusiform) volume and thickness in HD gene carriers.

Clinical stages of the study population are provided in the table, if information was available in the original papers. PreHD-A and PreHD-B indicate premanifest HD gene carriers classified based on the estimated time to disease onset (far or close respectively). Manifest HD gene carriers can be divided into HD stages based on their functional capacity, in which HD1 and HD2 represent early disease stages, and HD3 the most advanced stage.

Abbreviations: PreHD = premanifest HD gene carriers, HD = manifest Huntington's Disease, YTO = estimated years to disease onset, MRI = Magnetic Resonance Imaging, NMR = nuclear magnetic spectroscopy, UHDRS-TMS = Unified Huntington's Disease Rating Scale – Total Motor Score, SDMT = Symbol Digit Modality Test, VOSP = Visual Object and Space Perception, TMT = Trail Making Test, N/A = Not Applicable

TABLE 3 Visual cognitive domains and associated neuropsychological assessments

Domain	Definition	Assessments
Visual perception		
Color perception	Perception of colors and ability to distinguish contrast	Ishihara Color Test, Contrast Sensitivity Test
Visual recognition	Recognition of faces and facial expression of emotions	Emotion Recognition Tasks
Visual organization	Perceptual reorganizing to distinguish incomplete fragmented visual stimuli	Closure Speed, Visual Object and Space Perception battery, Hooper Visual Organization Test
Visuospatial function		
Visual attention	Awareness of visual stimuli	Line Bisection Test, Cancellation Task, Visual Search and Attention Test, Embedded Figures, Map Search, Trail Making Test A
Visual scanning	Ability to acquire information regarding environment and spatial distance (e.g. for reading, writing, telling time)	Counting dots, Visual Scanning Test, Mental Rotation, Street Map Task, Symbol Digit Modalities Test, Digit Symbol Task
Visual working memory		
Visual recognition memory	Ability to retrieve visuospatial information from memory	Recurring Figures Test, Family Pictures (subtest of Wechsler Memory Scale-III), Trail Making Test B
Visual Recall	Reproduction of a design or object	Visual Reproduction Task (immediate and delayed recall), Spot the change Task
Visuospatial Learning	Learning and recall memory of visuospatial stimuli	Visuospatial Learning Test, Trail Learning Test
Visuoconstruction		
Visuoconstructive ability	Spatial ability to reproduce complex geometric designs	Rey-Osterrieth Complex Figure Test
Visuomotor function		
Visuomotor	Ability to maintain gaze on a moving target	Circle-Tracing Task (direct and indirect feedback), 15-Objects task

Based on Lezak et al., 2004⁵⁶

memory accounts for the recall of visuospatial stimuli. Visuoconstruction is defined as the ability to organize and manually manipulate spatial information to make a design, i.e. copying a complex figure or constructing three-dimensional figures from two-dimensional units.⁵⁶ Last, visuomotor function involves visual scanning and tracking of movement and the ability to maintain gaze on a moving target.⁵⁷ A summary of the reviewed literature regarding visual cognition is presented in Table 4.

3.3.1. Visual perception

The perception of colors, contrast, and motion, the recognition of objects, facial expression, and emotions, and conceptual organizing skills are all classified as visual perception. The lateral geniculate nucleus is involved in the processing of colors and contrast resolution before further functional differentiation occurs in the striate cortex.⁵⁸ Limited studies have been performed that address basic visual processing of contrast and motion in HD. Patients with HD showed impaired contrast sensitivity for moving stimuli,⁵⁹ while contrast sensitivity for static stimuli seems unaffected in HD patients.^{59,60} This might indicate involvement of the (pre)-striate visual cortex early in the disease process.⁵⁹ Still, no structural or functional neuroimaging studies have been performed that confirm this hypothesis.

Conceptual organization or visual object perception has been examined in several studies in patients with HD, but methods differ and findings are inconsistent. One study assessed visuo-perceptive function using the Hooper Visual Organization test in premanifest and manifest HD gene carriers, for which participants needed to recognize and name the object that is displayed on a card in fragmented form.⁶¹ Both early and more advanced HD patients scored significantly lower on this task compared to premanifest and control individuals. No differences in scores were observed between premanifest HD and controls. Remarkably, 70% of the premanifest individuals scored above 25 points (maximum of 30 points), while only 20% of the early manifest individuals reached this score, which illustrates the impaired task performance in manifest HD.⁶¹ Three other studies assessed visuo-perceptual skills in HD patients using the Visual Object and Space Perception (VOSP) battery, which measures object recognition and space perception separately in eight subtests with minimal involvement of motor skills and executive functioning.^{34,62,63} A cross-sectional study showed that out of all the subtests of the VOSP, only the performance on the object decision task was impaired in HD patients (39% of the HD patients performed below the fifth percentile of the control norm),⁶³ while another cross-sectional study found an overall worse performance on the silhouettes and object decision subtasks in early HD patients compared to

controls.³⁴ Brain activity of the fusiform gyrus did not predict the performance on visual object perceptual tests,³⁴ which is unexpected since the fusiform gyrus is thought to be involved in object and facial recognition.⁶⁴ A longitudinal study that assessed in addition to visual cognition also executive function, language, learning, and intelligence, reported a decline in performance for object recognition and space perception in HD patients after a follow-up period of 2.5 years, measured using sum scores for all object recognition tasks and space perception tasks.⁶²

In contrast, a small study in 10 HD patients reported that the identification of individual objects and objects adjacent to each other remained unaffected, while deficits were found in the simultaneous perception of multiple objects that were presented in an overlapping manner.⁶⁵

The perception of motion can be measured using a motion discrimination task, in which participants need to decide whether dots moved to the right or left in a field of noise. Here, findings are also inconsistent, when assessing a motion discrimination task in HD patients.^{59,60} In a pilot study of 8 HD patients and 9 premanifest HD gene carriers, the discrimination of motion trajectories in noise was impaired in the manifest HD group, but not in premanifest HD gene carriers.⁶⁰ In a subsequent study with a larger sample (201 controls, 52 premanifest and 36 manifest HD gene carriers), no differences were observed in the performance on this task among different HD gene carrier groups and controls.⁵⁹ The authors explained these different findings because of possible differences in the severity of HD participants that were included in the two studies.⁵⁹ Therefore, no conclusions can be drawn from this limited evidence on the motion perception performance in HD patients.

In contrast, visuo-perceptual recognition of facial expressions and emotions has been extensively studied in HD patients. Several reviews have recently evaluated the current literature on emotion recognition in HD.⁶⁶⁻⁶⁸ Briefly, the ability to recognize basic emotions from facial expressions has consistently been found to be impaired in both manifest and premanifest HD, especially for negative emotions such as anger, disgust, and fear.^{67,68} Impairments in facial emotion recognition in HD seem to be associated with regional loss of brain tissue, altered brain activation, and changes in brain connectivity.⁶⁸ A large study by the Predict-HD study group found that, in premanifest HD gene carriers, deficits in negative emotion recognition were associated with atrophy of the fronto-striatal network, the precuneus and occipital regions, such as the lingual gyrus, cuneus, lateral occipital cortex, and middle-temporal cortex.⁶⁹

3.3.2. Visuospatial function

The dorsal temporo-occipital pathway is suggested to be involved in visuospatial cognition.¹ Visuospatial attention involves the awareness of visual stimuli to perceive objects, while visuospatial scanning is necessary to acquire information regarding the environment, spatial distance and relationship among objects. Therefore, visuospatial processing is important for daily functioning, such as walking, driving, reading, and writing, and is often essential when measuring other cognitive domains.

Eight studies specifically investigated visuospatial function, visual attention or visual scanning in HD patients.^{13,24,34,61,70-73} One study assessed a wide range of visuospatial tasks in HD patients and controls.⁷⁰ Factor analyses showed that overall visuospatial processing capacity (measured using the performance subscales of the WAIS-R, Embedded Figures Test, and Mental Reorientation Test) and spatial manipulation (involving performance on the Mental Rotation and Street Map task) were impaired in HD, whereas spatial judgment (comprising of scores of the Rod-And-Frame Test and In-Front-Of Test) appeared unaffected.⁷⁰

Another study also examined the ability to spatially rotate a mental image (i.e. a mental rotation task) in patients with HD and patients with Alzheimer's disease (AD).⁷¹ HD patients were able to mentally rotate a figure through space, but showed slowing in information processing speed (i.e. bradyphrenia) resulting in a worse performance, whereas in AD patients the accuracy, not the speed, was impaired compared to their respective age-matched controls.⁷¹ Other more recent studies, however, reported worse performance on the Mental Rotation task in both premanifest and manifest HD gene carriers compared to controls, with poorer performance in the more advanced disease stages that was not influenced by bradyphrenia.^{13,24}

Different neuropsychological assessments were used to measure visual scanning and attentional deficits in HD patients in several studies.^{24,34,61,72,73} The Cancellation Task and Line Bisection Test did not show any differences in visual attentional function between healthy controls, premanifest, and manifest HD gene carriers.⁶¹ In a longitudinal study, decline in performance on the Map Search attentional task was only observed in more advanced HD patients after a 12 months follow-up period.²⁴

The Symbol Digit Modalities Test (SDMT) and the Trail Making Test (TMT) are widely used assessments to measure cognitive function in HD patients.^{62,74,75} The SDMT is found to be the most sensitive cognitive task in large longitudinal studies to detect progressive change in HD gene carriers.^{62,74,75} An explanation for this might be that the SDMT is a demanding task that requires a high degree of visual scanning and memory, processing speed, object recognition, oculomotor function and motor speed. One study assessed the association between cognitive task performance and visual brain

activity changes.³⁴ Here, early HD patients' lower fusiform activity was associated with worse performance on the SDMT, which is not surprising as the SDMT also involves the recognition of symbols and shapes.³⁴

Among a large group of 767 premanifest HD gene carriers, the TMT part A was associated with visual search and sustained attention, whereas TMT part B was associated with executive functioning, processing speed and working memory.⁷² Premanifest HD gene carriers close to disease onset performed worse on both TMT part A and part B. Interestingly, only part A scores seemed to be mildly affected by motor disturbances.⁷²

Only one study specifically assessed visual scanning in premanifest and manifest HD gene carriers using the Digit Symbol Subtest, a subscale of the Wechsler Adult Intelligence Scale - Revised (WAIS-R), and quantitative eye movements.⁷³ While all participants used a similar visual scanning strategy, slowing and irregular visual scanning in both premanifest and manifest HD was related to worse performance on the Digit Symbol task compared to controls.⁷³ Although this might suggest deficits in visual scanning in early disease stages, the influence of motor impairment on cognitive performance was not taken into account.

Overall, visuospatial function in HD patients has been examined using various cognitive batteries, making it difficult to directly compare study findings. Some visual attentional tasks (such as the Mental Rotation, TMT part A and the SDMT) revealed impaired performance in both premanifest and manifest HD, while other tasks (such as the Line Bisection Test and Cancellation Task) showed no differences in task performance.

3.3.3. Visual working memory

Visual working memory accounts for the ability to retrieve visuospatial information from memory, and involves learning and recall of visuospatial stimuli. Six studies assessed visuospatial memory function in HD patients.^{13,63,76-79}

Compared with other neurodegenerative disorders, such as Alzheimer's' disease (AD) and Parkinson's disease (PD), patients with HD showed impairments in spatial working memory and visuospatial learning.^{76,77} In these studies, visuospatial working memory was determined as the ability to recall a sequence of squares at the right location on a screen⁷⁶, the recognition of abstract visual stimuli⁷⁶, and the recall of the right naming and location of sketched objects on cards.⁷⁷ Patients with HD were better at correctly naming the objects than recalling their spatial location, whereas the opposite was true for the AD and PD patients.⁷⁷ This was confirmed by a study in early stage HD patients that measured visual object and visuospatial working memory using an extensive battery of cognitive visual assessments.⁶³ Here, deficits in pattern and spatial

recognition memory, decreased reaction times in visual search, and an impaired spatial working memory were found in HD patients, while visual object working memory showed no changes compared with healthy controls.

To evaluate the influence of slowness of execution (bradykinesia), thinking (bradyphrenia) or motor speed on visual memory task performance, one study assessed accuracy and reaction times between different disease stages on a visual comparison task to spot the change of randomly selected colors between images.⁷⁸ Premanifest HD gene carriers close to disease onset and early stage HD patients showed lower working memory accuracy and slower response times compared to controls. As premanifest individuals without motor signs also showed impairments in task performance, the findings of this study imply that results are influenced by a decrease in cognitive performance and impaired information processing, rather than reduced motor speed.⁷⁸

A more recent study also reported poorer performance on the 'Spot the change' task in more advanced disease stages.¹³ In addition, task performance was associated with thickness of the lateral occipital cortex and lingual gyrus, while a non-visual motor task showed no associations with the visual cortex.¹³ This implies that the changes in occipital thickness are specific to visual cognition rather than general disease progression.¹³ In another study, visuospatial memory function was evaluated in HD patients and healthy controls using the Visual Spatial Learning Test (VSLT), which is a nonverbal memory test that measures immediate and delayed memory for designs and locations without requiring motor or language skills.⁷⁹ Compared to controls, premanifest HD gene carriers showed, besides an impaired recall for associations between object and spatial location, no deficits in the memory for objects, while HD patients showed impairments on all measures.⁷⁹

Generally, retrieving visuospatial information from memory seems to be inaccurate in early manifest stages and even in premanifest HD gene carriers close to disease onset, whereas the recognition and recall of naming objects from memory appears to be less affected.

3.3.4. Visuoconstructive abilities

Visuoconstruction involves the spatial ability to reproduce complex geometric designs. Interpretation of visuoconstructive deficits can be difficult because tests that are used to measure visuoconstruction often involve other domains, such as visuospatial, executive and motor functioning. Only two studies investigated visuoconstructive skills in HD patients by assessing the ability to copy a complex figure using the Rey-Osterrieth Complex Figure Test.^{61,80} The first study explored these visuoconstructive abilities of HD patients with age-matched controls for HD by recording the accuracy and time

to copy the design.⁸⁰ Here, patients with HD showed no differences in accuracy but needed more time to complete the test compared to their matched control group, which may have been due to the presence of motor disturbances.⁸⁰ A second study examined the same part of the Rey-Osterrieth Complex Figure test, in premanifest and manifest HD gene carriers but measured the correct elements that were copied instead of evaluating the accuracy of the lines to minimize motor interference.⁶¹ In HD patients, total correct scores declined in more advanced disease stages. Furthermore, early HD patients showed mild deficits in visuoconstruction but this was not significant compared with premanifest HD gene carriers.

Based on this literature, visuoconstructive skills become impaired in the more advanced disease stages. Still, more studies are necessary to fully determine the extent of these impairments and the possible influence of motor signs and bradyphrenia.

3.3.5. *Visuomotor function*

Visuomotor deficits in the tracking of movements and the ability to maintain gaze on a moving target have been reported in HD patients.^{25,26,81,82}

In two studies using a circle-tracing task to measure indirect and direct visual feedback, early HD patients were slower, less accurate and needed more time to detect errors.^{26,82}

This is consistent with another study using a visual tracking task that showed a higher error rate and longer time scores in HD patients, especially in the non-dominant hand, compared to controls.⁸¹ Premanifest HD gene carriers also showed less accuracy in completing the task compared to controls, however, no associations were found between visuomotor integration deficits in HD gene carriers and volumes of visual and motor cortices.²⁶ This might be explained by the multifactorial demands of the circle-tracing task that was used as an outcome measure.

To the contrary, another study found correlations between impaired visuomotor performance in premanifest HD gene carriers and decreased volumes of the prefrontal and occipital cortices.²⁵ In this study, visuomotor integration performance was measured using the time to complete the 15-objects test that contains 2 figures, each with overlapping drawings of 15 different items.²⁵ This task, however, can also be used to assess visual perception and in addition, it remains uncertain if other signs of HD, such as bradyphrenia, motor and eye movement disturbances, or visuoperceptual deficits rather than visuomotor dysfunction may have influenced the results of these studies.

TABLE 4 Overview of current literature on visual cognition in HD

	Study population	Clinical HD disease stage	Domain	Assessments	Main significant finding
Brouwer et al., 1984 ⁸⁰	Controls n = 25 * HD n = 10 AD n = 14	Disease duration: 3.4 years	Visuoperceptual, memory and constructive function	Road Map Test Rey-Osterrieth Complex Figures Mosaic Comparisons Test Stylus Maze Test	Impairments in visual discrimination, no difference in visuoconstructive ability and route learning in HD compared to controls
Oepen et al., 1985 ⁸¹	Controls n = 63 HD n = 15 HD at risk n = 17	YTO: not available (before genetic testing) Disease duration: not available	Visuomotor function	Continuous and discontinuous drawing/tracking task	Significant higher error rate (less accuracy) and longer time scores in HD compared to controls, especially in non-dominant hand
Mohr et al., 1991 ⁷⁰	Controls n = 19 HD n = 20	Disease duration: 6 years	Visuospatial function	Performance subtests of WAIS-R Embedded Figures Test Rod-and-Frame Test Mental Rotation Test Street Map Test Mental Reorientation Test In-Front-Of Test	Impaired visuospatial processing capacity and spatial manipulation in HD, no impairments in spatial judgment (Rod-and-Frame test and In-Front-Of Test) in HD compared to controls
Lange et al., 1995 ⁷⁶	Controls n = 85 * AD n = 13 HD n = 10	Disease duration: not available	Visuospatial learning and memory	Pattern and Spatial Recognition Test Matching-to-Sample test	Worse performance on spatial pattern recognition task and Spatial recognition of abstract stimuli
Gomez-Tortosa et al., 1996 ⁶¹	Controls n = 11 PreHD n = 15 HD n = 35	YTO: not available Disease duration: not available HD1 n = 13 HD2 n = 9 HD3 n = 13	Visual attention, visuoconstruction, and visuoperception	Cancellation task Line Bisection Rey-Osterrieth Complex Figures Hooper Visual Organization Test	Impaired visuoperception in HD patients, no significant differences between preHD and controls
Lawrence et al., 2000 ⁶³	HD-a n = 19 vs. Controls-a n = 20 HD-b n = 19 vs. Controls-b n = 20 HD-c n = 21 vs. Controls-c n = 17	Age at onset: 42.5 years Disease duration: 5 years	Visual object and visuospatial memory	HD-a: DMTS, VSMTS, VOSP HD-b: PAL HD-c: Pattern and Spatial recognition test, spatial working memory task	Deficits in pattern and spatial recognition memory, reaction times in visual search, and spatial working memory

TABLE 4 Continued

	Study population	Clinical HD disease stage	Domain	Assessments	Main significant finding
O'Donnell et al., 2003 ⁶⁰	Controls n = 20 PreHD n = 9 HD n = 8	YTO: not available Disease duration: 1 – 2 years	Early stage visual processing	Digit Symbol test Contrast sensitivity Motion discrimination	Impaired motion discrimination in HD, not in preHD
Brandt et al., 2005 ⁷¹	Controls n = 147 AD n = 143 PD n = 77 HD n = 110	Disease duration: 7.7 years	Visuospatial object and location memory	'Hopkins Board' (object identity and recall of spatial locations)	Impaired delayed recall of spatial location of items in HD compared to AD and PD
Lemay et al., 2005 ⁸²	Controls n = 13 HD n = 13	Disease duration: 0.5 – 6 years	Visuomotor function	Circle tracing task (direct and indirect)	Early HD patients were slower and deviated more than controls for the indirect visual feedback task. No differences in direct visual feedback
Lineweaver et al., 2005 ⁷¹	Controls n = 40 * AD n = 18 HD n = 18	Disease duration: not available	Visuospatial function	Mental Rotation task	Decreased speed in mental rotation task in HD and reduced accuracy in AD, compared to controls
Finke et al., 2007 ⁶⁵	Controls n = 15 HD n = 10	Age at onset: 37.4 years Disease duration: 4.6 years	Visual attention Object recognition	Simultaneous perception task	Simultaneous perception of multiple object in overlapping manner was impaired in HD, identification of single objects or objects adjacent to each other was unaffected in HD
Blekher et al., 2009 ⁷³	Controls n = 23 PreHD n = 21 HD n = 19	YTO: not available Disease duration: not available	Visual scanning	Digit Symbol test Visual scanning using eye movements	Slow and irregular visual scanning related to worse cognitive performance in preHD and HD
Gomez-Anson et al., 2009 ²⁵	Controls n = 21 PreHD n = 22	YTO: not available PreHD1: n = 12 (UHDRS-TMS = 0) PreHD2: n = 8 (UHDRS-TMS = 8)	Visuomotor function	15-Objects test Stroop TMT A and B Digit Symbol test Rey's Complex Figure Benton's Line Orientation test	PreHD performed slower on the 15-Objects test than controls. In total, 13 preHD (59%) had impaired performance in at least one of the other assessments
O'Rourke et al., 2011 ⁷²	Controls = 217 PreHD = 767	PreHD Far n = 297, YTO > 15 years PreHD Mid n = 287, YTO: 9 – 15 years PreHD Near n = 183, YTO: < 9 years	Perceptual processing, visual scanning and attention	TMT part A TMT part B	In preHD, TMT part A measures visual search and sustained attention, TMT part B measures cognitive flexibility and working memory
Say et al., 2011 ²⁶	Controls n = 122 PreHD-A n = 62 PreHD-B n = 57	PreHD-A n = 62, YTO: 14.1 years PreHD-B n = 57, YTO: 8.7 years HD1 n = 75	Visuomotor function	Circle tracing task (direct and indirect)	Less accuracy and slower task performance in both circle-tracing conditions for early and

TABLE 4 Continued

	Study population	Clinical HD disease stage	Domain	Assessments	Main significant finding
	HD1 n = 75 HD2 n = 45	HD2 n = 45 Disease duration: not available			preHD. With indirect condition, early and preHD required longer to detect and correct errors compared to controls
Dumas et al., 2012 ⁷⁸	Controls n = 122 PreHD n = 120 HD n = 121	PreHD-A n = 62, YTO: 14 years PreHD-B n = 58, YTO 9 years HD1 n = 77, disease duration: 5 years HD2 n = 44, disease duration: 8 years	Visuospatial working memory	Spot the change	Slow response times in preHD close to disease onset and early manifest HD
Wolf et al., 2014 ³⁴	Controls n = 20 HD n = 20	HD1/2 n = 20 Disease duration: 3.2 years	Visual scanning and visual object function	SDMT VOSP - subtests for object function	Decreased performance on all tasks in HD, lower fusiform activity only associated with worse performance on SDMT in HD
Johnson et al., 2015 ¹³	Controls n = 97 PreHD n = 109 HD n = 69	PreHD-A n = 51, YTO > 10.8 years PreHD-B n = 58, YTO < 10.8 years HD1 n = 40 HD2 n = 29 Disease duration: not available	Visual scanning, visuospatial processing and attention, visual working memory	SDMT Stroop Word Reading Trail Making Task part A Map Search Mental Rotation Spot the Change VLST	Worse performance on all tasks in advanced HD. Except for Mental Rotation, relation between task performance and occipital thickness in HD, see also Table 2
Pirogovsky et al., 2015 ⁷⁹	Controls n = 31 PreHD n = 30 HD n = 19	YTO: not available Age at onset HD: 44.7 years Disease duration: not available	Visuospatial memory	VLST	Impaired recall and recognition of designs in HD, object-place association memory impaired in preHD
Labuschagne et al., 2016 ²⁴	Controls n = 110 PreHD n = 119 HD n = 104	PreHD-A n = 55, YTO > 10.8 years PreHD-B n = 64, YTO < 10.8 years HD1 n = 59 HD2 n = 45 Disease duration: not available	Visuospatial attention / processing	Map Search Mental rotation	Lower scores on Map Search and Mental rotation task in all groups compared to controls. At follow-up, only declined performance in HD

* Controls were age-matched for AD and HD separately

Clinical stages of the study population are provided in the table, if information was available in the original papers. PreHD-A and PreHD-B indicate premanifest HD gene carriers classified based on the estimated time to disease onset (far or close respectively). Manifest HD gene carriers can be divided into HD stages based on their functional capacity, in which HD1 and HD2 represent early disease stages, and HD3 the most advanced stage.

Abbreviations: PreHD = premanifest HD gene carriers, HD = Huntington's Disease patients, YTO = estimated years to disease onset, Digit: Symbol test is a subscale of the Wechsler Adult Intelligence Scale - Revised (WAIS-R), SDMT = Symbol Digit Modality Test, VOSP = Visual Object and Space Perception, VLST = Visual Spatial Learning Test, TMT = Trail Making Test, PAL = Paired-Associate Learning, DMTS = Delayed Matching-To-Sample, VSMTS = Visual Search Matching-To-Sample



4. DISCUSSION

This review presents an overview regarding changes of the visual system in premanifest and manifest HD gene carriers. Although the visual cortex was not the main focus of many neuroimaging studies, there is increasing evidence of early neurodegeneration of the posterior cerebral cortex. Based on the current literature, alterations were primarily found in the associative visual areas, such as the lingual and fusiform gyri, and the lateral occipital cortex. The cuneus and primary visual cortex appear to be affected in more advanced disease stages. As changes of the visual association cortex were already detectable in the pre-symptomatic and early disease stages, this implies that the visual cortex might be an early marker of disease progression that can be used as an outcome measure in disease-modifying intervention trials.

Clinical visual deficits or visual hallucinations are not commonly reported as typical features of HD. Still, studies assessing visual cognitive function in HD report impairments in several domains, specifically tasks involving visual object perception, facial emotion recognition and visuospatial processing and working memory.

Studies assessing driving competence in HD patients also showed that visual processing speed, visual scanning, and visual attention are more sensitive predictors of performance on on-road driving assessments, compared to motor functioning.^{83,84}

The assessment of visual cognitive impairment is therefore of clinical importance as it can have implications in daily functioning, such as the impact on driving performance, the use of electronic devices and subsequently affects participating in social activities. For example, the impairment to recognize negative facial emotions, such as anger, disgust and fear, could affect communication and social relationships.⁶⁸ Also, patients with HD might have a higher risk of falling or experience difficulty with walking because of visual perceptual and visuomotor deficits. In addition, visual cognitive impairment can influence overall cognitive performance.

Visual cognitive impairments have primarily been found in the manifest disease stage, although visuospatial working memory deficits and changes in facial emotion recognition are also reported in HD gene carriers prior to clinical motor onset. Neuropsychological studies in HD patients, however, have used heterogeneous cognitive batteries to examine visual cognition involving various visual skills, making a direct comparison between studies difficult. This was particularly found in studies assessing visual attention in HD, where the Map Search, TMT part A, SDMT, Stroop, Digit Symbol task, Line Bisection test and Cancellation task were all used to measure visual attention. A standardized battery of cognitive tasks focusing on visual processing skills might provide more information regarding the specific underlying deficits. Using

cognitive tasks with minimal motor involvement is recommended to reduce the possible influence of other HD related signs, such as the Visual Object and Space Perception battery, the Visual Spatial Learning test and the Stroop tasks.

Visual cognitive impairment in HD gene carriers has previously been interpreted as a result of disturbances in the fronto-striatal network.^{57,63,80} However, more recent studies suggest that degeneration of cortical-striatal circuits that are linked to the associative cortical regions in the parietal lobe contribute to visual memory and visuospatial impairments associated with HD.^{77,79}

We believe that the posterior cerebral cortex is one of the first cortical areas that undergoes changes in early stages of HD. Therefore, systematic and preferably longitudinal assessment of the visual cortex in HD is warranted, to improve the understanding of structural and functional alterations in the visual pathway in patients with HD.

Linking structural changes of the visual cortex with functional cognitive decline over time can provide valuable information on disease progression and cortical degeneration. The use of a standardized battery of visual cognitive tasks might additionally provide more detailed information regarding impairments in specific visual domains. To reduce interference on task performance, we are of the opinion that visual neuropsychological tasks should be selected that are not influenced by motor speed, bradyphrenia or language skills.

To summarize, based on the current literature, early involvement of the visual cortex in the neurodegenerative process in HD has been reported. Structural, metabolic, and functional changes are primarily found in the associative cortices, such as the cuneus, lingual gyrus, and fusiform gyrus. Further research is nevertheless required to provide more insight into the pathophysiological changes of the posterior cerebral cortex in HD. Clinical visual deficits or visual hallucinations are not commonly reported as typical features of HD. However, visual cognitive impairments are seen in several domains, specifically tasks involving visual object perception, facial emotion recognition and visuospatial processing and working memory were impaired in pre-symptomatic and early disease stages. Because heterogeneous cognitive batteries were used, a direct comparison between studies was difficult. We are of the opinion that tasks with minimal motor involvement are most recommended for the assessment of visual cognitive function in future clinical trials, such as the Visual Object and Space Perception battery, the Visual Spatial Learning test, and the Stroop tasks. In addition, a motor task without a visual component, such as the Paced Tapping task, can be included in the test battery as a general proxy for disease progression.⁷⁵ In this way, the relationship between visual task performance and visual cortical changes can be measured exclusively.^{13,75}

Investigating the association of brain structure and function with visual cognition in HD using a standardized visual cognitive battery and different imaging modalities can quantify alterations and hopefully link structural posterior brain changes to functional impairments.

REFERENCES

1. Kravitz DJ, Saleem KS, Baker CI, Mishkin M. A new neural framework for visuospatial processing. *Nat Rev Neurosci.* 2011;12:217-230.
2. Tootell RBH, Tsao D, Vanduffel W. Neuroimaging weighs in: Humans meet macaques in "primate" visual cortex. *J Neurosci.* 2003;23(10):3981-3989.
3. Gustavo De Moraes C. Anatomy of the Visual Pathways. *J Glaucoma.* 2013;22(5):2-7.
4. Wandell BA, Dumoulin SO, Brewer AA. Visual field maps in human cortex. *Neuron.* 2007;56:366-383.
5. Prasad S, Galetta SL. Anatomy and physiology of the afferent visual system. In: *Handbook of Clinical Neurology.* Volume 102.; 2011:3-19.
6. Wichmann W, Müller-forell W. Anatomy of the visual system. *Eur J Radiol.* 2004;49:8-30.
7. Tobimatsu S, Celesia GG. Studies of human visual pathophysiology with visual evoked potentials. *Clin Neurophysiol.* 2006;117(7):1414-1433.
8. Ungerleider LG, Haxby J V. "What" and "where" in the human brain. *Curr Opin Neurobiol.* 1994;4:157-165.
9. Barton JJ. Higher cortical visual function. *Curr Opin Ophthalmol.* 1998;9(VI):40-45.
10. Braddick O, Atkinson J. Development of human visual function. *Vision Res.* 2011;51(13):1588-1609.
11. Tabrizi SJ, Langbehn DR, Leavitt BR, et al. Biological and clinical manifestations of Huntington's disease in the longitudinal TRACK-HD study: cross-sectional analysis of baseline data. *Lancet Neurol.* 2009;8(9):791-801.
12. Nopoulos PC, Aylward EH, Ross CA, et al. Cerebral cortex structure in prodromal Huntington disease. *Neurobiol Dis.* 2010;40(3):544-554.
13. Johnson EB, Rees EM, Labuschagne I, et al. The impact of occipital lobe cortical thickness on cognitive task performance: An investigation in Huntington's Disease. *Neuropsychologia.* 2015;79:138-146.
14. The Huntington's Disease Collaborative Research Group. A novel gene containing a trinucleotide repeat that is expanded and unstable on Huntington's disease chromosomes. *Cell.* 1993;72(6):971-983.
15. Roos RAC. Huntington's disease: a clinical review. *Orphanet J Rare Dis.* 2010;5(1):40.
16. van Duijn E, Craufurd D, Hubers AAM, et al. Neuropsychiatric symptoms in a European Huntington's disease cohort (REGISTRY). *J Neurol Neurosurg Psychiatry.* 2014;85(12):1411-1418.
17. Dumas EM, van den Bogaard SJA, Middelkoop HAM, Roos RAC. A review of cognition in Huntington's disease. *Front Biosci.* 2013;S5:1-18.
18. Bates GP, Dorsey R, Gusella JF, et al. Huntington disease. *Nat Rev Dis Prim.* 2015;1:1-21.

19. Vonsattel JP, Myers RH, Stevens TJ, Ferrante RJ, Bird ED, Richardson EP. Neuropathological classification of Huntington's disease. *J Neuropathol Exp Neurol*. 1985;44(6):559-577.
20. Thu DCV, Oorschot DE, Tippett LJ, et al. Cell loss in the motor and cingulate cortex correlates with symptomatology in Huntington's disease. *Brain*. 2010;133(4):1094-1110.
21. Nana AL, Kim EH, Thu DCV, et al. Widespread heterogeneous neuronal loss across the cerebral cortex in Huntington's disease. *J Huntingtons Dis*. 2014;3:45-64.
22. Waldvogel HJ, Kim EH, Thu DCV, Tippett LJ, Faull RLM. New perspectives on the neuropathology in Huntington's disease in the human brain and its relation to symptom variation. *J Huntingtons Dis*. 2012;1:143-153.
23. Rüb U, Seidel K, Vonsattel JP, et al. Huntington's disease (HD): Neurodegeneration of Brodmann's primary visual area 17 (BA17). *Brain Pathol*. 2015;25(6):701-711.
24. Labuschagne I, Cassidy AM, Scahill RI, et al. Visuospatial processing deficits linked to posterior brain regions in premanifest and early stage Huntington's disease. *J Int Neuropsychol Soc*. 2016;22:595-608.
25. Gómez-Ansón B, Alegret M, Muñoz E, et al. Prefrontal cortex volume reduction on MRI in preclinical Huntington's disease relates to visuomotor performance and CAG number. *Park Relat Disord*. 2009;15(3):213-219.
26. Say MJ, Jones R, Scahill RI, et al. Visuomotor integration deficits precede clinical onset in Huntington's disease. *Neuropsychologia*. 2011;49(2):264-270.
27. Rosas HD, Salat DH, Lee SY, et al. Cerebral cortex and the clinical expression of Huntington's disease: complexity and heterogeneity. *Brain*. 2008;131(4):1057-1068.
28. Scahill RI, Hobbs NZ, Say MJ, et al. Clinical impairment in premanifest and early Huntington's disease is associated with regionally specific atrophy. *Hum Brain Mapp*. 2013;34(3):519-529.
29. Aylward EH, Nopoulos PC, Ross CA, et al. Longitudinal change in regional brain volumes in prodromal Huntington disease. *J Neurol Neurosurg Psychiatry*. 2011;82(4):405-410.
30. Hobbs NZ, Henley SMD, Ridgway GR, et al. The progression of regional atrophy in premanifest and early Huntington's disease: a longitudinal voxel-based morphometry study. *J Neurol Neurosurg Psychiatry*. 2010;81(7):756-763.
31. Klöppel S, Draganski B, Golding CV, et al. White matter connections reflect changes in voluntary-guided saccades in pre-symptomatic Huntington's disease. *Brain*. 2008;131:196-204.
32. Paulsen JS. Functional imaging in Huntington's disease. *Exp Neurol*. 2009;216(2):272-277.
33. Rees EM, Scahill RI, Hobbs NZ. Longitudinal neuroimaging biomarkers in Huntington's disease. *J Huntingtons Dis*. 2013;2:21-39.
34. Wolf RC, Sambataro F, Vasic N, et al. Visual system integrity and cognition in early Huntington's disease. *Eur J Neurosci*. 2014;40(2):2417-2426.
35. Dumas EM, van den Bogaard SJA, Hart EP, et al. Reduced functional brain connectivity prior to and after disease onset in Huntington's disease. *NeuroImage Clin*. 2013;2(1):377-384.

36. Seibert TM, Majid DSA, Aron AR, Corey-Bloom J, Brewer JB. Stability of resting fMRI interregional correlations analyzed in subject-native space: a one-year longitudinal study in healthy adults and premanifest Huntington's disease. *Neuroimage*. 2012;59(3):2452-2463.
37. Odish OFF, van den Berg-Huysmans AA, van den Bogaard SJA, et al. Longitudinal resting state fMRI analysis in healthy controls and premanifest Huntington's disease gene carriers: A three-year follow-up study. *Hum Brain Mapp*. 2014;119:110-119.
38. Sappey-Marinier D, Calabrese G, Fein G, Hugg JW, Biggins C, Weiner MW. Effect of photic stimulation on human visual cortex lactate and phosphates using ¹H and ³¹P Magnetic Resonance Spectroscopy. *J Cereb Blood Flow Metab*. 1992;12:584-592.
39. Mochel F, N'Guyen TM, Deelchand D, et al. Abnormal response to cortical activation in early stages of Huntington disease. *Mov Disord*. 2012;27(7):907-910.
40. Clark VP, Lai S, Deckel AW. Altered functional MRI responses in Huntington's disease. *Neuroreport*. 2002;13(5):40-43.
41. Kim JS, Reading SAJ, Brashers-Krug T, Calhoun VD, Ross CA, Pearlson GD. Functional MRI study of a serial reaction time task in Huntington's disease. *Psychiatry Res - Neuroimaging*. 2004;131:23-30.
42. Pagano G, Niccolini F, Politis M. Current status of PET imaging in Huntington's disease. *Eur J Nucl Med Mol Imaging*. 2016;43:1171-1182.
43. Ciarmiello A, Giovacchini G, Giovannini E, et al. Molecular imaging of Huntington's disease. *J Cell Physiol*. 2017;(232):1988-1993.
44. Roussakis AA, Piccini P. PET imaging in Huntington's disease. *J Huntingtons Dis*. 2015;4:287-296.
45. Feigin A, Leenders KL, Moeller JR, et al. Metabolic network abnormalities in early Huntington's disease: An [¹⁸F]FDG PET study. *J Nucl Med*. 2001;42:1591-1596.
46. Feigin A, Tang C, Mattis P, et al. Thalamic metabolism and symptom onset in preclinical Huntington's disease. *Brain*. 2007;(130):2858-2867.
47. Gaura V, Lavisse S, Payoux P, et al. Association between motor symptoms and brain metabolism in early Huntington disease. *JAMA Neurol*. 2017;74(9):1088-1096.
48. Ma Y, Eidelberg D. Functional imaging of cerebral blood flow and glucose metabolism in Parkinson's disease and Huntington's disease. *Mol Imaging Biol*. 2007;9(4):223-233.
49. Wolf RC, Grön G, Sambataro F, et al. Magnetic resonance perfusion imaging of resting-state cerebral blood flow in preclinical Huntington's disease. *J Cereb Blood Flow Metab*. 2011;31(9):1908-1918.
50. Hua J, Unschuld PG, Margolis RL, van Zijl PCM, Ross CA. Elevated arteriolar cerebral blood volume in prodromal Huntington's disease. *Mov Disord*. 2014;29(3):396-401.
51. Lepron E, Péran P, Cardebat D, Démonet JF. A PET study of word generation in Huntington's disease: Effects of lexical competition and verb/noun category. *Brain Lang*. 2009;110:49-60.

52. Weeks RA, Ceballos-Baumann A, Piccini P, Boecker H, Harding AE, Brooks DJ. Cortical control of movement in Huntington's disease. A PET activation study. *Brain*. 1997;120:1569-1578.
53. Deckel AW, Cohen D, Duckrow R. Cerebral blood flow velocity decreases during cognitive stimulation in Huntington's disease. *Neurology*. 1998;51(6):1576-1583.
54. Hasselbalch SG, Oberg G, Sorensen SA, et al. Reduced regional cerebral blood flow in Huntington's disease studied by SPECT. *J Neurol Neurosurg Psychiatry*. 1992;55:1018-1023.
55. Chen JJ, Salat DH, Rosas HD. Complex relationships between cerebral blood flow and brain atrophy in early Huntington's disease. *Neuroimage*. 2012;59(2):1043-1051.
56. Lezak M, Howieson D, Loring D. *Neuropsychological Assessment*. 4th ed. Oxford University Press; 2004.
57. Lasker AG, Zee DS. Ocular motor abnormalities in Huntington's disease. *Vision Res*. 1997;37(24):3639-3645.
58. Wandell BA. Computational neuroimaging of human visual cortex. *Annu Rev Neurosci*. 1999;22:145-173.
59. O'Donnell BF, Blekher TM, Weaver M, et al. Visual perception in prediagnostic and early stage Huntington's disease. *J Int Neuropsychol Soc*. 2008;14:446-453.
60. O'Donnell BF, Wilt MA, Hake AM, Stout JC, Kirkwood SC, Foroud T. Visual function in Huntington's disease patients and presymptomatic gene carriers. *Mov Disord*. 2003;18(9):1027-1034.
61. Gómez-Tortosa E, del Barrio A, Barroso T, García Ruiz PJ. Visual processing disorders in patients with Huntington's disease and asymptomatic carriers. *J Neurol*. 1996;243(3):286-292.
62. Lemiere J, Decruyenaere M, Evers-Kiebooms G, Vandenbussche E, Dom R. Cognitive changes in patients with Huntington's disease (HD) and asymptomatic carriers of the HD mutation. *J Neurol*. 2004;251(8):935-942.
63. Lawrence AD, Watkins LH, Sahakian BJ, Hodges JR, Robbins TW. Visual object and visuospatial cognition in Huntington's disease: implications for information processing in corticostriatal circuits. *Brain*. 2000;123:1349-1364.
64. Kanwisher N, McDermott J, Chun MM. The fusiform face area: A module in human extrastriate cortex specialized for face perception. *J Neurosci*. 1997;17(11):4302-4311.
65. Finke K, Schneider WX, Redel P, et al. The capacity of attention and simultaneous perception of objects: A group study of Huntington's disease patients. *Neuropsychologia*. 2007;45:3272-3284.
66. Henley SMD, Novak MJU, Frost C, King J, Tabrizi SJ, Warren JD. Emotion recognition in Huntington's disease: A systematic review. *Neurosci Biobehav Rev*. 2012;36:237-253.
67. Bora E, Velakoulis D, Walterfang M. Social cognition in Huntington's disease: A meta-analysis. *Behav Brain Res*. 2016;297:131-140.

68. Kordsachia CC, Labuschagne I, Stout JC. Beyond emotion recognition deficits: A theory guided analysis of emotion processing in Huntington's disease. *Neurosci Biobehav Rev.* 2017;73:276-292.
69. Harrington DL, Liu D, Smith MM, et al. Neuroanatomical correlates of cognitive functioning in prodromal Huntington disease. *Brain Behav.* 2014;4(1):29-40.
70. Mohr E, Brouwers P, Claus JJ, Mann UM, Fedio P, Chase TN. Visuospatial cognition in Huntington's disease. *Mov Disord.* 1991;6(2):127-132.
71. Lineweaver TT, Salmon DP, Bondi MW, Corey-Bloom J. Differential effects of Alzheimer's disease and Huntington's disease on the performance of mental rotation. *J Int Neuropsychol Soc.* 2005;(11):30-39.
72. O'Rourke JF, Beglinger LJ, Smith MM, et al. The Trail Making Test in prodromal Huntington disease: contributions of disease progression to test performance. *J Clin Exp Neuropsychol.* 2011;33(5):567-579.
73. Blekher T, Weaver MR, Marshall J, et al. Visual Scanning and Cognitive Performance in Prediagnostic and Early-Stage Huntington's Disease. *Mov Disord.* 2009;24(4):533-540.
74. Stout J, Jones R, Labuschagne I, et al. Evaluation of longitudinal 12 and 24 month cognitive outcomes in premanifest and early Huntington's disease. *J Neurol Neurosurg Psychiatry.* 2012;83:687-694.
75. Tabrizi SJ, Scahill RI, Owen G, et al. Predictors of phenotypic progression and disease onset in premanifest and early-stage Huntington's disease in the TRACK-HD study: Analysis of 36-month observational data. *Lancet Neurol.* 2013;12(7):637-649.
76. Lange KW, Sahakian BJ, Quinn NP, Marsden CD, Robbins TW. Comparison of executive and visuospatial memory function in Huntington's disease and dementia of Alzheimer type matched for degree of dementia. *J Neurol Neurosurg Psychiatry.* 1995;58:598-606.
77. Brandt J, Shpritz B, Munro C, Marsh L, Rosenblatt A. Differential impairment of spatial location memory in Huntington's disease. *J Neurol Neurosurg Psychiatry.* 2005;76:1516-1519.
78. Dumas E, Say M, Jones R, et al. Visual working memory impairment in premanifest gene-carriers and early Huntington's disease. *J Huntingtons Dis.* 2012;1:97-106.
79. Pirogovsky E, Nicoll DR, Challener DM, et al. The Visual Spatial Learning Test: Differential impairment during the premanifest and manifest stages of Huntington's disease. *J Neuropsychol.* 2015;(9):77-86.
80. Brouwers P, Cox C, Martin A, Chase T, Fedio P. Differential Perceptual-Spatial Impairment in Huntington's and Alzheimer's Dementias. *Arch Neurol.* 1984;41:1073-1076.
81. Oepen G, Mohr U, Willmes K, Thoden U. Huntington's disease: visuomotor disturbance in patients and offspring. *J Neurol Neurosurg Psychiatry.* 1985;48:426-433.
82. Lemay M, Fimbel E, Beuter A, Chouinard S, Richer F. Sensorimotor mapping affects movement correction deficits in early Huntington's disease. *Exp Brain Res.* 2005;165:454-460.

83. Devos H, Nieuwboer A, Tant M, De Weerd W, Vandenberghe W. Determinants of fitness to drive in Huntington disease. *Neurology*. 2012;79:1975-1982.
84. Jacobs M, Hart EP, Roos RAC. Driving with a neurodegenerative disorder: an overview of the current literature. *J Neurol*. 2017;264(8):1678-1696.

