



Universiteit
Leiden
The Netherlands

Optimizing triage and treatment strategies in urinary tract infection

Stalenhoef, J.E.

Citation

Stalenhoef, J. E. (2019, May 8). *Optimizing triage and treatment strategies in urinary tract infection*. Retrieved from <https://hdl.handle.net/1887/72409>

Version: Not Applicable (or Unknown)

License: [Leiden University Non-exclusive license](#)

Downloaded from: <https://hdl.handle.net/1887/72409>

Note: To cite this publication please use the final published version (if applicable).

Cover Page



Universiteit Leiden

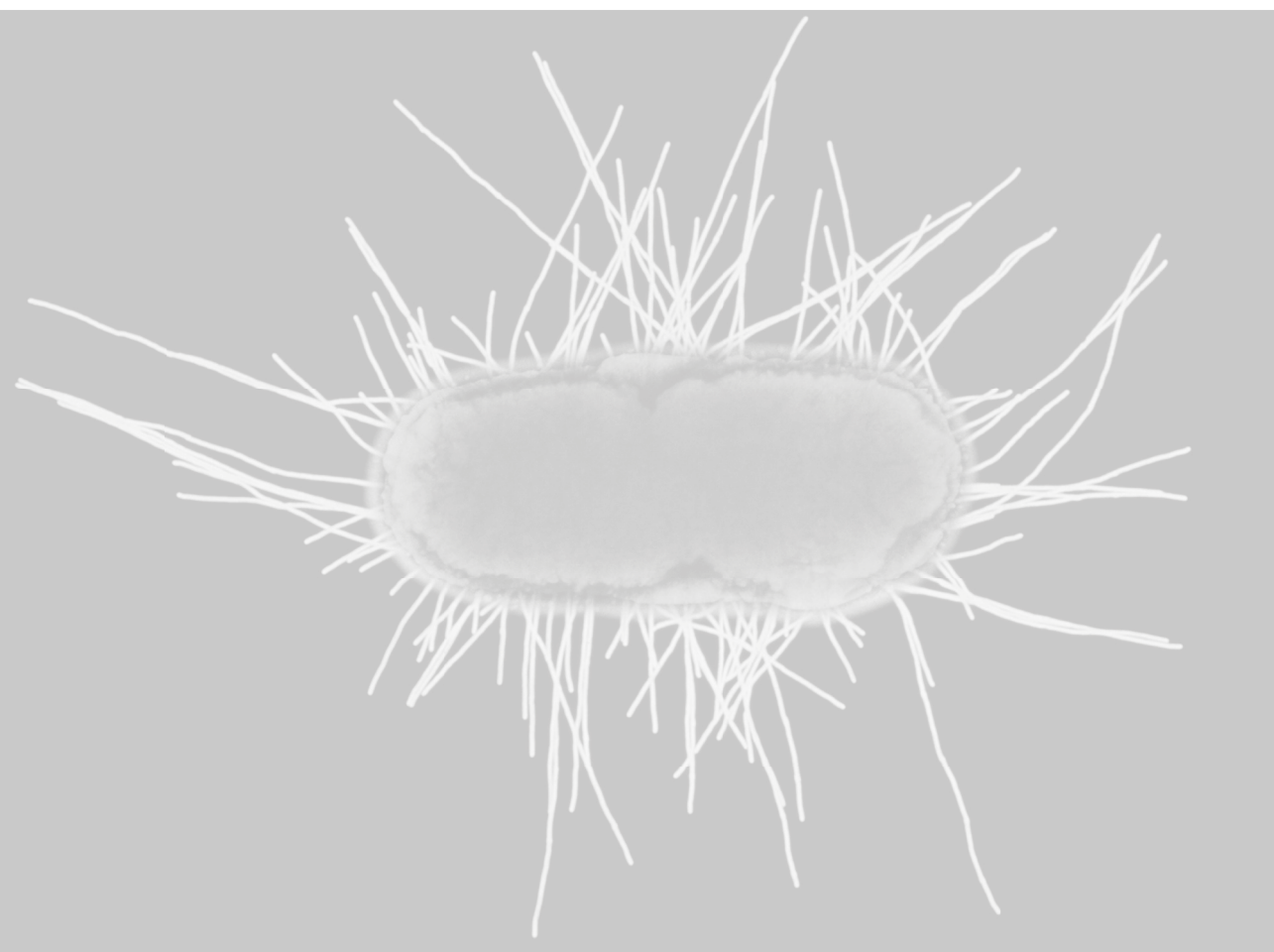


The handle <http://hdl.handle.net/1887/72409> holds various files of this Leiden University dissertation.

Author: Stalenhoef, J.E.

Title: Optimizing triage and treatment strategies in urinary tract infection

Issue Date: 2019-05-08



CHAPTER 7

Fecal microbiota transfer for multidrug resistant Gram-negatives; a clinical success combined with microbiological failure

J.E. Stalenhoef*, E.M. Terveer*, C.W. Knetsch, P.J. van 't Hof, I.N. Vlasveld, J. Keller, L.G. Visser, E.J. Kuijper

*both authors contributed equally

Open Forum Infect Dis. 2017 Mar 13;4(2):ofx047.

ABSTRACT

Combined fecal microbiota transfer (FMT) and antibiotic treatment prevented recurrences of urinary tract infections with multidrug resistant (MDR) *P. aeruginosa*, but failed to eradicate intestinal colonization with MDR *E. coli*. Based on microbiota analysis, failure was not associated with distinct diminished microbiota diversity.

INTRODUCTION

Multidrug resistance (MDR) of *Enterobacteriaceae* is an increasing worldwide problem that challenges the treatment of common bacterial infections. MDR has been declared one of the greatest challenges to global public health today, and innovative strategies for decolonization of MDR bacteria are urgently needed to reduce the use of reserve antibiotics and prevent transmission.¹ A few reports mention success with fecal microbiota transfer (FMT) to eliminate extended-spectrum β -lactamase (ESBL) producing *Enterobacteriaceae*. Failures have not been reported. We present a 34-year old patient on peritoneal dialysis, treated with FMT to eradicate a Verona Integron-encoded Metallo- β -lactamase (VIM)-positive *Pseudomonas aeruginosa* causing recurrent urinary tract infections, which hampered planned kidney-pancreas transplantation. Microbiome analysis was performed prior to and after infusion of fecal microbiota.

Case description

A 34-year old male with type 1 diabetes mellitus was referred to our tertiary hospital because of diabetic nephropathy. Screening for combined kidney pancreas transplant started. Two months after starting hemodialysis, he was admitted because of bacteremia and catheter related thrombophlebitis of the brachiocephalic vein by *Staphylococcus aureus*, which was treated with flucloxacillin for 6 weeks. Because the extensive thrombosis prohibited shunt or catheter placement, he was converted to peritoneal dialysis (PD). During admission, a transurethral catheter was placed because of neurogenic bladder dysfunction. Shortly after discharge he returned to our hospital with a febrile catheter-related urinary tract infection (UTI) and was treated empirically with ceftazidim. Urinary cultures were positive with a *bla*_{VIM} carbapenemase producing *P. aeruginosa*, resistant to carbapenems, cephalosporins, quinolones, aminoglycosides and fosfomycin, only susceptible to colistin with a MIC of 4mg/L. The same *P. aeruginosa* was isolated from a rectal swab and the PD-catheter exit site. The patient received colistin intravenously (IV) for 2 weeks and the urinary and PD catheter were replaced. In the following months, the patient suffered from recurrent febrile UTIs due to the MDR *P. aeruginosa* (details on antibiotic use shown in Figure 1). Because of the high likelihood of recurrence of UTI caused by this MDR organism for which the only antibiotic was nephrotoxic, kidney transplantation was considered contraindicated and the patient was removed from the waiting list. During colistin treatment of the third episode, a plan for decolonization was developed.

The transurethral catheter was removed and intermittent catheterization with twice weekly prophylactic intravesical high dose gentamicin instillments was started. Repeated negative cultures of urine, PD catheter-skin interface, skin, ears and throat excluded chronic prostatitis or colonization at other sites than the gut. No oral selective digestive decontamination was given. After consultation with our ethics committee, informed consent was obtained from the patient for treatment with fecal microbiota. Six weeks after the last IV course of colistin, the infusion of FMT was performed.

MATERIAL & METHODS

Donor feces infusion was performed using the support of the National Donor Feces Bank (<http://www.ndfb.nl/>) according to the FECAL trial protocol with minor modifications.² In summary, donor feces was obtained from an unrelated healthy volunteer. Donor serum and feces were extensively screened for fecal and blood transmitted diseases including MDR bacteria. 75 gram of feces was homogenized with saline, and sieved (300µm mesh) to remove undigested food fragments. Within 8 hours after defecation of the donor, 300ml fecal suspension was infused in the duodenum of the patient through a nasoduodenal tube, after full colon lavage. Stool samples were collected prior to infusion, after 1 week, 2 weeks, 1 month, 2 months and 3 months and screened for MDR presence using selective enrichment media, as described previously.³ A portion of the feces was stored within 4 hours after delivery at -80°C for microbiome research. To assess the relatedness of bacterial strains, Amplified Fragment Length Polymorphism (AFLP) technique was performed as described previously.⁴

Microbiota analysis

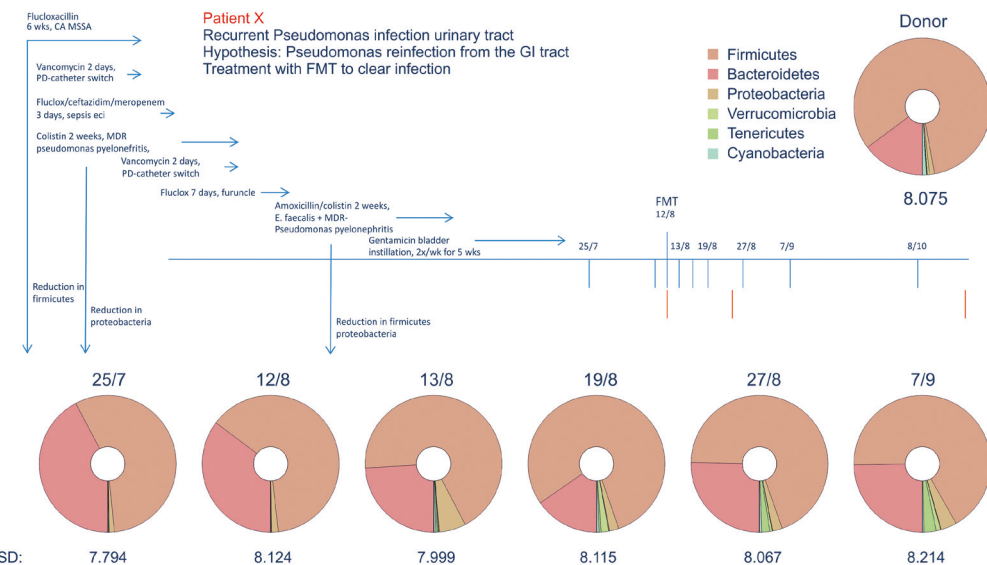
Bacterial DNA was isolated from the fecal samples using the ZR Fecal DNA MiniPrep kit (Zymo Research). Library preparation and amplification of the V4 hyper variable region 16S rRNA gene was performed using NEXTflex 16S V4 Ampliconseq kit v2.0. High-throughput sequencing was executed at ServiceXS (Leiden, the Netherlands) on the Illumina HiSeq 2500 platform (Illumina, San Diego, USA) in rapid run mode paired-end 250 base pairs read length. Raw sequences were processed and analysed using the open-source bioinformatics pipeline QIIME 1.9.1 (<http://qiime.org/>), the Operational Taxonomic Unit were picked using the open-reference protocol. Subsequently, microbiota profiles were reported at phylum level and visualized using the visualization tool Krona.⁵

RESULTS

No adverse event occurred during or after the infusion of microbiota, other than loose stools for 3 days. The stool culture taken prior to FMT was negative for the MDR *P. aeruginosa*, but did contain an ESBL producing *Escherichia coli*, susceptible to carbapenems, gentamicin, piperacillin/tazobactam and colistin. Subsequently 5 stool cultures up to 3 months of follow up remained negative for *P. aeruginosa*, however persisted in containing the ESBL producing *E. coli*. The *E. coli* post-FMT was identical to the *E. coli* found prior FMT, using AFLP. No infectious complications caused by *P. aeruginosa* were noted during 18 months of follow up. However, the patient was treated once with trimethoprim-sulfamethoxazole for cystitis caused by an ESBL positive *E. coli* 8 months after FMT. Unfortunately, this strain was not available for AFLP analysis.

16S analysis of the patient's stool 19 and 1 days prior FMT revealed a diverse microbiota composition, i.e., high Shannon diversity index of 7.8 and 8.1 respectively. No significant changes in microbiota diversity of the recipient were observed following the FMT (figure 1). At phyla level a high similarity of donor and recipient microbiota was observed with respect to the *Firmicutes* and *Bacteroidetes* as the expected main phyla of the microbiota (figure 1).

Figure 1. Timeline of recurrent infections, antibiotic use, and microbiota diversity prior to and after fecal microbiota transfer.



CA MSSA: catheter related bacteremia with methicillin sensitive *Staphylococcus Aureus*. MDR: multidrug resistant. PD: peritoneal dialysis. FMT: fecal microbiota transfer.

DISCUSSION

A 34-year old patient on peritoneal dialysis and recurrent urinary tract infections with a VIM-positive *P. aeruginosa* was treated with infusion of fecal microbiota to eradicate *P. aeruginosa* from the intestinal tract. A clinical success was observed, since at a follow-up period of 18 months no recurrent infections by *P. aeruginosa* were diagnosed. FMT may have contributed to clinical success but it cannot be excluded that MDR *P. aeruginosa* was already eradicated from the gut before FMT, as the *P. aeruginosa* could not be cultured the day before FMT.

A remarkable observation is the persistence of an ESBL positive *E. coli* after FMT. The *E. coli* was presumably acquired after eradication treatment for *P. aeruginosa*, since it had not been detected in earlier cultures. It is possible that the incomplete eradication of the MDR *E. coli* is the result of coexistence of donor and patient *E. coli* strains after FMT. A recent study showed this coexistence of donor and recipient strains, which persisted for at least 3 months after FMT for treatment of patients with metabolic syndrome.⁶ This suggests that novel strains, acquired via FMT, can colonize the gut without replacing the indigenous strain population of the recipient.

In contrast to the diminished microbiota of recurrent CDI patients, our patient had an intact microbiota diversity and composition at phylum level prior to FMT. Previous antibiotic treatment (Figure 1) had not resulted in a distinct disturbance of the intestinal flora. Only minor changes of the microbiota composition were observed after FMT with a slight increase of cyanobacteria and tenericutes. We suggest that diminished diversity appears not to play a role in MDR carriership as opposed to recurrent CDI.⁷ Therefore, one might question the efficacy of fecal transplantation in patients with a normal microbiota diversity. The disturbed microbiota and its recovery after FMT might explain the positive results of MDR eradication in patients with recurrent CDI.^{8,9} Interestingly, a recent paper showed that infusion of fecal microbiota in patients with recurrent CDI decreased the number and diversity of antimicrobial resistance genes, particularly by restoring dysbiosis and reducing the number of *Proteobacteria*.¹⁰ Furthermore, beneficial effect of microbiota transfer has been shown in mice colonized with vancomycin resistant *Enterococcus* (VRE) [11]. Clearly, more research on FMT for eradication of colonization of different MDR bacterial species is required.

A total of only eight case reports have been published, showing FMT resulted in intestinal decolonization of ESBL- and carbapenemase-producing Enterobacteriaceae, VRE, or methicillin-resistant *Staphylococcus aureus*.¹²⁻¹⁵ Unfortunately, no information has been provided on microbiota composition before and after transplantation. Five trials are currently underway regarding the use of FMT for MDR bacterial decolonization which should provide more insight on the role of the microbiota on colonisation with specific microorganisms.¹²

A limitation of our analysis is that the microbiota was determined by 16S analysis. Although very useful in bacterial taxonomic classification, it lacks the required resolution to track transmission of bacterial strains in the microbiota using single-nucleotide variants in metagenomes.⁶ Therefore, it was not possible to compare the composition of the microbiota at strain level, allowing a comparison between the donor and patient *P. aeruginosa* strains. However, no VIM-gene was

detected by PCR on DNA from three feces samples after FMT.

In conclusion, combined FMT and antibiotic treatment prevented recurrence of UTI with MDR *P. aeruginosa*. Intestinal colonization with ESBL producing *E. coli* persisted in the presence of a microbiota with intact diversity, suggesting that eradication of *E. coli* requires perhaps other specific strain(s) of microbes. More detailed analysis such as metagenomics, could identify specific strains that add to decolonization and should be applied in current studies on FMT for intestinal eradication of different MDR bacterial species.

REFERENCES

- 1 World Health Organization. Worldwide country situation analysis: response to antimicrobial resistance. Geneva.
- 2 van Nood E, Vrieze A, Nieuwdorp M, et al. Duodenal infusion of donor feces for recurrent *Clostridium difficile*. *N Engl J Med* 2013 Jan 31; 368(5):407-15.
- 3 Paltansing S, Vlot JA, Kraakman ME, et al. Extended-spectrum beta-lactamase-producing enterobacteriaceae among travelers from the Netherlands. *Emerg Infect Dis* 2013 Aug; 19(8):1206-13.
- 4 Vos P, Hogers R, Bleeker M, et al. AFLP: a new technique for DNA fingerprinting. *Nucleic Acids Res* 1995 Nov 11; 23(21):4407-14.
- 5 Ondov BD, Bergman NH, Phillippy AM. Interactive metagenomic visualization in a Web browser. *BMC Bioinformatics* 2011; 12:385.
- 6 Li SS, Zhu A, Benes V, et al. Durable coexistence of donor and recipient strains after fecal microbiota transplantation. *Science* 2016 Apr 29; 352(6285):586-9.
- 7 Chang JY, Antonopoulos DA, Kalra A, et al. Decreased diversity of the fecal Microbiome in recurrent *Clostridium difficile*-associated diarrhea. *J Infect Dis* 2008 Feb 1; 197(3):435-8.
- 8 Garcia-Fernandez S, Morosini MI, Cobo M, et al. Gut eradication of VIM-1 producing ST9 *Klebsiella oxytoca* after fecal microbiota transplantation for diarrhea caused by a *Clostridium difficile* hypervirulent R027 strain. *Diagn Microbiol Infect Dis* 2016 Dec; 86(4):470-1.
- 9 Dubberke ER, Mullane KM, Gerding DN, et al. Clearance of Vancomycin-Resistant *Enterococcus* Concomitant With Administration of a Microbiota-Based Drug Targeted at Recurrent *Clostridium difficile* Infection. *Open Forum Infect Dis* 2016 Sep; 3(3):ofw133.
- 10 Millan B, Park H, Hotte N, et al. Fecal Microbial Transplants Reduce Antibiotic-resistant Genes in Patients With Recurrent *Clostridium difficile* Infection. *Clin Infect Dis* 2016 Mar 29.
- 11 Ubeda C, Taur Y, Jenq RR, et al. Vancomycin-resistant *Enterococcus* domination of intestinal microbiota is enabled by antibiotic treatment in mice and precedes bloodstream invasion in humans. *J Clin Invest* 2010 Dec; 120(12):4332-41.
- 12 Manges AR, Steiner TS, Wright AJ. Fecal microbiota transplantation for the intestinal decolonization of extensively antimicrobial-resistant opportunistic pathogens: a review. *Infect Dis (Lond)* 2016 May 19;1-6.
- 13 Singh R, van NE, Nieuwdorp M, et al. Donor feces infusion for eradication of Extended Spectrum beta-Lactamase producing *Escherichia coli* in a patient with end stage renal disease. *Clin Microbiol Infect* 2014 Nov; 20(11):O977-O978.
- 14 Crum-Cianflone NF, Sullivan E, Ballon-Landa G. Fecal microbiota transplantation and successful resolution of multidrug-resistant-organism colonization. *J Clin Microbiol* 2015 Jun; 53(6):1986-9.
- 15 Lagier JC, Million M, Fournier PE, Brouqui P, Raoult D. Faecal microbiota transplantation for stool decolonization of OXA-48 carbapenemase-producing *Klebsiella pneumoniae*. *J Hosp Infect* 2015 Jun; 90(2):173-4.