



Universiteit  
Leiden  
The Netherlands

## **Advances in endothelial keratoplasty**

Birbal, R.S.

### **Citation**

Birbal, R. S. (2020, November 17). *Advances in endothelial keratoplasty*. Retrieved from <https://hdl.handle.net/1887/138387>

Version: Publisher's Version

License: [Licence agreement concerning inclusion of doctoral thesis in the Institutional Repository of the University of Leiden](#)

Downloaded from: <https://hdl.handle.net/1887/138387>

**Note:** To cite this publication please use the final published version (if applicable).

Cover Page



Universiteit Leiden



The handle <http://hdl.handle.net/1887/138387> holds various files of this Leiden University dissertation.

**Author:** Birbal, R.S.

**Title:** Advances in endothelial keratoplasty

**Issue Date:** 2020-11-17



# Part II

Selective, Minimally-Invasive and Potentially  
Tissue-Sparing Surgical Treatment Modalities  
for Corneal Endothelial Disorders

**Birbal RS<sup>1-3</sup>, Baydoun L<sup>1,2,4</sup>, Ham L<sup>1-3</sup>, Miron A<sup>1,2</sup>, van Dijk K<sup>1,2</sup>, Dapena I<sup>1,2</sup>, Jager MJ<sup>5</sup>, Böhringer S<sup>6</sup>, Oellerich S<sup>1</sup>  
and Melles GRJ<sup>1-3,7</sup>**

<sup>1</sup> *Netherlands Institute for Innovative Ocular Surgery (NIIOS), Rotterdam, The Netherlands*

<sup>2</sup> *Melles Cornea Clinic, Rotterdam, The Netherlands*

<sup>3</sup> *Amnitrans EyeBank, Rotterdam, The Netherlands*

<sup>4</sup> *Department of Ophthalmology, University Hospital Münster, Münster, Germany*

<sup>5</sup> *Department of Ophthalmology, Leiden University Medical Center, Leiden, The Netherlands*

<sup>6</sup> *Department of Biomedical Data Sciences, Leiden University Medical Center, Leiden, The Netherlands*

<sup>7</sup> *NIIOS-USA, San Diego, California, United States of America*

# Chapter 3

Effect of Surgical Indication and Preoperative  
Lens Status on Descemet Membrane Endothelial  
Keratoplasty Outcomes

Am J Ophthalmol 2020;212:79-87



## ABSTRACT

**Purpose:** To analyze 6-month results of 1000 consecutive Descemet membrane endothelial keratoplasty (DMEK) cases, and to evaluate if outcomes are influenced by surgical indication and preoperative lens status.

**Design:** Retrospective, interventional case series.

**Methods:** A series of 1000 eyes (738 patients) underwent DMEK mainly for Fuchs endothelial corneal dystrophy (FECD; 85.3%) or bullous keratopathy (BK; 10.5%). Main outcome measures were best-corrected visual acuity (BCVA), endothelial cell density (ECD), postoperative complications and re-transplantations.

**Results:** At 6 months after DMEK, there was no difference in BCVA outcome between FECD and BK eyes ( $P=0.170$ ), or between phakic and pseudophakic FECD eyes ( $P=0.066$ ) after correcting for patient age and preoperative BCVA. Endothelial cell loss at 6 months postoperatively was similar for phakic and pseudophakic FECD eyes (39%;  $P=0.852$ ), but higher for BK eyes than for FECD eyes (46% versus 39%,  $P=0.001$ ). Primary and secondary graft failure occurred in 3 (0.3%) and 2 eyes (0.2%), respectively, and 7 eyes developed allograft rejection (0.7%). Eighty-two eyes (8.2%) received re-bubbling for graft detachment and re-transplantation was performed in 20 eyes (2.0%). Re-bubbling was more often required in eyes treated for BK versus FECD eyes (12.4% versus 7.4%,  $P=0.022$ ).

**Conclusion:** DMEK consistently provides excellent short-term results, with similar high visual acuity levels for both FECD and BK eyes. As preoperative lens status did not influence DMEK outcomes, for phakic FECD eyes with a still relatively clear crystalline lens, lens preservation may be preferable in a selected group of younger patients, who may still benefit from their residual accommodative capacity.

## INTRODUCTION

Since its clinical introduction in 2006, Descemet membrane endothelial keratoplasty (DMEK) has emerged as an increasingly popular treatment option for corneal endothelial dysfunction.<sup>1,2</sup> This minimally-invasive surgical technique provides near-perfect anatomic restoration of the cornea and yields superior clinical results compared to its predecessors.<sup>3</sup>

Multiple studies have provided excellent outcomes<sup>4-7</sup> and have revealed that the first 6 months after DMEK appear to be the most critical time period after which the results mostly stabilize.<sup>3,8-11</sup> Since Fuchs endothelial corneal dystrophy (FECD) is the main indication for DMEK, most studies either focus on the clinical outcomes in FECD eyes or present results for all surgery indications combined.<sup>3,6,8-11</sup> When studying a smaller cohort of DMEK eyes at our own institute, we observed better results for eyes treated for FECD compared to eyes with bullous keratopathy (BK), and for phakic FECD compared with pseudophakic FECD eyes. We reported that preoperative parameters such as surgical indication and lens status may influence DMEK outcomes.<sup>12,13</sup> However, Brockmann et al. reported similar outcomes for eyes operated on for FECD and BK.<sup>14</sup> As such, further evaluation of the clinical impact of these parameters after DMEK would be of added value and could possibly enable us to counsel future patients more accurately on the expected outcomes.

Our expanding DMEK cohort and simultaneously growing dataset now allows us to perform more detailed analyses on subgroups. The objective of this study was to assess the overall 6-month clinical outcomes of 1000 consecutive DMEK cases operated at our institute, and to evaluate how these are influenced by surgical indication (FECD versus BK) and preoperative lens status (phakic versus pseudophakic FECD).

## METHODS

### Patient data

A cohort of 1000 consecutive eyes of 738 patients (mean age 68 ( $\pm$ 12) years; range 20-96 years) underwent DMEK for FECD (85.3%), BK (10.5%), failed previous transplant (3.7%) or other indications (0.5%) (Table 1) and was retrospectively analyzed. The 1000 cases that were evaluated were cases 26-1025 from a total of 1025 consecutive DMEK surgeries performed in our clinic. The



very first 25 DMEK cases (cases 1-25), that we consider to represent the learning curve of this technique, were excluded from analysis. Patient and donor demographics are displayed in Table 1. All patients signed an informed consent form prior to surgery for research participation and the study adhered to the tenets of the Declaration of Helsinki.

### **Graft preparation**

DMEK graft preparation was performed using the traditional and/ or standardized 'no-touch' technique at Amnitrans EyeBank Rotterdam.<sup>15,16</sup> In short, within 36 hours postmortem, donor globes were enucleated, and corneoscleral buttons were excised. Corneoscleral buttons were stored in organ culture medium (CorneaMax; Eurobio, Courtaboeuf, France) until the time of transplantation; mean graft storage time was 14.2 ( $\pm 4$ ) days (Table 1). After 1-2 weeks of culture, corneoscleral buttons were mounted endothelial side up on a custom-made holder and using a hockeystick knife (DORC International, Zuidland, The Netherlands) the trabecular meshwork was loosened over 360 degrees. After complete Descemet membrane (DM) stripping and trephination, the donor sheets spontaneously formed a roll with the endothelium facing outward. All rolls were preserved in organ culture medium until the time of transplantation. Endothelial cell morphology and viability were evaluated with an inverted light microscope (Axiovert 40; Zeiss, Göttingen, Germany) before and after DM stripping.

### **DMEK surgery**

Two weeks before DMEK surgery, a peripheral iridotomy was created at the 12 o'clock surgical position with a neodymium-doped yttrium aluminum garnet (Nd:YAG)-laser. DMEK-surgery was performed under local (retrobulbar) anesthesia at the Melles Cornea Clinic in Rotterdam. The standardized 'no-touch' DMEK technique was not fully implemented for approximately the first 250 cases, whereas it was for the latter 750 cases.<sup>4,17</sup> In short, three side ports were created, after which the anterior chamber was completely filled with air to facilitate scoring and descemetorhexis with a reversed Sinsky hook (DORC International, Zuidland, The Netherlands). A 3.0-mm limbal tunnel incision was created at the 12 o'clock position and the donor DM graft was stained with 0.06% trypan blue solution (VisionBlueTM; DORC International), aspirated into the Melles glass injector and implanted into the recipient anterior chamber. After a correct orientation was confirmed, the graft (endothelium facing down) was centered and unfolded before it was lifted onto the recipient posterior stroma. A complete air fill of the anterior chamber was applied for on average

**Table 1:** Demographics of Descemet membrane endothelial keratoplasty eyes (n=1000) and donors.

Baseline parameters	Result	
Number of eyes / patients		1000 / 738
Sex (female/male), % (n)	53%/47%	(392/346)
Indication for DMEK		
FECD	85.3%	(853)
BK: pseudophakic, aphakic, (removed) phakic IOL, (congenital) glaucoma, post-glaucoma surgery, post RK	10.5%	(105)
Failed graft: PKP / (re-)DSEK / (re-)DSAEK / DMEK	3.7%	(37)
Other: corneal dystrophies, corneal decompensation due to trauma, acanthamoeba keratitis)	0.5%	(5)
Mean age $\pm$ SD, years (n eyes)	68 $\pm$ 12	(1000)
Total study group		
FECD group	69 $\pm$ 11	(853)
Total FECD group <sup>a</sup>	72 $\pm$ 8	(629)
Pseudophakic FECD group	58 $\pm$ 9	(223)
Phakic FECD group	64 $\pm$ 17	(105)
BK group	64 $\pm$ 10	(37)
Failed graft group	45 $\pm$ 17	(5)
Other		
Pre- and postoperative lens status, % (n eyes)		
Pseudophakic	73.9%	(739)
Phakic	25.6%	(256)
Aphakic	0.5%	(5)
Presence of glaucoma drainage device, % (n eyes)		
Total Group	1.2%	(12)
FECD group	0.0%	(0)
BK group	9.5% <sup>b</sup>	(10)
Failed graft group	5.4% <sup>c</sup>	(2)
Other	0.0%	(0)
Donor age $\pm$ SD, years	67 $\pm$ 10	
Donor sex (female/male), % (n)	38%/62%	(381/619)
Donor death cause, % (n)		
Cancer	26.1%	(261)
Cardiovascular/Stroke	46.5%	(465)
Respiratory	19.1%	(191)
Trauma	2.8%	(28)
Other	5.4%	(54)
Not available	0.1%	(1)
Graft storage time in medium $\pm$ SD, days	14.2 $\pm$ 4	

SD: Standard deviation; FECD: Fuchs endothelial corneal dystrophy BK: Bullous keratopathy; PKP: Penetrating keratoplasty; Re-: Repeat, DSAEK: Descemet stripping automated endothelial keratoplasty; DSEK: Descemet stripping endothelial keratoplasty; DMEK: Descemet membrane endothelial keratoplasty; IOL: Intraocular lens; RK: Radial keratotomy

<sup>a</sup>: FECD group includes one aphakic eye <sup>c</sup>:

<sup>b</sup>: Percentage calculated based on 105 eyes with surgery indication BK

Percentage calculated based on 37 eyes with surgery indication 'Failed graft'

60 minutes (range, 30-120 minutes), after which an air-liquid exchange was performed leaving a 30-50% air bubble in the anterior chamber to promote graft adherence.

Postoperative topical medication included chloramphenicol 0.5% six times daily during the first week and twice daily during the second week and ketorolac tromethamine 0.4% and dexamethasone 0.1% four times daily for four weeks, followed by fluorometholone 0.1% four times daily, tapered to once daily at one year postoperatively, and once daily or once every other day indefinitely thereafter.

### **Data collection and statistical analysis**

Patients were examined before and 1, 3, and 6 months after DMEK. Best-corrected visual acuity (BCVA) was measured using a Snellen letter chart. A total of 201 eyes (20.1%) were either not available for BCVA analyses due to incomplete data (n=30; 3.0%), loss to follow-up (n=18; 1.8%), re-transplantation within 6 months after DMEK (n=20; 2.0%), or were excluded from BCVA analyses due to low visual potential induced by ocular comorbidities unrelated to the cornea (n=133; 13.3%). BCVA outcomes were converted to the logarithm of the minimum angle of resolution units (LogMAR) for statistical analyses.

Endothelial cell density (ECD) was evaluated *in vivo* using a Topcon SP3000p non-contact autofocus specular microscope (Topcon Medical Europe BV, Cappelletto a/d IJssel, The Netherlands). For ECD counting, the commercial software of the specular microscope (ImageNet software, Topcon Medical Europe) was employed and the automatically delineated cell borders were checked and when incorrectly assigned, the cell borders were manually re-assigned by a trained technician. For each follow-up the results of three ECD measurements per eye were averaged. A total of 109 eyes (10.9%) were not available for ECD analyses due to incomplete data or insufficient image quality (n=71; 7.1%), loss to follow-up (n=18; 1.8%), or re-transplantation within 6 months after DMEK (n=20; 2.0%).

Central corneal thickness (CCT) was measured using rotating Scheimpflug corneal tomography (Pentacam HR, Oculus Optikgeräte GmbH, Wetzlar, Germany) and CCT data were available for 872 eyes at the 6-month follow-up time point.

Graft detachment after DMEK was evaluated with slit-lamp examination and anterior segment optical coherence tomography (AS-OCT). Detachments were subdivided into minor (detachment  $\leq 1/3$  of the graft surface area) and major graft detachments (detachment  $> 1/3$  of the graft surface area). Allograft rejection was defined as the presence of an endothelial rejection line or keratic precipitates, with or without an increase in corneal thickness, anterior uveitis, and/ or ciliary injection on slit-lamp examination. Primary graft failure (PGF) was defined as a cornea that failed to clear in the presence of an attached graft, whereas secondary graft failure (SGF) was defined as corneal decompensation following an initial period of a clear cornea with a functional attached graft after DMEK.

For statistical analyses, second eyes of patients undergoing bilateral DMEK (n=262) were excluded. Binary outcomes were analyzed using logistic regression. Continuous outcomes were analysed using linear regression. For group comparisons, outcomes were corrected for age and preoperative values of the outcomes. Analyses were performed in R 3.5.0 using standard function *glm* and *lm*. All eyes were included for descriptive analyses, which was performed using Excel software for Windows (Microsoft Corp, Redmond, Washington, USA). *P*-values  $< 0.05$  were considered statistically significant.

## RESULTS

### Visual outcome

At 1 month after DMEK, 48% of the eyes of the entire cohort (excluding eyes with low visual potential) achieved a BCVA of  $\geq 20/25$  (0.8), 20% achieved  $\geq 20/20$  (1.0), and 4% achieved  $\geq 20/17$  (1.2). At 3 and 6 months after DMEK, these percentages increased to 66%, 32% and 8% of eyes, and 75%, 41% and 12% of eyes, respectively (Fig., Table 2). When also including eyes with low visual potential in the 6-month BCVA analysis, 65% of the eyes reached a BCVA of  $\geq 20/25$  (0.8), 35% achieved  $\geq 20/20$  (1.0), and 10% achieved  $\geq 20/17$  (1.2) (Table 2).

Of the eyes that underwent DMEK for FECD, 77% achieved a BCVA of  $\geq 20/25$  (0.8), 42% achieved  $\geq 20/20$  (1.0), and 12% achieved  $\geq 20/17$  (1.2) at 6 months after DMEK. Further analyses revealed that of the phakic and pseudophakic eyes treated for FECD, 84% of phakic FECD eyes achieved a BCVA of  $\geq 20/25$  (0.8), 56% of  $\geq 20/20$  (1.0), and 19% of  $\geq 20/17$  (1.2) versus 74%, 37% and 9% for



**Table 2.** Clinical outcomes after Descemet membrane endothelial keratoplasty, (continued)

Parameter	Total group						FECD						BK					
	Preoperative		6m FU		Total FECD group		Pseudophakic FECD group		Phakic FECD group		Preoperative		6m FU		Preoperative		6m FU	
	(n)	(±SD)	(n)	(±SD)	(n)	(±SD)	(n)	(±SD)	(n)	(±SD)	(n)	(±SD)	(n)	(±SD)	(n)	(±SD)	(n)	(±SD)
<b>Endothelial cell density (ECD)</b>																		
Mean ECD (±SD), (cells/mm <sup>2</sup> )	(n=891)	(n=891)	(n=789)	(n=789)	(n=789)	(n=789)	(n=582)	(n=582)	(n=206)	(n=206)	(n=206)	(n=77)	(n=77)	(n=77)	(n=77)	(n=77)	(n=77)	(n=77)
ECD decline (±SD), (%) <sup>a</sup>	2565 (±185)	1550 (±485)	2565 (±185)	1565 (±480)	2555 (±180)	1560 (±485)	2595 (±195)	1590 (±470)	2535 (±205)	1375 (±460)	46 (±18)	39 (±17)	39 (±18)	39 (±18)	39 (±17)	39 (±17)	39 (±17)	39 (±17)
<b>Pachymetry</b>																		
Mean CCT (±SD), (µm)	(n=872)	(n=872)	(n=777)	(n=777)	(n=777)	(n=573)	(n=573)	(n=203)	(n=203)	(n=203)	(n=77)	(n=77)	(n=77)	(n=77)	(n=77)	(n=77)	(n=77)	(n=77)
CCT decline (±SD), (%) <sup>a</sup>	687 (±144)	522 (±54)	670 (±99)	520 (±42)	677 (±104)	519 (±43)	647 (±75)	521 (±40)	796 (±205)	526 (±59)	30 (±17)	22 (±10)	22 (±11)	22 (±11)	22 (±10)	22 (±10)	22 (±10)	22 (±10)

FECD= Fuchs endothelial corneal dystrophy; BK= Bullous keratopathy; m= months; FU= Follow-up; BCVA= Best-corrected visual acuity; LVP= Low visual potential eyes; n= number of eyes; SD= standard deviation.

<sup>a</sup>Decline as compared to preoperative values

the pseudophakic FECD group, respectively ( $P < 0.001$ ) (Table 2, Fig.). However, when correcting for age and preoperative BCVA, visual acuity outcomes did not differ between the phakic and pseudophakic FECD eyes ( $P = 0.066$ ).

Further analyses of eyes that underwent DMEK for BK showed that 66% of eyes achieved a BCVA of  $\geq 20/25$  (0.8), 32% achieved  $\geq 20/20$  (1.0), and 13% achieved  $\geq 20/17$  (1.2) at 6 months after DMEK (Table 2). Comparison of BCVA outcomes of eyes treated for FECD and for BK, showed similar outcomes for both groups when correcting for patient age and preoperative BCVA ( $P = 0.172$ ). Overall, the entire cohort, as well as all subgroups showed an improvement in BCVA outcomes at 6 months after DMEK when compared to preoperative values ( $P < 0.001$ ).

### **Endothelial cell density**

Donor ECD for the entire cohort averaged 2565 ( $\pm 185$ ) cells/mm<sup>2</sup> before DMEK and 1550 ( $\pm 485$ ) cells/mm<sup>2</sup> (-40% ( $\pm 18\%$ )) at 6 months after DMEK ( $n=891$ ) ( $P < 0.001$ ) (Table 2). Eyes treated for FECD showed a decline in preoperative ECD of 39% at 6 months postoperatively ( $P < 0.001$ ), with no difference between phakic and pseudophakic eyes ( $P = 0.85$ ). Eyes treated for BK demonstrated a higher ECD decline of 46% than eyes treated for FECD at 6 months postoperatively ( $P = 0.001$ ) (Table 2).

### **Pachymetry**

Mean patient CCT improved from 687 ( $\pm 144$ )  $\mu\text{m}$  before DMEK to 522 ( $\pm 54$ )  $\mu\text{m}$  (-22%) at 6 months after DMEK ( $P < 0.001$ ) (Table 2). From preoperative to 6 months after DMEK, mean CCT decreased in all subgroups ( $P < 0.001$ ) and CCT at 6m postoperatively was comparable for all groups ( $P > 0.05$ ) (Table 2). In percentages, the reduction in CCT from preoperative to 6 months postoperatively was higher in eyes treated for BK than for eyes treated for FECD, 30% and 21%, respectively ( $P < 0.001$ ); this was also observed for pseudophakic FECD eyes as compared to phakic FECD eyes, 22% and 19%, respectively ( $P < 0.001$ ).

### **Postoperative complications and re-transplantation**

Within the first 6 months after DMEK, primary graft failure occurred in 3 eyes (0.3%) and secondary graft failure in 2 eyes (0.2%). Seven eyes developed allograft rejection (0.7%) (Table 3) and were all successfully managed by applying an intensified regimen of topical corticosteroids. Within 6 months after

phakic DMEK, phacoemulsification with intraocular lens implantation was performed in 4 of 256 eyes (1.6%) (Table 3).

**Table 3.** Early complications and secondary procedures after Descemet membrane endothelial keratoplasty (within 6 months).

	Total group (n=1000)	FECD			BK (n=105)
		Total FECD group (n=853)	Pseudophakic FECD group (n=629)	Phakic FECD group (n=223)	
<b>Postoperative complications</b>					
Primary graft failure <sup>a</sup>	0.3% (n=3)	0.1% (n=1)	0.2% (n=1)	0.0% (n=0)	1.9% (n=2)
Secondary graft failure <sup>b</sup>	0.2% (n=2)	0.0% (n=0)	0.0% (n=0)	0.0% (n=0)	1.0% (n=1)
Allograft rejection	0.7% (n=7)	0.5% (n=4)	0.6% (n=4)	0.0% (n=0)	2.9% (n=3)
Phacoemulsification + IOL <sup>c</sup>					
For pre-existent cataract	0.4% (n=1) <sup>d</sup>	-	-	-	-
For cataract after DMEK	1.2% (n=3)	0.9% (n=2)	-	0.9% (n=2)	4.5% (n=1)
Detachment <sup>e</sup>					
Detachments ≤1/3	8.7% (n=87)	8.8% (n=75)	9.2% (n=58)	7.6% (n=17)	8.6% (n=9)
Detachments >1/3	4.3% (n=43)	3.5% (n=30)	4.0% (n=25)	2.2% (n=5)	7.6% (n=8)
<b>Secondary procedures</b>					
Re-bubbling	8.2% (n=82)	7.4% (n=63)	8.0% (n=50)	5.8% (n=13)	12.4% (n=13)
Re-transplantation					
Re-DMEK	1.1% (n=11)	0.9% (n=8)	0.6% (n=4)	1.8% (n=4)	1.9% (n=2)
Secondary DSEK	0.8% (n=8)	0.7% (n=6)	1.0% (n=6)	0.0% (n=0)	1.9% (n=2)
Secondary PKP	0.1% (n=1)	0.0% (n=0)	0.0% (n=0)	0.0% (n=0)	1.0% (n=1)

FECD: Fuchs endothelial corneal dystrophy; BK: Bullous keratopathy; n: Number; DMEK: Descemet membrane endothelial keratoplasty; DSEK: Descemet stripping endothelial keratoplasty; PKP: Penetrating keratoplasty; IOL: Intraocular lens

<sup>a</sup>: Primary graft failure refers to an attached graft, but cornea fails to clear

<sup>b</sup>: Secondary graft failure refers to an attached graft with (signs of) corneal clearance, followed by corneal decompensation

<sup>c</sup>: Phakic eyes: total (n=256), FECD (n=223) and BK (n=22).

<sup>d</sup>: Surgery indication in this eye was acanthamoeba keratitis.

<sup>e</sup>: Includes all graft detachments as observed at the six months follow-up

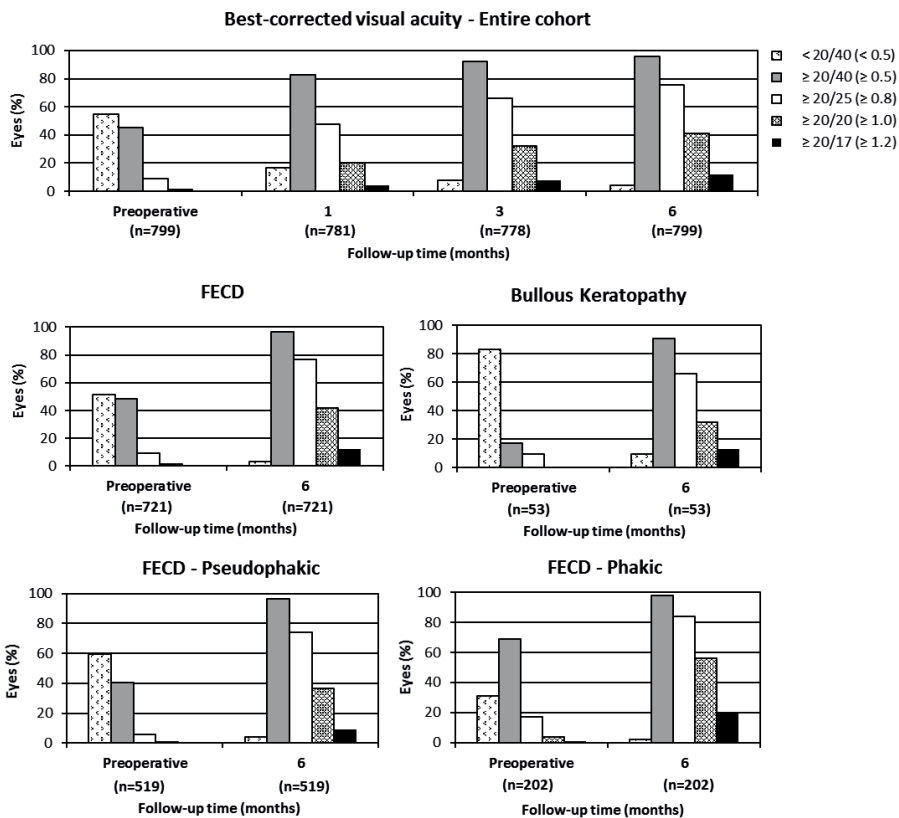
At 6 months after DMEK, a total of 130 of 1000 eyes (13.0%) showed persistent graft detachment, of which 8.7% (n=87) had a minor detachment and 4.3% (n=43) a major detachment. The overall detachment rate did not differ between FECD versus BK eyes ( $P = 0.09$ ) and between phakic and pseudophakic FECD eyes ( $P = 0.143$ ).

Eighty-two eyes (8.2%) received a re-bubbling procedure for visually significant graft dehiscence, of which 15 (1.5%) procedures were performed in the first 500 cases and 67 (6.7%) procedures in the second 500 cases. BK eyes



underwent a re-bubbling procedure more often than FECD eyes (12.4% versus 7.4%,  $P = 0.022$ ), whereas the procedure was performed at a comparable rate for phakic versus pseudophakic FECD eyes (5.8% versus 8.0%,  $P = 0.561$ ).

Graft detachment was the main indication for re-transplantation and a total of 20 eyes (2.0%) underwent a secondary keratoplasty within 6 months after DMEK, of which 5 eyes underwent re-transplantation after an unsuccessful re-bubbling procedure. Eleven of the re-transplantations were performed in the first 500 cases (1.1%) and 9 in the second 500 cases (0.9%). Re-transplantation



**Figure 1. Bar graphs displaying the best-corrected visual acuity up to 6 months after Desemet membrane endothelial keratoplasty.**

Graphs illustrate the best-corrected visual acuity (BCVA) up to 6 months postoperatively for the entire cohort (excluding low-visual-potential eyes) before and at 1, 3 and 6 months after DMEK (upper row), and for the two subgroups based upon surgical indication (Fuchs endothelial corneal dystrophy [FECD] and Bullous keratopathy [BK], middle row) and based upon preoperative lens status (pseudophakic and phakic FECD eyes, bottom row).

rate did not differ between FECD and BK eyes, nor between phakic and pseudophakic FECD eyes ( $P>0.05$  for all comparisons).

## DISCUSSION

The current study confirms that DMEK consistently provides excellent short-term outcomes, also on a larger scale. For this study, we additionally assessed outcomes based on surgical indication and preoperative lens status.

### Surgical indication

As most results regarding the outcome of DMEK that have been reported in the literature refer to FECD eyes, it is well known that patients with FECD may achieve very good visual acuity results after DMEK.<sup>3,6,8-11</sup> In this study we could show for a relatively large group of BK eyes, that even though overall BCVA results were lower than for FECD eyes, the difference was not significant when correcting for preoperative BCVA (lower in the BK group) and patient age; this outcome confirms the results of a recently published study on a smaller cohort.<sup>14</sup> Thus, it is important to emphasize that most BK eyes (66%) without visual-acuity limiting co-morbidities may expect a good visual performance of 0.8 (20/25) or 1.0 (20/20) or better, even early after DMEK. This may be due to the fast deswelling of BK corneas that on average reach normal CCT levels within 6 months after the operation, despite higher preoperative CCT values.

With this expanded study group, we were able to confirm prior results regarding ECD decline, which showed a larger decline in BK compared with FECD eyes.<sup>13,18</sup> In contrast, Brockmann et al. did not detect any difference, which could be either owing to their smaller sample size<sup>14</sup> or maybe also because of the relatively high percentage of eyes with a glaucoma drainage device in our BK group which has been shown to be a risk factor for high ECD decline after DMEK.<sup>19</sup> The lower ECD decline in the early postoperative phase after DMEK in FECD eyes may also explain the higher longer-term survival rates in FECD eyes compared to eyes treated for other indications.<sup>3,13,18,20</sup> These data may imply that FECD eyes, in general, perform better when it comes to endothelial cell rehabilitation and graft longevity, which could be attributed to a regenerative capacity of endothelial cells in the recipient corneal rim, whereas in BK eyes this may be less favorable owing to a relative depletion of host endothelial cells and pathological changes at the level of the corneal endothelium and/ or the stroma.<sup>14,21</sup> To enhance graft longevity in BK eyes,

one may therefore consider utilizing DMEK grafts of superior quality, that is, for example, grafts with a higher preoperative ECD ( $\geq 3000$  cells/mm<sup>2</sup>) since some reports indicated an effect of preoperative donor ECD on ECD outcome after DMEK.<sup>10,13,14,22</sup>

Compared with FECD eyes, BK is a more heterogenous group, consisting of eyes with slow corneal decompensation owing to previous cataract surgery, but also of eyes with complex pathology such as posterior segment surgery, glaucoma drainage devices and post-trauma. Thus from a 'clinical impression', we consider BK eyes to be at higher risk for postoperative graft dehiscence owing to a more edematous preoperative cornea with reduced imbibition pressure. However, interestingly, detachment rates did not depend on surgical indication according to the current analysis and as reported before by Brockmann and associates.<sup>14</sup> Still, when comparing subgroups, the overall re-bubbling rate was higher in BK than in FECD eyes, which could be explained by a larger extension of the detachment more often involving the visual axis but also by decision bias, i.e. spontaneous graft adherence may be considered less likely in BK eyes due to the pronounced edema, and therefore re-bubbling is indicated more quickly.

### **Lens status**

When correcting for preoperative BCVA (lower in pseudophakic FECD group) and patient age (lower in phakic FECD group), overall BCVA outcomes did not differ between phakic and pseudophakic FECD eyes. These findings confirm our results obtained with a smaller cohort before.<sup>12</sup> Furthermore, Triple DMEK studies have shown to yield similar short-term results compared to two-staged cataract and DMEK surgery.<sup>23-25</sup> Still, there are several reasons why we prefer a two-staged approach in cases with concomitant moderate-to-advanced cataract and FECD. First, in our experience about 30% of patients who first receive cataract surgery alone are satisfied with the visual outcome without requiring subsequent corneal transplantation (clinical observation). This allows postponing corneal transplantation a couple of months or even years while at the same time reducing the need for aftercare (i.e. regular follow-ups after keratoplasty and continuous topical steroidal treatment) which may be perceived as a burden for some patients. In addition, this approach could save corneal tissue and reduce waiting lists for keratoplasty. Second, a triple procedure may induce more intraocular inflammation than isolated surgery. Therefore, we usually wait 6-8 weeks after cataract surgery before performing DMEK. During that time the corneal condition not only stabilizes, but the

patient can also better evaluate if lens surgery alone was sufficient to improve visual performance, and post-surgical inflammation from cataract surgery is normally controlled within this time period. We believe minimized inflammation may be a better precondition before inserting antigenic tissue. Third, we try to avoid conditions that may interfere with graft adherence, as the use of viscoelastics may be associated with higher detachment rates.<sup>25</sup>

On the other hand, when first performing isolated DMEK, the present data together with the relatively low 5-year visually significant cataract formation rate of 16.9% recently described in a series of 124 phakic DMEK eyes,<sup>3</sup> may support a strategy to preserve the (clear) crystalline lens in a selected group of younger FECD patients, who may still benefit from a residual accommodative capacity and a better overall optical quality of the eye. Moreover, this approach may avoid complications of an additional surgery. Iatrogenic damage to the DMEK graft may be a legitimate concern regarding cataract surgery after DMEK.<sup>26</sup> Several studies, however, showed that cataract extraction is feasible with acceptable endothelial cell loss when performed with certain precautions.<sup>27-30</sup> If so, it would stand to reason to leave a relatively clear crystalline lens in situ for eyes in which the corneal disease is the predominant reason for visual deterioration, so that cataract surgery may be deferred to a later time point.<sup>31</sup>

Re-bubbling rates were comparable in phakic and pseudophakic FECD eyes, in line with observations by other groups.<sup>32</sup> It might be noteworthy, that the about four-fold increase in re-bubbling procedures from the first 500 DMEK cases to the second 500 DMEK cases can be attributed to our changed policy regarding re-bubbling graft detachments. While we initially tended to await spontaneous corneal clearance or graft attachment, we nowadays await the 1-week follow-up to decide if a re-bubbling procedure is required.<sup>33,34</sup>

In conclusion, our study confirms that DMEK consistently provides excellent short-term results, with similar high visual acuity levels for both FECD and BK eyes. As preoperative lens status did not influence DMEK outcomes, in phakic FECD eyes with a still relatively clear crystalline lens, it may be preferable to preserve the lens in a selected group of younger patients, who may still benefit from their residual accommodative capacity.

## REFERENCES

1. Melles GR, Ong TS, Ververs B, van der Wees J. Descemet membrane endothelial keratoplasty (DMEK). *Cornea* 2006;25:987-90
2. Eye Bank Association of America. *2018 Eye banking Statistical Report* Washington, DC: Eye Bank Association of America; 2019
3. Birbal RS, Ni Dhubhghaill S, Bourgonje VJA, et al. Five-year graft survival and clinical outcomes of 500 consecutive cases after Descemet membrane endothelial keratoplasty. *Cornea* 2020;39:290-7
4. Rodríguez-Calvo-de-Mora M, Quilendrino R, Ham L, et al. Clinical outcome of 500 consecutive cases undergoing Descemet's membrane endothelial keratoplasty. *Ophthalmology* 2015;122:464-70
5. Hamzaoglu EC, Straiiko MD, Mayko ZM, Sáles CS, Terry MA. The First 100 eyes of standardized Descemet stripping automated endothelial keratoplasty versus standardized Descemet membrane endothelial keratoplasty. *Ophthalmology* 2015;122:2193-9
6. Deng SX, Lee WB, Hammersmith KM, et al. Descemet membrane endothelial keratoplasty: safety and outcomes: a report by the American Academy of Ophthalmology. *Ophthalmology* 2018;125:295-310
7. Guerra FP, Anshu A, Price MO, Giebel AW, Price FW. Descemet's membrane endothelial keratoplasty: prospective study of 1-year visual outcomes, graft survival, and endothelial cell loss. *Ophthalmology* 2011;118:2368-73
8. Feng MT, Price MO, Miller JM, Price FW Jr. Air reinjection and endothelial cell density in Descemet membrane endothelial keratoplasty: five-year follow-up. *J Cataract Refract Surg* 2014;40:1116-21
9. Schlögl A, Tourtas T, Kruse FE, Weller JM. Long-term clinical outcome after Descemet membrane endothelial keratoplasty. *Am J Ophthalmol* 2016;169:218-226
10. Price DA, Kelley M, Price FW Jr, Price MO. Five-year graft survival of Descemet membrane endothelial keratoplasty (EK) versus Descemet stripping EK and the effect of donor sex matching. *Ophthalmology* 2018;125:1508-14
11. Schrittenlocher S, Schaub F, Hos D, Siebelmann S, Cursiefen C, Bachmann B. Evolution of consecutive Descemet membrane endothelial keratoplasty outcomes throughout a 5-year period performed by two experienced surgeons. *Am J Ophthalmol* 2018;190:171-8
12. Parker J, Dirisamer M, Naveiras M, et al. Outcomes of Descemet membrane endothelial keratoplasty in phakic eyes. *J Cataract Refract Surg* 2012;38:871-7
13. Baydoun L, Ham L, Borderie V, et al. Endothelial survival after Descemet membrane endothelial keratoplasty: effect of surgical indication and graft adherence status. *JAMA Ophthalmol* 2015;133:1277-85
14. Brockmann T, Brockmann C, Maier AB, Schroeter J, Bertelmann E, Torun N. Primary Descemet's membrane endothelial keratoplasty for Fuchs endothelial dystrophy versus bullous keratopathy: histopathology and clinical results. *Curr Eye Res* 2018;43:1221-27
15. Lie JT, Birbal R, Ham L, van der Wees J, Melles GR. Donor tissue preparation for Descemet membrane endothelial keratoplasty. *J Cataract Refract Surg* 2008;34:1578-83
16. Groeneveld-van Beek EA, Lie JT, van der Wees J, Bruinsma M, Melles GR. Standardized 'no-touch' donor tissue preparation for DALK and DMEK: harvesting undamaged

- anterior and posterior transplants from the same donor cornea. *Acta Ophthalmol* 2013;91:145-50
17. Dapena I, Moutsouris K, Droutsas K, Ham L, van Dijk K, Melles GR. Standardized “no-touch” technique for Descemet membrane endothelial keratoplasty. *Arch Ophthalmol* 2011;129:88-94
  18. Heinzelmann S, Böhringer D, Eberwein P, Reinhard T, Maier P. Outcomes of Descemet membrane endothelial keratoplasty, Descemet stripping automated endothelial keratoplasty and penetrating keratoplasty from a single centre study. *Graefes Arch Clin Exp Ophthalmol* 2016;254:515-22
  19. Birbal RS, Tong CM, Dapena I, et al. Clinical outcomes of Descemet membrane endothelial keratoplasty in eyes with a glaucoma drainage device. *Am J Ophthalmol* 2019;199:150-8
  20. Woo JH, Ang M, Htoon HM, Tan DT. Descemet membrane endothelial keratoplasty versus Descemet stripping automated endothelial keratoplasty and penetrating keratoplasty. *Am J Ophthalmol* 2019;207:288-303
  21. Morishige N, Sonoda KH. Bullous keratopathy as a progressive disease: evidence from clinical and laboratory imaging studies. *Cornea* 2013;32 Suppl 1:S77-83
  22. Fajgenbaum MAP, Kopsachilis N, Hollick EJ. Descemet’s membrane endothelial keratoplasty: surgical outcomes and endothelial cell count modelling from a UK centre. *Eye* 2018;32:1629-35
  23. Heinzelmann S, Maier P, Böhringer D, Hüther S, Eberwein P, Reinhard T. Cystoid macular oedema following Descemet membrane endothelial keratoplasty. *Br J Ophthalmol* 2015;99:98-102
  24. Laaser K, Bachmann BO, Horn FK, Cursiefen C, Kruse FE. Descemet membrane endothelial keratoplasty combined with phacoemulsification and intraocular lens implantation: advanced triple procedure. *Am J Ophthalmol* 2012;154:47-55
  25. Chaurasia S, Price FW Jr, Gunderson L, Price MO. Descemet’s membrane endothelial keratoplasty: clinical results of single versus triple procedures (combined with cataract surgery). *Ophthalmology* 2014;121:454-8
  26. Dapena I, Ham L, Tabak S, Balachandran C, Melles GR. Phacoemulsification after Descemet membrane endothelial keratoplasty. *J Cataract Refract Surg* 2009;35:1314-5
  27. Musa FU, Cabrerizo J, Quilendrin R, Dapena I, Ham L, Melles GR. Outcomes of phacoemulsification after Descemet membrane endothelial keratoplasty. *J Cataract Refract Surg* 2013;39:836-40
  28. Burkhart ZN, Feng MT, Price FW Jr, et al. One-year outcomes in eyes remaining phakic after Descemet membrane endothelial keratoplasty. *J Cataract Refract Surg* 2014;40:430-4
  29. Gundlach E, Maier AK, Tsangaridou MA, et al. DMEK in phakic eyes: targeted therapy or highway to cataract surgery? *Graefes Arch Clin Exp Ophthalmol* 2015;253:909-14
  30. Siggel R, Heindl LM, Cursiefen C. Descemet membrane endothelial keratoplasty (DMEK) in phakic eyes with shallow anterior chamber. *Graefes Arch Clin Exp Ophthalmol* 2015;253:817-9
  31. Tong CM, Baydoun L, Melles GRJ. Descemet membrane endothelial keratoplasty and refractive surgery. *Curr Opin Ophthalmol* 2017;28:316-25
  32. Godin MR, Boehlke CS, Kim T, Gupta PK. Influence of lens status on outcomes of Descemet membrane endothelial keratoplasty. *Cornea* 2019;38:409-12

33. Yeh RY, Quilendrino R, Musa FU, Liarakos VS, Dapena I, Melles GR. Predictive value of optical coherence tomography in graft attachment after Descemet's membrane endothelial keratoplasty. *Ophthalmology* 2013;120:240-5
34. Gerber-Hollbach N, Baydoun L, Fernandez-Lopez E, et al. Clinical outcome of rebubbling for graft detachment after Descemet membrane endothelial keratoplasty. *Cornea* 2017;36:771-6

