Universiteit Leiden
The Netherlands

Advances in endothelial keratoplasty

Birbal, R.S.

Citation
Birbal, R. S. (2020, November 17). *Advances in endothelial keratoplasty*. Retrieved from https://hdl.handle.net/1887/138387

Version:	Publisher's Version
License:	Licence agreement concerning inclusion of doctoral thesis in the Institutional Repository of the University of Leiden
Downloaded from:	https://hdl.handle.net/1887/138387

Note: To cite this publication please use the final published version (if applicable).

Cover Page

Universiteit Leiden

Leiden University Repository

The handle http://hdl.handle.net/1887/138387 holds various files of this Leiden University dissertation.

Author: Birbal, R.S.
Title: Advances in endothelial keratoplasty
Issue Date: 2020-11-17

Advances in Endothelial Keratoplasty

Rénuka S. Birbal

Advances in Endothelial Keratoplasty

Rénuka S. Birbal

Advances in Endothelial Keratoplasty

Thesis, Leiden University Medical Center, The Netherlands

Cover image and design by:	Claudia Claas, Valetti
Cover:	The cover image displays a watercolor drawing of the Sakura flower. The Sakura flower is a symbol of spiritual beauty and hope. When it blooms, it is a stunningly, transformative depiction of spring's promise of renewal after a dark winter. Its fleeting presence reminds us to live life with gratitude and to savour small joys in every moment.
Photography:	Netherlands Institute for Innovative Ocular Surgery (NIIOS), Rotterdam, The Netherlands
Layout and printed by:	Optima Grafische Communicatie, Rotterdam, The Netherlands (www.ogc.nl)
ISBN:	978-94-6361-455-9

Copyright © 2020 Rénuka Sadhna Birbal, Leiden, The Netherlands

No part of this thesis may be reproduced in any form or by any means without written permission from the author.

Financial support for the cover design and printing of this thesis was generously provided by:

Frédérique Bak Oogprothesen B.V., Visser Contactlenzen, Stichting Researchfonds Cornea Centrum Nederland and Stichting Leids Oogheelkundig Ondersteuningsfonds

Advances in Endothelial Keratoplasty

Proefschrift

Ter verkrijging van
de graad van Doctor aan de Universiteit Leiden,
op gezag van de Rector Magnificus prof. mr. C.J.J.M. Stolker
volgens besluit van het College voor Promoties
te verdedigen op dinsdag 17 november 2020
klokke 16.15 uur

door

Rénuka Sadhna Birbal
Geboren te ‘s-Gravenhage
in 1987

Promotor

Prof. Dr. M.J. Jager

Copromotor

Dr. G.R.J. Melles, Netherlands Institute for Innovative Ocular Surgery (NIIOS), Rotterdam, Nederland

Leden Promotiecommissie

Prof. Dr. G.P.M. Luyten

Prof. Dr. F.H.J. Claas

Dr. D. Gatinel, Rothschild Foundation, Parijs, Frankrijk

Dr. V. Kocaba, NIIOS, Rotterdam, Nederland & Singapore Eye Research Institute, Singapore

For my Family

CONTENTS

Preface		8
Chapter 1	General Introduction and Thesis Outline	11
Part I	**Donor Tissue Preparation**	
Chapter 2	Donor Tissue Preparation for Descemet Membrane Endothelial Keratoplasty: An Updated Review. *Cornea 2018;37:128-35*	43
Part II	**Selective, Minimally-Invasive and Potentially Tissue-Sparing Surgical Treatment Modalities for Corneal Endothelial Disorders**	
Chapter 3	Effect of Surgical Indication and Preoperative Lens Status on Descemet Membrane Endothelial Keratoplasty Outcomes. *Am J Ophthalmol 2020;212:79-87*	65
Chapter 4	Five-Year Graft Survival and Clinical Outcomes after Descemet Membrane Endothelial Keratoplasty: Results of the First 500 Consecutive Cases. *Cornea 2020;39:290-7*	85
Chapter 5	Clinical Outcomes of Descemet Membrane Endothelial Keratoplasty in Eyes with a Glaucoma Drainage Device. *Am J Ophthalmol 2019;199:150-8*	103
Chapter 6	Descemet Membrane Endothelial Transfer: Ultimate Outcome. *Cornea 2018;37:141-4*	125
Chapter 7	Outcomes of Hemi-Descemet Membrane Endothelial Keratoplasty for Fuchs Endothelial Corneal Dystrophy. *Cornea 2018;37:854-8*	134
Chapter 8	Quarter-Descemet Membrane Endothelial Keratoplasty: One- to Two-Year Clinical Outcomes. *Cornea 2020;39:277-82*	149
Chapter 9	Summary and Future Directions	163
Chapter 10	Nederlandse Samenvatting (Dutch Summary)	183
Appendices	List of Publications	206
	Acknowledgements	208
	Curriculum Vitae	211

PREFACE

Corneal diseases are among the leading causes of reversible blindness worldwide. When conservative measures fail, many eyes can be managed with corneal transplantation, also known as corneal grafting or keratoplasty.

The first successful corneal allograft transplantation in a human was performed by Dr. Eduard Zirm in 1905. Since then, innumerable ophthalmologists and scientists have contributed to the development of operating microscopes, the refinement of surgical instruments and new methodologies for corneal transplantation and the establishment of eye banks. Additionally, an increased understanding of corneal biology and an improved management of allograft rejection with anti-inflammatory agents, such as corticosteroids, have dramatically improved clinical outcomes.

Currently, corneal transplantation is one of the most often performed and most successful types of tissue transplantation. Historically, *full* thickness corneal transplantation, also known as penetrating keratoplasty (PK), has been the mainstay of care in the treatment of corneal disorders. In the past two decades, however, there has been a trend towards the selective, minimally-invasive replacement of the diseased corneal layers, rather than replacement of all layers. These *partial* thickness corneal transplantations are known as *lamellar keratoplasties.* Lamellar keratoplasty has revolutionized the management of corneal disorders and has significantly improved the utilization of cadaveric corneal grafts and clinical outcomes after keratoplasty.

In 2006, *Descemet membrane endothelial keratoplasty* (DMEK), the latest refinement of lamellar keratoplasty, was introduced, enabling selective replacement of Descemet membrane (DM) with its endothelial layer. DMEK provides a near-perfect corneal restoration yielding drastically improved clinical outcomes for patients with endothelial disorders.

Shortly after its introduction, corneal clearance was described in eyes with a (partial) graft detachment after DMEK or an almost 'free-floating' DMEK graft in the recipient anterior chamber. The latter procedure, which at some point was performed intentionally, was tentatively referred to as *Descemet membrane endothelial transfer* (DMET). DMET entailed descemetorhexis followed by insertion of a free-floating DMEK graft that contacted the posterior cornea only at the corneal incision. While some eyes showed corneal clearance after

the procedure, a major drawback of DMET is that, if corneal clearance occurs at all, it may take up to several months.

While DMEK was clinically very successful, it had yet failed to adequately address the significant shortage of corneal donor tissue in many parts of the world. Therefore, attempts were made to obtain more than one endothelial graft out of one donor cornea and a further refinement of DMEK included Hemi-DMEK, that is, transplantation of a full diameter, semi-circular graft. A preliminary study on the clinical outcomes of Hemi-DMEK showed that Hemi-DMEK may result in visual outcomes similar to those after conventional DMEK.

Aiming to use donor tissue even more efficiently and to surpass the drawbacks of DMET, Quarter-DMEK was developed as a hybrid technique that aimed to combine the advantages of both DMEK (fast corneal clearance) with DMET and 'descemetorhexis only' (host peripheral endothelial cell migration). Quarter-DMEK has shown promising 6-month results for an initial cohort of Fuchs endothelial corneal dystrophy eyes and bears the advantage of potentially quadrupling the availability of endothelial donor grafts if outcomes would remain stable on the longer term.

This thesis will focus on donor tissue preparation for DMEK and the feasibility and clinical outcomes of DMEK, DMET, Hemi-DMEK and Quarter-DMEK.

Chapter 1

General Introduction and Thesis Outline

GENERAL INTRODUCTION

The human cornea is the most anterior, transparent structure of the globe. It serves as a barrier to protect intraocular structures and provides about two-thirds of the entire refractive power of the eye.[1] The cornea measures 11-12 mm horizontally, and 10-11 mm vertically, with a central radius of curvature of approximately 8 mm. It has an average thickness of 500 to 600 µm.[1-3] With a high degree of innervation by the ophthalmic branch of the trigeminal nerve (approximately 300-400x that of the epidermis), it is one of the most sensitive tissues in the human body.[1] The cornea is uniquely avascular, and acquires its nutrients from the tear film or aqueous humor.[1,3,4] The lack of vascularization contributes to corneal clarity, optical performance, and relative immune privilege.[1,3] The cornea is amenable to transplantation and eye banks play an important role in procurement, storage, and allocation of corneal tissue for transplantation.

ANATOMY AND PHYSIOLOGY OF THE HUMAN CORNEA

The human cornea is a transparent tissue with a high degree of spatial organization and a strong correlation between structure and function. It consists of five histologic layers, from anterior to posterior: epithelium with its basement membrane, Bowman layer, stroma, Descemet membrane (DM) and endothelium (Fig. 1).[1-4] In order to optimize corneal optics and refractive power, a healthy tear film-cornea interface is required to provide a smooth and regular surface.[1,3,4] The tear film forms the primary biodefense system for the anterior surface of the eye.[1,3,4] It supplies nutrients and growth factors, which are essential for corneal homeostasis.[1,3,4]

The *epithelium* is the outermost anterior layer of the cornea. It is about 50 µm thick, and is composed of 5-7 layers of non-keratinized, stratified, squamous epithelial cells.[1,4] The epithelium is highly uniform from limbus to limbus to maintain a smooth refractive surface. It contributes to corneal transparency by having few intracellular organelles, and high concentrations of the intracytoplasmic enzyme crystalline.[1] The epithelium forms an effective corneal barrier and consists of several layers of superficial, flat, polygonal cells, two or three layers of suprabasal or wing cells, and a single cell layer of columnar basal cells.[1,3] Corneal epithelial cells have an average lifespan of 7-10 days and

complete epithelial turnover takes place on a weekly basis.[1,3,4]The epithelial basement membrane is 40-60 nm thick, and is composed of type IV collagen and laminin secreted by basal cells.[1,3,4]

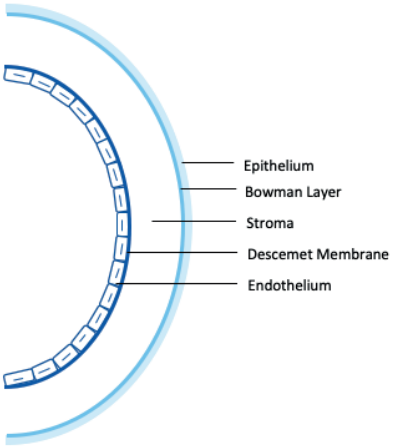

Figure 1. Schematic representation of the anatomical layers of the human cornea.

Bowman layer (BL) is an acellular layer positioned just beneath the epithelial basement membrane.[1-4] The anterior surface is very smooth, while the posterior surface extends into the anterior stroma.[1-4] It is approximately 8-14 µm thick, and thins with age.[1,5] In contrast to the underlying stromal collagen fibrils (diameter 32-36 nm) that run uniformly parallel across the corneal to form characteristic lamellae, BL consists of smaller, randomly interwoven collagen fibrils (24-27 nm).[6] These fibrils are primarily composed of collagen types I and III and form a dense, felt-like sheet.[7]BL does not regenerate after injury and to date, the physiologic function of BL remains to be elucidated.[1,3]

The *stroma* provides the largest portion of the structural framework of the cornea. It accounts for nearly 90% of the total corneal thickness and measures an average of 500 µm in humans.[1,3,4] The stroma contributes to corneal transparency, mechanical strength, and tectonic stability. It is made up of collagen fibers embedded in an extracellular matrix (ECM) composed of mainly water, inorganic salts, proteoglycans, and glycoproteins.[8] Keratocytes are the major cell type of the stroma and are scattered among the stromal lamellae.[1,3,4] They are involved in maintaining stromal homeostasis and hold the potential to create collagen molecules and glycosaminoglycans, while also creating matrix metalloproteases (MMPs).[1,3,4] Most of the keratocytes reside in the an-

terior stroma and contain corneal crystallins that are responsible for reducing backscatter.[9] In a healthy cornea, keratocytes remain dormant. They transform into myofibroblasts in response to various types of injury and participate in wound repair by producing ECM, secreting cytokines and collagen-degrading enzymes, and by contracting the edges of the wound. The collagen fibers (mainly types I and V) are structured in parallel bundles and organized in parallel-arranged lamellae.[1,3,4] Human stroma consists of 200-250 distinct lamella.[1,3,4] Each of them is aligned at right angles relative to fibers in adjacent lamellae.[10] The stroma is thicker peripherally than centrally, and as the collagen fibrils approach the limbus they may change direction to run circumferentially.[11] The ultrastructure of the lamellae varies, based on the stromal depth: deeper layers are more strictly organized than superficial layers.[3] The high degree of spatial organization of stromal fibers and extracellular matrix contributes to corneal transparency and rigidity. The posterior lamellae in the central cornea are more hydrated than the anterior lamellae and are believed to have less interlacing, resulting in easier swelling of the posterior stroma compared with the anterior stroma.[3] Stromal collagen fibrils are surrounded by specialized proteoglycan, consisting of keratan sulfate or chondroitin sulfate/dermatan sulfate side chains, which help regulate hydration and structural properties.[3]

In 2013, Dua studied the effect on corneal biomechanics and cleavage planes of injecting air into the posterior stroma as is done in deep anterior lamellar keratoplasty (DALK) with the big bubble (BB) technique. He proposed that there exists another, distinct, well-defined layer between the posterior stroma and Descemet membrane.[12] This acellular, 6-12 µm thick tissue was coined "Dua's layer", later renamed the "Dua-Fine layer".[13] It has been the source of much controversy and debate. Other groups have postulated that while this layer has a unique cohesiveness and configuration, it does not represent a distinct and separate corneal layer. Rather, the BB technique helps to describe the mechanical posterior stromal response to non-physiologic stress.[14,15]

Descemet membrane (DM) is located directly behind the posterior stroma and is the basement membrane of the corneal endothelium. DM gradually increases in thickness from 3 µm at birth to 10-12 µm in adulthood.[3] It is continually secreted by the corneal endothelium. Three distinct zones may be distinguished: a thin non-banded zone adjacent to the stroma (0.3 µm), an anterior banded zone (2-4 µm) and a posterior, amorphous, non-banded zone (>4 µm), that thickens with age. DM primarily consists of collagen types IV and VIII, laminin, and fibronectin.[16,17] DM, with its adjacent endothelium, can be peeled off from

the posterior stroma as a single sheet. Once completely detached, DM will spontaneously curl into a single or double roll.[18,19]

The *endothelium* is the innermost posterior layer of the human cornea and measures 4 µm in thickness in adulthood. This monolayer consists of tightly-packed hexagonal cells and appears as a honeycomb mosaic when viewed posteriorly.[3] The endothelium plays a key role in preserving corneal transparency by maintaining the cornea in a relative state of deturgescence.[1] The 'pump-leak' hypothesis proposes that the endothelium in a healthy cornea achieves corneal clarity by maintaining a state of equilibrium between two fluid transport pathways. A low-resistance apical junction between the endothelial cells allows fluid from the anterior chamber to 'leak' into the stroma (passive diffusion), whereas Na^+/K^+- and bicarbonate-dependent Mg^{2+}-ATPase pumps create local osmotic gradients, thereby actively returning fluid from the stroma to the anterior chamber.[1] Dysfunction of either of these pathways can result in corneal edema and reduced corneal transparency. The endothelial cell density (ECD) is approximately 6000 cells/mm^2 at birth and gradually decreases to about 3500 cells/mm^2 by the age of 5 years as the eyes grow.[20,21] During adulthood, ECD decrease slows down to an annual decrease of approximately 0.6%.[22,23] Apart from aging, accelerated cell loss may be caused by a genetic predisposition, prior intraocular surgery, trauma, elevated intraocular pressure, diabetes mellitus, and chronic anterior chamber inflammation.[24] Endothelial cells do not regenerate *in vivo*. When cells are lost, an endothelial defect will be restored by expansion (polymegathism) and active migration of adjacent cells. During this process, loss of hexagonality of the cells may occur (pleomorphism).[3,25,26] When the ECD count decreases to the extent that the overall remaining endothelial pumping capacity fails to maintain the equilibrium between the beforementioned pathways, endothelial decompensation may occur, resulting in irreversible corneal edema, reduced corneal clarity, pain and vision loss.[27]

Common indications for endothelial keratoplasty

Fuchs Endothelial Corneal Dystrophy

Fuchs endothelial corneal dystrophy (FECD) is the most common corneal dystrophy and currently one of the leading indications for corneal transplantation.[28] It was first described in 1910 by the Austrian ophthalmologist Ernst Fuchs and is a slowly progressive, bilateral corneal disease. Hallmark features of FECD include accumulation of wart-like excrescences of DM better known as 'guttae', thickening of DM, endothelial cell pleomorphism and polymegathism and loss of endothelial cells (Figs. 2,3).[29-32] With advancing disease, stromal edema may compromise visual function, with vision being worse in the morning and improving during the day. In end-stage disease, epithelial bullae may develop, evolving into subepithelial fibrosis and corneal vascularization.

Based on the time of onset of disease, two clinical subtypes of FECD may be distinguished: early-onset FECD (3-40 years) and late-onset FECD (>40 years), with the late-onset form being more common.[33] The early-onset form of FECD has been associated with autosomal dominant Q455K, Q455V and L450W mutations in the gene encoding the alpha 2 subunit collagen 8 (COL8A2). Men and women are equally affected. In contrast to early-onset FECD, a female predominance of 3:1 has been reported for late-onset FECD. Currently, 5 causal genes (TCF4, AGBL1, LOXHD1, SLC4A11 and ZEB1) and 4 causal loci on chromosomes 5, 9, 13, and 18 have been identified in individuals with late-onset FECD. Expanded repeats of the trinucleotide cytosine-thymine-guanine (CTG repeats) in the 3rd intron of TCF4 within chromosome 18q21.1 may be the most commonly identified genetic contributor to FECD.[34] Despite the identification of some genetic factors, the exact pathophysiology of FECD remains unclear and is thought to be a combination of both environmental and genetic factors. Both subtypes display a similar linear rate of disease progression.

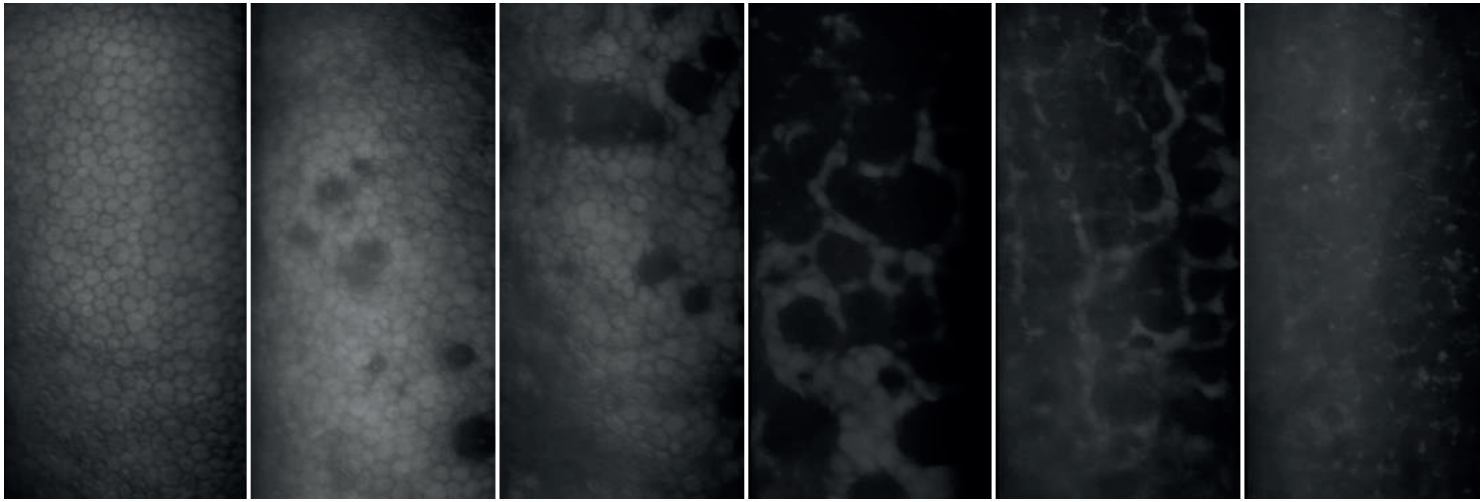

Figure 2. Specular microscopy images displaying healthy endothelium (left image) and different stages, from moderate to advanced, of Fuchs endothelial corneal dystrophy (images from left to right).

Bullous keratopathy

Bullous keratopathy develops as a result of endothelial decompensation due to endothelial injury caused by various conditions or events such as birth injury or intraocular surgery, including complicated cataract surgeries, glaucoma surgeries, or vitreoretinal surgeries. Symptoms may present in the immediate post-traumatic period or years after the injury. With advancing corneal edema, patients often manifest with (sub)epithelial bullae resulting in painful corneal micro-defects when they rupture.[35] In advanced stages, subepithelial fibrosis, with or without BL disruption, may develop.[35]

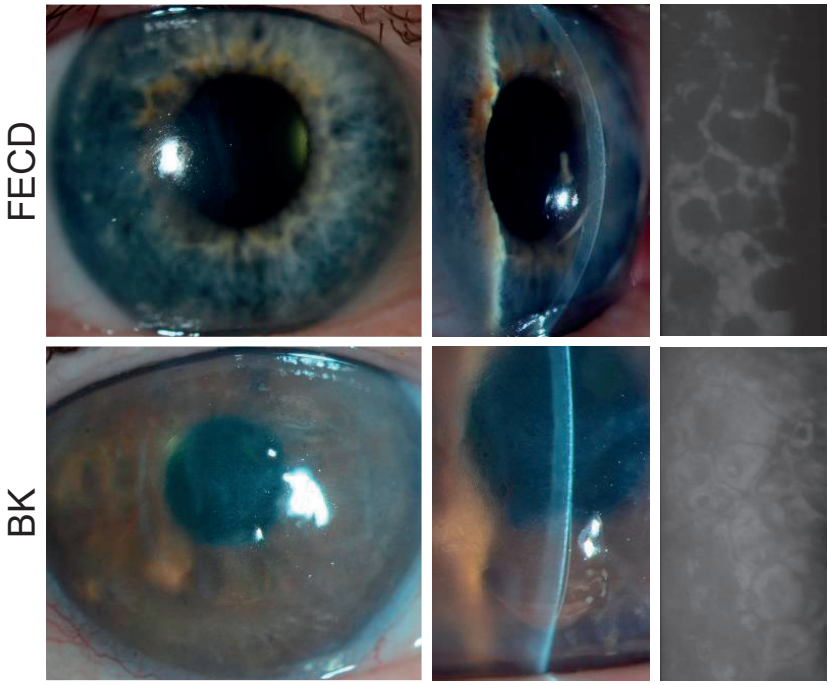

Figure 3. Slit-lamp and specular microscopy images of eyes with Fuchs endothelial corneal dystrophy (FECD) and bullous keratopathy (BK).

CORNEAL TRANSPLANTATION

History of corneal transplantation

Replacing diseased corneal tissue has been under consideration for a long time, with major changes occurring in recent years. The first description of keratoprosthesis originates from the French surgeon Guillaume Pellier de Quengsy.[36] During the French revolution in 1789, he hypothesized that a transparent material could be used to replace an opaque cornea in order to restore vision. In 1796, Erasmus Darwin proposed the first corneal trephine and postulated that the cornea might heal secondary to forming a transparent scar.[37] In 1813, Karl Himley proposed replacing opaque animal corneas with corneas from other animals, but it was not until 1818 that his student Franz Reisinger initiated these experimental animal corneal transplants.[38]In 1824, Reisinger coined the term 'keratoplasty' and proposed using animal tissue to replace human corneas. His animal experiments, however, failed to produce clear grafts. In 1837, the Irish surgeon Samuel Bigger reported his first successful penetrating graft on a pet gazelle blinded by extensive corneal scarring.[39] In 1838, inspired by Bigger, New York-based ophthalmologist Richard Kissam performed the first recorded corneal xenograft, from a 6-month old pig, on a young Irishman in 1838.[40] While increased light perception occurred immediately after the operation, the cornea opacified within the first fortnight and was absorbed within one month after the operation. For the remainder of the 19th century, the pioneers of corneal transplantation could be divided into two main groups: those who favored full-thickness allografts (Henry Powers) and those who favored partial-thickness lamellar xenografts (Arthur von Hippel).[38,41] In 1905, the first successful human allograft was performed by Eduard Zirm.[42] The recipient was a farmer who had sustained bilateral alkali burns while cleaning out a chicken coop with lime 16 months earlier. Zirm used donor tissue from the enucleated eye of an 11-year old boy whose eye had been blinded by a penetrating injury to the sclera. The eye was enucleated and the one donor cornea was used to procure two full-thickness grafts of 5 mm in diameter. While the graft in the right eye failed, the graft in the left eye remained clear and improved the visual acuity of the recipient from counting fingers preoperatively to 6/36 at 6 months after the operation. Since then, innumerable ophthalmologists and scientists have contributed to improving the technique, and in the century thereafter, penetrating keratoplasty (PK) became the mainstay of care in the treatment of all corneal disorders regardless of which layer was diseased.

History and evolution of endothelial keratoplasty

While the lamellar approach was already described with xenografts by Arthur von Hippel in 1888, it was not pursued in the decades thereafter. This was possibly because lamellar transplants were perceived to be technically more challenging than full-thickness transplants. While PK can yield an optically transparent cornea, it is also prone to potential complications such as poor wound healing, suture-related problems, high astigmatism, allograft rejection, graft failure, and unsatisfying visual outcomes, with many patients requiring contact lenses to reach their full visual potential after keratoplasty.[43,44]

Nevertheless, Charles Tillett performed the first posterior lamellar endothelial transplant underneath a manually dissected stromal flap in a patient with FECD in 1956.[45] In the 1960s, Barraquer et al. applied a similar technique which unfortunately also proved relatively unsuccessful.[46] These early attempts may have failed due to lack of suitable instrumentation to dissect thin corneal layers and limited understanding of endothelial cell physiology, resulting in early complications, and/or insufficient visual outcomes. As a result, the concept of endothelial keratoplasty was, once again, abandoned.

It was not until 1998, that Melles et al. introduced a technique for *posterior lamellar keratoplasty (PLK)*, currently known as *endothelial keratoplasty (EK)*, in which a posterior lamellar disc was excised from the recipient cornea and a same-size donor disc, consisting of posterior stroma, DM and endothelium, was implanted through a limbal scleral incision.[47] Although technically challenging, this technique provided clinical outcomes surpassing PK and circumvented many PK-associated complications.[48] In 2001, this technique was popularized as *deep lamellar endothelial keratoplasty (DLEK)* in the United States by Terry et al. (Fig. 4). In the initial PLK/DLEK technique, a donor disc was implanted into the recipient cornea through a 9-mm sclerocorneal incision and positioned against the recipient posterior cornea by means of an air-bubble.[47] In 2000, the initial technique was modified by Melles et al., folding the donor disc like a 'taco' to enable insertion through a self-sealing 5-mm tunnel incision.[49] This technique was popularized as *small incision DLEK*. Worldwide adoption was tempered by the technical difficulty of the procedure, which necessitated manual dissection of both donor and host tissue.

To simplify the technique, Melles et al. abandoned recipient stromal dissection and introduced 'descemetorhexis', a new approach in which only recipient DM and endothelium were stripped, using a reversed Sinskey hook.[50] Des-

cemetorhexis was followed by implantation of a taco-folded donor disc, which was subsequently positioned onto the denuded host posterior stroma with an air-bubble. This approach was first performed clinically in 2001 and was later popularized by Price et al. as *Descemet stripping endothelial keratoplasty (DSEK)*.[50-52] Gorovoy et al. further simplified the technique by introducing an automated microkeratome to dissect the donor graft from a corneoscleral button mounted on an artificial anterior chamber. [53] This modification changed the nomenclature to *Descemet stripping automated endothelial keratoplasty (DSAEK)* (Figs. 4, 5). After these refinements in technique, the worldwide adoption of DSEK/DSAEK grew exponentially and it became the preferred treatment option for corneal endothelial disorders.[54]

Although DSEK/DSAEK represents a massive improvement compared to its predecessors, it still has some drawbacks. Even after technically successful transplantations, final visual acuity is variable and occasionally unsatisfyingly low. This has among others been ascribed to the presence of varying thickness of posterior stroma within the donor graft.[54-60]

In 2002, Melles et al. further refined the concept of endothelial keratoplasty by completely eliminating the posterior stroma from the donor graft, allowing selective replacement of bare DM with its endothelial layer. [49] This technique was coined *Descemet membrane endothelial keratoplasty (DMEK)* and was first performed successfully in a patient in 2006 (Figs. 4, 5).[61]

Descemet Membrane Endothelial Keratoplasty

After its introduction in 2006, the surgical procedure was further refined and standardized and as a result, a standardized 'no-touch' DMEK-technique was introduced in 2011.[62] The technique entailed scoring and descemetorhexis under air followed by an air-fluid exchange and implantation of a DMEK graft, ideally folded into a double roll with the curls facing upward, into the recipient anterior chamber. The DMEK graft was then unfolded over the iris by means of an air bubble injected in between the two curls and corneal tapping, and lifted against the recipient posterior stroma by inserting an air bubble underneath the DMEK graft. At the end of the surgery, a complete air fill of the anterior chamber was maintained for 60 minutes, after which an air-liquid exchange was performed to pressurize the eye and promote graft adherence.

Since its implementation, DMEK has shown to provide faster visual rehabilitation, improved visual outcomes, and lower graft rejection rates compared with

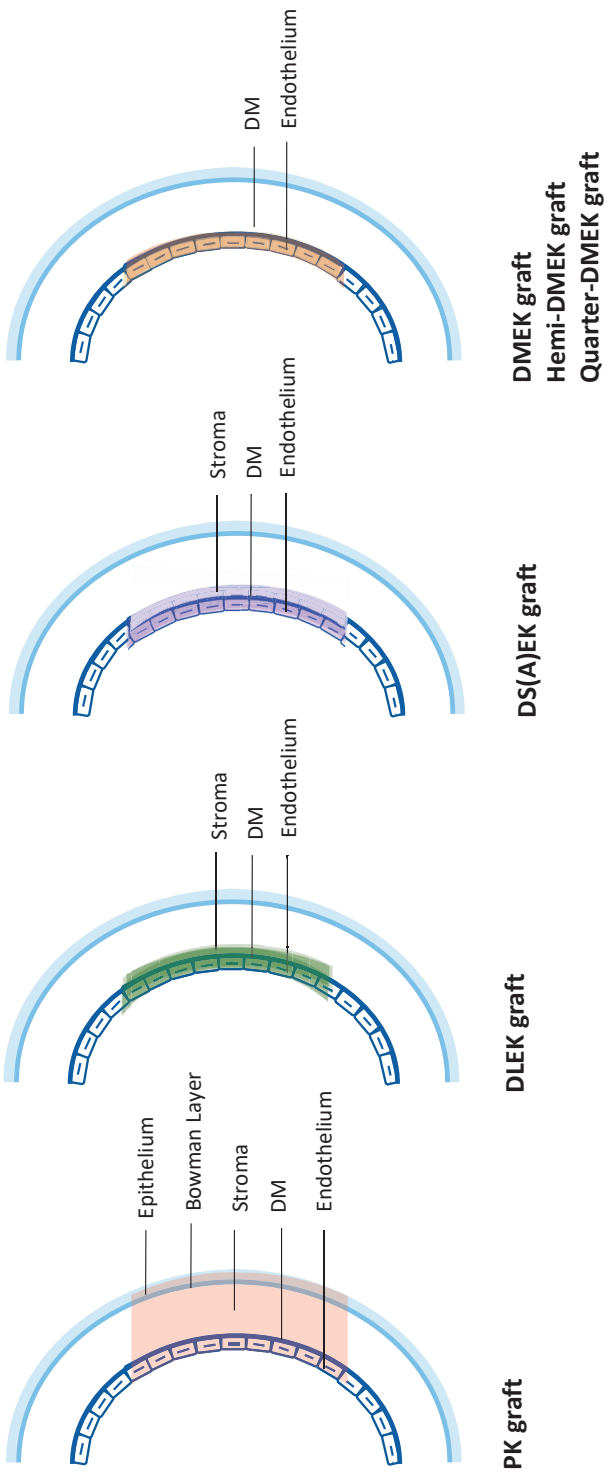

Figure 4. Schematic overview displaying the evolution of posterior keratoplasty techniques, from left to right: Penetrating keratoplasty (PK), Deep lamellar endothelial keratoplasty (DLEK), Descemet stripping (automated) endothelial keratoplasty (DS(A)EK) and conventional, Hemi- and Quarter-Descemet membrane endothelial keratoplasty (DMEK, Hemi-DMEK and Quarter-DMEK). DM= Descemet membrane

earlier EK-techniques.[63-70] In 2015, the American Academy of Ophthalmology evaluated the clinical efficacy, effectiveness and safety of DMEK by means of a systematic review.[71] The assessment revealed that 11 studies with 6-month clinical outcomes after DMEK reported that 32% to 85% of eyes achieved a BCVA of 20/25 or better, and 12 studies reported that 17% to 67% achieved a BCVA of 20/20 or better. Comparison of final visual acuity levels after DMEK and DSEK showed that, after surgery, a higher percentage in the DMEK group achieved a BCVA of 20/25 or better (50% vs 6%, 67% vs 31%, 53% vs 15% and 55% vs 13%) and a BCVA of 20/20 or better (46% vs 13%). Complications of DMEK include graft detachment, graft failure, allograft rejection, and endothelial cell loss. The mean rejection rate of 22 studies was 1.9% (range, 0% - 5.9%) during follow-up periods ranging from 6 months to 8 years. This is lower than the mean rejection rate of 10% (range, 0% - 45.5%) reported after DSEK.

Owing to its excellent results, an increasing number of corneal surgeons are adopting DMEK globally, and with increasing surgical experience complication rates are decreasing.[71] DMEK is nowadays increasingly employed in challenging cases such as eyes with anterior chamber intraocular lens implants and eyes with glaucoma drainage devices.[72-76]

Corneal graft failure

Corneal graft failure is an irreversible loss of corneal transparency due to graft dysfunction and thereby may become an indication for repeat keratoplasty. Graft failure is considered “primary”, if the cornea never cleared to regain satisfactory vision after the transplant surgery, or “secondary”, if the cornea initially cleared, but then decompensated at a later time point.[77] Predisposing risk factors for graft failure include previous graft failure, glaucoma (especially previous tube shunt surgery), peripheral anterior synechiae, corneal vascularization, immunologic allograft rejection, and ocular surface disease, especially lack of tears.[78] Signs of corneal graft failure include increased corneal thickness and corneal edema. Initial treatment consists of topical corticosteroid and hypertonic saline drops. Definitive treatment requires a repeat corneal transplantation.

Auxiliary techniques

As DMEK may still be perceived as relatively challenging in preparing and handling of the delicate donor graft, alternative keratoplasty techniques such as *Ultra-thin DSAEK* (in which a thin layer of posterior stroma (<100 µm) is transplanted as part of the donor lenticule), *pre-Descemet endothelial keratoplasty (PDEK) (*in which an even thinner layer of posterior stroma ‘the

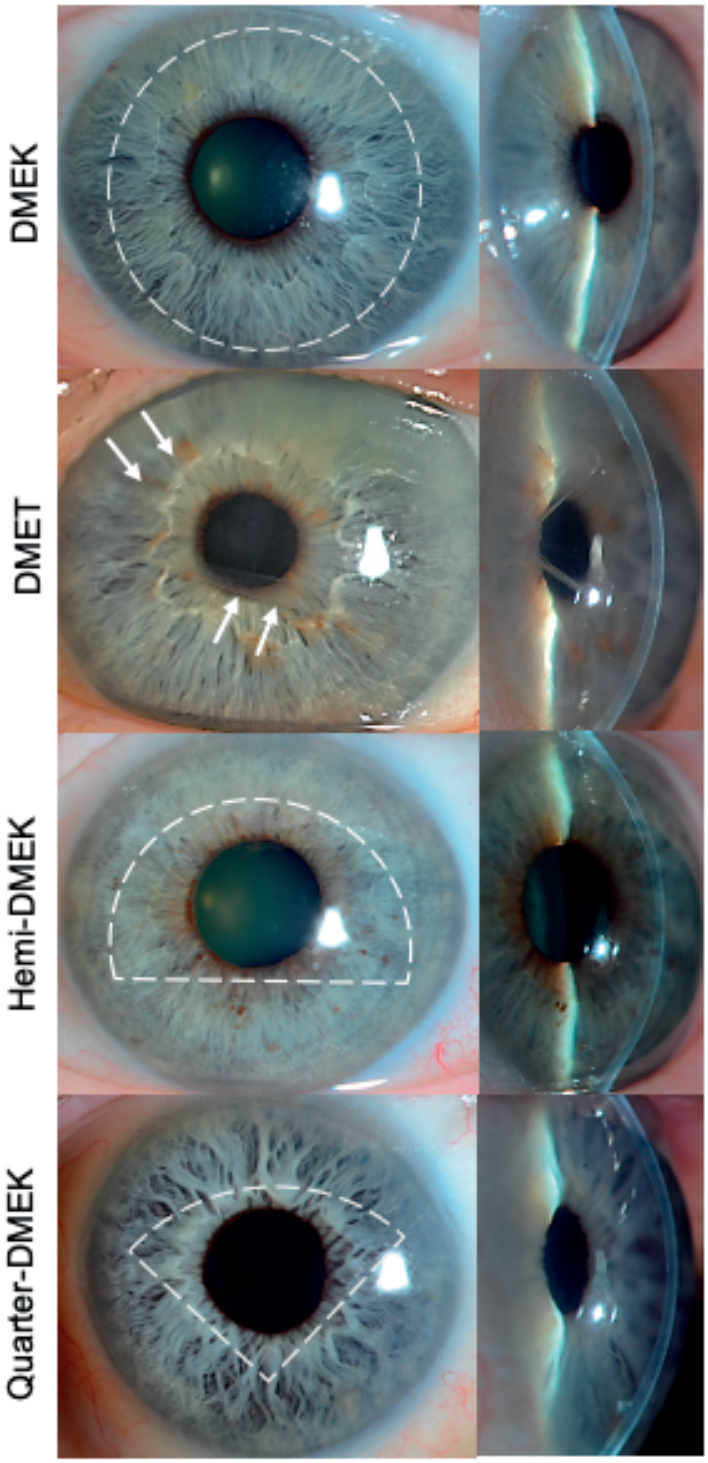

Figure 5. Slit-lamp images of eyes that underwent Descemet membrane endothelial keratoplasty (DMEK), Descemet membrane endothelial transfer (DMET), Hemi-DMEK and Quarter-DMEK. White dashed lines indicate the graft outline.

pre-Descemet layer' (<20 μm) is transplanted with the donor lenticule), and *DMEK with a stromal rim (DMEK-S)* were introduced as a middle way to allow for easier preparation and handling of the DMEK graft combined with visual outcomes possibly equaling those of DMEK.[79-81]

MODIFIED DMEK TECHNIQUES

Descemet Membrane Endothelial Transfer

The clinical observation that corneas showed resolution of corneal edema in the first few weeks after DMEK/DSAEK, despite (partial) graft detachment or in the absence of a DMEK graft, led to the introduction of *Descemet membrane endothelial transfer (DMET),* which consists of a descemetorhexis followed by insertion of the almost completely free-floating Descemet roll (i.e., with the graft contacting the posterior cornea only at the corneal incision) in 2008 (Fig. 5).[82-98] While preliminary results showed that DMET was effective in the management of eyes with FECD, it was not in eyes with BK.[85,98] This prompted the hypothesis that host endothelial cells in eyes with FECD still had some regenerative capacity and had retained the potential to migrate to bare stromal areas to repopulate them. This hypothesis was reinforced by case reports which reported corneal clearance after 'descemetorhexis only'.[86,87,89,93,99,100] However, mixed results have been reported for the latter technique, with a significant number of corneas failing to clear. A major drawback of DMET and 'descemetorhexis only' is that host peripheral endothelial cell migration is a relatively slow process and that, if corneal clearance occurs at all, it may take up to several months.

Hemi- and Quarter-Descemet membrane endothelial keratoplasty

As there is a substantial shortage of donor tissue for endothelial keratoplasty worldwide, which has not yet been met by the implementation of beforementioned techniques, further refinements of DMEK were introduced.[28] In 2014, Hemi-DMEK was introduced aiming to potentially double the availability of endothelial donor tissue (Fig. 5).[101] Hemi-DMEK represents a DMEK modification that differs from conventional DMEK only in graft shape. In Hemi-DMEK, an 'untrephined', full-diameter, semicircular (half-moon shaped) graft is utilized rather than a circular trephined Descemet graft.[102] As a Hemi-DMEK graft is untrephined and a conventional DMEK graft is trephined, both have a comparable graft surface area and a comparable number of endothelial cells is transplanted. Preliminary Hemi-DMEK studies have yielded visual outcomes

similar to those following conventional DMEK.[103-105] Longer-term studies are needed to determine whether the outcomes remain stable.

Mixed clinical outcomes after DMET and Hemi-DMEK and 'descemetorhexis only' led to the development of *Quarter-Descemet membrane endothelial keratoplasty (Quarter-DMEK)*.[106] Quarter-DMEK is a hybrid technique that aims to combine the advantages of both DMEK (fast corneal clearance) and 'descemetorhexis only' (host peripheral endothelial cell stimulation). In this relatively new technique, merely one quarter of a full-diameter donor Descemet graft is transplanted into eyes where FECD is limited to the central 6-7 mm optical zone of the cornea (Fig. 5). The first case report of Quarter-DMEK was published in 2016.[106] Quarter-DMEK showed promising visual acuity outcomes, but had a few drawbacks, including a higher rate of postoperative graft detachment, a steeper decline in endothelial cell density in the first 6 months after surgery and prolonged corneal clearance in some parts of the cornea.[107] Additional studies are needed to determine the efficacy of Quarter-DMEK relative to conventional circular DMEK.

EYE BANKING AND CORNEAL TRANSPLANTATION

Since the establishment of the first eye bank by Dr. Townley Paton in 1944, eye banks continue to play a key role in procuring, evaluating and distributing donated ocular tissue for transplantation and research. The evolution of PK to selective, lamellar EK was facilitated by a strong, symbiotic relationship between corneal surgeons and eye banks, especially since dissecting lamellar grafts has been perceived as more challenging than preparing full-thickness PK grafts. A successful outcome after keratoplasty largely depends on viable corneal endothelium.[108] Hence, the morphologic and functional status of the endothelium is the most important determinant for donor cornea suitability for transplantation and maintaining endothelial cell viability from the time of donor tissue retrieval until transplantation. Currently, two preservation methods are being applied by eye banks: hypothermic storage at 2-6ºC and organ culture storage at 30-37ºC.[109] Prolonged storage of donor tissue allows for extensive donor screening and facilitates surgical scheduling.

As with other endothelial keratoplasty techniques, donor tissue for DMEK may be prepared by corneal surgeons prior to surgery (surgeon-cut) or by experienced tissue specialists in an eye bank; this may take place up to 2 weeks

before surgery (pre-cut).[19,20,110,111] Pre-cut tissue may reduce overall intervention costs and surgery time, and allows for post-processing evaluation of the donor graft, providing corneal surgeons with accurate information about the donor tissue prior to surgery.[112]

Various techniques have been described for DMEK graft preparation, which may broadly be classified into those based on manual peeling and those aiming to achieve detachment of Descemet membrane (DM) by either injecting air or liquid between DM and the posterior stroma. Lie et al.[18] described the initial technique for DMEK graft preparation. A donor corneoscleral rim was mounted onto a custom-made fixation device with the endothelial side up. DM was cut anterior to the trabecular meshwork and pushed towards the center of the corneoscleral button. Grasping the outer edge of the graft, DM was loosened over 180 degrees and stripped for two-thirds. By submerging the rim in balanced salt solution (BSS), superficial trephination and complete stripping of DM were facilitated, after which the isolated graft spontaneously formed a roll with the endothelial layer facing outward. Groeneveld-van Beek et al.[19] modified the technique into the standardized "no-touch" technique, in which DM with the adjacent trabecular meshwork is loosened over 360 degrees rather than over 180 degrees and trephined on a soft contact lens instead of on the anterior cornea. The latter technique allows complete stripping of DM and facilitates further handling of the graft. It allows the user to obtain the maximum possible graft size, minimizes endothelial cell damage in the trephination area and leaves the anterior cornea intact and eligible for anterior lamellar keratoplasty. All preparation techniques feature different strengths and weaknesses which will be discussed in this thesis.

CORNEAL IMAGING TECHNIQUES AFTER ENDOTHELIAL KERATOPLASTY

Non-invasive corneal imaging modalities have proven to be useful diagnostic tools for evaluating graft adherence and graft function after EK. While slit-lamp biomicroscopy is the mainstay of corneal evaluation, Scheimpflug imaging and anterior segment optical coherence tomography (AS-OCT) may aid in assessing corneal optics and complications. Additionally, specular microscopy allows for analysis of endothelial cell density (ECD) and morphology.

Slit-lamp biomicroscopy is readily available in all ophthalmic clinical settings and aids in the assessment of graft adherence and corneal transparency after endothelial keratoplasty.[113] In the presence of corneal edema, however, it is not always possible to conclusively determine whether the DMEK graft is completely attached or not. 'Flat detachments', i.e. when the DMEK graft is not attached and positioned just parallel to the recipient posterior stroma, may be especially challenging to correctly interpret without the aid of imaging technology.[114] Auxiliary corneal imaging techniques, preferably AS-OCT, can be implemented to ensure that a (partially) detached graft in an eye with severe corneal edema does not go undetected. These techniques may, additionally, help to differentiate between a detached DMEK graft and an attached graft showing delayed corneal clearance, which may occur for instance due to a 'shock to the donor endothelial cells' pumping function.[115]

Corneal tomography analysis of the anterior segment utilizes a camera (based on the rotating Scheimpflug principle) perpendicular to a slit beam which can capture up to 100 images in two seconds (e.g. Pentacam HR). These images are used to create a 3-D model of the anterior segment of the eye and to provide quantitative data such as central radii, corneal asphericity, maps of curvature and elevation, chamber angle, chamber volume and chamber elevation as well as lens transparency.[116] Pentacam Scheimpflug imaging can aid with evaluating corneal astigmatism after keratoplasty and graft adherence after endothelial keratoplasty.[117] A drawback of this technique may be that, particularly in corneas with extensive corneal edema, backscatter may occur, which may impede adequate visualization of the graft and correct interpretation of graft adherence.[114,117] In addition, the Scheimpflug Pentacam uses Zernike polynomials to provide data on corneal wavefront aberrations. This can be valuable in detecting corneal irregularities which may explain unsatisfactory vision after endothelial keratoplasty.[118-120] Densitometry analysis can provide information on stromal opacities possibly affecting the quality of vision and the Pentacam can be applied to analyze the refractive stability of the cornea after endothelial keratoplasty. [121,122]

AS-OCT is a non-invasive imaging modality that provides both quantitative and qualitative information. It has a broad range of clinical applications. It generates two- and -three-dimensional cross-sectional images of tissue by integrating multiple axial scans (A-scans) into a composite lateral beam of light, the B-scan.[123,124] Time domain AS-OCT utilizes a light source emitting at 1310 nm, which offers the advantage of minimized scatter and high penetra-

tion.[123,124] This technique is particularly suited for imaging structural details in optical scattering media such as an edematous cornea, when slit-lamp biomicroscopy and Pentacam may fail to provide conclusive information. Recently, high-speed Fourier domain OCT (FD-OCT) has been introduced, which offers improved spatial resolution compared to time domain OCT. FD-OCT allows in vivo high-speed, high-resolution imaging of weakly backscattering tissues and can detect changes within a 10 µm range in corneal tissue.[125,126] Pre-operatively, AS-OCT may be employed to assess the thickness of the recipient cornea and to estimate the potential size of the graft. Intraoperatively, the OCT may be employed to visualize and assess graft orientation in DMEK surgery; especially in the presence of severe corneal edema, it may lead to faster graft positioning with less graft manipulation.[127] Postoperatively, AS-OCT may aid in detecting complications such as graft dislocation, anterior chamber angle narrowing, and pupillary block.[114,122] In addition, AS-OCT can precisely specify the extent and planarity of graft detachments. In the immediate postoperative period, when there is still an air-bubble in the anterior chamber, AS-OCT images should be interpreted with care as the edges of the air-bubble may reveal themselves as a separate line and may therefore mimic graft detachment. However, the air-bubble commonly presents as a relatively smooth line in comparison to a graft detachment.

Specular microscopy is a non-invasive imaging modality. It is currently the most widely applied diagnostic tool for evaluating the corneal endothelium, as it allows for *in vivo* visualization and analysis of the endothelium.[128-130] It is based on the reflection of the incoming light generated by the difference in refractive index of the endothelial cells and the aqueous humor.[128] As the main objective of endothelial keratoplasty is to regain endothelial function and subsequently corneal transparency, the donor endothelium should be closely monitored during the postoperative course.[128-130] Endothelial cell density is a key quantitative corneal endothelial parameter for evaluating the clinical outcome after keratoplasty, and polymegathism (cell size variability) and pleomorphism (cell shape variability, loss of hexagonal shape) are important qualitative indicators.[131,132] Image quality may be compromised by corneal pathology such as scarring or edema, which can increase light scattering in the stroma from collagen lamellae and keratocytes.[133] Commercial specular microscopes are usually provided with an automatic ECD analysis program. However, sufficient quality of the acquired images, with clearly displayed cell borders, and manual correction, is usually required to ensure reliable ECD measurements.[128,130,134]

AIM AND OUTLINE OF THIS THESIS

This thesis focuses on donor tissue preparation for DMEK and evaluates the feasibility and clinical outcomes of DMEK, DMET, Hemi-DMEK and Quarter-DMEK in the management of corneal endothelial disorders.

The first part of this thesis concerns donor tissue preparation for DMEK.
We tested whether the technique of DMEK graft dissection influences the clinical outcome after DMEK. ***Chapter 2*** provides an overview of the current harvesting techniques available for DMEK and a discussion of these techniques.

The second part of this thesis concerns the clinical outcome of selective, minimally-invasive and potentially tissue-sparing surgical treatment options for corneal endothelial disorders. We hypothesize that complete and lasting corneal rehabilitation may not always require a (nearly) fully, centrally attached large DMEK graft. We evaluated the six-month clinical results of 1000 consecutive DMEK cases and evaluated whether whether outcomes are influenced by surgical indication and preoperative lens status (**Chapter 3**).
Subsequently, we evaluated the five-year graft survival and clinical outcomes of 500 consecutive DMEK cases (**Chapter 4**). The feasibility and clinical outcomes of DMEK in eyes with a glaucoma drainage device are being described in **Chapter 5**. The next three chapters focus on the different endothelial grafting techniques, evaluating subtotal detachment of the DMEK graft after a DMEK procedure or intended DMET (**Chapter 6**), and outcomes of Hemi-DMEK (**Chapter 7**) and of Quarter-DMEK performed for FECD (**Chapter 8**).

REFERENCES

1. Sabet SJ, Adampoulou A. Basic structure and function of the human cornea and adnexal structures. In: *Copeland RA and Afshari NA (Ed.). Copeland and Afshari's Principles and Practice of Cornea*. Jaypee Brothers Medical Publishers, 2013
2. Duong QH. Corneal embryology. In: *Copeland RA and Afshari NA (Ed.). Copeland and Afshari's Principles and Practice of Cornea*. Jaypee Brothers Medical Publishers, 2013
3. DelMonte DW, Kim T. Anatomy and physiology of the cornea. *J Cataract Refract Surg* 2011;37:588-98
4. Sridhar MS. Anatomy of cornea and ocular surface. *Indian J Ophthalmol* 2018;66:190-4
5. Germundsson J, Karanis G, Fagerholm P, et al. Age-related thinning of Bowman's layer in the human cornea in vivo. *Invest Ophthalmol Vis Sci* 2013 11;54:6143-9
6. Marshall J, Grindle CF. Fine structure of the cornea and its development. T*rans Ophthalmol Soc U K* 1978;98:320-8
7. Wilson SE, Hong JW. Bowman's layer structure and function: critical or dispensable to corneal function? A hypothesis. *Cornea* 2000;19:417-20
8. Torricelli AA, Wilson SE. Cellular and extracellular matrix modulation of corneal stromal opacity. *Exp Eye Res* 2014;129:151-60
9. Jester JV, Moller-Pedersen T, Huang J, et al. The cellular basis of corneal transparency: evidence for 'corneal crystallins'. *J Cell Sci* 1999;112:613-22
10. Maurice DM. The transparency of the corneal stroma. *Vision Res.* 1970;10:107-8
11. Meek KM, Boote C. The organization of collagen in the corneal stroma. *Exp Eye Res* 2004;78:503-12
12. Dua HS, Faraj LA, Said DG, et al. Human corneal anatomy redefined: a novel pre-Descemet's layer (Dua's layer). *Ophthalmology* 2013;120:1778-85
13. Myron Y and Sassani *J Ocular Pathology 8th Edition* Elsevier, 2019
14. Jester JV, Murphy CJ, Winkler M, et al. Lessons in corneal structure and mechanics to guide the corneal surgeon. *Ophthalmology* 2013;120:1715-7
15. Schwab IR. Who's on first? *Ophthalmology* 2013;120:1718-9
16. Johnson DH, Bourne WM, Campbell RJ. The ultrastructure of Descemet's membrane. I. Changes with age in normal corneas. *Arch Ophthalmol* 1982;100:1942-7
17. Bourne WM, Johnson DH, Campbell RJ. The ultrastructure of Descemet's membrane III. Fuchs' dystrophy. *Arch Ophthalmol* 1982;100:1952-5
18. Lie JT, Birbal R, Ham L, et al. Donor tissue preparation for Descemet membrane endothelial keratoplasty. *J Cataract Refract Surg* 2008;34:1578-83
19. Groeneveld-van Beek EA, Lie JT, van der Wees J, et al. Standardized 'no-touch' donor tissue preparation for DALK and DMEK: harvesting undamaged anterior and posterior transplants from the same donor cornea. *Acta Ophthalmol* 2013;91:145-50
20. Bourne WM. Biology of the corneal endothelium in health and disease. *Eye* 2003;17:912-8
21. Mergler S, Pleyer U. The human corneal endothelium: new insights into electrophysiology and ion channels. *Prog Retin Eye Res* 2007;26:359-78
22. Murphy C, Alvarado J, Juster R, et al. Prenatal and postnatal cellularity of the human corneal endothelium. A quantitative histologic study. *Invest Ophthalmol Vis Sci* 1984;25:312-22

23. Bourne WM, Nelson LR, Hodge DO. Central corneal endothelial cell changes over a ten-year period. *Invest Ophthalmol Vis Sci* 1997;38:779-82
24. Capella JA. Regeneration of endothelium in diseased and injured corneas. *Am J Ophthalmol* 1972;74:810-7
25. Matsubara M, Tanishima T. Wound-healing of corneal endothelium in monkey: an autoradiographic study. *Jpn J Ophthalmol* 1983;27:444-50
26. Joyce NC. Cell cycle status in human corneal endothelium. *Exp Eye Res* 2005;81:629-38
27. van Dooren BTH. The corneal endothelium reflected: Studies on surgical damage to the corneal endothelium and on endothelial specular microscopy. Erasmus University Rotterdam 2006, June 21
28. Gain P, Jullienne R, He Z, et al. Global Survey of Corneal Transplantation and Eye Banking. *JAMA Ophthalmol* 2016;134:167-73
29. Fuchs E. Dystrophia epithelialis corneae. Graefes Arch Clin Exp Ophthalmol 1910:478–508
30. Wilson SE, Bourne WM. Fuchs' dystrophy. *Cornea* 1988;7:2-18
31. Gordon K Klintworth. Corneal dystrophies. *Orphanet J Rare Dis* 2009;4:7
32. Hussain Elhalis, Behrooz Azizi, Ula V. Jurkunas. Fuchs endothelial corneal dystrophy. *Ocul Surf* 2010; 8: 173–184
33. Villareal G, Kallay L, Vedana G, et al. Epidemiology and genetic basis of Fuchs endothelial corneal dystrophy. In: *Cursiefen C, Jun AS (Ed.). Current treatment options for Fuchs endothelial dystrophy.* Springer International Publishing Switzerland, 2017
34. Wieben ED, Aleff RA, Tosakulwong N, et al. A common trinucleotide repeat expansion within the transcription factor 4 (TCF4, E2-2) gene predicts Fuchs corneal dystrophy. *PLoS One* 2012;7:e49083
35. Morishige N, Sonoda KH. Bullous keratopathy as a progressive disease: evidence from clinical and laboratory imaging studies. *Cornea* 2013;32 Suppl 1:S77-83
36. Pellier de Quengsy G. Précis ou cours d'opérations sur la chirurgie des yeux par M.G. Pellier de Quengsy, fils. Paris: *Didot*; 1789
37. Darwin E. Zoonomia or the laws of organic life. Published by P. Byrne and W. Jones, Dublin 1796
38. Moffatt SL, Cartwright VA, Stumpf TH. Centennial review of corneal transplantation. *Clin Exp Ophthalmol* 2005; 33:642-57
39. Bigger SLL. An inquiry into the possibility of transplanting the cornea with a view to relieving blindness (hitherto deemed incurable) caused by several diseases of that structure. *Dublin J Med Sci* 1837;11:408–17
40. Kissam R. Ceratoplastics in man. *NY J Med* 1844;2:281–2
41. Power H. On transplantation of the cornea. IV International Congress of Ophthalmology 1873;IV:172–6
42. Zirm EK. Eine erfolgreiche totale keratoplastik. *Arch Ophthalmol* 1906;64:580–93
43. Williams KA, Muehlberg SM, Lewis RF, Coster DJ. How successful is corneal transplantation? A report from the Australian Corneal Graft Register. *Eye* 1995;9:219-27
44. Frost NA, Wu J, Lai TF, et al. A review of randomized controlled trials of penetrating keratoplasty techniques. *Ophthalmology* 2006;113:942-9
45. Tillett CW. Posterior lamellar keratoplasty. *Am J Ophthalmol* 1956;41:530-3
46. Barraquer JI. Lamellar keratoplasty. (Special techniques). *Ann Ophthalmol* 1972;4:437-69

47. Melles GR, Eggink FA, Lander F, et al. A surgical technique for posterior lamellar keratoplasty. *Cornea* 1998;17:618-26
48. Melles GR, Lander F, van Dooren BT, et al. Preliminary clinical results of posterior lamellar keratoplasty through a sclerocorneal pocket incision. *Ophthalmology* 2000;107:1850-6; discussion 1857
49. Melles GR, Lander F, Rietveld FJ. Transplantation of Descemet's membrane carrying viable endothelium through a small scleral incision. *Cornea* 2002;21:415-8
50. Melles GR, Wijdh RH, Nieuwendaal CP. A technique to excise the descemet membrane from a recipient cornea (descemetorhexis). *Cornea* 2004;23:286-8
51. Melles GRJ, Kamminga N. Techniques for posterior lamellar keratoplasty through a scleral incision. *Ophthalmologe* 2003;100:689–95
52. Price FW Jr, Price MO. Descemet's stripping with endothelial keratoplasty in 50 eyes: a refractive neutral corneal transplant. *J Refract Surg* 2005;21:339–45
53. Gorovoy MS. Descemet-stripping automated endothelial keratoplasty. *Cornea* 2006;25:886-9
54. Anshu A, Price MO, Tan DT, et al. Endothelial keratoplasty: a revolution in evolution. *Surv Ophthalmol* 2012;57:236-52
55. Price MO, Price FW Jr. Endothelial keratoplasty - a review. *Clin Exp Ophthalmol* 2010;38:128-40
56. Melles GR. Posterior lamellar keratoplasty: DLEK to DSEK to DMEK. *Cornea* 2006;25:879-81.
57. Dapena I, Ham L, Melles GR. Endothelial keratoplasty: DSEK/DSAEK or DMEK--the thinner the better? *Curr Opin Ophthalmol* 2009;20:299-307
58. Li JY, Terry MA, Goshe J, et al. Three-year visual acuity outcomes after Descemet's stripping automated endothelial keratoplasty. *Ophthalmology* 2012;119:1126-9
59. Dirisamer M, Parker J, Naveiras M, et al. Identifying causes for poor visual outcome after DSEK/DSAEK following secondary DMEK in the same eye. *Acta Ophthalmol* 2013;91:131-9
60. Letko E, Price DA, Lindoso EM, et al. Secondary graft failure and repeat endothelial keratoplasty after Descemet's stripping automated endothelial keratoplasty. *Ophthalmology* 2011;118:310-4
61. Melles GRJ, Ong TS, Ververs B, van der Wees J. Descemet membrane endothelial keratoplasty (DMEK). *Cornea* 2006;25:987–90
62. Dapena I, Moutsouris K, Droutsas K, et al. Standardized "no-touch" technique for descemet membrane endothelial keratoplasty. *Arch Ophthalmol* 2011;129:88-94
63. Guerra FP, Anshu A, Price MO, et al. Descemet's membrane endothelial keratoplasty: prospective study of 1-year visual outcomes, graft survival, and endothelial cell loss. *Ophthalmology* 2011;118:2368–73
64. Parker J, Dirisamer M, Naveiras M, et al. Outcomes of Descemet membrane endothelial keratoplasty in phakic eyes. *J Cataract Refract Surg* 2012;38:871–7
65. Ham L, Balachandran C, Verschoor CA, et al. Visual rehabilitation rate after isolated Descemet membrane transplantation: Descemet membrane endothelial keratoplasty. *Arch Ophthalmol* 2009;127:252–5
66. Tourtas T, Laaser K, Bachmann BO, et al. Descemet membrane endothelial keratoplasty versus Descemet stripping automated endothelial keratoplasty. *Am J Ophthalmol* 2012;153:1082–90

67. Anshu A, Price MO, Price FW, Jr. Risk of corneal transplant rejection significantly reduced with Descemet's membrane endothelial keratoplasty. *Ophthalmology* 2012;119:536–40
68. Price MO, Jordan CS, Moore G, et al. Graft rejection episodes after Descemet stripping with endothelial keratoplasty: part two: the statistical analysis of probability and risk factors. *Br J Ophthalmol* 2009;93:391–5
69. Dapena I, Ham L, Netuková M, et al. Incidence of early allograft rejection after Descemet membrane endothelial keratoplasty. *Cornea* 2011;30:1341–5
70. Price FW, Jr, Price MO. Evolution of endothelial keratoplasty. *Cornea* 2013;32:S28–32
71. Deng SX, Lee WB, Hammersmith KM, et al. Descemet membrane endothelial keratoplasty: safety and outcomes: A report by the American Academy of Ophthalmology. *Ophthalmology* 2018;125:295-310
72. Eye Bank Association of America. *2019 Eye Banking Statistical Report* Washington, DC: Eye Bank Association of America; 2020
73. Park CY, Lee JK, Gore PK, et al. Keratoplasty in the United States: a 10-year review from 2005 through 2014. *Ophthalmology* 2015;122:2432–42
74. Wiaux C, Baghdasaryan E, Lee OL, et al. Outcomes after Descemet stripping endothelial keratoplasty in glaucoma patients with previous trabeculectomy and tube shunt implantation. *Cornea* 2011;30:1304–11
75. Anshu A, Price MO, Price FW. Descemet's stripping endothelial keratoplasty: long-term graft survival and risk factors for failure in eyes with preexisting glaucoma. *Ophthalmology* 2012;119:1982–7
76. Aldave AJ, Chen JL, Zaman AS, et al. Outcomes after DSEK in 101 eyes with previous trabeculectomy and tube shunt implantation. *Cornea* 2014;33:223–9
77. Baydoun L, Melles GR. Refining the terminology of graft failure in reports on endothelial keratoplasty outcomes. *JAMA Ophthalmol* 2016;134:125-6
78. Price MO, Thompson RW Jr, Price FW Jr. Risk factors for various causes of failure in initial corneal grafts. *Arch Ophthalmol* 2003;121:1087-92
79. Busin M, Patel AK, Scorcia V, et al. Microkeratome-assisted preparation of ultrathin grafts for descemet stripping automated endothelial keratoplasty. *Invest Ophthalmol Vis Sci* 2012;53:521-24
80. Agarwal A, Dua HS, Narang P, et al. Pre-Descemet's endothelial keratoplasty (PDEK). *Br J Ophthalmol* 2014;98:1181–5
81. Studeny P, Farkas A, Vokrojova M, et al. Descemet membrane endothelial keratoplasty with a stromal rim (DMEK-S). *Br J Ophthalmol* 2010;94:909–14
82. Balachandran C, Ham L, Verschoor CA, et al. Spontaneous corneal clearance despite graft detachment in Descemet membrane endothelial keratoplasty (DMEK). *Am J Ophthalmol* 2009;148:227–34
83. Price FW Jr, Price MO. Comment on "Spontaneous corneal clearance despite graft detachment after Descemet membrane endothelial keratoplasty." *Am J Ophthalmol* 2010;149:173–4; author reply 174–5
84. Zafirakis P, Kymionis GD, Grentzelos MA, et al. Corneal graft detachment without corneal edema after Descemet stripping automated endothelial keratoplasty. *Cornea* 2010;29:456–8
85. Dirisamer M, Ham L, Dapena I, et al. Descemet membrane endothelial transfer: "Free-floating" donor Descemet implantation as a potential alternative to "keratoplasty." *Cornea* 2012;31:194–7

86. Moloney G, Petsoglou C, Ball M, et al. Descemetorhexis without grafting for Fuchs endothelial dystrophy—supplementation with topical ripasudil. *Cornea* 2017;36:642–8
87. Iovieno A, Neri A, Soldani AM, et al. Descemetorhexis without graft placement for the treatment of Fuchs endothelial dystrophy: pre-liminary results and review of the literature. *Cornea* 2017;36:637–41
88. Galvis V, Tello A, Berrospi RD, et al. Descemetorhexis without endothelial graft in Fuchs dystrophy. *Cornea* 2016;35:e26–8
89. Borkar DS, Veldman P, Colby KA. Treatment of Fuchs endothelial dystrophy by Descemet stripping without endothelial keratoplasty. *Cornea* 2016;35:1267–73
90. Moloney G, Chan UT, Hamilton A, et al. Descemetorhexis for Fuchs' dystrophy. *Can J Ophthalmol* 2015;50:68–72
91. Koenig SB. Planned descemetorhexis without endothelial keratoplasty in eyes with Fuchs corneal endothelial dystrophy. *Cornea* 2015;34:1149–51
92. Satué Palacián M, Sánchez Pérez A, Idoipe Corta M, et al. Descemetorhexis and corneal clearing: a new perspective on the treatment of endothelial diseases. *Arch Soc Esp Oftalmol* 2014;89:1–3
93. Koenig SB. Long-term corneal clarity after spontaneous repair of an iatrogenic descemetorhexis in a patient with Fuchs dystrophy. *Cornea* 2013;32:886–8
94. Shah RD, Randleman JB, Grossniklaus HE. Spontaneous corneal clearing after Descemet's stripping without endothelial replacement. *Ophthalmology* 2012;119:256–60
95. Bleyen I, Saelens IE, van Dooren BT, et al. Spontaneous corneal clearing after Descemet's stripping. *Ophthalmology* 2013;120:215
96. Braunstein RE, Airiani S, Chang MA, et al. Corneal edema resolution after "descemetorhexis." *J Cataract Refract Surg* 2003;29:1436–9
97. Ziaei M, Barsam A, Mearza AA. Spontaneous corneal clearance despite graft removal in Descemet stripping endothelial keratoplasty in Fuchs endothelial dystrophy. *Cornea* 2013;32:e164–6
98. Dirisamer M, Yeh RY, van Dijk K, et al. Recipient endothelium may relate to corneal clearance in Descemet membrane endothelial transfer. *Am J Ophthalmol* 2012;154:290–6
99. Rao R, Borkar DS, Colby KA, et al. Descemet membrane endothelial keratoplasty after failed Descemet stripping without endothelial keratoplasty. *Cornea* 2017;36:763–6
100. Parker J, Verdijk RM, Müller TM, et al. Histopathology of failed Descemet membrane endothelial transfer. *Eye Contact Lens* 2018;44 Suppl 1:S361-4
101. Lam FC, Baydoun L, Dirisamer M, et al. Hemi-Descemet membrane endothelial keratoplasty transplantation: a potential method for increasing the pool of endothelial graft tissue. *JAMA Ophthalmol* 2014;132:1469–73
102. Lie JT, Lam FC, Groeneveld-van Beek EA, et al. Graft preparation for Hemi-Descemet membrane endothelial keratoplasty (Hemi-DMEK). *Br J Ophthalmol* 2016;100:420–4
103. Lam FC, Baydoun L, Satué M, et al. One year outcome of Hemi-Descemet membrane endothelial keratoplasty. *Graefes Arch Clin Exp Ophthalmol* 2015;253:1955–8
104. Gerber-Hollbach N, Parker J, Baydoun L, et al. Preliminary outcome of Hemi-Descemet membrane endothelial keratoplasty for Fuchs endothelial dystrophy. *Br J Ophthalmol* 2016;100:1564–8
105. Müller TM, Baydoun L, Melles GR. 3-Year update on the first case series of Hemi-Descemet membrane endothelial keratoplasty. *Graefes Arch Clin Exp Ophthalmol* 2017;255:213–5

106. Müller TM, Lavy I, Baydoun L, et al. Case report of Quarter-Descemet membrane endothelial keratoplasty for fuchs endothelial dystrophy. *Cornea* 2017;36:104–7
107. Zygoura V, Baydoun L, Ham L, et al. Quarter-Descemet membrane endothelial keratoplasty (Quarter-DMEK) for Fuchs endothelial corneal dystrophy: 6 months clinical outcome. *Br J Ophthalmol* 2018;102:1425–30
108. Stocker FW. The endothelium of the cornea and its clinical implications. *Trans Am Ophthalmol Soc* 1953;51:669-786
109. Pels E, Rijneveld WJ. Organ culture preservation for corneal tissue. Technical and quality aspects. *Dev Ophthalmol* 2009;43:31-46
110. Price MO, Giebel AW, Fairchild KM, et al. Descemet's membrane endothelial keratoplasty: prospective multicenter study of visual and refractive outcomes and endothelial survival. *Ophthalmology* 2009;116:2361–8
111. Kruse FE, Laaser K, Cursiefen C, et al. A stepwise approach to donor preparation and insertion increases safety and outcome of Descemet membrane endothelial keratoplasty. *Cornea* 2011;30:580–7
112. Price MO, Baig KM, Brubaker JW, et al. Randomized, prospective comparison of precut vs surgeon-dissected grafts for Descemet stripping automated endothelial keratoplasty. *Am J Ophthalmol* 2008;146:36-41
113. Bennett TJ, Barry CJ. Ophthalmic imaging today: an ophthalmic photographer's viewpoint - a review. *Clin Exp Ophthalmol* 2009;37:2-13
114. Moutsouris K, Dapena I, Ham L, et al. Optical coherence tomography, Scheimpflug imaging, and slit-lamp biomicroscopy in the early detection of graft detachment after Descemet membrane endothelial keratoplasty. *Cornea* 2011;30:1369-75
115. Yeh RY, Quilendrino R, Musa FU, et al. Predictive value of optical coherence tomography in graft attachment after Descemet's membrane endothelial keratoplasty. *Ophthalmology* 2013;120:240-5
116. Konstantopoulos A, Hossain P, Anderson DF. Recent advances in ophthalmic anterior segment imaging: a new era for ophthalmic diagnosis? *Br J Ophthalmol* 2007;91:551-7
117. Dirisamer M, van Dijk K, Dapena I, et al. Prevention and management of graft detachment in Descemet membrane endothelial keratoplasty. *Arch Ophthalmol* 2012;130:280-91
118. Rudolph M, Laaser K, Bachmann BO, et al. Corneal higher-order aberrations after Descemet's membrane endothelial keratoplasty. *Ophthalmology* 2012;119:528-35
119. van Dijk K, Droutsas K, Hou J, et al. Optical quality of the cornea after Descemet membrane endothelial keratoplasty. *Am J Ophthalmol* 2014;158:71-9 e1
120. Dapena I, Yeh RY, Baydoun L, et al. Potential causes of incomplete visual rehabilitation at 6 months postoperative after Descemet membrane endothelial keratoplasty. *Am J Ophthalmol* 2013;156:780-8
121. Ham L, Dapena I, Moutsouris K, et al. Refractive change and stability after Descemet membrane endothelial keratoplasty. Effect of corneal dehydration-induced hyperopic shift on intraocular lens power calculation. *J Cataract Refract Surg* 2011;37:1455-64
122. Kwon RO, Price MO, Price FW Jr, et al. Pentacam characterization of corneas with Fuchs dystrophy treated with Descemet membrane endothelial keratoplasty. *J Refract Surg* 2010;26:972-9
123. Ramos JL, Li Y, Huang D. Clinical and research applications of anterior segment optical coherence tomography - a review. *Clin Exp Ophthalmol* 2009;37:81-9

124. Salomão MQ, Esposito A, Dupps WJ Jr. Advances in anterior segment imaging and analysis. *Curr Opin Ophthalmol* 2009;20:324-32
125. Wojtkowski M, Leitgeb R, Kowalczyk A, et al. In vivo human retinal imaging by Fourier domain optical coherence tomography. *J Biomed Opt* 2002;7:457– 63
126. Knecht PB, Kaufmann C, Menke MN, et al. Use of intraoperative fourier-domain anterior segment optical coherence tomography during Descemet stripping endothelial keratoplasty. *Am J Ophthalmol* 2010;150:360-5 e2
127. Saad A, Guilbert E, Grise-Dulac A, et al. Intraoperative OCT-Assisted DMEK: 14 Consecutive Cases. *Cornea* 2015;34:802-7
128. McCarey BE, Edelhauser HF, Lynn MJ. Review of corneal endothelial specular microscopy for FDA clinical trials of refractive procedures, surgical devices, and new intraocular drugs and solutions. *Cornea* 2008;27:1-16
129. Cavanagh HD, El-Agha MS, Petroll WM, et al. Specular microscopy, confocal microscopy, and ultrasound biomicroscopy: diagnostic tools of the past quarter century. *Cornea* 2000;19:712-22
130. Raecker ME, McLaren JW, Kittleson KM, et al. Endothelial image quality after Descemet stripping with endothelial keratoplasty: a comparison of three microscopy techniques. *Eye Contact Lens* 2011;37:6-10
131. Ham L, van Luijk C, Dapena I, et al. Endothelial cell density after Descemet membrane endothelial keratoplasty: 1- to 2-year follow-up. *Am J Ophthalmol* 2009;148:521-7
132. Price FW Jr, Price MO. Does endothelial cell survival differ between DSEK and standard PK? *Ophthalmology* 2009;116:367-8
133. Maurice DM. A scanning slit optical microscope. *Invest Ophthalmol* 1974;13:1033–7
134. Thuret G, Deb-Joardar N, Zhao M, et al. Agreement between two non-contact specular microscopes: Topcon SP2000P versus Rhine-Tec. *Br J Ophthalmol* 2007;91:979-80

Part I

Donor Tissue Preparation

Birbal RS[1-3], Sikder S[4], Lie JT[1,3], Groeneveld-van Beek EA[1,3], Oellerich S[1] and Melles GRJ[1-3]

[1] Netherlands Institute for Innovative Ocular Surgery, Rotterdam, The Netherlands

[2] Melles Cornea Clinic, Rotterdam, The Netherlands

[3] Amnitrans EyeBank, Rotterdam, The Netherlands

[4] Wilmer Eye Institute, Johns Hopkins University School of Medicine, Baltimore, Maryland, United States of America

Chapter 2

Donor Tissue Preparation for Descemet Membrane Endothelial Keratoplasty: An Updated Review

Cornea 2018;37:128-35

ABSTRACT

Purpose: To provide an overview of the current literature on donor tissue preparation for Descemet membrane endothelial keratoplasty (DMEK).

Methods: A comprehensive database search without date restrictions was performed in Pubmed and in The Cochrane Library in May, 2017. Keywords included *Descemet membrane endothelial keratoplasty, corneal transplantation, graft, harvest, dissection, preparation, endothelial cell and endothelial cell density.* Articles aiming to describe or evaluate a technique for DMEK graft preparation were considered eligible and were included in this review.

Results: A graft dissection technique that provides consistent tissue qualities and a low risk of preparation failure is essential for surgeons and eye banks preparing DMEK tissue. Various techniques have been described aiming to facilitate DMEK graft dissection, including manual dissection, pneumatic dissection, and hydrodissection. All show a trend toward a no-touch technique, e.g. without direct physical tissue manipulation during tissue harvesting, as a potential ideal approach to minimize graft damage.

Conclusion: An overview of the current harvesting techniques available for DMEK may benefit corneal surgeons as well as eye banks in choosing the best approach for each specific user.

INTRODUCTION

In the past decade, endothelial keratoplasty (EK) has rapidly replaced penetrating keratoplasty (PK) for the management of corneal endothelial disorders.[1] Descemet membrane endothelial keratoplasty (DMEK), the latest refinement of EK, allowed for further evolution of the field by enabling selective replacement of bare Descemet membrane (DM) with its endothelial layer.[2] Providing near-perfect restoration of the corneal anatomy, DMEK yielded faster visual rehabilitation,[3-6] improved visual outcome,[3-5] and lower graft rejection rates compared with earlier types of EK.[7-10]

Although DMEK is gaining widespread acceptance and numbers are showing a continued increase of DMEK procedures to 1522 in 2013, 2865 in 2014 and 4694 in 2015 in the United States alone,[11] the procedure is more challenging in preparing and handling the delicate donor graft.[12] Uptake of the procedure may be facilitated by proper training and choosing the most feasible harvesting technique that yields reproducible graft qualities. Since several techniques have been described for DMEK graft preparation, this review aims to provide an overview of the current literature regarding donor tissue dissecting techniques for DMEK and to provide corneal surgeons and eye banks with a useful reference for technique comparison and selection in a given setting.

MATERIALS AND METHODS

A comprehensive database search without date restrictions was performed in PubMed and The Cochrane Library in May 2017. Keywords included *Descemet membrane endothelial keratoplasty, corneal transplantation, graft, harvest, dissection*, *preparation, endothelial cell and endothelial cell density.* Search results were limited to studies published in English, studies on human corneas and full text available. Title and/or abstract of all records were screened for relevance. Articles aiming to describe or evaluate a technique for DMEK graft preparation were considered eligible and were included in this review, which resulted in inclusion of 50 articles on this topic.

RESULTS

Surgical technique

Current and evolving techniques to procure donor tissue for DMEK show a trend toward a no-touch technique, in which there is no direct physical graft handling, as a potential ideal approach to minimize endothelial cell loss.[12] Harvesting techniques may broadly be classified into those based on manual peeling and those aiming to achieve detachment of DM by either injecting air or liquid between DM and the posterior stroma (i.e., the pre-DM plane).

Manual dissection

Manual dissection entails carefully peeling away DM with its endothelial layer from the underlying stroma. Melles et al.[13] pioneered this technique describing superficial trephination of the posterior stroma and stripping of DM with the corneoscleral rim submerged in a balanced salt solution (BSS). Zhu et al.[14] described applying 4 incisions through DM to facilitate stripping. In 2008, Lie et al.[15] introduced the basis for the current technique. After mounting the donor corneoscleral rim on a custom-made fixation device with the endothelial side up, DM was cut anterior to the trabecular meshwork and pushed centrally. Grasping the outer edge of the graft, DM was loosened over 180 degrees and stripped for two-thirds. By submerging the rim in BSS, superficial trephination and complete stripping of DM were facilitated, after which the isolated graft spontaneously formed a roll with the endothelial layer facing outward. Groeneveld-van Beek et al.[16] modified the technique into the standardized 'no-touch' technique, in which DM with the adjacent trabecular meshwork is loosened over 360 degrees rather than over 180 degrees and trephined on a soft contact lens instead of on the anterior cornea.

Giebel and Price reported on the submerged cornea using backgrounds away (SCUBA) technique, which involved manually harvesting DM with the rim submerged in Optisol or BSS.[17,18] Tenkman et al.[19] used a blunt Y-hook rather than tying forceps to score the DM. After circumferentially lifting the scored edge of DM with a microfinger and grasping it with Tubingen forceps, DM was partially peeled in 4 quadrants with the central area still attached (i.e. the Corridor method). Repositioning of the graft on the underlying stroma preceded superficial trephination and complete peeling of the tissue.

Kruse et al.[20] used a razor blade to eliminate tissue outside an 8-mm marked zone to prevent tearing on the inside of the demarcated line and two forceps

instead of one for stripping, aiming to minimize formation of folds and surface tension affecting the endothelial cells. In 2013, Yoeruek et al.[21] described the use of two untoothed curvilinear forceps instead of one traditional forceps to facilitate stripping. Sikder et al.[22] reported on removing most of the donor stroma overlying DM with a microkeratome and removing the residual stroma with a Barraquer sweep-assisted lamellar dissection.

Tausif et al.[23] described a technique in which partial trephination of DM was followed by trypan blue-staining of the scored edge and a partial circumferential dissection of DM. Previously marked microtears were positioned at 6 o'clock representing the hinge of the flap. Using tying forceps and starting at 12 o'clock, DM was dissected by peeling toward the hinge. Peeling was stopped at 2 mm from the score mark, after which the center of the hinge was marked with a skin marker.

Pneumatic dissection

Pneumatic dissection entails injecting air into the deep stroma to obtain detachment of DM at the level of DM or pre-DM (Dua's layer), a concept which was first described by Anwar and Teichmann for anterior lamellar keratoplasty.[24] Modifications in the technique have allowed its use for DMEK. In 2005, Ignacio et al.[25] described mounting a corneoscleral rim on an artificial anterior chamber to apply negative pressure using air before trephining DM inside the Schwalbe line. Subsequently, positive pressure was applied to separate the peripheral part of DM from the central part. The graft was undermined from the underlying stroma using a blunt spatula. Venzano et al.[26] reported on trypan blue-staining of the endothelium to visualize needle positioning before introducing a big bubble. Zarei-Ghanavati et al.[27] described injecting air into a cornea with the endothelial side up rather than with the epithelial side up, followed by aspiration of the previously injected air to facilitate collapse of the big bubble; this technique was referred to as 'the Reverse big-bubble technique'.[28]

In 2010, Busin et al.[29] described microkeratome-assisted removal of two-thirds of the anterior stroma prior to air-injection. The air bubble was left inflated until the time of surgery. Another extension of pneumatic dissection 'DMEK with a stromal rim' (DMEK-S) was described by Studeny et al.[30] After introducing an air bubble into the pre-DM plane and removing 80% of the stroma, a circle of 6 mm in diameter was demarcated and the letter S was written on the stromal

rim. The bubble was then entered with scissors, and the remaining central part of the stroma was eliminated, resulting in a graft with a stromal rim.

In 2014, Agarwal et al.[31] reported on a pneumatic dissection technique for 'Pre-Descemet endothelial keratoplasty' (PDEK), a form of DMEK in which pre-DM layer, Descemet membrane and endothelium are transplanted. Air was introduced into a cornea with the endothelial side up to establish an air bubble between pre-DM and stroma or pre-DM and DM. Immediately after a big bubble was achieved, the bubble was marked with a trephine and trypan blue was injected to improve visualization of the graft. Corneal scissors were used to ensure complete detachment of the graft along the circumference of the trephination.

Hydrodissection

Hydrodissection entails applying a pressurized fine stream of liquid, either culture medium or BSS, into the pre-DM plane to obtain dissection of DM. For the procedure to be successful, a proper injection site and correct intensity of the applied pressure are essential.

In 2013, Muraine et al.[32] described a technique in which superficial trephination of DM was performed over 330 degrees rather than over 360 degrees. Using a spatula or Troutman forceps, the peripheral endothelium was detached on either side of the uncut 30 degrees to create a liftable flap and enter the pre-DM plane with a needle; culture medium or BSS was injected to obtain detachment of DM.

Salvalaio et al.[33] reported on the 'standardized submerged hydroseparation technique' (SubHys-technique), which involved introducing a bevel-up needle into a cornea submerged in organ culture until the bevel was completely inserted. Approximately 0.3 mL organ culture was injected to separate DM from the stroma. Additional culture medium was injected with increased pressure aiming to establish a bubble >10 mm in diameter. Thereupon, the cornea was mounted onto an artificial anterior chamber with the epithelial side up to trephine and excise the anterior cornea. The residual peripheral stroma was removed using microscissors. In 2016, Szurman et al.[34] described a 'no-touch' liquid bubble technique. After creating a sharp incision under the iris base, the Schlemm canal was entered to loosen the zone of high adherence by tangential dissection with a blunt spatula. Detachment of DM was obtained by injecting a vital dye into the pre-DM plane and simultaneous blocking of

reflux with a surgical pad. After corneal trephination, the donor tissue could be lifted from the stromal side using a spatula with a smooth, rounded olive tip extremity (i.e. olive spatula) to facilitate donor harvesting.

Anatomical analysis

The accuracy of mechanical lamellar dissection may be analysed using hematoxylin and eosin (H&E)-staining or periodic acid-Schiff (PAS)-staining with subsequent light microscopy analysis at respectively, x200 and x400 magnification or transmission electron microscopy and immunohistochemistry.[35,36]

McKee et al.[35] showed the superiority of PAS-staining over H&E-staining in revealing a sharp distinction between DM and stroma. Using the former method, McKee et al. and Ruzza et al. described residual stroma in all grafts harvested with pneumatic dissection, whereas very low to no residual stroma was reported for grafts prepared with hydrodissection.[35,37] These results may suggest that pneumatic dissection yields a very thin Descemet stripping endothelial keratoplasty (DSEK) graft rather than a DMEK graft.

In 2013, Schlötzer-Schrehardt et al.[36] analyzed 343 grafts and 7 whole corneoscleral rims after respectively, successful and unsuccessful manual peeling of DM (bimanual submerged technique). Transmission electron microscopy and immunohistochemistry revealed that failure to separate DM from the underlying stroma (2%) was due to the presence of ultrastructural peg-like linkages and increased adhesive glycoproteins along the Descemet membrane and stromal interface resulting in extremely strong adhesion of DM to the stroma. No stromal residues were observed after successful tissue preparation. In another study, Sikder et al.[22] used anterior segment optical coherence tomography for imaging of the donor graft, thereby revealing residual stroma underlying the graft.

Graft quality

Descemet grafts may be prepared by the surgeon in the operation room before surgery or one day in advance[17,20] or may be pre-dissected in an eye bank for up to 1 to 2 weeks before surgery.[15,16]

In contrast to surgeon-cut tissue, pre-dissected tissue allows for postprocessing evaluation of the donor graft, providing corneal surgeons with accurate information about the graft before surgery. In vitro assessment of endothelial quality is performed before and after graft preparation, using either light

Table 1. Overview donor tissue harvesting techniques with in vitro outcomes for Descemet membrane endothelial keratoplasty (DMEK).

	Study	Year	Harvesting technique	Number of grafts	Preparation time (min)	Mean graft size (mm)	Average ECD (cells/mm^2)		EC loss due to tissue preparation (%)	Tissue loss due to failed preparation (%)
							Before EDM stripping	After EDM stripping		
Manual dissection	Melles et al.[13]	2002	-	5	N/A	9.0	N/A	N/A	3 (±1)	N/A
	Zhu et al.[14]	2006	-	48	3-5	6-7	N/A	N/A	<3	17
	Lie et al.[15]	2008	Standardized traditional technique	10	N/A	9.5	2701 (±302)	2719 (±322)	4-7	0
	Yoeruek et al.[21] Standard forceps	2013	-	8	11.0#	8.5	N/A	N/A	7 (±3)^	0
	Curvilinear forceps			8	6.4#	8.5	N/A	N/A	3 (±2)^	0
	Giebel and Price et al.[17, 18]	2009	SCUBA technique	72	N/A	8.5-9.0	N/A	N/A	N/A	8
	Kruse et al.[20]	2011	Bimanual submerged technique	80	From 90 to <30	8.0	N/A	2600 (±252)	N/A	1
	Schlötzer-Schrehardt et al.[36]	2013		350	N/A	N/A	N/A	2553(±229)	N/A	2
	Sikder et al.[22]	2011	Microkeratome and Barraquer sweep assisted dissection	N/A	N/A	≥8.5	N/A	N/A	N/A	N/A
	Groeneveld-van Beek et al.[16]	2013	Standardized ('no-touch') technique	62	N/A	9.5	2539 (±120)	2519 (±125)	<5	0
	Livny et al.[39]	-		1075	N/A	N/A	N/A	N/A	N/A	3
	Tenkman et al.[19]	2014	-	263	N/A	8.0 (FED) 9.0 (PPBK or failed EK) <8.5 (Host corneal dm <11.5)	N/A	N/A	N/A	1
	Tausif et al.[23]	2014	-	50	N/A	N/A	2616 (±321)	2676 (±284)	N/A	24

Table 1. Overview donor tissue harvesting techniques with in vitro outcomes for Descemet membrane endothelial keratoplasty (DMEK). (*continued*)

	Study	Year	Harvesting technique	Number of grafts	Preparation time (min)	Mean graft size (mm)	Average ECD (cells/mm²)		EC loss due to tissue preparation (%)	Tissue loss due to failed preparation (%)
							Before EDM stripping	After EDM stripping		
Pneumatic dissection	Ignacio et al.[25]	2005	-	7	N/A	9.0	N/A	2095 (±704)	8 (±7)	0
	Venzano et al.[26]	2010	Anwar big-bubble technique	16	N/A	Group A N/A. Group B N/A. Group C 7.3	N/A	N/A	Group A: 83 (±10) Group B: 15 (±11) Group C: 3 (±3)	11
	Zarei-Ghanavati et al.[28]	2010	Reverse big-bubble technique	1	N/A	8.5	N/A	N/A	N/A	N/A
	Busin et al.[29]	2010	-	20	N/A	8.1	N/A	N/A	4 (±4) after 7 days	5
	Studeny et al.[30]	2010		20	20-30	8.0	N/A	2888 (±265)	N/A	N/A
	Krabcova et al.[40]*	2011	DMEK-S	12	N/A	N/A	2875 (±222)	2725 (±156)	5	N/A
	Krabcova et al.[41]**	2012		10	N/A	N/A	2249 (±147)	2131 (±157)	5	N/A
Hydrodissection	Agarwal et al.[31]	2014	PDEK	5	N/A	7.6	N/A	N/A	N/A	0
	Altaan et al.[42]	2015		10	N/A	8-8.5	996 (±284)	943(±273)	5 (±4)	0
	Muraine et al.[32]	2013	Liquid bubble technique	12	N/A	N/A	2765 (±256)	2651 (±305) after 3 days	4	4
	Salvalaio et al.[33]	2014	SubHys-technique	30	N/A	11.0	1920 (±223)	N/A	27 after 7 days	0
	Parekh et al.[43]	2014		54	N/A	10.8	2024 (±229)	2018 (±221)	11	0
	Szurman et al.[34]	2016	No-touch liquid bubble technique	86	<3	8.3	N/A	N/A	N/A	1

min= minutes; mm= millimeters; ECD= endothelial cell density; mm²= square millimeter; EDM= Descemet membrane with endothelial monolayer; EC= endothelial cell; SCUBA= Submerged cornea using backgrounds away; FED= Fuchs endothelial dystrophy; PPBK= Pseudophakic bullous keratopathy; EK= endothelial keratoplasty; dm= diameter; DMEK-S= Descemet membrane endothelial keratoplasty with a stromal rim; PDEK= Pre-Descemet's endothelial keratoplasty; SubHys= Standardized submerged hydro-separation; N/A= not available.

Data are expressed as mean (SD), absolute numbers, or percentages (SD).

Group A = Tissue stored with an inflated air-bubble

Group B = Air-bubble deflated immediately after detachment of the Descemet membrane was obtained

Group C = Descemet membrane with endothelial monolayer was trephined from the endothelial side after deflating the air-bubble

P-value = 0.01

^ *P*-value= 0.04

* First row: endothelial cell density >2500 cells/mm²; second row: endothelial cell density 2200-2500.

** Endothelial quality assessments were available for a total of 57 grafts.

microscopy for organ-cultured tissues or specular microscopy for cold stored tissues.[38] Endothelial cell morphology and viability are mainly evaluated using provoked swelling with 1.8% sucrose and staining with trypan blue 0.04% to visualize the cell borders and accentuate cells with damaged cell membranes and denuded areas of DM.[15,16] The endothelial cell density and viability of the corneoscleral rim are assessed using either an inverted light microscope or specular microscopy, and digital photographs are acquired. Endothelial cell density is calculated by manual counting using the fixed frame method or using a special image analysis program. After preparation of the DM graft, the roll is evaluated using the same method.

In vitro preparation outcomes

Evaluating the outcomes of the different tissue dissection methods (Table 1), manual peeling is observed to result in the least endothelial cell loss and tissue wastage compared with other dissection methods. Although it seems as if hydrodissection yields the largest mean graft size, the opposite is true. Although the maximum graft size is dependant on the size of the achieved air- of liquid bubble in, respectively, pneumatic dissection or hydrodissection, manual dissection allows the user to obtain the whole DM surface diameter.

Clinical endothelial outcomes

Independent of the applied dissection technique, clinical studies on the endothelial outcome after DMEK reveal a sharp decline of the endothelial cell density within the first 6 months postoperatively, followed by a stable decrease thereafter (Table 2).

DISCUSSION

In this study, we intended to provide an overview of the current and evolving graft dissecting techniques to provide corneal surgeons and eye banks with a useful reference for technique comparison and selection in a given setting. This information may assist them to adopt DMEK as a preferred surgical technique in the management of corneal endothelial disorders. In particular, minimization of endothelial cell loss seems critical to attain reproducibility of graft quality.

Using the standardized 'no-touch' technique,[16] preservation of the trabecular meshwork allows for complete stripping of DM and facilitates further handling

Table 2. Clinical endothelial outcome of DMEK harvesting techniques.

	Study	Year	Harvesting technique	Main indications for surgery	Number of grafts	Tissue loss due to failed preparation (%)	Preoperative ECD (cells/mm^2)	Number of grafts	ECD at 6m FU (cells/mm^2)	Mean ECD decrease at 6m FU (%)
Manual dissection	Ham et al.[44]	2009	Standardized traditional technique and/or Standardized ('no-touch') technique	FED	50	N/A	2618 (±201)	35	1876 (±522)	30
	Ham et al.[45]	2009		FED/ BK	26	N/A	2620 (±210)	26	1850 (±540)	29
	Ham et al.[46]	2010		FED/ BK	71	N/A	2630 (±200)	58	1870 (±520)	29
	Parker et al.[47]	2011		FED/ BK	225	N/A	2570	186	1710	34
	Dirisamer et al.[48]	2011		FED/ BK	200	N/A	2560 (±186)	173	1690 (±520)	34
	Baydoun et al.[49]	2012		FED/ BK	300	N/A	N/A	254	N/A	35
	Baydoun et al.[50]	2015		FED/ BK	352	N/A	2533 (±216)	327	1626 (±507)	35
	Peraza Nieves et al.[51]	2017		FED/ BK	500	N/A	2530 (±210)	447	1600 (±490)	37
	Price et al.[17]	2009	SCUBA technique	FED/ BK	72	17	N/A	38	N/A	32
	Guerra et al.[3]	2011		FED/ BK	136	First 40 cases 13%; Subsequent 96 cases:0%	2980 (±252)	124	N/A	31 (3m)
	Feng et al.[52]	2014		FED/ BK	673	N/A	2924	N/A	2147	27
	Deng et al.[53]	2015		FED/ BK	40	N/A	2878 (±212)	27	N/A	23
	Gorovoy et al.[54]	2015		N/A	125	N/A	2740 (±210)	125	2210 (±550) (1y)	19 (1y)
	Kruse et al.[20]	2011	Bimanual submerged technique	FED/ BK	80	1	2600 (±252)	74	1526 (±341) (1m)	N/A
	Laaser et al.[55]*	2011		FED/ BK	37	N/A	2647 (±236)	22	1587 (±373)	N/A
					45	N/A	2515 (±249)	25	1457 (±285)	N/A
	Tourtas et al.[6]	2012		FED/ BK	38	N/A	2575 (±260)	38	1520 (±299)	41
	Schlögl et al.[56]	2016	DMEK-S	FED/ BK	97	N/A	2602 (±243)	97	N/A	42 (1m)
	Studeny et al.[30]	2010		FED	18	N/A	2888 (±265)	18	1608 (±503) (1y)	44 (1y)
	Studeny et al.[57]	2013		FED/ BK	71	6	2907 (±51)	71	1273 (±82) (1m)	44

Table 2. Clinical endothelial outcome of DMEK harvesting techniques. (*continued*)

	Study	Year	Harvesting technique	Main indications for surgery	Number of grafts	Tissue loss due to failed preparation (%)	Preoperative ECD (cells/mm^2)	Number of grafts	ECD at 6m FU (cells/mm^2)	Mean ECD decrease at 6m FU (%)
Pneumatic dissection	Agarwal et al.[31]	2014	PDEK	BK	5	0	N/A	5	1551 (±65) (1m)	N/A
Hydrodis-section	Muraine et al.[32]	2013	Liquid bubble technique	FED	50	4 (replaced with back-up grafts)	2656 (±28)	47	1658 (±43)	N/A

ECD= Endothelial cell density; mm^2= square millimeter; FED= Fuchs endothelial dystrophy; BK= bullous keratopathy; FU= Follow up; d=day; m= month; y= year; PDEK = Pre-Descemet endothelial keratoplasty; N/A= not available;

Data are expressed as mean (SD), absolute numbers, or as percentages (SD).

* First row: patients who had received a graft prepared from a corneoscleral button that had been stored in Optisol-GS at 4C; second row: patients that had received a graft from a corneoscleral button that had been stored in Dulbecco modified eagle medium containing streptomycin and penicillin as well as fetal calf serum or in CorneaMax medium containing streptomycin and penicillin as well as fetal calf serum at 34 C.

of the graft. As the whole DM surface is peeled employing this method, it allows the user to obtain the maximum possible graft size, whereas other techniques might be limited by the size of the achieved bubble in this particular aspect. In addition, by trephining the donor DM on a soft contact lens instead of on the anterior cornea, endothelial cell damage in the trephination area is minimized and the anterior cornea is left intact, rendering it eligible for anterior lamellar keratoplasties. Donor tissue preparation using this technique does not require special or expensive equipment and can be performed at minimal cost, which makes it readily accessible to most corneal surgeons in contrast to techniques that require the use of a microkeratome for partial dissection of the graft.[22,29]

The additional stromal ring in DMEK-S[30] facilitates further handling of the graft, allows for marking of the anteroposterior orientation of the lamellae and minimizes the risk of upside-down grafting, thus avoiding unnecessary technical DMEK failure. The use of a vital dye in the 'no-touch' liquid bubble technique[34] improves homogenous staining of the stromal side of DM and leads to better orientation of the lamellae intraoperatively, thereby saving valuable surgical time as staining has already been performed.

Comparative studies (in vitro) on the feasibility and success of the different dissection methods are scarce and report on small sample sizes.[37,58-60] Manual dissection was shown to result in less tissue wastage compared with pneumatic dissection[58] and hydrodissection[59] and to yield a significantly higher area percentage covered by viable cells compared with hydrodissection (P=0.04) (Table 3).[60] Comparing pneumatic dissection to hydrodissection, the latter method was observed to have higher yield, to require fewer injections to achieve detachment, to require a lower pressure to facilitate big-bubble formation, and to yield a larger maximum graft size.[37] As for the various storage methods, graft storage as a free-floating roll was demonstrated to be superior to partial peeling (90%) and liquid bubble techniques in retaining viable endothelial cells during graft storage.[61]

Studies reporting the clinical endothelial outcome after DMEK for grafts prepared by the different techniques are predominantly available for manually dissected grafts. However, independent of the applied graft preparation technique, an endothelial cell density decrease of 19 to 44% at the 6 month follow-up compared with preoperative values was observed (Table 2), which was then usually followed by a slower decrease. Several explanations have been offered for the endothelial cell density decline within the first post-

Table 3. Comparative studies on dissection methods for DMEK.

Study	Year of Publication	Number of Grafts	Manual Dissection	Pneumatic Dissection	Hydrodissection	P-value
Yoeruek et al.[58]	2012	32				
Graft preparation time			19.7 min	8.8 min	-	<0.00
Graft preparation failure			6.3%	12.5%	-	N/A
Mean ECD decrease			9.9%	8.6%	-	0.55
Apoptotic cells			0.4 (±0.3) %	0.4 (±0.3) %	-	0.91
Ruzza et al.[37]	2015	20				
Graft preparation failure			-	20%	0%	N/A
No. injections required			-	1.9 (±1.1)	1.4 (±0.7)	0.33
Mean quantity required			-	1.1 (±1.3) ml	0.8 (±0.5) ml	0.41
Mean diameter bubble			-	9.1 (±1.7) mm	9.8 (±1.8) mm	0.44
Maximum diameter graft			-	10 mm	11 mm	N/A
Determined percentage of endothelial cell death			-	8.9 (±12.4) %	6.3 (±9.6) %	0.63
Brissette et al.[59*]	2015	20				
Graft preparation time Surgeon Fellow			301 (±85) s 523 (±58) s	-	359 (±83) s 543 (±44) s	0.46 0.33 0.24
Graft tears			0		5	<0.05
Bhogal et al.[60]	2016	16				
Area covered by viable cells			87.7 (±1.4) %	-	75.5 (±5.6) %	0.04

ECD= Endothelial cell density; N/A= not available; ml= millilitre; mm= millimetre. min= minutes; s= seconds.
Data are expressed as mean (SD), as absolute numbers or as percentages (SD).
* Endothelial cell viability was not evaluated on a validated scale.

operative months, including the use of different devices to evaluate the graft in vitro in the eye bank and *in vivo* postoperatively. Several research groups demonstrated a systematic overestimation of the actual pool of viable endothelial cells supplied by eye banks by assessing pan-corneal endothelial cell viability.[38,62, 63] Early postoperative cell loss was attributed to failing to recognize areas deprived of endothelial cells and/ or non-viable cells, failing to take into account auxiliary cell loss between the initial cell count in the eye bank and the surgery, including very small endothelial cell samples (50-300) and failing to take account of the 3-dimensional aspect of the graft.[62,63] Limitations of this review are the small sample sizes of the available in vitro studies and that evaluation of endothelial cell density and viability was not uniformly assessed in most of the included studies (Table 1). This is also due to the fact that there is a paucity of methods to accurately evaluate and quantify endothelial cell viability without damaging the graft. Limited availability of adequate data highlights the importance of re-evaluating current practice. Further studies

of larger sample size and long-term follow up are warranted to ensure that potential donor grafts are fully utilized.

DMEK graft dissection techniques are diverse and feature different strengths and weaknesses. Although a single technique does not need to be universally adopted, it is imperative for those preparing DMEK tissue to know the different techniques available and use the best technique for each specific user.

REFERENCES

1. Park CY, Lee JK, Gore PK, et al. Keratoplasty in the United States: A 10-Year Review from 2005 through 2014. *Ophthalmology* 2015;122:2432-42
2. Melles GR, Ong TS, Ververs B, et al. Descemet membrane endothelial keratoplasty (DMEK). *Cornea* 2006;25:987-990
3. Guerra FP, Anshu A, Price MO, et al. Descemet's membrane endothelial keratoplasty: prospective study of 1-year visual outcomes, graft survival, and endothelial cell loss. *Ophthalmology* 2011;118:2368–2373
4. Parker J, Dirisamer M, Naveiras M, et al. Outcomes of Descemet membrane endothelial keratoplasty in phakic eyes. *J Cataract Refract Surg* 2012;38:871–7
5. Ham L, Balachandran C, Verschoor CA, et al. Visual rehabilitation rate after isolated Descemet membrane transplantation: Descemet membrane endothelial keratoplasty. *Arch Ophthalmol* 2009;127:252–5
6. Tourtas T, Laaser K, Bachmann BO, et al. Descemet membrane endothelial keratoplasty versus Descemet stripping automated endothelial keratoplasty. *Am J Ophthalmol* 2012;153:1082–90
7. Anshu A, Price MO, Price FW Jr. Risk of corneal transplant rejection significantly reduced with Descemet's membrane endothelial keratoplasty. *Ophthalmology* 2012;119:536–40
8. Price MO, Jordan CS, Moore G, et al. Graft rejection episodes after Descemet stripping with endothelial keratoplasty: part two: the statistical analysis of probability and risk factors. *Br J Ophthalmol* 2009;93:391–5
9. Dapena I, Ham L, Netuková M, et al. Incidence of early allograft rejection after Descemet membrane endothelial keratoplasty. *Cornea* 2011;30:1341–5
10. Price FW Jr, Price MO. Evolution of endothelial keratoplasty. *Cornea* 2013;32:S28-32
11. Eye Bank Association of America. 2015 Eye Banking Statistical Report. Washington, D.C.: Eye Bank Association of America; 2016
12. Terry MA. Endothelial keratoplasty: why aren't we all doing Descemet membrane endothelial keratoplasty? *Cornea* 2012;31:469-71
13. Melles GRJ, Lander F, Rietveld FJR. Transplantation of Descemet's membrane carrying viable endothelium through a small scleral incision. *Cornea* 2002;21:415–8
14. Zhu Z, Rife L, Yiu S, et al. Technique for preparation of the corneal endothelium-Descemet membrane complex for transplantation. *Cornea* 2006;25:705–8
15. Lie JT, Birbal R, Ham L, et al. Donor tissue preparation for Descemet membrane endothelial keratoplasty. *J Cataract Refract Surg* 2008;34:1578–83
16. Groeneveld-van Beek EA, Lie JT, van der Wees J, et al. Standardized 'no-touch' donor tissue preparation for DALK and DMEK: harvesting undamaged anterior and posterior transplants from the same donor cornea. *Acta Ophthalmol* 2013;91:145–50
17. Price MO, Giebel AW, Fairchild KM, et al. Descemet's membrane endothelial keratoplasty: prospective multicenter study of visual and refractive outcomes and endothelial survival. *Ophthalmology* 2009;116:2361–8
18. Giebel AW, Price FW. Descemet's membrane endothelial keratoplasty (DMEK): the bare minimum. Price FW, Price MO(Eds.), DSEK: What You Need to Know about Endothelial Keratoplasty, Thorofare, NJ: SLACK Inc.; (2009), pp. 119–46
19. Tenkman LR, Price FW, Price MO. Descemet membrane endothelial keratoplasty donor preparation: navigating challenges and improving efficiency. *Cornea* 2014;33:319-25

20. Kruse FE, Laaser K, Cursiefen C, et al. A stepwise approach to donor preparation and insertion increases safety and outcome of Descemet membrane endothelial keratoplasty. *Cornea* 2011;30:580–7
21. Yoeruek E, Bartz-Schmidt KU. Novel surgical instruments facilitating Descemet membrane dissection. *Cornea* 2013;32:523-6
22. Sikder S, Ward D, Jun AS. A surgical technique for donor tissue harvesting for Descemet membrane endothelial keratoplasty. *Cornea* 2011;30:91–4
23. Tausif HN, Johnson L, Titus M, et al. Corneal donor tissue preparation for Descemet's membrane endothelial Keratoplasty. *J Vis Exp* 2014;91:51919
24. Anwar M, Teichmann KD. Big-bubble technique to bare Descemet's membrane in anterior lamellar keratoplasty. *J Cataract Refract Surg* 2002;28:398-403
25. Ignacio TS, Nguyen TT, Sarayba MA, et al. A technique to harvest Descemet's membrane with viable endothelial cells for selective transplantation. *Am J Ophthalmol* 2005;139:325-30
26. Venzano D, Pagani P, Randazzo N, et al. Descemet membrane air-bubble separation in donor corneas. *J Cataract Refract Surg* 2010;36:2022-7
27. Zarei-Ghanavati S, Zarei-Ghanavati M, Ramirez-Miranda A. Air-assisted donor preparation for DMEK. *J Cataract Refract Surg* 2011;37:1372; author reply 1372
28. Zarei-Ghanavati S, Khakshoor H, Zarei-Ghanavati M. Reverse big bubble: a new technique for preparing donor tissue of Descemet membrane endothelial keratoplasty. *Br J Ophthalmol* 2010;94:1110-1
29. Busin M, Scorcia V, Patel AK, et al. Pneumatic dissection and storage of donor endothelial tissue for Descemet's membrane endothelial keratoplasty: a novel Technique. *Ophthalmology* 2010;117:1517-20
30. Studeny P, Farkas A, Vokrojova M, et al. Descemet membrane endothelial keratoplasty with a stromal rim (DMEK-S). *Br J Ophthalmol* 2010;94:909-14
31. Agarwal A, Dua HS, Narang P, et al. Pre-Descemet's endothelial keratoplasty (PDEK). *Br J Ophthalmol* 2014;98:1181-5
32. Muraine M, Gueudry J, He Z, et al. Novel technique for the preparation of corneal grafts for Descemet membrane endothelial keratoplasty. *Am J Ophthalmol* 2013;156:851-9
33. Salvalaio G, Parekh M, Ruzza A, et al. DMEK lenticule preparation from donor corneas using a novel 'SubHyS' technique followed by anterior corneal dissection. *Br J Ophthalmol* 2014;98:1120-5
34. Szurman P, Januschowski K, Rickmann A, et al. Novel liquid bubble dissection technique for DMEK lenticule preparation. *Graefes Arch Clin Exp Ophthalmol* 2016;254:1819-23
35. McKee HD, Irion LC, Carley FM, et al. Donor preparation using pneumatic dissection in endothelial keratoplasty: DMEK or DSEK? *Cornea* 2012;31:798-800
36. Schlötzer-Schrehardt U, Bachmann BO, Tourtas T, et al. Reproducibility of graft preparations in Descemet's membrane endothelial keratoplasty. *Ophthalmology* 2013;120:1769-77
37. Ruzza A, Parekh M, Salvalaio G, et al. Bubble technique for Descemet membrane endothelial keratoplasty tissue preparation in an eye bank: air or liquid? *Acta Ophthalmol* 2015;93:e129-34
38. Pipparelli A, Thuret G, Toubeau D, et al. Pan-corneal endothelial viability assessment: application to endothelial grafts predissected by eye banks. *Invest Ophthalmol Vis Sci* 2011;52:6018-25

39. Livny E, Groeneveld-van Beek EA, Lie JT, et al. Minimizing graft preparation failure in Descemet membrane endothelial keratoplasty (DMEK). *Cornea* 2017;36:1452-7
40. Krabcova I, Studeny P, Jirsova K. Endothelial cell density before and after the preparation of corneal lamellae for Descemet membrane endothelial keratoplasty with a stromal rim. *Cornea* 2011;30:1436-41
41. Krabcova I, Studeny P, Jirsova K. Endothelial quality of pre-cut posterior corneal lamellae for Descemet membrane endothelial keratoplasty with a stromal rim (DMEK-S): two-year outcome of manual preparation in an ocular tissue bank. *Cell Tissue Bank* 2013;14:325-31
42. Altaan SL, Gupta A, Sidney LE, et al. Endothelial cell loss following tissue harvesting by pneumodissection for endothelial keratoplasty: an ex vivo study. *Br J Ophthalmol* 2015;99:710-3
43. Parekh M, Ruzza A, Salvalaio G, et al. Descemet membrane endothelial keratoplasty tissue preparation from donor corneas using a standardized submerged hydro-separation method. *Am J Ophthalmol* 2014;158:277-85
44. Ham L, Dapena I, van Luijk C, et al. Descemet membrane endothelial keratoplasty (DMEK) for Fuchs endothelial dystrophy: review of the first 50 consecutive cases. *Eye (Lond)* 2009;23:1990-8
45. Ham L, van Luijk C, Dapena I, et al. Endothelial cell density after descemet membrane endothelial keratoplasty: 1- to 2-year follow-up. *Am J Ophthalmol* 2009;148:521-7
46. Ham L, Dapena I, Van Der Wees J, et al. Endothelial cell density after Descemet membrane endothelial keratoplasty: 1- to 3-year follow-up. *Am J Ophthalmol* 2010;149:1016-7
47. Parker J, Dirisamer M, Naveiras M, et al. Endothelial cell density after Descemet membrane endothelial keratoplasty: 1- to 4-year follow-up. *Am J Ophthalmol* 2011;151:1107-1107
48. Dirisamer M, Ham L, Dapena I, et al. Efficacy of Descemet membrane endothelial keratoplasty: clinical outcome of 200 consecutive cases after a learning curve of 25 cases. *Arch Ophthalmol* 2011;129:1435-43
49. Baydoun L, Tong CM, Tse WW, et al. Endothelial cell density after Descemet membrane endothelial keratoplasty: 1 to 5-year follow-up. *Am J Ophthalmol* 2012;154:762-3
50. Baydoun L, Ham L, Borderie V, et al. Endothelial survival after Descemet membrane endothelial keratoplasty: Effect of surgical indication and graft adherence status. *JAMA Ophthalmol* 2015;133:1277-85
51. Peraza-Nieves J, Baydoun L, Dapena I, et al. Two-year clinical outcome of 500 consecutive cases undergoing Descemet membrane endothelial keratoplasty. *Cornea* 2017;36:655-60
52. Feng MT, Price MO, Miller JM, et al. Air reinjection and endothelial cell density in Descemet membrane endothelial keratoplasty: five-year follow-up. *J Cataract Refract Surg* 2014;40:1116-21
53. Deng SX, Sanchez PJ, Chen L. Clinical outcomes of Descemet membrane endothelial keratoplasty using eye bank-prepared tissues. *Am J Ophthalmol* 2015;159:590-6
54. Gorovoy IR, Gorovoy MS. Descemet membrane endothelial keratoplasty postoperative year 1 endothelial cell counts. *Am J Ophthalmol* 2015;159:597-600
55. Laaser K, Bachmann BO, Horn FK, et al. Donor tissue culture conditions and outcome after descemet membrane endothelial keratoplasty. *Am J Ophthalmol* 2011;151:1007-18

56. Schlögl A, Tourtas T, Kruse FE, Weller JM. Long-term clinical outcome after Descemet membrane endothelial keratoplasty. *Am J Ophthalmol* 2016;169:218-26
57. Studeny P, Sivekova D, Liehneova K, et al. Hybrid technique of lamellar keratoplasty (DMEK-S). *J Ophthalmol* 2013;2013:254383
58. Yoeruek E, Bayyoud T, Hofmann J, et al. Comparison of pneumatic dissection and forceps dissection in Descemet membrane endothelial keratoplasty: histological and ultrastructural findings. *Cornea* 2012;31:920-5
59. Brissette A, Conlon R, Teichman JC, et al. Evaluation of a new technique for preparation of endothelial grafts for Descemet membrane endothelial keratoplasty. *Cornea* 2015;34:557-9
60. Bhogal M, Balda MS, Matter K, et al. Global cell-by-cell evaluation of endothelial viability after two methods of graft preparation in Descemet membrane endothelial keratoplasty. *Br J Ophthalmol* 2016;100:572-8
61. Bhogal M, Matter K, Balda MS, et al. Organ culture storage of pre-prepared corneal donor material for Descemet's membrane endothelial keratoplasty. *Br J Ophthalmol* 2016;100:1576-83
62. Campolmi N, Trone MC, Nefzaoui C, et al. Very early endothelial cell loss after simultaneous corneal autograft and allograft. *Cornea* 2014;33:201-6
63. Gauthier AS, Garcin T, Thuret G, et al. Very early endothelial cell loss after penetrating keratoplasty with organ-cultured corneas. *Br J Ophthalmol* 2017;101:1113-18

Part II

Selective, Minimally-Invasive and Potentially Tissue-Sparing Surgical Treatment Modalities for Corneal Endothelial Disorders

Birbal RS[1-3], Baydoun L[1,2,4], Ham L[1-3] , Miron A[1,2], van Dijk K [1,2], Dapena I[1,2], Jager MJ[5], Böhringer S[6], Oellerich S[1] and Melles GRJ[1-3,7]

[1] Netherlands Institute for Innovative Ocular Surgery (NIIOS), Rotterdam, The Netherlands

[2] Melles Cornea Clinic, Rotterdam, The Netherlands

[3] Amnitrans EyeBank, Rotterdam, The Netherlands

[4] Department of Ophthalmology, University Hospital Münster, Münster, Germany

[5] Department of Ophthalmology, Leiden University Medical Center, Leiden, The Netherlands

[6] Department of Biomedical Data Sciences, Leiden University Medical Center, Leiden, The Netherlands

[7] NIIOS-USA, San Diego, California, United States of America

Chapter 3

Effect of Surgical Indication and Preoperative Lens Status on Descemet Membrane Endothelial Keratoplasty Outcomes

Am J Ophthalmol 2020;212:79-87

ABSTRACT

Purpose: To analyze 6-month results of 1000 consecutive Descemet membrane endothelial keratoplasty (DMEK) cases, and to evaluate if outcomes are influenced by surgical indication and preoperative lens status.

Design: Retrospective, interventional case series.

Methods: A series of 1000 eyes (738 patients) underwent DMEK mainly for Fuchs endothelial corneal dystrophy (FECD; 85.3%) or bullous keratopathy (BK; 10.5%). Main outcome measures were best-corrected visual acuity (BCVA), endothelial cell density (ECD), postoperative complications and re-transplantations.

Results: At 6 months after DMEK, there was no difference in BCVA outcome between FECD and BK eyes (P=0.170), or between phakic and pseudophakic FECD eyes (P=0.066) after correcting for patient age and preoperative BCVA. Endothelial cell loss at 6 months postoperatively was similar for phakic and pseudophakic FECD eyes (39%; P=0.852), but higher for BK eyes than for FECD eyes (46% versus 39%, P=0.001). Primary and secondary graft failure occurred in 3 (0.3%) and 2 eyes (0.2%), respectively, and 7 eyes developed allograft rejection (0.7%). Eighty-two eyes (8.2%) received re-bubbling for graft detachment and re-transplantation was performed in 20 eyes (2.0%). Re-bubbling was more often required in eyes treated for BK versus FECD eyes (12.4% versus 7.4%, P=0.022).

Conclusion: DMEK consistently provides excellent short-term results, with similar high visual acuity levels for both FECD and BK eyes. As preoperative lens status did not influence DMEK outcomes, for phakic FECD eyes with a still relatively clear crystalline lens, lens preservation may be preferable in a selected group of younger patients, who may still benefit from their residual accommodative capacity.

INTRODUCTION

Since its clinical introduction in 2006, Descemet membrane endothelial keratoplasty (DMEK) has emerged as an increasingly popular treatment option for corneal endothelial dysfunction.[1,2] This minimally-invasive surgical technique provides near-perfect anatomic restoration of the cornea and yields superior clinical results compared to its predecessors.[3]

Multiple studies have provided excellent outcomes[4-7] and have revealed that the first 6 months after DMEK appear to be the most critical time period after which the results mostly stabilize.[3,8-11] Since Fuchs endothelial corneal dystrophy (FECD) is the main indication for DMEK, most studies either focus on the clinical outcomes in FECD eyes or present results for all surgery indications combined.[3,6,8-11] When studying a smaller cohort of DMEK eyes at our own institute, we observed better results for eyes treated for FECD compared to eyes with bullous keratopathy (BK), and for phakic FECD compared with pseudophakic FECD eyes. We reported that preoperative parameters such as surgical indication and lens status may influence DMEK outcomes. [12,13] However, Brockmann et al. reported similar outcomes for eyes operated on for FECD and BK.[14] As such, further evaluation of the clinical impact of these parameters after DMEK would be of added value and could possibly enable us to counsel future patients more accurately on the expected outcomes.

Our expanding DMEK cohort and simultaneously growing dataset now allows us to perform more detailed analyses on subgroups. The objective of this study was to assess the overall 6-month clinical outcomes of 1000 consecutive DMEK cases operated at our institute, and to evaluate how these are influenced by surgical indication (FECD versus BK) and preoperative lens status (phakic versus pseudophakic FECD).

METHODS

Patient data

A cohort of 1000 consecutive eyes of 738 patients (mean age 68 (±12) years; range 20-96 years) underwent DMEK for FECD (85.3%), BK (10.5%), failed previous transplant (3.7%) or other indications (0.5%) (Table 1) and was retrospectively analyzed. The 1000 cases that were evaluated were cases 26-1025 from a total of 1025 consecutive DMEK surgeries performed in our clinic. The

very first 25 DMEK cases (cases 1-25), that we consider to represent the learning curve of this technique, were excluded from analysis. Patient and donor demographics are displayed in Table 1. All patients signed an informed consent form prior to surgery for research participation and the study adhered to the tenets of the Declaration of Helsinki.

Graft preparation

DMEK graft preparation was performed using the traditional and/ or standardized '*no-touch*' technique at Amnitrans EyeBank Rotterdam.[15,16] In short, within 36 hours postmortem, donor globes were enucleated, and corneoscleral buttons were excised. Corneoscleral buttons were stored in organ culture medium (CorneaMax; Eurobio, Courtaboeuf, France) until the time of transplantation; mean graft storage time was 14.2 (±4) days (Table 1). After 1-2 weeks of culture, corneoscleral buttons were mounted endothelial side up on a custom-made holder and using a hockeystick knife (DORC International, Zuidland, The Netherlands) the trabecular meshwork was loosened over 360 degrees. After complete Descemet membrane (DM) stripping and trephination, the donor sheets spontaneously formed a roll with the endothelium facing outward. All rolls were preserved in organ culture medium until the time of transplantation. Endothelial cell morphology and viability were evaluated with an inverted light microscope (Axiovert 40; Zeiss, Göttingen, Germany) before and after DM stripping.

DMEK surgery

Two weeks before DMEK surgery, a peripheral iridotomy was created at the 12 o'clock surgical position with a neodymium-doped yttrium aluminum garnet (Nd:YAG)-laser. DMEK-surgery was performed under local (retrobulbar) anesthesia at the Melles Cornea Clinic in Rotterdam. The standardized '*no-touch'* DMEK technique was not fully implemented for approximately the first 250 cases, whereas it was for the latter 750 cases.[4,17] In short, three side ports were created, after which the anterior chamber was completely filled with air to facilitate scoring and descemetorhexis with a reversed Sinskey hook (DORC International, Zuidland, The Netherlands). A 3.0-mm limbal tunnel incision was created at the 12 o'clock position and the donor DM graft was stained with 0.06% trypan blue solution (VisionBlueTM; DORC International), aspirated into the Melles glass injector and implanted into the recipient anterior chamber. After a correct orientation was confirmed, the graft (endothelium facing down) was centered and unfolded before it was lifted onto the recipient posterior stroma. A complete air fill of the anterior chamber was applied for on average

Table 1: Demographics of Descemet membrane endothelial keratoplasty eyes (n=1000) and donors.

Baseline parameters	Result	
Number of eyes / patients		1000 / 738
Sex (female/male), % (n)	53%/47%	(392/346)
Indication for DMEK		
FECD	85.3%	(853)
BK: pseudophakic, aphakic, (removed) phakic IOL,	10.5%	(105)
(congenital) glaucoma, post-glaucoma surgery, post RK	3.7%	(37)
Failed graft: PKP / (re-)DSEK / (re-)DSAEK / DMEK)	0.5%	(5)
Other: corneal dystrophies, corneal decompensation due to trauma, acanthamoeba keratitis)		
Mean age ±SD, years (n eyes)	68 ±12	(1000)
Total study group		
FECD group	69 ±11	(853)
Total FECD group[a]	72 ±8	(629)
Pseudophakic FECD group	58 ±9	(223)
Phakic FECD group	64 ±17	(105)
BK group	64 ±10	(37)
Failed graft group	45 ±17	(5)
Other		
Pre- and postoperative lens status, % (n eyes)		
Pseudophakic	73.9%	(739)
Phakic	25.6%	(256)
Aphakic	0.5%	(5)
Presence of glaucoma drainage device, % (n eyes)		
Total Group	1.2%	(12)
FECD group	0.0%	(0)
BK group	9.5%[b]	(10)
Failed graft group	5.4%[c]	(2)
Other	0.0%	(0)
Donor age ±SD, years	67 ±10	
Donor sex (female/male), % (n)	38%/62%	(381/619)
Donor death cause, % (n)		
Cancer	26.1%	(261)
Cardiovascular/Stroke	46.5%	(465)
Respiratory	19.1%	(191)
Trauma	2.8%	(28)
Other	5.4%	(54)
Not available	0.1%	(1)
Graft storage time in medium ±SD, days	14.2 ±4	

SD: Standard deviation; FECD: Fuchs endothelial corneal dystrophy BK: Bullous keratopathy; PKP: Penetrating keratoplasty; Re-: Repeat, DSAEK: Descemet stripping automated endothelial keratoplasty; DSEK: Descemet stripping endothelial keratoplasty; DMEK: Descemet membrane endothelial keratoplasty; IOL: Intraocular lens'; RK: Radial keratotomy

[a]: FECD group includes one aphakic eye

[b]: Percentage calculated based on 105 eyes with surgery indication BK

[c]: Percentage calculated based on 37 eyes with surgery indication 'Failed graft'

60 minutes (range, 30-120 minutes), after which an air-liquid exchange was performed leaving a 30-50% air bubble in the anterior chamber to promote graft adherence.

Postoperative topical medication included chloramphenicol 0.5% six times daily during the first week and twice daily during the second week and ketorolac tromethamine 0.4% and dexamethasone 0.1% four times daily for four weeks, followed by fluorometholone 0.1% four times daily, tapered to once daily at one year postoperatively, and once daily or once every other day indefinitely thereafter.

Data collection and statistical analysis

Patients were examined before and 1, 3, and 6 months after DMEK. Best-corrected visual acuity (BCVA) was measured using a Snellen letter chart. A total of 201 eyes (20.1%) were either not available for BCVA analyses due to incomplete data (n=30; 3.0%), loss to follow-up (n=18; 1.8%), re-transplantation within 6 months after DMEK (n=20; 2.0%), or were excluded from BCVA analyses due to low visual potential induced by ocular comorbidities unrelated to the cornea (n=133; 13.3%). BCVA outcomes were converted to the logarithm of the minimum angle of resolution units (LogMAR) for statistical analyses.

Endothelial cell density (ECD) was evaluated *in vivo* using a Topcon SP3000p non-contact autofocus specular microscope (Topcon Medical Europe BV, Capelle a/d IJssel, The Netherlands). For ECD counting, the commercial software of the specular microscope (ImageNet software, Topcon Medical Europe) was employed and the automatically delineated cell borders were checked and when incorrectly assigned, the cell borders were manually re-assigned by a trained technician. For each follow-up the results of three ECD measurements per eye were averaged. A total of 109 eyes (10.9%) were not available for ECD analyses due to incomplete data or insufficient image quality (n=71; 7.1%), loss to follow-up (n=18; 1.8%), or re-transplantation within 6 months after DMEK (n=20; 2.0%).

Central corneal thickness (CCT) was measured using rotating Scheimpflug corneal tomography (Pentacam HR, Oculus Optikgeräte GmbH, Wetzlar, Germany) and CCT data were available for 872 eyes at the 6-month follow-up time point.

Graft detachment after DMEK was evaluated with slit-lamp examination and anterior segment optical coherence tomography (AS-OCT). Detachments were subdivided into minor (detachment ≤1/3 of the graft surface area) and major graft detachments (detachment >1/3 of the graft surface area). Allograft rejection was defined as the presence of an endothelial rejection line or keratic precipitates, with or without an increase in corneal thickness, anterior uveitis, and/ or ciliary injection on slit-lamp examination. Primary graft failure (PGF) was defined as a cornea that failed to clear in the presence of an attached graft, whereas secondary graft failure (SGF) was defined as corneal decompensation following an initial period of a clear cornea with a functional attached graft after DMEK.

For statistical analyses, second eyes of patients undergoing bilateral DMEK (n=262) were excluded. Binary outcomes were analyzed using logistic regression. Continuous outcomes were analysed using linear regression. For group comparisons, outcomes were corrected for age and preoperative values of the outcomes. Analyses were performed in R 3.5.0 using standard function *glm* and *lm*. All eyes were included for descriptive analyses, which was performed using Excel software for Windows (Microsoft Corp, Redmond, Washington, USA). *P*-values < 0.05 were considered statistically significant.

RESULTS

Visual outcome

At 1 month after DMEK, 48% of the eyes of the entire cohort (excluding eyes with low visual potential) achieved a BCVA of ≥20/25 (0.8), 20% achieved ≥20/20 (1.0), and 4% achieved ≥20/17 (1.2). At 3 and 6 months after DMEK, these percentages increased to 66%, 32% and 8% of eyes, and 75%, 41% and 12% of eyes, respectively (Fig., Table 2). When also including eyes with low visual potential in the 6-month BCVA analysis, 65% of the eyes reached a BCVA of ≥20/25 (0.8), 35% achieved ≥20/20 (1.0), and 10% achieved ≥20/17 (1.2) (Table 2).

Of the eyes that underwent DMEK for FECD, 77% achieved a BCVA of ≥20/25 (0.8), 42% achieved ≥20/20 (1.0), and 12% achieved ≥20/17 (1.2) at 6 months after DMEK. Further analyses revealed that of the phakic and pseudophakic eyes treated for FECD, 84% of phakic FECD eyes achieved a BCVA of ≥20/25 (0.8), 56% of ≥20/20 (1.0), and 19% of ≥20/17 (1.2) versus 74%, 37% and 9% for

Table 2. Clinical outcomes after Descemet membrane endothelial keratoplasty.

	Total group		FECD						BK	
			Total FECD group		Pseudophakic FECD group		Phakic FECD group			
Parameter	**Preoperative**	**6m FU**	**Preoperative**	**6m FU**	**Preoperative**	**6m FU**	**Preoperative**	**6m FU**	**Preoperative**	**6m FU**
BCVA in Snellen (Decimal)										
[LVP eyes excluded]										
< 20/40 (< 0.5)	(n=799)	(n=799)	(n=721)	(n=721)	(n=519)	(n=519)	(n=202)	(n=202)	(n=53)	(n=53)
≥ 20/40 (≥ 0.5)	54.7%	4.1%	51.5%	3.3%	59.3%	3.9%	31.2%	2.0%	83.0%	9.4%
≥ 20/25 (≥ 0.8)	45.3%	95.9%	48.5%	96.7%	40.7%	96.1%	68.8%	98.0%	17.0%	90.6%
≥ 20/20 (≥ 1.0)	8.9%	75.3%	9.2%	76.7%	6.0%	74.0%	17.3%	83.7%	9.4%	66.0%
≥ 20/17 (≥ 1.2)	1.3%	40.9%	1.4%	42.0%	0.6%	36.6%	3.5%	55.9%	-	32.1%
	0.3%	12.1%	0.3%	12.2%	-	9.4%	1.0%	19.3%	-	13.2%
Mean BCVA (±SD), (logMAR)										
[LVP eyes excluded]	0.46 (±0.38)	0.09 (±0.21)	0.42 (±0.32)	0.08 (±0.21)	0.48 (±0.35)	0.10 (±0.23)	0.29 (±0.20)	0.04 (±0.10)	0.79 (±0.51)	0.13 (±0.22)
BCVA in Snellen (Decimal)										
[LVP eyes included]										
< 20/40 (< 0.5)	(n=932)	(n=932)	(n=809)	(n=809)	(n=598)	(n=598)	(n=210)	(n=210)	(n=88)	(n=88)
≥ 20/40 (≥ 0.5)	59.3%	12.0%	55.3%	8.7%	63.4%	10.7%	31.9%	2.9%	85.2%	35.2%
≥ 20/25 (≥ 0.8)	40.7%	88.0%	44.7%	91.3%	36.6%	89.3%	68.1%	97.1%	14.8%	64.8%
≥ 20/20 (≥ 1.0)	7.8%	64.6%	8.4%	68.4%	5.2%	64.2%	17.6%	80.5%	5.7%	39.8%
≥ 20/17 (≥ 1.2)	1.1%	35.1%	1.2%	37.5%	0.5%	31.8%	3.3%	53.8%	-	19.3%
	0.2%	10.4%	0.2%	10.9%	-	8.2%	1.0%	18.6%	-	8.0%
Mean BCVA (±SD), (logMAR)										
[LVP eyes included]	0.53 (±0.46)	0.16 (±0.30)	0.45 (±0.34)	0.12 (±0.24)	0.51 (±0.37)	0.15 (±0.27)	0.30 (±0.20)	0.05 (±0.12)	1.04 (±0.67)	0.38 (±0.51)

Table 2. Clinical outcomes after Descemet membrane endothelial keratoplasty. (*continued*)

	Total group		FECD						BK	
			Total FECD group		Pseudophakic FECD group		Phakic FECD group			
Parameter	**Preoperative**	**6m FU**	**Preoperative**	**6m FU**	**Preoperative**	**6m FU**	**Preoperative**	**6m FU**	**Preoperative**	**6m FU**
Endothelial cell density (ECD)										
Mean ECD (±SD), (cells/mm^2)	(n=891)	(n=891)	(n=789)	(n=789)	(n=582)	(n=582)	(n=206)	(n=206)	(n=77)	(n=77)
ECD decline (±SD), (%)[a]	2565 (±185)	1550 (±485)	2565 (±185)	1565 (±480)	2555 (±180)	1560 (±485)	2595 (±195)	1590 (±470)	2535 (±205)	1375 (±460)
		40 (±18)		39 (±18)		39 (±18)		39 (±17)		46 (±18)
Pachymetry										
Mean CCT (±SD), (μm)	(n=872)	(n=872)	(n=777)	(n=777)	(n=573)	(n=573)	(n=203)	(n=203)	(n=77)	(n=77)
CCT decline (±SD), (%)[a]	687 (±144)	522 (±54)	670 (±99)	520 (±42)	677 (±104)	519 (±43)	647 (±75)	521 (±40)	796 (±205)	526 (±59)
		22 (±12)		21 (±10)		22 (±11)		19 (±8)		30 (±17)

FECD= Fuchs endothelial corneal dystrophy; BK= Bullous keratopathy; m= months; FU= Follow-up; BCVA= Best-corrected visual acuity; LVP= Low visual potential eyes; n= number of eyes; SD= standard deviation.
[a]Decline as compared to preoperative values

the pseudophakic FECD group, respectively ($P < 0.001$) (Table 2, Fig.). However, when correcting for age and preoperative BCVA, visual acuity outcomes did not differ between the phakic and pseudophakic FECD eyes ($P = 0.066$).

Further analyses of eyes that underwent DMEK for BK showed that 66% of eyes achieved a BCVA of ≥20/25 (0.8), 32% achieved ≥20/20 (1.0), and 13% achieved ≥20/17 (1.2) at 6 months after DMEK (Table 2). Comparison of BCVA outcomes of eyes treated for FECD and for BK, showed similar outcomes for both groups when correcting for patient age and preoperative BCVA ($P = 0.172$). Overall, the entire cohort, as well as all subgroups showed an improvement in BCVA outcomes at 6 months after DMEK when compared to preoperative values ($P < 0.001$).

Endothelial cell density

Donor ECD for the entire cohort averaged 2565 (±185) cells/mm^2 before DMEK and 1550 (±485) cells/mm^2 (-40% (±18%)) at 6 months after DMEK (n=891) ($P < 0.001$) (Table 2). Eyes treated for FECD showed a decline in preoperative ECD of 39% at 6 months postoperatively ($P < 0.001$), with no difference between phakic and pseudophakic eyes ($P = 0.85$). Eyes treated for BK demonstrated a higher ECD decline of 46% than eyes treated for FECD at 6 months postoperatively ($P = 0.001$) (Table 2).

Pachymetry

Mean patient CCT improved from 687 (±144) µm before DMEK to 522 (±54) µm (-22%) at 6 months after DMEK ($P < 0.001$) (Table 2). From preoperative to 6 months after DMEK, mean CCT decreased in all subgroups ($P < 0.001$) and CCT at 6m postoperatively was comparable for all groups ($P>0.05$) (Table 2). In percentages, the reduction in CCT from preoperative to 6 months postoperatively was higher in eyes treated for BK than for eyes treated for FECD, 30% and 21%, respectively ($P < 0.001$); this was also observed for pseudophakic FECD eyes as compared to phakic FECD eyes, 22% and 19%, respectively ($P < 0.001$).

Postoperative complications and re-transplantation

Within the first 6 months after DMEK, primary graft failure occurred in 3 eyes (0.3%) and secondary graft failure in 2 eyes (0.2%). Seven eyes developed allograft rejection (0.7%) (Table 3) and were all successfully managed by applying an intensified regimen of topical corticosteroids. Within 6 months after

phakic DMEK, phacoemulsification with intraocular lens implantation was performed in 4 of 256 eyes (1.6%) (Table 3).

Table 3. Early complications and secondary procedures after Descemet membrane endothelial keratoplasty (within 6 months).

	Total group (n=1000)		FECD						BK (n=105)	
			Total FECD group (n=853)		Pseudophakic FECD group (n=629)		Phakic FECD group (n=223)			
Postoperative complications										
Primary graft failure[a]	0.3%	(n=3)	0.1%	(n=1)	0.2%	(n=1)	0.0%	(n=0)	1.9%	(n=2)
Secondary graft failure[b]	0.2%	(n=2)	0.0%	(n=0)	0.0%	(n=0)	0.0%	(n=0)	1.0%	(n=1)
Allograft rejection	0.7%	(n=7)	0.5%	(n=4)	0.6%	(n=4)	0.0%	(n=0)	2.9%	(n=3)
Phacoemulsification + IOL[c]										
For pre-existent cataract	0.4%	(n=1)[d]	-	-	-	-	-	-	-	-
For cataract after DMEK	1.2%	(n=3)	0.9%	(n=2)	-	-	0.9%	(n=2)	4.5%	(n=1)
Detachment[e]										
Detachments ≤1/3	8.7%	(n=87)	8.8%	(n=75)	9.2%	(n=58)	7.6%	(n=17)	8.6%	(n=9)
Detachments >1/3	4.3%	(n=43)	3.5%	(n=30)	4.0%	(n=25)	2.2%	(n=5)	7.6%	(n=8)
Secondary procedures										
Re-bubbling	8.2%	(n=82)	7.4%	(n=63)	8.0%	(n=50)	5.8%	(n=13)	12.4%	(n=13)
Re-transplantation										
Re-DMEK	1.1%	(n=11)	0.9%	(n=8)	0.6%	(n=4)	1.8%	(n=4)	1.9%	(n=2)
Secondary DSEK	0.8%	(n=8)	0.7%	(n=6)	1.0%	(n=6)	0.0%	(n=0)	1.9%	(n=2)
Secondary PKP	0.1%	(n=1)	0.0%	(n=0)	0.0%	(n=0)	0.0%	(n=0)	1.0%	(n=1)

FECD: Fuchs endothelial corneal dystrophy; BK: Bullous keratopathy; n: Number; DMEK: Descemet membrane endothelial keratoplasty; DSEK: Descemet stripping endothelial keratoplasty; PKP: Penetrating keratoplasty; IOL: Intraocular lens

[a]: Primary graft failure refers to an attached graft, but cornea fails to clear

[b]: Secondary graft failure refers to an attached graft with (signs of) corneal clearance, followed by corneal decompensation

[c]: Phakic eyes: total (n=256), FECD (n=223) and BK (n=22).

[d]: Surgery indication in this eye was acanthamoeba keratitis.

[e]: Includes all graft detachments as observed at the six months follow-up

At 6 months after DMEK, a total of 130 of 1000 eyes (13.0%) showed persistent graft detachment, of which 8.7% (n=87) had a minor detachment and 4.3% (n=43) a major detachment. The overall detachment rate did not differ between FECD versus BK eyes (P = 0.09) and between phakic and pseudophakic FECD eyes (P = 0.143).

Eighty-two eyes (8.2%) received a re-bubbling procedure for visually significant graft dehiscence, of which 15 (1.5%) procedures were performed in the first 500 cases and 67 (6.7%) procedures in the second 500 cases. BK eyes

underwent a re-bubbling procedure more often than FECD eyes (12.4% versus 7.4%, P = 0.022), whereas the procedure was performed at a comparable rate for phakic versus pseudophakic FECD eyes (5.8% versus 8.0%, P = 0.561).

Graft detachment was the main indication for re-transplantation and a total of 20 eyes (2.0%) underwent a secondary keratoplasty within 6 months after DMEK, of which 5 eyes underwent re-transplantation after an unsuccessful re-bubbling procedure. Eleven of the re-transplantations were performed in the first 500 cases (1.1%) and 9 in the second 500 cases (0.9%). Re-transplantation

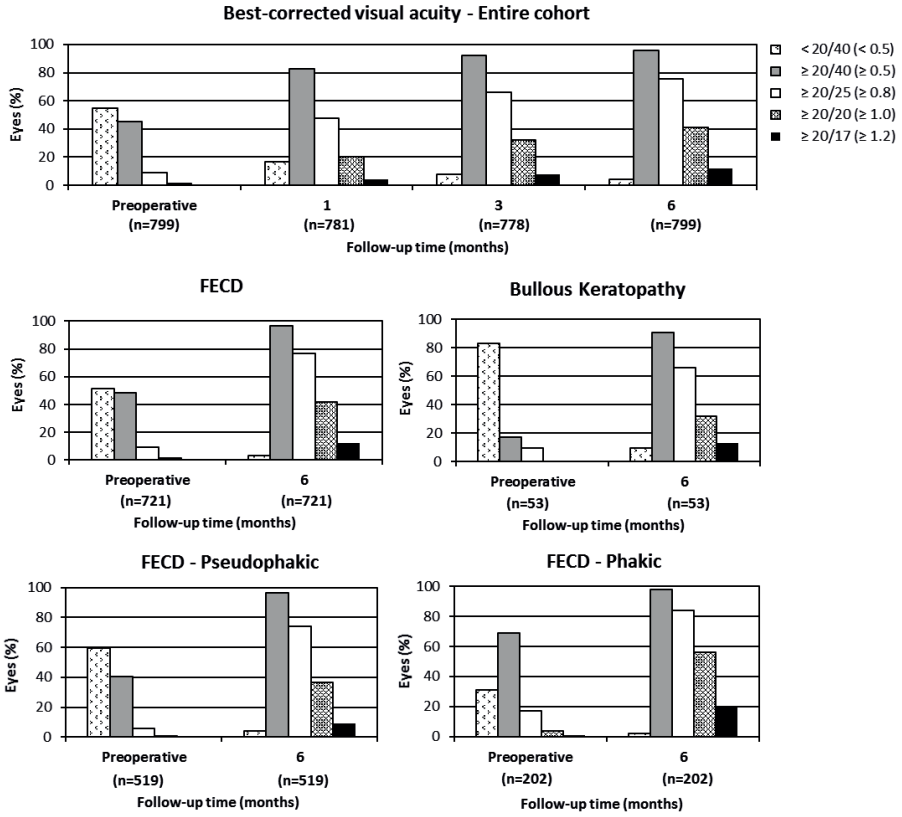

Figure 1. Bar graphs displaying the best-corrected visual acuity up to 6 months after Descemet membrane endothelial keratoplasty.
Graphs illustrate the best-corrected visual acuity (BCVA) up to 6 months postoperatively for the entire cohort (excluding low-visual-potential eyes) before and at 1, 3 and 6 months after DMEK (upper row), and for the two subgroups based upon surgical indication (Fuchs endothelial corneal dystrophy [FECD] and Bullous keratopathy [BK], middle row) and based upon preoperative lens status (pseudophakic and phakic FECD eyes, bottom row).

rate did not differ between FECD and BK eyes, nor between phakic and pseudophakic FECD eyes (P>0.05 for all comparisons).

DISCUSSION

The current study confirms that DMEK consistently provides excellent short-term outcomes, also on a larger scale. For this study, we additionally assessed outcomes based on surgical indication and preoperative lens status.

Surgical indication

As most results regarding the outcome of DMEK that have been reported in the literature refer to FECD eyes, it is well known that patients with FECD may achieve very good visual acuity results after DMEK.[3,6,8-11] In this study we could show for a relatively large group of BK eyes, that even though overall BCVA results were lower than for FECD eyes, the difference was not significant when correcting for preoperative BCVA (lower in the BK group) and patient age; this outcome confirms the results of a recently published study on a smaller cohort.[14] Thus, it is important to emphasize that most BK eyes (66%) without visual-acuity limiting co-morbidities may expect a good visual performance of 0.8 (20/25) or 1.0 (20/20) or better, even early after DMEK. This may be due to the fast deswelling of BK corneas that on average reach normal CCT levels within 6 months after the operation, despite higher preoperative CCT values.

With this expanded study group, we were able to confirm prior results regarding ECD decline, which showed a larger decline in BK compared with FECD eyes.[13,18] In contrast, Brockmann et al. did not detect any difference, which could be either owing to their smaller sample size[14] or maybe also because of the relatively high percentage of eyes with a glaucoma drainage device in our BK group which has been shown to be a risk factor for high ECD decline after DMEK.[19] The lower ECD decline in the early postoperative phase after DMEK in FECD eyes may also explain the higher longer-term survival rates in FECD eyes compared to eyes treated for other indications.[3,13,18,20] These data may imply that FECD eyes, in general, perform better when it comes to endothelial cell rehabilitation and graft longevity, which could be attributed to a regenerative capacity of endothelial cells in the recipient corneal rim, whereas in BK eyes this may be less favorable owing to a relative depletion of host endothelial cells and pathological changes at the level of the corneal endothelium and/ or the stroma.[14,21] To enhance graft longevity in BK eyes,

one may therefore consider utilizing DMEK grafts of superior quality, that is, for example, grafts with a higher preoperative ECD (≥ 3000 cells/mm^2) since some reports indicated an effect of preoperative donor ECD on ECD outcome after DMEK.[10,13,14,22]

Compared with FECD eyes, BK is a more heterogenous group, consisting of eyes with slow corneal decompensation owing to previous cataract surgery, but also of eyes with complex pathology such as posterior segment surgery, glaucoma drainage devices and post-trauma. Thus from a ´clinical impression`, we consider BK eyes to be at higher risk for postoperative graft dehiscence owing to a more edematous preoperative cornea with reduced imbibition pressure. However, interestingly, detachment rates did not depend on surgical indication according to the current analysis and as reported before by Brockmann and associates.[14] Still, when comparing subgroups, the overall re-bubbling rate was higher in BK than in FECD eyes, which could be explained by a larger extension of the detachment more often involving the visual axis but also by decision bias, i.e. spontaneous graft adherence may be considered less likely in BK eyes due to the pronounced edema, and therefore re-bubbling is indicated more quickly.

Lens status

When correcting for preoperative BCVA (lower in pseudophakic FECD group) and patient age (lower in phakic FECD group), overall BCVA outcomes did not differ between phakic and pseudophakic FECD eyes. These findings confirm our results obtained with a smaller cohort before.[12] Furthermore, Triple DMEK studies have shown to yield similar short-term results compared to two-staged cataract and DMEK surgery.[23-25] Still, there are several reasons why we prefer a two-staged approach in cases with concomitant moderate-to-advanced cataract and FECD, First, in our experience about 30% of patients who first receive cataract surgery alone are satisfied with the visual outcome without requiring subsequent corneal transplantation (clinical observation). This allows postponing corneal transplantation a couple of months or even years while at the same time reducing the need for aftercare (i.e. regular follow-ups after keratoplasty and continuous topical steroidal treatment) which may be perceived as a burden for some patients. In addition, this approach could save corneal tissue and reduce waiting lists for keratoplasty. Second, a triple procedure may induce more intraocular inflammation than isolated surgery. Therefore, we usually wait 6-8 weeks after cataract surgery before performing DMEK. During that time the corneal condition not only stabilizes, but the

patient can also better evaluate if lens surgery alone was sufficient to improve visual performance, and post-surgical inflammation from cataract surgery is normally controlled within this time period. We believe minimized inflammation may be a better precondition before inserting antigenic tissue. Third, we try to avoid conditions that may interfere with graft adherence, as the use of viscoelastics may be associated with higher detachment rates.[25]

On the other hand, when first performing isolated DMEK, the present data together with the relatively low 5-year visually significant cataract formation rate of 16.9% recently described in a series of 124 phakic DMEK eyes,[3] may support a strategy to preserve the (clear) crystalline lens in a selected group of younger FECD patients, who may still benefit from a residual accommodative capacity and a better overall optical quality of the eye. Moreover, this approach may avoid complications of an additional surgery. Iatrogenic damage to the DMEK graft may be a legitimate concern regarding cataract surgery after DMEK.[26] Several studies, however, showed that cataract extraction is feasible with acceptable endothelial cell loss when performed with certain precautions.[27-30] If so, it would stand to reason to leave a relatively clear crystalline lens in situ for eyes in whichthe corneal disease is the predominant reason for visual deterioration, so that cataract surgery may be deferred to a later time point.[31]

Re-bubbling rates were comparable in phakic and pseudophakic FECD eyes, in line with observations by other groups.[32] It might be noteworthy, that the about four-fold increase in re-bubbling procedures from the first 500 DMEK cases to the second 500 DMEK cases can be attributed to our changed policy regarding re-bubbling graft detachments. While we initially tended to await spontaneous corneal clearance or graft attachment, we nowadays await the 1-week follow-up to decide if a re-bubbling procedure is required.[33,34]

In conclusion, our study confirms that DMEK consistently provides excellent short-term results, with similar high visual acuity levels for both FECD and BK eyes. As preoperative lens status did not influence DMEK outcomes, in phakic FECD eyes with a still relatively clear crystalline lens, it may be preferable to preserve the lens in a selected group of younger patients, who may still benefit from their residual accommodative capacity.

REFERENCES

1. Melles GR, Ong TS, Ververs B, van der Wees J. Descemet membrane endothelial keratoplasty (DMEK). *Cornea* 2006;25:987-90
2. Eye Bank Association of America. *2018 Eye banking Statistical Report* Washington, DC: Eye Bank Association of America; 2019
3. Birbal RS, Ni Dhubhghaill S, Bourgonje VJA, et al. Five-year graft survival and clinical outcomes of 500 consecutive cases after Descemet membrane endothelial keratoplasty. *Cornea* 2020;39:290-7
4. Rodríguez-Calvo-de-Mora M, Quilendrino R, Ham L, et al. Clinical outcome of 500 consecutive cases undergoing Descemet's membrane endothelial keratoplasty. *Ophthalmology* 2015;122:464-70
5. Hamzaoglu EC, Straiko MD, Mayko ZM, Sáles CS, Terry MA. The First 100 eyes of standardized Descemet stripping automated endothelial keratoplasty versus standardized Descemet membrane endothelial keratoplasty. *Ophthalmology* 2015;122:2193-9
6. Deng SX, Lee WB, Hammersmith KM, et al. Descemet membrane endothelial keratoplasty: safety and outcomes: a report by the American Academy of Ophthalmology. *Ophthalmology* 2018;125:295-310
7. Guerra FP, Anshu A, Price MO, Giebel AW, Price FW. Descemet's membrane endothelial keratoplasty: prospective study of 1-year visual outcomes, graft survival, and endothelial cell loss. *Ophthalmology* 2011;118:2368-73
8. Feng MT, Price MO, Miller JM, Price FW Jr. Air reinjection and endothelial cell density in Descemet membrane endothelial keratoplasty: five-year follow-up. *J Cataract Refract Surg* 2014;40:1116-21
9. Schlögl A, Tourtas T, Kruse FE, Weller JM. Long-term clinical outcome after Descemet membrane endothelial keratoplasty. *Am J Ophthalmol* 2016;169:218-226
10. Price DA, Kelley M, Price FW Jr, Price MO. Five-year graft survival of Descemet membrane endothelial eeratoplasty (EK) versus Descemet stripping EK and the effect of donor sex matching. *Ophthalmology* 2018;125:1508-14
11. Schrittenlocher S, Schaub F, Hos D, Siebelmann S, Cursiefen C, Bachmann B. Evolution of consecutive Descemet membrane endothelial keratoplasty outcomes throughout a 5-year period performed by two experienced surgeons. *Am J Ophthalmol* 2018;190:171-8
12. Parker J, Dirisamer M, Naveiras M, et al. Outcomes of Descemet membrane endothelial keratoplasty in phakic eyes. *J Cataract Refract Surg* 2012;38:871-7
13. Baydoun L, Ham L, Borderie V, et al. Endothelial survival after Descemet membrane endothelial keratoplasty: effect of surgical indication and graft adherence status. *JAMA Ophthalmol* 2015;133:1277-85
14. Brockmann T, Brockmann C, Maier AB, Schroeter J, Bertelmann E, Torun N. Primary Descemet's membrane endothelial keratoplasty for Fuchs endothelial dystrophy versus bullous keratopathy: histopathology and clinical results. *Curr Eye Res* 2018;43:1221-27
15. Lie JT, Birbal R, Ham L, van der Wees J, Melles GR. Donor tissue preparation for Descemet membrane endothelial keratoplasty. *J Cataract Refract Surg* 2008;34:1578-83
16. Groeneveld-van Beek EA, Lie JT, van der Wees J, Bruinsma M, Melles GR. Standardized 'no-touch' donor tissue preparation for DALK and DMEK: harvesting undamaged

anterior and posterior transplants from the same donor cornea. *Acta Ophthalmol* 2013;91:145-50

17. Dapena I, Moutsouris K, Droutsas K, Ham L, van Dijk K, Melles GR. Standardized "no-touch" technique for Descemet membrane endothelial keratoplasty. *Arch Ophthalmol* 2011;129:88-94
18. Heinzelmann S, Böhringer D, Eberwein P, Reinhard T, Maier P. Outcomes of Descemet membrane endothelial keratoplasty, Descemet stripping automated endothelial keratoplasty and penetrating keratoplasty from a single centre study. *Graefes Arch Clin Exp Ophthalmol* 2016;254:515-22
19. Birbal RS, Tong CM, Dapena I, et al. Clinical outcomes of Descemet membrane endothelial keratoplasty in eyes with a glaucoma drainage device. *Am J Ophthalmol* 2019;199:150-8
20. Woo JH, Ang M, Htoon HM, Tan DT. Descemet membrane endothelial keratoplasty versus Descemet stripping automated endothelial keratoplasty and penetrating keratoplasty. *Am J Ophthalmol* 2019;207:288-303
21. Morishige N, Sonoda KH. Bullous keratopathy as a progressive disease: evidence from clinical and laboratory imaging studies. *Cornea* 2013;32 Suppl 1:S77-83
22. Fajgenbaum MAP, Kopsachilis N, Hollick EJ. Descemet's membrane endothelial keratoplasty: surgical outcomes and endothelial cell count modelling from a UK centre. *Eye* 2018;32:1629-35
23. Heinzelmann S, Maier P, Böhringer D, Hüther S, Eberwein P, Reinhard T. Cystoid macular oedema following Descemet membrane endothelial keratoplasty. *Br J Ophthalmol* 2015;99:98-102
24. Laaser K, Bachmann BO, Horn FK, Cursiefen C, Kruse FE. Descemet membrane endothelial keratoplasty combined with phacoemulsification and intraocular lens implantation: advanced triple procedure. *Am J Ophthalmol* 2012;154:47-55
25. Chaurasia S, Price FW Jr, Gunderson L, Price MO. Descemet's membrane endothelial keratoplasty: clinical results of single versus triple procedures (combined with cataract surgery). *Ophthalmology* 2014;121:454-8
26. Dapena I, Ham L, Tabak S, Balachandran C, Melles GR. Phacoemulsification after Descemet membrane endothelial keratoplasty. *J Cataract Refract Surg* 2009;35:1314-5
27. Musa FU, Cabrerizo J, Quilendrino R, Dapena I, Ham L, Melles GR. Outcomes of phacoemulsification after Descemet membrane endothelial keratoplasty. *J Cataract Refract Surg* 2013;39:836-40
28. Burkhart ZN, Feng MT, Price FW Jr, et al. One-year outcomes in eyes remaining phakic after Descemet membrane endothelial keratoplasty. *J Cataract Refract Surg* 2014;40:430-4
29. Gundlach E, Maier AK, Tsangaridou MA, et al. DMEK in phakic eyes: targeted therapy or highway to cataract surgery? *Graefes Arch Clin Exp Ophthalmol* 2015;253:909-14
30. Siggel R, Heindl LM, Cursiefen C. Descemet membrane endothelial keratoplasty (DMEK) in phakic eyes with shallow anterior chamber. *Graefes Arch Clin Exp Ophthalmol* 2015;253:817-9
31. Tong CM, Baydoun L, Melles GRJ. Descemet membrane endothelial keratoplasty and refractive surgery. *Curr Opin Ophthalmol* 2017;28:316-25
32. Godin MR, Boehlke CS, Kim T, Gupta PK. Influence of lens status on outcomes of Descemet membrane endothelial keratoplasty. *Cornea* 2019;38:409-12

33. Yeh RY, Quilendrino R, Musa FU, Liarakos VS, Dapena I, Melles GR. Predictive value of optical coherence tomography in graft attachment after Descemet's membrane endothelial keratoplasty. *Ophthalmology* 2013;120:240–5
34. Gerber-Hollbach N, Baydoun L, Fernandez-Lopez E, et al. Clinical outcome of rebubbling for graft detachment after Descemet membrane endothelial keratoplasty. *Cornea* 2017;36:771–6

Birbal RS[1-3], Ní Dhubhghaill S[1,2], Bourgonje VJA[1,2], Hanko J[1], Ham L[1-3], Jager MJ[4], Böhringer S[5], Oellerich S[1] and Melles GRJ[1-3]

[1] Netherlands Institute for Innovative Ocular Surgery (NIIOS), Rotterdam, The Netherlands

[2] Melles Cornea Clinic, Rotterdam, The Netherlands

[3] Amnitrans EyeBank, Rotterdam, The Netherlands

[4] Department of Ophthalmology, Leiden University Medical Center, Leiden, The Netherlands

[5] Department of Biomedical Data Sciences, Leiden University Medical Center, Leiden, The Netherlands

Chapter 4

Five-Year Graft Survival and Clinical Outcomes after Descemet Membrane Endothelial Keratoplasty: Results of the First 500 Consecutive Cases

Cornea 2020;39:290-7

ABSTRACT

Purpose: To report the five-year graft survival and clinical outcomes after Descemet membrane endothelial keratoplasty (DMEK).

Methods: A retrospective, interventional case series was performed at a tertiary referral center. Five hundred eyes of 393 patients that underwent DMEK for Fuchs endothelial corneal dystrophy, bullous keratopathy, failed previous corneal transplants other than DMEK or other indications were evaluated for graft survival, best-corrected visual acuity (BCVA), endothelial cell density, postoperative complications, and retransplantation rate.

Results: Kaplan-Meier analysis demonstrated an estimated survival probability of 0.90 [95% Confidence Interval (CI), 0.87-0.94] for the entire cohort at 5 years after DMEK. At this time-point, 82% of the eyes achieved a BCVA of ≥20/25 (0.8), 54% achieved ≥20/20 (1.0) and 16% achieved ≥20/17 (1.2). BCVA continued to improve from 6 to 36 months after DMEK-surgery ($P \leq 0.005$) and then remained stable up to 60 months postoperatively ($P > 0.08$). Preoperative donor endothelial cell density averaged 2530 (±210) cells/mm^2 and decreased by 37% at 6 months, 40% at 1 year, and 55% at 5 years after DMEK-surgery ($P < 0.001$ between all follow-up time points). During the study period, allograft rejection episodes developed in 2.8% of the eyes, primary graft failure occurred in 0.2% and secondary graft failure in 2.8% of the eyes. Re-keratoplasty was required in 8.8% of the eyes.

Conclusions: Five-year graft survival after DMEK is high, and visual acuity outcomes remain excellent and are accompanied by a low longer-term complication rate.

INTRODUCTION

Descemet membrane endothelial keratoplasty (DMEK) has gained popularity worldwide and may become the gold standard in the management of corneal endothelial disorders.[1-3] By replacing only the diseased innermost corneal layers, this technique yields unprecedented visual outcomes with low complication rates.[4-8] As DMEK numbers increase globally, examining and reporting mid- and long-term outcomes of large cohorts becomes important and may help in refining the current technique and in determining expectations, especially in comparison with other keratoplasty techniques. However, so far, only few longer-term DMEK studies are available.[8-11]

We previously reported the 6- and 24-month clinical results of the first 500 consecutive eyes that underwent DMEK at our institute (excluding the very first 25 cases representing the technique learning curve).[6,7] The aim of the current study is to provide an overview of the extended clinical results of this cohort up to 5 years postoperatively, with a particlar focus on graft survival. Secondary to these analyses, we evaluated parameters that may influence outcomes after DMEK.

METHODS

Patient data

Five hundred consecutive eyes of 393 patients [mean age 68 (±12) years; range, 20-96 years] underwent DMEK for Fuchs endothelial corneal dystrophy (FECD; 89.2%), bullous keratopathy (BK; 6.4%), a failed previous corneal transplant other than DMEK (3.2%) or other indications (1.2%) (Table 1) and were retrospectively evaluated. The 500 cases evaluated were cases 26 to 525 from a total of 525 consecutive DMEK surgeries performed in our clinic between October 2007 and September 2012. The first 25 DMEK cases (cases 1-25), that represent the very first 25 DMEK cases performed worldwide and also the learning curve of this technique, were excluded from this study. Additional patient and donor demographics are reported in Table 1. All patients signed an institutional review board-approved informed consent form before surgery, and the study adhered to the tenets of the Declaration of Helsinki.

Table 1: Demographics Descemet membrane endothelial keratoplasty eyes and donors.

		(n)
Number of eyes/patients	500/393	(213/180)
Sex (female/male)	54%/46%	
Mean age (±SD) in years	68 (±12)	
Indication for DMEK		
FECD	89.2%	(446)
BK (pseudophakic, aphakic, phakic IOL)	6.4%	(32)
Failed PKP/DSEK/DSAEK/PLK	3.2%	(16)
Other (corneal dystrophies, BK due to congenital glaucoma, corneal decompensation due to trauma)	1.2%	(6)
Preoperative lens status		
Pseudophakic	74.8%	(374)
Phakic	24.8%	(124)
Aphakic	0.4%	(2)
Diabetes Mellitus	14.2%	(56)
Donor age (±SD) in years	65 (±10)	
Donor sex (female/male)	39%/61%	(194/306)
Donor death cause		
Cancer	25.2%	(126)
Cardiovascular/stroke	51.4%	(257)
Respiratory	16.2%	(81)
Trauma	2.4%	(12)
Other	4.8%	(24)
Total graft storage time in medium (±SD) in days	13.5 (±4)	

SD: Standard deviation
FECD: Fuchs endothelial corneal dystrophy
BK: Bullous keratopathy
PKP: Penetrating keratoplasty
DSAEK: Descemet stripping automated endothelial keratoplasty
DSEK: Descemet stripping endothelial keratoplasty
PLK: Posterior lamellar keratoplasty
DMEK: Descemet membrane endothelial keratoplasty

DMEK graft preparation and surgery

Donor tissue preparation at Amnitrans EyeBank Rotterdam was performed using the traditional and/ or standardized '*no-touch*' technique, as previously described.[12,13] Endothelial cell morphology and viability were evaluated before and after graft preparation. DMEK grafts were then stored in organ culture medium (CorneaMax; Eurobio, Courtaboeuf, France) until the time of transplantation; mean graft storage time was 13.5 (±4) days (Table 1).

DMEK surgery was performed based on the standardized '*no-touch'* DMEK technique in a single center, as reported before,[14] that is, the standardized technique was not implemented completely for the first 250 eyes of the study

group, whereas for the second 250 cases, it was fully applied.[6] The postoperative topical medication protocol consisted of chloramphenicol 0.5% 6 times daily for the first postoperative week tapered to twice daily for the second postoperative week and ketorolac tromethamine 0.4% and dexamethasone 0.1% 4 times daily for 4 weeks, which was switched to fluorometholone 0.1% 4 times daily at the 1- month visit. Fluorometholone was then gradually tapered to once daily at 9 months postoperatively. Twelve months after the DMEK, patients were advised to continue using fluorometholone once daily or every other day indefinitely.

Data collection and statistical analysis

Patients were evaluated preoperatively, at 6 and 12 months and then yearly, up to 5 years after DMEK. Central corneal thickness (CCT) was measured by rotating Scheimpflug corneal tomography (Pentacam HR, Oculus Optikgeräte GmbH, Wetzlar, Germany). Best-corrected visual acuity (BCVA) was assessed using a Snellen letter chart and is reported as best-spectacle-corrected visual acuity, except for 3 eyes at the 5-year follow-up for which only contact-lens corrected visual acuity was available. Endothelial cell density (ECD) was evaluated *in vivo* using a Topcon SP3000p non-contact autofocus specular microscope (Topcon Medical Europe BV, Capelle a/d IJssel, The Netherlands). For ECD counting, the commercial software of the specular microscope (ImageNet software, Topcon Medical Europe) was used and the automatically delineated cell borders were checked, and when incorrectly assigned, the cell borders were manually re-assigned by a trained technician. For each follow-up the results of 3 ECD measurements were averaged.

Outcome parameters (BCVA, ECD, CCT, postoperative complications, retransplantation rate) are presented for all eyes with available follow-up data. The only exception was BCVA analysis, for which eyes with a low visual potential due to ocular co-morbidities unrelated to the cornea were excluded. The percentage of eyes with low visual potential did not exceed 11.8% of the study group at any included follow-up time point. BCVA outcomes were converted to the logarithm of the minimum angle of resolution (LogMAR) units for statistical analysis. When examining the influence of graft detachment, minor graft detachment was defined as a detachment ≤1/3 of the graft surface area and major graft detachment as a detachment >1/3 of the graft surface area. Allograft rejection was defined as the presence of an endothelial rejection line or keratic precipitates, with or without an increase in corneal thickness, anterior uveitis, and/ or ciliary injection on slit-lamp examination. Primary graft

failure (PGF) was defined as a cornea that failed to clear in the presence of an attached graft, while secondary graft failure (SGF) was defined as corneal decompensation after an initial period of a functional graft after DMEK.

Regarding statistical analysis, second eyes of patients undergoing bilateral DMEK (n=107) were excluded from the linear mixed model and survival analysis. Kaplan-Meier survival analysis was performed using SPSS 25.0 (SPSS Inc, Chicago, IL) to estimate the cumulative success probability of graft survival. All primary and secondary graft failures as well as retransplantations performed for graft detachment (technical failures)[15] were included as failures in the survival analysis. Log-rank tests were applied to test for equality of survival distributions of the different subgroups. Outliers were detected by visual inspection of histograms (baseline variables) and individual trajectories (outcomes). The influence of variables such as patient age, patient sex, lens status, surgery indication, graft storage time, intraoperative complications, graft adherence status, donor death cause, patient diabetes mellitus status, and donor age on ECD, BCVA and CCT was analyzed using linear mixed models with a random intercept and slope. *P* values were calculated using Wald tests. Mixed models were analyzed with package *lme4* using R version 3.5.0. All eyes were included for descriptive analysis, and analysis was performed using SPSS 25.0 and Excel Software for Windows.

RESULTS

Graft Survival

Kaplan-Meier survival analysis showed an estimated survival probability of 0.90 [95% CI, 0.87-0.94] for the entire cohort at 5 years after DMEK surgery (Table 2, Fig. 1).

The second group of 250 eyes undergoing DMEK surgery (0.94 [95% CI, 0.90-0.98]) showed a higher survival probability than the first group of 250 eyes undergoing DMEK surgery (0.88 [95% CI, 0.84-0.92]) ($P = 0.033$). Eyes operated on for FECD showed higher survival probabilities (0.93 [95% CI, 0.90-0.96]) than eyes treated for all other indications than FECD (0.72 [95% CI, 0.58-0.86]) ($P < 0.001$). Analysis based upon graft adherence status showed survival probabilities of 0.95 [95% CI, 0.93-0.98], 0.91 [95% CI, 0.81-1.01] and 0.27 [95% CI, 0.08-0.36] for fully attached grafts, grafts with a detachment of ≤1/3 of the graft surface area and graft with a detachment of >1/3 of the graft

Table 2. Cumulative Survival Probability after Descemet Membrane Endothelial Keratoplasty.

A - Total group	**Time (months)**		**0**	**6**	**12**	**24**	**36**	**48**	**60**
	Cumulative survival probability at FU	Estimate	.	0.98	0.95	0.94	0.92	0.91	0.90
		SE	.	0.01	0.01	0.01	0.02	0.02	0.02
	Cumulative events		0	9	19	24	30	33	34
	Remaining cases		393	375	355	327	297	276	250
B – First versus Second group of DMEK surgeries	**Time (months)**		**0**	**6**	**12**	**24**	**36**	**48**	**60**
1st Group	Cumulative survival probability at FU	Estimate	.	0.96	0.92	0.91	0.89	0.89	0.88
		SE	.	0.01	0.02	0.02	0.02	0.02	0.02
	Cumulative events		0	9	18	20	24	25	26
	Remaining cases		235	221	205	191	171	159	144
2nd Group	Cumulative survivals probability at FU	Estimate	.	.	0.99	0.97	0.96	0.94	0.94
		SE	.	.	0.01	0.01	0.02	0.02	0.02
	Cumulative events		0	0	1	4	6	8	8
	Remaining cases		158	154	150	136	126	117	106
C – Surgery indication (FECD vs. All other indications)	**Time (months)**		**0**	**6**	**12**	**24**	**36**	**48**	**60**
FECD	Cumulative survival probability at FU	Estimate	.	0.98	0.96	0.95	0.94	0.93	0.93
		SE	.	0.01	0.01	0.01	0.01	0.01	0.02
	Cumulative events		0	7	12	15	19	21	22
	Remaining cases		344	330	317	294	268	249	227
All other indication	Cumulative survival probability at FU	Estimate	.	0.96	0.85	0.80	0.75	0.72	0.72
		SE	.	0.03	0.05	0.06	0.07	0.07	0.07
	Cumulative events		0	2	7	9	11	12	12
	Remaining cases		49	45	38	33	29	27	23
D – Graft adherence status (Attached vs. Partially detached)	**Time (months)**		**0**	**6**	**12**	**24**	**36**	**48**	**60**
Attached	Cumulative survival probability at FU	Estimate	.	0.98	0.98	0.97	0.96	0.96	0.95
		SE	.	0.01	0.01	0.01	0.01	0.01	0.01
	Cumulative events		0	8	8	10	12	13	14
	Remaining cases		330	313	306	284	260	242	219
Detachment ≤1/3	Cumulative survival probability at FU	Estimate	.	.	0.97	0.94	0.91	0.91	0.91
		SE	.	.	0.03	0.04	0.05	0.05	0.05
	Cumulative events		0	0	1	2	3	3	3
	Remaining cases		38	38	35	32	29	28	26
Detachment >1/3	Cumulative survival probability at FU	Estimate	.	0.96	0.58	0.49	0.36	0.27	0.27
		SE	.	0.04	0.10	0.10	0.10	0.09	0.09
	Cumulative events		0	1	10	12	15	17	17
	Remaining cases		25	24	14	11	8	6	5

Cumulative graft survival probability is given for (A) the total study group and (B-D) divided into subgroups based on (B) first vs. the second group of surgeries; (C) surgery indication and (D) graft attachment status. In case of bilateral DMEK, only primary eyes were included for the survival analysis. (FU= follow-up, SE= standard error).

surface area [fully attached vs. ≤1/3 detached (P = 0.33); attached vs. >1/3 detached (P < 0.001), and ≤1/3 vs. >1/3 detached (P < 0.001)] (Fig. 1, Table 2).

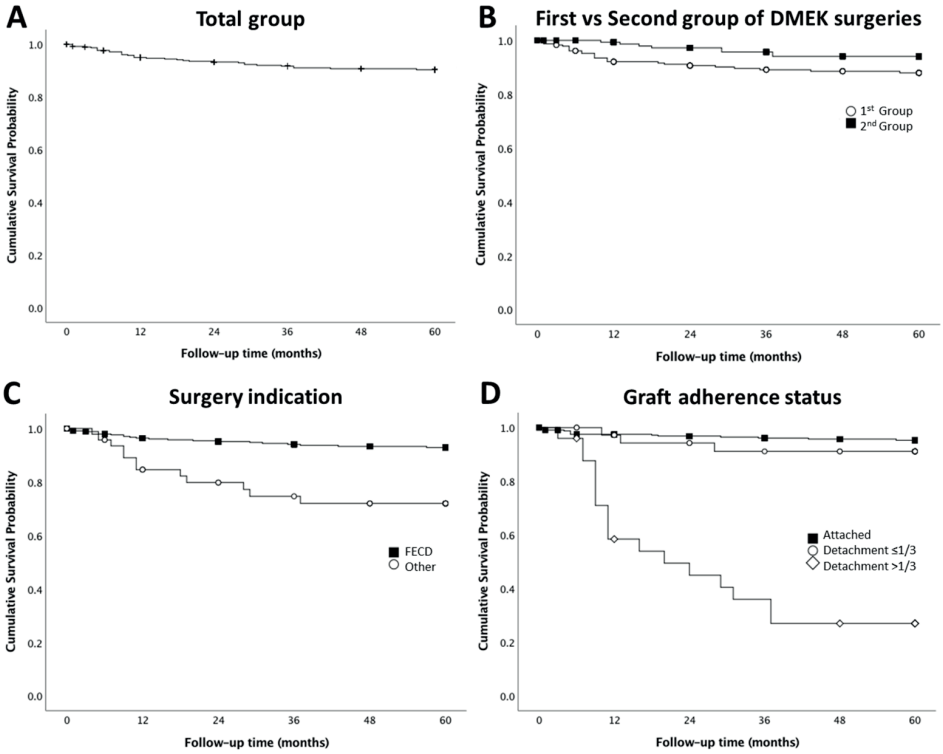

Figure 1. Kaplan-Meier curves showing the cumulative survival probabilities for Descemet membrane endothelial keratoplasty eyes.
Kaplan-Meier curves are shown for (A) the entire study group, (B) for the first 250 versus the second 250 operated Descemet membrane endothelial keratoplasty (DMEK) eyes, (C) for eyes operated on for FECD versus eyes operated on for all indications other than FECD, and (D) for eyes with completely attached grafts versus eyes with either a detachment of ≤1/3 of the graft surface area or eyes with a detachment of >1/3 of the graft surface area. Survival probabilities and number of eyes at risk per follow-up time-point are listed in Table 2.

Visual Outcome

At 5 years after DMEK, 82% of the eyes achieved a BCVA of ≥20/25 (0.8), 54% achieved ≥20/20 (1.0), and 16% achieved ≥20/17 (1.2) (Table 3, Fig. 2). BCVA improved from 6 to 36 months after DMEK surgery ($P \leq 0.005$) and then remained stable up to 60 months postoperatively (P >0.08 for time).

Table 3. Best-corrected visual acuity, endothelial cell density, and pachymetry results after Descemet membrane endothelial keratoplasty.

Clinical outcomes	Preoperative	At 6-months follow-up	At 12-months follow-up	At 24-months follow-up	At 36-months follow-up	At 48-months follow-up	At 60-months follow-up
BCVA in Snellen (Decimal)	(n=451)	(n=418)	(n=396)	(n=360)	(n=329)	(n=306)	(n=278)
< 20/40 (< 0.5)	59.9%	6.0%	2.2%	1.6%	1.8%	1.6%	1.4%
≥ 20/40 (≥ 0.5)	40.1%	94.0%	97.8%	98.4%	98.2%	98.4%	98.6%
≥ 20/25 (≥ 0.8)	8.0%	75.1%	80.1%	81.6%	84.2%	81.8%	82.4%
≥ 20/20 (≥ 1.0)	1.3%	41.1%	48.3%	51.5%	52.3%	48.1%	53.6%
≥ 20/17 (≥ 1.2)	-	12.9%	14.7%	15.6%	18.2%	16.6%	15.5%
Mean BCVA (±SD), (logMAR)	0.49 (±0.39)	0.11 (±0.27)	0.06 (±0.15)	0.05 (±0.12)	0.05 (±0.13)	0.06 (±0.17)	0.05 (±0.12)
Endothelial cell density (ECD)	(n=456)	(n=447)	(n=427)	(n=392)	(n=360)	(n=334)	(n=303)
Mean ECD (±SD), (cells/mm^2)	2530 (±210)	1600 (±490)	1530 (±488)	1400 (±491)	1310 (±499)	1210 (±483)	1140 (±465)
ECD Decrease (±SD), (%)*		37 (±18)	40 (±18)	45 (±18)	49 (±18)	52 (±18)	55 (±17)
Central corneal thickness (CCT)	(n=425)	(n=428)	(n=423)	(n=378)	(n=351)	(n=327)	(n=297)
Mean CCT (±SD), (μm)	667 (±92)	525 (±46)	527 (±40)	534 (±43)	534 (±39)	537 (±43)	539 (±45)
CCT Decrease (±SD), (%)*		20 (±11)	20 (±10)	19 (±10)	20 (±10)	20 (±10)	19 (±10)

*Decrease as compared to preoperative values
BCVA: Best-corrected visual acuity
SD: Standard deviation

Parameters correlated with changes in visual acuity (in logMAR) up to 60 months after DMEK were surgical indication and graft attachment status ($P < 0.05$) (Table 4). Eyes with FECD as surgical indication achieved better visual acuity levels than eyes with other indications than FECD or BK, on average 0.11 on the logMAR scale ($P = 0.004$). Eyes with completely attached DMEK grafts attained better visual acuity outcomes than eyes with a partial graft detachment > 1/3 of the graft surface area, approximately 0.43 on the logMAR scale ($P < 0.001$). No significant difference in 5-year BCVA was observed for FECD versus BK eyes nor for eyes with completely attached grafts versus eyes with ≤ 1/3 graft detachment. These results were not affected when only eyes that had BCVA data at all follow-ups available were analyzed.

Table 4. Effects of the covariates from the linear mixed models on clinical outcome after Descemet membrane endothelial keratoplasty. Effects of covariates was analyzed for outcomes visual acuity (logMar), endothelial cell density and pachymetry for all eyes included in the statistical analysis (n=393).

	BCVA (logMAR)			**ECD ***			**Pachymetry**		
	Coeff.	SE	*P*-value	Coeff.	SE	*P*-value	Coeff.	SE	*P*-value
Intercept	-0.07	0.06	0.2656	2216.32	216.36	<0.0001	553.96	15.60	<0.0001
Patient Age (years)	0.00	0.00	0.0614	-4.57	2.47	0.0644	-0.38	0.21	0.0666
Sex (female vs. male)	0.02	0.02	0.3232	-56.41	43.80	0.1978	**-9.29**	**3.88**	**0.0166**
Lens status (phakic vs. pseudophakic)	-0.02	0.02	0.3135	**-127.41**	**63.07**	**0.0434**	-10.12	5.49	0.0654
Indication (BK vs. FECD)	-0.00	0.03	0.8888	**-293.76**	**93.87**	**0.0018**	7.02	8.32	0.3991
Indication ('other' vs. FECD)	**0.11**	**0.04**	**0.0042**	-120.92	118.64	0.3081	**55.41**	**17.80**	**0.0018**
Patient Diabetes mellitus (yes vs. no)	0.02	0.03	0.4820	42.83	72.66	0.5556	12.74	6.68	0.0566
Intraoperative complications (yes vs. no)	-0.03	0.02	0.2522	-74.85	64.06	0.2427	0.23	5.64	0.9668
Detachment (≤1/3 vs. attached)	0.03	0.03	0.3396	**-374.52**	**74.85**	**<0.0001**	6.21	6.54	0.3422
Detachment (>1/3 vs. attached)	**0.43**	**0.03**	**<0.0001**	**-291.78**	**114.66**	**0.0109**	**50.23**	**9.30**	**<0.0001**

BCVA:	Best-corrected visual acuity	Coeff.:	Regression coefficients fixed effects
ECD:	Endothelial cell density	SE:	Standard error
BK:	Bullous keratopathy	≤1/3:	Detachment of ≤1/3 of the graft surface area
FECD:	Fuchs endothelial corneal dystrophy		
'Other':	All surgery indications other than BK and FECD	>1/3:	Detachment of >1/3 of graft surface area

* For ECD, additional parameters including donor age (years), donor death cause (cancer vs. cardiovascular, respiratory vs. cardiovascular, trauma vs. cardiovascular, other vs. cardiovascular) and graft storage time (days) were evaluated. Of these parameters, only graft storage time (Coeff.=-12.09, SE=5.30, ***P*=0.0224**) was related to changes in ECD.
Bold numbers, statistically significant P values (P<0.05)

Endothelial cell density

Donor ECD averaged 2530 (±210) cells/mm^2 preoperatively and decreased to 1600 (±490) cells/mm^2 (-37%) at 6 months , 1530 (±488) cells/mm^2 (-40%) at 1 year, and 1140 (±465) cells/mm^2 (-55%) at 5 years after DMEK surgery (Table 3, Fig. 2). After the initial sharp decline in ECD observed in the first 6 months after DMEK, ECD values gradually continued to decrease. From 1 year after surgery, an annual ECD decrease rate of approximately 7% was observed. The ECD decrease was significant between all follow-up time points from 6 to 60 months after DMEK ($P < 0.001$).

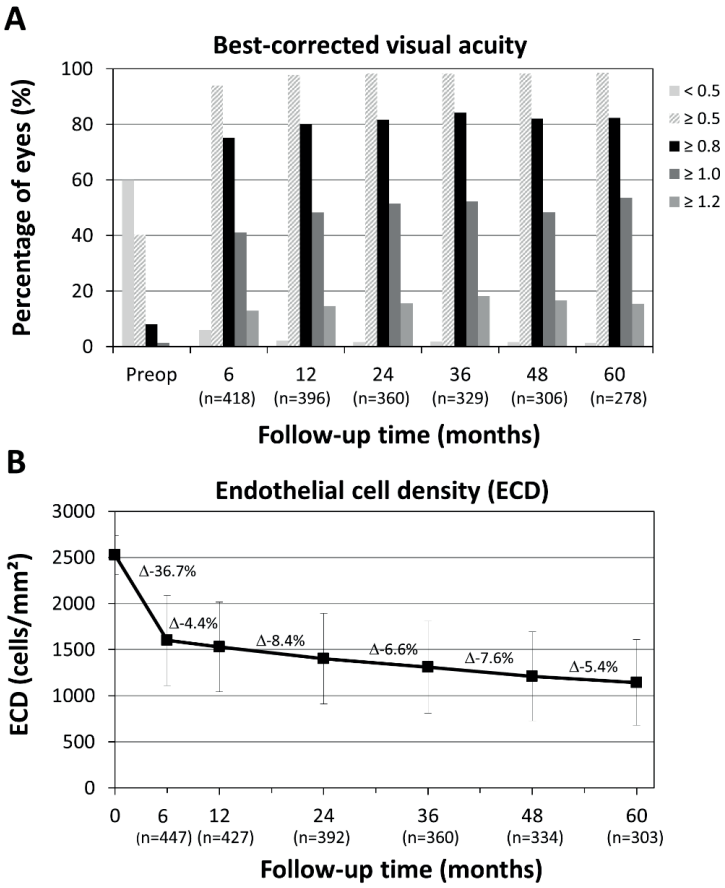

Figure 2. Graphs showing the best-corrected visual acuity and endothelial cell density outcome up to five years after Descemet membrane endothelial keratoplasty.
(A) Bar graphs displaying the percentage of eyes reaching best-corrected visual acuity (BCVA) levels (in decimal) as listed in the legend to the right. (B) Average endothelial cell density (ECD). Vertical bars represent standard deviations and percentages between follow-up time-points indicate the ECD decrease between these time-points.

Parameters associated with ECD outcomes included preoperative lens status, surgical indication, graft adherence status, and graft storage time (Table 4). Phakic recipient eyes had reduced ECD outcomes compared with pseudophakic recipient eyes (P = 0.04), and eyes operated on for BK had lower ECD outcomes compared with eyes operated on for FECD (P = 0.002). Analysis of graft adherence status revealed that eyes with completely attached DMEK grafts attained better ECD outcomes than eyes with a partial graft detachment ≤ 1/3 of the graft surface area (P < 0.001) or > 1/3 of the graft surface area (P = 0.01). Eyes receiving grafts with longer storage times had slightly reduced ECD outcomes compared with eyes receiving grafts within a shorter storage time (P = 0.02) (Table 4).

Pachymetry

Mean CCT improved from 667 (±92) µm before DMEK to 525 (±46) µm (-20%) at 6 months, 527 (±40) µm (-20%) at 1 year, and 539 (±45) µm (-19%) at 5 years after surgery (Table 3). Corneal thickness increased between 6 and 60 months after DMEK (P < 0.001). Parameters correlated with CCT outcomes included patient sex, surgery indication and graft attachment status (Table 4).

Postoperative complications and Retransplantation

A clinically proven allograft rejection episode occurred in 2.8% (n=14) of the entire study group during the 5-year study period. Two of these eyes (0.4%) developed allograft rejection after the patients had stopped using fluorometholone, and rejection was managed by restarting corticosteroids, whereas the other eyes (2.4%, n=12) developed rejection under corticosteroid use; of those, 1.6% (n=8) were successfully managed by applying an intensified corticosteroid regimen, while 0.8% (n=4) eventually required re-DMEK. Primary graft failure occurred in one eye (0.2%) and secondary graft failure in 2.8% (n=14) of the eyes, which included 4 eyes with a previous allograft rejection episode; 1.4% (n=7) of the eyes developed secondary graft failure within the first 2 years after surgery and the other 1.4% (n=7) after the second postoperative year. Out of 124 phakic DMEK eyes, 16.9% (n=21) underwent phacoemulsification cataract surgery within the study period.

Repeated keratoplasty was required in 8.8% (n=44) of all eyes [5.8% re-DMEK; 2.8% secondary DSEK; 0.2% secondary penetrating keratoplasty] and the majority of retransplantations were performed within 2 years after primary DMEK (6.4%, n=32). Indications for retransplantation included significant graft detachment (n=31), primary graft failure (n=1) and secondary graft failure (n=12).

Two eyes with a secondary graft failure did not undergo retransplantation within the study period.

DISCUSSION

The current study evaluated the 5-year graft survival and clinical outcomes of the first cohort to ever receive DMEK, excluding the initial learning curve cases, and also analyzed which parameters may influence these outcomes. Overall, our study confirms that DMEK continues to provide excellent clinical results up to 5 years postoperatively with high graft survival rates, in particular for eyes operated on for FECD and after technique standardization.

With an overall 90% cumulative graft survival rate achieved at 5 years after DMEK, our DMEK cohort had a slightly lower graft survival probability than the previously reported 93% and 96% DMEK graft survival rates.[8,10] This slight discrepancy may be on the one hand due to the fact that one of the previous studies only included FECD eyes,[10] that tend to have better survival probabilities than eyes with other surgery indications (as shown for our cohort here, with a 93% survival rate for FECD eyes only vs. 72% for other indications). On the other hand, because this is the first DMEK cohort ever, it is important to realize that these results still include a technique learning curve effect, even after excluding the very first 25 DMEK cases, which is reflected by the higher survival probability for the second 250 DMEK cases versus the first 250 cases (88% vs. 94%). This learning curve effect is also reflected by the fact that most eyes with a graft detachment of >1/3 of the graft surface area are part of the first 250 eyes (4.4% vs. 2.4%).[6] For these eyes, significantly lower survival probabilities were observed than for eyes with completely attached grafts or only small detachments, corroborating the beneficial effect of an early re-bubbling procedure. While in the first years after introducing DMEK, we often avoided performing a re-bubbling procedure in eyes with a partial graft detachment, as some corneas may show spontaneous corneal clearance or graft attachment, we nowadays usually await the 1-week follow-up before deciding for a repeat air injection,[16] and perform the procedure at its latest 6 to 8 weeks after DMEK.[17]

When comparing DMEK graft survival rates with those reported for Descemet stripping automated endothelial keratoplasty (DSAEK/DSEK) and penetrating keratoplasty (PK), which vary from 76 to 97%[18-23] and 67 to 93%,[21,24] re-

spectively, DMEK has demonstrated to provide at least similar survival rates. When hypothesizing that improved outcomes may be attributed to technique standardization and increased surgical experience, DMEK may surpass graft survival of DSAEK/DSEK and PK in the longer term.

In regard to BCVA, this study confirms that the excellent visual outcomes achieved at 6 months after DMEK are maintained until at least 5 years postoperatively. In contrast to our previous results,[7,9] continued BCVA improvement was observed from 6 to 36 months postoperatively. This may be attributed to a selection bias, as especially the elderly patients, who tend to have lower BCVA outcomes, are withdrawing from continuous follow-up, whereas younger patients are more consistently attending follow-up visits. Furthermore, unlike the 2-year BCVA results, 5-year BCVA results did not differ between FECD and BK eyes and also not between eyes with a completely attached graft and eyes with a ≤1/3 graft detachment.[7]

At 5 years after DMEK, ECD had decreased by approximately 55%, of which the main decrease was observed within the first 6 months after surgery. ECD decrease showed a similar course as after DSAEK/DSEK,[19-21,23] but a slower and more favorable decrease when compared with after PK.[25,26] With longer follow-up data for larger study groups, available in the near future, it will be interesting to analyze whether ECD will decrease linearly or exponentially and how this may impact long-term graft survival. Similar to our previous studies, main parameters associated with 5-year ECD outcomes included preoperative lens status, surgery indication, and graft adherence.[6,7]

The overall postoperative complication rate remained relatively low throughout the study period. As reported previously, partial graft detachment was the main early postoperative complication, whereas allograft rejection and secondary graft failure constituted the more severe complications in the later postoperative period.[6,7] With longer follow-up times available, the cumulative allograft rejection rate after DMEK now exceeds the initially reported rejection rate of approximately 1%, but is still lower than 5-year rates reported for DSAEK/DSEK and PK, 5.0 to 7.9%[18,21]and 14.1%,[21] respectively. In a recent study, Price et al. showed that even though rejection episodes were associated with increased ECD loss, they were not a risk factor for graft failure. The latter may be due to the fact that allograft rejection episodes after DMEK tend to be milder than with the other forms of keratoplasty and can usually be managed with an intensified corticosteroid regimen. Secondary graft failure occurred in

a similar percentage as reported for other DMEK studies[8] but in a lower rate than after DSAEK/DSEK and PK.[18-20,23,22,27] With an average annual graft failure rate of approximately 0.5% after the second postoperative year, failure rates after DMEK remain low up to the 5-year follow-up. For future longer-term studies, it will be important to see how these rates evolve, particularly when eyes approach the 500 cell/mm^2 ECD threshold.

Limitations of this study include the retrospective nature of the study and the increasing number of patients being lost to follow-up at longer follow-up time-points. However, when comparing our study with other DMEK studies with 5-year follow-up, we can still include a relatively high number of eyes at each follow-up time-point.[8,10,28]

In conclusion, DMEK yields favorable graft survival rates and provides fast and near-complete visual rehabilitation that is maintained up to at least 5 years postoperatively and that is accompanied by a low complication and retransplantation rate.

REFERENCES

1. Deng SX, Lee WB, Hammersmith KM, et al. Descemet membrane endothelial keratoplasty: Safety and outcomes. A report by the American Academy of Ophthalmology. *Ophthalmology* 2018;125:295-301
2. Oellerich S, Baydoun L, Peraza-Nieves J, et al. Multicenter study of 6-month clinical outcomes after Descemet membrane endothelial keratoplasty. *Cornea* 2017;36:1467-76
3. Flockerzi E, Maier P, Böhringer D, et al; all German Keratoplasty Registry Contributors. Trends in corneal transplantation from 2001 to 2016 in Germany: A report of the DOG-Section Cornea and its keratoplasty registry. *Am J Ophthalmol* 2018;188:91-8
4. Hamazaoglu EC, Straiko MD, Mayko ZM, et al. The first 100 of standardized Descemet stripping automated endothelial keratoplasty versus standardized Descemet membrane endothelial keratoplasty. *Ophthalmology* 2015;122:2193-9
5. Schrittenlocher S, Schaub F, Hos D, et al. Evolution of consecutive Descemet membrane endothelial keratoplasty outcomes throughout a 5-year period performed by two experienced surgeons. *Am J Ophthalmol* 2018;190:171-8
6. Rodríguez-Calvo-de-Mora M, Quilendrino R, Ham L, et al. Clinical outcome of 500 consecutive cases undergoing Descemet's membrane endothelial keratoplasty. *Ophthalmology* 2015;122:464-70
7. Peraza-Nieves J, Baydoun L, Dapena I, et al. Two-year clinical outcome of 500 consecutive cases undergoing Descemet membrane endothelial keratoplasty. *Cornea* 2017;36:655-60
8. Schlögl A, Tourtas T, Kruse FE, et al. Long-term clinical outcome after Descemet membrane endothelial keratoplasty. *Am J Ophthalmol* 2016;169:218-226
9. Ham L, Dapena I, Liarakos VS, et al. Mid-term results of Descemet membrane endothelial keratoplasty (DMEK):4 to 7 years clinical outcome. *Am J Ophthalmol* 2016;171:113-21
10. Price DA, Kelly M, Price FWjr, et al. Five-year graft survival of Descemet membrane endothelial keratoplasty (EK) versus Descemet stripping EK and the effect of donor sex matching. *Ophthalmology* 2018;125:1508-14
11. Baydoun L, Ham L, Borderie V, et al. Endothelial graft survival after Descemet membrane endothelial keratoplasty: effect of surgical indication and graft adherence status. *JAMA Ophthalmol* 2015;133:1277-85
12. Groeneveld-van Beek EA, Lie JT, van der Wees J, et al. Standardized 'no-touch' donor tissue preparation for DALK and DMEK: harvesting undamaged anterior and posterior transplants from the same donor cornea. *Acta Ophthalmol* 2013;91:145-50
13. Lie JT, Birbal R, Ham L, et al. Donor tissue preparation for Descemet membrane endothelial keratoplasty. *J Cataract Refract Surg* 2008;34:1578-83
14. Dapena I, Moutsouris K, Droutsas K, et al. Standardized "no-touch" technique for Descemet membrane endothelial keratoplasty. *Arch Ophthalmol* 2011;129:88-94
15. Baydoun L, Melles GRJ. Refining the terminology of graft failure in reports on endothelial keratoplasty outcomes. *JAMA Ophthalmology* 2016;134:125-26
16. Yeh RY, Quilendrino R, Musa FU, et al. Predictive value of optical coherence tomography in graft attachment after Descemet's membrane endothelial keratoplasty. *Ophthalmology* 2013;120:240-5

17. Gerber-Hollbach N, Baydoun L, Fernandez-Lopez E, et al. Clinical outcome of rebubbling for graft detachment after Descemet membrane endothelial keratoplasty. *Cornea* 2017;36:771-6
18. Price MO, Fairchild KM, Price DA, et al. Descemet's stripping endothelial keratoplasty five-year graft survival and endothelial cell loss. *Ophthalmology* 2011;118:725-9
19. Ratanasit A, Gorovoy MS. Long-term results of Descemet stripping automated endothelial keratoplasty. *Cornea* 2011;30:1414-8
20. Wacker K, Baratz KH, Maguire LJ, et al. Descemet stripping endothelial keratoplasty for Fuchs' endothelial corneal dystrophy: Five-year results of a prospective study. *Ophthalmology* 2016;123:154-60
21. Ang M, Soh Y, Htoon HM, et al. Five-year graft survival comparing Descemet stripping automated endothelial keratoplasty and penetrating keratoplasty. *Ophthalmology* 2016;123:1646-52
22. Dickman MM, Peeters JM, van den Biggelaar FJ, et al. Changing practice patterns and long-term outcomes of endothelial versus penetrating keratoplasty: A prospective Dutch registry study. *Am J Ophthalmol* 2016;170:133-142
23. van Rooij J, Lucas EH, Geerards AJ, et al. Corneal transplantation for Fuchs´ endothelial dystrophy: A comparison of three surgical techniques concerning 10 year graft survival and visual function. *PLoS One* 2018;13:e0203993
24. Rahman I, Carley F, Hillarby C, et al. Penetrating keratoplasty: indications, outcomes, and complications. *Eye (Lond)* 2009;23:1288-94
25. Patel SV, Diehl NN, Hodge DO, et al. Donor risk factors for graft failure in a 20-year study of penetrating keratoplasty. *Arch Ophthalmol* 2010;128:418-25
26. Cornea Donor Study Investigator Group, Lass JH, Gal RL, Dontchev M, et al. Donor age and corneal endothelial cell loss 5 years after successful corneal transplantation. Specular microscopy ancillary study results. *Ophthalmology* 2008;115:627-32
27. Ing JJ, Ing HH, Nelson LR, et al. Ten-year postoperative results of penetrating keratoplasty. *Ophthalmology* 1998;105:1855-65
28. Feng MT, Price MO, Miller JM, et al. Air reinjection and endothelial cell density in Descemet membrane endothelial keratoplasty: five-year follow-up. *J Cataract Refract Surg* 2014;40:1116-21

Birbal RS[1-3], Tong CM[1,4,5], Dapena I[1,2], Parker JS[6], Parker JS[1,5,6], Oellerich S[1] and Melles GRJ[1-3,5]

[1] *Netherlands Institute for Innovative Ocular Surgery (NIIOS), Rotterdam, The Netherlands*

[2] *Melles Cornea Clinic, Rotterdam, The Netherlands*

[3] *Amnitrans EyeBank, Rotterdam, The Netherlands*

[4] *University of Alberta, Edmonton, Canada*

[5] *NIIOS-USA, San Diego, California, United States of America*

[6] *Parker Cornea, Birmingham, Alabama, United States of America*

Chapter 5

Clinical Outcomes of Descemet Membrane Endothelial Keratoplasty in Eyes with a Glaucoma Drainage Device

Am J Ophthalmol 2019;199:150-8

ABSTRACT

Purpose: To evaluate the feasibility and clinical outcomes of Descemet membrane endothelial keratoplasty (DMEK) in eyes with a glaucoma drainage device (GDD).

Design: Retrospective, interventional case series.

Methods: Clinical outcomes of 23 DMEK procedures for bullous keratopathy (52%), failed previous transplant (39%) or Fuchs endothelial corneal dystrophy (9%) in 20 eyes (19 patients) with a GDD were retrospectively analyzed at two tertiary referral centers. Main outcome measures were best-corrected visual acuity (BCVA), endothelial cell density (ECD), postoperative complications, and graft survival.

Results: Mean length of postoperative follow-up after DMEK was 19 (±17) months. Kaplan-Meier survival analysis showed a 89% cumulative graft success rate at 1 year postoperatively. At 1 year postoperative (n=15), BCVA improved by ≥2 Snellen lines in 11 eyes (73%) and remained stable in 4 eyes (27%). Donor ECD decreased by 37% (n=14), 60% (n=11) and 71% (n=11) at 1, 6 and 12 months postoperatively, respectively. Postoperative complications up to two years postoperatively, comprised pupillary block in 1 eye successfully reversed by partial air removal, visually significant graft detachment requiring re-bubbling in 5 eyes (22%), allograft rejection successfully reversed with topical steroids in 2 eyes (9%), secondary graft failure in 2 eyes (9%) and cataract in one of 3 phakic eyes (33%). Re-keratoplasty was required in 2 eyes (9%).

Conclusions: With specific surgical modifications, DMEK provided acceptable clinical outcomes when taking the complexity of these eyes into account. However, presence of a GDD may reduce graft survival times and may pose a risk for more frequent re-grafting.

INTRODUCTION

Shifting paradigms in the field of corneal transplantation have led to an evolution in the management of corneal endothelial dysfunction in eyes with coexisting glaucoma and a glaucoma drainage device (GDD). With the introduction of Descemet stripping automated endothelial keratoplasty (DSAEK) and Descemet membrane endothelial keratoplasty (DMEK), penetrating keratoplasty (PK) has been replaced as the standard of care not only for endothelial disorders in general, but also for glaucomatous eyes with a GDD.[1-4]

Glaucomatous eyes may pose a challenge for corneal surgeons, as extensive corneal oedema often obscures visibility of the ocular structures, extensive peripheral anterior synechiae may require concurrent synechiolysis, and the presence of a GDD may necessitate adapted surgical protocols. Studies on the clinical outcomes of PK and DSAEK in eyes with endothelial dysfunction and a GDD are widely available and reveal increased allograft rejection rates and decreased graft survival rates compared to eyes without a GDD;[3-8] whereas reports on DMEK are sparse as it is a relatively new technique.[9-12]

With an increasing number of corneal surgeons adopting DMEK globally and employing it more and more in challenging cases, optimization of surgical technique and understanding of the clinical outcomes gain importance.[13] Thus, this study was intended to evaluate the feasibility and the clinical outcomes of DMEK in eyes with a GDD.

MATERIALS AND METHODS

Patient data

In this retrospective, interventional case series, 23 DMEK procedures were included that were performed in 20 eyes of 19 patients (mean age of 63.8 (±12.7); range 37-83 years) at two tertiary referral centers (Melles Cornea Clinic Rotterdam (Center 1) and Parker Cornea (Center 2)) (Table 1; Supplemental Table 1). All included eyes had a postoperative follow-up of at least 6 months. All patients signed an informed consent prior to surgery for research participation and the study adhered to the tenets of the Declaration of Helsinki.

Table 1. Patient and donor baseline characteristics

Characteristic	Result
Patient	
Number of procedures/ eyes/ patients	23/ 20/ 19
Recipient age, years (mean ±SD)	63.8 (±12.7)
Gender	
Female, n (%)	10 (53)
Male, n (%)	9 (47)
Race	
Caucasian, n (%)	15 (79)
African-American, n (%)	3 (16)
Other, n (%)	1 (5)
Lens status	
Phakic, n (%)	3 (13)
Pseudophakic, n (%)	20 (87)
Indication for surgery	
Bullous keratopathy, n (%)	12 (52)
Failed previous transplant, n (%)	9 (39)
Fuchs endothelial corneal dystrophy, n (%)	2 (9)
Type of Glaucoma	
Primary open angle glaucoma, n (%)	10
Secondary glaucoma, n (%)	5
Angle closure glaucoma, n (%)	3
Congenital glaucoma	2
Trabeculectomy, n (%)	13 (65)
Tube(s)	
1, n (%)	17 (85)
2, n (%)	3 (15)
Donor	
Donor age, years (mean ±SD)	68.6 (±7.4)
Donor gender	
Female, n (%)	11(48)
Male, n (%)	12 (52)
Donor death cause	
Cardiovascular/ stroke, n (%)	9 (39)
Respiratory, n (%)	4 (17)
Cancer, n (%)	8 (35)
Other, n (%)	2 (9)
Graft storage medium	
CorneaMax, n (%)	14 (61)
Optisol-GS, n (%)	9 (39)

SD= standard deviation; n= number

Donor tissue preparation

Corneosceral buttons were excised from donor globes less than 36 hours postmortem, and stored in organ culture medium (CorneaMax, Eurobio, Courtaboeuf, France) at 31 °C (Center 1) or in Optisol-GS corneal storage medium (Bausch & Lomb Inc, Rochester, United States; Center 2). For Center

1, donor tissue preparation was performed at Amnitrans EyeBank Rotterdam as previously described,[14,15] while for Center 2 donor tissue preparation was performed according to local protocol at the Alabama Eye Bank. Peripheral Descemet membrane was circumferentially stripped, preserving a small area still attached to the underlying posterior stroma in the center.

Surgical Technique

Surgeries were performed as previously described with some technique modifications.[16,17] A 3.0-mm clear corneal incision was created at the 12 o'clock position, avoiding the area of the GDD and the intracameral tube(s), and preserving the superior conjunctiva for future glaucoma surgery. Using a reversed Sinskey hook (DORC International, Zuidland, the Netherlands) and/ or custom-made scraper (Melles scraper; DORC International), scoring over 360 degrees and descemetorhexis were performed under air. In eyes with failed previous endothelial transplants (DSAEK or DMEK), grafts were stripped from the recipient posterior stroma in a similar fashion using identical instruments. After insertion, the graft was carefully unfolded and lifted against the recipient posterior stroma with an air bubble underneath, avoiding any contact between the graft and the tube(s). Subsequently, the anterior chamber was pressurized with air. Repetitive air injections were required for sufficient pressurization of the eye. The anterior chamber was then completely filled with air for on average >60 minutes and in most of the eyes the air-bubble was not reduced. If required, glaucoma tubes were trimmed during the DMEK procedure (n=6, 26%); none of the tubes was repositioned.

Postoperative management

For Center 1, the standard DMEK postoperative medication regimen included chloramphenicol 0.5% (6 times daily during the first week tapered to twice daily during the second week), ketorolac tromethamine 0.4% 4 times daily and dexamethasone 0.1% 4 times daily; switched to fluorometholone 0.1% 4 times daily at 1 month, and reduced to 3 times daily at 3 months, 2 times daily at 6 months, and once daily at 9 months postoperative.

For Center 2, postoperative medical therapy included Tobradex (tobramycin 0.3%/dexamethasone 0.1%; Novartis Pharmaceuticals Corporation, Hanover, New Jersey, USA) 4 times daily for 1 month; switched to prednisolone acetate 1% 4 times daily at 1 month postoperatively, tapered to 3 times daily at 3 months postoperatively, 2 times daily at 6 months postoperatively and once daily at 9 months postoperatively. In case of elevated intraocular pressure

(IOP), prednisolone acetate was replaced by fluorometholone. For pseudophakic eyes, bromfenac ophthalmic solution 0.07% was administered once daily during the first postoperative month.

Data collection and outcome analysis

In both centers, recipient eyes were examined at 1 day; 1 week; 1, 3, 6, 9 and 12 months; and every 6 months thereafter. Eyes were evaluated with anterior segment optical coherence tomography (AS-OCT) (Center 1: Heidelberg Slit Lamp-OCT; Heidelberg Engineering GmbH, Heidelberg, Germany; and Center 2: Zeiss Visante OCT; Carl Zeiss Meditec, Jena, Germany) and rotating Scheimpflug corneal tomography (Pentacam HR, Oculus Optikgeräte GmbH, Wetzlar, Germany). Endothelial cell density (ECD) was evaluated *in vivo* using non-contact specular microscopy (Center 1: Topcon SP3000p, Topcon Medical Europe BV, Capelle a/d Ijssel, the Netherlands; Center 2:Tomey EM-3000; CBD/Tomey, Phoenix, Arizona, USA).

Secondary graft failure (SGF) was defined as corneal decompensation following an initially functional graft after DMEK. Best-corrected visual acuity (BCVA) was assessed using a Snellen letter chart.BCVA was defined as stable for changes ≤1 Snellen lines, and as improving or deteriorating for changes ≥2 Snellen lines. BCVA outcomes were converted to logarithm of the minimum angle of resolution units (LogMAR) for analysis. IOP was measured with applanation tonometry and increased IOP following DMEK was defined as an IOP ≥24 mmHg or an increase in IOP of ≥10 mmHg from baseline.

Kaplan-Meier survival analysis was performed using SPPS 25.0 (SPSS Inc, Chicago, Illinois, USA) to estimate the cumulative success probability of graft survival. Only primary eyes were included for the survival analysis (excluding 3 repeat-DMEK procedures). Descriptive data analysis was performed using SPSS 25.0 and Excel Software for Windows (Microsoft, Redmond, Washington, USA).

RESULTS

Clinical outcomes

All surgeries were uneventful. Mean follow-up after DMEK was 19 (±17) months. Kaplan-Meier survival analysis showed 89% and 67% cumulative graft success rates at 1 and 2 years, respectively (Fig. 1).

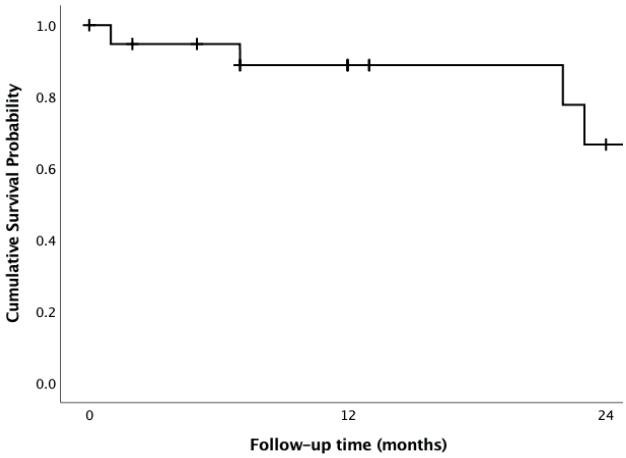

Time (months)		0	1	2	5	7	12	13	22	23	24
Cumulative success probability at FU	Estimate	.	.	0.95	0.95	0.95	0.89	0.89	0.89	0.78	0.67
	SE	.	.	0.05	0.05	0.05	0.08	0.08	0.08	0.12	0.15
Cumulative events		0	0	1	1	1	2	2	2	3	3
Remaining cases		20	19	18	17	16	13	10	8	7	7

Figure 1. Kaplan-Meier curve demonstrating the cumulative success rate of Descemet membrane endothelial keratoplasty in eyes with a glaucoma drainage device.
For eyes included twice in the study (n=3), only the first surgery was included for the survival analysis (n=20). The cumulative success probability was shown to be 0.89 and 0.67 at 1 and 2 years postoperatively, respectively. FU= follow-up, SE= standard error.

Median BCVA improved from 1.30 (IQR [2.00 – 0.82]) preoperatively, to 0.60 (IQR [1.30 – 0.40]) LogMar at 1 year after surgery, representing an improvement in Snellen equivalent from 20/400 (0.05) preoperatively to 20/80 (0.25) at 1 year after DMEK. At 1 year postoperatively (n=15), BCVA had improved by ≥2 Snellen lines in 11 eyes (73%) and remained stable in 4 eyes (27%) (Table 2).

Donor ECD decreased from 2810 (±330) cells/mm^2 before surgery (n=23) to 850 (±430) cells/mm^2 (-71%; n=11) at 1 year postoperatively (Table 2).

Mean pachymetry decreased from preoperatively 902 (±329) µm (n=18) to 633 (±165) µm (n=13) 1 year postoperatively. Mean IOP averaged 11.9 (±2.7) mmHg preoperatively and remained stable throughout the study period.

Table 2. Overview pre- and postoperative endothelial cell density, best-corrected visual acuity, central corneal thickness and Intraocular pressure.

	Cases (n)	Clinical outcome
LogMar BCVA, Median (IQR)		
Preoperative	23	1.30 (2.00 – 0.82)
1m FU	21	0.70 (1.65 – 0.52)
6m FU	17	0.60 (1.30 – 0.40)
12m FU	15	0.60 (1.30 – 0.40)
Change in BCVA from preoperative to 12m FU, n (%)	15	
Improved		11 (73)
Unchanged		4 (27)
Worsened		0
ECD in cells/mm^2, mean (SD) [ECD decrease in %, mean (SD)]		
Preoperative	23	2810 (±330)
1m FU	14	1820 (±510) [37 (±17)]
6m FU	11	1150 (±430) [60 (±15)]
12m FU	11	850 (±430) [71 (±13)]
CCT in µm, mean (SD)		
Preoperative	18	902 (±329)
1m FU	13	583 (±151)
6m FU	13	537 (±92)
12m FU	13	633 (±165)
IOP in mmHg, mean (SD)		
Preoperative	23	11.9 (±2.7)
1m FU	20	12.9 (±5.6)
6m FU	16	12.1 (±4.4)
12m FU	15	12.9 (±4.2)

BCVA: Best-corrected visual acuity
ECD: Endothelial cell density
FU: Follow-up
IOP: Intraocular pressure
IQR: Interquartile range
SD: Standard deviation

Postoperative complications

Pupillary block occurred in 1 of 23 (4%) cases (Case 12) and resulted in an IOP elevation, which could be reversed by partial air removal from the anterior chamber (Table 3). Interestingly, the same eye developed inflammation and spontaneous graft detachment (≥1/3 of the graft surface area) after the patient switched from dexamethasone to fluorometholone drops at 1 month post-operatively. After the eye was treated with an intensified regimen of topical steroids, it received secondary Descemet stripping endothelial keratoplasty

(DSEK). IOP elevation was observed in 2 of 23 (9%) cases (Cases 10 and 16) and occurred at 1 month and 6 months postoperatively, respectively. In both cases the patients were suspected to be steroid responders, and after the steroid load was reduced and topical beta-blockers were applied, the IOP normalized.

Visually significant graft detachment requiring re-bubbling was observed in 5 of 23 (22%) cases (Cases 3, 7, 13, 14a and 20). In case 3, all the air in the anterior chamber had escaped through the glaucoma shunt tube by the end of the operation. Because the postoperative AS-OCT showed a paracentral, ≥1/3 inferior detachment, the eye underwent immediate re-bubbling and the anterior chamber was left with a complete air fill. At 1 day postoperatively, AS-OCT examination showed a fully attached graft. Cases 7, 13 and 14a (<1/3 of the

Table 3. Postoperative complications

	n (%)
Follow-up time; mean (±SD)	19 (±17) months
Pupillary block	1 (4.3)
IOP decompensation	2 (8.7)
Graft detachment at 6m FU (n=17)	
Minor (<1/3)	10 (58.8)
Major (≥1/3)	2 (11.8)
Re-bubbling	5 (21.7)
Allograft rejection	2 (8.7)
Secondary graft failure	2 (8.7)
Re-keratoplasty	2 (8.7)
Cataract	1 (33.3) [a]

[a] 1 out of 3 phakic eyes developed cataract and underwent phacoemulsification at 15 months after DMEK.
SD= standard deviation; n= number

graft surface area) and Case 20 (≥1/3 of the graft surface area) underwent re-bubbling for graft detachment at 1 week postoperatively. In case 20, the graft detachment persisted and the eye underwent successful Descemet stripping automated endothelial keratoplasty (DSAEK) at 2 months postoperatively.

Allograft rejection was suspected in case 7 at 7 months postoperatively and was treated with an intensified regimen of topical steroids. Case 2 developed an allograft rejection at 9 months postoperatively and was successfully treated with topical steroids (Fig. 2). Secondary graft failure was observed in 2 of 23 (9%) cases (Cases 14a and 15a), which underwent successful re-DMEK at, respectively, 26 and 30 months postoperatively.

One of 3 phakic eyes developed cataract in the postoperative course and received phacoemulsification and posterior chamber lens implantation at 15 months postoperatively.

DISCUSSION

In the current study, the clinical outcomes of DMEK in eyes with a GDD were evaluated. While several research groups have reported outcomes of PK and DS(A)EK in eyes with a GDD, reports on DMEK are few, with small sample sizes and short-term follow-up (Table 4).[3-12,18-26] In addition, for the available keratoplasty studies heterogeneity in study design - for example 'mixed study groups' (shunt tube vs. trabeculectomy vs. trabeculectomy and shunt tube) - poses a challenge when interpreting results.

Our study showed lower graft survival rates for DMEK in eyes with a GDD compared to our standard DMEK cohort.[27] At 1 year postoperatively, survival probability was still at 89% for our study group, which decreased to 67% at 2 years postoperatively. This fast drop in survival probability was also reported after PK and DSAEK in eyes with a GDD (Table 4) and might be an inherent problem for this group of eyes taking their complexity into account. For these cases, counselling patients regarding the graft survival prognosis and the higher risk of needing to undergo re-endothelial keratoplasty may be even more important, so that patients can anticipate this.

The presence of a GDD also seems to negatively affect donor ECD, as ECD decrease was higher at 12 months postoperative (71%) than previously reported for our standard DMEK cohort.[27] The incidence of secondary graft failure was also higher than after standard DMEK, but occurred less frequently than compared to DSAEK (26-50%) and PK (30-70%) in eyes with a GDD.[3-5,8,18,19,21,22,24,25,26]

The underlying cause of the greater ECD decrease and higher graft failure rates in the presence of a GDD has been described to be 'multifactorial'. Firstly, changes in aqueous humour circulation patterns owing to a glaucoma shunt tube may adversely affect the endothelial cell viability.[23,24,28,29] Secondly, the GDD itself may induce a breach in the blood-aqueous barrier by intermittent tube-uveal touch and/ or chronic trauma by intermittent tube-corneal touch caused by heavily rubbing or forcefully blinking, resulting in an increase of influx of oxidative, apoptotic and inflammatory proteins, potentially causing

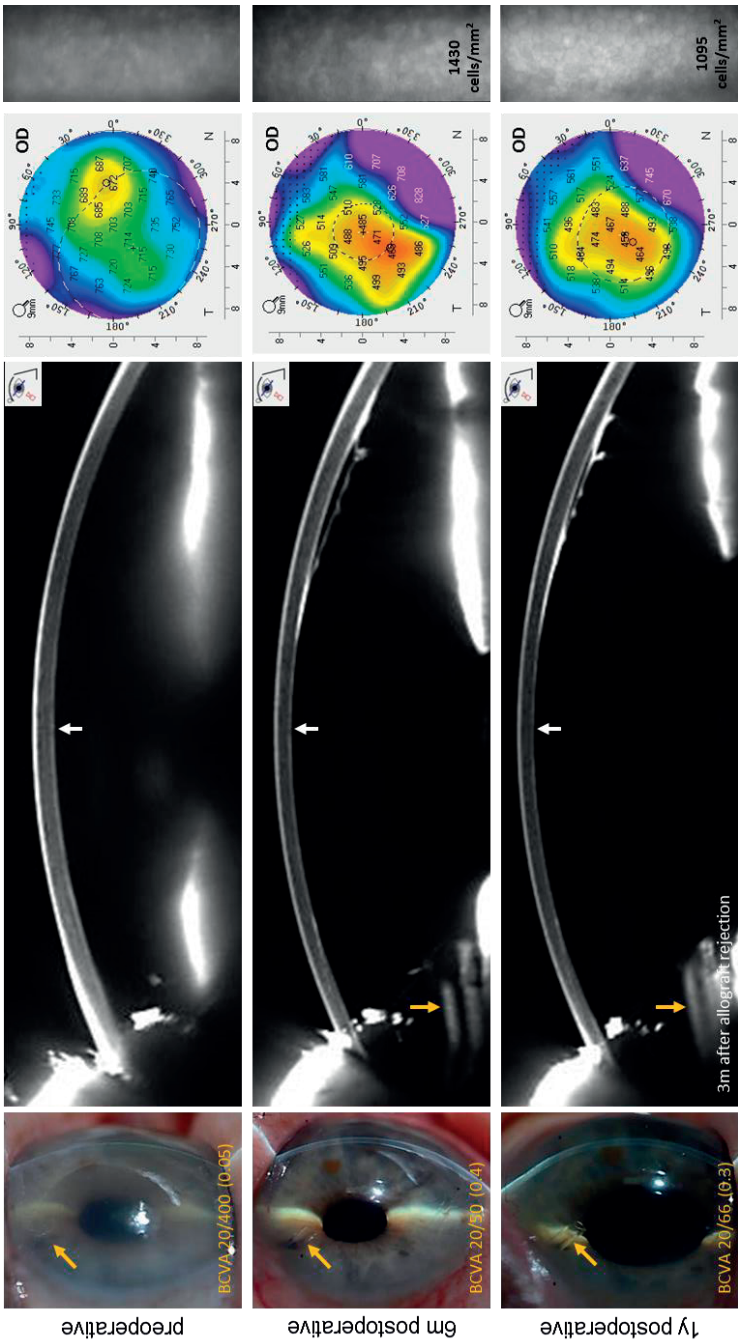

Figure 2. Slit-lamp images, Scheimpflug overviews and pachymetry and specular microscopy images before and after Descemet membrane endothelial keratoplasty (DMEK).
Images are shown for an eye (case 2) preoperatively (top row), at 6 months (second row) and at 1 year after DMEK (third row). Note the glaucoma drainage device superotemporally (orange arrows) and the deturgescence of the cornea (white arrows). The eye developed an allograft rejection at 9 months postoperatively, which was successfully reversed with an intensified regimen of topical steroids.

Table 4. Overview previously published studies on penetrating keratoplasty or endothelial keratoplasty in eyes with a glaucoma drainage device.

Type of surgery	Year	Author	No. of cases	Mean FU time (m)	Graft detachment % (n)	Allograft rejection n (%)	Graft survival (%)
PK	2001	Kwon et al.[18]	GDD n=55	34	n.a.	immunologic 7 (13%); non-immunologic 17 (31%)	70 (24m) 55 (37m) 40 (89m)
	2004	Alvarenga et al.[19]	GDD n=40	18	n.a.	n.a.	30
	2010	Witmer et al.[20]	GDD n=51	38	n.a.	1 (after cessation of topical steroids)	61
	2010	Hollander et al.[5]	GDD n=77	n.a.	n.a.	Overall 13 (17%)	89 (12m) 67 (24m) 64 (36m) 41 (48m)
	2012	Knape et al.[6]	GDD n=28	60	n.a.	13 (46%)	43
PK/ DSEK	2017	Iverson et al.[8]	PK GDD n=21 DSEK GDD n=12	23 14	n.a. 25 (3)	2 (10%) 0	62 58
DS(A)EK	2011	Wiaux et al.[2]	Surgically treated n=56 (52 eyes); GDD n=33 (29 eyes) Trab n=29	12	12.5 (7/56)	3/52 (6%)	87.5 (7/56)
	2012	DeCroos et al.[21]	Trab n=20; GDD n=27; multiple GDD n=12; GDD + Trab n=12	24	5 26 30 8.3	2 (3%)	95 74 80 66.7
	2012	Nguyen et al.[22]	Trab n= 18 Trab + GDD n=11 GDD n=35	44	16.7 18.2 17.1	n.a.	83.3 72.7 74.3
	2012	Kim et al.[23]	GDD n=11	20	36.4	36.4	18.2
	2012	Anshu et al.[3]	Trab n=26; Trab + GDD n=10; GDD n=10	Up to 60	n.a.	Overall 6 (13%)	Overall 59
	2013	Schoenberg et al.[24]	GDD n=18	24	50	n.a.	50

Table 4. Overview previously published studies on penetrating keratoplasty or endothelial keratoplasty in eyes with a glaucoma drainage device. (*continued*)

Type of surgery	Year	Author	No. of cases	Mean FU time (m)	Graft detachment % (n)	Allograft rejection n (%)	Graft survival (%)
	2014	Aldave et al.[4]	Total 76	21			
			Trab n=37;		13.5 (5/37)	5/35 (14.3%)	84
			GDD n=61;		18.0 (11/61)	6/52 (11.5%)	74
			Trab + GDD n=15		0	2/14 (14.3%)	93
	2015	Ni et al.[25]	GDD n=24		2	n.a.	
				12			87
				24			80
				36			70
	2016	Kang et al.[26]	129 cases/ 102 eyes	29		Overall 9 (8.8%)	
			Trab n=62		33.9 (21)		65
			GDD n=26;		42.3 (11)		54
			Trab + GDD n=14		35.7 (5)		57
	2017	Chiam et al.[7]	GDD n=14		Overall 0	Overall 1 (7.1%)	
				12			71
				24			36
				30			30
DMEK	2011	Bersudsky et al.[9]	GDD n=1	12	0	0	100
	2013	Heindl et al.[10]	GDD n=2	12	50	0	100
	2015	Liarakos et al.[11]	GDD n=1	6	0	0	100
	2017	Aravena et al.[12]	Total 60; GDD=23	10	Overall 23.2	Immunogenic 4 (3 after cessation of topical steroids and 1 in the control group)	100

EK = endothelial keratoplasty; no. = number; FU= follow-up; m=months; n= number; n.a.= not available; PK= penetrating keratoplasty; DS(A)EK= Descemet stripping (automated) endothelial keratoplasty; DMEK= Descemet membrane endothelial keratoplasty; GDD= glaucoma drainage device; Trab= trabeculectomy.

corneal endothelial damage.[28,30,31] Kim and associates similarly showed progressive decrease of the ECD in the first year after Ahmed valve implantation without keratoplasty in eyes with a GDD and even showed that cell loss was highest in the area of the tube.[32]

Graft detachment was the main postoperative complication, with 22% of eyes requiring a re-bubbling procedure. While this is comparable to rates reported in other series after DSAEK (17-50%) and DMEK (24%),[4,12,21-24] it is significantly higher than for our standard DMEK cohort.[27] This may reflect that eyes with a GDD are more prone to surgical complications, which is possibly related to the added difficulty of pressurizing these eyes with air at the conclusion of the operation.

The allograft rejection rate observed in this study is similar to the rates reported for DSAEK (7-14%)[3,4,7] but lower than the 10-40% reported for PK.[5,6,8,18] A possible explanation for the lower rejection rate may be the lower antigen load with reduction of the graft tissue. While our allograft rejection rate for DMEK in eyes with a GDD may seem higher than the 1-2% that we have reported for standard DMEK before,[33] the current study concerns a relatively small sample size and results should be interpreted with caution.

Most of the observed postoperative complications are thus inherent to the presence of a GDD but might partly be mitigated by special surgical considerations. These may include: 1) creating the main incision in such a way (more corneal rather than limbal) that a pre-existing filtering bleb of a trabeculectomy or a GDD is preserved and the superior conjunctiva is spared for possible future glaucoma surgery; 2) trimming or displacing the shunt tube laterally in order to avoid donor endothelial cell damage; 3) unfolding the Descemet graft over the tube rather than over the iris; 4) maintaining a complete air fill of the anterior chamber for 90-120 minutes (instead of 45-60 minutes) with repetitive air injections in between, if required; 5) leaving a 100% air bubble at termination of the surgery, since the risk of pupillary block glaucoma may be relatively small owing to the presence of a pre-existing peripheral iridotomy and the tube shunt.

The limitations posed by the retrospective study design and the relatively small sample size of this study may be surpassed by additional prospective studies of larger sample size and longer follow-up terms, possibly with control

groups (no glaucoma, medically treated glaucoma/ glaucoma without previous glaucoma surgery and trabeculectomy/ shunt tube only).

In conclusion, with specific surgical modifications, DMEK provided acceptable clinical outcomes when taking the complexity of eyes with a GDD into account. The presence of a GDD, however, may reduce graft survival times and may pose a risk for more frequent re-grafting.

REFERENCES

1. Park CY, Lee JK, Gore PK, et al. Keratoplasty in the United States: a 10-year review from 2005 through 2014. *Ophthalmology* 2015;122: 2432–42
2. Wiaux C, Baghdasaryan E, Lee OL, et al. Outcomes after Descemet stripping endothelial keratoplasty in glaucoma patients with previous trabeculectomy and tube shunt implantation. *Cornea* 2011;30:1304-11
3. Anshu A, Price MO, Price FW. Descemet's stripping endothelial keratoplasty: long-term graft survival and risk factors for failure in eyes with preexisting glaucoma. *Ophthalmology* 2012;119:1982-7
4. Aldave AJ, Chen JL, Zaman AS, Deng SX, Yu F. Outcomes after DSEK in 101 eyes with previous trabeculectomy and tube shunt implantation. *Cornea* 2014;33:223-9
5. Hollander DA, Giaconi JA, Holland GN, et al. Graft failure after penetrating keratoplasty in eyes with Ahmed valves. *Am J Ophthalmol* 2010;150:169-78
6. Knape RM, Szymarek TN, Tuli SS, Driebe WT, Sherwood MB, Smith MF. Five-year outcomes of eyes with glaucoma drainage device and penetrating keratoplasty. *J Glaucoma* 2012;21:608-14
7. Chiam PJ, Cheeseman R, Ho VW, et al. Outcome of Descemet stripping automated endothelial keratoplasty in eyes with an Ahmed glaucoma valve. *Graefes Arch Clin Exp Ophthalmol* 2017;255:987-93
8. Iverson SM, Spierer O, Papachristou GC, et al. Comparison of graft survival following penetrating keratoplasty and Descemet's stripping endothelial keratoplasty in eyes with a glaucoma drainage device. *Int Ophthalmol* 2018;38:223-31
9. Bersudsky V, Treviño A, Rumelt S. Management of endothelial decompensation because of glaucoma shunt tube touch by Descemet membrane endothelial keratoplasty and tube revision. *Cornea* 2011;30:709-11
10. Heindl LM, Koch KR, Bucher F, et al. Descemet membrane endothelial keratoplasty in eyes with glaucoma implants. *Optom Vis Sci* 2013;90:e241-4
11. Liarakos VS, Satué M, Livny E, et al. Descemet membrane endothelial keratoplasty for a decompensated penetrating keratoplasty graft in the presence of a long glaucoma tube. *Cornea* 2015;34:1613-6
12. Aravena C, Yu F, Deng SX. Outcomes of Descemet membrane endothelial keratoplasty in patients with previous glaucoma surgery. *Cornea* 2017;36:284-9
13. Eye Bank Association of America. *2016 Eye Banking Statistical Report.* Washington, DC: Eye Bank Association of America; 2017
14. Lie JT, Birbal R, Ham L, van der Wees J, Melles GR. Donor tissue preparation for Descemet membrane endothelial keratoplasty. *J Cataract Refract Surg* 2008;34:1578-83
15. Groeneveld-van Beek EA, Lie JT, van der Wees J, Bruinsma M, Melles GR. Standardized 'no-touch' donor tissue preparation for DALK and DMEK: harvesting undamaged anterior and posterior transplants from the same donor cornea. *Acta Ophthalmol* 2013;91:145-50
16. Melles GR, Ong TS, Ververs B, van der Wees J. Descemet membrane endothelial keratoplasty (DMEK). *Cornea* 2006;25:987-90
17. Dapena I, Moutsouris K, Droutsas K, Ham L, van Dijk K, Melles GR. Standardized "no-touch" technique for Descemet membrane endothelial keratoplasty. *Arch Ophthalmol* 2011;129:88-94

18. Kwon YH, Taylor JM, Hong S, et al. Long-term results of eyes with penetrating keratoplasty and glaucoma drainage tube implant. *Ophthalmology* 2001;108:272-8
19. Alvarenga LS, Mannis MJ, Brandt JD, Lee WB, Schwab IR, Lim MC. The long-term results of keratoplasty in eyes with a glaucoma drainage device. *Am J Ophthalmol* 2004;138:200-5
20. Witmer MT, Tiedeman JS, Olsakovsky LA, Conaway MR, Prum BE. Long-term intraocular pressure control and corneal graft survival in eyes with a pars plana Baerveldt implant and corneal transplant. *J Glaucoma* 2010;19:124-31
21. Decroos FC, Delmonte DW, Chow JH, et al. Increased rates of Descemet's stripping automated endothelial keratoplasty (DSAEK) graft failure and dislocation in glaucomatous eyes with aqueous shunts. *J Ophthalmic Vis Res* 2012;7:203-13
22. Nguyen P, Khashabi S, Chopra V, et al. Descemet stripping with automated endothelial keratoplasty: A comparative study of outcome in patients with preexisting glaucoma. *Saudi J Ophthalmol* 2013;27:73-8
23. Kim P, Amiran MD, Lichtinger A, Yeung SN, Slomovic AR, Rootman DS. Outcomes of Descemet stripping automated endothelial keratoplasty in patients with previous glaucoma drainage device insertion. *Cornea* 2012;31:172-5
24. Schoenberg ED, Levin KH, Savetsky MJ, Mcintire LU, Ayyala RS. Surgical outcomes of DSAEK in patients with prior Ahmed glaucoma drainage device placement. *Eur J Ophthalmol* 2013;23:807-13
25. Ni N, Sperling BJ, Dai Y, Hannush SB. Outcomes after Descemet stripping automated endothelial keratoplasty in patients with glaucoma drainage devices. *Cornea* 2015;34:870-5
26. Kang JJ, Ritterband DC, Lai K, Liebmann JM, Seedor JA. Descemet stripping endothelial keratoplasty in eyes with previous glaucoma surgery. *Cornea* 2016;35:1520-5
27. Ham L, Dapena I, Liarakos VS, et al. Midterm results of Descemet membrane endothelial keratoplasty: 4 to 7 years clinical outcome. *Am J Ophthalmol* 2016;171:113-21
28. Topouzis F, Coleman AL, Choplin N, et al. Follow-up of the original cohort with the Ahmed glaucoma valve implant. *Am J Ophthalmol* 1999;128:198-204
29. Williams KA, Lowe M, Bartlett C, Kelly TL, Coster DJ; All Contributors. Risk factors for human corneal graft failure within the Australian corneal graft registry. *Transplantation* 2008;86:1720-4
30. Anshu A, Price MO, Richardson MR, et al. Alterations in the aqueous humor proteome in patients with a glaucoma shunt device. *Mol Vis* 2011;17:1891-1900
31. Rosenfeld C, Price MO, Lai X, Witzmann FA, Price FW Jr. Distinctive and pervasive alterations in aqueous humor protein composition following different types of glaucoma surgery. *Mol Vis* 2015;21:911-8
32. Kim CS, Yim JH, Lee EK, Lee NH. Changes in corneal endothelial cell density and morphology after Ahmed glaucoma valve implantation during the first year of follow up. *Clin Exp Ophthalmol* 2008;36:142-7
33. Rodríguez-Calvo-de-Mora M, Quilendrino R, Ham L, et al. Clinical outcome of 500 consecutive cases undergoing Descemet's membrane endothelial keratoplasty. *Ophthalmology* 2015;122:464-70

Supplemental Table. Overview Baseline Characteristics, Pre- and Postoperative Endothelial

Center	Patient							ECD (cells/mm²) [ECD decrease (%)]				BCVA (Snellen (decimal))	
	Case no.	Age (y) / Sex	Race	Eye	Indication for surgery	Lens status	Tube (n)	Pre-op	1m FU	6m FU	1y FU	Preop	1m FU
1	1a[a]	37 / F	C	OS	BK	Phakic	1	2500	N/A	n.p.	n.p.	1/60 (0.017)	1/300 (0.003)
1	1b[a]	40 / F	C	OS	Failed DMEK	Pseudo-phakic	1	2500	n.p.	n.p.	n.p.	1/300 (0.003)	1/60 (0.017)
1	2	63 /M	C	OD	PPBK	Pseudo-phakic	1	2500	1818 [27]	1428 [43]	1095 [56]	20/400 (0.05)	20/66 (0.3)
1	3	42 / F	C	OD	PPBK	Pseudo-phakic	1	2600	LTFU			20/200 (0.1)	LTFU
1	4	41 / M	C	OD	Failed PK	Phakic	1	2700	N/A	n.p.	590 [78]	3/300 (0.01)	N/A
1	5	60 / F	C	OD	PPBK	Pseudo-phakic	1	2400	897 [63]	525 [78]	n.p.	3/300 (0.01)	20/100 (0.2)
1	6	72 / F	C	OS	Failed thin DSEK	Pseudo-phakic	1	2600	N/A	689 [73]	504 [81]	3/300 (0.01)	20/100 (0.2)
1	7	80 /M	C	OS	PPBK	Pseudo-phakic	1	2600	1748 [33]	1495 [42]	1343 [48]	20/100 (0.2)	20/50 (0.4)
1	8	62 / F	C	OS	PPBK	Pseudo-phakic	2	2800	1513 [46]	1269 [55]	687 [75]	1/300 (0.003)	20/100 (0.2)
1	9	73 / F	C	OS	PPBK	Pseudo-phakic	1	2700	N/A	563 [79]	n.p.	3/300 (0.01)	1/300 (0.003)
1	10	62 / M	C	OD	Failed re-DMEK[c]	Pseudo-phakic	1	2700	2241 [17]	703 [74]	286 [89]	1/300 (0.003)	20/133 (0.15)
1	11	58 / M	SA	OS	PPBK	Pseudo-phakic	1	2800	2182 [22]	LTFU		20/133 (0.15)	20/40 (0.5)
1	12	73 / M	AA	OD	PPBK	Pseudo-phakic	1	2500	N/A	DSEK		1/300 (0.003)	3/300 (0.01)
1	13	65 / F	AA	OS	PPBK	Pseudo-phakic	2	2700	N/A	n.p.	n.y.a.	3/300 (0.01)	0.25/200 (LP+)
2	14a[a]	64 / M	C	OD	Failed re-DSEK	Pseudo-phakic	1	3155	2952 [6]	1293 [59]	620 [80]	*20/70[e] (0.28)*	*20/40[b,e] (0.5)*
2	14b[a]	66 / M	C	OD	Failed DMEK	Pseudo-phakic	1	3145	1585 [50]	1479[b] [53]	1334 [58]	*20/200[e] (0.1)*	*20/100[e] (0.2)*
2	15a[a]	64 / M	C	OS	Failed re-DSEK	Pseudo-phakic	2	2793	1937 [31]	1593 [43]	621 [78]	*20/80[e] (0.25)*	*20/40[e] (0.5)*
2	15b[a]	66 / M	C	OS	Failed DMEK	Pseudo-phakic	2	2882	1811 [37]	1455 [50]	n.y.a.	*20/50[e] (0.4)*	*20/50[e] (0.4)*
2	16	62 / M	C	OD	PPBK	Pseudo-phakic	1	3831	2279 [41]	1398 [64]	1639 [57]	*20/400[e] (0.05)*	*20/60[e] (0.3)*
2	17	72 / F	C	OS	3x Failed DSAEK[d]	Pseudo-phakic	1	3003	1627 [46]	N/A	664 [78]	*20/200[e] (0.1)*	*20/400[e] (0.05)*
2	18	83 / M	AA	OD	FECD	Phakic	1	2874	1805 [37]	N/A	n.y.a	*20/400[e] (0.05)*	*20/70[e] (0.28)*

Cell Density, Best-Corrected Visual Acuity and Central Corneal Thickness

BCVA (Snellen (decimal))		CCT (μm)				IOP (mmHg)				Graft detachment at 6m FU (surface area)	Remarks
6m FU	1y FU	Pre-op	1m FU	6m FU	1y FU	Pre-op	1m FU	6m FU	1y FU		
1/300 (0.003)	3/300 (0.01)	1213	525	569	556	12	10	10	12	<1/3	Phacoemuls. (15m)
1/60 (0.017)	20/400 (0.05)	1176	590	437	913	11	11	14	10	<1/3	
20/50 (0.4)	20/66 (0.3)	714	520	477	459	16	17	10	12	≥1/3	Allograft rejection (9m)
LTFU		788	LTFU			14	LTFU			N/A	Re-bubbling (1.5h postop); patient returned to own ophthalmologist for check-up
20/80 (0.25)	20/50 (0.4)	710	782[b]	675	750	11	N/A	12	12	<1/3	
20/66 (0.3)	20/200 (0.1)	727	533	552	605	10	12	11	12	<1/3	Extensive PAS
20/100 (0.2)	20/66 (0.3)	1129	725	509	588	14	11	11	17	<1/3	
20/40 (0.5)	20/200 (0.1)	588	539	557	510	17	15	17	17	Fully attached	Tube trimmed during surgery; Re-bubbling (1w); suspected allograft rejection (7m)
20/100 (0.2)	20/200 (0.1)	1147	575	589	616	10	11	16	16	<1/3	
20/400 (0.05)	1/60 (0.017)	817	1038	779	1012	15	19	14	14	<1/3	Extensive PAS
20/80 (0.25)	20/80 (0.25)	1084	457	469	564	8	28	14	10	<1/3	IOP decompensation (1m)
LTFU		933	499	LTFU		11	18	LTFU		N/A	Patient returned to own ophthalmologist for check-up
DSEK		1882	n.p.	DSEK		10	6	DSEK		n.p.	Pupillary block à Elevation IOP (1d); Switch Dexa to FML à inflammation à graft detached (1m)
0.25/200 (LP+)	n.y.a.	951	n.p.	n.p.	n.y.a.	15	10	N/A	n.y.a.	<1/3 (5m)	Re-bubbling (1w)
20/40[e] (0.5)	*20/25[e] (0.8)*	N/A	N/A	N/A	N/A	11	N/A	8	12	≥1/3	Re-bubbling (1w); SGF (23m)
20/50[e] (0.4)	*20/70[e] (0.28)*	N/A	427[b]	487	493	11	10	8	11	<1/3	
20/30[e] (0.67)	*20/25[e] (0.8)*	N/A	N/A	N/A	N/A	8	6	10	10	N/A	SGF (22m)
20/40[e] (0.5)	n.y.a.	586	485[b]	481	n.y.a.	7	16	10	n.y.a.	Fully attached	Tube trimmed during surgery
20/50[e] (0.4)	*20/40[e] (0.5)*	714	524	527	526	13	18	25	23	Fully attached	Tube trimmed during surgery; IOP decompensation (6m)
20/400[e] (0.05)	*20/400[e] (0.05)*	N/A	513	N/A	641	13	3	4	5	N/A	Tube trimmed during surgery; synechiolysis of ext. PAS
20/400[e] (0.05)	n.y.a.	524	400[b]	429	n.y.a.	16	16	12	n.y.a.	Fully attached	

Supplemental Table. Overview Baseline Characteristics, Pre- and Postoperative Endothelial

Center	Patient							ECD (cells/mm^2) [ECD decrease (%)]				BCVA (Snellen (decimal))	
	Case no.	Age (y) / Sex	Race	Eye	Indication for surgery	Lens status	Tube (n)	Pre-op	1m FU	6m FU	1y FU	Preop	1m FU
2	19	76 / F	C	OS	PPBK	Pseudo-phakic	1	3356	1098 [67]	N/A	n.y.a.	20/400 (0.05)	*20/80* [e] *(0.25)*
2	20	76 / F	C	OS	FECD	Pseudo-phakic	1	2941	N/A	DSAEK		PH: 20/60 (0.3)	20/400 (0.05)

ECD= endothelial cell density; CCT= central corneal thickness; µm= micrometer; IOP= intraocular pressure; Y= years; n= number; w= weeks; m= months; FU= follow-up; Preop= preoperative; F= female; M= male; C= Caucasian; AA=African American; SA=Saudi-Arabian; OS= oculus sinister; OD= oculus dexter; (PP)BK= (pseudophakic) bullous keratopathy; N/A = not available; n.p.= not possible; LTFU= lost to follow-up; SGF = Secondary graft failure; PGF = Primary graft failure; DMEK= Descemet membrane endothelial keratoplasty; PK= penetrating keratoplasty; dexa= dexamethasone; FML= fluorometholone; DSEK= Descemet stripping endothelial keratoplasty; FECD= Fuchs endothelial corneal dystrophy; PH= visual acuity measured with Pinhole; ext. PAS= extensive peripheral anterior synechiae; phacoemuls.= phacoemulsification.

Cell Density, Best-Corrected Visual Acuity and Central Corneal Thickness (*continued*)

BCVA (Snellen (decimal))		CCT (μm)				IOP (mmHg)				Graft detachment at 6m FU (surface area)	Remarks
6m FU	**1y FU**	**Pre-op**	**1m FU**	**6m FU**	**1y FU**	**Pre-op**	**1m FU**	**6m FU**	**1y FU**		
20/60 (0.3)	n.y.a.	797	534	512	n.y.a.	11	10	12	n.y.a.	Fully attached	Tube trimmed during surgery
DSAEK		N/A	N/A	DSAEK		10	10	DSAEK		N/A	Tube trimmed during surgery; Re-bubbling (1w); secondary DSAEK for persistent graft detachment (2m)

[a] 1a,1b / 14a,14b / 15a,15b = Subsequent operations in the same eye.
[b] 3 months follow-up
[c] First DMEK, patient did not have a glaucoma drainage device implant yet.
[d] Related to shunt tube
[e] *Italic* Uncorrected visual acuity, BSCVA not available.

Birbal RS[1-3], Parker J[1,4], Dirisamer M[1,2,5], Janićijević A[1], Baydoun L[1,2], Dapena I[1,2] and Melles GRJ[1-3]

[1] *Netherlands Institute for Innovative Ocular Surgery, Rotterdam, The Netherlands*

[2] *Melles Cornea Clinic, Rotterdam, The Netherlands*

[3] *Amnitrans EyeBank, Rotterdam, The Netherlands*

[4] *Parker Cornea, Birmingham, Alabama, United States of America*

[5] *Department of Ophthalmology, Ludwig-Maximilians-University, Munich, Germany*

Chapter 6

Descemet Membrane Endothelial Transfer: Ultimate Outcome

Cornea 2018;37:141-4

ABSTRACT

Purpose: To evaluate the clinical outcome of 16 eyes undergoing Descemet membrane endothelial transfer (DMET).

Methods: In this retrospective cohort study, a consecutive series of 16 eyes from 16 patients was evaluated after subtotal detachment of the Descemet graft after a Descemet membrane endothelial keratoplasty procedure (n=8) or intended DMET (n=8) for either Fuchs endothelial dystrophy (FED; n=10) or Bullous keratopathy (BK; n=6).

Results: All 8 Descemet membrane endothelial keratoplasty procedures were complicated by subtotal detachment of the donor graft. The remaining 8 eyes that underwent a DMET procedure were uneventful and no postoperative complications occurred, except 1 eye with BK that experienced a postoperative wound leak. Throughout all postoperative time points, the partially attached status of all Descemet grafts was maintained. Although all eyes operated on for FED showed initial central corneal clearance, no eye operated for BK demonstrated any degree of corneal deturgescence. Ultimately, all 16 corneas decompensated and 15 of the 16 patients elected for re-transplantation, while one patient declined further surgery for health reasons. Re-transplantation was performed on average 10.3 (±7.4) months (range, 3-31 months) postoperatively.

Conclusion: Ultimately, regardless of the etiology of the endothelial dysfunction, DMET fails to provide satisfactory results in the long term; durable corneal clearance may therefore require the presence of a nearly completely attached Descemet graft.

INTRODUCTION

Since its introduction in 2002, Descemet membrane endothelial keratoplasty (DMEK) has increasingly become the globally preferred surgical treatment option for patients with corneal endothelial disorders.[1] More recently, we reported on 'Descemet membrane endothelial transfer' (DMET), in which a descemetorhexis is followed by insertion of an almost completely free-floating Descemet roll (i.e. with the graft contacting the posterior cornea only at the corneal incision) aiming to obtain corneal clearance by endothelial cell migration.[2,3]

Our initial evaluation of DMET comprised a cohort of 12 eyes from 12 patients, 7 operated on for Fuchs Endothelial Dystrophy (FED) and 5 for Bullous Keratopathy (BK). The short-term results showed repopulation of the denuded recipient stroma and corneal clearance in all eyes operated on for FED, but not for those with BK.[2,3] Since then, 4 additional eyes have undergone a DMET procedure; this study aims to provide the further results of this cohort.

MATERIALS AND METHODS

A consecutive series of 16 eyes from 16 patients (6 female; mean age of 62.8 ±[16.9] years) underwent DMET for either FED or BK (3 with pseudophakic BK, 2 with decompensated previous endothelial grafts, and 1 of unknown origin) in our tertiary referral center between February 2008 and September 2012. All patients signed an informed consent form for research participation, and the study was conducted according to the tenets of the Declaration of Helsinki.

Eight eyes underwent a DMEK procedure, subsequently complicated by a subtotal graft detachment in the immediate postoperative period, such that the greater portion of the graft was "free-floating" in the anterior chamber. In the remaining 8 eyes, various complicated anatomical situations (including nanophthalmos, histories of advanced glaucoma, unstable or dislocated intraocular lenses, or a combination thereof) resulted in an anticipated inability to provide air bubble support for the tissue at the end of surgery. Therefore, during the DMEK operation, the upper edge of the graft was fixated within the limbal incision to create contact between the donor tissue and the recipient posterior stroma.

Donor tissue preparation was performed as previously described.[4,5] In short, from donor globes retrieved within 36 hours postmortem, corneoscleral buttons were excised and stored in organ culture medium (CorneaMax; Eurobio, France) at 31°C for up to 3 weeks. The buttons were mounted endothelial side up on a custom-made holder with a suction cup to facilitate stripping of a 9.5 mm-diameter Descemet graft. Owing to its elastic properties, the graft spontaneously formed a single or double roll with the endothelium on the outside. After preparation, all Descemet rolls were stored again in organ culture medium until transplantation. Endothelial cell morphology and viability were evaluated in the eye bank before and after Descemet stripping.

Surgery was performed as previously described.[6] Eight of the 16 operations were completed as normal DMEK procedures; in the remaining 8 (with anticipated insufficient or ineffective air bubble support), the operation additionally included fixating the proximal edge of the graft within the limbal incision to ensure contact between the donor tissue and the recipient posterior cornea. Postoperative medical therapy included chloramphenicol 0.5% (6 times daily during the first week and twice daily during the second week), ketorolac tromethamine 0.4% 4 times daily and dexamethasone 0.1% 4 times daily, switched to fluorometholone 0.1% 4 times daily at 1 month, then reduced to 3 times daily at 3 months, 2 times daily at 6 months and once daily at 9 months postoperative.

Before and after surgery, corneal thickness measurements were obtained by Scheimpflug imaging (Pentacam HR; Oculus, Wetzlar, Germany), and endothelial cell density (ECD) measurements were made preoperatively in the eye bank, *in vitro*, using an inverted light microscope (Axiovert 40; Zeiss) and after surgery, using non-contact specular microscopy (Topcon SP3000; Topcon Medical Europe BV, Capelle a/d IJssel, the Netherlands).

RESULTS

All 8 DMEK procedures were complicated by a subtotal detachment of the donor graft. The remaining 8 eyes that underwent a DMET-procedure were uneventful and no postoperative complications occurred, except one eye with BK that experienced a postoperative wound leak. Throughout all postoperative time points, the partially attached status of all DMET grafts maintained; that is, in no case did any graft entirely adhere or totally detach spontaneously.

Ultimately, all 16 corneas decompensated and 15 of the 16 patients elected for re-transplantation, whereas one patient declined further surgery for health reasons. Re-transplantation was performed on average 10.3 (±7.4) months (range, 3-31 months) postoperatively.

All eyes operated on for FED (n=10) initially showed central (partial) corneal clearance, with a reduction in mean thinnest point pachymetry from 636 (±89) µm to 533 (±47) µm by six months postoperatively (n=6) (Fig. 1). Six of these 10 also improved their best-corrected visual acuity, although most of these eyes possessed low visual potential secondary to pre-existing retinal pathology. However, mean endothelial cell density measured at 6 months postoperatively was 797 (±743) cells/ mm^2 (n=6) and, ultimately, all 10 corneas decompensated (evidenced by decreasing vision and increasing corneal thickness), such that – at a mean of 11.6 (±9.2) months (range, 4-31 months) postoperatively – 9 of these 10 eyes received re-transplantation, with 1 patient declining additional surgery for health reasons.

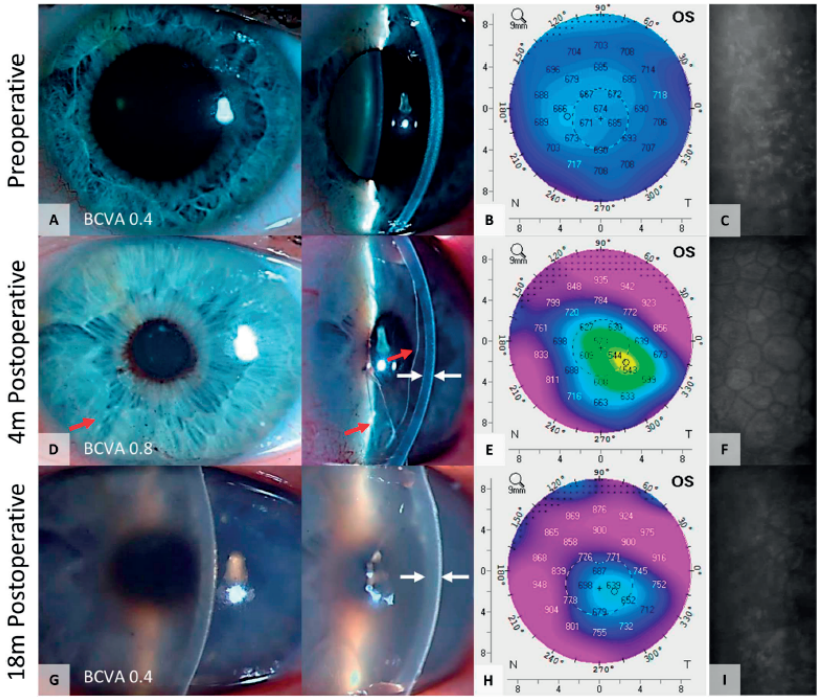

Figure 1. Slit-lamp images, pachymetry and specular microscopy preoperatively (A, B and C), at 4 months (D, E and F) and at 18 months after Descemet membrane endothelial transfer (G, H and I). Note the initial corneal clearance at 4 months and the corneal decompensation at 18 months postoperatively (white arrows). The red arrows display the borders of the Descemet graft.

By contrast, at no time point did any eye operated for BK demonstrate corneal clearance, measured by reduction in corneal thickness or a subjective improvement in vision (mean preoperative and 6 months postoperative thinnest point thickness 768 (±104) µm and 777 (±133) µm, respectively (n=5)). All 6 eyes were subsequently managed by re-transplantation at a mean of 8.3 (±3.6) months (range, 3-14 months) postoperatively.

DISCUSSION

In the past decade, a growing number of studies describing spontaneous corneal clearance in the presence of a detached Descemet graft[2,7-9] or in the absence of a Descemet graft, that is, 'descemetorhexis only'[10-21] have challenged the current concept of endothelial keratoplasty and questioned the necessity of grafting after descemetorhexis. Many of these studies have emphasized the short-term surgical results, including our own previous report on the efficacy of DMET.[3] Moreover, negative results have also been described, with a significant number of corneas failing to clear having been reported following "descemetorhexis only" procedures.[10,11,13,15,22,23]

The current study confirms that DMET may engender corneal clearance in eyes with FED, but not BK. This suggests that the mechanism of action of DMET may be primarily to stimulate a host endothelial migratory response, rather than to directly supply the transplanted eyes with additional functional cells. Nevertheless, our observations with DMET would suggest that the regenerative capacity of the endothelium in eyes with FED may not be sufficient to ensure lasting corneal clearance since all operated eyes experienced only partial and transient – not complete and durable – corneal deturgescence. This limited and transitory capacity of the recipient endothelium to self-repair in eyes with FED may explain why the reported success of "descemetorhexis only" strategies presently seems dependent on a small, central descemetorhexis, exclusively.[24] It may also explain the mechanism behind instances of corneas prematurely decompensating after DMEK in the presence of a large persistent graft detachment.[25] Accordingly, to obtain complete and lasting corneal rehabilitation, a (nearly) fully centrally attached Descemet graft may be mandatory. A further implication is that very large DMEK graft detachments, especially if greater than half the tissue surface area, may be best managed by re-bubbling, rather than by awaiting spontaneous corneal clearance, to minimize the risk of a subsequent corneal decompensation.[26]

Therefore, the current practice of DMEK may remain the preferred treatment option for the long-term management of corneal endothelial disorders, both FED and BK.

REFERENCES

1. Melles GR. Posterior lamellar keratoplasty: DLEK to DSEK to DMEK. *Cornea* 2006;25:879-81
2. Dirisamer M, Ham L, Dapena I, et al. Descemet membrane endothelial transfer: 'Free-floating' donor Descemet implantation as a potential alternative to 'keratoplasty'. *Cornea* 2012;31:194–7
3. Dirisamer M, Yeh RY, van Dijk K, et al. Recipient endothelium may relate to corneal clearance in Descemet membrane endothelial transfer. *Am J Ophthalmol* 2012;154:290–6
4. Lie JT, Birbal R, Ham L, et al. Donor tissue preparation for Descemet membrane endothelial keratoplasty. *J Cataract Refract Surg* 2008;34:1578-83
5. Groeneveld-van Beek EA, Lie JT, van der Wees J, et al. Standardized "no-touch" donor tissue preparation for DALK and DMEK: harvesting undamaged anterior and posterior transplants from the same donor cornea. *Acta Ophthalmol* 2013;91:145-50
6. Dapena I, Moutsouris K, Droutsas K, et al. Standardized 'no touch' technique for Descemet's membrane endothelial keratoplasty. *Arch Ophthalmol* 2011;129:88–94
7. Balachandran C, Ham L, Verschoor CA, et al. Spontaneous corneal clearance despite graft detachment in Descemet membrane endothelial keratoplasty (DMEK). *Am J Ophthalmol* 2009;148:227–34
8. Price FW Jr, Price MO. Comment on 'Spontaneous corneal clearance despite graft detachment after Descemet membrane endothelial keratoplasty.' *Am J Ophthalmol* 2010;149:173–174; author reply 174-5
9. Zafirakis P, Kymionis GD, Grentzelos MA, et al. Corneal graft detachment without corneal edema after Descemet stripping automated endothelial keratoplasty. *Cornea* 2010;29:456–8
10. Moloney G, Petsoglou C, Ball M, et al. Descemetorhexis without grafting for Fuchs endothelial dystrophy - supplementation with topical ripasudil. *Cornea* 2017;36:642-8
11. Iovieno A, Neri A, Soldani AM, et al. Descemetorhexis without graft placement for the treatment of Fuchs endothelial dystrophy: preliminary results and review of the literature. *Cornea* 2017;36:637-41
12. Galvis V, Tello A, Berrospi RD, et al. Descemetorhexis without endothelial graft in Fuchs dystrophy. *Cornea* 2016;35:e26-8
13. Borkar DS, Veldman P, Colby KA. Treatment of Fuchs endothelial dystrophy by Descemet stripping without endothelial keratoplasty. *Cornea* 2016;35:1267-73
14. Moloney G, Chan UT, Hamilton A, et al. Descemetorhexis for Fuchs' dystrophy. *Can J Ophthalmol* 2015;50:68-72
15. Koenig SB. Planned descemetorhexis without endothelial keratoplasty in eyes with Fuchs corneal endothelial dystrophy. *Cornea* 2015;34:1149-51
16. Satué Palacián M, Sánchez Pérez A, Idoipe Corta M, et al. Descemetorhexis and corneal clearing: a new perspective on the treatment of endothelial diseases. *Arch Soc Esp Oftalmol* 2014;89:1-3
17. Koenig SB. Long-term corneal clarity after spontaneous repair of an iatrogenic descemetorhexis in a patient with Fuchs dystrophy. *Cornea* 2013;32:886-8
18. Shah RD, Randleman JB, Grossniklaus HE. Spontaneous corneal clearing after Descemet's stripping without endothelial replacement. *Ophthalmology* 2012;119:256-60

19. Bleyen I, Saelens IE, van Dooren BT, et al. Spontaneous corneal clearing after Descemet's stripping. *Ophthalmology* 2013;120:215
20. Braunstein RE, Airiani S, Chang MA, et al. Corneal edema resolution after "descemetorhexis". *J Cataract Refract Surg* 2003;29:1436-9
21. Ziaei M, Barsam A, Mearza AA. Spontaneous corneal clearance despite graft removal in Descemet stripping endothelial keratoplasty in Fuchs endothelial dystrophy. *Cornea* 2013;32:e164–6
22. Rao R, Borkar DS, Colby KA, et al. Descemet membrane endothelial keratoplasty after failed Descemet stripping without endothelial keratoplasty. *Cornea* 2017;36:763-6
23. Parker J, Verdijk RM, Müller TM, et al. Histopathology of failed Descemet membrane endothelial transfer. *Eye Contact Lens* 2018;44 Suppl 1:S361-S4
24. Arbelaez JG, Price MO, Price FW Jr. Long-term follow-up and complications of stripping Descemet membrane without placement of graft in eyes with Fuchs endothelial dystrophy. *Cornea* 2014;33:1295-59
25. Lee HJ, Munir WM. Eventual endothelial failure after initial corneal clearing after a detached endothelial graft in Fuchs dystrophy. *Cornea* 2017;36:241-3
26. Gerber-Hollbach N, Baydoun L, López EF, et al. Clinical outcome of rebubbling for graft detachment after Descemet membrane endothelial keratoplasty. *Cornea* 2017;36:771-6

Birbal RS[1-3], Hsien S[1,2], Zygoura V[1,2], Parker JS[1,4], Ham L[1-3], van Dijk K[1,2], Dapena I[1,2], Baydoun L[1,2] and Melles GRJ[1-3]

[1] *Netherlands Institute for Innovative Ocular Surgery, Rotterdam, The Netherlands*

[2] *Melles Cornea Clinic, Rotterdam, The Netherlands*

[3] *Amnitrans EyeBank, Rotterdam, The Netherlands*

[4] *Parker Cornea, Birmingham, Alabama, United States of America*

Chapter 7

Outcomes of Hemi-Descemet Membrane Endothelial Keratoplasty for Fuchs Endothelial Corneal Dystrophy

Cornea 2018;37:854-8

ABSTRACT

Purpose: To report the mid-term outcomes of Hemi-Descemet membrane endothelial keratoplasty (Hemi-DMEK) performed for Fuchs endothelial corneal dystrophy (FECD).

Methods: In this prospective, interventional case series, we evaluated clinical outcomes of 10 eyes from 10 patients who underwent Hemi-DMEK for FECD. Main outcome measures were best-corrected visual acuity (BCVA), endothelial cell density (ECD), central pachymetry and postoperative complications.

Results: At 1 year postoperatively, 7/7 eyes (excluding 2 eyes with low visual potential) reached a BCVA of ≥20/40 (≥0.5), 6/7 (86%) ≥20/25 (≥0.8), 4/7 (57%) ≥20/20 (≥1.0) and 2/7 (29%) 20/17 (≥1.2). BCVA remained stable until 2 years postoperatively ($P \geq .05$) and further improved thereafter ($P < .05$). Mean ECD declined from 2740 (±180) cells/mm^2 preoperatively to 850 (±300) cells/mm^2 (n=9) at 1 year ($P \leq .05$) and showed an annual decrease of on average 6 to 7% thereafter ($P \geq .05$ between consecutive follow-ups). Pachymetry decreased from preoperatively 745 (±153) μm to 533 (±63) μm (n=9) and 527 (±35) μm (n=8) at 1 and 3 years postoperatively, respectively. Within the first 6 postoperative months, 4/10 eyes underwent re-bubbling for visually significant graft detachment. One eye received secondary circular DMEK for persistent graft detachment 1 month postoperatively; another eye developed secondary graft failure 2.5 years postoperatively, and one eye was suspected for allograft reaction 1.5 years postoperatively.

Conclusions: Hemi-DMEK may render visual outcomes comparable to those achieved by conventional DMEK. Despite low ECD counts by 6 months, ECD levels remain fairly stable thereafter. Hence, Hemi-DMEK may become a potential alternative technique for the treatment of FECD while increasing the yield of the endothelial tissue pool.

INTRODUCTION

Descemet membrane endothelial keratoplasty (DMEK) may become the globally preferred treatment option for patients with corneal endothelial disorders.[1] Recently, we have described Hemi-Descemet membrane endothelial keratoplasty (Hemi-DMEK) as a DMEK modification that differs from conventional DMEK only in the graft shape because instead of a circular trephined DMEK graft, Hemi-DMEK utilizes an untrephined, full-diameter, semi-circular ('half-moon' shaped) graft.[2-6] There is mounting evidence that in patients with Fuchs endothelial corneal dystrophy (FECD), corneal clearance may also be obtained with different graft shapes, without a completely attached graft, and sometimes by descemetorhexis alone through host endothelial cell migration.[7-13] The advantage of Hemi-DMEK over circular DMEK is that in Hemi-DMEK two semi-circular grafts, each of the same surface area as conventional DMEK grafts, can be retrieved from one donor cornea and transplanted into two recipients, hereby potentially doubling the availability of endothelial tissue.[2-6] This new DMEK-technique may be adopted, if longer-term clinical outcomes would be similar for both techniques. With this study, we therefore furnish the extended clinical results of the first cohort undergoing Hemi-DMEK worldwide, with up to 4 years of postoperative surveillance.

MATERIALS AND METHODS

A series of 10 eyes from 10 patients underwent Hemi-DMEK for FECD (Table 1). One eye received secondary circular DMEK one month postoperatively for persistent graft detachment after unsuccessful re-bubbling, hence, the clinical outcomes of nine eyes (mean patient age: 72±9 years (range 62- 86 years)), with successful Hemi-DMEK surgery are reported in this follow-up study. All patients signed an IRB-approved informed consent form for research participation and the study adhered to the tenets of the Declaration of Helsinki.

Donor tissue preparation and Hemi-DMEK surgery

Hemi-DMEK grafts were prepared as previously described.[4] From whole donor globes obtained less than 24 hours postmortem, corneoscleral buttons were excised and stored in organ culture medium at 31°C (CorneaMax; Eurobio, Courtaboeuf, France) until the time of graft preparation; at which time the buttons were mounted endothelial side-up in a custom-made holder, bisected with a surgical knife, and Descemet membrane was stripped free from both

Table 1. Overview baseline characteristics, pre- and postoperative endothelial cell density,

Patient					Donor			Preoperative		Surgery	ECD (cells/mm^2) [ECD decrease]	
Case no.	**Age (y)**	**Sex**	**Eye**	**Lens status**	**Age (y)**	**Eye**	**ECD (cells/ mm^2)**	**BCVA (Snellen (decimal))**	**CCT (µm)**	**Graft position**	**1y FU**	**2y FU**
1	66	F	OD	Pseudo phakic	49	OD	2500	20/125 (0.15)	662	D	1010 [60%]	1000 [60%]
2	72	F	OD	Pseudo phakic	70	OD	2700	*20/125 (0.15)*	707	D	1340 [51%]	1230 [54%]
3	65	F	OD	Pseudo phakic	67	OS	2900	20/30 (0.7)	681	D	850 [71%]	830 [71%]
4	86	F	OD	Pseudo phakic	63	OD*	3000	*20/80 (0.25)*	678	H	590 [80%]	660 [78%]
5	62	F	OS	Pseudo phakic	63	OD*	3000	20/60 (0.3)	901	H	1220 [59%]	1120 [63%]
6	69	M	OS	Pseudo phakic	69	OD §	2600	20/60 (0.3)	743	H	930 [64%]	1080 [58%]
7	*83*	*F*	*OS*	*Pseudo phakic*	*73*	*OD §*	*2600*	*20/32 (0.6)*	*605*	*D*	*Re-DMEK*	
8	86	F	OD	Pseudo phakic	86	OS #	2700	20/125 (0.15)	1083	D	590 [78%]	570 [79%]
9	77	M	OD	Pseudo phakic	86	OS #	2700	20/50 (0.4)	643	V	720 [74%]	680 [75%]
10	69	M	OS	Phakic	55	OD	2600	20/32 (0.6)	603	H	440 [83%]	420 [84%]
Mean ±SD	**72 ±9**				**68 ±12**		**2740 ±180**		**745 ±153**		**850±300 [69±11]**	**840±280 [69±11]**

y= year(s); F= female; M= male; OD= right eye; OS= left eye; ECD= endothelial cell density; BCVA= best-corrected visual acuity; CCT= central corneal thickness; FU= follow-up; w= week(s); LTFU= Lost to follow-up; N/A= not available yet; ARMD= age-related macula degeneration; SGF=Secondary graft failure

best-corrected visual acuity and central corneal thickness.

ECD (cells/mm²) [ECD decrease]		BCVA (Snellen (decimal))				CCT (μm)				Remarks
3y FU	**4y FU**	**1y FU**	**2y FU**	**3y FU**	**4y FU**	**1y FU**	**2y FU**	**3y FU**	**4y FU**	
960 [62%]	LTFU	20/22 (0.9)	20/22 (0.9)	20/22 (0.9)	LTFU	527	547	539	LTFU	
1050 [61%]	960 [65%]	20/40 (0.5)	20/50 (0.4)	20/32 (0.6)	20/40 (0.5)	535	527	528	537	Amblyopic Suspected allograft reaction (1.5y)
760 [74%]	690 [76%]	20/17 (1.2)	20/17 (1.2)	20/13 (1.5)	20/17 (1.2)	490	503	508	518	
Re-DMEK		20/60 (0.3)	20/125 (0.15)	Re-DMEK		667	706	Re-DMEK		ARMD, Re-bubbling (1w), SFG (2.5y)
1010 [66%]	N/A	20/22 (0.9)	20/20 (1.0)	20/20 (1.0)	N/A	585	595	590	N/A	
700 [73%]	N/A	20/20 (1.0)	20/22 (0.9)	20/20 (1.0)	N/A	548	565	559	N/A	Re-bubbling (3w)
			Re-DMEK							*Re-bubbling (1w), secondary DMEK (1m)*
550 [80%]	N/A	20/30 (0.7)	20/32 (0.6)	20/30 (0.7)	N/A	491	501	511	N/A	
700 [74%]	N/A	20/20 (1.0)	20/25 (0.8)	20/22 (0.9)	N/A	473	479	492	N/A	
430 [83%]	N/A	20/17 (1.2)	20/2 (1.0)	20/20 (1.0)	N/A	477	486	486	N/A	Re-bubbling (4w)
770 ±220 [72±8]						**533 ±63**	**545 ±71**	**527 ±35**		

Graft orientation: H: Long graft edge oriented horizontally; D: Long graft edge oriented diagonally; V: Long graft edge oriented vertically

*,§, # Hemi-DMEK grafts originated from the same donor eye. *Italics* = excluded from current analysis

corneal halves using fine forceps to produce two semi-circular ('half-moon' shaped) endothelial grafts. Endothelial cell morphology and viability were evaluated before and after Descemet stripping. Hemi-DMEK grafts were then stored in organ culture medium until the time of transplantation.[4]

Hemi-DMEK surgery could be completed with minor modifications compared to conventional DMEK.[2,14] After a circular descemetorhexis (on average 8-9 mm) was performed under air using a reversed Sinskey hook (DORC International, Zuidland, The Netherlands), the donor tissue was removed from organ culture, rinsed with balanced salt solution (BSS), stained with Trypan Blue 0.06% (VisionBlue; DORC International), and injected into the eye via a glass pipette (Melles glass inserter, DORC International). Indirect manipulations including taps on the external corneal surface and bursts of BSS were used for unfolding, after which the graft was lifted up to the posterior corneal surface by an air bubble. Subsequently, a complete air fill was maintained for 60 to 90 minutes, followed by a partial air-fluid exchange intending to leave the eye with an air bubble occupying 30% to 50% of the volume of the anterior chamber for graft support. Hemi-DMEK was performed by three experienced surgeons.

The postoperative medication regime resembled that followed after conventional DMEK, including topical steroids tapered to once daily over one year, which was, in some cases, further reduced to once every other day thereafter.[14]

Data collection

Routine follow-up appointments were scheduled for 1 day, 1 week, 1, 3, 6, 9 and 12 months, and every 6 months thereafter for assessing best-corrected visual acuity (BCVA), pachymetry (Pentacam HR, Oculus Optikgeräte GmbH, Wetzlar, Germany), anterior segment optical coherence tomography (Heidelberg Slit Lamp-OCT; Heidelberg Engineering GmbH, Heidelberg, Germany) and endothelial cell density (ECD), which was evaluated *in vivo* using a Topcon SP3000p non-contact autofocus specular microscope (Topcon Medical Europe BV, Capelle a/d Ijssel, the Netherlands). Images of the central corneal window were analyzed and manually corrected; up to three measurements of ECD were averaged (if the central endothelium could not be visualized, paracentral images were used for analysis).

Statistics

All analyses were performed using Excel Software for Windows. BCVA outcomes were converted to logarithm of the minimum angle of resolution (LogMAR) units to enable statistical analysis. The independent paired Student t-test was applied to assess differences between consecutive follow-up time points. $P < 0.05$ was considered statistically significant.

RESULTS

Clinical outcome

All corneas with successful Hemi-DMEK cleared by 6 months, and BCVA improved in all eyes (n=9). At 1 year postoperatively, all eyes (excluding two with low visual potential; n=7) attained a BCVA of ≥20/40 (≥0.5), 6/7 (86%) eyes ≥20/25 (≥0.8), 4/7 (57%) eyes ≥20/20 (≥1.0) and 2/7 (29%) eyes 20/17 (≥1.2) (Table 1; Fig. 1). BCVA remained stable until 2 years postoperatively ($P \geq 0.05$) and further improved thereafter ($P < 0.05$) (Table 1; Fig. 1).

Donor ECD decreased within the first postoperative year from 2740 (±180) cells/mm^2 before surgery (n=9) to 940 (±380) cells/mm^2 at 6 months (n=9), and 850 (±300) cells/mm^2 at 1 year after surgery (n=9) ($P < 0.05$) and showed on average an annual decrease of 6 to 7% thereafter ($P \geq 0.05$ between con-

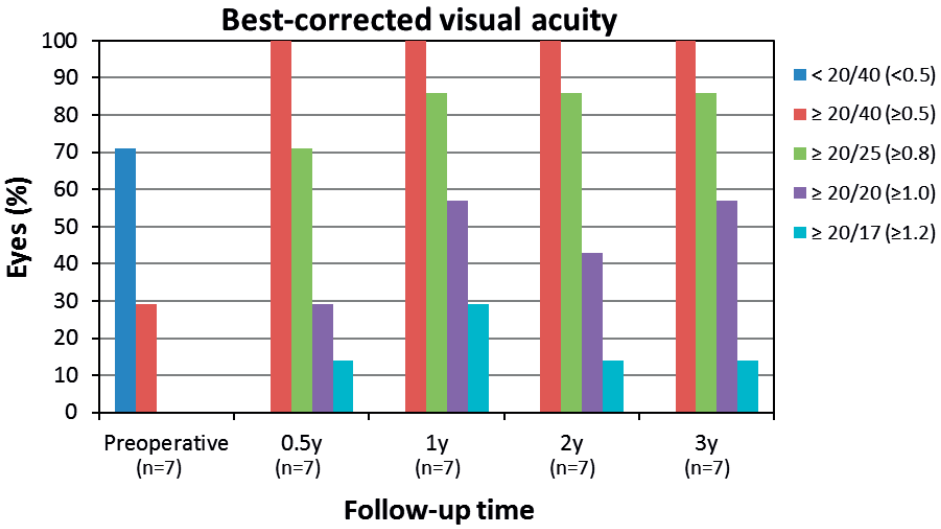

Figure 1. Bar graph displaying the best-corrected visual acuity. Best-corrected visual acuity (BCVA) is shown preoperatively and up to 3 years after Hemi-Descemet membrane endothelial keratoplasty (Hemi-DMEK).

secutive follow-ups) (Table 1; Fig. 2) with a yearly ECD decline comparable to conventional DMEK (Fig. 2).[15]

Mean pachymetry decreased from preoperatively 745 (±153) μm to 533 (±63) μm (n=9) and 527 (±35) μm (n=8) at 1 and 3 years postoperatively, respectively.

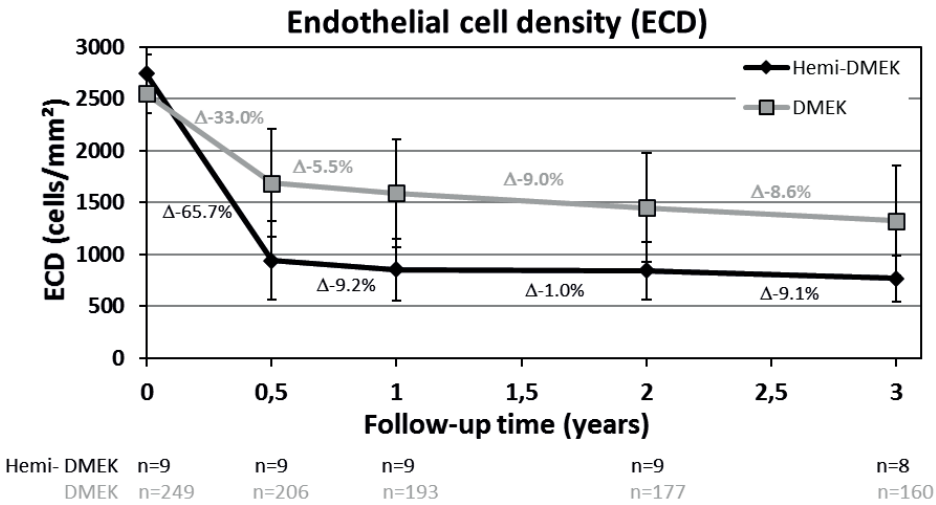

Figure 2. Graphs displaying mean endothelial cell density (ECD) before and up to 3 years after Hemi-DMEK and conventional DMEK. Percentages between follow-up time points represent the ECD decrease (Δ) between consecutive time points. Data for ECD decrease after conventional DMEK are taken from Ref. 15.

Complications

In the early postoperative period, 4 eyes (Cases 4, 6, 7 and 10) had visually significant graft detachment that required re-bubbling. In one of these eyes (Case 7) the detachment persisted and the eye therefore underwent secondary circular DMEK one month postoperatively; however also the circular graft showed poor graft attachment. Another re-bubbled eye (Case 4) developed secondary graft failure 2.5 years after Hemi-DMEK and was successfully re-operated with conventional circular DMEK. Except for a strongly adherent Hemi-DMEK graft, re-intervention was uneventful. Beyond 6 months postoperatively, one eye (Case 2) was suspected to have developed an allograft reaction at the 1.5 year-follow-up, which was successfully reversed by an intensified regimen of topical steroid therapy.

DISCUSSION

Theoretically, Hemi-DMEK represents an attractive surgical option because, if also successful in the longer term, it may potentially increase the amount of available corneal donor tissue. Previously, we reported our 6-month results for this first worldwide cohort of eyes undergoing Hemi-DMEK and the 3-year outcomes of the first three operated cases;[5,6] in this study, we describe the clinical course of 3 to 4 years of follow-up for this cohort.

As expected, BCVA after Hemi-DMEK may resemble that of conventional DMEK. The early and quick initial visual recovery was followed by a further improvement at the end of the follow-up period.[5,15,16] Still, entire corneal clearance after Hemi-DMEK may be a bit slower than after conventional DMEK due to the bare areas resulting from the mismatch of the circular descemetorhexis and the semi-circular Hemi-DMEK graft; however, all corneas with successful Hemi-DMEK were clear 6 months postoperatively (Fig. 3).[15,16]

In contrast to conventional DMEK, our study and previously published reports show that the initial sharp decline in ECD within the first 6 months is considerably higher after Hemi-DMEK (34% versus 65%).[2,6,15] This may be explained by different patterns of endothelial cell redistribution and migration after Hemi-DMEK compared with conventional DMEK, because of larger stromal bare areas. In addition, ECD measurements at different graft areas (centrally for conventional DMEK, and more peripheral or at the graft edge for Hemi-DMEK) may produce this difference in the ECD decrease.[2,3.6] Interestingly, contrary to our previously published report on the clinical outcomes of the very first 3 Hemi-DMEK eyes, in this 'larger' cohort a yearly ECD decrease of 6 to 7% could be observed, which would be similar for both DMEK-techniques.[6,15,17] Hence, the ECD decrease after this early drop may be caused by similar mechanisms in both DMEK-techniques.

As with conventional DMEK, after Hemi-DMEK, the main early complication was graft detachment, for which re-bubbling was required in 4/10 (40%) eyes. A possible explanation for the higher detachment rate after Hemi-DMEK than after conventional DMEK might be a 'learning curve' effect of this modified technique. The difference in graft shape may be another reason, since the Hemi-DMEK graft has one shorter axis, an edge detachment in the central graft area may more often affect the visual axis prompting faster re-bubbling.[16] Interestingly, the eye that received conventional DMEK one month postopera-

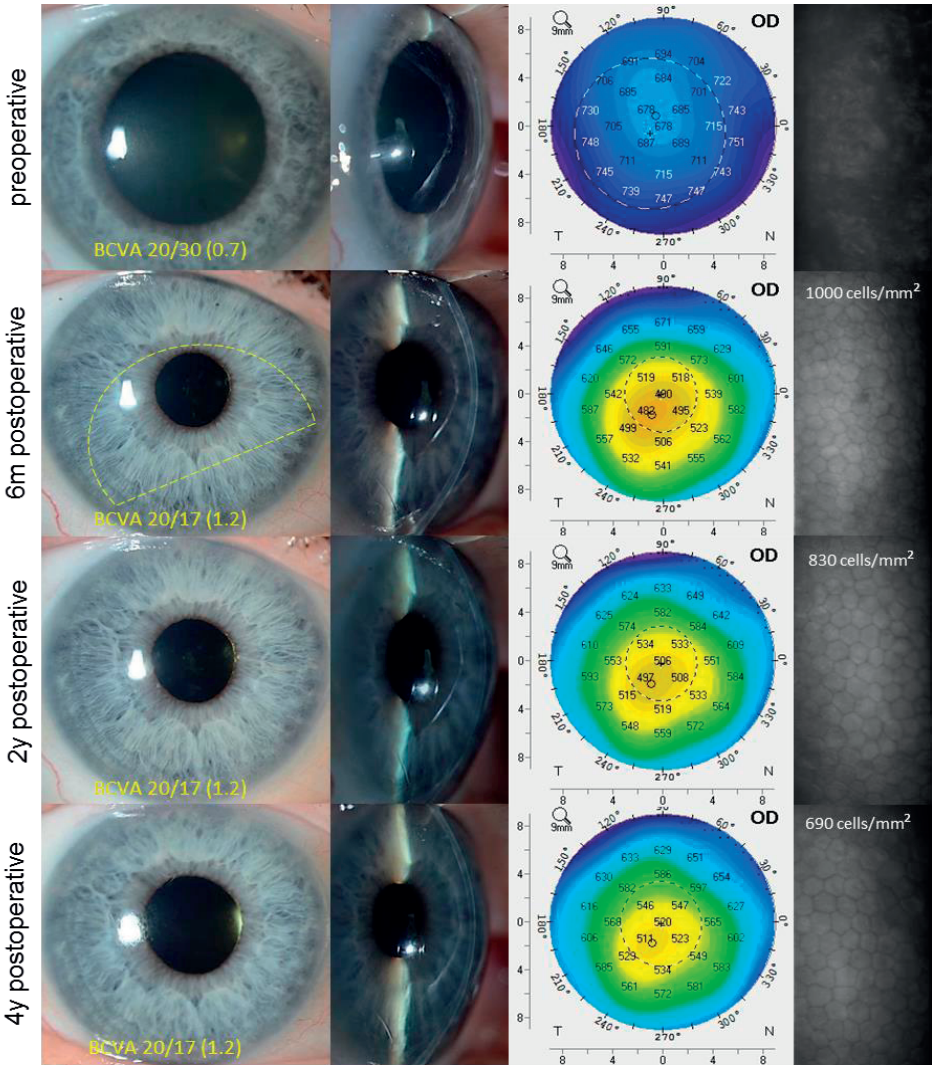

Figure 3. Slit-lamp, pachymetry and specular microscopy images before and after Hemi-Descemet membrane endothelial keratoplasty. Images are shown preoperatively (top row), at 6 months (second row), at 2 years (third row) and at 4 years (bottom row) after Hemi-DMEK (Case 3). The intermitted yellow line outlines the position of the Hemi-DMEK graft. Note continuous corneal clearance at 6 months, 2 years and 4 years as shown in slit-lamp images (left 2 columns).

tively after failed re-bubbling, also showed poor attachment of the circular DMEK graft, which suggests that there may also be recipient-related factors influencing graft attachment. One of the other re-bubbled eyes developed secondary graft failure 2.5 years after Hemi-DMEK. In the longer term, one eye

was suspected of having a mild allograft reaction. All other grafts remained clear, and no further complications were observed throughout the study period.

Theoretically, Hemi-DMEK allows to utilize two endothelial transplants originating from the same donor cornea. In this study, this approach was successful in 2 pairs (Cases 4/5 and Cases 8/9, Table 1). However, for a wider-spread clinical application of multiple endothelial grafts from the same donor cornea, eye banks may need to decide about the feasibility of allocating multiple grafts from one donor cornea and about more critical logistics because multiple grafts from one donor cornea with poor endothelial cell viability (although ECD may be high) may result in graft-related complications (i.e. graft detachment or failure) in multiple recipients.

Overall, although our case series was limited in size, the outcome after Hemi-DMEK may be encouraging since the procedure may allow for clinical outcomes similar to conventional DMEK and the procedure may potentially increase the yield of endothelial tissue from the same donor pool. Furthermore, in more complex eyes with anterior synechiae, glaucoma tubes and/or anterior segment dysgenesis, Hemi-DMEK may be considered over conventional DMEK as it may be easier to position and accommodate the graft in recipient eyes with asymmetrical anterior chamber dimensions. Hemi-DMEK may therefore become an alternative to conventional DMEK.

REFERENCES

1. Eye Bank Association of America. *2016 Eye Banking Statistical Report* Washington, D.C.: Eye Bank Association of America; 2017
2. Lam FC, Baydoun L, Dirisamer M, et al. Hemi-Descemet membrane endothelial keratoplasty transplantation: a potential method for increasing the pool of endothelial graft tissue. *JAMA Ophthalmol* 2014;132:1469-73
3. Lam FC, Baydoun L, Satué M, et al. One year outcome of hemi-Descemet membrane endothelial keratoplasty. *Graefes Arch Clin Exp Ophthalmol* 2015;253:1955-8
4. Lie JT, Lam FC, Groeneveld-van Beek EA, et al. Graft preparation for hemi-Descemet membrane endothelial keratoplasty (hemi-DMEK). *Br J Ophthalmol* 2016;100:420-4
5. Gerber-Hollbach N, Parker J, Baydoun L, et al. Preliminary outcome of hemi-Descemet membrane endothelial keratoplasty for Fuchs endothelial dystrophy. *Br J Ophthalmol* 2016;100:1564-8
6. Müller TM, Baydoun L, Melles GR. 3-Year update on the first case series of hemi-Descemet membrane endothelial keratoplasty. *Graefes Arch Clin Exp Ophthalmol* 2017;255:213-5
7. Tourtas T, Heindl LM, Kopsachilis N, et al. Use of accidentally torn Descemet membrane to successfully complete Descemet membrane endothelial keratoplasty. *Cornea* 2013;32:1418-22
8. Müller TM, Lavy I, Baydoun L, et al. Case report of Quarter-Descemet membrane endothelial keratoplasty for Fuchs endothelial dystrophy. *Cornea* 2017;36:104-7
9. Dirisamer M, Ham L, Dapena I, et al. Descemet membrane endothelial transfer: 'free-floating' donor Descemet implantation as a potential alternative to 'keratoplasty'. *Cornea* 2012;31:194–7
10. Balachandran C, Ham L, Verschoor CA, et al. Spontaneous corneal clearance despite graft detachment in Descemet membrane endothelial keratoplasty. *Am J Ophthalmol* 2009;148:227–34
11. Moloney G, Petsoglou C, Ball M, et al. Descemetorhexis without grafting for Fuchs endothelial dystrophy - supplementation with topical ripasudil. *Cornea* 2017;36:642-8
12. Iovieno A, Neri A, Soldani AM, et al. Descemetorhexis without graft placement for the treatment of Fuchs endothelial dystrophy: preliminary results and review of the literature. *Cornea* 2017;36:637-41
13. Borkar DS, Veldman P, Colby KA. Treatment of Fuchs endothelial dystrophy by Descemet stripping without endothelial keratoplasty. *Cornea* 2016;35:1267-73
14. Dapena I, Moutsouris K, Droutsas K, et al. Standardized "no-touch" technique for Descemet membrane endothelial keratoplasty. *Arch Ophthalmol* 2011;129:88-94
15. Ham L, Dapena I, Liarakos VS, et al. Midterm results of Descemet membrane endothelial keratoplasty: 4 to 7 years clinical outcome. *Am J Ophthalmol* 2016;171:113-21
16. Rodriguez-Calvo-de-Mora M, Quilendrino R, Ham L, et al. Clinical outcome of 500 consecutive cases undergoing Descemet's membrane endothelial keratoplasty. *Ophthalmology* 2015;122:464–70
17. Baydoun L, Tong CM, Tse WW, et al. Endothelial cell density after Descemet membrane endothelial keratoplasty: 1 to 5-year follow-up. *Am J Ophthalmol* 2012;154:762-3

Birbal RS[1-3], Ní Dhubhghaill S[1,2,4], Baydoun L[1,5], Ham L[1-3], Bourgonje VJA[1,2], Dapena I[1,2], Oellerich S[1] and Melles GRJ[1-3,6]

[1] *Netherlands Institute for Innovative Ocular Surgery (NIIOS), Rotterdam, The Netherlands*

[2] *Melles Cornea Clinic, Rotterdam, The Netherlands*

[3] *Amnitrans EyeBank, Rotterdam, The Netherlands*

[4] *Antwerp University Hospital, Edegem, Belgium*

[5] *University Hospital Münster, Münster, Germany*

[6] *NIIOS-USA, San Diego, California, United States of America*

Chapter 8

Quarter-Descemet Membrane Endothelial Keratoplasty: One- to Two-Year Clinical Outcomes

Cornea 2020;39:277-82

ABSTRACT

Purpose: To report clinical outcomes of the first Quarter-Descemet membrane endothelial keratoplasty (Quarter-DMEK) case series performed for central Fuchs endothelial corneal dystrophy.

Methods: This is a prospective, interventional case series analyzing the clinical outcomes of 19 eyes of 19 patients with central FECD, that is, with guttae predominantly in the 6- to 7-mm optical zone, who underwent unilateral Quarter-DMEK at a tertiary referral center. Main outcome measures were best-corrected visual acuity (BCVA), endothelial cell density (ECD), and postoperative complications. Included eyes had up to 2 years of postoperative follow-up.

Results: At 6 months postoperatively, all eyes reached a BCVA of ≥20/40 (≥0.5); 18 of 19 eyes (95%) ≥20/25 (≥0.8) and 9 of 19 eyes (42%) ≥20/20 (≥1.0). Thereafter, BCVA remained stable up to 2 years postoperatively. The mean donor ECD decreased from 2842 ±139 cells/mm^2 (n=19) before implantation to 913± 434 cells/mm^2 (-68%) at 6 months (n=19), 869 ±313 cells/mm^2 (-70%) at 12 months (n=18) and 758 ±225 cells/mm^2 (-74%) at 24 months (n=13) after Quarter-DMEK. Visually significant graft detachment requiring re-bubbling occurred in 8 of 19 eyes (42%).

Conclusions: Quarter-DMEK surgery yields visual outcomes similar to those of conventional DMEK and may potentially quadruple the availability of endothelial grafts. Further modifications of the graft preparation and the surgical technique may improve clinical outcomes in terms of lower ECD decrease and fewer graft detachments.

INTRODUCTION

Descemet membrane endothelial keratoplasty (DMEK) may currently be the most advanced technique in the management of corneal endothelial disorders.[1,2] In an effort to further increase donor tissue availability, in particular of endothelial grafts, Hemi-DMEK (semi-circular, 'half-moon' shaped graft instead of a conventional, circular graft of same surface area) was introduced in 2014 as a DMEK modification.[3] In 2016, this technique was further refined into Quarter-DMEK, where only a smaller graft, that is, one quadrant of a full-diameter donor Descemet membrane (DM) graft was transplanted into eyes with Fuchs endothelial corneal dystrophy (FECD), provided that it was limited to the central 6- to 7-mm optical zone of the cornea.[4]

We previously reported the 6-month clinical outcomes of the first 12 eyes that underwent Quarter-DMEK in our center and showed that this new technique was not only feasible but also resulted in good clinical outcomes in terms of best-corrected visual acuity (BCVA) up to 6 months postoperatively.[5] If longer-term outcomes would mimic those of conventional DMEK, Quarter-DMEK may have the potential to provide a far more efficient use of donor tissue. The aim of this study was therefore to evaluate the clinical results of the first Quarter-DMEK cohort of 19 eyes up to 2 years postoperatively.

METHODS

Patient data

A series of 19 eyes from 19 patients [mean age 66 (±9) years; range 56-82 years] underwent Quarter-DMEK for clinically significant central FECD, that is, with guttae predominantly in the central 6- to 7-mm optical zone of the cornea. Additional patient selection criteria entailed 1) mild to no FECD in the corneal periphery and 2) no other ocular comorbidities. Twelve eyes were pseudophakic and 7 eyes phakic (Table 1). All eyes had completed the 6-month follow-up, 18 eyes had completed the 12-month follow-up, and 13 eyes had completed the 24-month follow-up. The study received ethical approval (METC Zuidwest Holland), an institutional review board-approved informed consent was obtained from all patients before surgery and the study adhered to the tenets of the Declaration of Helsinki.

Donor tissue preparation

Quarter-DMEK donor tissue preparation was performed by a single experienced eye bank technician, as previously described.[4] In short, from whole donor globes obtained less than 24 hours postmortem, corneoscleral buttons were excised and stored in organ culture medium at 31°C (CorneaMax, Eurobio, Courtaboeuf, France) until graft preparation. The corneoscleral buttons were mounted endothelial side up on a custom-made holder with a suction cup and using a hockey stick knife (DORC International, Zuidland, The Netherlands) peripheral DM with its adjacent trabecular meshwork was loosened over 360 degrees. Using a surgical blade (no. 24 knife, Swann-Morton, Sheffield, UK), the buttons were then dissected into 4 equally sized quarters. DM was centripetally peeled from the underlying posterior stroma of each quarter, yielding four DM rolls. Endothelial cell morphology and viability were evaluated before and after graft preparation. Quarter-DMEK grafts were then stored in organ culture medium until the time of transplantation. After preparation, the mean Quarter-DMEK graft storage time was 5.9 (±1.7) days (Table 1). The 19 Quarter-DMEK grafts were prepared from 15 corneal buttons of 14 donors with a mean age of 69 (±9) years (range 51-84), that is, from 4 donor corneas, 2 Quarter-DMEK grafts were transplanted, while from the other 11 donor corneas, only a single Quarter-DMEK graft was used (Table 1). The other potential Quarter-DMEK grafts (n=41) were used either as back-up grafts during surgery or for research purposes.

Table 1. Demographics Quarter-Descemet membrane endothelial keratoplasty eyes and donors.

		(n)
Number of eyes/patients		19/19
Gender (female/male)	68% / 32%	(13/6)
Mean age (±SD) in years	66 (±9)	
Preoperative lens status		
Pseudophakic	63%	(12)
Phakic	37%	(7)
Number of corneas/donors		15/14
Donor age (±SD) in years	69 (±9)	
Donor gender (female/male)	29% / 71%	(4/10)
Donor death cause		
Cancer	29%	(4)
Cardiovascular/Stroke	50%	(7)
Respiratory	7%	(1)
Trauma	7%	(1)
Other	7%	(1)
Graft storage time in medium (±SD) in d		
Total	18.7 (±27.5)	
From preparation to surgery	5.9 (±1.7)	

d=days; n= number; SD= Standard deviation

Quarter-DMEK surgery

Quarter-DMEK surgery was performed according to the standardized no-touch DMEK technique with a few modifications.[4-6] Using a reversed Sinskey hook (DORC International), a descemetorhexis of approximately 7 to 8 mm was made under air. The Quarter-DMEK graft was thoroughly rinsed with balanced salt solution to fully eliminate the organ culture medium and stained with 0.06% Trypan blue (VisionBlue; DORC International). The graft was then aspirated into a curved glass injector (Melles glass inserter, DORC International) and injected into the recipient's anterior chamber. The Moutsouris sign was confirmed to ensure correct graft orientation, that is, with the endothelium facing the iris. The graft was unfolded and centered over the iris by indirect manipulations of the tissue through air, balanced salt solution and strokes on the outer corneal surface; and then elevated to the posterior corneal surface using an air bubble. At conclusion of the operation, a complete air fill of the anterior chamber was maintained for a period of 60 minutes, after which a partial air-fluid exchange was carried out to leave an estimated residual air bubble of 30% to 50% of the anterior chamber volume. Postoperative topical medication was identical to the protocol following conventional DMEK.[6]

Data collection and statistical analysis

Recipient eyes underwent ophthalmic examination at 1 day, 1 week, 1, 3, 6, 9, 12 and 24 months postoperatively. BCVA was measured using a Snellen letter chart, and the outcomes were converted to logarithm of the minimum angle of resolution (logMAR) units to enable statistical analysis. BCVA was defined as stable for changes ≤1 Snellen lines, and as improving or deteriorating for changes ≥2 Snellen lines. Intraocular pressure (IOP) was measured with applanation tonometry and increased IOP after Quarter-DMEK was defined as an IOP ≥24 mm Hg or an increase in IOP of ≥10 mm Hg from baseline. The eyes were examined with slit-lamp biomicroscopy, anterior segment ocular coherence tomography (Slit-lamp-OCT; Heidelberg Engineering, Heidelberg, Germany) and rotating Scheimpflug corneal tomography (Pentacam HR, Oculus Optikgeräte, Wetzlar, Germany). In addition, non-contact autofocus specular microscopy (Topcon SP3000p, Topcon Medical Europe, Capelle a/d IJssel, The Netherlands) was performed to evaluate postoperative endothelial cell density (ECD). Images of the central corneal window were analyzed and manually corrected by a trained technician; for each follow-up time point, up to 3 measurements of ECD were averaged. The independent paired Student *t* test was applied to assess differences between consecutive follow-up time points. $P < 0.05$ was considered statistically significant.

RESULTS

Clinical outcomes

At 6 months postoperatively, BCVA improved in 14 of 19 eyes (74%) and remained stable in 5 of 19 eyes (26%). The latter eyes all had a preoperative BCVA of 0.7 or higher. At 6 months after Quarter-DMEK, 19 of 19 eyes (100%) reached a BCVA of ≥20/40 (≥0.5); 18 of 19 eyes (95%) ≥20/25 (≥0.8) and 9 of 19 eyes (42%) ≥20/20 (≥1.0) (Table 2; Fig. 1A). Thereafter, BCVA remained stable up to 2 years postoperatively ($P \geq 0.05$).

Table 2. Clinical outcomes up to 2 years after Quarter-Descemet membrane endothelial keratoplasty for central Fuchs endothelial corneal dystrophy.

Clinical outcome	Preoperative (n=19)	At 6-Month Follow-up (n=19)	At 12-Month Follow-up (n=18)	At 24-Month Follow-up (n=13)
BCVA				
<20/40 (< 0.5)	31.6%	-	-	-
≥ 20/40 (≥ 0.5)	68.4%	100%	100%	100%
≥ 20/25 (≥ 0.8)	26.3%	94.7%	88.9%	84.6%
≥ 20/20 (≥ 1.0)	5.3%	42.1%	50.0%	38.5%
≥ 20/17 (≥ 1.2)	-	15.8%	22.2%	7.7%
Mean BCVA (±SD), (logMAR)	0.28 (±0.19)	0.04 (±0.08)	0.03 (±0.09)	0.05 (±0.07)
Change in BCVA from preoperative to FU, n (Percentage)				
Improved (≥2 Snellen lines)		14 (74%)	13 (72%)	11 (85%)
Unchanged (≥ 1 Snellen line)		5 (26%)	5 (28%)	2 (15%)
Worsened (≤ 2 Snellen lines)		0 (0%)	0 (0%)	0 (0%)
ECD (±SD), (cells/mm^2)	2842 (±139)	913 (±434)	869 (±313)	758 (±225)
ECD Decrease (±SD), (%) *		68 (±15)	70 (±11)	74 (±7)
Pachymetry (±SD), (μm)	639 (±89)	550 (±49)	555 (±51)	548 (±38)
Pachymetry Decrease (±SD), (%) *		12 (±14)	12 (±14)	15 (±14)

*Decrease as compared to preoperative values
BCVA: Best-corrected visual acuity
ECD: Endothelial cell density

Donor ECD averaged 2842 (±139) cells/mm^2 before surgery (n=19) and 913 (± 434) cells/mm^2 (-68%) at 6 months (n=19), 869 (±313) cells/mm^2 (-70%) at 12 months (n=18) and 758 (±225) cells/mm^2 (-74%) at 24 months after surgery (n=13) (Table 2, Fig. 1B). The annual ECD decrease rate from 12 to 24 months was 12.8% (Fig. 1B).

Mean pachymetry decreased from 639 (±89) μm (n=19) before surgery, to 550 (±49) μm at 6 months (n=19), 555 (±51) μm at 12 months (n=18) and 549 (±38) μm at 24 months after Quarter-DMEK (n=13).

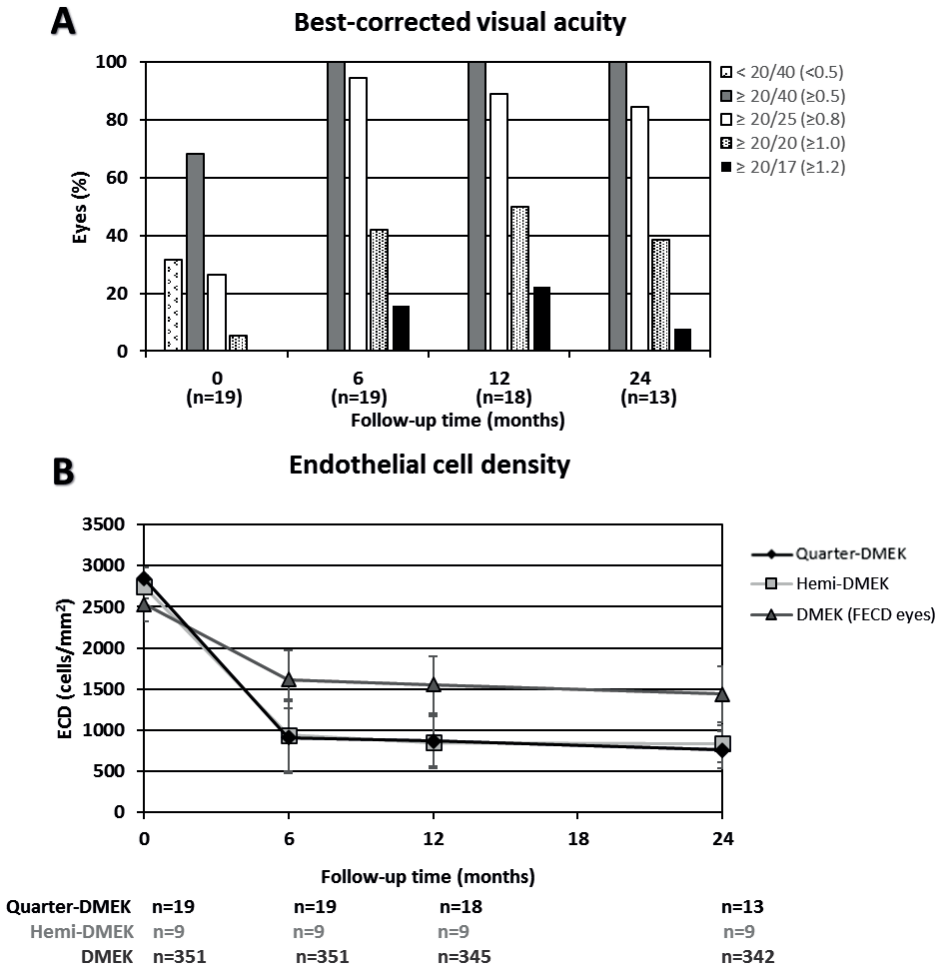

Figure 1. Best-corrected visual acuity and endothelial cell density before and up 2 years after Quarter-Descemet membrane endothelial keratoplasty. (A) Bar graph displaying best-corrected visual acuity (BCVA) for all time points. (B) Graphs displaying mean endothelial cell density (ECD) for all time points. For comparison, ECD values for Hemi-DMEK (extracted from Ref. 7) and conventional DMEK (taken from Ref. 8) are also included.

Postoperative complications and graft survival

In the early postoperative phase, 8 of 19 eyes (42%) showed visually significant graft detachment requiring a re-bubbling procedure, which was successful in all eyes. At the latest available follow-up visit, 12 of 19 eyes (63%) showed complete corneal clearance (Fig. 2), while 7 of 19 eyes (37%) showed a clear corneal center but persistent edema, sometimes accompanied by bullae, along the limbal round edge of the Quarter-DMEK graft or in one of the de-

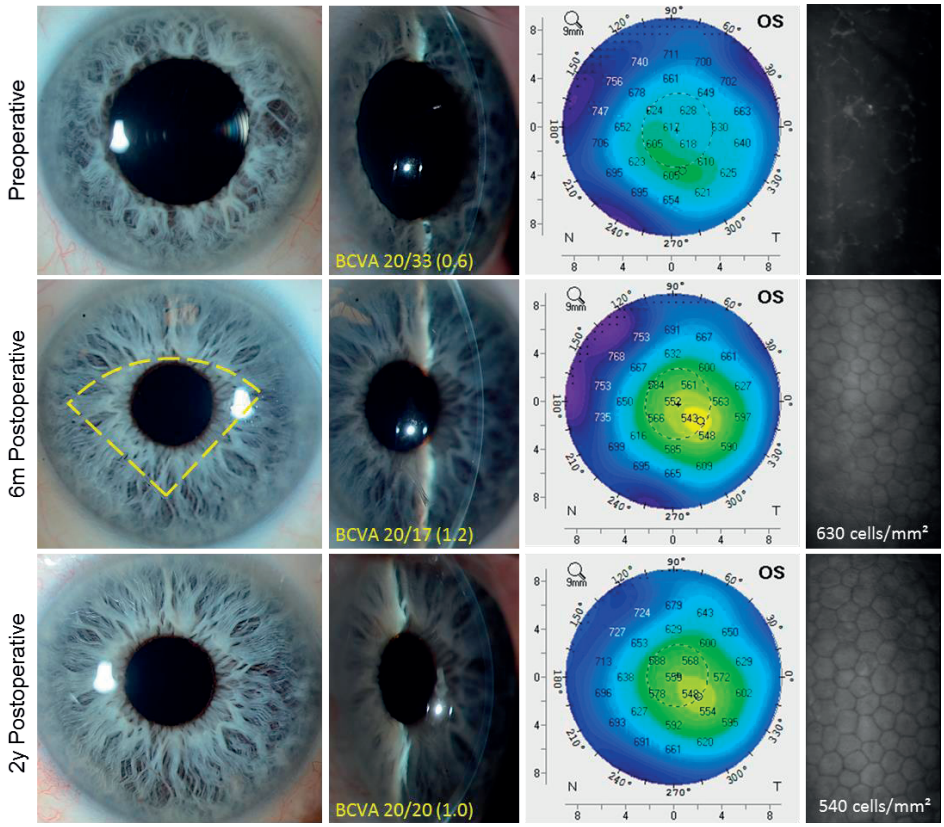

Figure 2. Slit-lamp images, pachymetry maps and central specular microscopy images before and after Quarter-Descemet membrane endothelial keratoplasty. Images are shown preoperatively (top row), at 6 months (middle row) and at 2 years (bottom row) after Quarter-DMEK. The intermitted yellow triangle outlines the approximate position of the Quarter-DMEK graft. Best-corrected visual acuity (BCVA) values in the second left column are reported in Snellen (Decimal); OS= oculus sinister.

nuded areas adjacent to the graft (Fig. 3). None of the patients with persistent peripheral corneal edema experienced any discomfort from it, and none of them developed any complications possibly related to the edema. In 2 of 19 eyes (11%) subtle graft fibrosis was observed along the round edge of the Quarter-DMEK graft (Fig. 3).

Two patients displayed persistent steroid-induced ocular hypertension after Quarter-DMEK. In both cases, the pressure was managed by instituting topical anti-glaucoma medication and an expedited tapering of the topical corticosteroids for the first patient and earlier transitioning from topical dexamethasone to topical fluorometholone for the second.

Allograft rejection and secondary graft failure did not occur throughout the study period, and none of the eyes required re-transplantation.

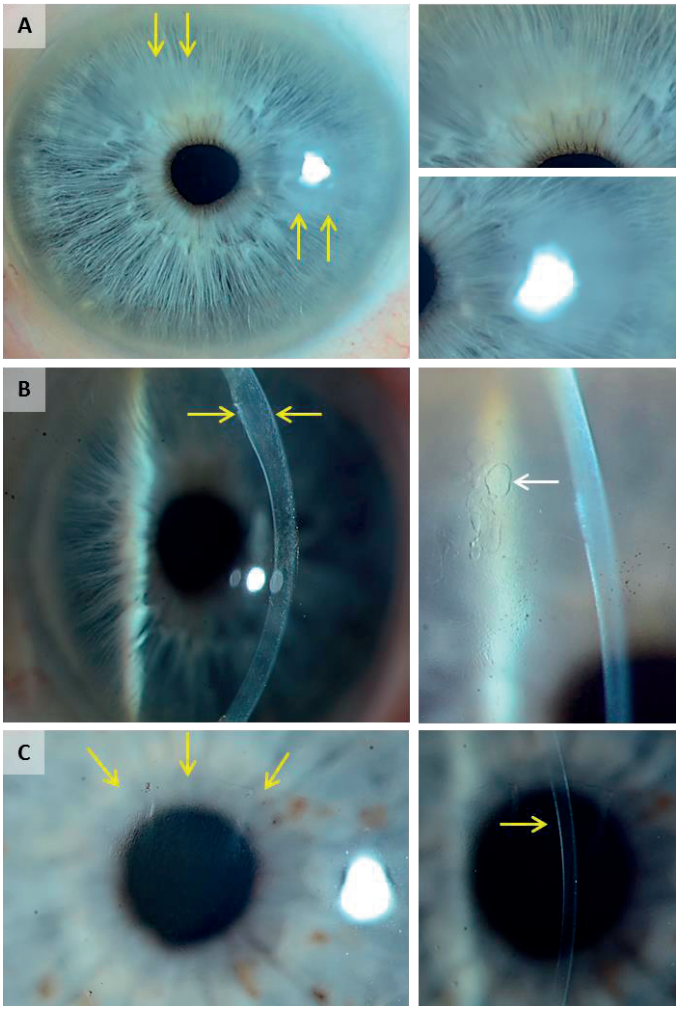

Figure 3. Slit-lamp images of an eye at 2 years after Quarter-Descemet membrane endothelial keratoplasty. (Top row, A) The intermitted white triangle outlines the approximate position of the Quarter-Descemet membrane endothelial keratoplasty (Quarter-DMEK) graft, and the yellow arrows indicate areas with persisting edema; along the round limbal edge of the graft and in the bare area temporal of the graft. (Middle row, B) The yellow arrows highlight edema in the superior part of the cornea, which in this eye is accompanied by bullae, highlighted with the white arrow. (Bottom row, C) The yellow arrows indicate graft fibrosis along the round limbal edge of the Quarter-DMEK graft.

DISCUSSION

The past 20 years of corneal endothelial transplantation techniques have been focused on reducing the amount of tissue transplanted, so that only the damaged layer of the cornea is replaced.[2,9] In Quarter-DMEK, the aim was to go one step further in patients with central FECD.[4] In these cases, only the central portion of the corneal endothelium was removed and replaced with a smaller graft, preserving more of the patient's own peripheral endothelial cells. This has the theoretical benefit of reduced donor antigen load, and the benefit of potentially quadrupling the amount of donor tissue available for transplantation.[5] In the current study, we reported clinical outcomes of 19 consecutive Quarter-DMEK cases up to 2 years postoperatively.

BCVA values after Quarter-DMEK reflected those after conventional and Hemi-DMEK. Fast visual rehabilitation within the first 6 months postoperatively was followed by a stabilization of BCVA throughout the study period. As expected, corneal clearance was less rapid after Quarter-DMEK compared to conventional DMEK and, in particular, lagged behind along the round limbal edge of the Quarter-DMEK graft and the adjacent bare stromal areas.[5] Recently, we showed that asymmetrical endothelial cell migration of Quarter-DMEK grafts *in vitro* may explain this corneal clearance pattern, with cell migration predominantly occurring from the radial cut edges, but not the round edge.[10] Additional studies investigating whether these peripheral cells constitute a valuable cellular reserve are required to optimize this technique.

Visually significant graft detachment requiring re-bubbling (42%) occurred in a similar rate compared with after Hemi-DMEK (40%), but a slightly higher rate compared with the first 25 cases of the initial conventional DMEK case series (36%).[7,11] This may be related to more difficult graft handling during surgery, but it may also be because edge detachments of these grafts almost always involve the visual axis, prompting re-bubbling more quickly.

A larger concern is the 68% drop in ECD in the early postoperative phase. In the first 6 months after Quarter-DMEK surgery, ECD decreased more steeply compared with that after conventional DMEK but resembled the sharp initial decline after Hemi-DMEK. Thereafter, all three DMEK-techniques showed a similar gradual yearly decline.[7,8] Eliminating the method error as a confounding variable, it was shown before for DMEK eyes that the largest drop in ECD from 1 day postoperative to 6 months postoperative may occur in the first week

postoperatively, and that a large proportion of the decrease from preoperative to 1 day postoperative may be because of preoperative overestimation of the viable cell count and increased surgical manipulation.[12] Another explanation could be a mismatch between the larger descemetorhexis and the smaller triangular-shaped Quarter-DMEK graft, resulting in larger areas of bare stroma that must be colonized by migrating donor cells. To date, no Quarter-DMEK graft has decompensated or required a re-operation but longer-term studies are required to determine how long the current BCVA outcomes can be maintained.

Before implementing Quarter-DMEK into clinical practice on a larger scale, it should be considered that the Quarter-DMEK technique may still be in progress and studies are underway to evaluate whether the procedure would benefit from a smaller descemetorhexis (diameter) aiming to reduce the surface of the bare areas that need to be repopulated by endothelial cells, adapting graft preparation to reduce the loss of cells along the radial cut edges of the graft, and/or removing the round peripheral edge of the Quarter-DMEK graft to promote cell migration toward the adjacent bare area in the corneal periphery.

In conclusion, Quarter-DMEK yields visual outcomes similar to those after conventional DMEK and may potentially increase availability of endothelial donor tissue. However, to obtain improved clinical outcomes, endothelial cell counts, and graft longevity, the acute drop in ECD must be addressed. If this can be improved to the level of conventional DMEK, the potential benefit from a single corneal donor could, in theory, be quadrupled for these central FECD cases.

REFERENCES

1. Melles GR, Ong TS, Ververs B, et al. Descemet membrane endothelial keratoplasty (DMEK). *Cornea* 2006;25:987-90
2. Van den Bogerd B, Dhubhghaill SN, Koppen C, et al. A review of the evidence for in vivo corneal endothelial regeneration. *Surv Ophthalmol* 2018;63:149-65
3. Lam FC, Baydoun L, Dirisamer M, et al. Hemi-Descemet membrane endothelial keratoplasty transplantation: a potential method for increasing the pool of endothelial graft tissue. *JAMA Ophthalmol* 2014;132:1469-73
4. Müller TM, Lavy I, Baydoun L, et al. Case report of Quarter-Descemet membrane endothelial keratoplasty for Fuchs endothelial dystrophy. *Cornea* 2017;36:104-7
5. Zygoura V, Baydoun L, Ham L, et al. Quarter-Descemet membrane endothelial keratoplasty (Quarter-DMEK) for Fuchs endothelial corneal dystrophy: 6 months clinical outcome. *Br J Ophthalmol* 2018;102:1425-30
6. Dapena I, Moutsouris K, Droutsas K, et al. Standardized “no-touch” technique for Descemet membrane endothelial keratoplasty. *Arch Ophthalmol* 2011;129:88-94
7. Birbal RS, Hsien S, Zygoura V, et al. Outcomes of Hemi-Descemet membrane endothelial keratoplasty for Fuchs endothelial corneal dystrophy. *Cornea* 2018;37:854-8
8. Oellerich S, Ham L, Frank LE, et al. Parameters associated with endothelial cell density variability after Descemet membrane endothelial keratoplasty. *Am J Ophthalmol* 2020;211:22-30
9. Melles GR. Posterior lamellar keratoplasty: DLEK to DSEK to DMEK. *Cornea* 2006;25:879-81
10. Miron A, Spinozzi D, Bruinsma M, et al. Asymmetrical endothelial cell migration from in vitro Quarter-Descemet membrane endothelial keratoplasty grafts. *Acta Ophthalmol* 2018;96:828-33
11. Ham L, Dapena I, van Luijk C, et al. Descemet membrane endothelial keratoplasty (DMEK) for Fuchs endothelial dystrophy: review of the first 50 consecutive cases. *Eye (Lond)* 2009;23:1990-8
12. Miron A, Bruinsma M, Ham L, et al. In vivo endothelial cell density decline in the early postoperative phase after Descemet membrane endothelial keratoplasty. *Cornea* 2018;37:673-7

Chapter 9

Summary and Future Directions

SUMMARY

Over the past two decades, lamellar keratoplasty has revolutionized the field of corneal transplantation and largely replaced penetrating keratoplasty (PK) as the preferred surgical treatment option for corneal endothelial disorders.[1] Since its introduction in 1998, endothelial keratoplasty (EK) has evolved from Deep lamellar endothelial keratoplasty (DLEK) via Descemet stripping (automated) endothelial keratoplasty (DS(A)EK) to Descemet membrane endothelial keratoplasty (DMEK).[2] Global scarcity of corneal donor tissue inspired further refinement of conventional DMEK and led to the development of Hemi- and Quarter-DMEK.[3,4] These EK-techniques may potentially increase the availability of endothelial donor grafts.

For this thesis, donor tissue preparation for DMEK and the feasibility and clinical outcomes of DMEK and modified DMEK-techniques were evaluated in the management of corneal endothelial disorders.

Part I - Donor tissue preparation

Adequate knowledge of the currently available DMEK graft harvesting techniques may benefit corneal surgeons and eye banks in choosing the best approach for each specific user (**Chapter 2**).[5] Current and evolving techniques to harvest donor tissue show a trend towards increased utilization of a 'no-touch' technique, an approach in which there is no direct physical graft handling to minimize endothelial cell loss.[6] Harvesting techniques may broadly be classified into those based on manual peeling and those based on air- or liquid-assisted detachment at the stroma-Descemet membrane interface.[5] While these techniques are diverse and feature different strengths and weaknesses, different approaches may all provide excellent results.[5]

Part II - Selective, minimally-invasive and potentially tissue-sparing surgical treatment modalities for corneal endothelial disorders

DMEK

Since its clinical introduction in 2006, DMEK has emerged as an increasingly popular surgical treatment option for corneal endothelial disorders.[1,2] Multiple studies have substantiated initial reports on excellent clinical outcomes and have reliably shown that the first 6 months after DMEK appear to be the most critical time period, after which the results mostly stabilize.[7-15] Our expanding DMEK-cohort and simultaneously growing dataset allowed us to perform

in-depth analyses on subgroups. As such, we did not only evaluate overall clinical outcome in our six-month assessment of 1000 DMEKs but also analyzed how surgical indication (Fuchs endothelial corneal dystrophy (FECD) versus bullous keratopathy (BK)) and preoperative lens status (phakic versus pseudophakic) in FECD eyes affected the results (**Chapter 3**).[16]

Our study showed similar high visual acuity levels for both FECD and BK eyes when correcting for preoperative visual acuity and patient age. Hence, it may be important to emphasize that most BK eyes without visual acuity-limiting comorbidities may also expect a good visual outcome, even early after DMEK. While preoperative lens status did not influence DMEK outcomes, preservation of the crystalline lens may be preferred in a select group of younger patients with FECD and a relatively clear lens, as they may still benefit from their residual accommodative capacity and a better overall optical quality of the eye. In addition, the 5-year rate of visually-significant cataract formation after DMEK is relatively low (16%).[7]

DMEK continued to provide excellent clinical outcomes and high graft survival rates up to 5 years postoperatively (**Chapter 4**).[7] In this series of the first 500 DMEK eyes, eyes with FECD demonstrated better survival probabilities at 5 years postoperatively compared to eyes with other surgical indications (93% for isolated FECD versus 72% for other indications). A technique learning curve may also have been involved in attaining higher graft survival rates. This was reflected by the higher survival probability of the second 250 DMEK cases (94%) versus the first 250 cases (88%) and substantiated by the significantly lower survival probabilities of eyes with a graft detachment of >1/3 of the graft surface area (27%) compared to eyes with completely attached grafts (95%) or only small detachments (91%). Major graft detachments occurred less frequently in the second 250 cases (2.4%) compared to the first 250 cases (4.4%). These outcomes support the beneficial effect of an early re-bubbling procedure.

This study confirmed that the excellent visual outcomes achieved at 6 months after DMEK may be maintained up to at least 5 years postoperatively. The overall postoperative complication rate remained relatively low throughout the 5-year study period. Partial graft detachment was the main early postoperative complication, whereas allograft rejection and secondary graft failure constituted the more severe complications in the later postoperative period. Repeat keratoplasty was required at a relatively low rate (8.8%).

DMEK in challenging cases

With specific surgical modifications, DMEK proved feasible in eyes with a glaucoma drainage device (GDD) and provided acceptable clinical outcomes (**Chapter 5**).[17,18] Our data show thatthe presence of a GDD may reduce graft longevity and pose a risk for more frequent re-grafting, as we noticed that DMEK graft survival was lower in eyes with a GDD compared to our standard DMEK cohort: the survival probability was 89% at 1 year after DMEK, and decreased to 67% at 2 years after DMEK. The presence of a GDD negatively affected donor endothelial cell density (ECD). At 1 year after DMEK, ECD decline was 71%, which is almost twice as high as for our standard DMEK cohort. The incidence of secondary graft failure (8.7%) was also higher compared to after standard DMEK. The underlying cause of the faster drop in graft survival and the steeper ECD decline in the presence of a GDD may be multifactorial. It may be due to changes in aqueous humor circulation patterns owing to a GDD, which may adversely affect endothelial cell viability, and/or the GDD itself that may induce a breach in the blood-aqueous barrier caused by heavily rubbing or forcefully blinking, resulting in an increase of influx of oxidative, apoptotic, and inflammatory proteins, which may potentially damage corneal endothelial cells.[19-24] In addition, eyes with glaucoma necessitating a GDD may be more prone to immune reactions, as glaucomatous ganglion cell damage may be related to immune responses as well.[25]

Graft detachment was the main early postoperative complication, with 22% of eyes requiring a re-bubbling procedure. This may reflect that eyes with a GDD are more prone to surgical complications, which is possibly related to the added difficulty of pressurizing these eyes with air at the conclusion of the operation.

Most of the observed postoperative complications seem to be inherent to the presence of a GDD, and may partially be mitigated by special surgical considerations.[17,18] For this select group of patients it is imperative to do appropriate patient counseling.

Modified DMEK-techniques

Descemet membrane endothelial transfer

In the early years of EK, it was generally believed that, for grafted endothelial tissue to restore corneal transparency, a complete apposition between donor and host tissue was mandatory; i.e. without a fully, centrally-attached graft, corneal clearance could not be obtained and visual rehabilitation would not occur. Over the past decade, a growing number of studies have described spontaneous corneal clearance in the presence of a detached endothelial graft after DS(A)EK or DMEK, or in the absence of an endothelial graft, that is 'descemetorhexis only', thereby challenging this concept and questioning the necessity of grafting after descemetorhexis.[26-40] Descemet membrane endothelial transfer (DMET), in which descemetorhexis is followed by insertion of an almost completely free-floating Descemet roll (i.e. with the graft fixated within a corneoscleral incision to ensure contact with the posterior cornea) aims to obtain corneal clearance by endothelial cell migration.[41]

Our initial evaluation of DMET comprised a cohort of 12 eyes from 12 patients, seven operated on for FECD and five for BK, and showed repopulation of the denuded recipient stroma and corneal clearance in all eyes operated on for FECD, but not in those operated on for BK.[41,42] This suggests that the underlying pathology may be the main determinant of the clinical outcome and that recipient endothelial cells rather than donor endothelial cells contribute to corneal clearance.

While DMET initially showed promising results for FECD cases, our study on the long-term outcome of these 16 DMET cases showed that, regardless of the etiology of endothelial dysfunction, all corneas ultimately decompensated and required repeat EK (**Chapter 6**).[43] Hence, the regenerative capacity of endothelial cells in eyes with FECD may not be sufficient to ensure complete and durable corneal deturgescence after DMET. In order to obtain complete and lasting corneal rehabilitation, a (nearly) fully, centrally-attached Descemet graft may be mandatory.

Hemi-DMEK

In 2014, Hemi-DMEK was introduced. This technique allowed for the utilization of a single donor cornea for two endothelial keratoplasty procedures in two recipient eyes with FECD, thereby potentially doubling the availability of endothelial donor tissue.[44]

Our initial cohort of ten Hemi-DMEK eyes showed that the same level of visual rehabilitation may be acquired with Hemi-DMEK as with conventional DMEK (**Chapter 7**).[45-49] While delayed corneal clearance may occur in the periphery of the cornea due to bare stromal areas resulting from the mismatch of the circular descemetorhexis and the semicircular shape of the Hemi-DMEK graft, the central cornea was not negatively affected as the Hemi-DMEK graft was positioned to cover the central cornea, thereby resulting in fast visual clearance.

In the first 6 months after surgery, a higher decline in ECD was observed than after conventional DMEK (65% vs 34%). This may be explained by different patterns of endothelial cell redistribution and migration after Hemi-DMEK compared to conventional DMEK that may be due to larger denuded stromal areas. In addition, ECD measurements at different graft areas (centrally for conventional DMEK and more peripheral or at the graft edge for Hemi-DMEK) may produce this difference in the ECD decrease. After the initial drop in ECD, an annual decline of 6-7% was observed, which is comparable to that after conventional DMEK. Hence, the ECD decrease after this early drop may be caused by similar mechanisms in both techniques. As with conventional DMEK, the main complication after Hemi-DMEK was graft detachment (40%), which may be associated with the learning curve for this modified DMEK technique; another factor may be the different graft shape, as the Hemi-DMEK graft has one shorter axis. A higher number of re-bubbling procedures was performed for graft detachments after Hemi-DMEK, as minor graft detachments more often affected the visual axis.

Quarter-DMEK

Given the initial success of Hemi-DMEK and our goal to utilize corneal donor tissue even more efficiently, Quarter-DMEK was introduced.[50] Quarter-DMEK offers the theoretical benefit of reduced donor antigen load and of potentially quadrupling the amount of donor tissue available for transplantation as four endothelial grafts may be obtained from one donor cornea and transplanted into four recipient eyes.[50]

In our initial series of 19 Quarter-DMEK eyes, BCVA values equaled BCVA outcomes after conventional and Hemi-DMEK (**Chapter 8**).[51,52] Quarter-DMEK provided fast visual rehabilitation, but corneal deturgescence was slower than after conventional DMEK and, in particular, lagged behind along the round limbal edge of the Quarter-DMEK graft and in the adjacent bare stromal areas.[51,52]

In vitro evaluation of organ-cultured Quarter-DMEK grafts revealed that endothelial cell migration is asymmetrical and primarily occurs along the radial cut edges of the graft, and not at the round edge of the graft, i.e. the far, limbal periphery of the graft.[53] This asymmetrical migration of corneal endothelial cells may be attributed to the different molecular structure of the peripheral DM.[53] With (initial) corneal clearance and endothelial cell migration primarily occurring along the radial cut edges, it may be worthwhile to position the graft eccentrically, with its radial cut edges near the pupillary area and the peripheral round edge near the corneal periphery, to avoid slowly-resolving corneal edema in the visual axis.

Visually-significant graft detachment requiring re-bubbling procedures (42%) occurred at a rate comparable for Hemi-DMEK (40%), but at a slightly higher rate compared with the first 25 cases of the initial conventional DMEK case series (36%). This may be related to more difficult graft handling during surgery, to curvature incongruence, considering the central recipient cornea is aligned with the paracentral donor cornea, and/or the fact that graft detachments in Quarter-DMEK almost always involve the visual axis, prompting re-bubbling procedures more quickly. As with Hemi-DMEK, a steep initial decline in ECD was observed in the first 6 months postoperatively (68%), which was followed by a slower decline thereafter. This may be explained by increased surgical manipulation and endothelial cell migration as the mismatch between the larger descemetorhexis and the smaller triangular-shaped Quarter-DMEK graft may contribute to larger areas of bare stroma that need to be colonized by migrating donor cells.

Quarter-DMEK may benefit from a smaller descemetorhexis (diameter) aiming to reduce the surface of the bare areas that need to be repopulated by endothelial cells, adapted graft preparation protocols to reduce the endothelial cell loss along the radial cut edges of the graft and/or by eliminating the round peripheral edge of the Quarter-DMEK graft to promote cell migration toward the adjacent bare area in the corneal periphery. While Quarter-DMEK may induce sufficient corneal deturgescence, topical administration of Rho-associated kinase (ROCK)-inhibitors, as also applied in 'Descemet stripping only' and endothelial cell injection therapy, may potentially enhance endothelial cell migration and corneal clearance.[54,55]

CONCLUDING REMARKS

DMEK graft dissection techniques are diverse and feature different strengths and weaknesses. While the type of utilized DMEK-graft dissection technique may influence clinical outcomes after DMEK, a single technique does not need to be universally adopted. It is, however, imperative for those preparing DMEK tissue to know the different techniques available, so they can choose the best approach for them individually and for their given setting.

DMEK has shown to provide excellent short- as well as mid-term clinical outcomes for various surgical indications such as FECD and BK. In addition, DMEK proved feasible in challenging cases such as glaucomatous eyes with a glaucoma drainage device. While DMET initially showed promising results for FECD cases, it ultimately failed to provide complete and durable corneal rehabilitation, highlighting the importance of a well-attached endothelial graft to achieve durable corneal clearance. Therefore, conventional DMEK may remain the preferred treatment option for long-term management of corneal endothelial disorders.

Hemi-DMEK and Quarter-DMEK may be encouraging because the procedures may allow for clinical outcomes similar to conventional DMEK and may potentially increase the availability of endothelial donor tissue. If longer-term studies show that outcomes remain stable, these techniques may become an alternative to conventional DMEK. Quarter-DMEK, however, may benefit from some further modifications in order to obtain improved clinical outcomes in terms of cell density decrease and additional studies are warranted to further evaluate this.

FUTURE DIRECTIONS

Modern lamellar keratoplasty techniques have significantly improved clinical outcomes of corneal transplantation and reduced the rates of postoperative complications such as graft rejection and graft failure. Nonetheless, postoperative complications remain a major cause of repeat transplantation, while at the same time, global shortage of corneal donor tissue persists. Evolution in the field of corneal endothelial regeneration is therefore targeted towards overcoming these obstacles.

In recent years, Descemet stripping without endothelial keratoplasty (DWEK), also known as Descemet stripping only (DSO), bioengineered corneal endothelium, pharmaceutical agents such as Rho kinase (ROCK)-inhibitors, and gene therapy have been proposed as alternative or complementary treatment options in the management of corneal endothelial dysfunction.

DWEK was introduced for the treatment of early FECD stages following numerous observations of spontaneous corneal clearance in eyes with an endothelial defect in the absence of an endothelial graft.[26,27,36] As the name suggests, this technique entails removal of the diseased central DM and endothelium without insertion of an endothelial donor graft.[29-35,37-40] DWEK intends to stimulate centripetal migration of healthy, peripheral endothelial cells to replace the central endothelium. Early case series on the clinical outcomes of DWEK generated mixed results, with better clearance rates reported in cases where a smaller 3-4 diameter descemetorhexis was employed.[54] This may be explained by the limited and transitory capacity of recipient endothelium to self-repair in eyes with FECD, as observed after DMET. Drawbacks of DWEK include unpredictability of corneal clearance and suboptimal vision despite corneal clearance.[54] Fast, slow and non-responders have been described. As no donor tissue is used, outcomes are most likely determined by either patient or surgical factors. While no patient factors of significance have yet been described, the presence of posterior stromal scarring, related to stromal scoring, is more often observed in slow to non-responders.[54] Consequently, recommendations have been made to strip DM without scoring it, thereby aiming to maximize cell preservation and migration. Further recommendations included placing emphasis on symmetry and centration of the descemetorhexis during surgery to minimize ghosting and irregular astigmatism. Pharmacological adjuncts such as ROCK-inhibitors have been described to significantly speed up visual recovery and induce higher central endothelial cell counts. In addition,

ROCK-inhibitors have been described as salvage therapy in initially unsuccessful DWEK cases.[56,57] If DWEK does not induce corneal clearance, subsequent EK may still be performed with favorable outcomes. Although DWEK may represent a cost-effective and time-efficient procedure, worldwide adoption has been reasonably limited by its inconsistent outcomes. Larger studies with longer follow-up are required to further determine the potential of this technique.

Expanding on the concept of DWEK, *primary descemetorhexis followed by acellular Descemet membrane transplantation* (DMT) was introduced after *in vitro* tests showed that endothelial cell migration after descemetorhexis might be facilitated by the presence of a Descemet membrane.[58,59] A first *in vivo* human study demonstrated the potential of this technique in achieving repopulation of the transplanted acellular DM graft with healthy, peripheral host endothelial cells and corneal clearance.[60] Further series are warranted to determine the clinical (additional) merit of this technique.

Human corneal endothelial cells can enlarge and migrate but are believed not to proliferate *in vivo*, whereas they do proliferate *in vitro*.[61-64] Currently, the only way to replace diseased corneal endothelial cells (CECs) is by EK. The global shortage of endothelial grafts inspired the development of 'tissue-engineered endothelial grafts' that can subsequently be transplanted into humans. Usage of *bioengineered corneal endothelium* basically comprises two primary approaches: scaffold-based and cell-based. The concept of transplanting CECs was first suggested by Jumblatt and associates in 1978.[65] In an animal study on rabbit eyes, full-thickness transplantation of a rabbit cornea seeded with cultured endothelial rabbit cells was shown to restore corneal transparency.[66] Since then, several studies have demonstrated the feasibility of transplanting CECs to restore corneal clarity not only *in vitro* but also *in vivo* with both non-human and human CECs.[67-70] All initially reported procedures, however, required the use of a human donor cornea as a carrier for the CECs, which hampered the merits of cultured CEC transplantation as the same number of donor corneas would still be required to treat patients.[71] The introduction and success of lamellar keratoplasty techniques such as DS(A)EK and DMEK, inspired scientists to develop bioengineered corneal endothelial cell sheets that could subsequently be implanted like a DS(A)EK/DMEK graft by a DSAEK/DMEK procedure. Previous *in vitro* studies have evaluated the use of denuded DM, human anterior lens capsules (HALC) and bioengineered matrices consisting of silk-fibroin, collagen, gelatin or a combination of biopolymers, as

potential carriers for cultured CECs.[68,72-80] Subsequent *in vivo* animal studies tested the use of (cross-linked) collagen sheets, plastic compressed collagen type I 'REAL architecture for 3D tissues' (RAFT), and biological carriers such as DM, HALC and amniotic membrane.[72,78,79,81-84] However, none of the carriers reported in the literature to date have been an adequate replacement of standard endothelial grafts and therefore, bioengineered cell-carrier constructs have not yet progressed into clinical practice.

To avoid carrier-related challenges, alternative methods to transplant cultured CECs were trialed, such as injecting free-floating corneal endothelial cells into the anterior chamber. In 2018, a proof-of-concept clinical study by Kinoshita and associates demonstrated that injection of human CECs restored the corneal endothelium in 11 human eyes with BK.[55] After removal of an approximately 8 mm diameter portion of the diseased corneal endothelium with a silicon tip needle, ex vivo cultured CECs, supplemented with a ROCK-inhibitor, were injected into the recipients anterior chamber. All eyes demonstrated regeneration of a monolayer sheet-like structure and achieved restoration of corneal transparency. At 24 weeks after cell injection, ECD was more than 500 cells/mm^2 (range, 947 to 2833 cells/mm^2).

While injecting cultured CECs into the anterior chamber is a minimally invasive approach that shows great promise, larger, prospective, randomized controlled trials are required to refine this technique and to ensure long term efficacy and safety. These might include studies to evaluate potential adverse effects (for example, unattached donor cells entering the systemic circulation and their effect), host immune response (or lack thereof) to cultivated injected endothelial cells, the role of HLA matching, and the potential role of ROCK-inhibitors.[85] Finally, it is possible that adoption of this technique may be slow, despite successful results, as the protocols need to be carefully standardized and need to comply with high regulatory demands including good manufacturing practice (GMP) for cell production, which currently results in very high costs as compared to standard endothelial grafts.

The use of *Rho kinase or rho-associated protein kinase (ROCK)-inhibitors,* as pharmaceutical therapeutic agents or adjuncts for the treatment of corneal endothelial dysfunction, has been a topic of great interest. ROCK is a serine/threonine kinase that serves as an essential downstream effector of Rho-GTPase, and ultimately affects cell adhesion, motility, proliferation, differentiation and apoptosis.[86-89] While the most commonly known ROCK-inhibitor 'Y-27632'

has shown promising results in promoting corneal endothelial regeneration in *in vitro* experiments and in *in vivo* animal models, it may be premature to assume that all the beneficial effects of ROCK inhibitors observed in animal models will be similarly reproduced in humans since animal CECs possess stronger regenerative potential.[89-98] ROCK-inhibitors have also been described as salvage therapy after DWEK and as complementary therapy in DWEK and cell-based therapies.[54,84,97] While ROCK-inhibitors show potential, their efficacy and safety on corneal regeneration *in vivo* needs to be further determined in adequately powered human clinical trials.

Gene therapy is also being explored as a potential avenue for management of corneal endothelial diseases. Although FECD is genetically heterogeneous, many cases are associated with expanded trinucleotide cytosine-thymine-guanin (CTG) repeats in the TCF4 gene.[99] Emerging therapies utilizing anti-sense oligonucleotides (AON) and prokaryotic clustered regularly interspaced palindromic repeat (CRISPR) endonucleases aim to target this sequence and functionally knock down its gene expression.[100] While *ex vivo* human studies have shown that gene therapy is a potentially viable treatment option in the management of FECD, further research has yet to show whether this also holds true for *in vivo* human clinical trials.[101-105]

Exciting novel treatment modalities such as regenerative therapy, bio-engineered corneal grafts, cell therapy and gene therapy have emerged and show promising preliminary results. Further research is warranted to refine the current techniques and to investigate the therapeutic relevance of each of them. Until then, endothelial keratoplasty will remain the standard of care for the management of corneal endothelial dysfunction.

REFERENCES

1. Eye Bank Association of America. *2019 Eye Banking Statistical Report* Washington, DC: Eye Bank Association of America; 2020
2. Melles GR. Posterior lamellar keratoplasty: DLEK to DSEK to DMEK. *Cornea* 2006;25:879-81
3. Lam FC, Baydoun L, Dirisamer M, et al. Hemi-Descemet membrane endothelial keratoplasty transplantation: a potential method for increasing the pool of endothelial graft tissue. *JAMA Ophthalmol* 2014;132:1469–73
4. Müller TM, Lavy I, Baydoun L, et al. Case report of Quarter-Descemet membrane endothelial keratoplasty for fuchs endothelial dystrophy. *Cornea* 2017;36:104–7
5. Birbal RS, Sikder S, Lie JT, et al. Donor tissue preparation for Descemet membrane endothelial keratoplasty: An updated review. *Cornea* 2018;37:128-35
6. Terry MA. Endothelial keratoplasty: why aren't we all doing Descemet membrane endothelial keratoplasty? *Cornea* 2012;31:469–71
7. Birbal RS, Ni Dhubhghaill S, Bourgonje VJA, et al. Five-year graft survival and clinical outcomes of 500 consecutive cases after Descemet membrane endothelial keratoplasty. *Cornea* 2020;39:290-7
8. Rodríguez-Calvo-de-Mora M, Quilendrino R, Ham L, et al. Clinical outcome of 500 consecutive cases undergoing Descemet's membrane endothelial keratoplasty. *Ophthalmology* 2015;122:464–70
9. Hamzaoglu EC, Straiko MD, Mayko ZM, et al. The first 100 eyes of standardized Descemet stripping automated endothelial keratoplasty versus standardized Descemet membrane endothelial keratoplasty. *Ophthalmology* 2015;122:2193–9
10. Deng SX, Lee WB, Hammersmith KM, et al. Descemet membrane endothelial keratoplasty: safety and outcomes: a report by the American Academy of Ophthalmology. *Ophthalmology* 2018;125:295–310
11. Guerra FP, Anshu A, Price MO, et al. Descemet's membrane endothelial keratoplasty: prospective study of 1-year visual outcomes, graft survival, and endothelial cell loss. *Ophthalmology* 2011;118:2368–73
12. Feng MT, Price MO, Miller JM, et al. Air reinjection and endothelial cell density in Descemet membrane endothelial keratoplasty: five-year follow-up. *J Cataract Refract Surg* 2014;40:1116–21
13. Schlögl A, Tourtas T, Kruse FE, et al. Long-term clinical outcome after Descemet membrane endothelial keratoplasty. *Am J Ophthalmol* 2016;169:218–26
14. Price DA, Kelley M, Price FW Jr, et al. Five-year graft survival of Descemet membrane endothelial keratoplasty (EK) versus Descemet stripping EK and the effect of donor sex matching. *Ophthalmology* 2018;125:1508–14
15. Schrittenlocher S, Schaub F, Hos D, et al. Evolution of consecutive Descemet membrane endothelial keratoplasty outcomes throughout a 5-year period performed by two experienced surgeons. *Am J Ophthalmol* 2018;190:171–8
16. Birbal RS, Baydoun L, Ham L, et al. Effect of surgical indication and preoperative lens status on Descemet membrane endothelial keratoplasty outcomes. *Am J Ophthalmol* 2020;212:79-87

17. Birbal RS, Tong CM, Dapena I, et al. Clinical outcomes of Descemet membrane endothelial keratoplasty in eyes with a glaucoma drainage device. *Am J Ophthalmol* 2019;199:150-8
18. Birbal RS, Tong CM, Dapena I, et al. Reply to a comment: Clinical outcomes of Descemet membrane endothelial keratoplasty in eyes with a glaucoma drainage device. *Am J Ophthalmol* 2019;208:440-1
19. Kim P, Amiran MD, Lichtinger A, et al. Outcomes of Descemet stripping automated endothelial keratoplasty in patients with previous glaucoma drainage device insertion. *Cornea* 2012;31:172–5
20. Schoenberg ED, Levin KH, Savetsky MJ, et al. Surgical outcomes of DSAEK in patients with prior Ahmed glaucoma drainage device placement. *Eur J Ophthalmol* 2013;23:807–13
21. Topouzis F, Coleman AL, Choplin N, et al. Follow-up of the original cohort with the Ahmed glaucoma valve implant. *Am J Ophthalmol* 1999;128:198–204
22. Williams KA, Lowe M, Bartlett C, et al. Risk factors for human corneal graft failure within the Australian corneal graft registry. *Transplantation* 2008;86:1720–4
23. Anshu A, Price MO, Richardson MR, et al. Alterations in the aqueous humor proteome in patients with a glaucoma shunt device. *Mol Vis* 2011;17:1891–1900
24. Rosenfeld C, Price MO, Lai X, et al. Distinctive and pervasive alterations in aqueous humor protein composition following different types of glaucoma surgery. *Mol Vis* 2015;21:911–18
25. Chen H, Cho KS, Vu THK, et al. Commensal microflora-induced T cell responses mediate progressive neurodegeneration in glaucoma. *Nat Commun* 2018;10;9:3209
26. Balachandran C, Ham L, Verschoor CA, et al. Spontaneous corneal clearance despite graft detachment in Descemet membrane endothelial keratoplasty (DMEK). *Am J Ophthalmol* 2009;148:227–34
27. Price FW Jr, Price MO. Comment on "Spontaneous corneal clearance despite graft detachment after Descemet membrane endothelial keratoplasty." *Am J Ophthalmol* 2010;149:173–4; author reply 174–5
28. Zafirakis P, Kymionis GD, Grentzelos MA, et al. Corneal graft detachment without corneal edema after Descemet stripping automated endothelial keratoplasty. *Cornea* 2010;29:456–8
29. Moloney G, Petsoglou C, Ball M, et al. Descemetorhexis without grafting for Fuchs endothelial dystrophy—supplementation with topical ripasudil. *Cornea* 2017;36:642–8
30. Iovieno A, Neri A, Soldani AM, et al. Descemetorhexis without graft placement for the treatment of Fuchs endothelial dystrophy: pre-liminary results and review of the literature. *Cornea* 2017;36:637–41
31. Galvis V, Tello A, Berrospi RD, et al. Descemetorhexis without endothelial graft in Fuchs dystrophy. *Cornea* 2016;35:e26–8
32. Borkar DS, Veldman P, Colby KA. Treatment of Fuchs endothelial dystrophy by Descemet stripping without endothelial keratoplasty. *Cornea* 2016;35:1267–73
33. Moloney G, Chan UT, Hamilton A, et al. Descemetorhexis for Fuchs' dystrophy. *Can J Ophthalmol* 2015;50:68–72
34. Koenig SB. Planned Descemetorhexis without endothelial keratoplasty in eyes with Fuchs corneal endothelial dystrophy. *Cornea* 2015;34:1149–51

35. Satué Palacián M, Sánchez Pérez A, Idoipe Corta M, et al. Descemetorhexis and corneal clearing: a new perspective on the treatment of endothelial diseases. *Arch Soc Esp Oftalmol* 2014;89:1–3
36. Koenig SB. Long-term corneal clarity after spontaneous repair of an iatrogenic Descemetorhexis in a patient with Fuchs dystrophy. *Cornea* 2013;32:886–8
37. Shah RD, Randleman JB, Grossniklaus HE. Spontaneous corneal clearing after Descemet's stripping without endothelial replacement. *Ophthalmology* 2012;119:256–60
38. Bleyen I, Saelens IE, van Dooren BT, et al. Spontaneous corneal clearing after Descemet's stripping. *Ophthalmology* 2013;120:215
39. Braunstein RE, Airiani S, Chang MA, et al. Corneal edema resolution after "Descemetorhexis." *J Cataract Refract Surg* 2003;29:1436–9
40. Ziaei M, Barsam A, Mearza AA. Spontaneous corneal clearance despite graft removal in Descemet stripping endothelial keratoplasty in Fuchs endothelial dystrophy. *Cornea* 2013;32:e164–6
41. Dirisamer M, Ham L, Dapena I, et al. Descemet membrane endothelial transfer: "Free-floating" donor Descemet implantation as a potential alternative to "keratoplasty." *Cornea* 2012;31:194–7
42. Dirisamer M, Yeh RY, van Dijk K, et al. Recipient endothelium may relate to corneal clearance in Descemet membrane endothelial transfer. *Am J Ophthalmol* 2012;154:290–6
43. Birbal RS, Parker J, Dirisamer M, et al. Descemet Membrane Endothelial Transfer: Ultimate Outcome. *Cornea* 2018;37:141-4
44. Lam FC, Baydoun L, Dirisamer M, et al. Hemi-Descemet membrane endothelial keratoplasty transplantation: a potential method for increasing the pool of endothelial graft tissue. *JAMA Ophthalmol* 2014;132:1469–73
45. Lam FC, Baydoun L, Satué M, et al. One year outcome of Hemi-Descemet membrane endothelial keratoplasty. *Graefes Arch Clin Exp Ophthalmol* 2015;253:1955–8
46. Lie JT, Lam FC, Groeneveld-van Beek EA, et al. Graft preparation for Hemi-Descemet membrane endothelial keratoplasty (hemi-DMEK). *Br J Ophthalmol* 2016;100:420–4
47. Gerber-Hollbach N, Parker J, Baydoun L, et al. Preliminary outcome of Hemi-Descemet membrane endothelial keratoplasty for Fuchs endothelial dystrophy. *Br J Ophthalmol* 2016;100:1564–8
48. Müller TM, Baydoun L, Melles GR. 3-Year update on the first case series of Hemi-Descemet membrane endothelial keratoplasty. *Graefes Arch Clin Exp Ophthalmol* 2017;255:213–5
49. Birbal RS, Hsien S, Zygoura V, et al. Outcomes of Hemi-Descemet Membrane Endothelial Keratoplasty for Fuchs Endothelial Corneal Dystrophy. *Cornea* 2018;37:854-8
50. Müller TM, Lavy I, Baydoun L, et al. Case report of Quarter-Descemet membrane endothelial keratoplasty for Fuchs endothelial dystrophy. *Cornea* 2017;36:104–7
51. Zygoura V, Baydoun L, Ham L, et al. Quarter-Descemet membrane endothelial keratoplasty (Quarter-DMEK) for Fuchs endothelial corneal dystrophy: 6 months clinical outcome. *Br J Ophthalmol* 2018;102:1425–30
52. Birbal RS, Ni Dhubhghaill S, Baydoun L, et al. Quarter-Descemet Membrane Endothelial Keratoplasty: One- to Two-Year Clinical Outcomes. *Cornea* 2020;39:277-82
53. Miron A, Spinozzi D, Bruinsma M, et al. Asymmetrical endothelial cell migration from in vitro Quarter-Descemet membrane endothelial keratoplasty grafts. *Acta Ophthalmol* 2018;96:828–33

54. Garcerant D, Hirnschall N, Toalster N, et al. Descemet's stripping without endothelial keratoplasty. *Curr Opin Ophthalmol* 2019;30:275-85
55. Kinoshita S, Koizumi N, Ueno M, et al. Injection of cultured cells with a ROCK inhibitor for bullous keratopathy. *N Engl J Med* 2018; 378: 995-1003
56. Huang MJ, Kaine S, Dhaliwal DK. Descemetorhexis without endothelial keratoplasty verses DMEK for treatment for Fuchs endothelial corneal dystrophy. *Cornea* 2018; 37: 1479-83
57. Macsai MS, Shiloach M. Use of topical rho kinase inhibitors in the treatment of Fuchs dystrophy after Descemet stripping only. *Cornea* 2019; 38: 529-534
58. Bhogal M, Lwin CN, Seah XY, et al. Allogeneic Descemet's Membrane Transplantation Enhances Corneal Endothelial Monolayer Formation and Restores Functional Integrity Following Descemet's Stripping. *Invest Ophthalmol Vis Sci* 2017 1;58:4249-4260
59. Soh YQ, Peh G, George BL, et al. Predicative Factors for Corneal Endothelial Cell Migration. *Invest Ophthalmol Vis Sci* 2016;57:338-48
60. Soh YQ, Mehta JS. Regenerative Therapy for Fuchs Endothelial Corneal Dystrophy. *Cornea* 2018;37:523-27
61. Joyce NC, Meklir B. Joyce SJ, et al. Cell cycle protein expression and proliferative status in human corneal cells. *Invest Ophthalmol Vis Sci* 1996; 37: 645-55
62. Joyce N. Proliferative capacity of corneal endothelial cells. *Exp Eye Res* 2012; 95: 16-23.
63. Baum JL, Niedra R, Davis C, et al. Mass culture of human corneal endothelial cell. *Arch Ophthalmol* 1979; 97: 1136-40
64. Soh YQ, Peh GS, Mehta JS. Translational tissues for human corneal endothelial tissue engineering. *J Tissue Eng Regen Med* 2017; 11: 2425-42
65. Jumblatt MM, Maurice DM, McCulley JP. Transplantation of tissue-cultured corneal endothelium. *Invest Ophthalmol Vis Sci* 1978;17:1135-41
66. Jumblatt MM, Maurice DM, McCulley JP. Transplantation of tissue-cultured corneal endothelium. *Invest Ophthalmol Vis Sci* 1978;17:1135–41
67. Gospodarowicz D, Greenburg G, Alvarado J. Transplantation of cultured bovine corneal endothelial cells to rabbit cornea: clinical implications for human studies. *Proc Natl Acad Sci U S A* 1979;76:464–8
68. Ishino Y, Sano Y, Nakamura T, et al. Amniotic membrane as a carrier for cultivated human corneal endothelial cell transplantation. *Invest Ophthalmol Vis Sci* 2004;45:800–6
69. Sumide T, Nishida K, Yamato M, et al. Functional human corneal endothelial cell sheets harvested from temperature-responsive culture surfaces. *Faseb J* 2006;20:392–4
70. Hitani K, Yokoo S, Honda N, et al. Transplantation of a sheet of human corneal endothelial cell in a rabbit model. *Mol Vis* 2008;14:1–9
71. Okumura N, Koizumi N. Regeneration of the Corneal Endothelium. *Curr Eye Res* 2020;45:303-12
72. Mimura T, Yamagami S, Amano S. Corneal endothelial regeneration and tissue engineering. *Progr Retin Eye Res* 2013;35:1–17
73. Mimura T, Yamagami S, Yokoo S, et al. Cultured human corneal endothelial cell transplantation with a collagen sheet in a rabbit model. *Invest Ophthalmol Vis Sci* 2004;45:2992–7
74. Watanabe R, Hayashi R, Kimura Y, et al. A novel gelatin hydrogel carrier sheet for corneal endothelial transplantation. *Tissue Eng Part A* 2011;17:2213–19

75. Liang Y, Liu W, Han B, et al. Fabrication and characters of a corneal endothelial cells scaffold based on chitosan. *J Mater Sci Mater Med* 2011;22:175–83
76. Parikumar P, Haraguchi K, Ohbayashi A, et al. Successful transplantation of in vitro expanded human cadaver corneal endothelial precursor cells on to a cadaver bovine's eye using a nanocomposite gel sheet. *Curr Eye Res* 2014;39:522–6
77. Parikumar P, Haraguchi K, Senthilkumar R, et al. Human corneal endothelial cell transplantation using nanocomposite gel sheet in bullous keratopathy. *Am J Stem Cells* 2018;7:18–24
78. Kopsachilis N, Tsinopoulos I, Tourtas T, et al. Descemet's membrane substrate from human donor lens anterior capsule. *Clin Exp Ophthalmol* 2012;40:187–94
79. Yoeruek E, Saygili O, Spitzer MS, et al. Human anterior lens capsule as carrier matrix for cultivated human corneal endothelial cells. *Cornea* 2009;28:416–20
80. Spinozzi D, Miron A, Bruinsma M, et al. Evaluation of the suitability of biocompatible carriers as artificial transplants using cultured porcine corneal endothelial cells. *Curr Eye Res* 2019;44:243-9
81. Navaratnam J, Utheim TP, Rajasekhar VK, et al. Substrates for expansion of corneal endothelial cells towards bioengineering of human corneal endothelium. *J Funct Biomater* 2015;6:917–45
82. Koizumi N, Sakamoto Y, Okumura N, et al. Cultivated corneal endothelial cell sheet transplantation in a primate model. *Invest Ophthalmol Vis Sci* 2007;48:4519–26
83. Levis HJ, Peh GS, Toh KP, et al. Plastic compressed collagen as a novel carrier for expanded human corneal endothelial cells for transplantation. *PLoS One* 2012;7:e50993
84. Peh GSL, Ang HP, Lwin CN, et al. Regulatory compliant tissue-engineered human corneal endothelial grafts restore corneal function of rabbits with bullous keratopathy. *Sci Rep* 2017;7:14149
85. Dana R. A new frontier in curing corneal blindness. *N Engl J Med* 2018 15;378:1057-8
86. Nakagawa O, Fujisawa F, Ishizaki T, et al. ROCK-I and ROCK-II, two isoforms of Rhoassociated coiled-coil forming protein serine/threonine kinase in mice. *FEBS Lett* 1996 26;392:189-93
87. Riento K and Ridley AJ. Rocks: multifunctional kinases in cell behavior. *Nat Rev Mol Cell Biol* 2003;4:446-56
88. Narumiya S, Tanji M, and Ishizaki T. Rho signaling, ROCK and mDia1, in transformation, metastasis and invasion. *Cancer Metastasis Rev* 2009;28:65-76
89. Okumura N, Ueno M, Koizumi N, et al. Enhancement on primate corneal endothelial cell survival in vitro by a ROCK inhibitor. *Invest Ophthalmol Vis Sci* 2009;50:3680-7
90. Okumura N, Nakano S, Kay EP, et al. Involvement of cyclin D and p27 in cell proliferation mediated by ROCK inhibitors Y-27632 and Y-39983 during corneal endothelium wound healing. *Invest Ophthalmol Vis Sci* 2014 15;55:318-29
91. Peh GS, Adnan K, George BL, et al. The effects of Rho-associated kinase inhibitor Y-27632 on primary human corneal endothelial cells propagated using a dual media approach. *Sci Rep* 2015 16;5:9167
92. Okumura N, Koizumi N, Ueno M, et al. Enhancement of corneal endothelium wound healing by Rho-associated kinase (ROCK) inhibitor eye drops. *Br J Ophthalmol* 2011;95:1006-9
93. Van Horn DL, Hyndiuk RA. Endothelial wound repair in primate cornea. *Exp Eye Res* 1975;21:113-24

94. Van Horn DL, Sendele DD, Seideman S, et al. Regenerative capacity of the corneal endothelium in rabbit and cat. *Invest Ophthalmol Vis Sci* 1977;16:597-613
95. Matsubara M, Tanishima T. Wound-healing of the corneal endothelium in the monkey: a morphometric study. *Jpn J Ophthalmol* 1982;26:264-73
96. Okumura N, Koizumi N, Kay EP, et al. The ROCK inhibitor eye drop accelerates corneal endothelium wound healing. *Invest Ophthalmol Vis Sci* 2013 3;54:2493-502
97. Okumura N, Inoue R., Okazaki R, et al. Effect of the Rho kinase inhibitor Y-27632 on corneal endothelial wound healing. *Invest Ophthalmol Vis Sci* 2015;56:6067-74
98. Okumura N, Okazaki Y, Inoue R, et al. Effect of the Rho-associated kinase inhibitor eye drop (ripasudil) on corneal endothelial wound healing. *Invest Ophthalmol Vis Sci* 2016;57:1284-92
99. Wieben ED, Aleff RA, Tang X, et al. Trinucleotide repeat expansion in the transcription factor 4 (TCF4) gene leads to widespread mRNA splicing changes in Fuchs' endothelial corneal dystrophy. *Invest Ophthalmol Vis Sci* 2017;58: 343–352
100. Karimian A, Azizian K, Parsian H, et al. CRISPR/Cas9 technology as a potent molecular tool for gene therapy. *J Cell Physiol* 2019;234:12267-77
101. Zarouchlioti C, Sanchez-Pintado B, Hafford Tear NJ, et al. Antisense therapy for a common corneal dystrophy ameliorates TCF4 repeat expansion-mediated toxicity. *Am J Hum Genet* 2018;102:528–39
102. Hu J, Rong Z, Gong X, et al. Oligonucleotides targeting TCF4 triplet repeat expansion inhibit RNA foci and mis-splicing in Fuchs' dystrophy. *Hum Mol Genet* 2018;27:1015–26
103. Pinto BS, Saxena T, Oliveira R, et al. Impeding transcription of expanded microsatellite repeats by deactivated Cas9. *Mol Cell* 2017;68:479–90.e5
104. Chang YK, Hwang JS, Chung T-Y, et al. SOX2 activation using CRISPR/dCas9 promotes wound healing in corneal endothelial cells. *Stem Cells* 2018;36:1851–62
105. Zhu AY, Jaskula-Ranga V, Jun AS. Gene Editing as a Potential Therapeutic Solution for Fuchs Endothelial Corneal Dystrophy: The Future Is Clearer. *JAMA Ophthalmol* 2018 1;136:969-70

Chapter 10

Nederlandse Samenvatting
(Dutch Summary)

INTRODUCTIE

In de afgelopen twee decennia heeft de introductie van de lamellaire keratoplastiek een revolutie teweeggebracht op het gebied van hoornvliestransplantaties waarbij de penetrerende keratoplastiek (PKP) grotendeels vervangen is als de chirurgische voorkeursbehandeling voor aandoeningen van het cornea-endotheel.[1] Sinds de introductie van de endotheliale keratoplastiek (EK) in 1998 is deze geëvolueerd van diepe lamellaire endotheliale keratoplastiek (DLEK) naar Descemet stripping (automated) endotheliale keratoplastiek (DS(A)EK) en vervolgens naar Descemet membraan endotheliale keratoplastiek (DMEK).[2] Het verschil tussen deze technieken ligt vooral in het steeds dunner worden van het getransplanteerde weefsel. Wereldwijde schaarste aan donorweefsel voor hoornvliestransplantaties heeft geleid tot een verdere verfijning van de conventionele DMEK-techniek en de ontwikkeling van Hemi- en Quarter-DMEK.[3,4] Deze EK-technieken zouden de beschikbaarheid van endotheliaal donorweefsel mogelijk kunnen vergroten.

In dit proefschrift worden de methoden van donorweefselpreparatie voor DMEK en de toepasbaarheid en klinische resultaten van DMEK en gemodificeerde DMEK-technieken in de behandeling van aandoeningen van het cornea-endotheel geëvalueerd.

Deel I – Preparatie van donorweefsel

Adequate kennis van de hedendaags beschikbare DMEK donorweefselpreparatietechnieken kan corneachirurgen en oogbanken helpen bij het selecteren van de juiste aanpak voor de preparatie van donorweefsel (**hoofdstuk 2**).[5] De huidige en zich verder ontwikkelende technieken voor donorweefselpreparatie tonen een trend richting het gebruik van een '*no-touch*' techniek, waarbij er geen direct fysiek contact met het donorweefsel plaatsvindt met als doel het endotheelcelverlies tot een minimum te beperken.[6] De verschillende technieken kunnen grofweg in drie groepen worden opgedeeld: enerzijds manuele striptechnieken en anderzijds technieken die gebruik maken van lucht of vloeistof om donorweefsel te verkrijgen.[5] Hoewel de beschikbare technieken divers zijn en verschillende sterke en zwakke punten hebben, kunnen al deze verschillende benaderingen uitstekende resultaten opleveren.[5]

Deel II - Selectieve, minimaal invasieve en potentieel weefselsparende chirurgische behandelingsmogelijkheden voor aandoeningen van het cornea-endotheel

DMEK

Sinds de klinische introductie van DMEK in 2006, heeft deze techniek aan populariteit gewonnen bij de chirurgische behandeling van aandoeningen van het cornea-endotheel.[1,2] Verschillende studies hebben de resultaten van initiele studies inmiddels onderbouwd en op betrouwbare wijze aangetoond dat de eerste zes maanden na DMEK de meest kritische periode lijken te vormen, waarna de resultaten zich meestal stabiliseren.[7-15] Het groeiende DMEK-cohort bij het NIIOS en de daar simultaan meegroeiende dataset hebben ons in staat gesteld om gedetailleerde subgroep analyses te verrichten. Zodoende hebben we niet alleen een algemene analyse van de klinische resultaten in de eerste zes maanden na 1000 DMEK-operaties verricht maar hebben we ook geanalyseerd hoe operatie-indicatie (Fuchs endotheeldystrofie (FED) versus bulleuze keratopathie (BK)) en, specifiek in FED-ogen, preoperatieve lensstatus (eigen lens versus kunstlens) van invloed is op de resultaten (**hoofdstuk 3**).[16]
Onze studie toonde een vergelijkbaar hoge gezichtsscherpte voor zowel FED- als BK-ogen, na correctie voor preoperatieve gezichtsscherpte en de leeftijd van de patiënt. Daarom is het belangrijk om te benadrukken dat de meeste BK-ogen, zonder visus-beperkende comorbiditeiten, ook een goed visueel resultaat kunnen verwachten na DMEK, zelfs in de vroege postoperatieve fase. Hoewel de preoperatieve lensstatus statistisch gezien geen invloed heeft op de klinische uitkomsten na DMEK, verdient het behoud van de heldere ooglens de voorkeur in een deel van de jongere patiënten met FED en een relatief heldere lens, omdat zij dan nog steeds voordeel zouden kunnen hebben van hun resterende accommodatievermogen en een betere algehele optische kwaliteit van het oog. Daarnaast is het 5-jaarlijkse percentage van visueel significante cataractvorming na DMEK relatief laag (16%).[7] DMEK resulteert in uitstekende klinische resultaten met een hoge levensduur van de transplantaten tot minstens vijf jaar na de operatie (**hoofdstuk 4**). In deze reeks van de eerste 500 DMEK-ogen toonden FED-ogen een betere overlevingskans van het transplantaat vijf jaar na de operatie vergeleken met overige operatie-indicaties (93% voor FED versus 72% voor overige indicaties). Een leercurve van de techniek kan een rol hebben gespeeld bij het bereiken van hogere overlevingspercentages van de transplantaten. Dit bleek uit de hogere overlevingskans van de tweede 250 DMEK-operaties (94%) vergeleken met de eerste 250 DMEK-operaties (88%) en dit wordt verder onderbouwd door de significant lagere

overlevingskansen van ogen met een loslating van >1/3 van het oppervlak van het transplantaat (27%) ten opzichte van ogen met een volledig aanliggend transplantaat (95%) of een geringe loslating van ≤1/3 van het oppervlak van het transplantaat (91%). Grote loslatingen van het transplantaat kwamen minder vaak voor bij de tweede 250 DMEK-operaties (2.4%) vergeleken met de eerste 250 DMEK-operaties (4.4%). Deze uitkomsten ondersteunen het gunstige effect van een vroege re-bubbling procedure.

Deze studie bevestigt dat de uitstekende visuele resultaten die bij zes maanden na DMEK bereikt worden, ten minste vijf jaar na de operatie behouden blijven. Het totale percentage postoperatieve complicaties bleef gedurende de gehele 5-jarige studieperiode relatief laag. Gedeeltelijke loslating van het transplantaat was de voornaamste vroege postoperatieve complicatie terwijl transplantaatafstoting (in 2.8%) en secundair transplantaatfalen (in 2.8 %) tot de ernstigere complicaties in de latere postoperatieve periode behoorden. Re-keratoplastiek was nodig in een relatief laag percentage (8.8%) van ogen.

DMEK in ogen met complexe pathologie

Met specifieke chirurgische aanpassingen bleek DMEK uitvoerbaar in ogen met glaucoom en een al aanwezige drainage-implant en leverde het aanvaardbare klinische resultaten op (**hoofdstuk 5**).[17,18] Onze data tonen aan dat de aanwezigheid van een drainage-implant de levensduur van het transplantaat kan verminderen en aanleiding kan geven tot frequentere noodzaak tot re-keratoplastiek.De overlevingskans van het transplantaat in de eerstgenoemde groep ogen was 89% bij 1 jaar na DMEK, en daalde tot 67% bij 2 jaar na DMEK. De aanwezigheid van een drainage-implant had een slechte invloedop de donor endotheelceldichtheid (ECD). Eén jaar na DMEK was de ECD-daling 71%, wat bijna twee keer zo hoog is als voor ons standaard DMEK cohort. De incidentie van secundair transplantaatfalen (8.7%) was ook hoger vergeleken met ons standaard DMEK-cohort (2.0%). De oorzaak is mogelijk multifactorieel: veranderingen in de circulatiepatronen van het kamerwater als gevolg van de drainage-implant kunnen mogelijk de levensvatbaarheid van de endotheelcellen negatief beïnvloeden, of de drainage-implant zelf kan de bloed-kamerwater barrière hebben verstoord, o.a. als gevolg van hevig op het oog wrijven of krachtig knipperen. Dit kan leiden tot een toename van de instroom van oxidatieve en inflammatoire eiwitten die mogelijk schade kunnen toebrengen aan de endotheelcellen van het hoornvlies.[19-24] Bovendien kunnen ogen met glaucoom die een drainage-implant nodig hebben, ook vatbaarder

zijn voor immuunreacties, omdat glaucomateuze ganglioncelschade mogelijk gerelateerd is aan immuunreacties.[25]

Loslating van het transplantaat was de voornaamste vroege postoperatieve complicatie, met als gevolg dat bij 22% van de ogen een re-bubbling procedure moest worden uitgevoerd. Dit kan erop wijzen dat ogen met een drainage-implant meer risico lopen op chirurgische complicaties die mogelijk verband houden met de moeilijkheden om de druk te verhogen tegen het eind van de operatie.

De meeste van de waargenomen postoperatieve complicaties lijken inherent te zijn aan de aanwezigheid van een drainage-implant en kunnen gedeeltelijk worden voorkomen met behulp van chirurgische aanpassingen.[17,18] Voor deze selecte groep patiënten is het noodzakelijk om adequate begeleiding te bieden.

Gemodificeerde DMEK-technieken

Descemet membraan endotheliale transfer

In de beginjaren van EK werd algemeen aangenomen dat volledige hechting van het donorweefsel aan het centrale gedeelte van het hoornvlies van de gastheer nodig was om de helderheid van het hoornvlies te herstellen en visuele rehabilitatie te induceren. In de afgelopen tien jaar is in een toenemend aantal studies een spontane opheldering van het hoornvlies beschreven in aanwezigheid van een losliggend endotheeltransplantaat na DS(A)EK of DMEK, en in afwezigheid van een endotheeltransplantaat, dat wil zeggen na 'geïsoleerde descemetorhexis'. Deze observaties hebben bovenstaande hypothese en de noodzaak tot endotheelceltransplantatie na descemetorhexis in twijfel getrokken.[26-40] Descemet membraan endotheliale transfer (DMET), waarbij de descemetorhexis wordt gevolgd door het inbrengen van een bijna volledig vrij zwevende Descemet-rol (d.w.z. met fixatie van een heel klein gedeelte van het transplantaat in een corneosclerale incisie om contact met het achterste gedeelte van het hoornvlies te verzekeren) is een techniek met als doel opheldering van het hoornvlies te induceren door endotheelcelmigratie.[41]

Onze initiële evaluatie van DMET omvatte een cohort van 12 ogen van 12 patienten, zeven geopereerd voor FED en vijf voor BK, en toonde repopulatie van het posterieure stroma van de ontvanger en opheldering van het hoornvlies in alle ogen die werden geopereerd voor FED, maar niet in de ogen die werden

geopereerd voor BK.[41,42] Dit dit wekt de suggestie dat de onderliggende pathologie de belangrijkste determinant van de primaire klinische uitkomst zou kunnen zijn en dat met name endotheelcellen van de gastheer, en niet van de donor, bijdragen aan de opheldering van het hoornvlies.

Hoewel DMET aanvankelijk veelbelovende resultaten toonde in FED-ogen, toonde ons onderzoek naar de langetermijnresultaten van DMET-operaties aan dat, ongeacht de etiologie van de endotheelceldisfunctie, alle hoornvliezen uiteindelijk decompenseerden en re-EK nodig hadden (**hoofdstuk 6**).[43] Het regeneratieve vermogen van endotheelcellen in FED-ogen is waarschijnlijk ontoereikend om volledige en blijvende opheldering van het hoornvlies na DMET te bewerkstelligen. Volledige en blijvende rehabilitatie van het hoornvlies vereist zeer waarschijnlijk een (bijna) volledig, centraal aangehecht endotheeltransplantaat.

Hemi-DMEK

In 2014 werd Hemi-DMEK geïntroduceerd. Deze techniek maakt het mogelijk om één hoornvlies voor twee EK-procedures in twee FED-ogen van twee verschillende gastheren te gebruiken en heeft de potentie om de beschikbaarheid van endotheliaal donorweefsel te verdubbelen.[44]

Ons eerste cohort van tien Hemi-DMEK-ogen heeft aangetoond dat met Hemi-DMEK hetzelfde niveau van visuele rehabilitatie kan worden bereikt als met conventionele DMEK (**hoofdstuk 7**).[45-49] Hoewel opheldering van het perifere hoornvlies vertraagd optrad door lege stromale gebieden als gevolg van de mismatch van de cirkelvormige descemetorhexis en de halfronde vorm van het Hemi-DMEK-transplantaat, werd opheldering van het centrale hoornvlies van de gastheer niet negatief beïnvloed doordat het Hemi-DMEK-transplantaat precies zo werd gepositioneerd dat deze het centrale gedeelte van het hoornvlies bedekte, wat resulteerde in een snelle visuele rehabilitatie.

In de eerste zes maanden na Hemi-DMEK werd een grotere afname in ECD waargenomen dan na conventionele DMEK (65% versus 34%). Dit kan mogelijk worden verklaard door de verschillende patronen van endotheelcelredistributie en -migratie na Hemi-DMEK vergeleken metde conventionele DMEK-techniek, met name als gevolg van grotere lege stromale gebieden. Daarnaast kunnen ECD-metingen in verschillende gebieden van het transplantaat (centraal voor conventionele DMEK en meer perifeer of aan de rand van het Hemi-DMEK-transplantaat) leiden tot het verschil in ECD-daling. Na een aanvankelijke da-

ling in ECD, werd een jaarlijkse daling van ongeveer 6-7% in ECD gemeten, wat vergelijkbaar is met conventionele DMEK. Net zoals bij conventionele DMEK was de belangrijkste complicatie na Hemi-DMEK (partiële) loslating van het transplantaat (40%), wat gerelateerd kan worden aan de leercurve voor deze gemodificeerde DMEK-techniek. Een bijkomende factor kan het verschil inde vorm van het transplantaat zijn, omdat het Hemi-DMEK-transplantaat één kortere as heeft. Een groter aantal re-bubbling procedures moest worden verricht vanwege loslating van het transplantaat. Dit komt doordat kleine (partiële) loslatingen van het transplantaat bij Hemi-DMEK vaker de visuele as betreffen.

Quarter-DMEK

Gezien het aanvankelijke succes van Hemi-DMEK en het doel om hoornvliesdonorweefsel nog efficiënter te gebruiken, werd Quarter-DMEK geïntroduceerd.[50] Quarter-DMEK biedt het theoretische voordeel van een lagere antigeenbelasting door de donor en een mogelijke verviervoudiging van de hoeveelheid endotheliaal donorweefsel beschikbaar voor transplantatie omdat vier Quarter-DMEK-transplantaten kunnen worden verkregen, uit één donorcornea die vervolgens getransplanteerd kunnen worden in vier verschillende gastheren.[50] In onze eerste reeks van 19 Quarter-DMEK-ogen waren de BCVA-waarden gelijk aan de BCVA-waarden na conventionele- en Hemi-DMEK (**hoofdstuk 8**).[51,52] Quarter-DMEK resulteerde in snelle visuele rehabilitatie, echter de opheldering van het hoornvlies was trager dan na conventionele DMEK en bleef vooral achter langs de ronde, limbale rand van het Quarter-DMEK-transplantaat en de aangrenzende kale stromale gebieden.[51,52]

Uit *in vitro*-evaluatie van orgaan-gekweekte Quarter-DMEK-transplantaten is gebleken dat de migratie van endotheelcellen asymmetrisch is en voornamelijk plaatsvindt langs de radiale snijranden van het transplantaat, en niet langs de ronde rand van het transplantaat, d.w.z. de limbale periferie van het transplantaat.[53] Deze asymmetrische migratie van endotheelcellen van de cornea kan worden toegeschreven aan de verschillen in moleculaire structuur van de perifere DM.[53] Met de (initiële) opheldering van het hoornvlies en de endotheelcelmigratie die voornamelijk langs de radiale snijranden van het transplantaat plaatsvinden, zou het kunnen lonen om het transplantaat excentrisch te positioneren, dat wil zeggen met zijn radiale snijranden in de buurt van het pupillaire gebied en de perifere ronde rand in de buitenste rand van de cornea, ter preventie van een langzame vermindering van hoornvliesoedeem in de visuele as.

Visueel significante loslating van het transplantaat die een re-bubbling procedure vereist (42%) kwam in een vergelijkbaar percentage voor als na Hemi-DMEK (40%) maar in een iets hoger percentage vergeleken met de eerste 25 DMEK-operaties van de oorspronkelijke conventionele DMEK serie (36%). Dit kan te maken hebben met de moeilijke hanteerbaarheid van het transplantaat gedurende de operatie, met incongruente krommingen van het hoornvlies omdat het paracentrale gedeelte van het donorweefsel afgestemd wordt op het centrale hoornvlies van de gastheer, en/of met het feit dat loslating van het transplantaat bij Quarter-DMEK bijna altijd de visuele as betreft waardoor een re-bubbling procedure eerder wordt verricht. Net als bij Hemi-DMEK werd in de eerste zes maanden na de operatie een sterke initiële daling in de ECD waargenomen (68%), waarna een minder sterke daling volgde. Dit zou enerzijds kunnen komen door de verhoogde mate van chirurgische manipulatie van het transplantaat bij Hemi- en Quarter-DMEK en anderzijds door migratie van endotheelcellen die de kale stromale gebieden, als gevolg van de mismatch tussen de grote descemetorhexis en het kleinere Quarter-DMEK transplantaar, proberen te repopuleren.

Quarter-DMEK zou baat hebben bij: 1. het gebruik van een kleinere descemetorhexis (diameter) met als doel het oppervlak van de kale gebieden die moeten worden gerepopuleerd met endotheelcellen te verkleinen; 2. gemodificeerde protocollen voor preparatie van het Quarter-DMEK-transplantaat om zo het verlies van endotheelcellen langs de radiale snijranden van het transplantaat te minimaliseren en/of 3. door het elimineren van de ronde perifere rand van het Quarter-DMEK-transplantaat om zo de endotheelcelmigratie in de richting van het aangrenzende kale gebied in de perifere hoornvliesrand te bevorderen. Hoewel Quarter-DMEK voldoende opheldering van het hoornvlies kan induceren, zou lokale toediening van Rho-geassocieerde kinase (ROCK)-remmers, zoals ook toegepast bij 'Descemet stripping only' en endotheelcel-injectietherapieën, mogelijk de endotheelcelmigratie en de opheldering van het hoornvlies verder kunnen verbeteren.[54,55]

Slotopmerkingen

Preparatietechnieken voor DMEK-transplantaten zijn divers en hebben verschillende sterke en zwakke punten. Hoewel de toegepaste preparatietechniek het klinische resultaat na DMEK kan beïnvloeden, behoeft één enkele techniek niet universeel te worden toegepast. Het is echter belangrijk dat corneachirurgen en oogbankspecialisten die DMEK-donorweefsel prepareren op de hoogte zijn van de verschillende beschikbare technieken, zodat ze de beste benadering kunnen kiezen voor henzelf en voor hun specifieke situatie.

Verschillende studies hebben aangetoond dat DMEK resulteert in uitstekende klinische resultaten, zowel op de korte als op de middellange termijn, en voor verschillende chirurgische indicaties zowel voor FED als BK. DMEK bleek bovendien haalbaar in veel ogen met een complexere pathologie zoals glaucomateuze ogen met een drainage-implantaat. Hoewel DMET aanvankelijk veelbelovende resultaten toonde voor FED-ogen, faalde deze techniek uiteindelijk om een volledige en blijvende opheldering van het hoornvlies te bewerkstelligen. Dit benadrukt het belang van een goed aangehecht endotheeltransplantaat bij het bereiken van blijvende opheldering van het hoornvlies. Daarom zal in conventionele DMEK voorlopig de voorkeursbehandeling blijven er voor de lange termijn behandeling van aandoeningen van het cornea-endotheel.

Hemi-DMEK en Quarter-DMEK hebben potentie omdat de procedures klinische resultaten leveren die vergelijkbaar zijn met die van conventionele DMEK en daarbij de beschikbaarheid van endotheliaal donorweefsel kunnen vergroten. Indien studies met een langere follow-up duur aantonen dat de resultaten stabiel blijven, hebben deze technieken, in specifieke ogen met een beginstadium van FED, de potentie een alternatief te worden voor conventionele DMEK. Quarter-DMEK kan baat hebben van de ontwikkeling van chirurgische aanpassingen zodat optimalere klinische resultaten verkregen kunnen worden voor wat betreft de afname in de endotheelceldichtheid. Aanvullende studies zijn nodig ter verdere evaluatie van deze relatief nieuwe techniek.

Toekomstperspectief

State of the art lamellaire keratoplastiektechnieken hebben de klinische resultaten van hoornvliestransplantaties aanzienlijk verbeterd en het aantal postoperatieve complicaties, zoals afstoting en falen van het transplantaat, verminderd. Desalniettemin blijven postoperatieve complicaties een belangrijke oorzaak van re-keratoplastiek terwijl er tegelijkertijd wereldwijd een tekort aan hoornvliesdonorweefsel bestaat. De ontwikkelingen op het gebied van regeneratie van het cornea-endotheel zijn daarom gericht op het overwinnen van deze obstakels.

In de afgelopen jaren zijn Descemet stripping zonder endotheliale keratoplastiek (DWEK), ook wel bekend als Descemet stripping only (DSO), de klinische toepassing van *in vitro* gekweekte endotheelcellen, farmaceutische middelen zoals Rho kinase (ROCK)-remmers en gentherapie voorgesteld als alternatieve of aanvullende behandelingsopties in de behandeling van aandoeningen van het cornea-endotheel.

De talrijke waarnemingen van spontane opheldering van het hoornvlies in ogen met een endotheeldefect in afwezigheid van een endotheeltransplantaat leidden tot de introductie van de DWEK voor de behandeling van vroege FED-stadia.[26,27,36] Zoals de naam al doet vermoeden, wordt bij deze techniek het aangedane centrale deel van het Descemet Membraan (DM) en het nog aanwezige endotheel verwijderd zonder dat er donorendotheel wordt getransplanteerd.[29-35,37-40] DWEK heeft als doel de centripetale migratie van gezonde, perifere endotheelcellen te stimuleren ter vervanging van het centrale endotheel. Initiële case series betreffende de klinische uitkomsten van DWEK leverden gemengde resultaten op, waarbij de beste resultaten qua opheldering van het hoornvlies werden gerapporteerd voor operaties waarbij een kleine descemetorhexis van ongeveer drie à vier mm werd toegepast.[54] Dit kan worden verklaard door het beperkte en vergankelijke vermogen van het gastheer-endotheel om zichzelf te herstellen in ogen met FED, zoals waargenomen na DMET. Nadelen van DWEK zijn onder meer de onvoorspelbaarheid van opheldering van het hoornvlies en het gebleken suboptimale zicht op de langere termijn.[54] Voor deze techniek zijn snelle, langzame en niet-responsieve ogen beschreven. Aangezien er geen donorweefsel wordt gebruikt, worden de primaire uitkomsten bepaald door patiënt óf chirurgische factoren. In langzaam tot niet-responsieve ogen wordt de aanwezigheid van posterieure stromale littekens, gerelateerd aan loshalen van het stroma, vaker waargenomen.[54]Dit leidde tot de aanbeveling om DM te strippen zonder

dit eerst over 360 graden los te halen, met als doel zoveel mogelijk perifere endotheelcellen te behouden en de celmigratie te maximaliseren. Ook werd aanbevolen om de nadruk te leggen op de symmetrie en het centrering van de descemetorhexis gedurende de operatie om zo het optreden van 'ghosting' en irregulair astigmatisme te minimaliseren. Farmacologische hulpmiddelen zoals ROCK-remmers zouden het visuele herstel aanzienlijk kunnen versnellen en een hoger aantal centrale endotheelcellen. Bovendien worden ROCK-remmers beschreven als laatste redmiddel bij aanvankelijk niet-succesvolle DWEK-procedures.[56,57] Indien DWEK onvoldoende opheldering van het hoornvlies geeft, kan aansluitend alsnog EK worden verricht met een gunstige prognose. Hoewel DWEK een kosteneffectieve en tijdsefficiënte procedure zou kunnen zijn, is de wereldwijde acceptatie tot nu toe uitgebleven als gevolg van de inconsistente uitkomsten. Grotere studies met een langere follow-up duur zijn nodig om de potentie van deze techniek verder te evalueren.

In navolging van het concept van DWEK en nadat bij *in vitro* tests bleek dat endotheelcelmigratie na descemetorhexis mogelijk wordt vergemakkelijkt door de aanwezigheid van een Descemet membraan, werd de combinatie van primaire descemetorhexis gevolgd door acellulaire Descemet-membraan-transplantatie (DMT) geïntroduceerd.[58,59] Een eerste *in vivo* studie bij de mens toonde de potentie van deze techniek aan in het bereiken van repopulatie van het getransplanteerde acellulaire DM-transplantaat met gezonde, perifere gastheer-endotheelcellen en opheldering van het hoornvlies.[60] Verder onderzoek is nodig om de toegevoegde klinische waarde van deze techniek nader te bepalen.

Endotheelcellen van de humane cornea kunnen zich uitrekken en migreren, maar er wordt verondersteld dat zij zich niet *in vivo* vermenigvuldigen, terwijl zij dit *in vitro* wel doen.[61-64] Momenteel is EK de enige manier om aangedane, zieke endotheelcellen van de cornea (CEC) te vervangen. Het wereldwijde tekort aan endotheeltransplantaten heeft geleid tot de ontwikkeling van '*in vitro* gekweekte endotheelcellen', die vervolgens in de mens kunnen worden getransplanteerd. Transplantatie van *in vitro* gekweekte endotheelcellen is in principe gebaseerd op twee primaire benaderingen: drager-gebaseerd en cel-gebaseerd. Het concept van CEC-transplantatie werd geïntroduceerd door Jumblatt et al. in 1978.[65] In een proefdieronderzoek met konijnenogen werd aangetoond dat volledige transplantatie van een konijnen hoornvlies, bedekt met gekweekte endotheelcellen van een konijn, de transparantie van het hoornvlies kon herstellen.[66] Sindsdien hebben verscheidene studies de

haalbaarheid van het transplanteren van CEC om de helderheid van het hoornvlies te herstellen aangetoond, niet alleen *in vitro* maar ook *in vivo* met zowel niet-humane als humane CEC.[67-70] Alle aanvankelijk gerapporteerde procedures vereisten echter het gebruik van een menselijke donorcornea als drager van de CEC, wat de theoretische voordelen van gekweekte CEC-transplantatie teniet deed aangezien er nog steeds evenveel donorcornea's nodig zouden zijn om de patiënten te behandelen.[71] De introductie en het succes van lamellaire keratoplastiektechnieken zoals DS(A)EK en DMEK inspireerden wetenschappers tot het *in vitro* kweken van endotheelcelmembranen die vervolgens als een DS(A)EK/DMEK-transplantaat konden worden geïmplanteerd door middel van een DSAEK/DMEK-procedure. In eerdere *in vitro* studies is het gebruik van geïsoleerde DM, humane anterieure lenscapsules (HALC) en biotechnologische membranen bestaande uit zijde-fibroïne, collageen, gelatine of een combinatie van biopolymeren, als potentiële dragers voor gekweekte CEC geëvalueerd.[68,71-80] In latere *in vivo* proefdierstudies werd het gebruik van (gecrosslinkte) collageen membranen, door plastic samengeperste type I collageen membranen 'REAL architecture for 3D tissues' (RAFT) en biologische dragers zoals DM, HALC en amnion membraan getest.[72,78,79,81-84] Geen van de dragers die tot nu toe in de literatuur zijn vermeld, zijn echter een adequate vervanging van de huidige standaard EK-technieken en daarom hebben *in vitro* gekweekte endotheelcel-drager constructies nog geen toepassing gevonden in de klinische praktijk.

Om drager-gerelateerde uitdagingen te vermijden, werden alternatieve methoden voor transplantatie van gekweekte CEC getest, zoals het injecteren van vrij zwevende cornea-endotheelcellen in de voorste oogkamer. In 2018 toonde een 'proof of concept' klinische studie van Kinoshita et al. aan dat injectie van humane CEC in 11 humane ogen met BK de endotheellaag kon herstellen.[55] Na verwijdering van een deel van het aangedane hoornvliesendotheel (ongeveer acht mm in diameter) met een naald met een siliconen tip, werden *ex vivo* gekweekte CEC, tezamen met een ROCK-remmer, geïnjecteerd in de voorste oogkamer van de patiënt. Alle ogen toonden regeneratie aan van de éénlagige, vliesachtige structuur en herstel van de transparantie van het hoornvlies. 24 weken na de celinjectie bedroeg de ECD meer dan 500 cellen/mm^2 (spreiding, 947 tot 2833 cellen/mm^2).

Hoewel het injecteren van gekweekte CEC in de voorste oogkamer een veelbelovende minimaal invasieve benadering is, zijn grotere, prospectieve, gerandomiseerde studies nodig om deze techniek te verfijnen en om de werk-

zaamheid en veiligheid op de lange termijn te garanderen. Het betreft hierbij studies ter evaluatie van mogelijk schadelijke bijkomstige effecten (bijvoorbeeld vrij zwevende donorendotheelcellen die in de systemische circulatie terecht komen en de gevolgen daarvan), de immuunrespons (of het gebrek daaraan) van de gastheer op gekweekte geïnjecteerde endotheelcellen, de rol van HLA-matching en de mogelijke rol van ROCK-remmers.[85]

Het is goed mogelijk dat acceptatie van deze techniek, ondanks de succesvolle resultaten, uiteindelijk traag verloopt, omdat de protocollen zorgvuldig moeten worden gestandaardiseerd en moeten voldoen aan strikte regelgeving en beleid, waaronder een goede manier van produceren (GMP) voor de cel productie wat momenteel leidt tot zeer hoge kosten in vergelijking met standaard EK.

Het gebruik van ROCK-remmers, als farmaceutisch therapeutisch middel of hulpmiddel bij de behandeling van aandoeningen van het cornea-endotheel, is een onderwerp dat sterk in de belangstelling staat. ROCK is een serine/threonine kinase dat dient als een essentiële downstream-effector van Rho-GTPase, en als zodanig invloed heeft op celadhesie, motiliteit, proliferatie, differentiatie en apoptose.[86-89] Hoewel de meest bekende ROCK-remmer 'Y-27632' veelbelovende resultaten heeft aangetoond bij het bevorderen van de regeneratie van het hoornvliesendotheel in *in vitro* experimenten en in *in vivo* proefdiermodellen, lijkt het voorbarig om aan te nemen dat alle gunstige effecten van ROCK-remmers die in diermodellen zijn waargenomen, bij de mens zullen kunnen worden gereproduceerd aangezien dierlijke CEC een sterkere regeneratieve potentie hebben.[89-98] ROCK-remmers zijn ook beschreven als laatste redmiddel voor DWEK en als complementaire therapie bij DWEK en celtherapie.[54,84,97] Hoewel ROCK-remmers potentie hebben, moet hun werkzaamheid en veiligheid op het gebied van hoornvliesregeneratie *in vivo* verder worden vastgesteld in voldoende grote humane klinische studies.

Gentherapie wordt ook onderzocht als een mogelijke strategie in de behandeling van aandoeningen van het cornea-endotheel. Hoewel FECD genetisch heterogeen is, worden veel gevallen geassocieerd met toename van de trinucleotide cytosine-thymine-guanine (CTG) herhalingen in het TCF4-gen.[99] Opkomende therapieën die gebruik maken van antisense oligonucleotiden (AON) en prokaryotische geclusterde, regelmatig onderbroken palindromische repeat (CRISPR) endonucleases hebben als doel deze sequentie aan te pakken en de genexpressie ervan functioneel uit te schakelen.[100] Hoewel

ex vivo humane studies hebben aangetoond dat gentherapie een in potentie haalbare behandelingsoptie is in de behandeling/preventie van FED, moet verder onderzoek nog uitwijzen of dit ook geldt voor *in vivo* humane klinische studies.[101-105]

Nieuwe behandelingsmodaliteiten zoals regeneratieve therapieën, transplantatie van *in vitro* gekweekte endotheelcellen en gentherapie zijn geïntroduceerd en hebben veelbelovende preliminaire resultaten laten zien. Verder onderzoek is nodig om de huidige technieken te verfijnen en de therapeutische relevantie van elk van ze vast te kunnen stellen. Tot die tijd zal EK de standaard blijven in de behandeling van aandoeningen van het cornea-endotheel.

REFERENTIES

1. Eye Bank Association of America. *2019 Eye Banking Statistical Report* Washington, DC: Eye Bank Association of America; 2020
2. Melles GR. Posterior lamellar keratoplasty: DLEK to DSEK to DMEK. *Cornea* 2006;25:879-81
3. Lam FC, Baydoun L, Dirisamer M, et al. Hemi-Descemet membrane endothelial keratoplasty transplantation: a potential method for increasing the pool of endothelial graft tissue. *JAMA Ophthalmol* 2014;132:1469–73
4. Müller TM, Lavy I, Baydoun L, et al. Case report of Quarter-Descemet membrane endothelial keratoplasty for fuchs endothelial dystrophy. *Cornea* 2017;36:104–7
5. Birbal RS, Sikder S, Lie JT, et al. Donor tissue preparation for Descemet membrane endothelial keratoplasty: An updated review. *Cornea* 2018;37:128-35
6. Terry MA. Endothelial keratoplasty: why aren't we all doing Descemet membrane endothelial keratoplasty? *Cornea* 2012;31:469–71
7. Birbal RS, Ni Dhubhghaill S, Bourgonje VJA, et al. Five-year graft survival and clinical outcomes of 500 consecutive cases after Descemet membrane endothelial keratoplasty. *Cornea* 2020;39:290-7
8. Rodríguez-Calvo-de-Mora M, Quilendrino R, Ham L, et al. Clinical outcome of 500 consecutive cases undergoing Descemet's membrane endothelial keratoplasty. *Ophthalmology* 2015;122:464–70
9. Hamzaoglu EC, Straiko MD, Mayko ZM, et al. The first 100 eyes of standardized Descemet stripping automated endothelial keratoplasty versus standardized Descemet membrane endothelial keratoplasty. *Ophthalmology* 2015;122:2193–9
10. Deng SX, Lee WB, Hammersmith KM, et al. Descemet membrane endothelial keratoplasty: safety and outcomes: a report by the American Academy of Ophthalmology. *Ophthalmology* 2018;125:295–310
11. Guerra FP, Anshu A, Price MO, et al. Descemet's membrane endothelial keratoplasty: prospective study of 1-year visual outcomes, graft survival, and endothelial cell loss. *Ophthalmology* 2011;118:2368–73
12. Feng MT, Price MO, Miller JM, et al. Air reinjection and endothelial cell density in Descemet membrane endothelial keratoplasty: five-year follow-up. *J Cataract Refract Surg* 2014;40:1116–21
13. Schlögl A, Tourtas T, Kruse FE, et al. Long-term clinical outcome after Descemet membrane endothelial keratoplasty. *Am J Ophthalmol* 2016;169:218–26
14. Price DA, Kelley M, Price FW Jr, et al. Five-year graft survival of Descemet membrane endothelial keratoplasty (EK) versus Descemet stripping EK and the effect of donor sex matching. *Ophthalmology* 2018;125:1508–14
15. Schrittenlocher S, Schaub F, Hos D, et al. Evolution of consecutive Descemet membrane endothelial keratoplasty outcomes throughout a 5-year period performed by two experienced surgeons. *Am J Ophthalmol* 2018;190:171–8
16. Birbal RS, Baydoun L, Ham L, et al. Effect of surgical indication and preoperative lens status on Descemet membrane endothelial keratoplasty outcomes. *Am J Ophthalmol* 2020;212:79-87

17. Birbal RS, Tong CM, Dapena I, et al. Clinical outcomes of Descemet membrane endothelial keratoplasty in eyes with a glaucoma drainage device. *Am J Ophthalmol* 2019;199:150-8
18. Birbal RS, Tong CM, Dapena I, et al. Reply to a comment: Clinical outcomes of Descemet membrane endothelial keratoplasty in eyes with a glaucoma drainage device. *Am J Ophthalmol* 2019;208:440-1
19. Kim P, Amiran MD, Lichtinger A, et al. Outcomes of Descemet stripping automated endothelial keratoplasty in patients with previous glaucoma drainage device insertion. *Cornea* 2012;31:172–5
20. Schoenberg ED, Levin KH, Savetsky MJ, et al. Surgical outcomes of DSAEK in patients with prior Ahmed glaucoma drainage device placement. *Eur J Ophthalmol* 2013;23:807–13
21. Topouzis F, Coleman AL, Choplin N, et al. Follow-up of the original cohort with the Ahmed glaucoma valve implant. *Am J Ophthalmol* 1999;128:198–204
22. Williams KA, Lowe M, Bartlett C, et al. Risk factors for human corneal graft failure within the Australian corneal graft registry. *Transplantation* 2008;86:1720–24
23. Anshu A, Price MO, Richardson MR, et al. Alterations in the aqueous humor proteome in patients with a glaucoma shunt device. *Mol Vis* 2011;17:1891–1900
24. Rosenfeld C, Price MO, Lai X, et al. Distinctive and pervasive alterations in aqueous humor protein composition following different types of glaucoma surgery. *Mol Vis* 2015;21:911–18
25. Chen H, Cho KS, Vu THK, et al. Commensal microflora-induced T cell responses mediate progressive neurodegeneration in glaucoma. *Nat Commun* 2018;10;9:3209
26. Balachandran C, Ham L, Verschoor CA, et al. Spontaneous corneal clearance despite graft detachment in Descemet membrane endothelial keratoplasty (DMEK). *Am J Ophthalmol* 2009;148:227–34
27. Price FW Jr, Price MO. Comment on “Spontaneous corneal clearance despite graft detachment after Descemet membrane endothelial keratoplasty.” *Am J Ophthalmol* 2010;149:173–4; author reply 174–5
28. Zafirakis P, Kymionis GD, Grentzelos MA, et al. Corneal graft detachment without corneal edema after Descemet stripping automated endothelial keratoplasty. *Cornea* 2010;29:456–8
29. Moloney G, Petsoglou C, Ball M, et al. Descemetorhexis without grafting for Fuchs endothelial dystrophy—supplementation with topical ripasudil. *Cornea* 2017;36:642–8
30. Iovieno A, Neri A, Soldani AM, et al. Descemetorhexis without graft placement for the treatment of Fuchs endothelial dystrophy: pre-liminary results and review of the literature. *Cornea* 2017;36:637–41
31. Galvis V, Tello A, Berrospi RD, et al. Descemetorhexis without endothelial graft in Fuchs dystrophy. *Cornea* 2016;35:e26–8
32. Borkar DS, Veldman P, Colby KA. Treatment of Fuchs endothelial dystrophy by Descemet stripping without endothelial keratoplasty. *Cornea* 2016;35:1267–73
33. Moloney G, Chan UT, Hamilton A, et al. Descemetorhexis for Fuchs’ dystrophy. *Can J Ophthalmol* 2015;50:68–72
34. Koenig SB. Planned Descemetorhexis without endothelial keratoplasty in eyes with Fuchs corneal endothelial dystrophy. *Cornea* 2015;34:1149–51

35. Satué Palacián M, Sánchez Pérez A, Idoipe Corta M, et al. Descemetorhexis and corneal clearing: a new perspective on the treatment of endothelial diseases. *Arch Soc Esp Oftalmol* 2014;89:1–3
36. Koenig SB. Long-term corneal clarity after spontaneous repair of an iatrogenic Descemetorhexis in a patient with Fuchs dystrophy. *Cornea* 2013;32:886–8
37. Shah RD, Randleman JB, Grossniklaus HE. Spontaneous corneal clearing after Descemet's stripping without endothelial replacement. *Ophthalmology* 2012;119:256–60
38. Bleyen I, Saelens IE, van Dooren BT, et al. Spontaneous corneal clearing after Descemet's stripping. *Ophthalmology* 2013;120:215
39. Braunstein RE, Airiani S, Chang MA, et al. Corneal edema resolution after "Descemetorhexis." *J Cataract Refract Surg 2003*;29:1436–9
40. Ziaei M, Barsam A, Mearza AA. Spontaneous corneal clearance despite graft removal in Descemet stripping endothelial keratoplasty in Fuchs endothelial dystrophy. *Cornea* 2013;32:e164–6
41. Dirisamer M, Ham L, Dapena I, et al. Descemet membrane endothelial transfer: "Free-floating" donor Descemet implantation as a potential alternative to "keratoplasty." *Cornea* 2012;31:194–7
42. Dirisamer M, Yeh RY, van Dijk K, et al. Recipient endothelium may relate to corneal clearance in Descemet membrane endothelial transfer. *Am J Ophthalmol* 2012;154:290–6
43. Birbal RS, Parker J, Dirisamer M, et al. Descemet Membrane Endothelial Transfer: Ultimate Outcome. *Cornea* 2018;37:141-4
44. Lam FC, Baydoun L, Dirisamer M, et al. Hemi-Descemet membrane endothelial keratoplasty transplantation: a potential method for increasing the pool of endothelial graft tissue. *JAMA Ophthalmol* 2014;132:1469–73
45. Lam FC, Baydoun L, Satué M, et al. One year outcome of Hemi-Descemet membrane endothelial keratoplasty. *Graefes Arch Clin Exp Ophthalmol* 2015;253:1955–8
46. Lie JT, Lam FC, Groeneveld-van Beek EA, et al. Graft preparation for Hemi-Descemet membrane endothelial keratoplasty (hemi-DMEK). *Br J Ophthalmol* 2016;100:420–4
47. Gerber-Hollbach N, Parker J, Baydoun L, et al. Preliminary outcome of Hemi-Descemet membrane endothelial keratoplasty for Fuchs endothelial dystrophy. *Br J Ophthalmol* 2016;100:1564–8
48. Müller TM, Baydoun L, Melles GR. 3-Year update on the first case series of Hemi-Descemet membrane endothelial keratoplasty. *Graefes Arch Clin Exp Ophthalmol* 2017;255:213–5
49. Birbal RS, Hsien S, Zygoura V, et al. Outcomes of Hemi-Descemet Membrane Endothelial Keratoplasty for Fuchs Endothelial Corneal Dystrophy. *Cornea* 2018;37:854-8
50. Müller TM, Lavy I, Baydoun L, et al. Case report of Quarter-Descemet membrane endothelial keratoplasty for Fuchs endothelial dystrophy. *Cornea* 2017;36:104–7
51. Zygoura V, Baydoun L, Ham L, et al. Quarter-Descemet membrane endothelial keratoplasty (Quarter-DMEK) for Fuchs endothelial corneal dystrophy: 6 months clinical outcome. *Br J Ophthalmol* 2018;102:1425–30
52. Birbal RS, Ni Dhubhghaill S, Baydoun L, et al. Quarter-Descemet Membrane Endothelial Keratoplasty: One- to Two-Year Clinical Outcomes. *Cornea* 2020;39:277-82
53. Miron A, Spinozzi D, Bruinsma M, et al. Asymmetrical endothelial cell migration from in vitro Quarter-Descemet membrane endothelial keratoplasty grafts. *Acta Ophthalmol* 2018;96:828–33

54. Garcerant D, Hirnschall N, Toalster N, et al. Descemet's stripping without endothelial keratoplasty. *Curr Opin Ophthalmol* 2019;30:275-85
55. Kinoshita S, Koizumi N, Ueno M, et al. Injection of cultured cells with a ROCK inhibitor for bullous keratopathy. *N Engl J Med* 2018; 378: 995-1003
56. Huang MJ, Kaine S, Dhaliwal DK. Descemetorhexis without endothelial keratoplasty verses DMEK for treatment for Fuchs endothelial corneal dystrophy. *Cornea* 2018; 37: 1479-83
57. Macsai MS, Shiloach M. Use of topical rho kinase inhibitors in the treatment of Fuchs dystrophy after Descemet stripping only. *Cornea* 2019; 38: 529-534
58. Bhogal M, Lwin CN, Seah XY, et al. Allogeneic Descemet's Membrane Transplantation Enhances Corneal Endothelial Monolayer Formation and Restores Functional Integrity Following Descemet's Stripping. *Invest Ophthalmol Vis Sci* 2017 1;58:4249-4260
59. Soh YQ, Peh G, George BL, et al. Predictive Factors for Corneal Endothelial Cell Migration. *Invest Ophthalmol Vis Sci* 2016;57:338-48
60. Soh YQ, Mehta JS. Regenerative Therapy for Fuchs Endothelial Corneal Dystrophy. *Cornea* 2018;37:523-27
61. Joyce NC, Meklir B. Joyce SJ, et al. Cell cycle protein expression and proliferative status in human corneal cells. *Invest Ophthalmol Vis Sci* 1996; 37: 645-55
62. Joyce N. Proliferative capacity of corneal endothelial cells. *Exp Eye Res* 2012; 95: 16-23
63. Baum JL, Niedra R, Davis C, et al. Mass culture of human corneal endothelial cell. *Arch Ophthalmol* 1979; 97: 1136-40
64. Soh YQ, Peh GS, Mehta JS. Translational tissues for human corneal endothelial tissue engineering. *J Tissue Eng Regen Med* 2017; 11: 2425-42
65. Jumblatt MM, Maurice DM, McCulley JP. Transplantation of tissue-cultured corneal endothelium. *Invest Ophthalmol Vis Sci* 1978;17:1135-41
66. Jumblatt MM, Maurice DM, McCulley JP. Transplantation of tissue-cultured corneal endothelium. *Invest Ophthalmol Vis Sci* 1978;17:1135–41
67. Gospodarowicz D, Greenburg G, Alvarado J. Transplantation of cultured bovine corneal endothelial cells to rabbit cornea: clinical implications for human studies. *Proc Natl Acad Sci U S A* 1979;76:464–8
68. Ishino Y, Sano Y, Nakamura T, et al. Amniotic membrane as a carrier for cultivated human corneal endothelial cell transplantation. *Invest Ophthalmol Vis Sci* 2004;45:800–06
69. Sumide T, Nishida K, Yamato M, et al. Functional human corneal endothelial cell sheets harvested from temperature-responsive culture surfaces. *Faseb J* 2006;20:392–4
70. Hitani K, Yokoo S, Honda N, et al. Transplantation of a sheet of human corneal endothelial cell in a rabbit model. *Mol Vis* 2008;14:1–9
71. Okumura N, Koizumi N. Regeneration of the Corneal Endothelium. *Curr Eye Res* 2020;45:303-12
72. Mimura T, Yamagami S, Amano S. Corneal endothelial regeneration and tissue engineering. *Progr Retin Eye Res* 2013;35:1–17
73. Mimura T, Yamagami S, Yokoo S, et al. Cultured human corneal endothelial cell transplantation with a collagen sheet in a rabbit model. *Invest Ophthalmol Vis Sci* 2004;45:2992–7
74. Watanabe R, Hayashi R, Kimura Y, et al. A novel gelatin hydrogel carrier sheet for corneal endothelial transplantation. *Tissue Eng Part A* 2011;17:2213–9

75. Liang Y, Liu W, Han B, et al. Fabrication and characters of a corneal endothelial cells scaffold based on chitosan. *J Mater Sci Mater Med* 2011;22:175–83
76. Parikumar P, Haraguchi K, Ohbayashi A, et al. Successful transplantation of in vitro expanded human cadaver corneal endothelial precursor cells on to a cadaver bovine's eye using a nanocomposite gel sheet. *Curr Eye Res* 2014;39:522–26
77. Parikumar P, Haraguchi K, Senthilkumar R, et al. Human corneal endothelial cell transplantation using nanocomposite gel sheet in bullous keratopathy. *Am J Stem Cells* 2018;7:18–24
78. Kopsachilis N, Tsinopoulos I, Tourtas T, et al. Descemet's membrane substrate from human donor lens anterior capsule. *Clin Exp Ophthalmol* 2012;40:187–94
79. Yoeruek E, Saygili O, Spitzer MS, et al. Human anterior lens capsule as carrier matrix for cultivated human corneal endothelial cells. *Cornea* 2009;28:416–20
80. Spinozzi D, Miron A, Bruinsma M, et al. Evaluation of the suitability of biocompatible carriers as artificial transplants using cultured porcine corneal endothelial cells. *Curr Eye Res* 2019;44:243-9
81. Navaratnam J, Utheim TP, Rajasekhar VK, et al. Substrates for expansion of corneal endothelial cells towards bioengineering of human corneal endothelium. *J Funct Biomater* 2015;6:917–45
82. Koizumi N, Sakamoto Y, Okumura N, et al. Cultivated corneal endothelial cell sheet transplantation in a primate model. *Invest Ophthalmol Vis Sci* 2007;48:4519–26
83. Levis HJ, Peh GS, Toh KP, et al. Plastic compressed collagen as a novel carrier for expanded human corneal endothelial cells for transplantation. *PLoS One* 2012;7:e50993
84. Peh GSL, Ang HP, Lwin CN, et al. Regulatory compliant tissue-engineered human corneal endothelial grafts restore corneal function of rabbits with bullous keratopathy. *Sci Rep* 2017;7:14149
85. Dana R. A new frontier in curing corneal blindness. *N Engl J Med* 2018 15;378:1057-8
86. Nakagawa O, Fujisawa F, Ishizaki T, et al. ROCK-I and ROCK-II, two isoforms of Rhoassociated coiled-coil forming protein serine/threonine kinase in mice. *FEBS Lett* 1996 26;392:189-93
87. Riento K and Ridley AJ. Rocks: multifunctional kinases in cell behavior. *Nat Rev Mol Cell Biol* 2003;4:446-56
88. Narumiya S, Tanji M, and Ishizaki T. Rho signaling, ROCK and mDia1, in transformation, metastasis and invasion. *Cancer Metastasis Rev* 2009;28:65-76
89. Okumura N, Ueno M, Koizumi N, et al. Enhancement on primate corneal endothelial cell survival in vitro by a ROCK inhibitor. *Invest Ophthalmol Vis Sci* 2009;50:3680-7
90. Okumura N, Nakano S, Kay EP, et al. Involvement of cyclin D and p27 in cell proliferation mediated by ROCK inhibitors Y-27632 and Y-39983 during corneal endothelium wound healing. *Invest Ophthalmol Vis Sci* 2014 15;55:318-29
91. Peh GS, Adnan K, George BL, et al. The effects of Rho-associated kinase inhibitor Y-27632 on primary human corneal endothelial cells propagated using a dual media approach. *Sci Rep* 2015 16;5:9167
92. Okumura N, Koizumi N, Ueno M, et al. Enhancement of corneal endothelium wound healing by Rho-associated kinase (ROCK) inhibitor eye drops. *Br J Ophthalmol* 2011;95:1006-9
93. Van Horn DL, Hyndiuk RA. Endothelial wound repair in primate cornea. *Exp Eye Res* 1975;21:113-24

94. Van Horn DL, Sendele DD, Seideman S, et al. Regenerative capacity of the corneal endothelium in rabbit and cat. *Invest Ophthalmol Vis Sci* 1977;16:597-613
95. Matsubara M, Tanishima T. Wound-healing of the corneal endothelium in the monkey: a morphometric study. *Jpn J Ophthalmol* 1982;26:264-73
96. Okumura N, Koizumi N, Kay EP, et al. The ROCK inhibitor eye drop accelerates corneal endothelium wound healing. *Invest Ophthalmol Vis Sci* 2013 3;54:2493-502
97. Okumura N, Inoue R., Okazaki R, et al. Effect of the Rho kinase inhibitor Y-27632 on corneal endothelial wound healing. *Invest Ophthalmol Vis Sci* 2015;56:6067-74
98. Okumura N, Okazaki Y, Inoue R, et al. Effect of the Rho-associated kinase inhibitor eye drop (ripasudil) on corneal endothelial wound healing. *Invest Ophthalmol Vis Sci* 2016;57:1284-92
99. Wieben ED, Aleff RA, Tang X, et al. Trinucleotide repeat expansion in the transcription factor 4 (TCF4) gene leads to widespread mRNA splicing changes in Fuchs' endothelial corneal dystrophy. *Invest Ophthalmol Vis Sci* 2017;58: 343–52
100. Karimian A, Azizian K, Parsian H, et al. CRISPR/Cas9 technology as a potent molecular tool for gene therapy. *J Cell Physiol* 2019;234:12267-77
101. Zarouchlioti C, Sanchez-Pintado B, Hafford Tear NJ, et al. Antisense therapy for a common corneal dystrophy ameliorates TCF4 repeat expansion-mediated toxicity. *Am J Hum Genet* 2018;102:528–39
102. Hu J, Rong Z, Gong X, et al. Oligonucleotides targeting TCF4 triplet repeat expansion inhibit RNA foci and mis-splicing in Fuchs' dystrophy. *Hum Mol Genet* 2018;27:1015–26
103. Pinto BS, Saxena T, Oliveira R, et al. Impeding transcription of expanded microsatellite repeats by deactivated Cas9. *Mol Cell* 2017;68:479–90.e5
104. Chang YK, Hwang JS, Chung T-Y, et al. SOX2 activation using CRISPR/dCas9 promotes wound healing in corneal endothelial cells. *Stem Cells* 2018;36:1851–62
105. Zhu AY, Jaskula-Ranga V, Jun AS. Gene Editing as a Potential Therapeutic Solution for Fuchs Endothelial Corneal Dystrophy: The Future Is Clearer. *JAMA Ophthalmol* 2018 1;136:969-70

Appendices

List of Publications

Acknowledgements

Curriculum Vitae

LIST OF PUBLICATIONS

1. Dockery PW, Parker JS, **Birbal RS**, Tong CM, Parker JS, Joubert KP and Melles GRJ. Clinical outcomes of Descemet membrane endothelial keratoplasty performed in eyes with comorbid keratoconus and corneal endothelial dysfunction. *Submitted for publication*
2. **Birbal RS**, Baydoun L, Ham L, Miron A, van Dijk K, Dapena I, Jager MJ, Böhringer S, Oellerich S and Melles GRJ. Effect of surgical indication and preoperative lens status on Descemet Membrane Endothelial Keratoplasty outcomes. *Am J Ophthalmol* 2020;212:79-87
3. **Birbal RS**, Parker JS, van Dijk K, Oellerich S, Dapena I and Melles GRJ. Hydrops after corneal perforation during manual deep anterior lamellar keratoplasty (DALK) for keratoconus. *Acta Ophthalmol* 2020;98:e522-3
4. **Birbal RS**, Ni Dhubhghaill S, Baydoun L, Ham L, Bourgonje V, Dapena I, Oellerich S and Melles GRJ. Quarter-Descemet Membrane Endothelial Keratoplasty: One- to two-year clinical outcomes. *Cornea* 2020;39:277-82
5. **Birbal RS**, Ni Dhubhghaill S, Bourgonje VJA, Hanko J, Ham L, Jager MJ, Böhringer S, Oellerich S and Melles GRJ. Five-year graft survival and clinical outcomes after Descemet membrane endothelial keratoplasty: Results of the first 500 consecutive cases. *Cornea* 2020;39:290-7
6. **Birbal RS**, Tong CM, Dapena I, Parker JS, Parker JS, Oellerich S and Melles GRJ. Reply to Comment: Descemet membrane endothelial keratoplasty in eyes with a glaucoma drainage device. *Am J Ophthalmol* 2019;208:440-1
7. Parker J, **Birbal RS**, van Dijk K, Oellerich S, Dapena I and Melles GRJ. Reply to Comment: Are Descemet membrane ruptures the root cause of corneal hydrops in keratoconic eyes? *Am J Ophthalmol* 2019;205:204-5
8. Tong CM, Parker JS, Dockery PW, **Birbal RS** and Melles GRJ. Use of intraoperative anterior segment optical coherence tomography for Bowman layer transplantation. *Acta Ophthalmol* 2019;97:e1031-2
9. Parker JS, **Birbal RS**, van Dijk K, Oellerich S, Dapena I and Melles GRJ. Are Descemet membrane ruptures the root cause of corneal hydrops in keratoconic eyes? *Am J Ophthalmol* 2019;205:147-52
10. **Birbal RS**, Tong CM, Dapena I, Parker JS, Parker JS, Oellerich S and Melles GRJ. Clinical outcomes of Descemet membrane endothelial keratoplasty in eyes with a glaucoma drainage device. *Am J Ophthalmol* 2019;199:150-8
11. **Birbal RS**, van Dijk K, Parker JS, Otten H, Belmoukadim M, Ham L, Baydoun L, Dapena I and Melles GRJ. Manual mid-stromal dissection to stabilize progressive corneal ectasia in keratoconus. *Eye Vis* 2018;11;5:26
12. Miron A, Spinozzi D, Bruinsma M, Lie J, **Birbal RS**, Baydoun L, Oellerich S and Melles GRJ. Asymmetrical endothelial cell migration from in vitro Quarter-DMEK grafts. *Acta Ophthalmol* 2018;96:828-33
13. Zygoura V, **Birbal RS**, van Dijk K, Parker J, Baydoun L, Dapena I and Melles GRJ. Validity of Bowman layer transplantation for keratoconus: visual performance at 5-7 years. *Acta Ophthalmol* 2018;96:e901-2
14. Dragnea DC, **Birbal RS**, Ham L, Dapena I, Oellerich S, van Dijk K and Melles GRJ. Bowman Layer transplantation for progressive keratoconus. *Eye Vis* 2018;12;5:24

15. Baydoun L, Zygoura V, Hsien S, **Birbal RS**, Spinozzi D, Lie J, Ham L, Oellerich S and Melles GRJ. Clinical feasibility of using multiple grafts from a single donor for Quarter-DMEK. *Acta Ophthalmol* 2018;96:e656-8
16. **Birbal RS**, Hsien S, Zygoura V, Parker JS, Ham L, van Dijk K, Dapena I, Baydoun L and Melles GRJ. Outcomes of Hemi-Descemet membrane endothelial keratoplasty for Fuchs endothelial corneal dystrophy. *Cornea* 2018;37:854-8
17. **Birbal RS**, Parker JS, Dirisamer M, Janicijevic A, Baydoun L, Dapena I and Melles GRJ. Descemet membrane endothelial transfer (DMET): Ultimate outcome. *Cornea* 2018;37:141-4
18. **Birbal RS**, Sikder S, Lie J, Groeneveld-van Beek E, Oellerich S and Melles GRJ. Donor tissue preparation for Descemet membrane endothelial keratoplasty (DMEK): An updated review. *Cornea* 2018;37:128-35
19. Livny E, Groeneveld-van Beek E, Lie J, Mangundap K, Bruinsma M, **Birbal RS**, van der Wees J and Melles GRJ. Minimizing graft preparation failure in Descemet membrane endothelial keratoplasty (DMEK). *Cornea* 2017;36:1452-7
20. Ham L, van Luijk C, Dapena I, Wong TH, **Birbal R**, van der Wees J and Melles GR. Endothelial cell density after descemet membrane endothelial keratoplasty: 1- to 2-year follow-up. *Am J Ophthalmol* 2009;148:521-7
21. Balachandran C, Ham L, **Birbal RS**, Wong TH, van der Wees J and Melles GR. Simple technique for graft insertion in descemet-stripping (automated) endothelial keratoplasty using a 30-gauge needle. *J Cataract Refract Surg* 2009;35:625-8
22. Lie JT, **Birbal R**, Ham L, Dapena I, van der Wees J and Melles GRJ. Reply to Comment by Athanasiadis I et al on: Donor tissue preparation for Descemet membrane endothelial keratoplasty. *J Cataract Refract Surg* 2009;35:408
23. Lie JT, **Birbal R**, Ham L, van der Wees J and Melles GR. Donor tissue preparation for Descemet membrane endothelial keratoplasty. *J Cataract Refract Surg* 2008;34:1578-83

A

Books/ Book chapters

1. Dockery PW, Parker JS, **Birbal RS**, van Dijk K, Tong M, Ambati B, Baydoun L, Dapena I and Melles GRJ. Bowman layer transplantation. In: The Keratoplasty – Practical guide. *Submitted for publication*
2. Tong M, Parker J, van Dijk K, **Birbal RS** and Melles GRJ. The Melles technique. In Jacob S (ed.): Mastering DALK – A video textbook on Deep anterior lamellar keratoplasty. 2019; Chapter 7
3. Parker JS, **Birbal RS**, van Dijk K, Tong M, Ambati B, Baydoun L, Dapena I and Melles GRJ. Bowman Layer Transplantation for Advanced Keratoconus. In Barbara A (ed.): Controversies in the management of keratoconus. 2019; Chapter 27
4. Parker J, **Birbal R** and Melles GRJ – Picture Perfect DMEK: A visual guide to a beautiful operation. 2018

ACKNOWLEDGEMENTS

It is with great pleasure that I am writing what will arguably be the most meaningful and most read chapter of this dissertation. I am greatly indebted to everyone who has, in some way, contributed to my personal or professional development, and would like to thank a few people in particular.

First and foremost, I wish to express my deepest gratitude to my greatest mentor Dr. Gerrit Melles. Dear Gerrit, I admire you for your creativity, perseverance, and vision, and would like to thank you for all the growth that I was privileged to experience under your tutelage. You truly inspire me.

I would like to acknowledge Professor Dr. Martine Jager. Dear Martine, I have been incredibly fortunate to have you as my adviser. Thank you for your invaluable guidance and support, not only throughout this endeavor but also beyond.

My sincere gratitude goes to all of our patients at the Melles Cornea Clinic Rotterdam who have generously shared their time, patience, and experiences, as well as to all our tissue donors and their families. Without them, corneal transplantation would not be possible.

I would like to extend a heartfelt thank you to the whole NIIOS team. Dr. Silke Oellerich, thank you for your invaluable guidance with all NIIOS research projects. Dr. Isabel Dapena and Dr. Lamis Baydoun, thank you for laying the foundation on which this thesis was built. Dr. Ruth Quilendrino, thank you for your kindness and warmth throughout this entire process. I feel honored to have you standing beside me as my paranymph on this special day. Professor Dr. Sorcha Ní Dhubhghaill, thank you for being a great mentor to me, and Dr. Jacqueline van der Wees, thank you for welcoming me back in the eye bank and for allowing me to advance my dexterity and eye banking knowledge.

Thank you to Dr. Stefan Böhringer and Dr. Laurence Frank for your help with the statistical analyses. Dr. Vincent Bourgonje, thank you for your assistance with cell counting and image acquisition. Dr. Hans Frank, working together again reminded me of old times. Thank you! Gertrude Kort, Kristin Mangundap, Katja Immerzeel, and Esther (Groeneveld-) van Beek, thank you for your friendship and for all that I was fortunate to learn from you.

It has truly been a privilege to work alongside and learn from the NIIOS fellows. I admire all of you for your wisdom, kindness, and taste for adventure. I have worked very closely with Dr. Vasiliki Zygoura and Dr. Diana Santander García and would like to thank the both of you for always teaching me in the clinic and beyond, and for all the fun moments that we were fortunate to share.

Dr. Shameema Sikder, thank you for your friendship and constant support.
Dr. Maya Tong, thank you for being a trusted friend whom I can rely on for advice and fantastic colleague for our projects together and throughout the writing of this thesis.

I would like to express my deepest gratitude to Dr. and Mrs. John Parker, to Dr. and Mrs. Jack Parker, and to Allison Parker for welcoming me in their clinic and homes. Thank you for your endless kindness and Southern hospitality. Roll tide!

My deep appreciation also goes out to my most kind and knowledgeable colleagues from Visser Contactlenzen: Henny Otten, Dieuwke van de Wiel-van Ooik and Marieke Carsouw.

I would like to acknowledge my mentor Dr. Michel J.W. Zaal and all my other colleagues at the Ophthalmic Medical Center Zaandam and Jongsma Medical. Thank you for your kindness and your endless willingness to teach me. Frédérique Bak, thank you for introducing me into the world of ocular prostheses, and for your constant encouragement.

To my dear friends: thank you for your endless support for my research, and for continuously reminding me of all the beautiful things in life outside of ophthalmology. Thank you for dragging me away from my books so I wouldn't miss out on some of the best times we have had together. I am lucky to have you!

Dear Mala mousie, I have been blessed to have had you as my second mother and wish you were still here to experience this special day with me. Shanice, I am so proud of the beautiful young woman that you have become and feel honored to have you standing beside me as my paranymph today. Dear Robby, thank you for our culinary adventures and other exciting endeavors. Dear Vinod bhai and Mala bhaudjie, thank you for your spiritual guidance.

My dear parents, thank you for your endless love, support and encouragement; and for teaching me the value of hard work and perseverance. To my beloved father: You have been, without a doubt, one of the greatest blessings in my life. I miss you. My sister and brother, Roshnie and Gregory, thank you for continuously encouraging and supporting me to follow my dreams. Dear Martijn and Shivani, I am happy that you have both become irreplaceable parts of our family. To my sweet little nephew and niece, Shayan and Gia: You are my little rays of sunshine.

CURRICULUM VITAE

Rénuka Sadhna Birbal was born on October 24, 1987 in The Hague, The Netherlands. She graduated from secondary school (Atheneum, Segbroek College, The Hague) in 2005, after which she started her medical training at the Erasmus University Rotterdam. During the first few years of her medical training, Rénuka worked as an eye bank technician at the Amnitrans EyeBank Rotterdam (AER) and a research student at the Netherlands Institute for Innovative Ocular Surgery (NIIOS) in Rotterdam (supervisor: Dr. G.R.J. Melles). She completed clinical and research minors with the Department of Obstetrics and Gynecology at the Singapore General Hospital in Singapore and the Department of Trauma Surgery at the Groote Schuur Hospital in Capetown, South-Africa. After obtaining her medical degree in 2015, Rénuka worked as a medical doctor at the Department of General Surgery at the Haaglanden Medical Center in The Hague. In 2016, Rénuka returned to NIIOS as a medical doctor and a research fellow, where she was responsible for specialized cornea consultations and assisting corneal surgeries at the Melles Cornea Clinic Rotterdam, and processing donor tissue at the AER. She participated in multiple research projects on the topics of eye banking and advanced lamellar keratoplasty techniques designed and implemented at NIIOS. These include projects with Parker Cornea in Birmingham, AL, USA. As part of the NIIOS Academy, Rénuka contributed to regional and international instructional and wetlab courses on eye banking and lamellar keratoplasty. In August 2017, she was accepted for a joint PhD-position at the Leiden University Medical Center and NIIOS (advisors: Prof. Dr. M.J. Jager and Dr. G.R.J. Melles). During this period, she continued her clinical and teaching duties. Renuka has presented her research at various national and international conferences, including as an invited expert speaker for an American keratoconus symposium. In January 2019, she was a member of the organizing committee for the annual meeting of the European Eye Bank Association in Rotterdam. In the summer of 2019, Rénuka completed a clinical observership at the Anterior and Refractive Surgery Department of the Adolphe de Rothschild Hospital Foundation and Institut Laser Vision Noémie de Rothschild in Paris, France (supervisor: Dr. D. Gatinel). She subsequently worked as a medical doctor in General Ophthalmology at the Ophthalmic Medical Center Zaandam, The Netherlands (supervisor: Dr. M.J.W. Zaal). Rénuka started as a medical doctor at the Department of Ophthalmology at the Radboud University Medical Center in Nijmegen, The Netherlands, on November 1, 2020, and will commence her residency at the same institute in January 2021 (residency program director: Dr. S. Keijser).