



Universiteit  
Leiden  
The Netherlands

## **Vulvar cancer : pathogenesis, molecular genetics and treatment**

Nooij, L.S.

### **Citation**

Nooij, L. S. (2018, June 28). *Vulvar cancer : pathogenesis, molecular genetics and treatment*. Retrieved from <https://hdl.handle.net/1887/62866>

Version: Not Applicable (or Unknown)

License: [Licence agreement concerning inclusion of doctoral thesis in the Institutional Repository of the University of Leiden](#)

Downloaded from: <https://hdl.handle.net/1887/62866>

**Note:** To cite this publication please use the final published version (if applicable).

Cover Page



Universiteit Leiden



The handle <http://hdl.handle.net/1887/62866> holds various files of this Leiden University dissertation

**Author:** Nooij, Linda

**Title:** Vulvar cancer : pathogenesis, molecular genetics and treatment

**Date:** 2018-06-28

## CHAPTER 8

### **General discussion and summary**



## General discussion and summary

Despite major advances in the past decade, treatment of vulvar cancer (VC) remains challenging and is still associated with significant mortality and morbidity. VC is a cancer type with a particularly high age of onset, with a peak incidence around seventy years of age. The fact that this cancer predominantly affects older women has important implications for treatment and recovery, as co-morbidities are not infrequent. VC is also a rare cancer with only around 300 new cases a year in the Netherlands. Due to this rarity, this cancer subtype is under researched and little is known about the carcinogenesis and its molecular features compared to other more frequently occurring cancers.

For this thesis we intended to shed light on some significant clinical issues as well as advancing our basic understanding of VC. The work presented in this thesis follows the current trend in medical oncology, in which we have sought for avenues towards individualising treatment for this particularly fragile patient population. In the first section, we challenge current guidelines regarding the extent of the surgical procedure for both the primary lesions as well as the groin area. Also, treatment options in case of a recurrence are discussed. In the second section the discussion continues with studies that increase our understanding of the VC carcinogenesis (e.g. initiating events and driver alterations) and how this may provide avenues towards personalised treatment.

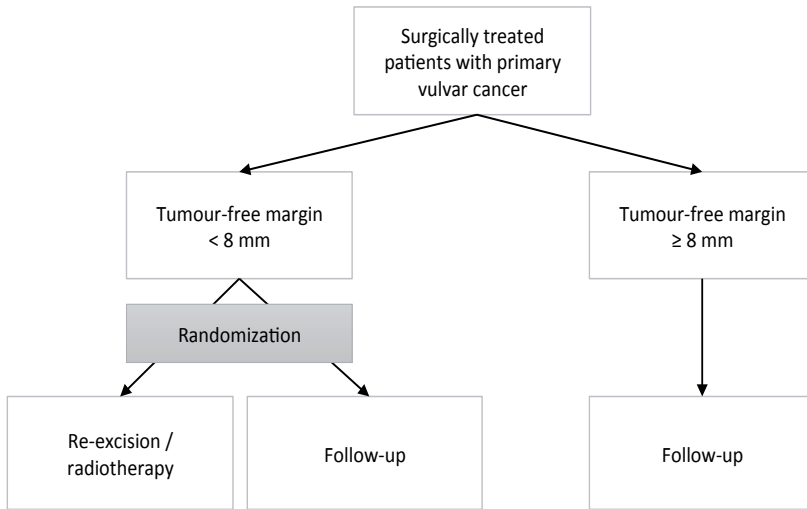
### *Section I. Clinical challenges in the treatment of vulvar cancer (chapter 2, 3 and 4)*

In the first section of this thesis we have focussed on two critical questions regarding the primary surgery of VC. In chapter 2 we asked ourselves what the limits are for safe tumour-free margins in VC. Arguably, this is the most important question in primary surgery of VC, because there's a fine balance between being radical and overtreatment. In recent years, following a trend seen in many other tumour types, surgery of VC has become more and more conservative (1, 2). The question of the minimal tumour-free margin has been asked before. At this moment a tumour-free margin of  $\geq 8$  mm is considered the norm to prevent local recurrence, which has been adopted in many guidelines (3-8). In our investigation we challenged this advice and examined whether a tumour-free margin of  $< 8$  mm is indeed associated with an increased chance of developing a local recurrence as compared to  $\geq 8$  mm (**chapter 2**). In this study we first performed a meta-analysis of current available literature and found a clear increase in local recurrence risk in the group of patients with a tumour-free margin of  $< 8$  mm (pooled risk ratio 1,99,  $p=0.02$ ), supporting the current guidelines (3, 4, 9, 10). However, the studies included in this meta-analysis were heterogeneous regarding tumour and treatment characteristics. A particular weakness we noticed was the lack of a clear definition of local recurrence. We then decided to perform a cohort study on VC patients treated in the LUMC, using a strict definition for local recurrence. We

defined a local recurrence as a histologically confirmed recurrence of VC within 2 years, located on the ipsilateral side of the vulva. In this cohort study we found that the chance of a (strictly defined) local recurrence was not different in patients with a tumour-free margin of < 8 mm (10%) versus  $\geq$  8 mm (12%). In fact, patients truly at high risk of a (strictly defined) local recurrence are those with tumour-positive margins (31%). From this we concluded that aiming for a tumour-free margin of 8 mm might be too stringent. This was further supported by a recent large study (11) on 289 VC patients with FIGO stage IB and higher, in which the authors found a local recurrence rate of 12.6% for patients with a tumour-free margin of < 8 mm and 10.2% for patients with a tumour-free margin of  $\geq$  8 mm ( $p=0.392$ ). None of the patients received adjuvant treatment after primary treatment (11).

Despite these convincing results on the limited role of a minimal tumour-free margin of 8 mm for prevention of local recurrence, clinicians are reserved in changing current guidelines and adjusting treatment strategy. The data presented in **chapter 2** and the study of Woelber et al. (11) argue that a tumour-free margin of < 8 mm should not be the determining factor for adjuvant treatment. Other tumour characteristics, such as tumour size, the presence of lymph vascular space invasion and tumour-positive lymph nodes have proven to be much stronger prognosticators with regard to the development of a local recurrence, and therefore these factors should determine the decision for re-excision or adjuvant radiotherapy (12-14). However, for the field to make such a change, the data on the prognostic impact of the tumour-free margins are probably insufficient. Not only are the available data conflicting, they are also based on retrospective cohorts. To overcome these limitations, a possible next step could be to perform a prospective randomised controlled trial aiming to investigate the benefit of adjuvant treatment for patients with a tumour-free margin of < 8 mm. Such a trial can be named 'Surgical Margins in the Treatment of Vulvar Cancer' (the SuMaToV-trial, figure 1). All patients who are surgically treated for primary VC can be included in the trial. Patients without an indication for adjuvant treatment based upon clinical or tumour characteristics other than a tumour-free margin of <8mm will be randomised between adjuvant treatment (standard arm) or no adjuvant treatment (experimental arm). Adjuvant treatment in the standard arm should consist of re-excision when possible or otherwise radiotherapy in accordance with the current guidelines (5-8). After a minimum of two year follow-up the first results can be analysed. The primary outcome is recurrence free survival. Secondary outcomes are treatment related morbidity and overall survival. Local recurrences should be registered according to a previous established strict definition as we used in our study; histologically confirmed recurrence on the ipsilateral side of the vulva within two years after primary treatment. As a translational component to this study, molecular analysis to define clonal relationship with the primary tumour may be considered. Treatment

related morbidity and overall survival should be registered in all patient groups. Through such a prospective study a final answer on this important clinical question is possible.



**Figure 1: Proposed randomization strategy for the SuMaToV trial (Surgical Margins in the Treatment of Vulvar cancer)**

Of course, our strict definition for local recurrence can be debated. So far, there is no golden standard definition, and therefore our definition is based upon common sense and the experience that most recurrences develop within two years after primary treatment (40-80%) (15, 16). Interestingly, a recently published long term follow-up study from the Groningen International Study on Sentinel nodes in Vulvar cancer (GROINNS-V) also found a relatively high percentage of late recurrences. Median time until local recurrence was 27 months and local recurrence rate was 27.2% 5 years after primary treatment and even 39.5% 10 years after primary treatment. Most of these local recurrences occurred more than two years after primary treatment (63.9%) (17). It can be argued, however, that many of these late recurrences are second primary tumours instead of true recurrences. It is assumed that the complete vulva is at risk for the development of multiple tumours due to a so called “field effect” or “field cancerization”. This assumption is supported by the clinical course of VC patients. It is not uncommon that VC patients present with multifocal tumours on the vulva, which are probably unrelated to each other. The concept of field cancerization is not unique to the vulva, and has also been described in other organ systems where (pre-)neoplastic processes are present at multiple sites. For example, field cancerization is a concept used in several other organ systems such as head and neck, lung, esophagus, cervix, colon, breast, bladder and skin (18-23). It has been shown that a contiguous (epi)genetically altered field can be the basis of multiple genetically related but independent lesions,

which probably should be regarded as second primary tumours rather than local recurrences. Such a field has been shown for metachronous lesions that were > 7 cm apart (18, 22). Given the strong association between VC and chronic lichen sclerosis (LS), LS may be regarded as “the field” that predisposes for the development of latent vulvar precancerous lesions. Whether these latent precancerous lesions progress is likely dependent on the acquisition of additional genetic alterations, which in turn result in subclones with uncontrolled cellular proliferation, such as *TP53* mutations in dVIN. Eventually, these subclones are likely to evolve into invasive cancer (18, 24). This sequence of events can occur at multiple different sites within the fields and at different points in time. Although data in support of this model in VC are still limited, it appears very likely to be applicable in this disease too.

The presence of a field has important implications when we consider the above described studies on local recurrences. We have proposed a clinical definition of true recurrence (ipsilateral and within 2 years), reflecting those lesions that are the result of incomplete removal of the primary tumour. New lesions that occur at the contralateral side of the vulva or after more than 2 years are unlikely the result of inadequate primary surgery, but rather the consequence of an incompletely excised field at risk. We currently don't know how to recognise, demarcate and remove or treat this field to prevent second primary tumours to occur, which would be a topic of great interest for future research. Precancerous lesions such as differentiated vulvar intraepithelial neoplasia (dVIN) or vulvar acanthosis with altered differentiation (VAAD) in the margins are currently not an indication for re-excision. In our study on the value of the histological margin (*chapter 2*) we also evaluated the influence of dVIN presence in the resection margin on local recurrence rate. We were not able to prove that the presence of dVIN increases local recurrence risk. Still, given the above described hypothesis, this seems plausible and should be further investigated in a more comprehensive study. In a study on 28 patients with head and neck squamous cell carcinoma (HNSCC) all margins of the surgical specimen were analysed to determine the extension of a genetically altered field. Genetic alterations were detected in 10/28 (36%) of the patients and in 7 patients these alterations were present in the surgical margins. After a median follow-up time of twelve months, none of these patients had developed a local recurrence (22).

Field cancerization might also explain the differences found in our meta-analysis (4, 9-11, 25, 26) and cohort study (*chapter 2*). The width of the tumour-free margin does not influence the chance of developing a true recurrence, a histologically confirmed recurrence within two years after primary treatment and on the ipsilateral side of the vulva. On the other hand, a tumour-free margin of > 8 mm increases the chance of removing “the field” and thereby theoretically decreases the chance of developing second primary tumours. This might explain the results found in our cohort study, in which



we held on to a very strict definition of local recurrence. The studies included in our meta-analysis often did not define a local recurrence, which probably means that all new tumours on the vulva were seen as local recurrences, independent of time or localization on the vulva.

Contradictory to our proposal for less radical surgery in the SuMaToV trial, but supportive for the presence of a field is a theory proposed by Höckel et al (27). The authors have studied early embryology to analyse local tumour spread and found that the pattern of local tumour spread for cervical and VC is confined by compartments defined by their embryonic development. This is called ontogenetic anatomy and the compartment theory (27, 28). Crossing the border of these compartments is a relative late step during malignant progression. In order to do this phenotypical changes of the tumour cells are necessary. Following this theory even more radical surgery to maintain local tumour control would be required. In one of their studies the authors performed vulvar field resection based upon the ontogenetic anatomy in 54 VC patients in order to investigate if this surgical approach results in an improvement of local tumour control. After a median follow-up time of nineteen months, none of the patients had developed a local recurrence. Unexpectedly, perioperative complication rate was low (29). So, perhaps indeed even more extensive surgery is necessary for prevention of a local recurrence as well as second primary tumours. On the other hand, less radical surgery will increase the chance of a second primary tumour, but reduces morbidity. The question arises whether the morbidity associated with more extensive surgery outweighs the benefits of preventing recurrent disease and thus which approach is best for the patient and results in a better overall survival.

In order to further investigate this it is necessary to make a genuine differentiation between true local recurrences and second primary tumours based upon molecular features rather than an arbitrary clinical definition. The development of our VC Next Generation Sequencing (NGS) panel (*chapter 7*) may serve this purpose as it can provide objective molecular data that can be used to define clonal relationships between two lesions, although a correct distinction between true recurrences and second primary tumours will be challenging and perhaps impossible in some cases. Hypothetically, a true local recurrence most likely will have an identical mutational profile, potentially accompanied with one or two additional somatic mutations. This would be the most likely situation based upon the hypothesis that a true local recurrence develops from tumour cells that were left behind during primary surgery. Second primary tumours will show a different mutational profile compared to the mutational profile of the previous tumour. These second primary tumours have developed after a different second hit elsewhere in the vulnerable field. If we are able to make a genuine distinction between true recurrences and second primary tumours we might also be able to implement this

difference in clinical practise and to advise different treatment strategies. Literature on HNSCC has shown that a second primary tumour has a more aggressive course than true local recurrences (23). This may also be true for VC patients which suggests that more radical surgery is indicated for patients with a second primary tumour followed by more stringent follow-up in comparison to patients with a true local recurrence.

A second clinical challenge in which the extent of surgery is under debate is the primary treatment of the groins in patients with VC, as extensive groin surgery is associated with high morbidity (30, 31). Yet, adequate treatment of the groins is critical, because a recurrence in the groin(s) is associated with an exceptional high mortality rate of up to 90% (32, 33). This high mortality rate is confirmed in our study on groin surgery in VC patients, in which we describe a nine times increased chance of dying for patients who develop a groin recurrence compared to patients who did not develop a groin recurrence (*chapter 3*). The introduction of the sentinel node (SN) procedure as a treatment alternative for the groins has proven to be safe and led to a dramatic decrease in postoperative morbidity of groin treatment (31, 34). Still, approximately half of the patients do not fulfil the criteria for undergoing a SN-procedure, i.e. a unifocal tumour, smaller than 4 cm (31, 34). For patients with a multifocal tumour and/or a tumour larger than 4 cm more extensive treatment is necessary. Currently, most guidelines advise a full inguinofemoral lymphadenectomy (IFL) for all these patients (2, 31). However, our analysis of the risk of recurrence in lymph node positive VC patients shows that nodal debulking followed by radiotherapy is a safe alternative treatment for patients with clinically suspicious lymph nodes and/or macrometastases (*chapter 3*). Our findings are supported by a previous study published by Hyde et al (35), with the difference that our study also addressed the morbidity in these patients. Our study shows a reduction in short term and long term postoperative morbidity in patients treated with nodal debulking, without adversely influencing the chance of developing a recurrence in the groin(s). A recently published review thoroughly investigated different surgical approaches and postoperative morbidity in VC patients who underwent an IFL. The authors found an overall post-operative wound complication rate of up to 85%. Furthermore, the authors found that this complication rate can be reduced slightly following specific surgical techniques such as: using separate incisions, unilateral IFL, sparing of the saphenous vein, preservation of the fascia lata and continuous skin sutures (31). Still, based on our study and the study from Hyde et al. (35) we propose nodal debulking to be the preferred treatment in patients with clinically suspicious lymph nodes and/or macrometastases, resulting in lower morbidity than full IFL. This advice is not yet included in the current guidelines (5, 6, 8). When the guidelines are revised these studies should be included in composing an advise.

The third clinical challenge in the treatment of VC addressed in this thesis, is the optimal treatment when VC does recur. The chance of developing a recurrence is high (12-37%) (12, 15) and this is relevant, as 5-year survival dramatically decreases for patients who develop a recurrence (25-50% versus 50-90% for patients with primary VC). The prognosis of patients with recurrent VC has not improved over the years (8, 13, 36). Therefore, there is an ongoing discussion on how to treat recurrent disease. In order to structure this discussion, this thesis provides an overview of up-to-date literature on the treatment of recurrent VC in order to give an evidence based advise for treatment of recurrent VC (*chapter 4*). In the context of a local recurrence, there is general consensus, that when feasible re-resection with clear margins is the treatment of choice. If surgery is not an option, (chemo)radiotherapy is a good alternative. Patients with a local recurrence with a depth of infiltration > 1mm are advised a full IFL when primary treatment of their VC did not comprise a full IFL (15, 37). This treatment strategy of the groins causes high morbidity rates and the question arises whether the SN-procedure is also a good alternative when treating patients with a local recurrence. Alternative treatment strategies are currently being investigated. A recently published study found that a repeat SN-procedure is feasible, although technically challenging (38). The GROINSS-V study group is aiming to investigate the safety of the SN-procedure for patients with a local recurrence in the next national GROINSS-V trial. The outcomes of this trial will probably contribute in further reducing treatment related morbidity if it proves that this procedure is also safe for patients with a local recurrence (34). In this context it might also be clinically relevant to distinguish between true local recurrences and second primary tumours.

Treatment of a groin recurrence is even more challenging, especially because a groin recurrence used to be considered as almost always fatal (14, 15). Yet, a recent study found a 50% survival rate for patients with a groin recurrence after 7 years and concludes that treatment of a groin recurrence is no longer merely palliative (39). At this moment, the advised treatment for a groin recurrence is surgery, consisting of either a full IFL or debulking, followed by radiotherapy when possible (33). Due to the improved survival rates for patients with a groin recurrence (39) further developments in the treatment of a groin recurrence are highly important.

#### *Pathogenesis of VC (chapter 5, 6 and 7)*

The second section of this thesis concentrates on the pathogenesis of VC with a focus on genetic alterations that might be involved. A gynaecologist in the outward patient clinic can encounter patients with various forms of vulvar complaints in different stages of vulvar disease. Patients who present with a vulvar precursor lesion are at risk of developing a VC in the course of their lives. The chance of developing VC depends on the type of the precursor lesion. Knowledge of the underlying mechanisms of initiation

and progression from a precursor lesion towards an invasive lesion is limited, and may inform preventive strategies. Up until now, VCs have been subdivided into two different biological subtypes; those that are associated with high risk Human Papilloma Virus (hrHPV) and those that are not (40-42). This dichotomy view, however, may be too simplistic and particularly little is known about the initiating and early driving events in the pathogenesis of non-HPV associated cancers

For HPV-dependent VC, in many ways the literature parallels that of HPV-dependent cervical cancer and head and neck cancer (43, 44). In that respect, the current application of HPV vaccination in the prevention and treatment of cervical cancer may also be used to prevent and treat VC (44). The nomenclature for vulvar precursor lesions has been somewhat confusing, however currently the hrHPV precursor vulvar high-grade squamous intraepithelial lesions (HSIL) is the preferred term (formerly known as usual VIN 2/3). Differentiation between HSIL, which has a 9-16% chance of progression to VC when left untreated (45) and low-grade squamous intraepithelial lesions (LSIL) (46, 47) is important, since vulvar LSILs are not pre-cancerous and treatment is only necessary if a patient has complaints (48). In **chapter 6** we investigated the diagnostic value of stathmin immunohistochemistry (IHC) as an adjunct marker to differentiate between LSIL and HSIL, and found a high sensitivity and specificity for HSIL lesions. Therefore, stathmin expression can be used as an additional marker in difficult cases, in which p16 and Ki67 are not conclusive (49).

Little is known about the pathogenesis of HPV-independent VCs and their precursor lesions called “differentiated VIN (dVIN)” (42, 45). Recent work, clearly demonstrates that dVIN has a high malignant potential, with 80% of all dVINs reported to progress to (invasive) cancer (42, 45, 50). Given the high malignant potential of untreated dVIN it is important to recognise these lesions early and assure patients of adequate treatment and follow-up. At this moment immunohistochemical staining with p53 is commonly used as a marker for dVIN, because *TP53* is frequently mutated in dVIN lesions. In other cancers, an aberrant expression pattern of p53 (either complete absent staining or a strong diffuse staining pattern) has been shown to be an excellent surrogate marker for *TP53* mutation (51). P53 IHC is therefore in pathology practice often used to differentiate between (HPV-associated) vulvar HSIL and dVIN (52). An interesting question that was raised during our studies was whether p53-IHC would also be a surrogate marker for the presence of a *TP53* mutation in the context of VCs. In this light we investigated the p53 staining pattern in the 36 VC patients in our NGS cohort (**chapter 7**) and compared these results with the mutational *TP53* status. Although this is a limited cohort size, we found a substantial concordance ( $\kappa = 0.72$ ) between IHC and NGS. Extension of these data is probably possible for vulvar precursor lesions and therefore, p53-IHC may be an easy to implement surrogate marker for *TP53* mutations in vulvar precursor lesions. We did

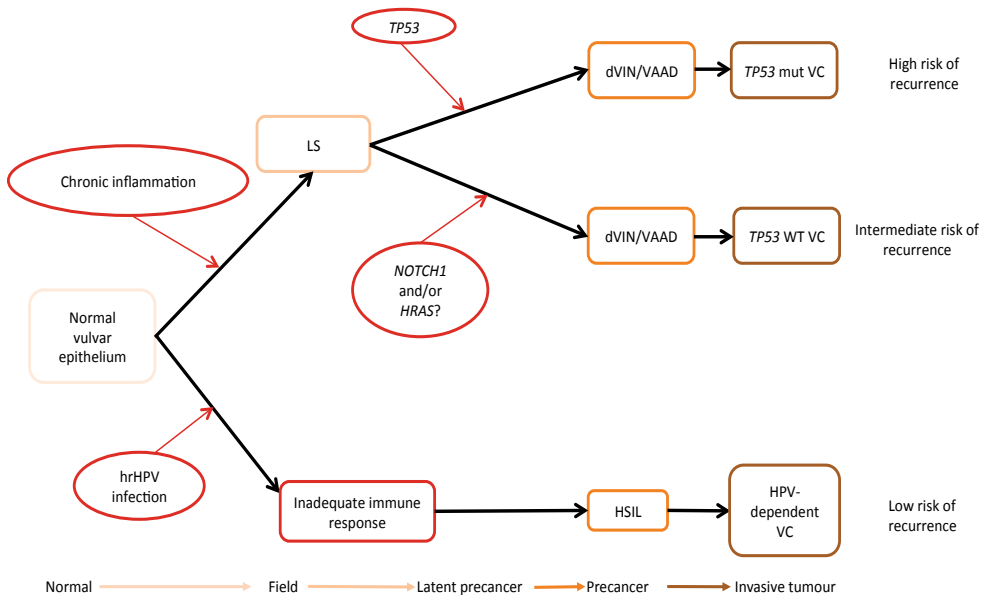
notice that p53 staining patterns in *TP53* mutant vulvar cancers can vary, and educating gynecopathologists will be required, as the interpretation of p53 staining is somewhat different from ovarian or endometrial adenocarcinomas. Recognizing the specific p53-IHC patterns will require further study and will likely improve the kappa, and thereby the utility of p53-IHC as an adequate surrogate.

**Chapter 5** of this thesis gives an overview of the current literature on (epi)genetic alterations and summarizes available molecular data in vulvar (pre)cancer thus far. Clearly, the (epi)genetic landscape of VC, and particularly its major precursor dVIN is largely unknown and limited to some studies confirming frequent *TP53* mutations (53-55). Therefore, we next aimed to explore the mutational landscape of vulvar (pre)cancer using targeted NGS (**chapter 7**). We found a high mutation frequency in HPV-independent dVIN and LS lesions in *TP53* (48% and 31%, respectively), *NOTCH1* (20% and 50%, respectively) and *HRAS* (10% and 31%, respectively). Interestingly, *HRAS* and *NOTCH1* mutations were relatively frequent in vulvar precancers that were *TP53* wildtype. The recurrent *NOTCH1* mutations in VC was a novel finding in this study. The exact role of *NOTCH1* in vulvar (pre)cancers remains uncertain. Reports on *NOTCH1* function describe *NOTCH1* as an oncogene as well as a tumour suppressor gene, depending on the tissue type. The canonical Notch pathway is probably oncogenic and mainly involved in cell proliferation, differentiation and survival (56). Dysregulated Notch plays a crucial role in tumour development by altering the developmental state of a cell and consequently maintaining the cells in a proliferative or undifferentiated state (57).

The findings in the HPV-independent VCs largely overlapped with the findings in the precancerous lesions with recurrent somatic mutations in *TP53*, *NOTCH1* and *HRAS*. This suggests that these gene alterations are likely relevant early events in the development of VC and supports a, not previously appreciated, third molecular subtype of VC. This subtype is HPV-independent and does not carry a pathogenic *TP53* mutation. In our study 10 of 29 VCs (35%) were HPV-independent and *TP53* wildtype. Earlier studies had implicitly identified this subtype, but did not give it any attention (53, 58, 59). Interestingly, HPV-independent and *TP53* wildtype cancers have also been identified in two large studies on HNSCC (60, 61), a tumour type that greatly resembles the oncogenesis of vulvar cancers. In the TCGA-study on 279 HNSCC, 36 cancers (13%) fell within the category (60). The earlier published study by Stransky et al. on 74 HNSCC patients, identified 16 (22%) of these cancers (61). A recent study in which full coding sequencing of *TP53* was performed found no somatic mutation in *TP53* in 14/59 (24%) HPV-independent VCs, supporting a third VC subtype (58). The initiating events and genetic alterations driving this subtype are unknown, but our work supports a role for *NOTCH1* and *HRAS* mutations in this subtype. Our study was limited to targeted mutational data, and therefore lacks information on genes that were

not in our panel. Therefore, we may have missed relevant copy number alterations or epigenetic changes, which should be a theme of future studies.

So, following the results from **chapter 7**, we can speculate on a refined VC oncogenesis model (Figure 2) in which we also incorporated field cancerization. We propose that LS is the oncogenic field of vulvar epithelial surface required to initiate tumorigenesis. This chronic inflammation results in an increased burden on the basal epithelial keratinocytes, effected the fidelity of DNA replication. This results in areas in which (epi)genetic changes accumulate and result in latent precancerous without a specific histological substrate. Subsequently, when the basal keratinocytes in these latent precancers encounter a somatic mutation in *TP53* or in *NOTCH1* the carcinogenesis is accelerated and results in histologically changes that fall within the spectrum of dVIN/VAAD. In the absence of *TP53* mutation it is possible that additional genomic alterations are required to progress towards invasive VC, however a pathogenic *TP53* mutations is likely sufficient for invasion. This model would favour resection of not only the invasive cancer, but also any visible precancer, in order to reduce the chance of a true recurrence. Second primary tumours arising from the oncogenic field and its latent precancers can't be prevented unless the field is completely excised .



**Figure 2: Proposed model for the pathogenesis of vulvar cancer**

LS: lichen sclerosus, dVIN: differentiated vulvar intraepithelial neoplasia, VAAD: vulvar acanathosis with altered differentiation, mut: mutant, WT: wildtype, VC: vulvar cancer, hrHPV: high risk human papilloma virus, HSIL: high grade squamous intraepithelial lesion

Obviously, a model of three molecular subtypes would only be of clinical value, if these three subtypes display a differential clinical behaviour (eg. risk of recurrence and or differential treatment response). Therefore, we evaluated the prognostic value of hrHPV on local recurrence rate and overall survival in **chapter 7**. We found a significant improved prognosis for HPV-dependent VCs compared to HPV-independent VCs. The group of patients with HPV-dependent VC developed a local recurrence in 5.3% of the patients and had a better disease specific five-year survival (p-value 0.049). HPV remained a favourable prognostic factor in multivariable analysis (hazard ratio 0.29, p-value 0.02), despite the association with better clinico-pathological characteristics. These results are supported by a recently published study by McAlpine et al, who also found a better progression free and disease specific survival in 217 patients with HPV-dependent VC (62). Previous studies on tumours that greatly resemble the pathogenesis of VC, i.e. penile squamous cell carcinoma (PSCC) and HNSCC also show comparable results, with an unequivocal difference in prognosis between HPV-dependent and HPV-independent patient groups. Patients with HPV-dependent tumours have less recurrences and a better overall survival (63, 64). Given these results it is tempting to consider universal HPV testing for patients with VC. However, due to the retrospective nature of these studies, the question whether the indolent behavior is independent of treatment remains unresolved. Currently, all patients with VC, irrespective of HPV status, are treated identical. Interestingly, studies in HNSCC patients have shown a better response of HPV-dependent tumours on adjuvant treatment (chemotherapy and radiotherapy) (64-66). In addition, one recently published study on 57 VC patients treated with radiotherapy with or without surgical resection found a better progression free and overall survival for patients with HPV-dependent tumours, suggesting sensitivity to radiation (67). Although further research in a prospective cohort is necessary to validate these outcomes, these results are promising and may inform future trial designs. It appears that patients with HPV-dependent VC may benefit from less extensive primary surgery and are more likely to respond to radiation. This may become relevant for both local treatment as well as for treatment of the groins. Furthermore, follow-up schemes of patients with HPV-dependent VC might be less intensive because of the minimal chance of developing a recurrence. In addition to a prognostic benefit for HPV-dependent VC patients, we evaluated the influence of aberrant or normal p53 staining on prognosis in the HPV-independent VC patients. Local recurrence rate was 16.3% for HPV-independent tumours with a p53 normal staining pattern and 22.6% for HPV-independent tumours with an aberrant staining pattern for p53. This difference was not significant (p-value 0.246), probably due to the number of patients included in our cohort. Expansion of a VC cohort with adequate follow-up will provide further insights on the clinical value of distinguishing three VC subtypes in future research.



*Conclusion*

In conclusion, the molecular heterogeneity of VCs offers novel avenues for the introduction of more individualized treatment strategies in the near future. HPV status and the presence of *TP53* mutations will likely become critical variables required to determine the extent of primary treatment and the necessity of adjuvant treatment, as well as the treatment strategy for recurrent VC. Furthermore, targeted therapy against certain somatic mutations as well as immune therapy will probably undergo a huge development in the next decades and will undoubtedly become part of the treatment plan of VC patients. These developments can contribute to a better prognosis for these patients and to less invalidating surgical and adjuvant treatment. To get these novel developments to our patients, however, prospective trials in which molecular analyses are an integral part, will be required.



## References

1. Hacker NF. Current management of early vulvar cancer. *AnnAcadMedSingapore*. 1998;27(5):688-92.
2. Hacker NF, Eifel PJ, van d, V. Cancer of the vulva. *IntJGynaecolObstet*. 2012;119 Suppl 2:S90-S6.
3. Heaps JM, Fu YS, Montz FJ, Hacker NF, Berek JS. Surgical-pathologic variables predictive of local recurrence in squamous cell carcinoma of the vulva. *Gynecol Oncol*. 1990;38(3):309-14.
4. de Hullu JA, Hollema H, Lolkema S, Boezen M, Boonstra H, Burger MP, et al. Vulvar carcinoma. The price of less radical surgery. *Cancer*. 2002;95(11):2331-8.
5. National Dutch Guideline Gynaecologic Tumors; Vulvar Carcinoma. <http://www.oncoline.nl> ed2015.
6. RCOG guideline vulval carcinoma. <https://www.rcog.org.uk/globalassets/documents/guidelines/vulvalcancerguideline.pdf> ed2015.
7. National Comprehensive Cancer Network guideline on vulvar cancer. [https://www.nccn.org/store/login/login.aspx?ReturnURL=http://www.nccn.org/professionals/physician\\_gls/pdf/vulvar.pdf](https://www.nccn.org/store/login/login.aspx?ReturnURL=http://www.nccn.org/professionals/physician_gls/pdf/vulvar.pdf) ed2016.
8. Guideline vulvar cancer, national cancer institute. 2015.
9. Chan JK, Sugiyama V, Pham H, Gu M, Rutgers J, Osann K, et al. Margin distance and other clinico-pathologic prognostic factors in vulvar carcinoma: a multivariate analysis. *Gynecol Oncol*. 2007;104(3):636-41.
10. Groenen SM, Timmers PJ, Burger CW. Recurrence rate in vulvar carcinoma in relation to pathological margin distance. *Int J Gynecol Cancer*. 2010;20(5):869-73.
11. Woelber L, Griebel LF, Eulenburg C, Sehoul J, Jueckstock J, Hilpert F, et al. Role of tumour-free margin distance for loco-regional control in vulvar cancer-a subset analysis of the Arbeitsgemeinschaft Gynakologische Onkologie CaRE-1 multicenter study. *Eur J Cancer*. 2016;69:180-8.
12. Gadducci A, Tana R, Barsotti C, Guerrieri ME, Genazzani AR. Clinico-pathological and biological prognostic variables in squamous cell carcinoma of the vulva. *Crit RevOncolHematol*. 2012;83(1):71-83.
13. Preti M, Ronco G, Ghiringhello B, Micheletti L. Recurrent squamous cell carcinoma of the vulva: clinicopathologic determinants identifying low risk patients. *Cancer*. 2000;88(8):1869-76.
14. Woelber L, Mahner S, Voelker K, Eulenburg CZ, Giesecking F, Choschzick M, et al. Clinicopathological prognostic factors and patterns of recurrence in vulvar cancer. *Anticancer Res*. 2009;29(2):545-52.
15. Coulter J, Gleeson N. Local and regional recurrence of vulval cancer: management dilemmas. *Best Pract Res Clin Obstet Gynaecol*. 2003;17(4):663-81.
16. Gadducci A, Cionini L, Romanini A, Fanucchi A, Genazzani AR. Old and new perspectives in the management of high-risk, locally advanced or recurrent, and metastatic vulvar cancer. *Crit RevOncolHematol*. 2006;60(3):227-41.
17. Te Grootenhuis NC, van der Zee AG, van Doorn HC, van d, V, Vergote I, Zanagnolo V, et al. Sentinel nodes in vulvar cancer: Long-term follow-up of the GROningen INternational Study on Sentinel nodes in Vulvar cancer (GROINSS-V) I. *GynecolOncol*. 2016;140(1):8-14.
18. Braakhuis BJ, Tabor MP, Kummer JA, Leemans CR, Brakenhoff RH. A genetic explanation of Slaughter's concept of field cancerization: evidence and clinical implications. *Cancer Res*. 2003;63(8):1727-30.

19. Torezan LA, Festa-Neto C. Cutaneous field cancerization: clinical, histopathological and therapeutic aspects. *AnBrasDermatol*. 2013;88(5):775-86.
20. Dakubo GD, Jakupciak JP, Birch-Machin MA, Parr RL. Clinical implications and utility of field cancerization. *Cancer Cell International*. 2007;7 :15 Mar 2007.
21. Slaughter DP, Southwick HW, Smejkal W. Field cancerization in oral stratified squamous epithelium; clinical implications of multicentric origin. *Cancer*. 1953;6(5):963-8.
22. Tabor MP, Brakenhoff RH, van Houten VM, Kummer JA, Snel MH, Snijders PJ, et al. Persistence of genetically altered fields in head and neck cancer patients: biological and clinical implications. *Clin Cancer Res*. 2001;7(6):1523-32.
23. Califano J, Westra WH, Meininger G, Corio R, Koch WM, Sidransky D. Genetic progression and clonal relationship of recurrent premalignant head and neck lesions. *Clin Cancer Res*. 2000;6(2):347-52.
24. Eva LJ, Ganesan R, Chan KK, Honest H, Malik S, Luesley DM. Vulval squamous cell carcinoma occurring on a background of differentiated vulval intraepithelial neoplasia is more likely to recur: a review of 154 cases. *J Reprod Med*. 2008;53(6):397-401.
25. Baiocchi G, Mantoan H, de Brot L, Badiglian-Filho L, Kumagai LY, Faloppa CC, et al. How important is the pathological margin distance in vulvar cancer? *Eur J Surg Oncol*. 2015;41(12):1653-8.
26. Catanzarite T, Neubauer N, Doll K, Singh D, Schink J, Lurain J. Margin status as predictor of recurrence in squamous cell carcinoma of the vulva: Challenging the 8 millimeter rule. *International Journal of Gynecological Cancer*. 2014;Conference: 14th Biennial Meeting of the International Gynecologic Cancer Society:October 2012.
27. Hockel M, Horn LC, Illig R, Dornhofer N, Fritsch H. Ontogenetic anatomy of the distal vagina: relevance for local tumor spread and implications for cancer surgery. *Gynecol Oncol*. 2011;122(2):313-8.
28. Hockel M, Horn LC. The puzzle of close surgical margins is not puzzling. *Gynecologic Oncology*. 2013;130(1):224-5.
29. Hockel M, Schmidt K, Bornmann K, Horn LC, Dornhofer N. Vulvar field resection: novel approach to the surgical treatment of vulvar cancer based on ontogenetic anatomy. *Gynecol Oncol*. 2010;119(1):106-13.
30. Gaarenstroom KN, Kenter GG, Trimbos JB, Agous I, Amant F, Peters AA, et al. Postoperative complications after vulvectomy and inguinofemoral lymphadenectomy using separate groin incisions. *IntJGynecolCancer*. 2003;13(4):522-7.
31. Pouwer AW, Arts HJ, van der Velden J, de Hullu JA. Limiting the morbidity of inguinofemoral lymphadenectomy in vulvar cancer patients; a review. *Expert Rev Anticancer Ther*. 2017:1-10.
32. Oonk MH, Hollema H, de Hullu JA, van der Zee AG. Prediction of lymph node metastases in vulvar cancer: a review. *IntJGynecolCancer*. 2006;16(3):963-71.
33. Cormio G, Loizzi V, Carriero C, Cazzolla A, Putignano G, Selvaggi L. Groin recurrence in carcinoma of the vulva: management and outcome. *EurJCancer Care (Engl)*. 2010;19(3):302-7.
34. van der Zee AG, Oonk MH, de Hullu JA, Ansink AC, Vergote I, Verheijen RH, et al. Sentinel node dissection is safe in the treatment of early-stage vulvar cancer. *JClinOncol*. 2008;26(6):884-9.

35. Hyde SE, Valmadre S, Hacker NF, Schilthuis MS, Grant PT, van d, V. Squamous cell carcinoma of the vulva with bulky positive groin nodes-nodal debulking versus full groin dissection prior to radiation therapy. *IntJGynecolCancer*. 2007;17(1):154-8.
36. Faul C, Miramow D, Gerszten K, Huang C, Edwards R. Isolated local recurrence in carcinoma of the vulva: Prognosis and implications for treatment. *International Journal of Gynecological Cancer*. 1998;8(5):409-14.
37. Salom EM, Penalver M. Recurrent vulvar cancer. *Curr TreatOptions Oncol*. 2002;3(2):143-53.
38. Doorn HC, van Beekhuizen HJ, Gaarenstroom KN, van d, V, van der Zee AG, Oonk M, et al. Repeat sentinel lymph node procedure in patients with recurrent vulvar squamous cell carcinoma is feasible. *GynecolOncol*. 2016.
39. Frey JN, Hampl M, Mueller MD, Gunthert AR. Should Groin Recurrence Still Be Considered as a Palliative Situation in Vulvar Cancer Patients?: A Brief Report. *Int J Gynecol Cancer*. 2016;26(3):575-9.
40. Del Pino M, Rodriguez-Carunchio L, Ordi J. Pathways of vulvar intraepithelial neoplasia and squamous cell carcinoma. *Histopathology*. 2013;62(1):161-75.
41. van der Avoort IA, Shirango H, Hoevenaars BM, Grefte JM, de Hullu JA, de Wilde PC, et al. Vulvar squamous cell carcinoma is a multifactorial disease following two separate and independent pathways. *IntJGynecolPathol*. 2006;25(1):22-9.
42. Preti M, Scurry J, Marchitelli CE, Micheletti L. Vulvar intraepithelial neoplasia. *BestPractResClinObstetGynaecol*. 2014;28(7):1051-62.
43. Sano D, Oridate N. The molecular mechanism of human papillomavirus-induced carcinogenesis in head and neck squamous cell carcinoma. *Int J Clin Oncol*. 2016;21(5):819-26.
44. Crosbie EJ, Einstein MH, Franceschi S, Kitchener HC. Human papillomavirus and cervical cancer. *Lancet*. 2013;382(9895):889-99.
45. van de Nieuwenhof HP, van der Avoort IA, de Hullu JA. Review of squamous premalignant vulvar lesions. *Crit RevOncolHematol*. 2008;68(2):131-56.
46. Bornstein J. The 2015 International Society for the Study of Vulvovaginal Disease Terminology of Vulvar Squamous Intraepithelial Lesions. 2015.
47. RJ K, ML C, CS H, RH Y. WHO classification of Tumours of Female Reproductive Organs. Lyon: IARC; 2014 2014.
48. Nelson EL, Bogliatto F, Stockdale CK. Vulvar Intraepithelial Neoplasia (VIN) and Condylomata. *ClinObstetGynecol*. 2015;58(3):512-25.
49. McCluggage WG. Premalignant lesions of the lower female genital tract: cervix, vagina and vulva. *Pathology*. 2013;45(3):214-28.
50. McAlpine JN, Kim SY, Akbari A, Eshragh S, Reuschenbach M, von Knebel Doeberitz M, et al. HPV-independent Differentiated Vulvar Intraepithelial Neoplasia (dVIN) is Associated With an Aggressive Clinical Course. *Int J Gynecol Pathol*. 2017.
51. Kobel M, Piskorz AM, Lee S, Lui S, LePage C, Marass F, et al. Optimized p53 immunohistochemistry is an accurate predictor of TP53 mutation in ovarian carcinoma. *J Pathol Clin Res*. 2016;2(4):247-58.

52. Singh N, Leen SL, Han G, Faruqi A, Kokka F, Rosenthal A, et al. Expanding the morphologic spectrum of differentiated VIN (dVIN) through detailed mapping of cases with p53 loss. *AmJSurgPathol*. 2015;39(1):52-60.
53. Flowers LC, Wistuba II, Scurry J, Muller CY, Ashfaq R, Miller DS, et al. Genetic changes during the multistage pathogenesis of human papillomavirus positive and negative vulvar carcinomas. *J Soc Gynecol Investig*. 1999;6(4):213-21.
54. Gasco M, Sullivan A, Repellin C, Brooks L, Farrell PJ, Tidy JA, et al. Coincident inactivation of 14-3-3sigma and p16INK4a is an early event in vulval squamous neoplasia. *Oncogene*. 2002;21(12):1876-81.
55. Aulmann S, Schleibaum J, Penzel R, Schirmacher P, Gebauer G, Sinn HP. Gains of chromosome region 3q26 in intraepithelial neoplasia and invasive squamous cell carcinoma of the vulva are frequent and independent of HPV status. *JClinPathol*. 2008;61(9):1034-7.
56. Borggrefe T, Oswald F. The Notch signaling pathway: transcriptional regulation at Notch target genes. *Cell MolLife Sci*. 2009;66(10):1631-46.
57. Aithal MG, Rajeswari N. Role of Notch signalling pathway in cancer and its association with DNA methylation. *JGenet*. 2013;92(3):667-75.
58. Kashofer K, Regauer S. Analysis of full coding sequence of the TP53 gene in invasive vulvar cancers: Implications for therapy. *Gynecol Oncol*. 2017.
59. Choschzick M, Hantaredja W, Tennstedt P, Giesecking F, Wolber L, Simon R. Role of TP53 mutations in vulvar carcinomas. *Int J Gynecol Pathol*. 2011;30(5):497-504.
60. Cancer Genome Atlas Research N. Comprehensive genomic characterization of head and neck squamous cell carcinomas. *Nature*. 2015;517(7536):576-82.
61. Stransky N, Egloff AM, Tward AD, Kostic AD, Cibulskis K, Sivachenko A, et al. The mutational landscape of head and neck squamous cell carcinoma. *Science*. 2011;333(6046):1157-60.
62. McAlpine JN, Leung S, Cheng A, Miller D, Talhouk A, Gilks CB, et al. HPV-independent vulvar squamous cell carcinoma has a worse prognosis than HPV-associated disease: a retrospective cohort study. *Histopathology*. 2017.
63. Lont AP, Kroon BK, Horenblas S, Gallee MP, Berkhof J, Meijer CJ, et al. Presence of high-risk human papillomavirus DNA in penile carcinoma predicts favorable outcome in survival. *Int J Cancer*. 2006;119(5):1078-81.
64. Fakhry C, Westra WH, Li S, Cmelak A, Ridge JA, Pinto H, et al. Improved survival of patients with human papillomavirus-positive head and neck squamous cell carcinoma in a prospective clinical trial. *JNatlCancer Inst*. 2008;100(4):261-9.
65. Chung CH, Gillison ML. Human papillomavirus in head and neck cancer: its role in pathogenesis and clinical implications. *ClinCancer Res*. 2009;15(22):6758-62.
66. Ragin CC, Taioli E. Survival of squamous cell carcinoma of the head and neck in relation to human papillomavirus infection: review and meta-analysis. *IntJCancer*. 2007;121(8):1813-20.
67. Lee LJ, Howitt B, Catalano P, Tanaka C, Murphy R, Cimbak N, et al. Prognostic importance of human papillomavirus (HPV) and p16 positivity in squamous cell carcinoma of the vulva treated with radiotherapy. *Gynecol Oncol*. 2016;142(2):293-8.



