



Universiteit  
Leiden  
The Netherlands

## Clinical outcomes of modern lamellar keratoplasty techniques

Dijk, K. van

### Citation

Dijk, K. van. (2018, January 16). *Clinical outcomes of modern lamellar keratoplasty techniques*. Retrieved from <https://hdl.handle.net/1887/59337>

Version: Not Applicable (or Unknown)

License: [Licence agreement concerning inclusion of doctoral thesis in the Institutional Repository of the University of Leiden](#)

Downloaded from: <https://hdl.handle.net/1887/59337>

**Note:** To cite this publication please use the final published version (if applicable).

Cover Page



Universiteit Leiden



The handle <http://hdl.handle.net/1887/59337> holds various files of this Leiden University dissertation

**Author:** Dijk, Korine van

**Title:** Clinical outcomes of modern lamellar keratoplasty techniques

Date: 2018-01-16

# Chapter 7

Bowman layer transplantation to reduce and stabilize advanced progressive keratoconus

Korine van Dijk, Vasilis S. Liarakos, Jack Parker, Lisanne Ham, Jessica T. Lie, Esther A. Groeneveld-van Beek, and Gerrit R.J. Melles

Ophthalmology 2015;122:909-917

2

3

4

6

7

8

9

10

A

**ABSTRACT**

**Objective.** To evaluate the clinical outcome of mid-stromal isolated Bowman layer transplantation, a new surgical technique to reduce and stabilize ectasia in eyes with advanced keratoconus, to postpone penetrating keratoplasty or deep anterior lamellar keratoplasty and to enable continued daily contact lens wear.

**Design.** Prospective, non-randomized cohort study at a tertiary referral center.

**Participants.** Twenty-two eyes of 19 patients with progressive, advanced keratoconus, not eligible for UV-crosslinking.

**Interventions.** A mid-stromal manual dissection was made and an isolated donor Bowman layer was positioned within the stromal pocket. Main Outcome Measures: Before and up to 36 months after surgery (mean follow-up 21 ( $\pm$ 7) months), best spectacle-corrected visual acuity (BSCVA), best contact lens corrected visual acuity (BCLVA), Scheimpflug-based corneal tomography measurements, endothelial cell density, biomicroscopy, refraction, and intra- and postoperative complications were recorded.

**Results.** Two surgeries were complicated by an intra-operative perforation of Descemet membrane; no other intraoperative or postoperative complications were observed. Kmax decreased on average from 77.2 ( $\pm$ 6.2) diopters (D) to 69.2 ( $\pm$ 3.7) D ( $P$ <.001) at one month after surgery and remained stable thereafter ( $P$  $\geq$ .072). Mean BSCVA improved from 1.27 ( $\pm$ 0.44) logarithm of the minimum angle of resolution units before surgery to 0.90 ( $\pm$ 0.30) logarithm of the minimum angle of resolution units 12 months after surgery ( $P$ <.001), while BCLVA remained stable ( $P$ =.105). Mean thinnest point pachymetry increased from 332 ( $\pm$ 59)  $\mu$ m preoperative to 360 ( $\pm$ 50)  $\mu$ m at the latest follow up ( $P$ =.012), and no change in endothelial cell density was found ( $P$ =.355).

**Conclusions.** With isolated Bowman layer transplantation, reduction and stabilization of corneal ectasia was achieved in eyes with progressive, advanced keratoconus. Given the low risk for complications, the procedure may be performed to postpone penetrating or deep anterior lamellar keratoplasty.

**Keywords:** Keratoconus, corneal crosslinking, deep anterior lamellar keratoplasty, progressive ectasia, Bowman layer, pachymetry, corneal transplantation, surgical technique



## INTRODUCTION

Keratoconus is described as a bilateral, non-inflammatory progressive disorder characterized by protrusion and thinning of the cornea, causing a compromised optical performance.<sup>1,2</sup> To obtain a better optical performance in mild to moderate keratoconus stages, hard contact lens fitting as well as implantation of intracorneal ring segments (ICRS) may be valuable options.<sup>2</sup> In cases of advanced keratoconus - if contact lens intolerance is present or no acceptable vision can be obtained with contact lenses - deep anterior lamellar keratoplasty (DALK) and penetrating keratoplasty (PK) are common procedures.<sup>2</sup> However, none of these treatment options stop the progression of keratoconus.

Over the past decade, corneal UV-crosslinking has been introduced to strengthen the stromal collagenous corneal matrix, in order to delay or avoid further keratoconus progression.<sup>3</sup> As a result, corneal transplantation may be postponed or no longer be required. UV-crosslinking is currently indicated for use in keratoconic corneas of at least 400 microns in thickness after removal of the epithelium, and in which the preoperative maximum keratometry (Kmax) value does not exceed 58 Diopters (D).<sup>4</sup> Although techniques are being developed to treat thinner and steeper corneas,<sup>5-7</sup> it may be less suitable for more advanced keratoconus. Nevertheless, advanced keratoconus patients may still profit from stabilizing the cornea and halting the progression in order to preserve the visual acuity, while postponing or even preventing DALK or PK and thereby avoiding the inherent complications of these procedures.<sup>8-14</sup>

We recently developed a technique to strengthen and flatten the cornea in cases of advanced keratoconus by means of mid-stromal transplantation of an isolated Bowman layer graft.<sup>15</sup> Long term stabilization of ectasia may be obtained by the Bowman layer itself, as well as through the wound healing effect between the host stroma and the Bowman layer graft.<sup>16,17</sup>

In the current study, we evaluated the clinical outcome of Bowman layer transplantation in a first series of 22 eyes with advanced keratoconus,<sup>18</sup> to enable continued contact lens wear, while avoiding many of the short and long term complications of PK or DALK.

## METHODS

Mid-stromal dissection with transplantation of an isolated donor Bowman layer in a stromal pocket was performed in 22 eyes of 19 patients (10 male and 9 female; 17 to 72 years of age) with progressive keratoconus stage III-IV.<sup>18</sup> Demographics and case characteristics are presented in Table 1. All eyes had a Kmax of more than 67.5D and a best spectacle-corrected visual acuity (BSCVA) of worse than 20/60 (<0.3) (Table 2 and Table 3). All included eyes had documented evidence of keratoconus progression (defined

as  $\geq 1D$  change in simulated keratometry (simK) values and/or  $\geq 2D$  change in Kmax), and a history of subjective decline in visual acuity. Given the corneal steepness and/or thickness, none of the eyes was considered eligible for UV-crosslinking or ICRS.<sup>19-21</sup>

All patients signed an institutional review board-approved informed consent; the study was conducted according to the Declaration of Helsinki and was registered at www.clinicaltrials.gov (study identifier NCT01686906).

**Table 1.** Demographics and keratoconus characteristics

Case #*	Age/ Gender	OD/OS	KC grade**	Preoperative distance corneal apex to Kmax (mm)	Remarks
1	37F	OS	III - IV	0.16	Pre-existing central corneal scarring
2	23F	OS	III	0.24	Alopecia areata, atopy
3	71F	OS	III - IV	0.17	Pre-existing central corneal scarring, cataract
4	17F	OD	III - IV	0.85	
5	18M	OD	IV	0.40	Pre-existing central corneal scarring, atopy
6	27M	OD	III	0.17	Pre-existing central corneal scarring, atopy
7	29F	OD	IV	0.48	Atopy
8	20F	OS	IV	0.43	
9	30M	OD	III - IV	0.21	Pre-existing central corneal scarring
10	29F	OS	IV	0.34	Pre-existing central corneal scarring, atopy, Crosslinking 2009
11	26M	OD	III	1.42	Pre-existing central corneal scarring
12	32M	OS	IV	0.15	Pre-existing central corneal scarring, atopy
13	45F	OS	III	0.90	Pre-existing central corneal scarring
14	35F	OS	III - IV	1.29	Pre-existing central corneal scarring
15	40M	OD	III - IV	2.37	Pre-existing central corneal scarring
16	43M	OS	III - IV	0.61	Intra-operative perforation
17	20M	OS	III - IV	0.30	
18	26M	OS	III - IV	0.38	
19	39F	OS	III - IV	1.31	PRK 2001, Crosslinking 2008
20	28M	OS	III	1.58	Pre-existing central corneal scarring
21	35M	OS	III - IV	0.31	Intra-operative perforation
22	18F	OS	III - IV	0.42	

F = female; M = male; KC = keratoconus; Kmax = maximum keratometry; PRK = photorefractive keratectomy.

\*Three patients had bilateral surgery: cases 4 and 22, cases 6 and 20, and cases 7 and 9.

\*\*Keratoconus grading according to Pentacam Topographic Keratoconus Classification.<sup>18</sup>

Table 2. Preoperative and postoperative corneal curvature data

Case #	FU time (months)	Anterior mean K-values (D)						K max (D)						Posterior mean K-values (D)									
		Pre-op	1m	6m	Latest FU	$\Delta$ Pre-op to latest FU	Pre-op	1m	6m	Latest FU	$\Delta$ Pre-op to latest FU	Pre-op	1m	6m	Latest FU	$\Delta$ Pre-op to latest FU	Pre-op	1m	6m	Latest FU	$\Delta$ Pre-op to latest FU		
1	36	62.8	59.4	59.4	57.1	-5.7	73.2	66.2	67.5	67.0	-6.2	-11.2	-8.3	-8.6	-10.1	1.1							
2	36	64.0	61.5	60.9*	59.3	-4.7	72.7	67.9	69.1*	70.3	-2.4	-9.5	-9.1	-8.9*	-8.3	1.2							
3	24	61.7	n.a.	60.2	60.5	-1.2	70.3	n.a.	70.2	70.5	0.2	-9.9	n.a.	-9.9	-9.8	0.1							
4	24	62.8	60.4	60.1	59.7	-3.1	77.8	77.9	73.8	72.0	-5.8	-9.6	-9.5	-9.7	-9.2	0.4							
5	18	75.4	66.0	69.1	69.5	-5.9	84.7	71.2	73.7	73.8	-10.9	-11.4	-9.6	-10.2	-10.1	1.3							
6	24	67.0	60.5	60.8	57.5	-9.5	76.2	65.3	66.9	67.9	-8.3	-11.1	-9.0	-9.8	-9.9	1.2							
7	24	61.9	57.1	56.6	59.3	-2.6	80.1	68.3	68.3	69.0	-11.1	-9.2	-8.8	-8.9	-9.5	-0.3							
8	24	74.1	61.1	64.6	69.6	-4.5	92.0	72.3	78.3	77.1	-14.9	-10.9	-8.9	-9.7	-10.5	0.4							
9	24	69.3	60.1	64.2	70.9	1.6	85.3	68.6	73.1	82.5	-2.8	-10.3	-9.6	-9.9	-11.2	-1.1							
10	24	59.6	49.0	55.8	56.1	-3.5	79.8	71.4	67.6	70.4	-9.4	-9.3	-8.4	-8.5	-8.1	1.2							
11	18	63.4	56.9	60.0	62.5	-0.9	78.0	69.0	66.1	69.1	-8.9	-10.2	-7.8	-8.9	-9.0	1.2							
12	18	67.5	62.7	61.7	63.5	-4.0	84.0	71.2	69.1	72.5	-11.5	-10.5	-9.2	-10.2	-10.3	0.2							
13	18	55.4	53.0	53.2	53.0	-2.4	69.5	65.9	63.0	57.9	-11.6	-8.8	-8.5	-8.4	-8.2	0.6							
14	18	63.7	63.9	62.3	62.9	-0.8	73.7	63.9	77.3	72.9	-0.8	-9.3	-9.5	-9.7	-10.3	-1.0							
15	18	62.8	58.3	60.7	62.1	-0.7	71.6	72.4	72.8	74.3	2.7	-10.6	-9.4	-9.8	-9.9	0.7							
16	12	[64.1]	n.r.	n.r.	n.r.		[79.1]	n.r.	n.r.	n.r.		[-11.9]	n.r.	n.r.	n.r.								
17	12	74.8	62.0	65.9	68.3	-6.5	83.6	72.3	70.4	75.9	-7.7	-12.3	-10.4	-11.3	-11.1	1.2							
18	18	59.2	57.9	55.5	59.9	0.7	70.7	71.3	65.7	73.2	2.5	-9.8	-10.2	-9.2	-9.7	0.1							
19	12	55.7	54.0	56.2	55.0	-0.7	72.4	67.4	69.0	68.4	-4.0	-9.0	-8.0	-9.0	-9.1	-0.1							
20	12	61.4	60.9	60.3	60.3	-1.1	76.3	70.0	78.8	73.7	-2.6	-9.0	-7.6	-7.6	-8.1	0.9							
21	12	[87.0]	n.r.	n.r.	n.r.		[108.4]	n.r.	n.r.	n.r.		[-13.1]	n.r.	n.r.	n.r.								
22	12	57.5	53.5	55.9	55.6	-1.9	71.8	62.2	65.1	65.4	-6.4	-9.1	-8.3	-8.5	-8.5	0.6							

**Table 2.** Preoperative and postoperative corneal curvature data (continued)

Case #	FU time (months)	Anterior mean K-values (D)					K max (D)					Posterior mean K-values (D)				
		Pre-op	1m	6m	Latest FU	$\Delta$ Pre-op to latest FU	Pre-op	1m	6m	Latest FU	$\Delta$ Pre-op to latest FU	Pre-op	1m	6m	Latest FU	$\Delta$ Pre-op to latest FU
Average	20	64.0	58.9	60.2	61.1	-2.9	77.2	69.2	70.3	71.2	-6.0	-10.1	-9.0	-9.3	-9.5	0.5
SD	7	5.8	4.2	3.9	5.1	2.7	6.2	3.7	4.5	5.0	5.0	1.0	0.8	0.8	1.0	0.7
P-value (pre-op to FU)**			<b>.000</b>	<b>.000</b>	<b>.000</b>			<b>.000</b>	<b>.000</b>	<b>.000</b>			<b>.000</b>	<b>.000</b>	<b>.000</b>	
P-value (1m to FU)**				<b>.028</b>	<b>.018</b>				.323	.072				<b>.008</b>	<b>.004</b>	
P-value (6m to FU)**					.098					.298					.107	

FU = follow-up; Kmax = maximum keratometry; m = month; n.a. = not available; n.r. = not relevant; pre-op = preoperative; SD = standard deviation 'Bold' indicates significant change; \*4 months follow-up; \*\*paired T-test

## Donor tissue

The procedure for harvesting a Bowman layer graft has been previously described.<sup>15,22</sup> The tissue used for Bowman layer graft creation came from two sources: whole globes (obtained less than 24 hours post-mortem, but with corneas deemed not suitable for either PK or endothelial keratoplasty), or from the anterior lamellae left behind from prior Descemet membrane endothelial keratoplasty (DMEK) graft preparation. Donor globes were mounted on a globe holder (DORC International, Zuidland, The Netherlands) and anterior corneal buttons were mounted on an artificial anterior chamber (Gebauer Medizintechnik, Neuhausen, Germany or Katena, Rockmed, Oirschot, The Netherlands). The epithelium was carefully removed using surgical spears. Over 360 degrees a superficial incision was made using a 30-gauge needle just within the limbal corneal periphery.

With a McPherson forceps and a custom-made stripper (DORC International), an isolated Bowman layer was carefully dissected from the anterior stroma, over 360 degrees from the periphery toward corneal center, so that a 9.0 to 11.0 mm diameter Bowman-flap was obtained. Due to the elastic properties of Bowman layer, a 'Bowman-roll' formed spontaneously. The Bowman-roll was then submerged in ethanol 70% to remove remnant epithelial cells, and stored in organ culture medium (CorneaMax, Eurobio, Courtaboeuf, France) at 31°C, until the time of transplantation.

## Surgical technique

All eyes were operated under local anesthesia (4 ml 1% ropivacain hydrochloride with 150IE Hyason), followed by ocular massage and a Honan's balloon for 10 minutes, and the patient was positioned in the anti-Trendelenburg position.<sup>15</sup>

A mid-stromal pocket up to the limbus over 360 degrees was created under air, using the manual dissection technique previously described to create a lamellar dissection plane in DALK,<sup>23,24</sup> in which, in contrast to the dissection plane in DALK, the depth of the dissection aimed for mid-stromally.<sup>15</sup> Into the created pocket, a glide (BD Visitec™ Surgical Glide (Fichman), Beaver-Visitec International, Waltham, USA) was inserted and the air was removed from the anterior chamber. The Bowman-roll was again immersed in 70% ethanol for 30 seconds to remove all remnant cellular material, thoroughly rinsed with balanced salt solution (BSS; B&L, Rochester, USA), and stained with trypan blue (VisionBlue™, DORC International). Then, the Bowman-roll was placed atop the glide, and carefully inserted into the stromal pocket, unfolded and centered, using a cannula and BSS to manipulate the tissue. The eye was then pressurized obtaining normal intraocular pressure by filling the anterior chamber with BSS. Postoperative medication included chloramphenicol 0.5% six times daily and dexamethasone 0.1% four times daily.

All surgical procedures were recorded on DVD (Pioneer DVR-RT601H-S, Tokyo, Japan). Before surgery, and at standardized time intervals at one day, one week, and at one, three, six, twelve, 18, 24 and 36 months after surgery, best corrected visual acuity was

measured, and subjective refraction, slit-lamp biomicroscopy, and Scheimpflug-based corneal tomography (Pentacam HR, Oculus, Wetzlar, Germany) were recorded. Up to six months postoperatively, also anterior segment optical coherence tomography (AS-OCT; Slit-lamp OCT, Heidelberg Engineering GmbH, Heidelberg, Germany) was performed. The endothelium was photographed and evaluated *in vivo* using a Topcon SP3000p non-contact autofocus specular microscope (Topcon Medical Europe, Capelle a/d IJssel, The Netherlands). Central images were analyzed and manually corrected and multiple measurements of endothelial cell density were averaged. If the central endothelium could not be visualized due to central corneal scarring, paracentral images were analyzed.

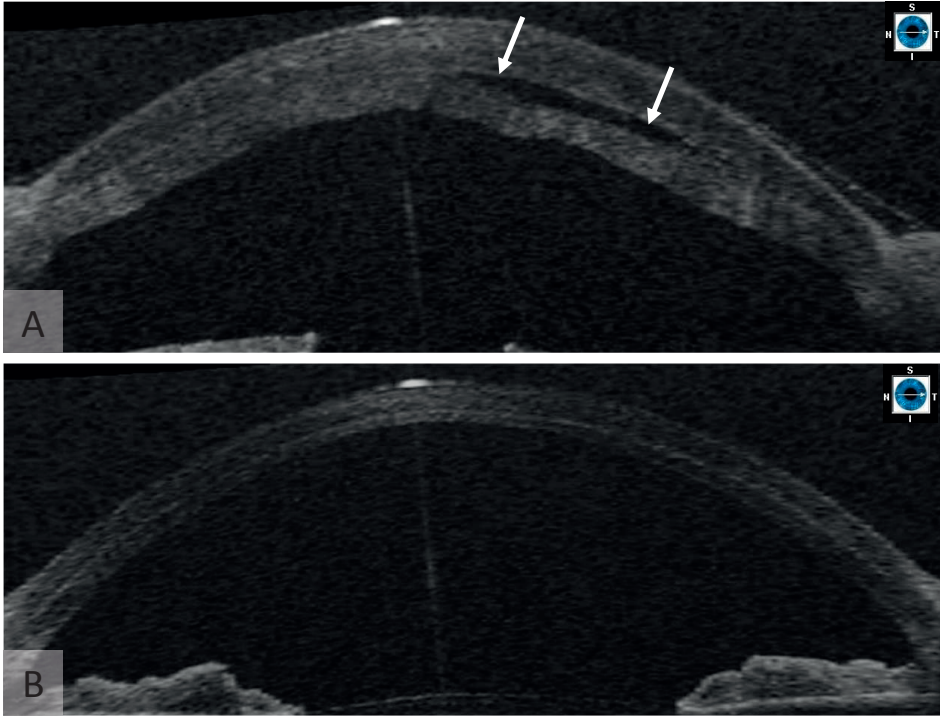
Statistical analysis was performed with SPSS 13 for Windows (SPSS Inc., Chicago, IL). Visual acuity was measured with a Snellen chart, using a forced choice test with a 100% contrast Snellen projection letter chart at 6 meters under mesopic lighting conditions; values were converted to logarithm of the minimum angle of resolution units (LogMAR) for statistical analysis. Normality was initially verified by measuring the standard error of kurtosis and the standard error of skewness for each group of measurements. When the standard error of both measures was between -2 and +2, the distribution was considered normal. In addition, we applied the Kolmogorov-Smirnov statistic, with a Lilliefors significance level for testing normality. All distributions were found to be normal, after which paired t-tests were used to compare Scheimpflug-based and visual acuity data between time-points. Pearson correlations were used to determine the relationship between preoperative and postoperative refractive outcome. Regression analysis was performed in order to evaluate the potential impact of preoperative corneal characteristics on the anatomical effect of the surgery. Statistical significance was determined as  $P \leq 0.05$ .

## RESULTS

Of the 22 Bowman layer transplantations, 20 were uneventful. In two cases an intraoperative perforation of Descemet membrane during manual dissection occurred (Cases 16 and 21; Table 1). Although PK was offered, both patients chose to await corneal clearance after re-endothelialization of the perforation site. The cornea of Case 21 cleared slowly and BSCVA improved during the first postoperative 6 months. However, after initial clearance, Case 16 showed progressive corneal decompensation, for which PK has been scheduled. These two eyes were excluded from postoperative evaluation for this study; hence a total of 20 eyes were analysed further.

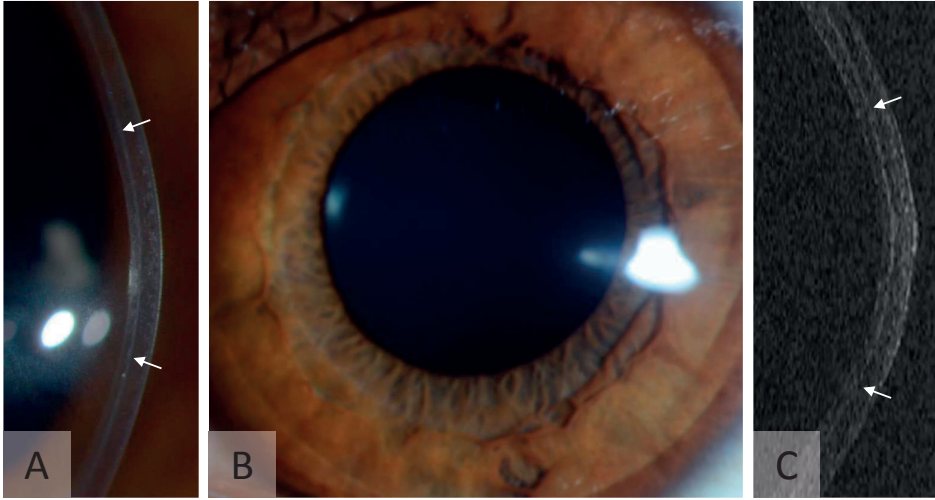
Throughout the study period no other intra- or postoperative complications related to stromal dissection and/or isolated Bowman layer transplantation were observed. Because the donor Bowman layer was intentionally stretched toward the corneal limbus, an

intrastromal cavity was seen in some eyes at the first postoperative days (Figure 1).<sup>15</sup> At later time intervals, the implant could be visualized with biomicroscopy and AS-OCT as a thin line within the recipient corneal stroma, in all transplanted corneas (Figure 1 and 2).



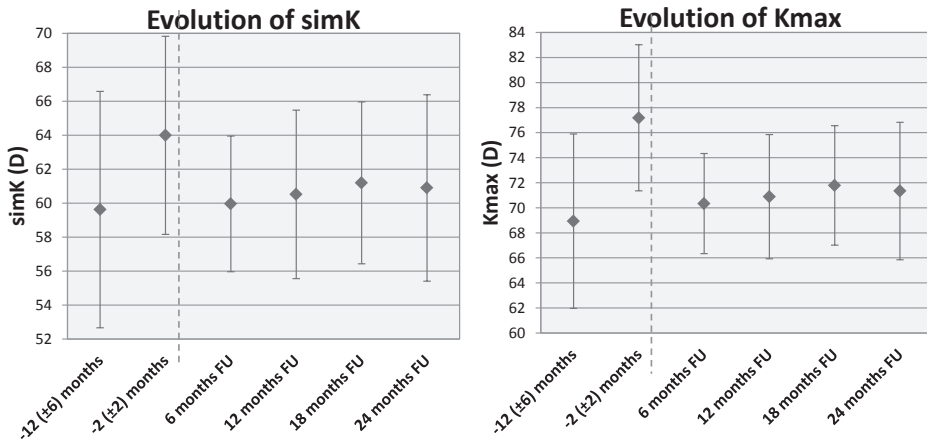
**Figure 1.** Optical coherence tomography images of a cornea (case 22) (A) immediately after Bowman layer transplantation and (B) 1 day after surgery. A, Note the intrastromal cavity (white arrows) immediately after surgery. B, These disappeared within the first postoperative day.

The 20 eyes studied (Table 1) had a mean follow up of 20 ( $\pm 7$ ) months (range 12 to 36 months) (Table 2). Compared to preoperative measurements, a “flattening” effect (flattened corneal curvature) was observed in 18 out of 20 (90%) eyes (Figure 3). On average, anterior simK decreased from 64.0 ( $\pm 5.8$ ) D before surgery, to 58.9 ( $\pm 4.2$ ) D at one month ( $P < .001$ ); Kmax decreased from 77.2 ( $\pm 6.2$ ) D to 69.2 ( $\pm 3.7$ ) D ( $P < .001$ ); and posterior mean K decreased from -10.1 ( $\pm 1.0$ ) D to -9.0 ( $\pm 0.8$ ) D ( $P < .001$ ) (Figure 4; Table 2). After the first postoperative month, Kmax remained stable during further follow-up ( $P \geq .072$ ) (Table 2). The simK- and posterior K-values showed a small regression from one to six months postoperatively ( $P \leq .028$ ), before stabilizing thereafter ( $P \geq .098$ ) (Figure 3 and Figure 4; Table 2). In two eyes (Cases 15 and 18; Table 2), the corneal curvature showed continued steepening despite the Bowman layer inlay. No specific reason could be found for this progression, except for the fact that Case 15 had a very eccentric cone (Table 1).



**Figure 2.** Slit-lamp images and optical coherence tomography (OCT) image after Bowman layer transplantation. The (A, B) slit-lamp images and (C) OCT image were obtained 6 months after Bowman layer transplantation (case 22). The Bowman layer transplant (white arrows) is visible as a thin white line within the recipient stroma (A and C), whereas the cornea is clear and without any interface haze or stromal reaction (B).

At the latest follow-up, mean central corneal thickness (CCT) and thinnest point thickness (TPT) both showed an increase in thickness ( $P=.008$  and  $P=.012$ , respectively) (Table 4). However, three corneas (Cases 5, 8 and 22) were found to be thinner after surgery (Table 4).



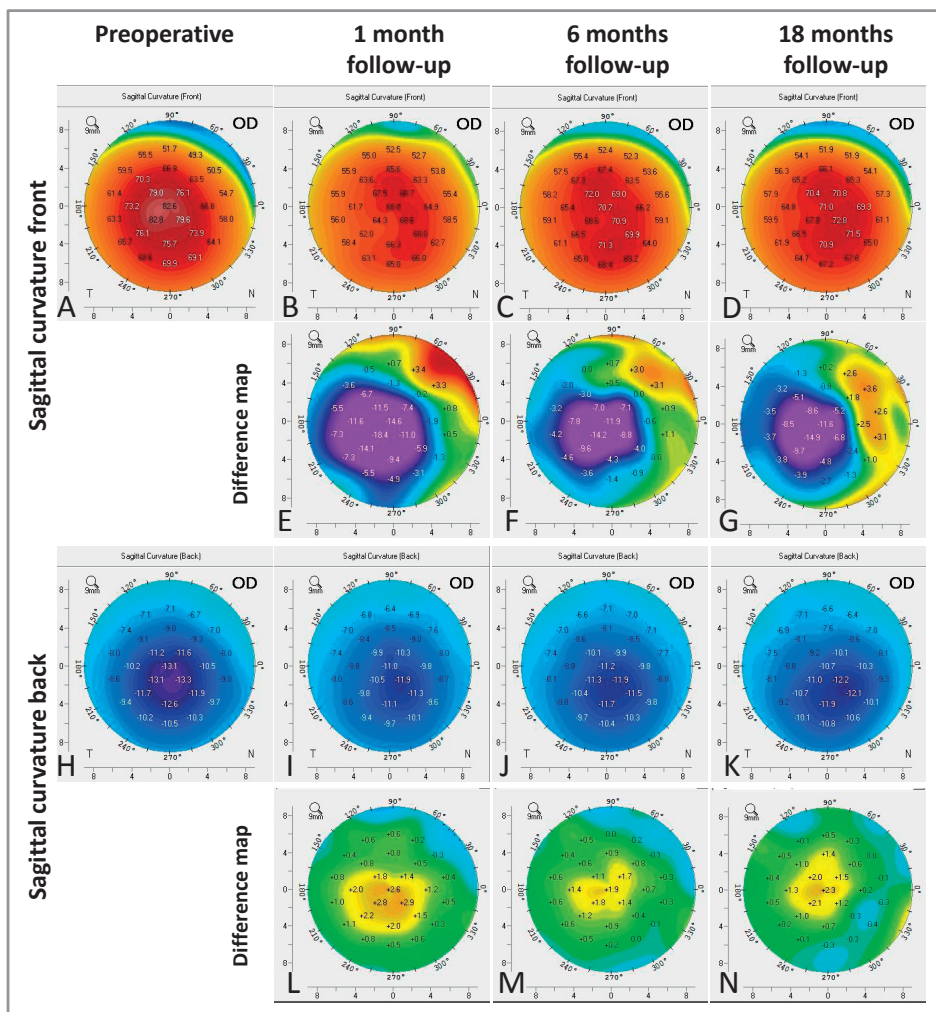
**Figure 3.** Graphs showing the evolution in mean simulated keratometry (simK) and maximum keratometry (Kmax) values. The mean simK and Kmax values are displayed. The dashed line indicates the approximate time point of Bowman layer transplantation. Note the preoperative progression, postoperative flattening, and stabilization thereafter. D = diopters; FU = follow-up



Table 3. Preoperative and postoperative best-corrected visual acuity

Case #	FU time (months)	BSCVA Snellen (decimal)				BCLVA Snellen (decimal)			
		Pre-op	6m	12m	Latest FU	Pre-op	6m	12m	Latest FU
1	36	20/100 (0.20)	20/200 (0.10)	20/100 (0.20)	20/100 (0.20)	20/50 (0.40)	20/100 (0.20)	20/70 (0.30)	20/50 (0.40)
2	36	CF	CF	20/200 (0.10)	<b>20/80 (0.25)</b>	20/30 (0.70)	20/30 (0.70)	20/40 (0.50)	<b>20/40 (0.50)</b>
3	24	CF	CF	20/200 (0.10)	20/400 (0.05)	n.a.	20/100 (0.20)	20/100 (0.20)	20/70 (0.30)
4	24	20/200 (0.10)	20/200 (0.10)	20/70 (0.30)	<b>20/40 (0.50)</b>	20/40 (0.50)	20/30 (0.70)	20/40 (0.50)	20/35 (0.60)
5	18	CF	20/200 (0.10)	20/200 (0.10)	CF	20/50 (0.40)	20/35 (0.60)	20/40 (0.50)	20/40 (0.50)
6	24	n.a.	20/125 (0.15)	20/100 (0.20)	20/125 (0.15)	20/50 (0.40)	20/50 (0.40)	20/40 (0.50)	<b>20/35 (0.60)</b>
7	24	20/125 (0.15)	20/70 (0.30)	20/70 (0.30)	20/125 (0.15)	20/20 (1.00)	20/40 (0.50)	20/25 (0.80)	<b>20/35 (0.60)</b>
8	24	CF	20/100 (0.20)	20/100 (0.20)	<b>20/100 (0.20)</b>	20/100 (0.20)	20/50 (0.40)	20/70 (0.30)	<b>20/40 (0.50)</b>
9	24	CF	CF	20/200 (0.10)	20/400 (0.05)	20/50 (0.40)	20/50 (0.40)	20/70 (0.30)	20/50 (0.40)
10	24	CF	20/200 (0.10)	20/100 (0.20)	<b>20/125 (0.15)</b>	20/25 (0.80)	20/30 (0.70)	20/35 (0.60)	<b>20/40 (0.50)</b>
11	18	CF	20/400 (0.05)	20/200 (0.10)	20/400 (0.05)	20/40 (0.50)	20/50 (0.40)	20/40 (0.50)	20/50 (0.40)
12	18	CF	CF	20/200 (0.10)	20/400 (0.05)	20/40 (0.50)	20/50 (0.40)	20/40 (0.50)	20/40 (0.50)
13	18	20/100 (0.20)	20/400 (0.05)	20/70 (0.30)	20/125 (0.15)	20/25 (0.80)	20/50 (0.40)	20/50 (0.40)	<b>20/40 (0.50)</b>
14	18	CF	CF	20/200 (0.10)	20/400 (0.05)	20/50 (0.40)	20/50 (0.40)	20/50 (0.40)	20/50 (0.40)
15	18	CF	20/400 (0.05)	20/200 (0.10)	20/400 (0.05)	20/70 (0.30)	20/70 (0.30)	20/70 (0.30)	20/70 (0.30)
16	12	[CF]	[CF]	[CF]	[CF]	[20/400 (0.05)]	n.a.	n.a.	n.a.
17	12	20/400 (0.05)	20/200 (0.10)	20/100 (0.20)	<b>20/125 (0.15)</b>	20/100 (0.20)	20/70 (0.30)	20/125 (0.15)	20/100 (0.20)
18	18	20/400 (0.05)	20/200 (0.10)	20/100 (0.20)	<b>20/80 (0.25)</b>	n.a.	20/40 (0.50)	20/30 (0.70)	20/30 (0.70)
19	12	20/80 (0.25)	20/200 (0.10)	20/70 (0.30)	20/80 (0.25)	20/50 (0.40)	20/50 (0.40)	20/50 (0.40)	20/40 (0.50)
20	12	20/200 (0.10)	20/125 (0.15)	20/100 (0.20)	20/125 (0.15)	20/35 (0.60)	20/40 (0.50)	20/40 (0.50)	20/40 (0.50)
21	12	[20/400 (0.05)]	[20/50 (0.40)]	[20/50 (0.40)]	<b>[20/50 (0.40)]</b>	n.a.	n.a.	n.a.	n.a.
22	12	20/200 (0.10)	20/70 (0.30)	20/100 (0.20)	<b>20/100 (0.20)</b>	20/30 (0.70)	20/30 (0.70)	20/30 (0.70)	20/30 (0.70)

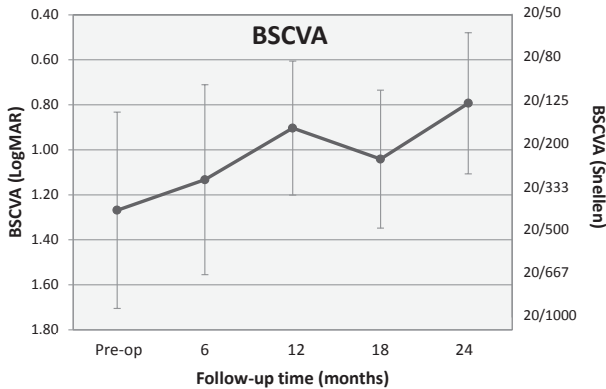
BCLVA = Best contact lens corrected visual acuity; BSCVA = Best spectacle-corrected visual acuity; CF = Counting fingers ; FU = Follow-up; m = months; n.a. = not available; Pre-op = preoperative; "Bold" indicates  $\geq 2$  lines change compared to preoperative.



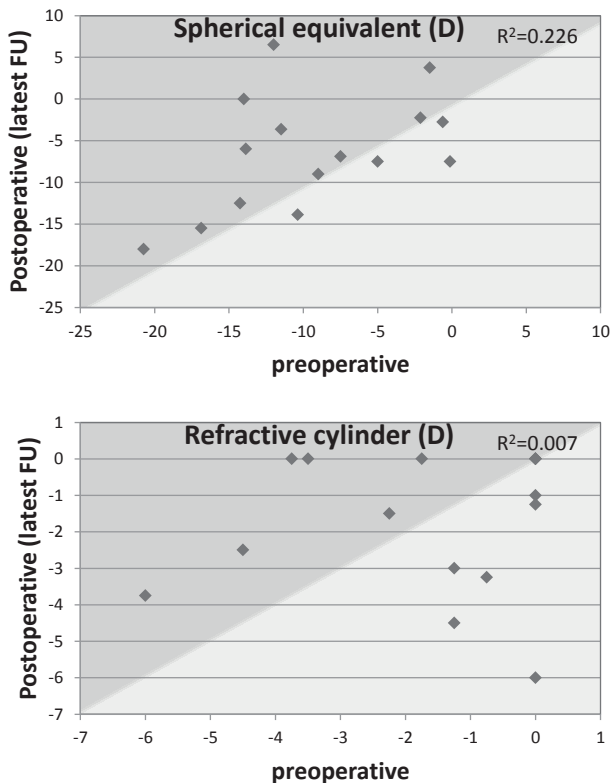
**Figure 4.** Topography maps of a cornea before and after Bowman layer transplantation. Topography maps of a cornea (case 5) before and at 1, 6, and 18 months after Bowman layer transplantation (A - D, H - K), as well as maps showing the difference from before surgery to the follow-up points (E - G, L - N) are shown. Note that the (A, B, E) anterior and (H, I, L) posterior curvature show corneal flattening from baseline to 1 month after surgery. From 1 to 6 months after surgery, a small regression in anterior (B, C, F) and posterior (I, J, M) curvature is seen, after which stabilization is seen (C, D, G, J, K, N). OD = right eye.

Since one eye had low visual potential due to cataract (Case 3), and in another eye, the preoperative visual acuity was measured only with a contact lens (Case 6), the overall visual outcome could be evaluated in 18 eyes. Furthermore, pre-existing central corneal scarring affecting the visual axis was present in twelve corneas (Table 1). Mean LogMAR BSCVA changed from 1.27 ( $\pm 0.44$ ) preoperatively, to 0.90 ( $\pm 0.30$ ) at twelve months after Bowman layer transplantation ( $P < .001$ ) (Figure 5, Table 3). No change in BSCVA was

observed after the first twelve months ( $P=.357$ ) (Figure 5, Table 3). At the last follow-up, compared to preoperatively, BSCVA improved by 2 Snellen lines or more in seven eyes (Cases 2, 4, 8, 10, 17, 18 and 22), improved by one line in six eyes (Cases 9, 11, 12, 14, 15 and 20), remained stable in four eyes (Cases 1, 5, 7 and 19) and declined by one line in one eye (Case 13) (Table 3).



**Figure 5.** Graph displaying the evolution in average best spectacle-corrected visual acuity (BSCVA). The graph shows a progressive improvement in BSCVA over the first postoperative year ( $P<.001$  at 12 months).



**Figure 6.** Scatterplots displaying the effect of isolated Bowman layer transplantation on the spherical equivalent and refractive cylinder. The preoperative-to-postoperative effect of isolated Bowman layer transplantation for advanced keratoconus on (A) spherical equivalent and (B) refractive cylinder is shown. Note the tendency toward (A) a hyperopic shift, whereas (B) the refractive cylinder does not show any change. D = diopter; FU = follow-up.

**Table 4.** Preoperative and postoperative pachymetry data

Case #	FU time (months)	Central corneal thickness (µm)				Thinnest point thickness (µm)			
		Pre-op	1 m FU	6 m FU	Latest FU	Pre-op	1 m FU	6 m FU	Latest FU
1	36	303	455	473	442	247	350	379	371
2	36	398	440	458	492	262	393	325	355
3	24	368	n.a.	378	416	342	n.a.	355	390
4	24	426	401	407	424	365	348	367	369
5	18	382	366	387	388	328	309	311	286
6	24	418	468	435	444	401	453	396	400
7	24	462	463	457	462	420	439	408	423
8	24	396	363	365	367	322	338	335	291
9	24	421	417	406	444	384	393	378	382
10	24	385	384	407	458	265	331	346	383
11	18	308	332	335	312	252	264	262	269
12	18	505	584	485	521	396	480	386	444
13	18	400	363	392	405	360	352	377	382
14	18	490	483	501	521	337	384	367	377
15	18	300	362	330	313	236	315	295	259
16	12	381	n.r.	n.r.	n.r.	202	n.r.	n.r.	n.r.
17	12	334	303	292	385	282	268	261	350
18	18	425	400	390	442	404	380	348	409
19	12	405	415	408	393	330	348	366	337
20	12	379	469	409	494	305	379	336	345
21	12	324	n.r.	n.r.	n.r.	253	n.r.	n.r.	n.r.
22	12	442	417	424	420	399	369	374	379
Average	20	397	415	407	427	332	363	349	360
SD	7	57	64	53	58	59	56	41	50
P-value (pre-op to FU)*			.186	.359	<b>.008</b>		<b>.010</b>	.095	<b>.012</b>
P-value (1m to FU)*					.170				.619

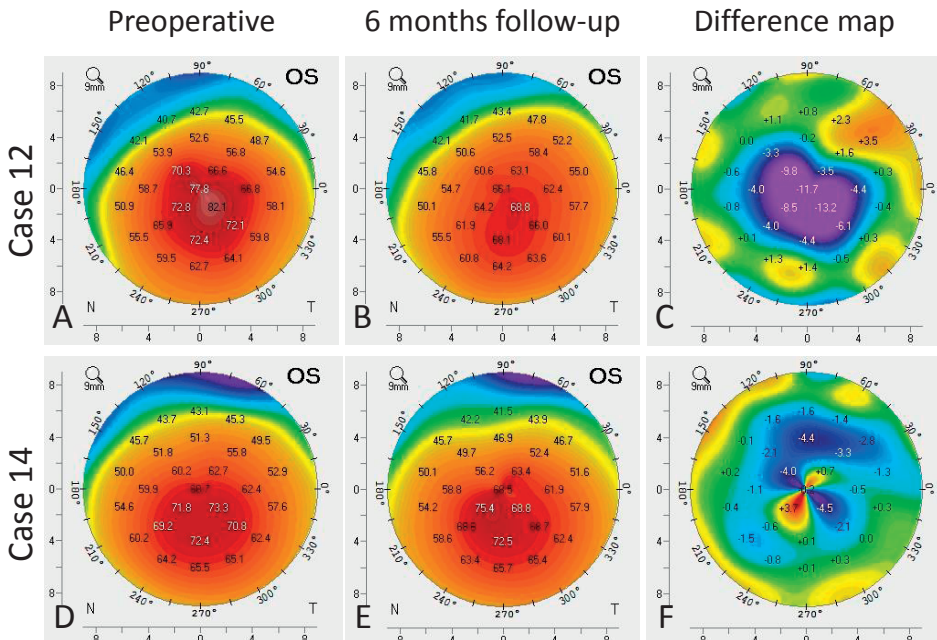
FU = Follow-up; m = months; n.a = not available; n.r. = not relevant; Pre-op = preoperative SD = standard deviation; \*Paired T-test

Average best contact lens corrected visual acuity (BCLVA) showed no change from pre- to postoperative at any time point ( $P>.1$ ). At the latest follow-up, 13/20 eyes (68%) had a BCLVA of 20/40 or better ( $\geq 0.5$ ). Lower BCLVA could commonly be attributed to pre-existing corneal scarring (Table 1 and Table 3). BCLVA declined two or more Snellen lines in four eyes (Cases 2, 7, 10, 13). However, except for Case 13, instead of deterioration, the other three cases subjectively experienced an improvement in vision in daily life.

Mean spherical equivalent (SE) showed a tendency towards a hyperopic shift from -9.30 ( $\pm 6.3$ ) D preoperatively to -5.68 ( $\pm 6.3$ ) D at the latest follow-up ( $P=.059$ ), and preop-

erative SE showed a borderline correlation with the postoperative SE ( $r=0.475$ ,  $r^2=0.226$ ,  $P=.074$ ) (Figure 6). Regarding the refractive cylinder, no change ( $P=.791$ ) or correlation concerning the absolute value ( $r=0.084$ ,  $r^2=0.007$ ,  $P=.771$ ) was found (Figure 6). Mean endothelial cell density did not change from preoperative ( $2600 (\pm 452)$  cells/mm<sup>2</sup>) to twelve months postoperative ( $2475 (\pm 448)$  cells/mm<sup>2</sup>) ( $P=.175$ ), or thereafter ( $P=.355$ ).

The predictive value of preoperative corneal curvature and pachymetry indices regarding the “flattening” effect of the surgery (postoperative decrease in Kmax values) was evaluated with regression analysis. A combination of baseline Kmax, simK, “corneal apex to Kmax distance”, CCT and TPT could predict the anatomical “flattening” effect of the surgery ( $P=.019$ ). The analysis showed that preoperative Kmax, simK and “apex to Kmax distance” (eccentricity of the keratoconus cone), had the largest impact on the postoperative flattening effect ( $\beta=0.945$ ,  $P=.006$ ;  $\beta=-0.809$ ,  $P=.017$  and  $\beta=-0.422$ ,  $P=.05$ , respectively). Thus, a steeper Kmax, combined with a “flatter” simK and a shorter “corneal apex to Kmax distance” (describing a steep “nipple-shaped” cone) resulted in larger flattening ( $P=.003$ ) (Figure 7). Preoperative pachymetry indices (CCT and TPT) were not correlated with the flattening effect of the surgery ( $P=.906$  and  $P=.668$ , respectively).



**Figure 7.** Topography and related difference maps of 2 corneas (cases 12 and 14) (A, D) before and (B, E) 6 months after Bowman layer transplantation. After Bowman layer transplantation, substantial flattening was seen (A - C) in case 12, in which the cornea initially had (A) a very steep, central cone. By contrast, Bowman layer transplantation resulted in only mild corneal flattening in (D - F) case 14, which initially had (D) a more eccentric cone. OS = left eye.

## DISCUSSION

In this study, the clinical outcome of isolated Bowman layer transplantation to reduce and stabilize ectasia in advanced keratoconus eyes with a Kmax of more than 67.5D was evaluated. An initial overall flattening effect of about 8D was found as well as stabilization of the corneal curvature.

Until the late 1990s, progressive keratoconus was managed with contact lens fitting and adjustment for as long as a lens was tolerated by the eye and an acceptable visual acuity was achieved before either a PK or DALK was performed. Today, with the introduction of UV-crosslinking, long term stabilization of a keratoconic cornea may be obtained, so that corneal transplantation may be postponed or no longer be required.<sup>2-4</sup> Originally not recommended in corneas with a CCT less than 400 $\mu$ m after removal of the epithelium, recently there has been a development to expand the use of UV-crosslinking into eyes with thinner corneas by means of a variety of modifications to the original procedure, of which the use of hypo-osmolar riboflavin solution is the most common.<sup>4-7</sup> At present however, there have been limited studies on the efficacy and safety of UV-crosslinking in thin corneas, with relatively few including eyes with severe thinning (<350 $\mu$ m).<sup>5,19,25,26</sup> Furthermore, although it has been demonstrated that UV-crosslinking may be safely performed in eyes with a relatively steep keratoconus, the risk of complications or failure seems higher than in less progressed cases.<sup>6,21</sup>

Another possibility to avoid corneal transplantation in keratoconus eyes, may be by reshaping the cornea using ICRS.<sup>27,28</sup> Still, eyes with severe thinning and steepening of the cornea seem currently ineligible for the procedure secondary to the relatively higher rate of complications and poorer visual outcomes.<sup>20</sup> Nevertheless, patients not eligible for either UV-crosslinking or ICRS,<sup>19-21</sup> but with still satisfactory vision, similarly would benefit from stabilizing the cone and flattening the cornea, to enable continued contact lens wear, while avoiding or postponing a PK or DALK. This may be an important advantage since the long term outcome of corneal transplantation may frequently be complicated by a cascade of complications.<sup>8,11-14,29-31</sup> Furthermore, although textbooks characterize keratoconus as a 'non-inflammatory disorder',<sup>1</sup> clinical observation suggests that eyes with advanced keratoconus may be prone to 'inflammatory' ocular surface reactions, presumably owing to atopic constitution,<sup>2,32-35</sup> rendering PK or DALK as 'high-risk' procedures.

Since keratoconic corneas show invariably fragmentation of Bowman layer,<sup>36</sup> we hypothesized that a surgical approach in which the potential functionality of Bowman layer in stabilizing the cornea could be restored while avoiding the risk factors related to PK and DALK.<sup>15</sup> Although positioning an isolated donor Bowman layer onto a keratoconic cornea (i.e., in its true anatomical position) could be technically feasible, it would be difficult to obtain sufficient traction force across the cornea to flatten the

central cone, because the thin donor Bowman layer can not be fixated with any sutures or glues currently available. Hence, we chose to position the donor Bowman layer inside a stromal pocket, which resulted in significant regression and stabilization of corneal ectasia. The procedure exerted the most effect in corneas with a relatively 'steep Kmax combined with a "flatter" simK', and a 'small corneal apex to Kmax distance' (Figure 7). In other words, more corneal flattening was obtained with progress of disease, i.e., in more advanced cases, and with more central cones. Throughout the study follow-up, 18/20 (90%) showed stabilization, indicating that the procedure may have potential in the management of keratoconus cases ineligible for UV-crosslinking.

To what extent was Bowman layer transplantation effective in managing advanced keratoconus? As with UV-crosslinking, the main objective of the procedure was confined to stabilization and possibly regression of the ectatic corneal curvature, to enable continued contact lens wear, which in turn would give an acceptable visual acuity. The observed improvement in BSCVA may have limited value in daily life, since all patients had much better visual acuity with a contact lens. Therefore, the true value of the procedure may be that in all eyes an acceptable contact lens corrected vision was preserved while stabilizing the cornea at the same time.

Another parameter to assess the efficacy of donor Bowman layer transplantation is the risk of complications in comparison with its alternative procedures, DALK and PK. In UV-crosslinking and refractive surgery, a decrease in BSCVA of 2 or more Snellen lines at six to twelve months after surgery is usually defined as a 'complication'.<sup>21,37</sup> In our study, none of the eyes had a decrease in BSCVA of two or more Snellen lines. The only real complication encountered in this series was the occurrence of an intraoperative micro-perforation of Descemet membrane in two eyes. However, because the same intrastromal dissection technique was used, this complication presumably also would have happened with manual DALK, for which a 8 - 15% micro-perforation rate has been reported,<sup>38,39</sup> but that may be higher in a selective group of advanced keratoconus. Additional considerations may be that donor Bowman layer transplantation should be associated with a negligible risk of allograft rejection (because acellular tissue is transplanted), and that limited visual outcome may result from pre-existing corneal scarring in about half of these advanced keratoconus eyes.

An interesting finding was that four cases showed an objective decrease in BCLVA, whereas three of these patients experienced a subjective improvement. This may indicate that less irregularity of the corneal curvature after donor Bowman layer transplantation gives better optical image quality during daily activities, despite the lower visual acuity. For the remaining eye, a rigid gas permeable contact lens (worn before the surgery), was replaced by a scleral contact lens (after surgery). This change in contact lens type may go with some subjective loss of visual acuity. Overall, however, BCLVA did not change from before to after surgery, indicating that potential candidates for Bowman layer

transplantation should present with a subjectively acceptable BCLVA before surgery. For this group of patients, Bowman layer transplantation could become a supplementary treatment option in the management of advanced keratoconus, to postpone PK or DALK and to minimize the risk of long term complications.



## REFERENCES

1. Rabinowitz YS. Keratoconus. *Surv Ophthalmol* 1998;42:297-319
2. Romero-Jiménez M, Santodomingo-Rubido J, Wolffsohn JS. Keratoconus: a review. *Cont Lens Anterior Eye* 2010;33:157-166
3. Wollensak G, Spoerl E, Seiler T. Riboflavin/ultraviolet-a-induced collagen crosslinking for the treatment of keratoconus. *Am J Ophthalmol* 2003;135:620-627
4. Chan E, Snibson GR. Current status of corneal collagen cross-linking for keratoconus: a review. *Clin Exp Optom* 2013;96:155-164
5. Raiskup F, Spoerl E. Corneal cross-linking with hypo-osmolar riboflavin solution in thin keratoconic corneas. *Am J Ophthalmol* 2011;152:28-32
6. Ivarsen A, Hjortdal J. Collagen cross-linking for advanced progressive keratoconus. *Cornea* 2013;32:903-906
7. Sloot F, Soeters N, van der Valk R, Tahzib NG. Effective corneal collagen crosslinking in advanced cases of progressive keratoconus. *J Cataract Refract Surg* 2013;39:1141-1145
8. Kelly TL, Williams KA, Coster DJ, for the Australian Graft Registry. Corneal transplantation for keratoconus: a registry study. *Arch Ophthalmol* 2011;129:691-697
9. Tan DHT, Dart JKG, Holland EJ, Kinoshita S. Corneal transplantation. *Lancet* 2012;379:1749-1761
10. Niziol LM, Musch DC, Gillespie BW, et al. Long-term outcomes in patients who received a corneal graft for keratoconus between 1980 and 1986. *Am J Ophthalmol* 2013;155:213-219
11. Williams KA, Muehlberg SM, Lewis RF, Coster DJ. How successful is corneal transplantation? A report from the Australian Corneal Graft Register. *Eye* 1995;9:219-227
12. De Toledo JA, de la Paz MF, Barraquer RI, Barraquer J. Long-term progression of astigmatism after penetrating keratoplasty for keratoconus: evidence of late recurrence. *Cornea* 2003;22:317-323
13. Elder MJ, Stack RR. Globe rupture following penetrating keratoplasty. How often, why, and what can we do to prevent it? *Cornea* 2004;23:776-780
14. Nagra PK, Hammersmith KM, Rapuano CJ, et al. Wound dehiscence after penetrating keratoplasty. *Cornea* 2006;25:132-135
15. van Dijk K, Parker J, Tong CM, et al. Mid-stromal isolated Bowman layer graft to reduce advanced keratoconus to postpone penetrating or deep anterior lamellar keratoplasty. *JAMA Ophthalmol* 2014;132:495-501
16. Melles GRJ, Binder PS. A comparison of wound healing in sutured and unsutured corneal wounds. *Arch Ophthalmol* 1990;108:1460-1469
17. Melles GRJ, Binder PS, Anderson JA. Variation in healing throughout the depth of long-term, unsutured, corneal wounds in human autopsy specimens and monkeys. *Arch Ophthalmol* 1994;112:100-109
18. Oculus Pentacam Instruction Manual - Measurement and evaluation system for the anterior segment of the eye. Wetzlar, Germany: Oculus Optikgeräte GmbH; 2005
19. Hafezi F. Limitation of collagen cross-linking with hypoosmolar riboflavin solution: failure in an extremely thin cornea. *Cornea* 2011;30:917-919
20. Health Quality Ontario. Intrastromal corneal ring implants for corneal thinning disorders: an evidence-based analysis. *Ont Health Technol Assess Ser* 2009;9:1-90
21. Koller T, Mrochen M, Seiler T. Complication and failure rates after corneal crosslinking. *J Cataract Refract Surg* 2009;35:1358-1362
22. Lie JT, Droutsas K, Ham L, et al. Isolated Bowman layer transplantation to manage persistent subepithelial haze after excimer laser surface ablation. *J Cataract Refract Surg* 2010;36:1036-1041

23. Melles GRJ, Lander F, Rietveld FJR, et al. A new surgical technique for deep stromal, anterior lamellar keratoplasty. *Br J Ophthalmol* 1999;83:327-333
24. Melles GRJ, Rietveld FJR, Beekhuis WH, Binder PS. A technique to visualize corneal incision and lamellar dissection depth during surgery. *Cornea* 1999;18:80-86
25. Hafezi F, Mrochen M, Iseli HP, Seiler T. Collagen crosslinking with ultraviolet-A and hypotonic riboflavin solution in thin corneas. *J Cataract Refract Surg* 2009;35:621-624
26. Meek KM, Hayes S. Corneal cross-linking--a review. *Ophthalmic Physiol Opt* 2013;33:78-93
27. Piñero DP, Alio JL. Intracorneal ring segments in ectatic corneal disease – A review. *Clin Exp Ophthalmol* 2010;38:154-167
28. Khan MI, Injarie A, Muhtaseb M. Intrastromal corneal ring segments for advanced keratoconus and cases with high keratometric asymmetry. *J Cataract Refract Surg* 2012;38:129-136
29. Watson SL, Ramsay A, Dart JKG, et al. Comparison of deep lamellar keratoplasty and penetrating keratoplasty in patients with keratoconus. *Ophthalmology* 2004;111:1676-1682
30. Jonas JB, Rank RM, Budde WM. Immunologic graft reactions after allogenic penetrating keratoplasty. *Am J Ophthalmol* 2002;133:437-443
31. Kok YO, Tan GFL, Loon SC. Review: Keratoconus in Asia. *Cornea* 2012;31:581-593
32. Yildiz EH, Erdurmus M, Hammersmith KM, et al. Comparative study of graft rejection in keratoconus patients with and without self-reported atopy. *Cornea* 2009;28:846-850
33. Sugar J, Macsai MS. What causes keratoconus? *Cornea* 2012;31:716-719
34. Cheung IMY, McGhee CNJ, Sherwin T. A new perspective on the pathobiology of keratoconus: interplay of stromal wound healing and reactive species-associate processes. *Clin Exp Optom* 2013;96:188-196
35. Lema I, Sobrino T, Durán JA, et al. Subclinical keratoconus and inflammatory molecules from tears. *Br J Ophthalmol* 2009;6:820-824
36. Ambekar R, Toussaint KC Jr, Johnson AW. The effect of keratoconus on the structural, mechanical, and optical properties of the cornea. *J Mech Behav Biomed Mater* 2011;4:223-236
37. Stulting RD, Carr JD, Thompson KP, et al. Complications of laser in situ keratomileusis for the correction of myopia. *Ophthalmology* 1999;106:13-20
38. Reinhart WJ, Musch DC, Jacobs DS, et al. Deep anterior lamellar keratoplasty as an alternative to penetrating keratoplasty: A report by the American Academy of Ophthalmology. *Ophthalmology* 2011;118:209-218
39. Villarrubia A, Fuentes-Páez G, Dapena I, Palacín E. Deep anterior lamellar keratoplasty with Melles' technique: Mid-term clinical outcome. *J Emmetropia* 2010;1:182-186



