



Universiteit  
Leiden  
The Netherlands

## Clinical outcomes of modern lamellar keratoplasty techniques

Dijk, K. van

### Citation

Dijk, K. van. (2018, January 16). *Clinical outcomes of modern lamellar keratoplasty techniques*. Retrieved from <https://hdl.handle.net/1887/59337>

Version: Not Applicable (or Unknown)

License: [Licence agreement concerning inclusion of doctoral thesis in the Institutional Repository of the University of Leiden](#)

Downloaded from: <https://hdl.handle.net/1887/59337>

**Note:** To cite this publication please use the final published version (if applicable).

Cover Page



Universiteit Leiden



The handle <http://hdl.handle.net/1887/59337> holds various files of this Leiden University dissertation

**Author:** Dijk, Korine van

**Title:** Clinical outcomes of modern lamellar keratoplasty techniques

Date: 2018-01-16

# Chapter 5

## Two-Year Refractive Outcomes After Descemet Membrane Endothelial Keratoplasty

Korine van Dijk, Marina Rodriguez-Calvo-de-Mora, Hilde van Esch,  
Laurence Frank, Isabel Dapena, Lamis Baydoun, Silke Oellerich, and  
Gerrit RJ Melles

Cornea 2016;35:1548-1555

2

3

4

5

6

7

8

9

10

A

## ABSTRACT

**Purpose.** To monitor refractive changes after Descemet membrane endothelial keratoplasty (DMEK) and to determine what may influence these changes and the time point of stabilization.

**Methods.** From 67 pseudophakic DMEK eyes operated on for Fuchs endothelial dystrophy at a tertiary referral center biomicroscopy, visual acuity, subjective refraction and Scheimpflug based corneal tomography data were obtained before, and up to 2 years postoperatively. Visual acuity and changes in spherical equivalent (SE), mean anterior and posterior simulated keratometry (Km), and central pachymetry were analyzed.

**Results.** At 3 months postoperatively, both hyperopic (28/67 eyes) and myopic (21/67 eyes) shifts were observed, 18/67 eyes showed no SE change. Mean change in SE at 3 months was +0.33 Diopters (D) (95% confidence interval (CI)=[0.11,0.54],  $P=.028$ ), which stabilized thereafter ( $P>.466$ ). Initial flattening of mean anterior Km by 0.66D (95% CI=[-0.81,-0.51],  $P<.001$ ) at 3 months was followed by a slow steepening, which became significant between 1 and 2 years postoperatively ( $P<.001$ ). Posterior Km stabilized after 3 months ( $P>.252$ ). Pre- to 3 months postoperative absolute changes in anterior Km were positively related to preoperative backscattered light from the central anterior cornea ( $P=.035$ ), and the presence of partial graft detachment postoperatively ( $P=.013$ ).

**Conclusion.** After DMEK, SE and posterior corneal curvature were on average stable at 3 months after surgery, while the mean anterior corneal curvature showed an ongoing gradual change. Changes in anterior corneal curvature may be related to preoperative anterior corneal densitometry or postoperative partial graft detachment.

**Keywords:** Descemet membrane endothelial keratoplasty, DMEK, Fuchs endothelial dystrophy, refraction, Pentacam, pachymetry.

## INTRODUCTION

With the introduction of endothelial keratoplasty (EK),<sup>1</sup> it has been postulated that elimination of anterior corneal incisions or graft fixation by sutures should result in minimal postoperative refractive changes, as well as long term refractive stability of the operated eye.<sup>1-3</sup> In contrast to the unpredictable refractive outcomes after penetrating keratoplasty, EK procedures such as Deep lamellar endothelial keratoplasty (DLEK), Descemet stripping (automated) endothelial keratoplasty (DSEK/DSAEK) and Descemet membrane endothelial keratoplasty (DMEK) indeed share the advantage of inducing limited refractive changes.<sup>2-5</sup> A hyperopic shift has been described to occur both after DSEK/DSAEK and DMEK,<sup>6-10</sup> but this change in corneal power may largely originate from stromal tissue addition and/or corneal deturgescence, rather than from an anterior corneal change.<sup>5-8</sup>

With a mean refractive shift of approximately 0.3 Diopters (D), DMEK may be the first technique in corneal transplantation that (on average) is virtually refractive neutral. However, larger refractive shifts in individual cases have also been observed after DMEK, but have not been associated yet with any potential causes.<sup>7,8</sup> In terms of refractive stability, longer term stability has been surveyed after DLEK,<sup>9,11</sup> and DSAEK,<sup>12</sup> but not yet after DMEK.

Determining the presence or absence of (late onset) refractive changes with DMEK and assessing anterior corneal surface changes may be important to facilitate intraocular lens power calculation, because a majority of eyes may be eligible for cataract removal before, during or after EK. Furthermore, it is of interest to estimate the time point of refractive stability to allow for an accurate prescription of spectacles.

The purpose of this study was to monitor the refractive change and stability after DMEK, and to determine which factors may possibly influence the change in refraction and the time point of stabilization in a larger series of pseudophakic DMEK eyes operated on for Fuchs endothelial dystrophy.

## MATERIAL AND METHODS

Prospectively collected data of consecutive pseudophakic DMEK eyes (n=163) successfully operated on for Fuchs endothelial dystrophy between November 2007 and January 2011, without clinically significant graft detachment and with no history of previous ocular surgery other than uncomplicated phacoemulsification, were retrospectively evaluated. Only eyes with a complete data set for all relevant follow-up time points up to two years after surgery regarding best spectacle-corrected visual acuity (BSCVA), subjective refraction and Scheimpflug imaging were included in our study, whereas eyes with

incomplete follow-up data (n=37) or unreliable Scheimpflug imaging data (n=13) were excluded. Other exclusion criteria involved visual impairment attributable to retinal (n=8) or optic nerve pathologies (n=2), posterior capsular opacities (n=3) and amblyopia (n=1). In case of a bilateral DMEK (n=32), only the first operated eye was included.

All participants signed an informed consent for research participation. This study was conducted in compliance with the Institutional Review Board and Informed Consent requirements, and adhered to the Declaration of Helsinki.

### **Surgical procedure**

DMEK graft preparation and surgeries were performed as previously described.<sup>13,14</sup> Briefly, a YAG-laser peripheral iridotomy was made at 12 o'clock 2 weeks prior to surgery. Surgery was performed under local (retrobulbar) anaesthesia, and the patient was positioned in the anti-Trendelenburg position. Three side ports were made, the anterior chamber was filled with air, and a 'descemetorhexis' was conducted using a reversed Sinsky hook (DORC International, Zuidland, The Netherlands).<sup>14</sup> After a 3.0-mm limbal tunnel incision, the donor Descemet-roll was stained with 0.06% trypan blue solution (VisionBlueTM, DORC International), and sucked into a custom-made injector (DORC International), before it was inserted into the anterior chamber.<sup>14</sup> The graft was then oriented endothelial side down, centered, unfolded, and lifted onto the recipient posterior stroma. The anterior chamber was completely filled with air for 1 hour, followed by an air-liquid exchange to reduce the air, leaving a 30% to 50% air bubble in the anterior chamber, and to pressurize the eye.<sup>14</sup>

### **Examinations**

All included eyes underwent complete ophthalmological evaluation before and at 1, 3, 6, 12 and 24 months postoperatively.

Fuchs endothelial dystrophy severity was described using a modified Krachmer grading scale, based on the area and confluence of guttae and the presence of edema and categorized in 6 stages.<sup>15</sup> Grades 1 and 2 were considered as mild Fuchs endothelial dystrophy, grades 3 and 4 as moderate Fuchs endothelial dystrophy, whereas grades 5 and 6 were regarded as advanced Fuchs endothelial dystrophy. BSCVA, manifest refraction and rotating Scheimpflug imaging (Oculus Pentacam HR 70900, Wetzlar, Germany) of the preoperative and 3, 6, 12 and 24 months postoperative examinations were used for evaluation. During Pentacam examination, the automatic release mode was used to eliminate operator-induced errors. Only good quality images, as categorized by the Pentacam software, were analyzed. The software provides horizontal and vertical simulated keratometry values (SimK) for the posterior and anterior corneal surfaces on a ring 15 degrees around the corneal apex.<sup>16</sup> To convert radii of curvature into corneal power, the program uses the refractive indices of 1.3375 (keratometric index) and 1.0 (air) concern-

ing the anterior corneal SimK, whereas refractive indices of 1.332 (aqueous humor) and 1.376 (cornea) were used for the posterior corneal SimK.<sup>16</sup> Mean simulated keratometry (Km) values of the anterior and posterior corneal surfaces were used for analysis, as well as pachymetry at the pupil center. Furthermore, to be able to objectively measure Fuchs endothelial dystrophy severity additionally to the (more observer dependent) modified Krachmer scale, mean backscattered light of the central 2 mm of the anterior 120  $\mu\text{m}$  from the cornea, which has been shown to correlate with disease severity,<sup>17</sup> was obtained using the Pentacam corneal densitometry display. To standardize ambient light conditions, all measurements were performed in a windowless clinical assessment room with a uniform ambient light level of 4 lux as measured by a luxmeter (Votcraft BL-10 L Luxmeter; Conrad Electronic SE Hirschau, Germany). Corneal density was quantified on a percent scale from 0 (no obscuring) to 100 (completely opaque).

BSCVA, using a forced choice test, and subjective refraction were measured with a 100% contrast Snellen projection letter chart at 6 meters in mesopic lighting conditions. After converting BSCVA values to logarithm of the minimum angle of resolution units (LogMAR) and sphero-cylinder refractive errors to spherical equivalent (SE), calculations were performed. If a change in refraction differed by more than 0.25D from the preoperative refraction, it was classified as a myopic or hyperopic shift; smaller shifts were considered refractive neutral.

Independent paired Student t-tests were performed with Excel Software for Windows (Microsoft, 2007) to compare age, baseline BSCVA, anterior central corneal densitometry and central pachymetry between the moderate and advanced Fuchs endothelial dystrophy group. Further statistical analyses were performed with R (version 3.1.2) using the packages nlme (version 3.1-118) and mle4 (version 1.176). A point-biserial correlation was used to evaluate the association between preoperative Fuchs endothelial dystrophy stage and central anterior corneal backscatter. For repeated measures analysis of variance, linear mixed models were used to assess changes in SE and keratometry parameters over time, the time point of stabilization, and to investigate whether factors such as patient age, gender, preoperative LogMAR BSCVA, preoperative Fuchs endothelial dystrophy stage, preoperative backscattered light from the central 2 mm of the anterior 120  $\mu\text{m}$  of the cornea, and postoperative partial graft detachment influenced the refractive outcome. Furthermore, after checking multicollinearity, logistic regression analyses were used to evaluate the predictive value of the above mentioned parameters on the initial absolute shifts (divided into shifts of  $>1.0\text{D}$  and  $\leq 1.0\text{D}$ ) in SE and keratometry parameters at 3 months postoperative. The outcomes of these analyses were corrected for all included parameters. To prevent alpha inflation and power loss due to multiple testing, all *P*-values were corrected using the Benjamini and Hochberg method,<sup>18</sup> after which a *P*-value of  $<.05$  was considered statistically significant.

## RESULTS

Patient demographics are summarized in Table 1. Sixty-seven eyes of 67 patients (37 females and 30 males; mean age 71.1 ( $\pm$ 8.5) years) met the inclusion criteria for this study. Eyes underwent DMEK surgery at Fuchs endothelial dystrophy grades 3 to 6 (Table 1). Of the 27 eyes with advanced Fuchs endothelial dystrophy (grades 5 and 6), 23 presented preoperatively with epithelial edema, in 7 eyes the edema was accompanied by (sub) epithelial bullae. Advanced Fuchs endothelial dystrophy was associated with higher anterior corneal densitometry values ( $r=0.68$ ,  $P<.001$ ), and accompanied by worse BSCVA and thicker central pachymetry ( $P<.001$ ) (Table 1).

Postoperatively, fifty-six eyes showed a completely attached DMEK graft, while in 11 eyes a partial graft detachment ( $\leq 1/3$  of the graft surface area, not affecting the visual axis) was present (Table 1). At the 3 months follow-up, 7 corneas of the 11 cases with a partial graft detachment showed epithelial edema over the detached area, while 3 of these corneas still presented with some residual epithelial edema at the 6 months follow-up, and 1 at the 12 months follow-up. The eyes with partial graft detachments

**Table 1.** Demographics and baseline characteristics of pseudophakic DMEK eyes.

	Total Group	Moderate FED	Advanced FED
FED grading*		3 and 4	5 and 6
Number of eyes (n, %)	67	40 (60%)	27 (40%)
Age (years)			
mean (SD)	71 ( $\pm$ 9)	71 ( $\pm$ 8)	71 ( $\pm$ 9)
range	49-89	59-83	49-89
Male / Female (n, %)	30/37 (45%/55%)	18/22 (45%/55%)	12/15 (44%/56%)
Baseline BSCVA			
mean LogMAR (SD)	0.46 ( $\pm$ 0.27)	0.36 ( $\pm$ 0.17)	0.62 ( $\pm$ 0.33) <sup>ooo</sup>
range (Snellen)	20/400 - 20/25	20/133 - 20/25	20/400 - 20/25
Baseline corneal densitometry			
anterior 120 $\mu$ m / central 2 mm	40.0 ( $\pm$ 12.8)	33.0 ( $\pm$ 6.8)	50.5 ( $\pm$ 12.5) <sup>ooo</sup>
Baseline central pachymetry ( $\mu$ m)	679 ( $\pm$ 95)	638 ( $\pm$ 46)	739 ( $\pm$ 116) <sup>ooo</sup>
Postoperative graft status (n)			
Completely attached	56	33	23
Partial graft detachment+	11	7	4

SD: Standard deviation

FED: Fuchs endothelial dystrophy

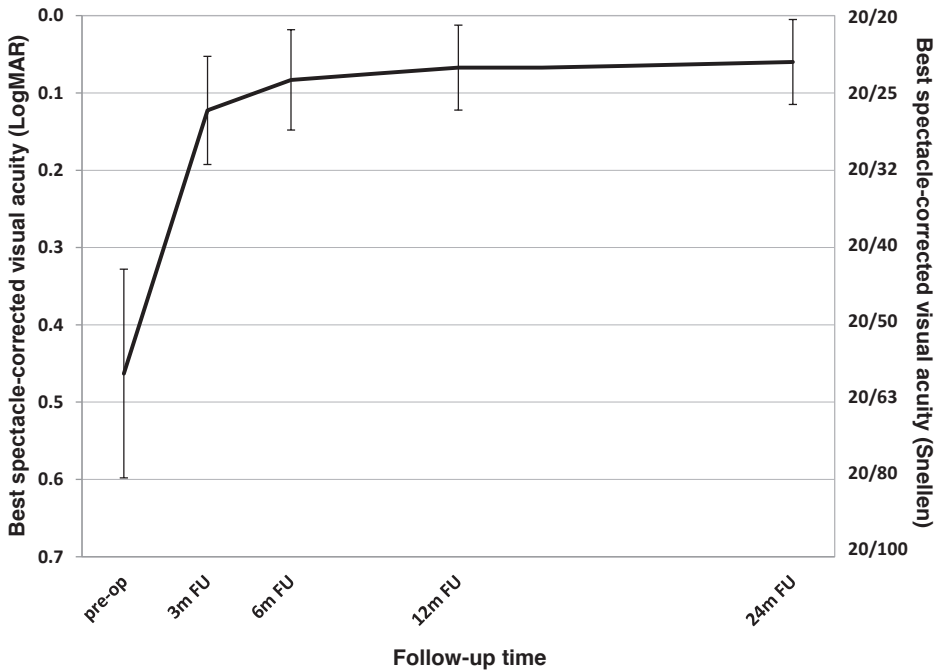
DMEK: Descemet membrane endothelial keratoplasty

\*Based on modified Krachmer scale by reference 15

+Partial graft detachment of  $\leq 1/3$  of graft surface area (not affecting the visual axis)

<sup>o</sup> $P<.001$  versus moderate FED cases





**Figure 1.** Graph displaying mean best spectacle-corrected visual acuity (BSCVA) after Descemet membrane endothelial keratoplasty (DMEK). BSCVA is presented in logarithm of the minimum angle of resolution units (LogMar) preoperatively and at 3, 6, 12 and 24 months after DMEK. Vertical bars represent the standard deviation. Note the fast visual rehabilitation from preoperative to 3 months after DMEK, after which a slower visual improvement occurs from 3 to 12 months postoperatively, and stabilization thereafter. (m = months, FU = Follow up)

showed comparable visual rehabilitation with eyes with a completely attached graft ( $P>.508$ ).

Mean BSCVA improved from 0.46 ( $\pm 0.27$ ) LogMAR preoperatively to 0.12 ( $\pm 0.14$ ) LogMAR at 3 months and 0.07 ( $\pm 0.11$ ) LogMAR at 12 months postoperatively ( $P<0.001$ ), representing an improvement in Snellen equivalent of 20/59 (0.34) before to 20/27 (0.75) at 3 months and 20/24 (0.85) at 12 months after DMEK. Thereafter, BSCVA remained stable up to the 2 year-follow-up ( $P=.342$ ) (Figure 1).

Table 2 shows the mean and median subjective and objective refractive parameters over time. After an observed mean change in SE of +0.33D (95% Confidence Interval (CI)=[0.11,0.54],  $P=.028$ ,  $r^2=0.03$ ; representing a small effect) from before to 3 months after surgery no changes were found thereafter ( $P>.466$ ) (Table 2). No change in mean refractive cylinder from before to any evaluated postoperative follow-up was observed ( $P>.312$ ), however large variations were found in individual cases.

For the anterior corneal curvature an average decrease (flattening) of -0.66D (95% CI=[-0.81,-0.51],  $P<.0001$ ,  $r^2=0.23$ ; medium to large effect) in Km was observed (Table 2).

**Table 2.** Distribution of subjective and objective refractive parameters during follow-up visits

		Preoperative	Postoperative			
			3 months FU	6 months FU	12 months FU	24 months FU
Spherical equivalent (D)	Mean (SD)	0.02 ( $\pm 1.74$ )	<b>0.35 (<math>\pm 1.49</math>)</b>	0.24 ( $\pm 1.65$ )	0.23 ( $\pm 1.49$ )	0.21 ( $\pm 1.49$ )
	Median	0.00	<b>0.38</b>	0.38	0.25	0.25
P-value *	(previous FU to FU)		<b>0.028</b>	0.466	0.918	0.918
r <sup>2</sup> **			<b>0.03</b>			
Refractive cylinder (D)	Mean (SD)	-1.22 ( $\pm 0.86$ )	-1.37 ( $\pm 1.04$ )	-1.29 ( $\pm 0.92$ )	-1.47 ( $\pm 1.03$ )	-1.48 ( $\pm 0.97$ )
	Median	-1.25	-1.25	-1.25	-1.50	-1.25
P-value *	(previous FU to FU)		0.361	0.570	0.312	0.896
r <sup>2</sup> **						
Anterior curvature (Km) (D)	Mean (SD)	43.03 ( $\pm 1.52$ )	<b>42.36 (<math>\pm 1.60</math>)</b>	42.49 ( $\pm 1.55$ )	42.61 ( $\pm 1.61$ )	<b>42.82 (<math>\pm 1.55</math>)</b>
	Median	42.90	<b>42.60</b>	42.60	42.80	<b>42.80</b>
P-value*	(previous FU to FU)		<b>&lt;0.0001</b>	0.099	0.099	<b>0.008</b>
r <sup>2</sup> **			<b>0.23</b>			<b>0.03</b>
Posterior curvature (Km) (D)	Mean (SD)	-5.50 ( $\pm 0.72$ )	<b>-6.43 (<math>\pm 0.43</math>)</b>	-6.36 ( $\pm 0.34$ )	-6.32 ( $\pm 0.34$ )	-6.30 ( $\pm 0.33$ )
	Median	-5.60	<b>-6.40</b>	-6.30	-6.30	-6.30
P-value *	(previous FU to FU)		<b>&lt;0.0001</b>	0.252	0.470	0.699
r <sup>2</sup> **			<b>0.53</b>			
Central corneal thickness ( $\mu\text{m}$ )	Mean (SD)	679 ( $\pm 95$ )	<b>526 (<math>\pm 49</math>)</b>	522 ( $\pm 39$ )	526 ( $\pm 31$ )	533 ( $\pm 36$ )
	Median	659	<b>524</b>	523	528	530
P-value *	(previous FU to FU)		<b>&lt;0.0001</b>	0.423	0.423	0.423
r <sup>2</sup> **			<b>0.68</b>			

FU: Follow-up, SD : Standard deviation,  $\mu\text{m}$ : Micrometer, \*: *P*-value representing statistical significance of difference between FU and previous FU calculated with repeated measures analysis of variance. Corrected for alpha-inflation with Benjamini and Hochberg<sup>18</sup>, Bold: Statistically significant,  $r^2$ : Effect size of difference between FU and previous FU (interpretation according to Cohen's classification  $r^2 = 0.01$  small effect,  $r^2 = 0.09$  medium effect, and  $r^2 = 0.25$  large effect)<sup>32</sup>, \*\*: Only mentioned with statistically significant change between follow-up visits, Km: Mean simulated keratometry, D: Diopters

After the first 3 postoperative months the anterior corneal curvature showed a gradual steepening, which became significant between 1 and 2 years postoperatively (estimated mean difference ( $\Delta\text{m}$ )=0.21D, 95% CI=[0.06,0.35],  $P=.008$ ,  $r^2=0.03$ ; small effect) (Table 2). Posterior Km steepened from before to 3 months postoperatively ( $\Delta\text{m}=-0.93\text{D}$ , 95% CI=[-1.04,-0.83],  $P<.0001$ ,  $r^2=0.53$ ; large effect) and was stable thereafter ( $P>.699$ ) (Table 2). Likewise, mean central pachymetry decreased with 145 $\mu\text{m}$  (95% CI=[-157,-133],  $P<.0001$ ,  $r^2=0.68$ ; large effect) from before to 3 months after surgery, after which it stabilized ( $P>.423$ ) (Table 2).

Both hyperopic and myopic shifts in refraction were observed (Figure 2). Twenty-eight eyes (42%) showed a hyperopic shift, while 21 eyes (31%) had a myopic shift at the 3 months follow-up (Figure 2A). The absolute change in SE was  $\leq 0.50\text{D}$  in 27 eyes (39%)

**Table 3.** Logistic regression analyses with the initial absolute shifts in spherical equivalent and keratometry parameters at 3 months postoperative divided into shifts  $\geq 1.0$  or  $< 1.0$  diopter as dependent variable, and patient's age, gender, preoperative LogMAR best spectacle-corrected visual acuity, preoperative Fuchs endothelial dystrophy stage, preoperative anterior densitometry and postoperative graft attachment status as predictor variables.

	SE			Anterior Km			Posterior Km		
	OR	95% CI	P-value	OR	95% CI	P-value	OR	95% CI	P-value
Intercept	0.08	0.01 – 0.79	.038	0.00	0.00 – 0.07	<.001	0.06	0.00 – 0.56	.002
Preoperative logMar BSCVA	0.79	0.08 – 7.39	.833	2.55	0.21 – 46.63	.481	0.54	0.04 – 4.52	.612
Preoperative FED stage*	0.75	0.15 – 3.52	.721	1.65	0.23 – 12.45	.616	2.90	0.61 – 14.23	.178
Preoperative anterior densitometry <sup>o</sup>	1.05	0.99 – 1.12	.132	<b>1.08</b>	<b>1.01 – 1.18</b>	<b>.035</b>	1.03	0.79 – 1.10	.348
Postoperative partial graft detachment+	0.65	0.13 – 2.97	.591	<b>9.37</b>	<b>1.72 – 63.85</b>	<b>.013</b>	1.92	0.32 – 9.20	.411
Age	1.07	1.00 – 1.15	.052	0.99	0.91 – 1.08	.818	1.00	0.94 – 1.08	.921
Gender	1.54	0.48 – 5.19	.480	2.51	0.56 – 12.89	.237	1.14	0.33 – 3.93	.829

SE: Spherical equivalent

Km: Mean simulated keratometry

BSCVA: Best spectacle-corrected visual acuity

FED: Fuchs endothelial dystrophy

OR: Odds ratio (provides the absolute predictive impact on the dependent variable)

CI: Confidence interval

"Bold": Statistically significant

\*Based on modified Krachmer scale by reference 15

<sup>o</sup>Anterior 120  $\mu\text{m}$  / central 2 mm

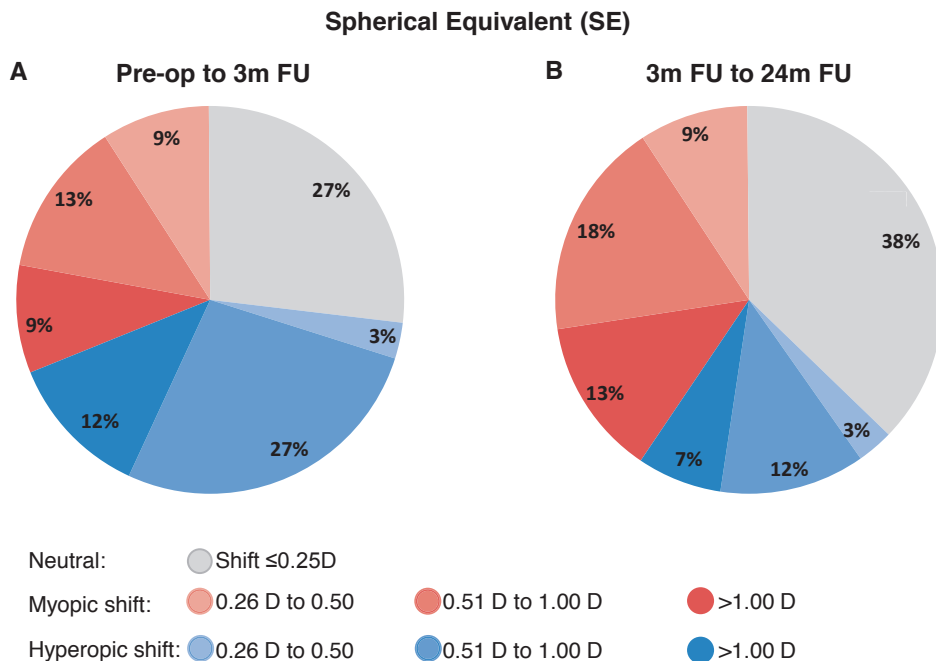
+Partial graft detachment of  $\leq 1/3$  of graft surface area

and  $\leq 1.00\text{D}$  in 53 eyes (79%) (Figure 2A). Between 3 months and 2 years after surgery SE continued to change  $>0.50\text{D}$  in half of the cases (34/67), of which 20% (14/67) changed  $>1.00\text{D}$  (Figure 2B).

Fifty-three eyes (73%) showed a flattening of the anterior corneal curvature from before to 3 months after the surgery (Figure 3A). The initial flattening at 3 months postoperatively was  $>1.00\text{D}$  in 18 eyes (27%), while 7 eyes (11%) steepened  $>1.00\text{D}$  thereafter (Figure 3B).

Except for one eye in which no change in posterior Km was observed, all eyes showed a steepening in the posterior curvature from before to 3 months after the surgery (Figure 3C). The subsequent change beyond 3 months and until 2 years postoperatively was  $\leq 0.10\text{D}$  in 66% of the eyes (Figure 3D).

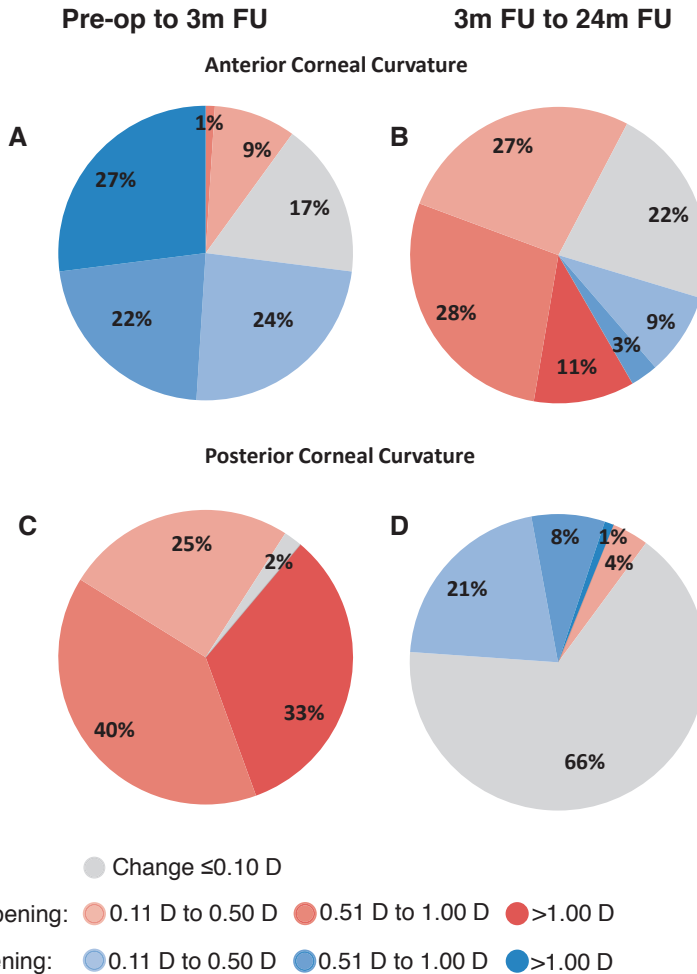
Logistic regression analyses indicated that absolute changes in anterior Km from before to 3 months after DMEK were positively related to preoperative central 2 mm anterior corneal densitometry (back scattered light) (Table 3). Each percent increase in anterior corneal backscattered light gave an 8% higher probability of a pre- to postoperative shift in anterior Km  $>1.00\text{D}$  (Odds Ratio (OR)=1.08, 95% CI=[1.01, 1.18],  $P=.035$ )



**Figure 2.** Pie charts displaying the contribution of different shifts in spherical equivalent (SE). The change in SE is shown for (A) preoperative to 3 months after Descemet membrane endothelial keratoplasty (DMEK) and for (B) 3 to 24 months postoperatively. Note that (A) from preoperative to 3 months postoperatively, a hyperopic or myopic shift was present in respectively 42% and 31% of cases, while 27% of cases showed no change ( $\leq 0.25$  Diopters). (B) After that in 38% of cases SE stabilized, but also changes in both hyperopic (22%) and myopic (30%) direction were observed. (A, B) In 21% and 20% of cases, respectively, the shift was larger than 1 Diopter from preoperative to 3 months postoperative and from 3 months to 24 months postoperatively. (m = months, FU = Follow up)

(Table 3). Additionally, the presence of a partial graft detachment postoperatively gave a 9 times higher likelihood for a larger shift in anterior Km than a completely attached graft (OR=9.37, 95% CI=[1.72, 63.85],  $P=.013$ ) (Table 3).

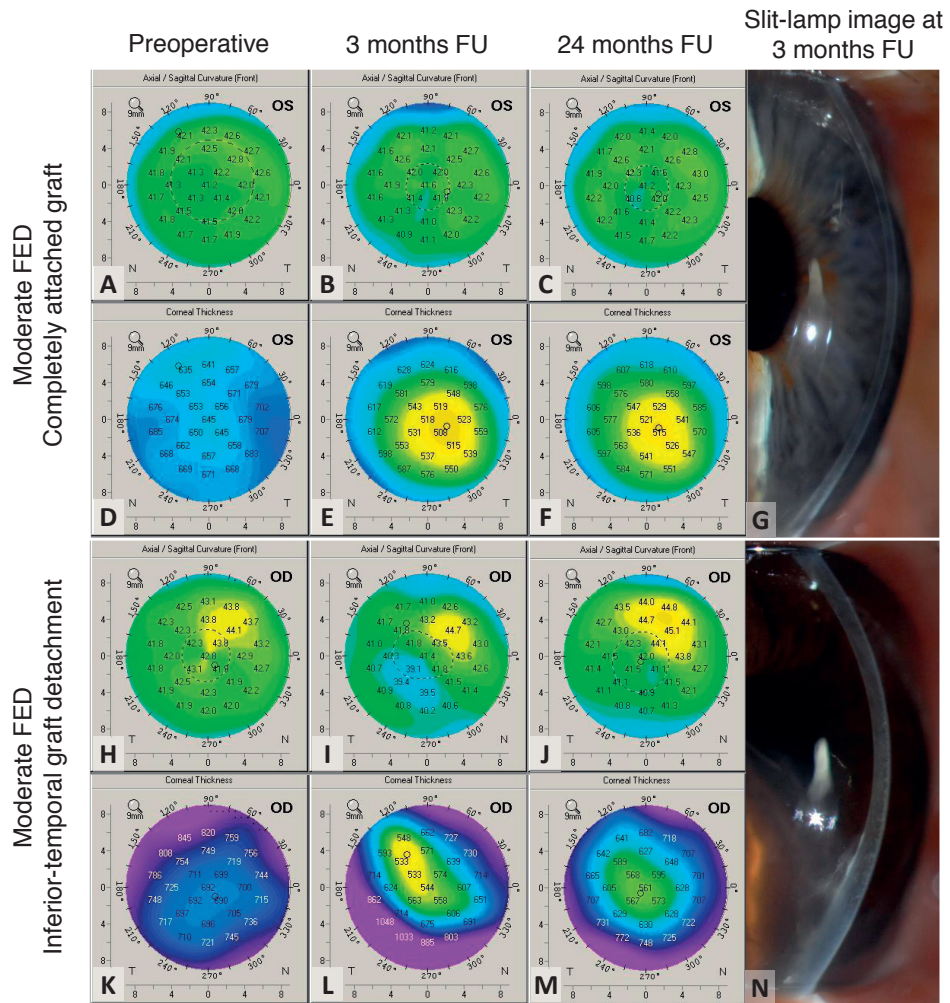
The observed gradual steepening of the anterior corneal curvature after the third postoperative month was found to be related to patient's age ( $P=.002$ ,  $r^2=0.15$ ; representing a large effect). Per age increment of one year, the anterior Km steepened with 0.07D. None of the other predictors showed a significant relation with later changes in subjective or objective refractive parameters ( $P>.05$ ).



**Figure 3.** Pie charts displaying the contribution of different changes in simulated keratometry (Km) for the anterior and posterior cornea. Km values are displayed for the (A, B) anterior and (C, D) posterior cornea. Pie charts (A) and (C) display the changes from preoperative to 3 months after Descemet membrane endothelial keratoplasty (DMEK), and in pie charts (B) and (D) the changes from 3 to 24 months postoperatively are shown. Note that (A, B) the anterior corneal curvature showed a flattening in about 73% of cases from preoperative to 3 months after DMEK, followed by a steepening in approximately the same amount of cases thereafter. (C, D) Posterior Km steepened in almost all cases, after which stabilization was seen in most cases. (A, C) Changes of >1.00 Diopter were initially present in both the anterior (27%), as well as the posterior (33%) cornea, (B, D) but were relatively rare thereafter. (m = months, FU = Follow up)

## DISCUSSION

From previous studies on refractive outcome after EK we have learned that, by only replacing the posterior layers and not compromising the anterior cornea, EK procedures induce limited, more predictable, refractive changes and a more stable corneal power



**Figure 4.** Sagittal curvature front and corneal thickness maps in 2 cases with moderate Fuchs endothelial dystrophy (FED) before and at 3 and 24 months after Descemet membrane endothelial keratoplasty (DMEK) with a completely attached and a partially detached graft and related slit-lamp images at 3 months postoperatively. (A to G) In a cornea operated on for moderate FED, the anterior corneal topography (A to C) is relatively stable from before to 3 and 24 months after DMEK, and corneal pachymetry (D to F) shows an evenly distributed deturgescence pattern in the presence of a completely attached graft (G). (H to N) In the presence of a partially detached graft (N), the anterior corneal topography (H to J) shows initial flattening in the area with graft detachment and a partial reversal thereafter. Furthermore, an unevenly distributed deturgescence pattern (K to M) is present, mainly until 3 months postoperatively. (FU = Follow up)

compared to penetrating keratoplasty.<sup>2-5</sup> Whereas the refractive shift after DSEK/DSAEK may be caused by a 'negative lenticular shape' of the graft, after DMEK the change in refraction may solely result from postoperative de-swelling of the recipient's edematous cornea.<sup>5-8,10,19</sup>

In the current study, refractive changes up to 2 years after DMEK in a cohort of pseudophakic Fuchs endothelial dystrophy eyes were evaluated. A mean hyperopic shift of approximately 0.3D at 3 months after surgery was found. Furthermore, the posterior corneal curvature showed a steepening of about 1D, and pachymetry reduced by 150 $\mu$ m. These results compare well with other reports on refractive outcome after DMEK.<sup>5,7,8</sup>

However, whereas the mean refractive shift after DMEK may be relatively small, wide variation in refractive shifts between individuals have been observed.<sup>7,8</sup> About 20% of eyes in our study showed refractive changes larger than 1D, in both hyperopic and myopic direction (Figure 2). The same variation was observed in corneal curvature changes, mostly concerning the anterior cornea (Figure 3A and 3B). Overall, a mean flattening of the anterior corneal curvature of about 0.6D was observed, which confirmed previous reports of our group.<sup>7,20</sup> In contrast, a relatively stable anterior corneal contour after DMEK has also been observed by us,<sup>5</sup> and others.<sup>8,21,22</sup>

It has been hypothesized that larger, less predictable refractive changes after DMEK may be more likely with advanced Fuchs endothelial dystrophy compared to the moderate stages of the disease.<sup>7,22</sup> This seems plausible given the fact that more advanced Fuchs endothelial dystrophy results in a more decompensated (more edematous) cornea, causing larger bulging of the central posterior corneal curvature towards the anterior chamber, as well as involvement of the anterior cornea, with anterior stromal changes, epithelial edema, with or without subepithelial bullae formation, and topographical hot spots.<sup>14,23-24</sup> Furthermore, the restoration of the corneal hydration status of more decompensated corneas may plausibly cause a somewhat larger change in corneal refractive index.<sup>25</sup> Refractive changes in these advanced cases may also be less predictable due to residual subepithelial fibrosis after long-term edema, which may produce local variations in both the anterior corneal curvature and the refractive index of the cornea.<sup>26</sup> We have recently stated that extensive edema in corneas with endothelial disease may result in surface irregularities and consequently need for contact lenses to improve postoperative vision after EK,<sup>27</sup> but it may perhaps also induce less predictable postoperative refractive outcomes.

Nevertheless, our statistical analyses could not reveal any significant relation between Fuchs endothelial dystrophy severity and the observed changes in subjective or objective refractive parameters. Possibly due to the fact that, even though the modified Krachmer scale used for Fuchs endothelial dystrophy grading is a fairly quantitative assessment, it may have some observer dependency. Furthermore, the preoperative subjective refractions in advanced Fuchs endothelial dystrophy cases may have been less accurate due to corneal decompensation. Interestingly though, larger pre- to post-DMEK changes in anterior corneal curvature seemed related to anterior corneal backscattered light, which was shown to be related to Fuchs endothelial dystrophy severity with higher levels of anterior corneal backscatter in more advanced Fuchs endothelial dystrophy

cases.<sup>17</sup> Furthermore, this relation was confirmed in this study. As such, anterior corneal backscattered light may give an objective measure for Fuchs endothelial dystrophy rating, and so reveal its impact on refractive parameters.

Another interesting outcome of this study is that partial DMEK graft detachment of <1/3 of the graft surface area may also induce larger postoperative changes of the anterior corneal curvature. This may be explained by a more unevenly distributed corneal deturgescence pattern, in which the cornea overlying the detachment may be edematous for a somewhat longer period, compared to the area with graft attachment.<sup>28,29</sup> Subsequently, epithelial edema in these detached areas may interfere with simulated keratometry readings, especially in the first postoperative months (Figure 4).

Although most refractive parameters evaluated in this study stabilized on average at 3 months after surgery, several eyes showed refractive changes thereafter. Reasonably, with more advanced Fuchs endothelial dystrophy and partial graft detachment it may take longer for the cornea to re-adopt a non-edematous status, i.e. pachymetry and corneal curvatures returning to normal, and to obtain refractive stabilization. However, no relation was found between either Fuchs endothelial dystrophy stage, anterior corneal densitometry or graft attachment status and later changes (changes after the 3 months follow-up) in subjective or objective refractive parameters. Only patient age seemed to be associated with the gradual steepening of the anterior corneal curvature seen after the 3 months follow-up. Also in the normal cornea, the anterior corneal topography has been shown to change with aging, with the tendency of the central anterior corneal curvature (especially the horizontal meridian) to steepen with age.<sup>30</sup>

In eyes with Fuchs endothelial dystrophy and concomitant cataract, cataract surgery may be performed prior to or during DMEK. With modern intraocular lens (IOL) power calculation formulas, the cornea is assumed to be a thin spherical lens with a fixed anterior to posterior corneal curvature ratio and a refractive index of 1.3375. These formulas are not suitable after photorefractive keratotomy and laser-assisted in situ keratomileusis, because of the changed anterior corneal curvature, resulting in an altered relationship between the corneal curvatures.<sup>31</sup> With EK, the anterior corneal curvature may be relatively stable. Instead, IOL power calculation with DSEK/DSAEK may be difficult owing to tissue addition with partially unknown optical characteristics in the posterior cornea.<sup>7,8</sup> No tissue is added with DMEK, so that after the surgery an anterior to posterior corneal curvature ratio is to be expected which compares equal to normal corneas. Consequently, IOL power calculations for cataract surgery prior to or combined with DMEK may be performed using routine nomograms. Given the expected mean hyperopic shift after DMEK of +0.33D, a refractive IOL-power calculation toward -0.50D to -1.00D may be advocated to get an emmetropic or slightly myopic result.<sup>8</sup> Especially in more advanced Fuchs endothelial dystrophy cases, however, IOL power selection may be more challenging, i.e. more unforeseen refractive shifts owing to changes in



the anterior corneal curvature are to be expected. Therefore, patients with advanced Fuchs endothelial dystrophy may be counseled about somewhat larger, less predictable refractive shifts postoperatively. Moreover, especially with DMEK, a procedure that may give full visual rehabilitation, it may be important to possibly avoid these refractive surprises by timely surgical intervention. The latter may also be true for the use of toric IOLs before or during DMEK. Further research regarding astigmatic changes, including vector analyses may be helpful in determining if and when a toric IOL may be useful in cases with Fuchs endothelial dystrophy and concomitant cataract.

In conclusion, DMEK may give a minimal refractive change and stabilization thereof at 3 months after surgery in mild Fuchs endothelial dystrophy cases. More advanced Fuchs endothelial dystrophy may give larger, more variable refractive shifts, complicating IOL power calculation.

## REFERENCES

1. Melles GR, Eggink FA, Lander F, et al. A surgical technique for posterior lamellar keratoplasty. *Cornea* 1998;17:618-626
2. Terry MA, Ousley PJ. In pursuit of emmetropia: spherical equivalent refraction results with deep lamellar endothelial keratoplasty (DLEK). *Cornea* 2003;22:619-626
3. Bahar I, Kaiserman I, McAllum P, et al. Comparison of posterior lamellar keratoplasty techniques to penetrating keratoplasty. *Ophthalmology* 2008;115:1525-1533
4. Price FW Jr, Price MO. Descemet's stripping with endothelial keratoplasty in 50 eyes: a refractive neutral corneal transplant. *J Refract Surg* 2005;21:339-345
5. Ham L, Dapena I, Moutsouris K, et al. Refractive change and stability after Descemet membrane endothelial keratoplasty Effect of corneal dehydration-induced hyperopic shift on intraocular lens power calculation. *J Cataract Refract Surg* 2011;37:1455-1464
6. Holtz HA, Meyer JJ, Espandar L, et al. Corneal profile analysis after Descemet stripping automated endothelial keratoplasty and its relationship to postoperative hyperopic shift. *J Cataract Refract Surg* 2008;34:211-214
7. Van Dijk K, Ham L, Tse WW, et al. Near complete visual recovery and refractive stability in modern corneal transplantation: Descemet membrane endothelial keratoplasty (DMEK). *Cont Lens Anterior Eye* 2013;36:13-21
8. Schoenberg ED, Price FW Jr, Miller J, et al. Refractive outcomes of Descemet membrane endothelial keratoplasty triple procedures (combined with cataract surgery). *J Cataract Refract Surg* 2015;41:1182-1189
9. Van Dijk K, Dapena I, Moutsouris K, et al. First DLEK Series: 10-Year Follow-up. *Ophthalmology* 2011;118:424
10. Droutsas K, Lazaridis A, Papaconstantinou D, et al. Visual Outcomes After Descemet Membrane Endothelial Keratoplasty Versus Descemet Stripping Automated Endothelial Keratoplasty-Comparison of Specific Matched Pairs. *Cornea* 2016;35:765-771
11. Mashor RS, Kaiserman I, Kumar NL, et al. Deep Lamellar Endothelial Keratoplasty. Up to 5-year follow-up. *Ophthalmology* 2010; 117:680-686
12. Pouyeh B, Feuer W, Yoo SH, et al. Refractive stability after phaco-DSAEK. *Ophthalmology* 2012;119:2190
13. Lie JT, Birbal R, Ham L, et al. Donor tissue preparation for Descemet membrane endothelial keratoplasty. *J Cataract Refract Surg* 2008;34:1578-1583
14. Dapena I, Moutsouris K, Droutsas K, et al. Standardized 'no touch' technique for Descemet membrane endothelial keratoplasty (DMEK). *Arch Ophthalmol* 2011;129:88-94
15. Kopplin LJ, Przepyszny K, Schmotzer B, et al; Fuchs' Endothelial Corneal Dystrophy Genetics Multi-Center Study Group. Relationship of Fuchs endothelial corneal dystrophy severity to central corneal thickness. *Arch Ophthalmol* 2012;130:433-439
16. Oculus Optikgeräte GmbH (2005): Oculus Pentacam Instruction Manual. Measurement and evaluation system for the anterior segment of the eye. Oculus Optikgeräte GmbH, Münchholzhäuser Str. 29, 35582 Wetzlar, Germany
17. McLaren JW, Wacker K, Kane KM, et al. Measuring Corneal Haze by Using Scheimpflug Photography and Confocal Microscopy. *Invest Ophthalmol Vis Sci* 2016;57:227-235
18. Benjamini Y, Hochberg Y. Controlling the false discovery rate: A practical and powerful approach to multiple testing. *J Royal Stat Soc Series B Stat Methodol* 1995;57:289-300

19. Maier AK, Gundlach E, Gonnermann J, et al. Retrospective contralateral study comparing Descemet membrane endothelial keratoplasty with Descemet stripping automated endothelial keratoplasty. *Eye (Lond)* 2015;29:327-332
20. Parker J, Dirisamer M, Naveiras M, et al. Outcomes of Descemet membrane endothelial keratoplasty in phakic eyes. *J Cataract Refract Surg* 2012;38:871-877
21. Kwon RO, Price MO, Price FW Jr, et al. Pentacam characterization of corneas with Fuchs dystrophy treated with Descemet membrane endothelial keratoplasty. *J Refract Surg* 2010;26:972-979
22. Alnawaiseh M, Rosentreter A, Eter N, et al. Changes in corneal refractive power for patients with Fuchs endothelial dystrophy after DMEK. *Cornea* 2016;35:1073-1077
23. Wacker K, McLaren JW, Patel SV. Directional posterior corneal profile changes in Fuchs' endothelial corneal dystrophy. *Invest Ophthalmol Vis Sci* 2015;56:5904-5911
24. Shimizu T, Yamaguchi T, Satake Y, et al. Topographic hot spot before Descemet stripping automated endothelial keratoplasty is associated with postoperative hyperopic shift. *Cornea* 2015;34:257-263
25. Meek KM, Dennis S, Khan S. Changes in the refractive index of the stroma and its extrafibrillar matrix when the cornea swells. *Biophys J* 2003;85:2205-2212
26. Meek KM, Knupp C. Corneal structure and transparency. *Prog Retin Eye Res* 2015;49:1-16
27. van Dijk K, Parker J, Liarakos VS, et al. Incidence of irregular astigmatism eligible for contact lens fitting after Descemet membrane endothelial keratoplasty. *J Cataract Refract Surg* 2013;39:1036-1046
28. Dirisamer M, Dapena I, Ham L, et al. Patterns of corneal endothelialization and corneal clearance after Descemet membrane endothelial keratoplasty for Fuchs endothelial dystrophy. *Am J Ophthalmol* 2011;152:543-555
29. Lam FC, Baydoun L, Dirisamer M, et al. Hemi-Descemet membrane endothelial keratoplasty transplantation: a potential method for increasing the pool of endothelial graft tissue. *JAMA Ophthalmol* 2014;132:1469-1473
30. Hashemi H, Asgari S, Emamian MH, et al. Age-related changes in corneal curvature and shape: The Shahroud Eye Cohort Study. *Cornea* 2015;34:1456-1458
31. De Bernardo M, Capasso L, Caliendo L, et al. IOL power calculation after corneal refractive surgery. *Biomed Res Int* 2014;2014:658350
32. Cohen J. A power primer. *Psychol Bull* 1992;112:155-159

