



Universiteit  
Leiden

The Netherlands

## **Inflammation in injury-induced vascular remodelling : functional involvement and therapeutical options**

Schepers, A.

### **Citation**


Schepers, A. (2008, April 9). *Inflammation in injury-induced vascular remodelling : functional involvement and therapeutical options*. TNO Quality of Life, Gaubius Laboratory, Faculty of Medicine / Leiden University Medical Center (LUMC), Leiden University. Retrieved from <https://hdl.handle.net/1887/12687>

Version: Corrected Publisher's Version

License: [Licence agreement concerning inclusion of doctoral thesis in the Institutional Repository of the University of Leiden](#)

Downloaded from: <https://hdl.handle.net/1887/12687>

**Note:** To cite this publication please use the final published version (if applicable).



# CHAPTER 4

Short-term dexamethasone treatment inhibits  
vein graft thickening in hypercholesterolemic  
ApoE3Leiden transgenic mice.

A. Schepers MD<sup>1,2</sup>, N.M.M. Pires MSc<sup>1,3</sup>, D. Eefting MD<sup>1,2</sup>, M.R. de Vries BSc<sup>1</sup>, J.H. van Bockel MD, PhD<sup>2</sup>, P.H.A. Quax PhD<sup>1,2</sup>

<sup>1</sup>Gaubius Laboratory TNO Quality of Life, Leiden, The Netherlands, <sup>2</sup>Dept. of Vascular Surgery and <sup>3</sup>Dept. of Cardiology, Leiden University Medical Center, Leiden, The Netherlands,

**Journal of Vascular Surgery 2006; 43: 809-815**

## ABSTRACT

---

**Objective:** The aim of this study was to assess whether the anti-inflammatory agent dexamethasone can inhibit vein graft thickening without the occurrence of serious side effects.

**Methods:** Venous interposition grafting was performed in the common carotid artery of hypercholesterolemic ApoE3Leiden transgenic mice. Mice were treated with dexamethasone (0.15 mg/kg/day orally) and after 28 days vein graft thickening was quantified.

**Results:** Treatment with dexamethasone resulted in a significant 43% reduction in lesion area without changes in lesion composition, when compared to nontreated controls. However, dexamethasone, when administered for a prolonged period of time, is known for its potential serious side-effects. To overcome these potential side-effects of prolonged dexamethasone treatment the effect of a short-term 7 days dexamethasone treatment was studied. This short dexamethasone treatment resulted in a 49% decrease of vein graft thickening at 28 days. Furthermore, it was demonstrated that dexamethasone treatment led to reduced local expression of several proinflammatory cytokines and factors in the vein grafts 24 hours after surgery. Finally, observations in mice were verified in human saphenous organ cultures. Exposure to dexamethasone for either 7 days or 28 days significantly reduced intimal hyperplasia formation on cultured saphenous vein segments.

**Conclusion:** Short-term anti-inflammatory treatment with dexamethasone leads to a significant reduction in vein graft thickening over an extended period, possibly by the reduction of early expression of proinflammatory cytokines. This 7-day treatment minimizes the risk of unwanted side-effects of long-term dexamethasone treatment and may be a new approach in order to prevent graft failure.

## INTRODUCTION

---

Venous bypass grafting is the most common treatment to bypass an atherosclerotic obstruction of an artery. After grafting, a remodeling process is initiated in these veins as a consequence of the increased blood pressure and shear stress, but also by vessel injury due to surgery. This process results in the formation of intimal hyperplasia (IH) and accelerated atherosclerosis which may lead to obstruction of the graft. This process is also known as vein graft disease<sup>1,2</sup>. Vein graft disease is the major cause of late graft failure, with failure rates of 10 to 40% after 1 year and 50 to 60% after 10 years<sup>3</sup>.

It has been well established that other forms of vascular remodeling- for instance atherosclerosis and post-angioplasty neointima formation- are inflammation-mediated processes<sup>4</sup>. However, the role of inflammation in vein graft disease is largely unknown. Morphological analysis shows that IH in a vein graft consists mainly of smooth muscle cells (SMC), macrophages and other inflammatory cells, such as T-cells. The important role of inflammatory mediators in both restenosis and atherosclerosis and the presence of inflammatory cells in vein grafts argue for a role of inflammation in vein graft disease.

Dexamethasone is known for its anti-inflammatory and antiproliferative properties and frequently used for the experimental treatment of atherosclerosis and restenosis<sup>5-9</sup>. Recently, clinical trials have been initiated to investigate the effect of dexamethasone in in-stent restenosis<sup>10-13</sup>.

Concerning vein graft disease, the effect of dexamethasone treatment on vein graft thickening of the vein graft is largely unknown and to our knowledge has only been studied once<sup>14</sup>. In this article the effects of dexamethasone on vein graft thickening are described. Because long-term dexamethasone treatment is accompanied by serious side effects (eg skin dystrophy, muscle atrophy, and impaired stress response), and because of its aggravating effect on spontaneous atherosclerosis development, we studied whether short-term 7 days-treatment with dexamethasone could be as efficient as continuous treatment in preventing vein graft thickening in a murine model for vein graft disease. To validate clinical relevance of the murine data, experiments were repeated in clinically relevant tissue: human saphenous vein organ cultures. In these organ cultures, the effect of both 7 days and 28 days of exposure to dexamethasone on IH formation was assessed.

## MATERIALS AND METHODS

---

### Mice.

All animal experiments were approved by the TNO animal welfare committee. For all experiments male ApoE3Leiden<sup>15</sup> mice on a C57/BL6 background, aged between 14 and 20 weeks, were used. Animals were fed a cholesterol-enriched high-fat diet (1% cholesterol, 0.05% cholate, Arie Blok, Woerden, The Netherlands) starting 3

weeks before the beginning of each experiment. All mice received water and food ad libitum. Serum cholesterol levels were determined 1 week before the start of the experiment and at death. Before surgery, mice were anesthetized with Midazolam (5 mg/kg, Roche, Basel, Switzerland), Medetomidine (0.5 mg/kg, Orion, Helsinki, Finland), and Fentanyl (0.05 mg/kg, Janssen, Geel, Belgium).

#### **Dexamethasone treatment.**

For all experiments, mice were randomly divided in two groups. One group received approximately 0.15mg/kg/day dexamethasone dissolved in the drinking water (based on a daily water intake of 3 ml per mouse) throughout the entire experiment, starting one day before the start of each experiment.

#### **Carotid vein graft model.**

Mice were either treated with dexamethasone or received no treatment and served as controls (n=6 in both groups). A venous interposition in the carotid artery was placed in each mouse as described previously<sup>16</sup>. In brief, the right common carotid artery of the recipient was dissected free from its surroundings from the bifurcation at the distal end towards the proximal end. The artery was cut in the middle and ligated with an 8.0 silk suture. The caval veins were harvested from genetically identical donor mice and grafted between the 2 ends of the carotid artery by sleeving the ends of the vein over the artery cuff and ligating them together with an 8.0 silk suture. At death, animals were perfused in vivo with 4% formaldehyde for 5 minutes. Vein grafts were harvested and fixed overnight in 4% formaldehyde, dehydrated, and embedded in paraffin.

#### **Quantification of vein graft thickening and immunohistochemistry.**

Twenty-eight days after surgery, mice were sacrificed as described above, and vein grafts were harvested and embedded in paraffin. Serial cross-sections of the embedded vein graft were made through the entire specimen and routinely stained with hematoxylin-phloxin-saffron (HPS). Using serial cross-sections for the analysis, overestimation or underestimation of treatment effect due to a non-equally distributed occurrence of vein graft thickening (as we see both in human vein grafts as in our murine vein graft interpositions) is prevented.

Measurement of vein graft thickening in the samples was performed using image analysis software (Qwin, Leica, Wetzlar, Germany). Because only very few layers of cells are in the media of murine veins and because there is no morphological border between the neointima and media, vein graft thickening, ie, the region between the lumen and adventitia, was used to define the lesion area. For each mouse five equally spaced perpendicular cross-sections were used to determine the vessel wall thickening.

All immunohistochemistry was performed on paraffin-embedded sections of vein grafts 28 days after surgery. The cellular composition of the thickened vein grafts was visualized by using antibodies against macrophages (AIA31240, Accurate Chemical, Westbury, USA), T-cells (CD3, Serotec, Oxford, UK) and vascular SMC ( $\alpha$ -smooth muscle actin, Amersham, Buckinghamshire, UK). The amount of SMC and

macrophages was quantified by computed-assisted morphometric analysis (Qwin), and expressed as the percentage of total smooth muscle actin-positive or AIA-positive area in cross-sections. T-cell number was determined by counting CD3-positive cells in the vessel wall of 6 equally spaced cross-sections per vein graft and divided by vessel wall surface in these cross-sections.

### **Prolonged dexamethasone exposure and analysis of general well-being and atherosclerosis.**

Side-effects of prolonged Dexamethasone treatment, including spontaneous atherosclerosis, were studied in mice (n=15) that received dexamethasone treatment 0.15 mg/kg/day for 25 weeks. A group of littermates (n=15) not exposed to dexamethasone served as control. Mice were extensively observed with regards to daily activity, fur quality, and infections. All mice were sacrificed after 25 weeks as described above. The aortic root and the heart were collected for histological analysis, as these locations were previously identified as atherosclerotic-prone regions<sup>17</sup>.

The hearts were dissected, stored overnight in phosphate-buffered 3.8% formalin fixation and embedded in paraffin. Serial cross sections (5µm thick) throughout the entire aortic valve area were used for histological analysis. Sections were routinely stained with HPS. Per mouse, 4 sections with 30 µm intervals were used for quantification of atherosclerotic lesion area. Lesion area was determined using morphometric software (Qwin).

### **Human saphenous vein (HSV) organ culture.**

Segments of saphenous veins, obtained from patients undergoing saphenous vein stripping, (provided by Dr. H. Stigter, Deaconess Hospital, Leiden, The Netherlands) were used for these cultures. Healthy looking segments of the stripped veins were put into culture as previously described<sup>18,19</sup>. Segments (n=4 per group) were exposed to dexamethasone (0.75 mg/ml medium) for either 7 or 28 days, or served as controls. After 28 days, segments were harvested, fixed overnight in formaldehyde (4%) and embedded in paraffin. All segments were routinely stained by HPS and neointimal surface was assessed on multiple sections (n=9 per vein segment) and quantified using Qwin Image analysis software.

### **Messenger RNA isolation, cDNA synthesis and real time RT-PCR.**

To obtain vein grafts for Messenger RNA isolation (mRNA) isolation, mice (n=4 per group) were either treated with dexamethasone or received no treatment and were sacrificed one day after vein graft surgery. At sacrifice, mice were perfused with NaCl 0.9%, after which the vein grafts were harvested and snap-frozen. Total RNA was isolated using the RNeasy Mini Kit for Fibrous tissue (Qiagen, Venlo, The Netherlands) and DNA contamination was excluded with an on-column DNase treatment (Qiagen). Synthesis of cDNA was performed by using 250 ng mRNA and Ready-To-Go Beads (Amersham Biosciences) according to the manufacturer's protocol.

Intron-spanning primer-probe sets were designed using Primer Express™ 1.5 software (Applied Biosystems, Foster City, USA) for MCP-1, MIP-1 $\alpha$ , TNF- $\alpha$ , CD14 and TLR-4 (for sequences, Table 4.1). GAPDH was used as a housekeeping gene. The PCR reaction was performed using qPCR Mastermix (Eurogentec, Seraing, Belgium). Analysis of mRNA expression by real time RT-PCR was performed on an ABI Prism™ 7700 sequence detection system (Perkin Elmer Biosystems, Boston, USA).

For analysis, cycle threshold of the gene of interest was subtracted from the cycle threshold of the housekeeping gene GAPDH ( $\Delta$ Ct).  $\Delta\Delta$ Ct was determined as the difference between  $\Delta$ Ct-values of the Dexamethasone-treated vein grafts and the normalized  $\Delta$ Ct-value of vein grafts in the control group (being the average of  $\Delta$ Ct-values in the control group). Data are presented as relative expression of all genes in the Dexamethasone-treated group calculated as  $1/(2^{-\Delta\Delta Ct})$ . In this presentation, mRNA expression of all genes in the control group is defined as 1.

### Statistical analysis.

Before the start of each experiment a power analysis was made to obtain a statistically sound study. Data are presented as mean  $\pm$  SEM. Comparisons of morphometric data of murine vein grafts and RT-PCR data were performed with the Mann-Whitney rank sum test. Morphometric data of IH in human saphenous veins were compared with a paired Student T-test. P-values  $<.05$  were considered statistical significant.

## RESULTS

---

### Continuous dexamethasone treatment inhibits vein graft thickening in a murine vein graft model.

The effect of dexamethasone on vein graft thickening was studied in ApoE3Leiden mice. Six mice received dexamethasone (0.15mg/kg/day) during the complete experimental period, starting 1 day before surgery and six mice served as controls. Mice were sacrificed after 28 days. Preoperative plasma cholesterol levels did not differ between the Dexamethasone and control group. However a modest, yet not significant increase in plasma cholesterol was seen in the dexamethasone-treated group at time of sacrifice (dexamethasone: before surgery  $13.8\pm 1.26$ mmol/L, at sacrifice  $15.4\pm 1.28$ mmol/L vs control: before surgery  $12.7\pm 1.08$ mmol/L, at sacrifice  $12.7\pm 3.2$ mmol/L). During the experiment four out of six mice receiving dexamethasone treatment did not gain weight, compared to one out of six in the control group. In the dexamethasone-treated group, thrombosis occurred in one vein graft and this vein graft was excluded from analysis.

Quantification of vein graft thickening showed a 43% reduction in the dexamethasone-treated group, compared with the control group ( $0.32\pm 0.04$ mm<sup>2</sup> vs  $0.56\pm 0.12$ mm<sup>2</sup>; P=.028; Figure 4.1, panel A+B). Luminal area did not differ between the two treatment groups (dexamethasone  $0.78\pm 0.1$ mm<sup>2</sup>, control  $0.75\pm 0.08$ mm<sup>2</sup>, P=.75). The cellular composition of the thickened graft was not significantly different between the two groups, as analyzed by immunohistochemistry. The thickened



vein grafts were mainly composed of SMCs and macrophages. Furthermore, small numbers of T-cells were present in the vessel wall. The AIA-positive area, reflecting macrophages, was  $20.8 \pm 3.5\%$  in the control group, compared to  $22.7 \pm 3.3\%$  in the dexamethasone-treated group (Figure 4.1, panel D). The  $\alpha$ -SM-actin positive area, reflecting vascular SMCs, was  $39.3 \pm 7.2\%$  in the control group as compared to  $40.6 \pm 4.2\%$  in the treated group (Figure 4.1, panel C). Also, the number of T-cells did not differ significantly between the groups (control:  $6.20 \pm 0.68$  cells/mm<sup>2</sup>; dexamethasone:  $5.79 \pm 1.77$  cells/mm<sup>2</sup>).

### **Prolonged dexamethasone treatment is accompanied by clinical side effects and increase spontaneous atherosclerosis in mice.**

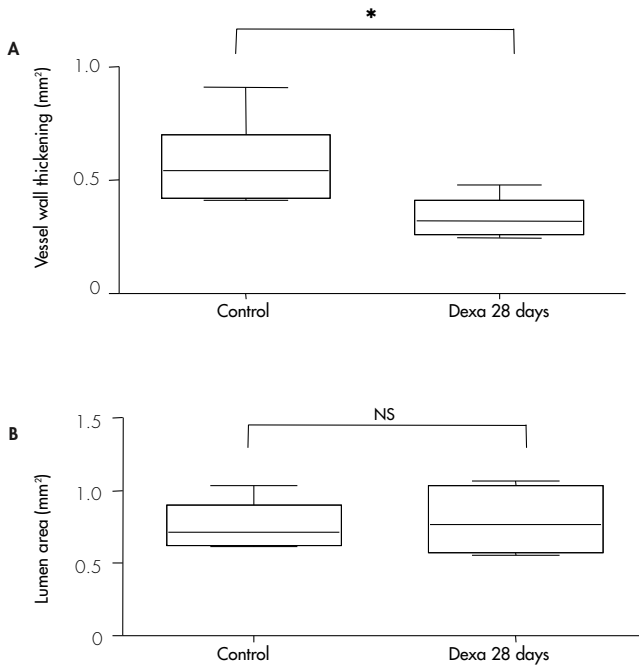
To study whether the slight increase in serum cholesterol and failure to gain weight in the dexamethasone-treated animals above, can be addressed as the start of adverse effects of dexamethasone, we next evaluated the effect of long-term exposure to dexamethasone in mice.

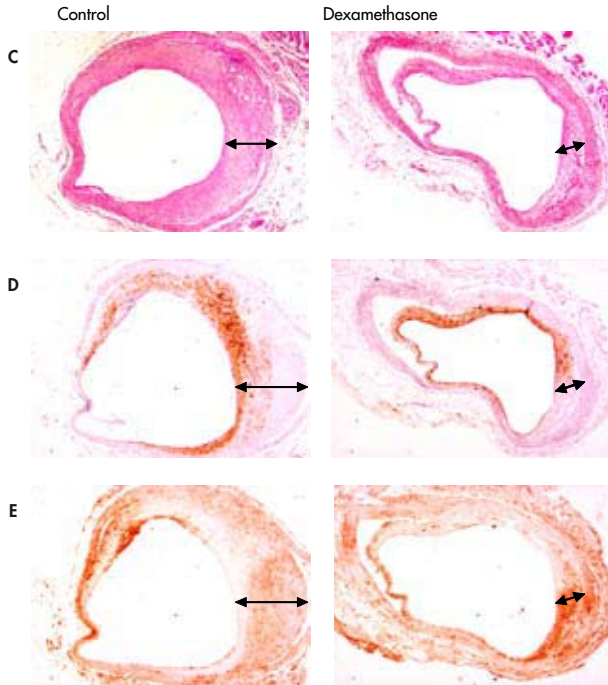
Therefore, ApoE3Leiden mice receiving a cholesterol-enriched diet were randomly divided in two groups. One group (n=15) was treated for 25 weeks with dexamethasone. During the course of this 25 weeks period, animals in the dexamethasone-treated group progressively showed several side-effects of the use of dexamethasone. Four mice revealed signs of infection and were terminated. Animals treated with dexamethasone gained less weight, leading to differences in body weight at time of sacrifice ( $25.3 \pm 1.9$ g vs  $30.6 \pm 2.8$ g,  $P < .001$ ). Serum cholesterol levels increased significantly in the dexamethasone-treated animals ( $33.7 \pm 7.4$ mmol/l), compared to the control group ( $15.0 \pm 3.3$ mmol/l,  $P < .001$ ). Furthermore, dexamethasone-treated animals expressed reduced daily activity and had impaired fur quality. Moreover, dexamethasone treatment resulted in a 4.7-fold increase in atherosclerotic plaque area in the aortic root (dexamethasone treated  $0.461 \pm 0.199$ mm<sup>2</sup>; control  $0.098 \pm 0.047$ mm<sup>2</sup>,  $P < .001$ ).

### **Short-term 7 day treatment with dexamethasone reduces vein graft thickening.**

Because long-term treatment with dexamethasone is accompanied by serious side-effects, the effect of short-term dexamethasone treatment on vein graft thickening was assessed. Six ApoE3Leiden mice underwent vein graft surgery and were treated for 1 week with dexamethasone, after which dexamethasone was withdrawn and mice were allowed to drink normal drinking water. The control group consisted of mice that underwent vein graft surgery and were not exposed to dexamethasone. After 4 weeks vessel wall thickness was determined. No difference was seen in plasma cholesterol levels and animal weight before to surgery and at time of sacrifice (data not shown). A reduction of vein graft thickening was seen in the vein grafts of the dexamethasone-treated mice ( $0.25 \pm 0.07$ mm<sup>2</sup>): there was a decrease of 49% when compared with the control group ( $0.62 \pm 0.11$ mm<sup>2</sup>,  $P = .04$ ; Figure 4.2). Luminal area did not differ significantly in both groups (Dexamethasone:  $0.67 \pm 0.09$ mm<sup>2</sup>, control  $0.75 \pm 0.08$ mm<sup>2</sup>,  $P = .75$ ). Furthermore, the lesions of 7 days-treated animals showed a similar morphology as those of the group treated for 28 days with dexamethasone.

**Figure 4.1:** *Dexamethasone treatment (0.15mg/kg/day in drinking water) reduces vein graft thickening in hypercholesterolemic ApoE3-Leiden mice after 28 days of treatment. Panel A: Quantification of vein graft thickening shows a reduction of 43% in the dexamethasone-treated animals, as compared to controls (n=6, \* represents P<.05), whereas no significant changes in luminal area were observed (Panel B). Panel C: Representative cross-section, arrows indicate thickened vessel wall (HPS staining, magnification 40x). No differences are seen in the cellular composition of thickened grafts in both groups, as determined by computer-assisted morphometric analysis. Panel D:  $\alpha$ -SM-actin staining representing vascular SMC. Panel E: AIA31240 staining representing macrophages.*



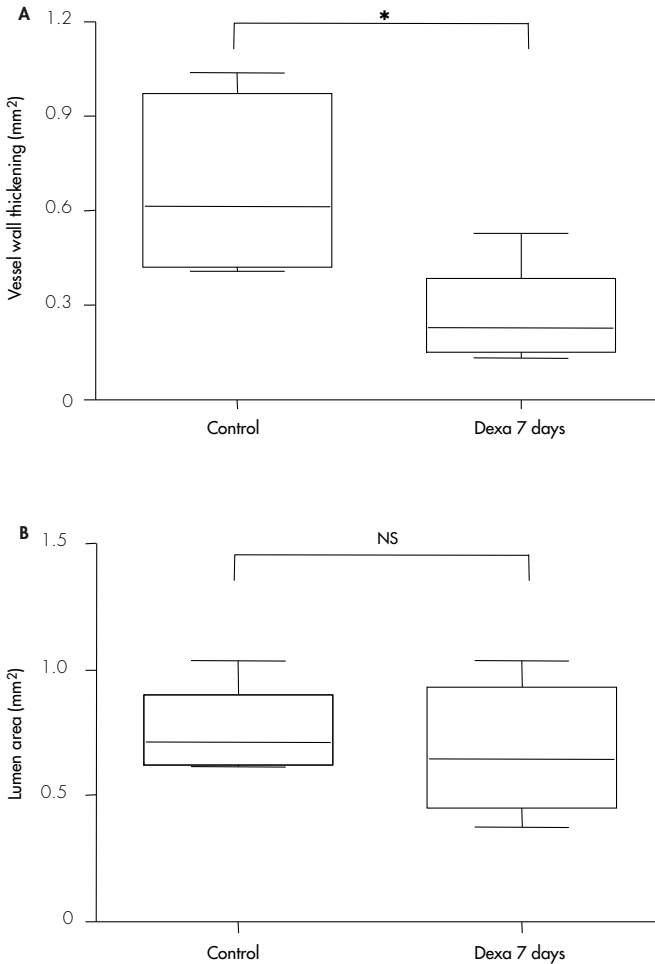


### **Effect of Dexamethasone on early expression of pro-atherogenic cytokines.**

Because short-term dexamethasone treatment results in reduced graft thickening on the long term, we hypothesized that dexamethasone might reduce early expression of proinflammatory cytokines in the remodeling vein grafts and thereby hampers the initiation of the remodeling process in the vein grafts. To study this hypothesis, mRNA analysis of both dexamethasone-treated and control vein grafts was performed.

The effect of dexamethasone treatment on the early expression of several proinflammatory cytokines and inflammatory markers was studied in vein grafts, either dexamethasone-treated and control, harvested 24 hours after surgery. This time frame was chosen since previous data show that cytokines are rapidly upregulated in time (being hours after surgery; data not shown). The cytokines and inflammatory markers used in this experiment were selected on their involvement in the process of atherosclerosis or restenosis<sup>20-25</sup>.

**Figure 4.2:** Effect of 7 days dexamethasone treatment on vein graft thickening 28 days after surgery in hypercholesterolemic ApoE3-Leiden mice. Significant inhibition of vein graft thickening in the 7 days-treated animals (Panel A), when compared to controls (n=6, \* represents  $P<.05$ ). No significant difference in luminal area between the two groups (Panel B, n.s. represents not significant).



The proinflammatory cytokines TNF- $\alpha$  and MIP-1 $\alpha$  were significantly downregulated in vein grafts of dexamethasone-treated animals when compared to control vein grafts. The relative expression of TNF- $\alpha$ : in the dexamethasone group was  $0.15\pm0.07$  ( $P=.021$ ), that of MIP-1 $\alpha$   $0.12\pm0.06$  ( $P=.029$ ). Another potent pro-atherogenic cytokine, MCP-1, showed a modest, yet not significant, down-regulation in the dexamethasone-treated vein grafts, with a relative expression of  $0.32\pm0.06$  ( $P=.25$ ). Dexamethasone treatment also resulted in decreased expression of TLR-4

(relative expression  $0.036\pm 0.05$ ;  $P=0.21$ ) and its cofactor CD14 (relative expression  $0.26\pm 0.08$ ;  $P=0.43$ ; Figure 4.3).

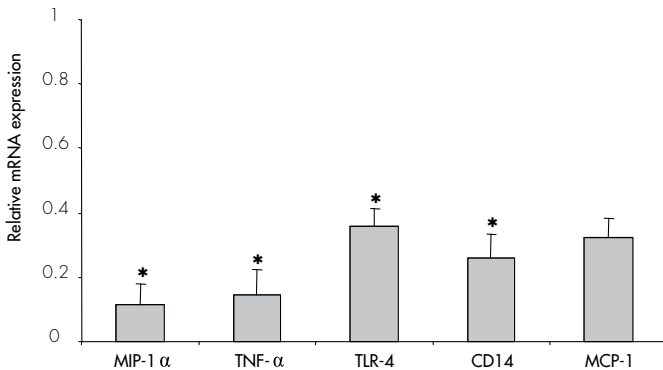
### Effect of both continuous and short-term dexamethasone exposure on IH formation in human saphenous vein cultures.

To determine whether the murine in vivo vein graft model reacts in a similar way on stimuli as clinically relevant human tissue, we used human saphenous vein organ cultures to study the effects of dexamethasone exposure on the development of IH.

Human saphenous vein organ cultures were exposed for either 7 or 28 days to dexamethasone in the medium ( $0.75\text{mg/ml}$ ) and compared them with untreated control segments.

Both 7 days as 28 days of exposure to dexamethasone resulted in a marked reduction of IH formation (Figure 4.4). In the untreated control veins IH surface was  $0.059\pm 0.006\text{mm}^2$ , whereas in the segments that underwent 28 days exposure to dexamethasone, IH was  $0.014\pm 0.002\text{mm}^2$  ( $P=0.006$ ). Short-term treatment by 7 days exposure to dexamethasone, resulted in lowered IH formation of  $0.018\pm 0.002\text{mm}^2$  ( $P=0.021$  when compared to untreated vessels,  $p=0.19$  when compared to 28 days treated vessels).

**Figure 4.3:** Effect of dexamethasone treatment on the early mRNA expression of pro-inflammatory cytokines in injured vessels of ApoE3-Leiden mice ( $n=4$  per group). Relative mRNA expression in time in the dexamethasone-treated group is depicted compared to mRNA expression the control group (expression in control group defined as "1", \* represents  $P<0.05$ ).



## DISCUSSION

This study shows that short-term anti-inflammatory therapy using dexamethasone inhibits vein graft thickening in venous bypass grafts over an extended period of time. It is well appreciated that atherosclerosis and other forms of vascular remodeling, such

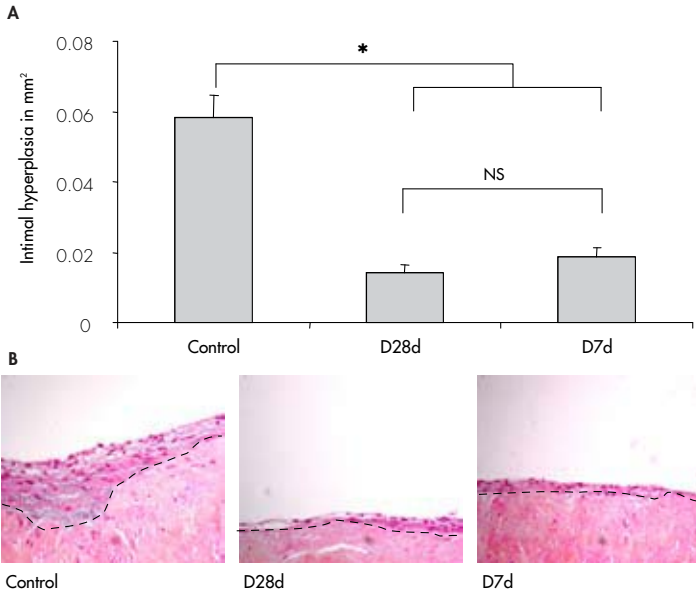
as postangioplasty neointimal formation and vein graft disease are inflammatory-mediated processes. Extending this observation to the clinical situation, it is obvious that some of the commonly used anti-inflammatory agents would deserve further investigation in this respect. One of the most widely used anti-inflammatory agents is the group of corticosteroids, commonly used for several diseases like rheumatoid arthritis, inflammatory bowel disease, organ transplantation and chronic obstructive pulmonary disease.

Several pre-clinical studies describe the effect of corticosteroids on postangioplasty restenosis. The effect of dexamethasone has often been studied in various *in vitro* and animal models for postinterventional neointima formation<sup>5,7,9,26,27</sup>. Most animal studies show a decrease in neointimal formation in the dexamethasone-treated group. Even though it is well known that corticosteroid therapy is associated with several side-effects, these findings led to the initiation of several clinical studies to assess the beneficial effect of corticosteroid therapy on the development of in-stent restenosis; most of them are still ongoing. Two studies have been recently published that describe the effect of dexamethasone-eluting stents. Liu et al. showed that implantation of a dexamethasone-coated stent is safe and feasible<sup>12</sup>. Recently another clinical study was published. Hoffmann et al. did not observe any beneficial effects of the dexamethasone-coated stent on the development of restenosis<sup>10</sup>. Two other studies have been published about the effect of oral corticosteroid treatment on the development of in stent restenosis with conflicting results. Versaci et al. report a striking decrease in restenosis rate in patients with persistently high CRP levels when treated with oral immunosuppressive therapy with prednisone<sup>13</sup>. The article of Lee et al. did not describe any beneficial effect on restenosis rate when patients were pre-treated with a single dose methylprednisolone<sup>11</sup>.

Whereas the effect of corticosteroids on post-angioplasty neointimal formation is being thoroughly studied, the effect of corticosteroids on vein graft thickening is unknown. To our knowledge only one study describes a beneficial effect of dexamethasone treatment on vein graft thickening in rats<sup>14</sup>. However, this is not a hypercholesterolemic model and the thickened graft consisted mainly of SMCs, whereas in patients graft lesions consist of SMCs, macrophages and T-cells. In the study described in this article, we used hyperlipidemic ApoE3Leiden mice in a model of vein graft disease that highly resembles the morphology of human restenotic vein grafts.

In this model, we demonstrate that continuous treatment with dexamethasone for 28 days causes a significant reduction in vein graft thickening, without altering the cellular composition of the thickened vessel wall. An outward remodeling was seen in these vein grafts, which could be attributed to the fact that the vessel wall of the graft is initially very thin, and consists just a few cell layers. Hyperplasia results in vessel wall thickening, which will principally be outwards directed.

**Figure 4.4:** Effect of either short-term (D7d) or prolonged (D28d) dexamethasone exposure (0.75mg/ml medium) in IH formation in human saphenous vein organ cultures (n=12 per group). In both dexamethasone exposed groups a significantly lowered amount of IH was seen, when compared to the control segments (\* represents  $P < .05$ , magnification 100x, dotted line indicates border separating media from intima).



However, prolonged dexamethasone treatment is known to be accompanied by serious side effects, like an impaired immune response, osteoporosis and an increased risk of atherosclerotic events (probably due to dyslipidemia)<sup>28,29</sup> in humans. Moreover, although in the 28-day period of the vein graft experiment an effective inhibition of vein graft thickening was observed, the first signs of negative side-effects were detectable in the treated mice: these were failure to gain weight and slightly increased plasma cholesterol levels.

To prove that the occurrence of these clinical features was caused by dexamethasone treatment, we included an experiment in which ApoE3Leiden mice were treated with the same dose of dexamethasone as in the vein graft experiments, but for a prolonged period of time. The response of the animals to dexamethasone treatment highly mimicked what is seen in patients: an impaired well-being, infections and, most strikingly, increased atherosclerosis in the aortic root was observed.

To analyze whether the potential problem of unwanted side effects can be avoided, we tested whether a short treatment with dexamethasone (7 days) directly after surgery was as effective as a continuous treatment. A 49% reduction in vein graft thickening after a 7-day treatment with dexamethasone was observed that was comparable

to the reduction after a 28 days treatment. These data indicate that short-term dexamethasone treatment directly after surgery has the same potential to reduce graft thickening as a prolonged treatment.

This information is of great importance for eventual clinical application, since limiting duration of dexamethasone treatment may avoid potential side effects.

To gain further insight in the mechanism of how short-term dexamethasone treatment can result in a long-time reduction of vein graft thickening, we studied the hypothesis that dexamethasone hampers vein graft thickening by inhibiting early proinflammatory cytokine expression. Indeed, significant reduction mRNA expression of several proinflammatory cytokines could be detected in the dexamethasone-treated vein grafts.

Despite of a reduction in expression of proinflammatory cytokines, dexamethasone treatment did not result in a decreased macrophage content in the thickened grafts. This is in contrast with previous reports of Asai et al.<sup>5</sup>, who describes a reduction in macrophage content in atherosclerotic tissue of cholesterol-fed rabbits. A possible explanation for this difference might be the fact that dexamethasone also reduces SMC proliferation<sup>30</sup>, and thereby keeps the balance between macrophages and SMCs in the vein graft unchanged.

As a final experiment and to study whether our findings in mice can be extrapolated to human tissue, we repeated the experiments in human saphenous vein organ cultures. Like the short-term dexamethasone treatment in murine vein grafts, IH formation was hampered in the vessel segments that were exposed to dexamethasone for 7 days. The fact that in the saphenous vein organ cultures IH is mainly a SMC proliferation-driven process underscores the effect of dexamethasone on SMCs proliferation as discussed above.

In conclusion, this study demonstrated that short-term dexamethasone treatment leads to a reduction of lesion area both in vein grafts in mice and in human saphenous organ cultures, thereby minimizing the risk of unwanted systemic side-effects that occur in prolonged dexamethasone treatment. Therefore, this approach might be suitable for further exploration in patients to reduce the risk of vein graft stenosis due to IH and accelerated atherosclerosis. However, as we learned from previous clinical trials for postinterventional restenosis, more research is necessary to obtain more insight about the optimal dose and treatment period.



## REFERENCES

---

1. Motwani JG, Topol EJ. Aortocoronary saphenous vein graft disease: pathogenesis, predisposition, and prevention. *Circulation* 1998; 97(9):916-931.
2. Bourassa MG, Campeau L, Lesperance J, Grondin CM. Changes in grafts and coronary arteries after saphenous vein aortocoronary bypass surgery: results at repeat angiography. *Circulation* 1982; 65(7 Pt 2):90-97.
3. Bush HL, Jr., Jakubowski JA, Curl GR, Deykin D, Nabeth DC. The natural history of endothelial structure and function in arterialized vein grafts. *J Vasc Surg* 1986; 3(2):204-215.
4. Ross R. Atherosclerosis--an inflammatory disease. *N Engl J Med* 1999; 340(2):115-126.
5. Asai K, Funaki C, Hayashi T, Yamada K, Naito M, Kuzuya M *et al.* Dexamethasone-induced suppression of aortic atherosclerosis in cholesterol-fed rabbits. Possible mechanisms. *Arterioscler Thromb* 1993; 13(6):892-899.
6. Petrik PV, Law MM, Moore WS, Colburn MD, Quinones-Baldrich W, Gelabert HA. Dexamethasone and enalapril suppress intimal hyperplasia individually but have no synergistic effect. *Ann Vasc Surg* 1998; 12(3):216-220.
7. Poon M, Gertz SD, Fallon JT, Wiegman P, Berman JW, Sarembock IJ *et al.* Dexamethasone inhibits macrophage accumulation after balloon arterial injury in cholesterol fed rabbits. *Atherosclerosis* 2001 Apr; 155(2):371-80 155(2):371-380.
8. Van Put DJ, Van Hove CE, De Meyer GR, Wuyts F, Herman AG, Bult H. Dexamethasone influences intimal thickening and vascular reactivity in the rabbit collared carotid artery. *Eur J Pharmacol* 1995; 294(2-3):753-761.
9. Villa AE, Guzman LA, Chen W, Golomb G, Levy RJ, Topol EJ. Local delivery of dexamethasone for prevention of neointimal proliferation in a rat model of balloon angioplasty. *J Clin Invest* 1994; 93(3):1243-1249.
10. Hoffmann R, Langenberg R, Radke P, Franke A, Blindt R, Ortlepp J *et al.* Evaluation of a high-dose dexamethasone-cluting stent. *Am J Cardiol* 2004; 94(2):193-195.
11. Lee CW, Chae JK, Lim HY, Hong MK, Kim JJ, Park SW *et al.* Prospective randomized trial of corticosteroids for the prevention of restenosis after intracoronary stent implantation. *Am Heart J* 1999; 138(1 Pt 1):60-63.
12. Liu X, Huang Y, Hanet C, Vandormael M, Legrand V, Dens J *et al.* Study of antirestenosis with the BiodivYsio dexamethasone-cluting stent (STRIDE): a first-in-human multicenter pilot trial. *Catheter Cardiovasc Interv* 2003; 60(2):172-178.
13. Versaci F, Gasparone A, Tomai F, Ribichini F, Russo P, Proietti I *et al.* Immunosuppressive Therapy for the Prevention of Restenosis after Coronary Artery Stent Implantation (IMPRESS Study). *J Am Coll Cardiol* 2002; 40(11):1935-1942.
14. Norman PE, House AK. Influence of dexamethasone on intimal thickening in experimental vein graft. *Cardiovasc Surg* 1993; 1(6):724-728.
15. van den Maagdenberg AM, Hofker MH, Krimpenfort PJ, de B, I, van Vlijmen B, van der BH *et al.* Transgenic mice carrying the apolipoprotein E3-Leiden gene exhibit hyperlipoproteinemia. *J Biol Chem* 1993; 268(14):10540-10545.
16. Lardenoye JH, de Vries MR, Grimbergen JM, Havekes LM, Knaapen MW, Kockx MM *et al.* Inhibition of accelerated atherosclerosis in vein grafts by placement of external stent in ApoE3Leiden transgenic mice. *Arterioscler Thromb Vasc Biol* 2002; 22(9):1433-1438.
17. Gijbels MJ, van der CM, van der Laan LJ, Emeis JJ, Havekes LM, Hofker MH *et al.* Progression and regression of atherosclerosis in APOE3-Leiden transgenic mice: an immunohistochemical study. *Atherosclerosis* 1999; 143(1):15-25.
18. Soyombo AA, Angelini GD, Bryan AJ, Jasani B, Newby AC. Intimal proliferation in an organ culture of human saphenous vein. *Am J Pathol* 1990; 137(6):1401-1410.
19. Quax PH, Lamfers ML, Lardenoye JH, Grimbergen JM, de Vries MR, Slomp J *et al.* Adenoviral expression of a urokinase receptor-targeted protease inhibitor inhibits neointima formation in murine and human blood vessels. *Circulation* 2001; 103(4):562-569.
20. Pasterkamp G, Van Keulen JK, de Kleijn DP. Role of Toll-like receptor 4 in the initiation and progression of atherosclerotic disease. *Eur J Clin Invest* 2004; 34(5):328-334.
21. Shimada K, Miyachi K, Mokuno H, Watanabe Y, Iwama Y, Shigeikiyo M *et al.* Promoter polymorphism in the CD14 gene and concentration of soluble CD14 in patients with in-stent restenosis after elective coronary stenting. *Int J Cardiol* 2004; 94(1):87-92.
22. Aiello RJ, Bourassa PA, Lindsey S, Weng W, Natoli E, Rollins BJ *et al.* Monocyte chemoattractant protein-1 accelerates atherosclerosis in apolipoprotein E-deficient mice. *Arterioscler Thromb Vasc Biol* 1999; 19(6):1518-1525.

23. Reape TJ, Groot PH. Chemokines and atherosclerosis. *Atherosclerosis* 1999; 147(2):213-225.
24. van Royen N, Hoefler I, Bottinger M, Hua J, Grundmann S, Voskuil M *et al.* Local monocyte chemoattractant protein-1 therapy increases collateral artery formation in apolipoprotein E-deficient mice but induces systemic monocytic CD11b expression, neointimal formation, and plaque progression. *Circ Res* 2003; 92(2):218-225.
25. Zimmerman MA, Selzman CH, Reznikov LL, Miller SA, Raeburn CD, Emmick J *et al.* Lack of TNF-alpha attenuates intimal hyperplasia after mouse carotid artery injury. *Am J Physiol Regul Integr Comp Physiol* 2002; 283(2):R505-R512.
26. Bailey JM, Butler J. Anti-inflammatory drugs in experimental atherosclerosis. I. Relative potencies for inhibiting plaque formation. *Atherosclerosis* 1973; 17(3):515-522.
27. Pires NM, Schepers A, van der Hoeven BL, de Vries MR, Boesten LS, Jukema JW *et al.* Histopathologic alterations following local delivery of dexamethasone to inhibit restenosis in murine arteries. *Cardiovasc Res* 2005 (68): 215-224.
28. Kalbak K. Incidence of arteriosclerosis in patients with rheumatoid arthritis receiving long-term corticosteroid therapy. *Ann Rheum Dis* 1972; 31(3):196-200.
29. Nashel DJ. Is atherosclerosis a complication of long-term corticosteroid treatment? *Am J Med* 1986; 80(5):925-929.
30. Voisard R, Seitzer U, Baur R, Dartsch PC, Osterhues H, Hoher M *et al.* Corticosteroid agents inhibit proliferation of smooth muscle cells from human atherosclerotic arteries in vitro. *Int J Cardiol* 1994; 43(3):257-267.

