



Universiteit
Leiden

The Netherlands

Inflammation in injury-induced vascular remodelling : functional involvement and therapeutical options

Schepers, A.

Citation

Schepers, A. (2008, April 9). *Inflammation in injury-induced vascular remodelling : functional involvement and therapeutical options*. TNO Quality of Life, Gaubius Laboratory, Faculty of Medicine / Leiden University Medical Center (LUMC), Leiden University. Retrieved from <https://hdl.handle.net/1887/12687>

Version: Corrected Publisher's Version


License: [Licence agreement concerning inclusion of doctoral thesis in the Institutional Repository of the University of Leiden](#)

Downloaded from: <https://hdl.handle.net/1887/12687>

Note: To cite this publication please use the final published version (if applicable).

INFLAMMATION IN INJURY-INDUCED VASCULAR REMODELING;

Functional Involvement and Therapeutical Options



**INFLAMMATION IN
INJURY-INDUCED
VASCULAR REMODELING;**

Functional Involvement and
Therapeutical Options

Cover: Thickenend vein graft

2008, A.Schepers

ISBN 978-90-9022822-8

Layout by Claire Monaghan

Printed by Gildeprint, Enschede

The printing of this thesis was financially supported by Arie Blok Diervoeding,
Mutaro Management and TNO Quality of Life

**Inflammation in injury-induced
vascular remodeling;
functional involvement and therapeutical options**

Proefschrift

ter verkrijging van

de graad van Doctor aan de Universiteit Leiden,

op gezag van de rector Magnificus prof. mr. P.F. van der Heijden,

volgens het besluit van het Colleges voor Promoties

te verdedigen op woensdag 9 april 2008

klokke 16.15 uur

door

Abbey Schepers

geboren te Delft in 1976

Promotiecommissie:

Promotores:

Prof. Dr. P.H.A. Quax

Prof. Dr. J.H. van Bockel

Referent:

Prof. Dr. A.J. van Zonneveld

Overige Leden:

Prof. Dr. V.W. van Hinsberg

Prof. Dr. M.R. Daha

Prof. Dr. T.J.C. van Berkel


The research described in this thesis was performed in the Gaubius Laboratory, TNO-Quality of Life, Leiden, The Netherlands.

The studies described in this thesis was supported by a grant of The Netherlands Heart Foundation (Molecular Cardiology Program, Grant M93.001).

Aan mijn ouders
Voor Ries, Fynn en Jory

CONTENTS

CHAPTER 1	
General Introduction	9
CHAPTER 2	
Histopathologic Alterations Following Local Delivery of Dexamethasone to Inhibit Restenosis in Murine Arteries.	35
CHAPTER 3	
The effect of interleukin-10 knock-out and overexpression on neointima formation in hypercholesterolemic ApoE3Leiden mice.	53
CHAPTER 4	
Short-term dexamethasone treatment inhibits vein graft thickening in hypercholesterolemic ApoE3Leiden transgenic mice.	71
CHAPTER 5	
Anti-MCP-1 gene therapy inhibits vascular smooth muscle cells proliferation and attenuates vein graft thickening both in vitro and in vivo.	89
CHAPTER 6	
Both MIP-1 α and RANTES and their receptors are expressed in murine vein grafts and aggravate vein graft remodeling.	107
CHAPTER 7	
Inhibition of Complement Component C3 Reduces Vein Graft Atherosclerosis in ApoE3Leiden Transgenic Mice.	125
CHAPTER 8	
Blocking of the Chemotactic Complement Endproduct C5a Inhibits Accelerated Atherosclerosis in Vein Grafts.	143
CHAPTER 9	
Discussion	159
NEDERLANDSE SAMENVATTING	169
LIST OF PUBLICATIONS	179
CURRICULUM VITAE	181
COLOUR FIGURE OVERVIEW	183



CHAPTER 1

General Introduction

1.1 ATHEROSCLEROSIS; DEMOGRAPHICS AND CLINICAL PROBLEM

Atherosclerosis is one of the major causes of morbidity and death in the Western World. The disease is characterized by narrowing of arteries due to development of so-called plaques, consisting of accumulations of lipids and fibrous elements in the vessel wall. Plaques are typically located in median and large arteries. Symptoms are usually related to type of the vessel involved and the resulting end-organ ischemia (varying from stroke, myocardial infarction, to intermittent claudicating and lower limb gangrene).

Complications and symptoms of atherosclerosis usually occur in the elderly, but early atherosclerotic lesions, (fatty-streaks) can be detected already in the second and third decade and even at an earlier age. Fatty streaks consist largely of macrophages and T-lymphocytes and can develop to more advanced lesions in which lipid depositions and smooth muscle cell proliferation become more evident. An advanced atherosclerotic plaque is typically build up from a lipid core which often incorporates necrotic debris from apoptotic foam cells, a fibrous cap consisting of three fibroblasts and smooth muscle cells and “shoulders” containing various inflammatory cells¹.

It has been recognized that the origin of this process is inflammation and the role of the inflammatory processes in the vessel wall became more evident. The publication of the article of R. Ross definitively highlighted the role of inflammation and the contribution of the immune system as one of the main players in atherosclerosis².

Today’s therapies, in order to reduce atherosclerosis-related morbidity by relieving end-organ ischemia, can be divided in preventive measures, such as lipid lowering, blood pressure control and anti-platelet therapy, and treatment of symptoms by revascularization of the end-organ by percutaneous interventions or reconstructive surgery.

Percutaneous interventions consist of percutaneous transluminal angioplasty (PTA) of stenotic vessel segments with or without the placement of a stent, whereas reconstructive surgery consist of bypassing the occluded vessel segment by a conduit. Conduits may be arterial, venous and prosthetic. Since this thesis describes processes after PTA and venous bypass surgery, arterial and prosthetic conduits are not further discussed in this work.

1.2 PERCUTANEOUS TRANSLUMINAL ANGIOPLASTY

Cardiac catheterization in humans is a technique developed by Forssmann (1929, Dresden, Germany). Clinical applications of cardiac catheterization were introduced in 1941 by Cournand and Richards, utilizing catheter techniques to measure cardiac output in injured soldiers in World War II. In 1964, Dotter invented the transluminal angioplasty for occluded arteries in the lower extremities, using multiple catheters

of increasing diameter to open blocked arteries and improve blood flow. Gruentzig modified the Dotter catheters and added a balloon to dilate occluded vessel segments. The first balloon angioplasty in peripheral arteries was performed in 1974, whereas human coronary balloon angioplasty was performed in 1977³.

Major improvements of the technique of PTA are the development of the Palmaz-Schatz stent in 1994, reducing elastic recoil of dilated arteries and the clinical introduction of the first “drug-eluting” stent manufactured by Johnson & Johnson/Cordis in 2002⁴, preventing in-stent restenosis. In time, PTA has become one of the most frequently used procedures in obstructive vascular disease.

1.2.1 RESTENOSIS

Long term success of PTA is limited by a phenomenon called restenosis. Restenosis is defined as closing or narrowing of an artery that was previously opened by a procedure such as angioplasty and occurs due to a combination of remodeling and intimal hyperplasia development. Physiologically, vascular remodeling might be either outward or inward directed (expansive versus constrictive remodeling), however in case of restenosis only constrictive remodeling appears to be a major determinant of luminal renarrowing⁵⁻⁷. Intimal hyperplasia describes the changes seen in the tunica intima of a vessel segment that underwent balloon angioplasty, endarterectomy or surgical reconstruction. It consists of accumulation of smooth muscle cells and fibroblasts from different origins that migrate into the intima, and displays a pathological proliferation rate at that location, resulting in restenosis.

1.2.2 PATHOPHYSIOLOGY RESTENOSIS

The exact pathophysiology of development of restenosis is unknown; however several processes have been shown to be involved. It has been established that restenosis occurs as “response to injury” to mechanical damage to the vessel wall after balloon angioplasty consisting of denudation of the endothelial layer and disruption of cell-architecture and extra-cellular matrix.

Directly after balloon dilatation, the stretched vessel segment remains its increased diameter for several days. A virtually complete denudation of the endothelial layer is seen and due to loss of endothelial integrity massive thrombi develop. In the tunica media damage due to stretching is characterized by disruption of the inner and outer elastic lamina (also called deep medial tearing) and increased levels of apoptotic smooth muscle cells (SMC) are demonstrable as early as 30 minutes after balloon dilatation^{8,9}.

After this initial phase regeneration occurs, consisting of proliferation of the remaining endothelium and medial smooth muscle cells. Furthermore, cell migration results in the presence of smooth muscle cells and myofibroblasts in the intima, now

called “neointima”. Recent studies provided evidence for heterogeneous origin of the smooth muscle cells in the neointima. Some studies show that smooth muscle cells migrate from the media of the damaged vessel segment to the neointima¹⁰, and lots of previous studies focused on inhibition of migration of smooth muscle cells¹¹⁻¹⁴. Other studies demonstrate the influx of bone marrow derived progenitor cells as being the source of neointimal smooth muscle cells¹⁵. Once these cells have entered the neointima, proliferation indexes in the neointima are high, resulting in increase of neointima size (now called intimal hyperplasia) and in a gradually decreasing luminal size^{16, 17}.

Eventually, remodeling appears to be limited. Hypothetically, one can assume that restoration of the endothelial layer diminishes a great part of the drive for the inflammatory reaction. Furthermore, since smooth muscle cells proliferation results in a phenomenon called arterialisation, thereby adapting to the new situation and reducing the damage done by pulsatile stretching, the inflammatory response to that kind of damage is limited after surgery. However, clear data that can prove this hypothesis are lacking.

1.3 VEIN GRAFTING

Venous bypass grafting refers to the procedure where an occluded or injured arterial vessel segment is bridged by an autologous venous vessel segment. Historically, it was performed on war casualties suffering traumatic vascular injury of the extremities; a technique firstly described in the beginning of the 20th century. Venous bypass grafting, as known today, has its roots in 1950 as Holden publishes a reports in which he described to have used a saphenous vein graft to bypass an angiographically demonstrated atherosclerotic lesion in the lower limb¹⁸, closely followed by a publication of Kunlin¹⁹ who described approximately the same procedure from the Clinique of Leriche in Strassbourg. Coronary bypass grafting was firstly described in 1968 by Favaloro²⁰, when surgical procedures on the heart became technically possible.

Nowadays, coronary bypass surgery is more and more performed using arterial conduits, such as the left and right mammary artery and the gastroepiploic artery, since this technique displays less graft failure. Nonetheless, venous grafts remain frequently used for both coronary bypass surgery, if arterial conduits are not sufficient or available and in particular in grafting of peripheral arteries of the extremities.

1.3.1 VEIN GRAFT DISEASE

Failing of vein grafts can be divided in 3 phases. In the early phases after engraftment (days-weeks after surgery), 3-12% of the vein grafts fail due to acute thrombosis of the graft²¹. Usually technical problems, such as kinking of the graft, persistent valves, poor run-off or a technically insufficient anastomosis, are the cause of this acute bypass failure. Intermediate (30 days-2 years) and late graft failure (> 2 years) are caused by complete different pathophysiological mechanisms, namely vein graft remodeling consisting of intimal hyperplasia formation and accelerated atherosclerosis. After 10 years up to 60% of the grafts has failed, depending on anatomical localization of the bypass²²⁻²⁴.

Intimal hyperplasia is believed to be responsible for intermediate graft failure (failure between 1 month and 1 year after surgery²¹) It refers to hyperplasia of the intima (and to a lesser extent the media), predominantly consisting of smooth muscle cells and increased amounts of extra-cellular matrix deposition. Typically intimal hyperplasia develops at the proximal and distal anastomosis of the grafts and and probably turbulent flow and accompanying altered shear forces contribute to intimal hyperplasia.

On the long term (beyond 1 year after surgery²¹), vein grafts are highly susceptible for development of a distinct, rapidly progressive form of atherosclerosis, generally known as accelerated atherosclerosis or vein graft disease, being the major cause of late vein graft failure. Vein graft atherosclerotic lesions are more diffuse, concentric and friable as compared with conventional atherosclerotic plaques; they are build up containing more foam cells and lipid depositions and have poorly developed fibrous caps.

It is generally believed that promoting factors for the development of accelerated atherosclerosis are mechanical injury at time of surgery, altered shear- and circumferential wall stress, and the occurrence of pulsatile flow in a vessel previously exposed to venous flow profiles. Furthermore, risk factors playing a role in spontaneous atherosclerosis, such as hyperlipidemia and smoking also play an important role in development of vein graft disease²⁵⁻²⁸.

1.3.2 PATHOPHYSIOLOGY VEIN GRAFT DISEASE

The consecutive stages of vein graft disease development can be divided in 3 parts. First, there is the direct peri- and post-operative phase. Surgical trauma, particularly pressure distension²⁹ and preservation of the vein³⁰⁻³² results in damage of the endothelium and affects tissue connections. Furthermore, ischemia occurs once the vein graft is harvested from the body. The period after engraftment is characterized by ischemia-reperfusion injury at the luminal side of the vein. However, after engraftment ischemic damage might persist in the more distant layers of the vein due to removal from vasa vasorum³³. Like in post-PTA restenosis, due to the non-intact endothelial layer and the overt collagen exposed to the blood stream, thrombi

form on the vein graft wall. These thrombi contain activated platelets, being an early source of various cytokines and growth factors that stimulate endothelial cells to express adhesion molecules but will also promote smooth muscle cell recruitment³⁴.

In days to weeks after surgery, the endothelial layer is restored. The source of endothelial cells is still a matter of discussion. Reports suggest that endothelial cells of vein grafts are derived from circulating progenitor cells³⁵, are build up of the remaining islands of endothelial cells after surgery³⁶ or migrated into the vein graft from the adjacent artery³⁷. Although restoration of the endothelial layer is completed soon after engraftment, signs of endothelial activation can be recognized throughout the later stages of remodeling^{38, 39}.

As an early event, smooth muscle cell apoptosis occurs in all layers of the vein graft, but most extensively in the media where no viable cell can be detected some days after engraftment^{40, 41}. Not only the surgical procedure is a cause for endothelial damage and smooth muscle cell apoptosis of vein grafts, it is also hypothesized that increased biomechanical forces after engraftment in the form of stretch stress plays a major role⁴².

Inflammatory cells (predominantly polymorphonuclear and mononuclear cells) invade the vein graft wall as early as 24 hours after engraftment³⁸. They localize throughout the whole vessel wall including the adventitia, but are mostly present in the direct subendothelial space.

In the later stages of vein graft remodeling “restoration” of the vein graft wall is accomplished by migration and proliferation of smooth muscle cells into the neointima and media, thereby contributing to vein graft thickening and arterIALIZATION. The origin of these cells remains topic of debate. Other than in spontaneous atherosclerosis and post-PTA restenosis, several studies in mice show that the majority of these cells are graft-extrinsic^{43, 44}. Whether these data can be extrapolated to the human situation remains a matter of debate.

Later on, the graft may acquire an atherosclerosis-like morphology as the tissue-macrophages take up lipid and become foam cells^{38, 45, 46}. Cellular analysis reveals more macrophages and other inflammatory cell infiltration in vein graft lesions than can be seen in regular atherosclerotic lesions⁴⁷⁻⁴⁹.

1.4 MOUSE MODELS

Mouse models for studying restenosis or vein graft disease are of interest taking into account the availability of many transgenic mice, including those with an atherosclerotic phenotype, such as the apolipoprotein (APO) E knockout mouse (APOE^{-/-}), the low-density lipoprotein (LDL) receptor knockout mouse (LDLR^{-/-}) and the diet-dependent hyperlipidemic ApoE3Leiden transgenic mouse.

(Partially adapted from “A Handbook of Mouse Models for Cardiovascular Diseases; Chapter 8: Perivascular cuff-, electronic and chemical injury-induced stenosis”

Nuno M.M. Pires^{1,2}, Margreet R. de Vries¹, Abbey Schepers^{1,2}, Daniel Eefting^{1,2}, Jan-Willem H. P. Lardenoye², Paul H.A. Quax^{1,2}

¹TNO-Quality of Life, Gaubius Laboratory, Leiden, The Netherlands

²Leiden University Medical Center, Leiden, The Netherlands

Intravascular injury models to mimic the injury that is inflicted to the vessel wall during PTA are available, but are technically complicated and the reproducibility is not that good, e.g. due to the lack of balloon catheters of appropriately small sizes. As an alternative, models based on perivascular injury are developed to study neointima formation in mouse models.

In 1997, Carmeliet and colleagues described a model in which femoral arteries in mice were injured perivascularly via a single delivery of an electric current. After surgical exposure of the femoral artery, a single current pulse of two seconds (160 μ A) causes a complete loss of all medial smooth muscle cells (SMC) in the affected vessel over a length of 2-3mm. In addition, by this treatment the arterial segment is denuded of intact endothelium and mural (non-occlusive) platelet-rich thrombosis is present within two hours after injury. Via a vascular wound-healing response the mural thrombus degrades, transient infiltration of the vessel wall by inflammatory cells appears, and the necrotic debris diminishes progressively several days after the intervention. Simultaneously, SMC originating from the borders of the injured segment migrate towards the necrotic centre, ultimately leading to SMC accumulation.

Two mouse models of chemical injury-induced neointima formation, both adapted from thrombosis models, have been described in the past years. Kikuchi et al. adapted a (photo) chemical model of thrombosis to a model of neointima formation in the mouse femoral artery. In this model, endothelial injury is inflicted by photochemical reaction by a transluminal green light and intravenous administration of rose Bengal solution. An approximately 2mm long segment of the intact femoral artery is irradiated until blood flow completely stops due to a platelet- and fibrin-rich thrombus. Twenty-four hours later, spontaneous reflow is seen with denudation of the endothelium and medial SMC loss. Within seven days neointima formation starts and reaches a maximum after 21 days, mainly consisting of SMC. Zhu et al. adapted a thrombosis model developed by Farrehi and colleagues to a vascular injury model. In this model, the carotid artery is carefully exposed and a filter paper saturated with a 10% ferric chloride solution is placed on the adventitia for three minutes. This oxidative vascular injury leads to the formation of a transiently occlusive platelet-rich

thrombus with endothelial cell loss and medial cell necrosis. After four weeks, intimal and medial hyperplasia is present in hyperlipidemic mice mainly consisting of SMC and foam cells.

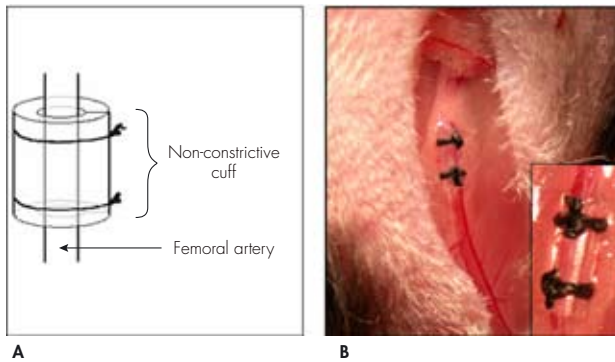
Perivascular cuff injury-induced stenosis mouse model

In 1989, Booth and colleagues established a model for accelerated formation of atherosclerotic-like lesions in the carotid arteries of rabbits. This model is based on placement of a plastic perivascular collar in the rabbit common carotid artery which results in the development of an intimal lesion containing foam cells and SMC in the cuffed segment. Based on the success of this model, in the mid 90s, this model was downscaled to mice and modified using both non-constrictive and constricting tubes. These murine models are widely used to study both accelerated atherosclerosis phenomena and the process of restenosis.

Von der Thüsen et al. defined a mouse model in which a constricting silastic collar is placed around the common carotid artery of hypercholesterolemic mice. The development of collar-induced lesions is found to occur predominantly in the area proximal to the collar and to be dependent on a high-cholesterol diet. Lesions initially consist of monocyte-derived foam cells and as maturation progresses plaques become increasingly heterogeneous with the development of a necrotic core and a fibrous caps with typical shoulder regions.

Moroi et al. were the first to describe a model for inducing neointima formation in the femoral artery of mice. The murine femoral artery is isolated and loosely sheathed with a non-occlusive polyethylene cuff (Figure 1.1). In this model, the endothelial cells are not directly manipulated or removed, oppositely to what occurs in other intravascular injury models for induction of neointima formation. Placement of the cuff results in highly reproducible neointima formation within the cuffed vessel segment in a 2 to 3 week period and mainly consists of SMC on top of the internal elastic lamina underneath an endothelial monolayer. Remarkably, arteries dissected from surrounding tissues (sham-operated) but where a cuff is not placed, do not develop a neointima. The presence of the cuff seems to be essential for inducing the neointima formation after the initial perivascular injury inflicted during surgery. Moreover, if in a similar way a cuff is placed around the carotid artery in the mouse, no neointima formation is observed in the cuffed vessel segment. The reason for this most likely is the anatomic difference between the femoral artery and the carotid artery in the mouse.

Figure 1.1: Schematic representation (A) and microphotograph (B) of femoral artery cuff positioning.



For all experiments studying post-angioplasty restenosis in this thesis the perivascular cuff injury-induced stenosis mouse model was used.

(End citation “A Handbook of Mouse Models for Cardiovascular Diseases; Chapter 8: Perivascular cuff, electronic and chemical injury-induced stenosis”)

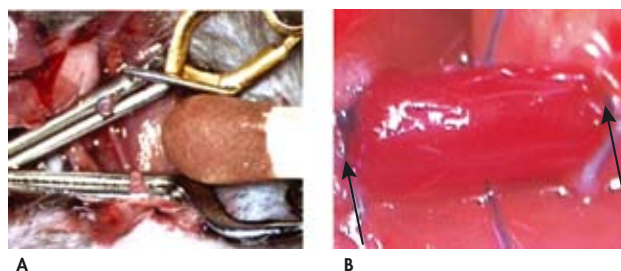
1.4.2 MOUSE MODEL FOR VEIN GRAFT DISEASE

Models to study vein graft disease have been developed for several species varying from rodents to quadrupeds to primates, each with their own pro's and con's. Initially, larger animals such as dogs, sheep, pig and rabbit were favored, facilitating the technical aspects of the anastomosis. For the same reason, venous interponates in peripheral arteries, such as carotids and femoral arteries, were used. In the last decade, mouse models for vein grafting have become of interest because of the availability of inbred, transgenic and knock-out strains. Using mice provides major advantages in studying vein graft disease, since they allow studying the effect of a single gene or protein.

However, the size of the animal requires an alternative approach to anastomose the vessels. The most frequently used murine model to study vein graft disease is the model of Xu⁵⁰. In this model a venous interponate is anastomosed in the murine carotid artery. Therefore the caval vein of a donor mouse is harvested and preserved in heparin containing NaCl 0.9%. In a recipient mouse the right carotid artery is dissected free from its surroundings, ligated at two sides with a silk ligature and cut in the middle. Two clamps are placed distally and proximally from the ligatures, to maintain haemostatic control throughout the procedure, leaving a free end of artery at both sides (Figure 1.2A). Then two plastic cuffs are created and the vessel ends are sleeved through the cuffs. After releasing the ligatures the vessel is folded inside-out around the cuffs and fixed with a silk ligature. The donor caval vein is sleeved

over both cuffs and fixed with a second silk ligature. After removal of the clamps, the caval vein functions as a venous interponate in the carotid artery and pulsatile flow in the graft confirms a successful procedure (Figure 1.2B). When performed in hypercholesterolemic mice, vein grafts in this model undergo a striking remodeling with IH formation and atherosclerotic changes⁴⁵, resulting in formation of lesions that are concentric and friable, with lipid deposition and foam cell accumulation in the intima and media, and have a poorly developed or absent fibrous caps. This morphology is highly similar to the changes seen in human vein grafts.

Figure 1.2: *Bypass model in a mouse. Panel A: The common carotid artery is divided and occluded with 2 clamps. The inferior caval vein of a donor mouse will be implanted as interposition. Panel B: Venous interponate in situ, arrows indicate anastomotic side.*



In this thesis this mouse model for vein graft disease is used. The cuff-assisted anastomosis, making the model feasible, is at the same time the main drawback of the model, being in fact a non-physiological anastomosis. Recently, in an attempt to make the model more human-like, mouse models are designed using either a side-to-side or an end-to-end anastomosis with interrupted sutures⁵¹⁻⁵³. These models appear to have certain advantages over the “cuff-assisted” model. Since poly-ethylene cuffs are absent, less immunogenic, non-self material is present around the venous interponate and thereby the risk of inflammatory reactions other than those seen in daily practice (form surgical dissection and sutures), minimizes. Furthermore, in these models jugular veins are used to graft in the aorta, thereby overcoming the need for heterogenous grafts, harvested from donor mice. Heterologous grafts, although taken from inbred littermates carry the risk of immunological reactions similar to rejection. Finally, a more physiological flow profile is claimed, when there is direct contact between the artery and vein at the place of anastomosis. However, this assumption can be doubted. Due to caliber difference between arteries and veins, turbulent flow is present at the side of anastomosis, just as it is near the cuff-assisted anastomosis.

Disadvantages of these models include the difficulty of surgery, the duration of the surgery (over 60 minutes instead of 30 minutes in the cuff-assisted model) and the fact that these models have not yet been assessed in hypercholesterolemic mice.

As mentioned above, the studies presented in this thesis were performed in the cuff-assisted model, mainly because of the fact that these new models, as described above,

for vein grafting have been described only recently and the cuff-assisted model is very well suited to study this type of pathology because sophisticated interventions and manipulations are relatively easy.

1.5 INFLAMMATION; INTRODUCTION

(For a general review see^{54, 55})

Inflammation is defined as the response of an organism to tissue damage, either applied exogenously (e.g. chemical, thermal or immunological) or endogenously. Although stimuli inducing an inflammatory reaction may vary widely, the reaction of the host (in this case the mammalian body) tend to be similar. In general, inflammation consists of leukocyte exudation at the place of injury. Therefore, leukocytes need to pass the consecutive processes of margination, rolling along the endothelium, adhesion, transmigration through the endothelial layer and chemotaxis to the location of the tissue damage. There, the inflammatory reaction is focused on trying to achieve elimination of the stimulus and repair of the defect by regeneration of parenchyma or replacement by fibro-elastic scar tissue.

For most part, the inflammatory reaction is anchored by the immune system. Grossly, it can be divided in the innate and adaptive immune response.

1.5.1 INNATE IMMUNITY

Immunity is complex. First, all animals possess a primitive system of defense against the pathogens to which they are susceptible, the so-called innate immunity. Innate immunity is nonspecific, being not directed against specific invaders but against any pathogens entering the body. It makes the difference between self and non-self, and includes two parts.

One part, called *humoral* innate immunity, involves a variety of substances found in body fluids and released by damaged cells. Inflammation is regulated by these chemical factors, including specialized chemical mediators, called cytokines. Cytokines can be either promote or diminish inflammatory reactions and are released by injured cells and leukocytes. The group of cytokines include interleukins (responsible for communication between leukocytes); interferons (anti-viral effects); chemokines (which promote chemotaxis). These cytokines and other chemicals serve to establish a barrier against the spread of infection, and to promote healing of any damaged tissue following the removal of pathogens.

The other part is called *cellular* innate immunity. The innate leukocytes include mast cells, eosinophils, basophils, natural killer cells, and the phagocytes (macrophages, neutrophils and dendritic cells) and function by identifying pathogens that might cause infection ultimately resulting in elimination of the pathogen by processes as phagocytosis, toxin release and induction of phagocytosis.

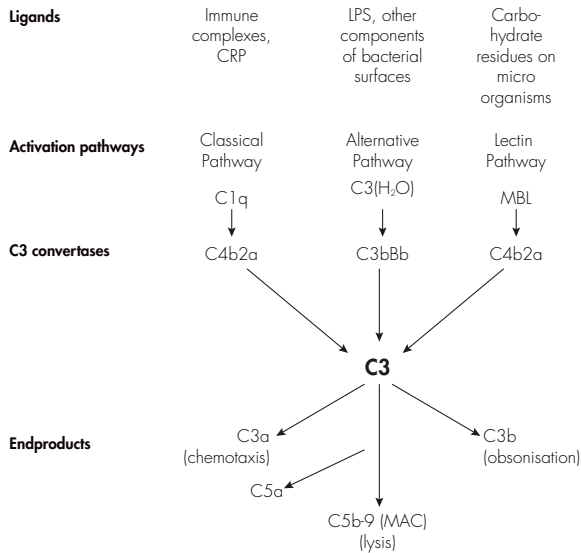
1.5.2 ADAPTIVE IMMUNITY

Only vertebrates have an additional and more sophisticated system of defense mechanisms, called adaptive immunity, that can recognize and destroy foreign invaders. The defensive reaction of the adaptive immune system is called the immune response. Antigens are not foreign microorganisms and tissues themselves, but substances, such as toxins or enzymes, in the microorganisms or tissues that the immune system considers foreign. Immune responses are normally directed against the antigen that provoked them and are said to be antigen-specific. Specificity is one of the two properties that distinguish adaptive immunity from innate immunity. The other is called immunologic memory. Immunologic memory is the ability of the adaptive immune system to mount a stronger and more effective immune response against an antigen after its first encounter with that antigen, leaving the organism better able to resist it in the future. In concrete, the adaptive immune response consists of antibodies (or immunoglobulins) produced by B-cells directed to a specific antigen, B-cells and the different subsets of T-cells.

1.5.3 COMPLEMENT

The complement system is a biochemical cascade of the immune system that helps clear pathogens from an organism. It is a major component of the innate immune system, but also contributes in adaptive immunity. The complement system consists of more than 35 soluble and cell-bound proteins, 12 of which are directly involved in the complement pathways. These plasma proteins can be enzymatically activated via a cascade reaction resulting in the generation of biologically active fragments. These end products have functions as cytolysis, chemotaxis, opsonization, as well as the marking of pathogens for phagocytosis. The complement system can be activated via 3 separate pathways, the classical pathway, the lectin pathway and the alternative pathway, each with its own activation mechanisms. Functioning of the complement system is depicted in Figure 1.3 and explicitly reviewed in⁵⁶⁻⁵⁸.

Figure 1.3: Schematic overview of the complement cascade. *Depicted are the three pathways by which the cascade can be activated and their specific ligands. After activation of C3 convertase, the key molecule C3 is cleaved into active components. These active components (C3a and C3b) have inflammatory properties: chemotaxis of inflammatory cells and obsonisation of foreign invaders. Furthermore, cleavage of C3 results in the formation of various active endproducts more downstream in the cascade, such as C5a, being the most potent chemotactic agent of the cascade, and the Membrane Attack Complex (MAC, C5b-9) which is a composed molecule capable of cell lysis.*



Adapted from thesis L.A. Trouwe; used with permission of the author.

1.6 EVIDENCE FOR INFLAMMATION DRIVEN VASCULAR REMODELING

For a long time the problem of restenosis after percutaneous interventions and vein graft disease focused on the problem of smooth muscle cell migration and proliferation, based on the morphological findings of (re)stenotic lesions characterized by smooth muscle cells in the neointima.

However, as a result of the discussion regarding the role of inflammation in spontaneous atherosclerosis, the link to related processes such as restenosis and vein graft disease was quickly drawn, and many indications for involvement of inflammatory processes in restenosis could easily be found. As described above, leukocyte adhesion is seen in the early phases both in arteries after PTA as in vein grafts after engraftment. Furthermore, macrophages-derived foam cell accumulation is demonstrated in vein grafts. All these findings led to the nowadays general assumption that inflammation plays an important role in post-interventional vascular remodeling. In that line of thought, SMC migration and proliferation is seen as a result of the inflammatory reaction present in the vessel wall after vascular interventions.

A typical inflammatory reaction can be seen as a “response to injury” and usually follows a more or less common course. Initially cells of the vasculature of damaged tissue expresses chemokines and adhesion molecules to enable recruitment of leucocytes and subsequently rolling of the leucocytes on the endothelial layer, creating the conditions for diapedesis and invasion of the damaged tissue. Different subsets of leucocytes can contribute to various forms of reaction and “communicate” by the production of cytokines. Generally, macrophages play an important role, since they are assumed to be the most potent phagocytes, responsible for foreign or damaged tissue resorption. Production of growth factors and cytokines by the invaded cells ultimately results in stimuli to regenerate the damaged tissue.

Theoretically, the inflammatory reaction present after vascular intervention should follow such a path. Nevertheless, when putting together the scientific evidence for this hypothesis, one should notice that this is mainly circumstantial evidence. This is a logical consequence of the fact that the inflammatory reaction is too complex to study successive events as a whole in one experiment. Therefore, most studies focus on a specific part of the inflammatory reaction. In the following chapter, a recapitulation is given of the available evidence for the hypothesis that various components of the inflammatory reaction are involved in post-interventional vascular remodeling.

1.6.1 ADHESION MOLECULES

As described before, vascular interventions such as balloon dilatation, stent placement or handling during harvesting of a saphenous vein before grafting cause damage to the endothelium, thereby altering normal homeostatic properties of an intact

endothelial layer. Studies in animal models show that the remaining endothelial cells become activated and produce a variety of cytokines and upregulate adhesion molecules (P-Selectin, ICAM, VCAM) allowing leukocytes to migrate to the injured vessel wall and adhere to the endothelium^{59, 59-61}. The same phenomenon can be seen in greater saphenous veins that were exposed to pressure distension during surgery⁶².

In addition of endothelial cell activation, platelets massively adhere to the uncovered or injured areas of the intima, producing various pro-inflammatory cytokines, such as CD40L⁶³, RANTES⁶⁴ and P-selectin⁶⁵, inducing production of growth hormones and cytokines and altering adhesive and chemotactic properties of vascular cells^{66, 67}. Upregulation of soluble adhesion molecules can also be detected in the serum early after PTA, indicating that this reaction is not solely detectable in the treated vessel segment⁶⁸ and these levels appear to correspond with the extent of restenosis that can be observed in time⁶⁹⁻⁷¹.

1.6.2 CHEMOKINES

Inflammatory cells migrate to affected vessel segments by a process called chemotaxis. Many chemotactic agents have been shown to be involved in chemotaxis of monocytes and neutrophils to the site of vascular intervention. Monocyte Chemoattractant Protein-1 (MCP-1) is one of the most studied chemokines in vascular remodeling. It expresses strong chemoattractant properties for monocytes, and to a lesser extent T-cells⁷², and induces on monocytes the expression of integrins required for migration through the vessel wall. Furthermore, it has been shown that it has pro-mitogenic properties for SMC^{73, 74}. Its role in spontaneous atherosclerosis is well established, and MCP-1 is emerged as the possible molecular link between ox-LDL and foam cells recruitment. In the later stages, MCP-1 might also contribute to the pro-thrombotic aspects of advanced atherosclerotic lesion (all reviewed in⁷⁵). Regarding post-PTA restenosis, human studies proved a correlation between serum MCP-1 levels after PTA and an increased risk of restenosis⁷⁶. Animal studies underscore the pro-restenotic role of MCP-1 and show that lowering of MCP-1 expression results in decreased neointima formation and also reduces monocyte content in restenotic lesions⁷⁷⁻⁷⁹.

Besides MCP-1, many other chemokines are involved post-angioplasty restenosis, although their role is less extensively studied. For instance Il-8, a potent neutrophil-specific chemokine, has been shown to be upregulated in the perivascular tissue after balloon dilatation of porcine coronary arteries⁸⁰. RANTES, produced by accumulating activated platelets, has been shown to attenuate monocyte recruitment⁶⁴ and levels are correlated with restenosis⁸¹ whereas MCP-3 mRNA is upregulated upon vascular injury, suggesting a role in the remodeling process⁸².

1.6.3 CYTOKINES

Various cytokines has been shown to be involved in restenosis. After vascular injury in general endothelial cell and vascular smooth muscle cells are able to produce cytokines including interleukins Il-1 β , Il-6, Il-8⁸³, TGF- β and TNF- α ⁸⁴. Cytokines are considered to be involved in regulation of the inflammatory response, eg chemotaxis, activation of leukocytes, inducing apoptosis and stimulation of smooth muscle cell proliferation. Since the enormous number of different kinds of cytokines, only some will be discussed in more detail.

TNF- α is a key pro-inflammatory cytokine produced by a number of cells, including macrophages, neutrophils, endothelial cells, and SMCs in response to a variety of stimuli such as LPS release or endothelial damage. TNF- α protein is present in atherectomy specimen of restenotic lesions⁸⁵ and in diseased vein grafts⁸⁶. Furthermore, it was a independent predictor for restenosis after PTA⁸⁷. Blockade of TNF- α has been proven useful in order to reduces restenosis in both a murine and rabbit model for restenosis^{87,88}.

Il-1 β and Il-6, like TNF- α , are also pro-inflammatory cytokines and known to be synthesized in injured vessel segments after balloon dilatation⁸⁹. Il-1 receptor polymorphisms have been shown to be protective for development of restenosis⁹⁰, whereas serum Il-6 levels after PTA are predictive for the development of restenosis⁹¹.

An exemple of an anti-inflammatory cytokine that is involved in vascular remodeling is Il-10. This cytokine has pleiotropic effects in immunoregulation and inflammation. It down-regulates the expression of Th-1 cytokines, enhances B cell survival, proliferation, and antibody production, deactivates monocytes and can block NF-kappa B activity (a nuclear transcription factor involved in various inflammatory processes). Il-10 has been reported to inhibit post-injury restenosis in hypercholesterolemic rabbits and it reduced intimal hyperplasia after wire denudation in normocholesterolemic mice and rats⁹²⁻⁹⁴.

1.6.4 INFLAMMATORY CELLS

As described above, various cell-types are capable of infiltrating inflamed tissue, and cell-types may differ in each type of inflammatory reaction (depending on the site of inflammation and the provocative factor). In the following alineas evidence for involvement of some inflammatory cells in vascular remodeling is summarized.

6.3.a Monocytes

Monocytes, alike their contribution in spontaneous atherosclerosis, appear to be crucial in the various stages of restenosis and vein graft disease. After angioplasty, monocytes are present in the vessel wall within 20 days after the procedure, as

shown in human autopsy specimen⁹⁵. These results were confirmed by animal studies, in which adhering monocytes were detected in the first days after balloon angioplasty^{96,97} and vein grafting^{38,98}. Also in the later stages of arterial remodeling after PTA, monocytes and macrophages can be detected in the different layers of the vessel wall^{80,80,99}. Functional involvement of monocyte recruitment is suggested by studies indicating that after PTA, circulating monocytes increase in blood in a time-dependent manner and the peak monocytes count relates to neointimal volume¹⁰⁰. Furthermore, monocyte depletion after implantation of the vein graft results in reduced vein graft thickening in rat vein grafts¹⁰¹.

6.3.b T-lymphocytes

Various subsets of T-lymphocytes are involved in atherogenesis, as reviewed in¹⁰² and one might extrapolate this to restenosis development. Although not present in the normal tunica intima, T-cells have been shown to adhere and invade damaged vessel segments and remain present up to 10 days after injury in the developing neointima^{60,103}. However, studies providing direct evidence for their involvement are lacking. Moreover, cyclosporine treatment, blocking activation and proliferation of T-lymphocytes did not have any effect on restenosis development in rabbits, thereby suggesting that T lymphocyte—mediated immune responses are not involved in neointima proliferation after balloon dilatation¹⁰³. Clear evidence for a role for T-cell involvement or the lack thereof in post-interventional vascular remodeling remains to be provided.

6.3.c Neutrophils

In the first hours after angioplasty neutrophils adhere and invade the damaged vessel segment^{104, 105}. Also neutrophil accumulation can be seen in the adventitia⁸⁰. The same adherence and invasion can be detected in pressure-distended vein grafts¹⁰⁶. Functional involvement of neutrophils is suggested since, upregulation of neutrophil adhesion molecules after PTA is associated with restenosis¹⁰⁷, combined with the findings that after stent placement activated neutrophils contribute to the oxidative burst, that was associated with occurrence of restenosis in the future¹⁰⁸.

1.7 AIM OF THE THESIS

The aim of this thesis was to study the functional involvement of various selected inflammatory processes in the development of post-PTA restenosis and vein graft disease. Therefore we evaluated the effect of specified anti-inflammatory interventions in various murine models of post-interventional vascular remodeling (perivascular cuff-induced femoral artery stenosis and vein graft accelerated atherosclerosis).

Stated that the influx of leucocytes is the main event in the development of both forms of remodeling, we furthermore focused on the effects of these specified interventions on inflammatory cell adhesion to the vein graft wall.

We aim to postulate a clear involvement of inflammatory processes in post-interventional vascular remodeling, and discover new opportunities for treatment in order to diminish (re)stenosis.

1.8 OUTLINE OF THE THESIS

Firstly, we established the role of inflammatory processes in cuff-induced vascular remodeling by studying the effect of both local and systemic administration of the corticosteroid dexamethasone in this model. Local dexamethasone delivery was achieved by placement of dexamethasone-eluting cuffs. This approach was chosen, since Dexamethasone is a very potent anti-inflammatory agent, possibly altering the inflammatory reaction in the vessel wall, and recently dexamethasone-eluting stents were introduced for clinical use. Taking these recent advances into account, not only the effect on intimal hyperplasia formation was studied, also histopathological alterations in the vessel wall after placement of dexamethasone-eluting cuffs were evaluated and results are described in **Chapter 2**.

In **Chapter 3**, the modulation of the restenotic response following perivascular cuff placement was assessed using both over-expression and inhibition of Il-10, a well known and potential anti-inflammatory cytokine (as described above). Since in human studies an inflammatory reaction can be detected in serum days after PTA, special attention was given to the systemic effects of Il-10 over-expression with regards to cytokine production.

Since inflammation is hardly studied in vein graft disease, a “proof-of-principle” study was performed, studying the hypothesis that if inflammatory processes are involved in vein graft disease, it should be inhibited by Dexamethasone treatment. Furthermore, since prolonged treatment with Dexamethasone is associated with unfavorable side-effects, it was decided to evaluate whether it is possible to temporarily block the inflammatory reaction and still inhibit vein graft disease in the long run, two treatments regimes of Dexamethasone were tested and results are presented in **Chapter 4**.

As discussed, one of the most important chemokines in vascular inflammation is MCP-1, a potent chemoattractant for monocytes. However, its role in vein graft disease was never studied. Therefore, in **Chapter 5**, a dominant negative receptor antagonist of MCP-1 (7ND-MCP-1) and a gene-therapeutic approach was used to block MCP-1 activity in remodeling vein grafts *in vivo*. In this particular study, the focus was not solely on the effects on vein graft thickening and monocyte invasion, but MCP-1s’ direct effects on smooth muscle cell proliferation was also assessed.

Besides MCP-1, other CC-chemokines might be involved in vein graft disease. Out of the large group of CC-chemokines MIP-1 α and RANTES were selected for their known chemotactic properties to monocytes. Their presence and functional involvement was studied and described in **Chapter 6**, using MetRANTES as a potent inhibitor of CCR1 and CCR5 downstream signaling.

Complement is a major contributor in many inflammatory processes, although its role in vascular inflammation, such as atherosclerosis and post-interventional remodeling, is still under debate. The goal of **Chapter 7** was to provide evidence for involvement of the complement system as a whole in the pathophysiology of vein graft disease. Several approaches were used to demonstrate the presence of complement components and to block complement activation in the *in vivo* mouse model of vein graft disease.

To further specify the involvement of the complement cascade in vein graft disease, component of the complement system, C5a, was selected for its potent chemotactic properties. The role of C5a in development of vein graft disease, particularly vein graft thickening and foamcell content, is described in **Chapter 8**, using a pharmacological approach to hamper C5a function.

All results are summarized and discussed in **Chapter 9**, Summary and General Discussion. Furthermore, future perspectives and some recommendations for further research are given for this interesting and clinically relevant field of science.

REFERENCES


1. Lusis AJ. Atherosclerosis. *Nature* 2000 September 14;407(6801):233-41.
2. Ross R. Atherosclerosis--an inflammatory disease. *N Engl J Med* 1999 January 14;340(2):115-26.
3. King SB, III. Angioplasty from bench to bedside to bench. *Circulation* 1996 May 1;93(9):1621-9.
4. Morice MC, Serruys PW, Sousa JE, Fajadet J, Ban HE, Perin M, Colombo A, Schuler G, Barragan P, Guagliumi G, Molnar F, Falotico R. A randomized comparison of a sirolimus-eluting stent with a standard stent for coronary revascularization. *N Engl J Med* 2002 June 6;346(23):1773-80.
5. Post MJ, Borst C, Kuntz RE. The relative importance of arterial remodeling compared with intimal hyperplasia in lumen renarrowing after balloon angioplasty. A study in the normal rabbit and the hypercholesterolemic Yucatan micropig. *Circulation* 1994 June;89(6):2816-21.
6. Mintz GS, Popma JJ, Pichard AD, Kent KM, Satler LF, Wong C, Hong MK, Kovach JA, Leon MB. Arterial remodeling after coronary angioplasty: a serial intravascular ultrasound study. *Circulation* 1996 July 1;94(1):35-43.
7. Pasterkamp G, Galis ZS, de Kleijn DP. Expansive arterial remodeling: location, location, location. *Arterioscler Thromb Vasc Biol* 2004 April;24(4):650-7.
8. Perlman H, Maillard L, Krasinski K, Walsh K. Evidence for the rapid onset of apoptosis in medial smooth muscle cells after balloon injury. *Circulation* 1997 February 18;95(4):981-7.
9. Pollman MJ, Hall JL, Gibbons GH. Determinants of vascular smooth muscle cell apoptosis after balloon angioplasty injury. Influence of redox state and cell phenotype. *Circ Res* 1999 January 8;84(1):113-21.
10. Schwartz SM. Perspectives series: cell adhesion in vascular biology. Smooth muscle migration in atherosclerosis and restenosis. *J Clin Invest* 1997 June 15;99(12):2814-6.
11. Lamfers ML, Lardenoye JH, de Vries MR, Aalders MC, Engelse MA, Grimbergen JM, van H, V, Quax PH. In vivo suppression of restenosis in balloon-injured rat carotid artery by adenovirus-mediated gene transfer of the cell surface-directed plasmin inhibitor ATF.BPTI. *Gene Ther* 2001 April;8(7):534-41.
12. Engelse MA, Lardenoye JH, Neele JM, Grimbergen JM, de Vries MR, Lamfers ML, Pannekoek H, Quax PH, De Vries CJ. Adenoviral activin expression prevents intimal hyperplasia in human and murine blood vessels by maintaining the contractile smooth muscle cell phenotype. *Circ Res* 2002 January 5;90:1128-34.
13. Johnson TW, Wu YX, Herdeg C, Baumbach A, Newby AC, Karsch KR, Oberhoff M. Stent-based delivery of tissue inhibitor of metalloproteinase-3 adenovirus inhibits neointimal formation in porcine coronary arteries. *Arterioscler Thromb Vasc Biol* 2005 April;25(4):754-9.
14. Forough R, Koyama N, Hasenstab D, Lea H, Clowes M, Nikkari ST, Clowes AW. Overexpression of tissue inhibitor of matrix metalloproteinase-1 inhibits vascular smooth muscle cell functions in vitro and in vivo. *Circ Res* 1996 October;79(4):812-20.
15. Xu Y, Arai H, Zhuge X, Sano H, Murayama T, Yoshimoto M, Heike T, Nakahata T, Nishikawa S, Kita T, Yokode M. Role of bone marrow-derived progenitor cells in cuff-induced vascular injury in mice. *Arterioscler Thromb Vasc Biol* 2004 March;24(3):477-82.
16. Geary RL, Williams JK, Golden D, Brown DG, Benjamin ME, Adams MR. Time course of cellular proliferation, intimal hyperplasia, and remodeling following angioplasty in monkeys with established atherosclerosis. A nonhuman primate model of restenosis. *Arterioscler Thromb Vasc Biol* 1996 January;16(1):34-43.
17. Groves PH, Banning AP, Penny WJ, Lewis MJ, Cheadle HA, Newby AC. Kinetics of smooth muscle cell proliferation and intimal thickening in a pig carotid model of balloon injury. *Atherosclerosis* 1995 September;117(1):83-96.
18. Holden WD. Reconstruction of the femoral artery for atherosclerotic thrombosis. *Surgery* 1950;27:417-22.
19. Kunlin J. Le traitement de l'ischémie artérielle par la greffe veineuse longue. *Rev Chir Paris* 1951;70:206-36.
20. Favaloro R. Saphenous vein autograft replacement of severe segmental coronary artery occlusion. Operative technique. *Ann Thorac Surg* 1968;5:334-9.
21. Motwani JG, Topol EJ. Aortocoronary saphenous vein graft disease: pathogenesis, predisposition, and prevention. *Circulation* 1998 March 10;97(9):916-31.
22. Davies MG, Hagen PO. Pathophysiology of vein graft failure: a review. *Eur J Vasc Endovasc Surg* 1995 January;9(1):7-18.
23. Grondin CM, Campeau L, Thornton JC, Engle JC, Cross FS, Schreiber H. Coronary artery bypass grafting with saphenous vein. *Circulation* 1989 June;79(6 Pt 2):124-129.
24. Lawrie GM, Morris GC, Jr., Earle N. Long-term results of coronary bypass surgery. Analysis of 1698 patients followed 15 to 20 years. *Ann Surg* 1991 May;213(5):377-85.
25. Boyle EM, Jr., Lille ST, Allaire E, Clowes AW, Verrier ED. Endothelial cell injury in cardiovascular surgery: atherosclerosis. *Ann Thorac Surg* 1997 March;63(3):885-94.

26. Dobrin PB, Littooy FN, Endean ED. Mechanical factors predisposing to intimal hyperplasia and medial thickening in autogenous vein grafts. *Surgery* 1989 March;105(3):393-400.
27. Shafi S, Palinski W, Born GV. Comparison of uptake and degradation of low density lipoproteins by arteries and veins of rabbits. *Atherosclerosis* 1987 July;66(1-2):131-8.
28. Larson RM, McCann RL, Hagen PO, Dixon SH, Fuchs JC. Effects of experimental hypertension and hypercholesterolemia on the lipid composition of the aorta. *Surgery* 1977 December;82(6):794-800.
29. Chung AW, Rauniyar P, Luo H, Hsiang YN, van BC, Okon EB. Pressure distention compared with pharmacologic relaxation in vein grafting upregulates matrix metalloproteinase-2 and -9. *J Vasc Surg* 2005 October;42(4):747-56.
30. Fahner PJ, Idu MM, van Gulik TM, Legemate DA. Systematic review of preservation methods and clinical outcome of infrainguinal vascular allografts. *J Vasc Surg* 2006 September;44(3):518-24.
31. Schaeffer U, Tanner B, Strohschneider T, Stadtmuller A, Hannekum A. Damage to arterial and venous endothelial cells in bypass grafts induced by several solutions used in bypass surgery. *Thorac Cardiovasc Surg* 1997 August;45(4):168-71.
32. Sottiriari VS, Stanley JC, Fry WJ. Ultrastructure of human and transplanted canine veins: effects of different preparation media. *Surgery* 1983 January;93(1 Pt 1):28-38.
33. Mitra AK, Gangahar DM, Agrawal DK. Cellular, molecular and immunological mechanisms in the pathophysiology of vein graft intimal hyperplasia. *Immunol Cell Biol* 2006 April;84(2):115-24.
34. Torsney E, Mayr U, Zou Y, Thompson WD, Hu Y, Xu Q. Thrombosis and neointima formation in vein grafts are inhibited by locally applied aspirin through endothelial protection. *Circ Res* 2004 June 11;94(11):1466-73.
35. Xu Q, Zhang Z, Davison F, Hu Y. Circulating progenitor cells regenerate endothelium of vein graft atherosclerosis, which is diminished in ApoE-deficient mice. *Circ Res* 2003 October 17;93(8):e76-e86.
36. Carmeliet P, Moons L, Stassen JM, De MM, Bouche A, van den Oord JJ, Kockx M, Collen D. Vascular wound healing and neointima formation induced by perivascular electric injury in mice. *Am J Pathol* 1997 February;150(2):761-76.
37. Dillej RJ, McGeachie JK, Tennant M. Vein to artery grafts: a morphological and histochemical study of the histogenesis of intimal hyperplasia. *Aust N Z J Surg* 1992 April;62(4):297-303.
38. Stark VK, Warner TF, Hoch JR. An ultrastructural study of progressive intimal hyperplasia in rat vein grafts. *J Vasc Surg* 1997 July;26(1):94-103.
39. Davies MG, Klyachkin ML, Dalen H, Massey MF, Svendsen E, Hagen PO. The integrity of experimental vein graft endothelium--implications on the etiology of early graft failure. *Eur J Vasc Surg* 1993 March;7(2):156-65.
40. Mayr M, Li C, Zou Y, Huemer U, Hu Y, Xu Q. Biomechanical stress-induced apoptosis in vein grafts involves p38 mitogen-activated protein kinases. *FASEB J* 2000 February;14(2):261-70.
41. Davies MG, Hagen PO. Pathobiology of intimal hyperplasia. *Br J Surg* 1994 September;81(9):1254-69.
42. Xu Q. Biomechanical-stress-induced signaling and gene expression in the development of arteriosclerosis. *Trends Cardiovasc Med* 2000 January;10(1):35-41.
43. Zhang L, Freedman NJ, Brian L, Peppel K. Graft-extrinsic cells predominate in vein graft arterIALIZATION. *Arterioscler Thromb Vasc Biol* 2004 March;24(3):470-6.
44. Hu Y, Mayr M, Metzler B, Erdel M, Davison F, Xu Q. Both donor and recipient origins of smooth muscle cells in vein graft atherosclerotic lesions. *Circ Res* 2002 October 1;91(7):e13-e20.
45. Lardenoye JH, de Vries MR, Lowik CW, Xu Q, Dhore CR, Cleutjens JP, van Hinsbergh VW, van Bockel JH, Quax PH. Accelerated atherosclerosis and calcification in vein grafts: a study in APOE*3 Leiden transgenic mice. *Circ Res* 2002 October 1;91(7):577-84.
46. Shelton ME, Forman MB, Virmani R, Bajaj A, Stoney WS, Atkinson JB. A comparison of morphologic and angiographic findings in long-term internal mammary artery and saphenous vein bypass grafts. *J Am Coll Cardiol* 1988 February;11(2):297-307.
47. Kalan JM, Roberts WC. Morphologic findings in saphenous veins used as coronary arterial bypass conduits for longer than 1 year: necropsy analysis of 53 patients, 123 saphenous veins, and 1865 five-millimeter segments of veins. *Am Heart J* 1990 May;119(5):1164-84.
48. Kockx MM, De Meyer GR, Bortier H, de Meyere N, Muhring J, Bakker A, Jacob W, Van Vaeck L, Herman A. Luminal foam cell accumulation is associated with smooth muscle cell death in the intimal thickening of human saphenous vein grafts. *Circulation* 1996 September 15;94(6):1255-62.
49. Neitzel GF, Barboriak JJ, Pintar K, Qureshi I. Atherosclerosis in aortocoronary bypass grafts. Morphologic study and risk factor analysis 6 to 12 years after surgery. *Arteriosclerosis* 1986 November;6(6):594-600.
50. Zou Y, Dietrich H, Hu Y, Metzler B, Wick G, Xu Q. Mouse model of venous bypass graft arteriosclerosis. *Am J Pathol* 1998 October;153(4):1301-10.
51. Salzberg SP, Filsoufi F, Anyanwu A, von HK, Karlof E, Carpentier A, Dansky HM, Adams DH. Increased neointimal formation after surgical vein grafting in a murine model of type 2 diabetes. *Circulation* 2006 July 4;114(1 Suppl):1302-1307.

52. Zhang L, Hagen PO, Kisslo J, Peppel K, Freedman NJ. Neointimal hyperplasia rapidly reaches steady state in a novel murine vein graft model. *J Vasc Surg* 2002 October;36(4):824-32.
53. Diao Y, Xue J, Segal MS. A novel mouse model of autologous venous graft intimal hyperplasia. *J Surg Res* 2005 June 1;126(1):106-13.
54. Delves PJ, Roitt IM. The immune system. First of two parts. *N Engl J Med* 2000 July 6;343(1):37-49.
55. Delves PJ, Roitt IM. The immune system. Second of two parts. *N Engl J Med* 2000 July 13;343(2):108-17.
56. Guo RF, Ward PA. Role of C5a in inflammatory responses. *Annu Rev Immunol* 2005;23:821-52.
57. Walport MJ. Complement. First of two parts. *N Engl J Med* 2001 April 5;344(14):1058-66.
58. Walport MJ. Complement. Second of two parts. *N Engl J Med* 2001 April 12;344(15):1140-4.
59. Roque M, Fallon JT, Badimon JJ, Zhang WX, Taubman MB, Reis ED. Mouse model of femoral artery denudation injury associated with the rapid accumulation of adhesion molecules on the luminal surface and recruitment of neutrophils. *Arterioscler Thromb Vasc Biol* 2000 February 20;20(2):335-42.
60. Tanaka H, Sukhova GK, Swanson SJ, Clinton SK, Ganz P, Cybulsky MI, Libby P. Sustained activation of vascular cells and leukocytes in the rabbit aorta after balloon injury. *Circulation* 1993 October;88(4 Pt 1):1788-803.
61. Eriksson EE, Karlof E, Lundmark K, Rotzius P, Hedin U, Xie X. Powerful inflammatory properties of large vein endothelium in vivo. *Arterioscler Thromb Vasc Biol* 2005 April;25(4):723-8.
62. Chello M, Mastroberro P, Frati G, Patti G, D'Ambrosio A, Di SG, Covino E. Pressure distension stimulates the expression of endothelial adhesion molecules in the human saphenous vein graft. *Ann Thorac Surg* 2003 August;76(2):453-8.
63. Henn V, Slupsky JR, Grafe M, Anagnostopoulos I, Forster R, Muller-Berghaus G, Kroczeck RA. CD40 ligand on activated platelets triggers an inflammatory reaction of endothelial cells. *Nature* 1998 February 5;391(6667):591-4.
64. Schober A, Manka D, von HP, Huo Y, Hanrath P, Sarembock IJ, Ley K, Weber C. Deposition of platelet RANTES triggering monocyte recruitment requires P-selectin and is involved in neointima formation after arterial injury. *Circulation* 2002 September 17;106(12):1523-9.
65. Wang K, Zhou X, Zhou Z, Mal N, Fan L, Zhang M, Lincoff AM, Plow EF, Topol EJ, Penn MS. Platelet, not endothelial, P-selectin is required for neointimal formation after vascular injury. *Arterioscler Thromb Vasc Biol* 2005 August;25(8):1584-9.
66. Cha JK, Jeong MH, Bae HR, Han JY, Jeong SJ, Jin HJ, Lim YJ, Kim SH, Kim JW. Activated platelets induce secretion of interleukin-1beta, monocyte chemoattractant protein-1, and macrophage inflammatory protein-1alpha and surface expression of intercellular adhesion molecule-1 on cultured endothelial cells. *J Korean Med Sci* 2000 June 15;15(3):273-8.
67. Massberg S, Vogt F, Dickfeld T, Brand K, Page S, Gawaz M. Activated platelets trigger an inflammatory response and enhance migration of aortic smooth muscle cells. *Thromb Res* 2003 June 1;110(4):187-94.
68. Lee WL, Sheu WH, Liu TJ, Lee WJ, Tsao CR, Ju YH, Liao MF, Chen YT, Ting CT. The short-/intermediate-term changes in novel vascular inflammatory markers after angioplasty plus stenting in patients with symptomatic advanced systemic arterial diseases. *Atherosclerosis* 2004 September;176(1):125-32.
69. Heider P, Wildgruber MG, Weiss W, Berger HJ, Eckstein HH, Wolf O. Role of adhesion molecules in the induction of restenosis after angioplasty in the lower limb. *J Vasc Surg* 2006 May;43(5):969-77.
70. Schulze PC, Kluge E, Schuler G, Lauer B. Periprocedural kinetics in serum levels of cytokines and adhesion molecules in elective PTCA and stent implantation: impact on restenosis. *Arterioscler Thromb Vasc Biol* 2002 December 1;22(12):2105-7.
71. Belch JJ, Shaw JW, Kirk G, McLaren M, Robb R, Maple C, Morse P. The white blood cell adhesion molecule E-selectin predicts restenosis in patients with intermittent claudication undergoing percutaneous transluminal angioplasty. *Circulation* 1997 April 15;95(8):2027-31.
72. Rollins BJ. Chemokines. *Blood* 1997 August 1;90(3):909-28.
73. Selzman CH, Miller SA, Zimmerman MA, Gamboni-Robertson F, Harken AH, Banerjee A. Monocyte chemoattractant protein-1 directly induces human vascular smooth muscle proliferation. *Am J Physiol Heart Circ Physiol* 2002 October;283(4):H1455-H1461.
74. Viedt C, Vogel J, Athanasiou T, Shen W, Orth SR, Kubler W, Kreuzer J. Monocyte chemoattractant protein-1 induces proliferation and interleukin-6 production in human smooth muscle cells by differential activation of nuclear factor-kappaB and activator protein-1. *Arterioscler Thromb Vasc Biol* 2002 June 1;22(6):914-20.
75. Charo IF, Taubman MB. Chemokines in the pathogenesis of vascular disease. *Circ Res* 2004 October 29;95(9):858-66.
76. Cipollone F, Marini M, Fazio M, Pini B, Iezzi A, Reale M, Paloscia L, Materazzo G, D'Annunzio E, Conti P, Chiarelli F, Cuccurullo F, Mezzetti A. Elevated circulating levels of monocyte chemoattractant protein-1 in patients with restenosis after coronary angioplasty. *Arterioscler Thromb Vasc Biol* 2001 March;21(3):327-34.

77. Egashira K, Zhao Q, Kataoka C, Ohtani K, Usui M, Charo IF, Nishida K, Inoue S, Katoh M, Ichiki T, Takeshita A. Importance of monocyte chemoattractant protein-1 pathway in neointimal hyperplasia after periarterial injury in mice and monkeys. *Circ Res* 2002 June 14;90(11):1167-72.
78. Usui M, Egashira K, Ohtani K, Kataoka C, Ishibashi M, Hiasa K, Katoh M, Zhao Q, Kitamoto S, Takeshita A. Anti-monocyte chemoattractant protein-1 gene therapy inhibits restenotic changes (neointimal hyperplasia) after balloon injury in rats and monkeys. *FASEB J* 2002 November;16(13):1838-40.
79. Furukawa Y, Matsumori A, Ohashi N, Shioi T, Ono K, Harada A, Matsushima K, Sasayama S. Anti-monocyte chemoattractant protein-1/monocyte chemoattracting and activating factor antibody inhibits neointimal hyperplasia in injured rat carotid arteries. *Circ Res* 1999 February 19;84(3):306-14.
80. Okamoto E, Couse T, De LH, Vinten-Johansen J, Goodman RB, Scott NA, Wilcox JN. Perivascular inflammation after balloon angioplasty of porcine coronary arteries. *Circulation* 2001 October 30;104(18):2228-35.
81. Inami N, Nomura S, Manabe K, Kimura Y, Iwasaka T. Platelet-derived chemokine RANTES may be a sign of restenosis after percutaneous coronary intervention in patients with stable angina pectoris. *Platelets* 2006 December;17(8):565-70.
82. Wang X, Li X, Yue TL, Ohlstein EH. Expression of monocyte chemoattracting protein-3 mRNA in rat vascular smooth muscle cells and in carotid artery after balloon angioplasty. *Biochim Biophys Acta* 2000 January 3;1500(1):41-8.
83. Loppnow H, Bil R, Hirt S, Schonbeck U, Herzberg M, Werdan K, Rietschel ET, Brandt E, Flad HD. Platelet-derived interleukin-1 induces cytokine production, but not proliferation of human vascular smooth muscle cells. *Blood* 1998 January 1;91(1):134-41.
84. Bazzoni F, Beutler B. The tumor necrosis factor ligand and receptor families. *N Engl J Med* 1996 June 27;334(26):1717-25.
85. Clausell N, de L, V, Molossi S, Liu P, Turley E, Gotlieb AI, Adelman AG, Rabinovitch M. Expression of tumour necrosis factor alpha and accumulation of fibronectin in coronary artery restenotic lesions retrieved by atherectomy. *Br Heart J* 1995 June;73(6):534-9.
86. Christiansen JF, Hartwig D, Bechtel JF, Kluter H, Sievers H, Schonbeck U, Bartels C. Diseased vein grafts express elevated inflammatory cytokine levels compared with atherosclerotic coronary arteries. *Ann Thorac Surg* 2004 May;77(5):1575-9.
87. Monraats PS, Pires NM, Schepers A, Agema WR, Boesten LS, de Vries MR, Zwinderman AH, de Maat MP, Doevendans PA, de Winter RJ, Tio RA, Waltenberger J, 't Hart LM, Frants RR, Quax PH, van Vlijmen BJ, Havekes LM, van Der LA, van der Wall EE, Jukema JW. Tumor necrosis factor-alpha plays an important role in restenosis development. *FASEB J* 2005 December;19(14):1998-2004.
88. Zhou Z, Lauer MA, Wang K, Forudi F, Zhou X, Song X, Solowski N, Kapadia SR, Nakada MT, Topol EJ, Lincoff AM. Effect of anti-tumor necrosis factor-alpha polyclonal antibody on restenosis after balloon angioplasty in a rabbit atherosclerotic model. *Atherosclerosis* 2002 March;161(1):153-9.
89. Chamberlain J, Gunn J, Francis S, Holt C, Crossman D. Temporal and spatial distribution of interleukin-1 beta in balloon injured porcine coronary arteries. *Cardiovasc Res* 1999 October;44(1):156-65.
90. Kastrati A, Koch W, Berger PB, Mehilli J, Stephenson K, Neumann FJ, von BN, Bottiger C, Duff GW, Schomig A. Protective role against restenosis from an interleukin-1 receptor antagonist gene polymorphism in patients treated with coronary stenting. *J Am Coll Cardiol* 2000 December;36(7):2168-73.
91. Hojo Y, Ikeda U, Katsuki T, Mizuno O, Fukazawa H, Kurosaki K, Fujikawa H, Shimada K. Interleukin 6 expression in coronary circulation after coronary angioplasty as a risk factor for restenosis. *Heart* 2000 July;84(1):83-7.
92. Feldman LJ, Aguirre L, Ziol M, Bridou JP, Nevo N, Michel JB, Steg PG. Interleukin-10 inhibits intimal hyperplasia after angioplasty or stent implantation in hypercholesterolemic rabbits. *Circulation* 2000 February 29;101(8):908-16.
93. Zimmerman MA, Reznikov LL, Raeburn CD, Selzman CH. Interleukin-10 attenuates the response to vascular injury. *J Surg Res* 2004 October;121(2):206-13.
94. Mazighi M, Pelle A, Gonzalez W, Mtairag eM, Philippe M, Henin D, Michel JB, Feldman LJ. IL-10 inhibits vascular smooth muscle cell activation in vitro and in vivo. *Am J Physiol Heart Circ Physiol* 2004 August;287(2):H866-H871.
95. Ueda M, Becker AE, Fujimoto T, Tsukada T. The early phenomena of restenosis following percutaneous transluminal coronary angioplasty. *Eur Heart J* 1991 August;12(8):937-45.
96. Stadius ML, Rowan R, Fleischhauer JF, Kernoff R, Billingham M, Gown AM. Time course and cellular characteristics of the iliac artery response to acute balloon injury. An angiographic, morphometric, and immunocytochemical analysis in the cholesterol-fed New Zealand white rabbit. *Arterioscler Thromb* 1992 November;12(11):1267-73.
97. Bayes-Genis A, Campbell JH, Carlson PJ, Holmes DR, Jr., Schwartz RS. Macrophages, myofibroblasts and neointimal hyperplasia after coronary artery injury and repair. *Atherosclerosis* 2002 July;163(1):89-98.

98. Kwei S, Stavrakis G, Takahas M, Taylor G, Folkman MJ, Gimbrone MA, Jr., Garcia-Cardena G. Early adaptive responses of the vascular wall during venous arterIALIZATION in mice. *Am J Pathol* 2004 January;164(1):81-9.
99. Kearney M, Pieczek A, Haley L, Losordo DW, Andres V, Schainfeld R, Rosenfield K, Isner JM. Histopathology of in-stent restenosis in patients with peripheral artery disease. *Circulation* 1997 April 15;95(8):1998-2002.
100. Fukuda D, Shimada K, Tanaka A, Kawarabayashi T, Yoshiyama M, Yoshikawa J. Circulating monocytes and in-stent neointima after coronary stent implantation. *J Am Coll Cardiol* 2004 January 7;43(1):18-23.
101. Wolff RA, Tomas JJ, Hullett DA, Stark VE, van Rooijen N, Hoch JR. Macrophage depletion reduces monocyte chemotactic protein-1 and transforming growth factor-beta1 in healing rat vein grafts. *J Vasc Surg* 2004 April;39(4):878-88.
102. Robertson AK, Hansson GK. T cells in atherogenesis: for better or for worse? *Arterioscler Thromb Vasc Biol* 2006 November;26(11):2421-32.
103. Andersen HO, Hansen BF, Holm P, Stender S, Nordestgaard BG. Effect of cyclosporine on arterial balloon injury lesions in cholesterol-clamped rabbits: T lymphocyte-mediated immune responses not involved in balloon injury-induced neointimal proliferation. *Arterioscler Thromb Vasc Biol* 1999 July;19(7):1687-94.
104. Bienvu JG, Tanguay JF, Chauvet P, Merhi Y. Relationship between platelets and neutrophil adhesion and neointimal growth after repeated arterial wall injury induced by angioplasty in pigs. *J Vasc Res* 2001 March;38(2):153-62.
105. Gonschior P, Gerheuser F, Lehr HA, Welsch U, Hofling B. Ultrastructural characteristics of cellular reaction after experimentally induced lesions in the arterial vessel. *Basic Res Cardiol* 1995 March;90(2):160-6.
106. Schlitt A, Pruefer D, Buerke U, Russ M, Dahm M, Oelert H, Werdan K, Buerke M. Neutrophil adherence to activated saphenous vein and mammary endothelium after graft preparation. *Ann Thorac Surg* 2006 April;81(4):1262-8.
107. Inoue T, Sakai Y, Morooka S, Hayashi T, Takayanagi K, Takabatake Y. Expression of polymorphonuclear leukocyte adhesion molecules and its clinical significance in patients treated with percutaneous transluminal coronary angioplasty. *J Am Coll Cardiol* 1996 November 1;28(5):1127-33.
108. Inoue T, Kato T, Hikichi Y, Hashimoto S, Hirase T, Morooka T, Imoto Y, Takeda Y, Sendo F, Node K. Stent-induced neutrophil activation is associated with an oxidative burst in the inflammatory process, leading to neointimal thickening. *Thromb Haemost* 2006 January;95(1):43-8.



CHAPTER 2

Histopathologic Alterations Following Local Delivery of Dexamethasone to Inhibit Restenosis in Murine Arteries.

Nuno M. M. Pires^{1,2}, Abbey Schepers^{1,3}, Barend L. van der Hoeven²,
Margreet R. de Vries¹, Lianne S. M. Boesten^{1,4}, J. Wouter Jukema²,
Paul H. A. Quax^{1,3}

¹TNO-Quality of Life, Gaubius Laboratory, Zernikedreef 9, 2333 CK Leiden, The Netherlands ²Department of Cardiology, Leiden University Medical Center, Albinusdreef 2, 2333 ZA Leiden, The Netherlands ³Department of Surgery, Leiden University Medical Center, Albinusdreef 2, 2333 ZA Leiden, The Netherlands ⁴Department of General Internal Medicine, Leiden University Medical Center, Albinusdreef 2, 2333 ZA Leiden, The Netherlands

Cardiovascular Research 2005; 68: 415-424

ABSTRACT

Objective: Dexamethasone-eluting stents are currently under evaluation to prevent post-angioplasty restenosis. The efficacy and safety of dexamethasone as an anti-restenotic agent is still unclear. We assess the effect of perivascular delivery of dexamethasone on vascular pathology in a mouse model of restenosis.

Methods and results: In this study we investigate the ability of both systemic and local dexamethasone treatment to inhibit neointima formation after cuff placement around C57BL/6 mouse femoral artery. As in the clinical situation, systemic dexamethasone treatment shows adverse side effects in animals, including weight loss. In contrast, local delivery of dexamethasone using a drug-eluting polymer cuff inhibits neointima formation and has no systemic adverse effects. Pathobiological examination of the experimental arteries, however, reveals a dose-dependent medial atrophy, a reduction in vascular smooth muscle cells and collagen content, an increase in apoptotic cell count and disruption of the internal elastic lamina.

Conclusions: Our results demonstrate that although local dexamethasone delivery is effective as an inhibitor for neointima formation, it is dose-dependently associated with adverse vascular morphological changes pointing to a loss of vascular integrity.

INTRODUCTION

Percutaneous Transluminal Coronary Angioplasty (PTCA) has become the main treatment for revascularization of atherosclerotic coronary arteries in patients with (symptomatic) stenosis. The major drawback of this procedure, however, is the occurrence of restenosis¹. Recently, drug-eluting stents were successfully introduced in interventional cardiology leading to an accentuated drop in the (in-stent) restenosis rate^{2,3}. Many new anti-proliferative, anti-inflammatory, anti-migratory or pro-healing compounds are currently under evaluation to be loaded onto stents, including dexamethasone. Dexamethasone is widely used as a generic anti-inflammatory agent⁴. Dexamethasone is a glucocorticoid that exerts diverse inhibitory effects on several inflammatory-mediated responses and on smooth muscle cell (SMC) proliferation, two important events in the restenotic process⁵⁻¹³.

In several animal models of restenosis, treatment with dexamethasone either locally^{5,14-18} or systemically^{6,19} demonstrated dissimilar outcomes on neointima formation inhibition depending on the animal model used and on the route of administration. Dexamethasone-eluting stents (DES) to prevent post-angioplasty restenosis have been developed recently and are currently under evaluation. Two short-term clinical trials using DES have been published showing conflicting results^{20,21}.

One well-defined mouse model of neointima formation consists of placement of a non-constrictive perivascular cuff around the mouse femoral artery, which results in a reproducible and concentric intimal thickening, mainly due to rapid induction of SMC proliferation²²⁻²⁴. Previously, we showed that the non-occlusive perivascular cuff to induce neointima formation could be constructed from a polymeric formulation suitable for controlled drug delivery²⁵. This novel drug-eluting polymer cuff simultaneously induces reproducible intimal hyperplasia and allows locally confined delivery of anti-restenotic compounds to the cuffed vessel segment. This new approach gives the possibility to evaluate the effects of the tested compounds on neointima formation, vessel wall pathology and potential side effects²⁵.

In the present study we assessed the effect of systemic and local dexamethasone treatment on neointima formation inhibition in a mouse model of restenosis. More importantly, we evaluated the microscopic histopathologic alterations after local delivery of dexamethasone on arterial wall integrity and adverse vascular toxic effects.

METHODS

Femoral artery cuff mouse model.

For experiments, 12 weeks old male C57BL/6 mice were used. Animals were fed a standard chow diet (R/M-H, ssniff, Soest, Germany). Mice were bred and housed under specific pathogen-free conditions and given food and water ad libitum during the entire experiment. At the time of surgery, mice were anaesthetized with an

intraperitoneal (i.p.) injection of 5 mg/kg Dormicum (Roche, Basel, Switzerland), 0.5 mg/kg Dormitor (Orion, Helsinki, Finland) and 0.05 mg/kg Fentanyl (Janssen, Geel, Belgium). The femoral artery was dissected from its surroundings and loosely sheathed with a non-constrictive cuff [22-24].

All animal work was approved by TNO institutional regulatory authority and carried out in compliance with guidelines issued by the Dutch government. The investigation conforms with the *Guide for the Care and Use of Laboratory Animals* published by the US National Institutes of Health (NIH Publication No. 85-23, revised 1996).

Systemic dexamethasone treatment.

Systemic dexamethasone treatment (0.30 mg/kg, LUMC Pharmacy, Leiden, The Netherlands) was achieved either by i.p. injections or oral therapy. Oral treatment was calculated for an average animal body weight of 30 g and a daily water consumption of 3 ml. Treatment was attained by adding dexamethasone to the daily drinking water throughout the whole experimental period, starting one day before surgery. The selected systemic dexamethasone dose was based on previous publications^{6,19}. Eighteen mice were randomly divided into three groups according to the type of treatment (n=6/group). One group of mice was given daily i.p. dexamethasone injections, the second group was given dexamethasone in the drinking water, and the third group served as control and received normal drinking water and daily saline i.p. injections.

All mice underwent femoral artery cuff placement as described above and a polyethylene cuff (Portex, Kent, England, 0.40 mm inner diameter, 0.80 mm outer diameter, 2.0 mm length) was placed loosely around the murine femoral artery²²⁻²⁴.

Dexamethasone-eluting PCL cuffs.

Powder dexamethasone was purchased from Sigma Diagnostics (St Louis, USA). Poly(ϵ -caprolactone) (PCL) based drug delivery cuffs were manufactured as described previously²⁵. Dexamethasone-eluting PCL cuffs were made from blended molten drug-polymer mix and designed to fit around the femoral artery of mice. Drug-eluting PCL cuffs had the shape of a longitudinal cut cylinder with an internal diameter of 0.5 mm, an external diameter of 1 mm, a length of 2.0 mm and a weight of approximately 5.0 mg.

Mice underwent femoral artery cuff placement as earlier described. Either a control empty drug-eluting PCL cuff or a dexamethasone-eluting PCL cuff (1%, 5%, and 20% (w/w)) was used (n=6/group).

In vitro release profiles of dexamethasone.

PCL cuffs were loaded with 1%, 5%, and 20% (w/w) dexamethasone (n=5) and their in vitro release profiles were performed by UV-VIS (238 nm) absorbance methods as described previously^{25,26}. Calibration graphs were established by measuring the absorbance of a set of standards in the 0-50 μ g/ml concentration range.

Similarly, *in vitro* release profiles were also performed for dexamethasone-eluting stents (3.5 mm diameter, 22 mm length, Dexamet™, Abbott Vascular Devices Ltd, Ireland) as described above (n=2).

Quantification and histological assessment of intimal lesions in cuffed femoral arteries.

Animals were sacrificed 21 days after cuff placement. The thorax was opened and a mild pressure-perfusion (100 mmHg) with 4% formaldehyde in 0.9% NaCl (v/v) was performed for 5 minutes by cardiac puncture. After perfusion, femoral artery was harvested, fixed overnight in 4% formaldehyde, dehydrated and paraffin embedded. Serial cross-sections (200 µm; 5 µm thick) were used throughout the entire length of the cuffed femoral artery for histological analysis. All samples were routinely stained with hematoxylin-phloxine-saffron (HPS). Weigert's elastin staining was used to visualize elastic laminae.

Ten equally spaced cross-sections were used in all mice to quantify intimal lesions. Using image analysis software (Leica Qwin, Wetzlar, Germany), total cross sectional medial area was measured between the external and internal elastic lamina; total cross sectional intimal area was measured between the endothelial cell monolayer and the internal elastic lamina.

Internal elastic lamina (IEL) disruption was assessed in all mice by evaluating the number of IEL rupture in ten equally spaced cross-sections throughout the entire length of the cuffed femoral artery segment.

Apoptotic cells were detected by terminal deoxynucleotidyl transferase-mediated dUTP-biotin nick-end labeling (TUNEL) using *in situ* cell death detection kit (Roche Applied Science, Basel, Switzerland) according to the manufacturer instructions. Only TUNEL-positive nuclei that displayed morphological features of apoptosis including cell shrinkage, aggregation of chromatin into dense masses, and nuclear fragmentation were included. TUNEL-positive nuclei were counted in six equally spaced cross-sections in all mice and expressed as a percentage of the total number of nuclei.

Smooth muscle cells (SMC) were visualized with α -SMC actin staining (1:800, Roche Applied Science, Mannheim, Germany). Collagen content was determined using Sirius red stain. The amount of SMC and collagen was determined by morphometry as the total SMC-actin positive or Sirius red-positive area in six equally spaced serial cross-sections in all animals.

Statistical analysis.

All data are presented as mean \pm SEM. Data were analyzed using the Mann-Whitney U-test (SPSS 11.5 for Windows). *P*-values less than 0.05 were regarded as statistically significant.

RESULTS

Inhibition of neointima formation by systemic dexamethasone treatment.

We assessed the ability of systemic dexamethasone treatment, by either daily intraperitoneal (i.p.) boost injection or sustained oral therapy, to reduce cuff-induced neointima formation in our established mouse model of reactive stenosis. As shown in Figure 2.1A-C in control placebo-treated cuffed femoral, neointima was four to six cell layers thick, whereas in both systemic dexamethasone-treated groups cuff-induced neointima was maximally one or two cell layers thick. Morphometric analysis of the cuffed artery segments of both systemic dexamethasone-treated groups showed a comparable significant reduction on neointima formation (placebo treatment: 3.2 ± 0.2 ; i.p. treatment: 1.3 ± 0.2 , $P=0.002$; oral treatment: $0.9 \pm 0.2 \times 10^3 \mu\text{m}^2$, $P=0.002$; Figure 2.1D). Moreover, intima/media ratios of the dexamethasone-treated groups were also significantly decreased (placebo treatment: 0.40 ± 0.05 ; i.p. treatment: 0.16 ± 0.02 , $P=0.002$; oral treatment: 0.17 ± 0.02 , $P=0.005$) as compared to controls. This indicates that both systemic treatments similarly inhibited cuff-induced neointima formation.

With regard to side effects of systemic dexamethasone therapy, dexamethasone-treated animals showed adverse effects associated with dexamethasone systemic therapy, namely impaired wound healing and loss of muscular mass. Dexamethasone-treated animals lost weight during the 3 week-study period (i.p. treatment: pre-operative 29.0 ± 1.0 ; sacrifice 25.4 ± 1.5 , $P=0.04$; oral treatment: pre-operative 26.2 ± 0.7 ; sacrifice 21.6 ± 1.4 g, $P=0.02$). Furthermore, clinical signs of delayed healing were present in 4 out of 12 dexamethasone-treated animals (2 in the i.p. treatment and 2 in the oral-treated group). No weight loss or impaired wound healing was observed in the control placebo-treated group. Moreover, general well-being of the dexamethasone-treated animals was also impaired, since treated animals with dexamethasone showed a profound decrease in daily activity and diminished fur quality. It should be noted that some of the above references (i.e. wound healing, fur quality and daily activity) are qualitative observation, since they are hardly quantifiable. Nevertheless, these observations are relevant indicators of possible side effects of dexamethasone systemic therapy.

Dexamethasone in vitro release profiles.

In order to overcome the adverse side effects observed with the systemic dexamethasone treatment we made use of a drug-eluting PCL cuff loaded with increasing concentrations of dexamethasone which allows restricted local perivascular delivery of compounds to the cuffed vessel segment.

PCL cuffs were loaded with 1%, 5%, and 20% (w/w) dexamethasone and their in vitro release profiles were determined for a 3-week period. Likewise, in vitro release profiles were also performed from dexamethasone-eluting stents for 21 days.

As shown in Figure 2.2, dexamethasone showed a sustained and dose-dependent release from the PCL cuffs for a 21-day period. Dexamethasone release was almost

complete for the lower loading dose (1%: $90.6 \pm 9.1\%$) whereas the cuffs with higher concentrations still contained dexamethasone (5%: $88.8 \pm 0.2\%$; 20%: $65.0 \pm 2.8\%$). Dexamethasone-eluting DEXAMET™ stents showed a comparable amount of drug released in the 21-day test period to the dexamethasone-eluting PCL cuffs (data not shown).

Figure 2.1: Representative cross-sections of cuffed murine femoral arteries. A: Placebo treatment. B: *i.p.* dexamethasone treatment. C: Oral dexamethasone treatment. HPS staining, magnification 400x (arrow indicates the internal elastic lamina; arrowheads indicate the external elastic lamina). D: Total intimal area of cuffed murine femoral arteries 21 days after cuff placement. Total intimal area was quantified by image analysis using ten serial cross-sections from each cuffed artery and expressed in μm^2 (mean \pm SEM, $n=6$). NS, $P>0.05$ (NS, not significant); $**P<0.01$.

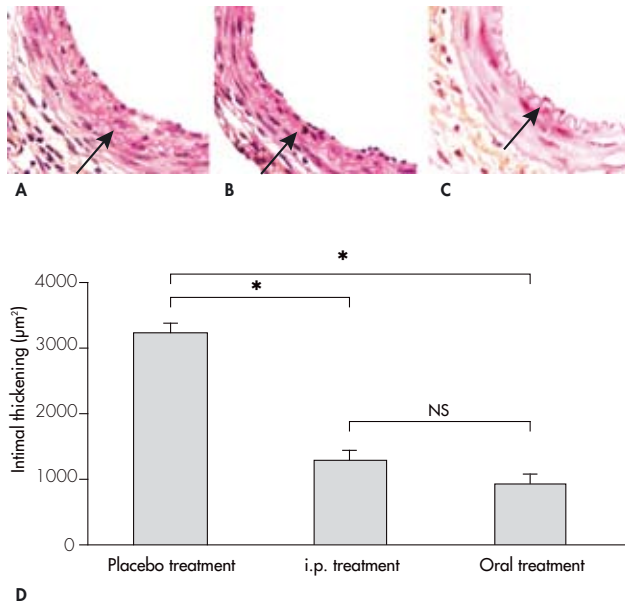
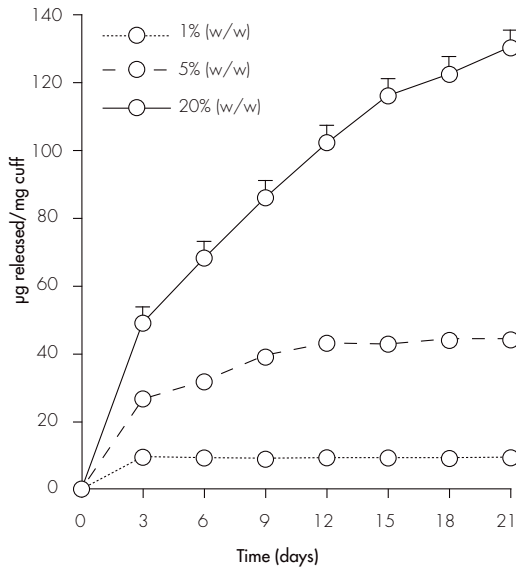


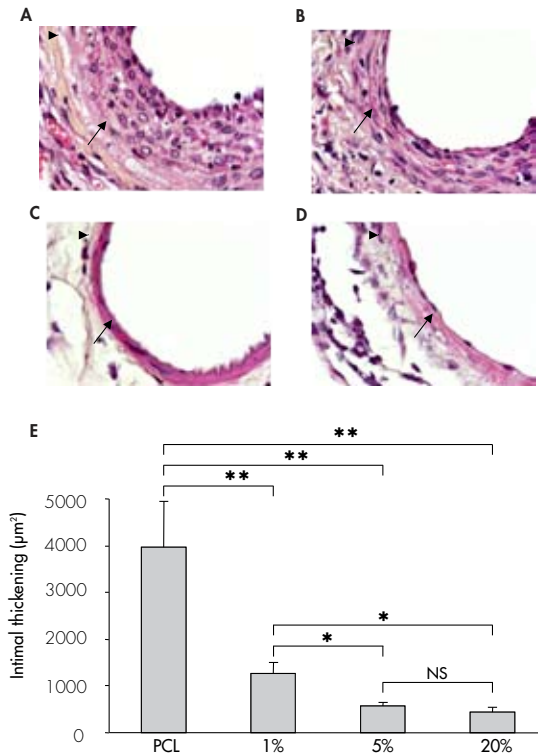
Figure 2.2: In vitro release profiles. *In vitro* release profiles of dexamethasone-eluting PCL cuffs loaded with increasing concentrations of dexamethasone for a 21-day period (mean±SEM, n=5).



Inhibition of neointima formation by perivascular dexamethasone delivery.

To assess the effect of local perivascular dexamethasone delivery on cuff-induced neointima formation, PCL cuffs were loaded with 1%, 5%, and 20% (w/w) dexamethasone and placed around the femoral artery of male C57BL/6 mice for a 21-day period. Microscopic analysis of the cuffed femoral artery segments revealed that, after three weeks, a concentric neointima had been formed in mice receiving a control empty PCL cuff (Figure 2.3A). Most importantly, animals receiving a 1%, 5%, and 20% (w/w) dexamethasone-eluting PCL cuffs showed a strongly reduced intimal hyperplasia development or almost a complete absence of neointimal tissue (Figure 2.3B-D). Morphometric quantification by computer-assisted analysis revealed a significant and dose-dependent inhibition in cuff-induced neointima formation in all tested dexamethasone concentrations when compared with animals receiving a control empty PCL cuff (PCL cuff: 3.9 ± 0.9 ; 1%: 1.2 ± 0.2 , $P=0.007$; 5%: 0.6 ± 0.1 , $P=0.03$; 20%: $0.5 \pm 0.1 \times 10^3 \mu\text{m}^2$, $P=0.01$; Figure 2.3E). Likewise, a similar dose-dependent decrease was seen in intima/media ratios of all dexamethasone loadings (PCL cuff: 0.35 ± 0.12 ; 1%: 0.15 ± 0.02 , $P=0.03$; 5%: 0.13 ± 0.01 , $P=0.03$; 20%: 0.08 ± 0.03 , $P=0.02$) as compared to control empty PCL cuffed femoral arteries.

Figure 2.3: Representative cross-sections of cuffed murine femoral arteries treated with increasing concentrations of dexamethasone 21 days after cuff placement. A: Control empty drug-eluting PCL cuff. B: 1% (w/w) dexamethasone-eluting PCL cuff. C: 5% (w/w) dexamethasone-eluting PCL cuff. D: 20% (w/w) dexamethasone-eluting PCL cuff. HPS staining, magnification 400x (arrow indicates the internal elastic lamina; arrowheads indicate the external elastic lamina). E: Total intimal area of cuffed murine femoral arteries 21 days after drug-eluting PCL cuff placement. Total intimal area was quantified by image analysis using ten serial cross-sections from each cuffed artery and expressed in μm^2 (mean \pm SEM, n=6). NS, $P>0.05$ (NS, not significant); * $P<0.05$; ** $P<0.01$.



Animals receiving a 5% and 20% (w/w) dexamethasone-eluting PCL cuff showed local clinical signs of impaired wound healing in 1 and 2 out of 6 mice, respectively. No delayed healing was observed in the 1% (w/w) dexamethasone-eluting PCL cuff or in the control group. No significant changes in body weights were observed between any of the groups (data not shown). It should be noted that animals locally treated with dexamethasone did not show any impaired general well-being, contrary to what is observed after the systemic treatment.

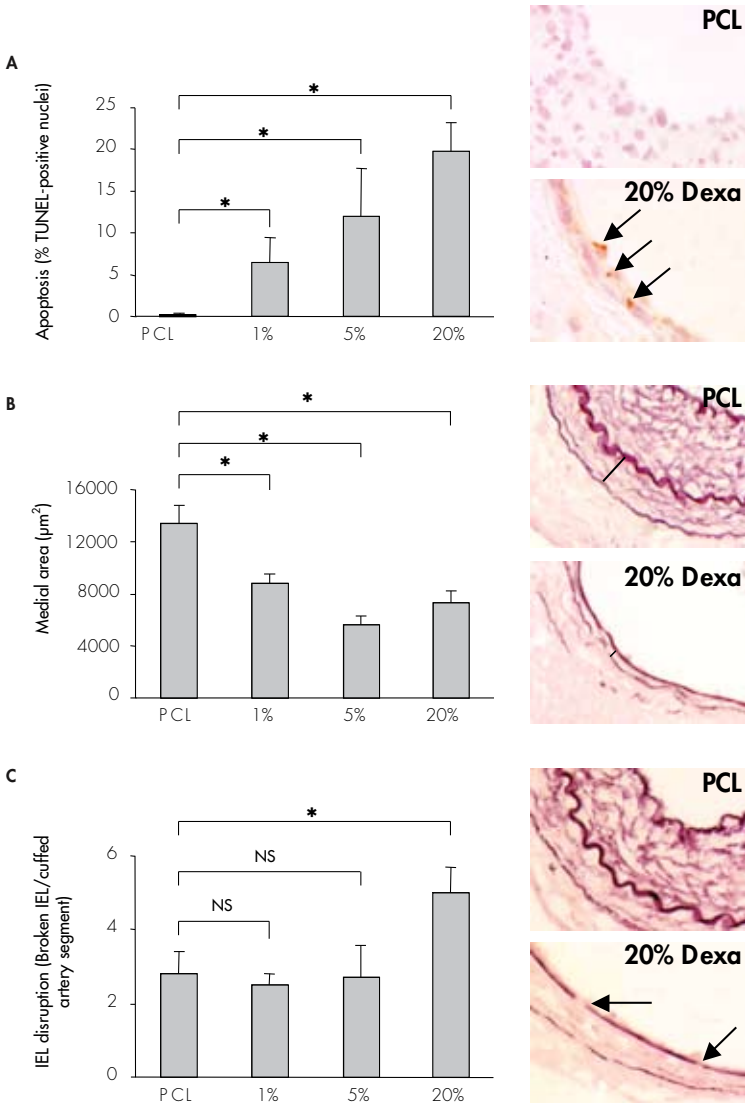
Pathobiological evaluation of perivascular dexamethasone delivery on vessel wall integrity.

The overall structure of the media in the dexamethasone-treated mice had a changed appearance, pointing to an atrophic phenotype. This response demonstrated a dose-dependent reaction (Figure 2.3A-D).

To evaluate the adverse effects on the vessel wall of local perivascular delivery of increasing dexamethasone concentrations in more detail we first performed a standard TUNEL assay to assess apoptotic cells in the cuffed femoral artery segments after 21 days. As shown in Figure 2.4A, low levels of TUNEL-positive cells were seen in control empty PCL cuffed femoral arteries ($0.3 \pm 0.1\%$). Nevertheless, increasing dexamethasone concentrations delivered locally to the vessel wall demonstrated a dose-dependent raise in the percentage of TUNEL-positive cells (1%: $7.3 \pm 3.2\%$, $P=0.02$; 5%: $12.0 \pm 5.7\%$, $P=0.03$; 20%: $19.7 \pm 3.5\%$, $P=0.02$). In the dexamethasone-treated arteries these TUNEL-positive cells were localized mainly in the media since there were hardly any cells forming a neointima. The increase in the number of apoptotic cells resulted in a significant medial cell loss in the dexamethasone-treated arteries (PCL cuff: 13.4 ± 1.4 ; 1%: 8.8 ± 0.7 , $P=0.03$; 5%: 5.6 ± 0.6 , $P=0.02$; 20%: $7.3 \pm 0.9 \times 10^3 \mu\text{m}^2$, $P=0.01$; Figure 2.4B) as compared to control empty PCL cuffed arteries.

Figure 2.4: Histomorphometrical quantification of cuffed femoral arteries treated with increasing concentrations of dexamethasone. *Percentage of TUNEL-positive nuclei (A), total medial area (B) and internal elastic lamina (IEL) disruption (C) of cuffed femoral arteries treated with increasing concentrations of dexamethasone 21 days after drug-eluting PCL cuff placement. TUNEL-positive nuclei were counted in six equally spaced cross-sections from each cuffed artery and expressed as a percentage of the total number of nuclei. Medial area was quantified by image analysis using ten serial cross-sections in each cuffed artery and expressed in μm^2 . IEL disruption was assessed in ten serial cross-sections from each cuffed femoral artery and expressed as the number of broken IEL per cuffed artery segment. Mean \pm SEM, $n=6$. NS, $P>0.05$ (NS, not significant); * $P<0.05$.*

Inserts: **A:** TUNEL staining; femoral artery segments locally treated with 20% (w/w) dexamethasone (20% Dexa) show an increase in TUNEL-positive nuclei as compared to control empty PCL (PCL) cuffed segments. Arrows indicate TUNEL-positive nuclei, magnification 600x. **B:** Weigert's elastin staining; cuffed artery segments treated with 20% (w/w) dexamethasone show a striking medial atrophy. Bars indicate cross-sectional medial area, magnification 600x. **C:** Weigert's elastin staining; control empty PCL cuffed femoral arteries show an intact IEL while local delivery of dexamethasone enhances IEL disruption. Arrows indicate IEL disruption, magnification 600x.

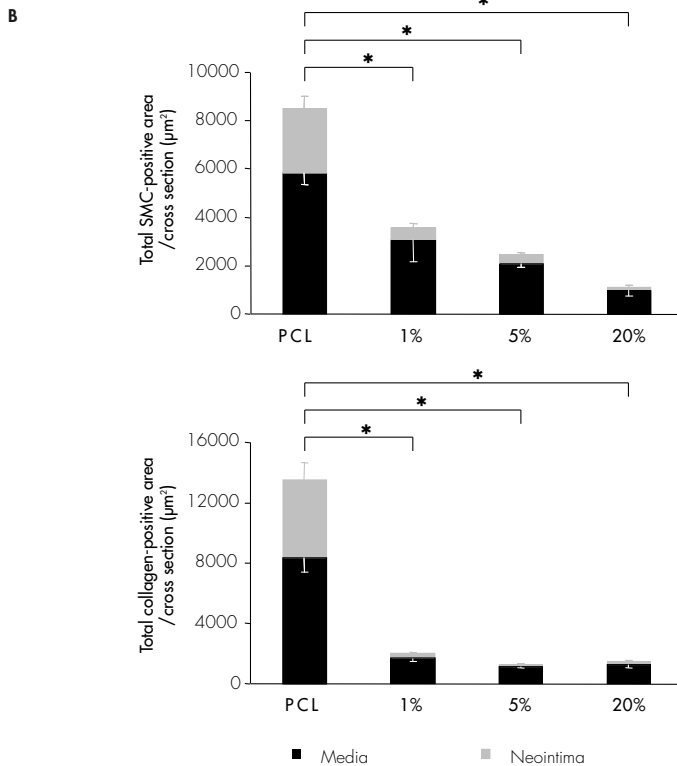
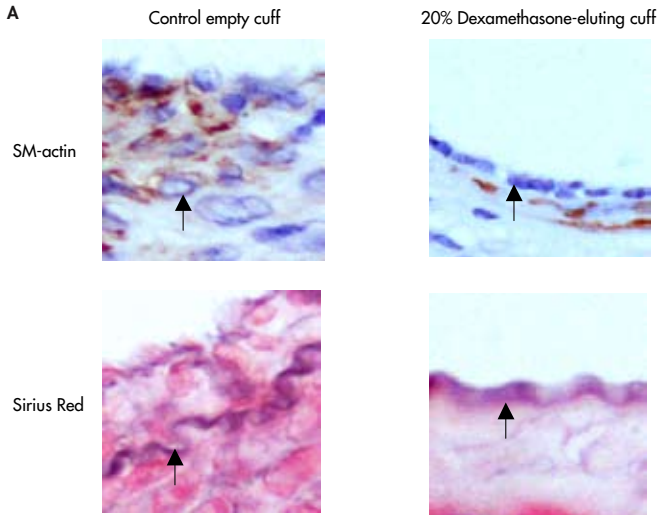


Vascular integrity was also assessed by evaluating the disruption of the internal elastic lamina (IEL) in the cuffed vessel segments. As depicted in Figure 2.4C, control empty PCL cuffed femoral arteries showed a number of IEL rupture similar to the one found in the lower concentrations of dexamethasone-eluting PCL cuffs (PCL cuff: 2.8 ± 0.6 ; 1%: 2.5 ± 0.3 , $P=0.2$; 5%: 2.7 ± 0.9 , $P=0.9$). In contrast, the 20% (w/w) dexamethasone-eluting PCL cuff showed a 1.8-fold increase in IEL disruption (5.0 ± 0.7 , $P=0.03$) as compared to control empty PCL cuffed arteries.

Furthermore, total SMC content of experimental cuffed arteries was reduced in a dose-dependent manner when compared to control PCL cuffed vessels (PCL cuff: 8.5 ± 0.5 ; 1%: 3.6 ± 1.1 , $P=0.02$; 5%: 2.5 ± 0.2 , $P=0.03$; 20%: $1.1 \pm 0.3 \times 10^3 \mu\text{m}^2$, $P=0.01$, Figure 2.5A and B). Similarly, dexamethasone-treated segments also showed a striking decrease in vascular collagen content when compared to control cuffed arteries (PCL cuff: 13.5 ± 0.8 ; 1%: 2.0 ± 0.3 , $P=0.02$; 5%: 1.3 ± 0.1 , $P=0.03$; 20%: $1.5 \pm 0.2 \times 10^3 \mu\text{m}^2$, $P=0.03$, Figure 2.5A and B). Total SMC- and collagen-positive areas were assessed both in the media and in the neointima. As illustrated in Figure 2.5B, neointimal tissue showed a reduction in SMC and collagen content conceivably related to the intimal hyperplasia inhibition in the experimental arteries. Remarkably, medial tissue was also affected upon local dexamethasone treatment showing a striking decrease in both SMC and collagen content in the dexamethasone-treated arteries.

All dose-dependent vascular morphological changes observed in the local dexamethasone-treated arteries point to a loss of vessel wall integrity and adverse vascular toxic effects. Surprisingly, animals systemically treated with dexamethasone did not show any vascular adverse morphological changes like medial atrophy, increased apoptotic cell count or IEL fragmentation contrary to what is observed after local dexamethasone treatment (data not shown).

Figure 2.5: A: Representative cross-sections of cuffed murine femoral artery 21 days after placement of either a control empty PCL cuff or a 20% (w/w) dexamethasone-eluting PCL cuff. Alpha smooth muscle cell actin staining for smooth muscle cells; a striking decrease in alpha SMC-positive cells content is observed in the cuffed vessel perivascularly treated with dexamethasone. Sirius red stain for collagen; a reduced vascular collagen content is present in vessel segments locally treated with dexamethasone. Magnification 600x (arrow indicates the internal elastic lamina). **B:** Total SMC- (top) and collagen-positive (bottom) area of cuffed murine femoral arteries treated with increasing concentrations of dexamethasone at 21 days after drug-eluting PCL cuff placement. SMC- and collagen-positive areas were quantified both in the media (black bars) and in the neointima (grey bars) by image analysis using six serial sections in each cuffed artery and expressed in μm^2 . Mean \pm SEM, $n=6$. * $P<0.05$.



DISCUSSION

Drug-eluting stents coated with anti-restenotic drugs are a new promising tool to prevent post-angioplasty restenosis²⁷. Several drugs have recently been coated onto stents to evaluate their potential as anti-restenotic agents. One of these drugs is dexamethasone, a glucocorticoid which is capable of inhibiting restenosis through several possible mechanisms. Firstly, glucocorticoids are potent anti-inflammatory agents that inhibit leukocyte adhesion and aggregation⁷ and decrease the expression of several cytokines like monocytes chemoattractant protein-1 (MCP-1)^{5,6,8}, interleukin-1 (IL-1)⁹ and interleukin-6 (IL-6)⁵. Secondly, they have a strong anti-proliferative effect and are able to inhibit SMC proliferation [10-13]. Finally, corticoids may decrease extracellular matrix deposition and remodeling through its ability to decrease collagen synthesis²⁸. All these processes are believed to be important in the occurrence of restenosis.

Dexamethasone is a powerful agent that ideally should be administrated locally at the site of injury because of the detrimental side effects that are related to prolonged systemic administration. It is well known from clinical practice that prolonged systemic dexamethasone therapy frequently leads to altered body fat deposition, muscle atrophy, impaired wound healing and increased plasma lipid levels. Furthermore, similar side effects are described in mice exposed to dexamethasone treatment for a prolonged period of time (unpublished data, 2005).

In our study, systemic dexamethasone treatment during the experimental period inhibited cuff-induced neointima proliferation (60% inhibition with i.p. treatment and 71% inhibition with oral treatment) at the tested dose but was associated with systemic side effects including weight loss, reduced daily activity and decreased fur quality, all pointing to a significantly impaired general well-being (Figure 2.1).

In order to overcome these dexamethasone-related systemic side effects we made use of a drug-eluting poly(ϵ -caprolactone) (PCL) cuff to locally deliver dexamethasone²⁵. Restricted local perivascular delivery of dexamethasone using a drug-eluting PCL cuff had no systemic side effects. The degree of neointimal growth inhibition was almost identical in the two higher concentrations (86% inhibition in the 5% and 89% in the 20% dexamethasone-eluting PCL cuff group) suggesting that a certain minimum amount of local drug concentration is necessary to inhibit intimal hyperplasia (Figure 2.3) and that higher concentrations might only raise local adverse side effects of the compound (Figure 2.4 and 2.5).

Several studies evaluating the local effect of dexamethasone on neointimal hyperplasia have been performed showing inconsistent outcomes. Periadvential dexamethasone delivery to the common carotid artery of rats significantly reduced intimal hyperplasia¹⁴. Conflictingly, the same drug delivery device failed to reduce neointima formation in a porcine model of restenosis¹⁵. Dexamethasone-eluting stents (DES) have failed to inhibit neointima formation in porcine coronary arteries^{5,16} but proved to be successful in canine femoral arteries¹⁷. These divergent results might

be due to different dexamethasone concentrations or to species-related arterial differences.

Two published short-term human pilot studies using DES show conflicting results. The STRIDE trial (71 patients) using a BiodvYsio DES (dexamethasone dose of 0.5 $\mu\text{g}/\text{mm}^2$ of stent) reported a binary restenosis rate at 6-month follow-up of 13.3%²⁰. Hoffmann and colleagues used a high-dose DES (2.2 $\mu\text{g}/\text{mm}^2$ of stent) for the treatment of de novo coronary lesions in 30 patients. At 6-month clinical follow-up the restenosis rate was fairly high with 31%, although this study included 17% of diabetic patients which are known to be predisposed to higher restenosis rates²¹. Independently of the intimal hyperplasia inhibition outcome none of the studies, either clinical or preclinical, focused on the potential vascular pathobiological effects of local delivery of dexamethasone.

It is suggested that the strongly hydrophobic character of the majority of the anti-restenotic drugs in use, such as dexamethasone, can lead to high arterial wall concentrations that exceed the bulk concentration²⁹. This highly concentrated local delivery of potent anti-restenotic agents may lead to increased vessel wall toxicity. In our experiments, we indeed found a positive correlation between adverse morphological changes in the vasculature and the concentration of dexamethasone used. This indicates that increasing amounts of dexamethasone delivered to the arterial wall might not only inhibit neointima proliferation but also adversely affect the vessel wall exposed to the drug, leading to increased apoptosis and a loss of general vessel wall integrity.

Although the physical structure of our dexamethasone-eluting PCL cuff is somewhat different from that of a DES (the thickness of the polymer layer is different, the drug release is periadventitially rather than intraluminarily and species-related arterial distinctions) attention should be given to vascular specimens treated with intracoronary DES, since we observe that the amount of dexamethasone released by a DES already invokes adverse toxic effects in murine arteries (Table 2.1). Our studies demonstrate that there is only a small therapeutic window in which a delicate balance between SMC proliferation inhibition and minimal vascular pathological side effects can be attained. This may have significant implications when initiating new clinical studies using higher doses of dexamethasone and at the clinical scenario of overlapping stents.


In conclusion, systemic and local dexamethasone therapy leads to an inhibition of neointimal growth in a murine model of vascular hyperplasia. Nonetheless, systemic dexamethasone treatment is associated with systemic side effects. Local delivery of dexamethasone leads to an abolition of the systemic side effects but was associated with medial atrophy, reduced vascular SMC and collagen content, increased number of apoptotic cells and internal elastic lamina fracture. These outcomes point to a loss of vascular integrity, particularly at high concentrations. The results of this study indicate that although local dexamethasone delivery has the potential to inhibit neointima formation, the toxic-therapeutic window in which the delicate balance

between maximal anti-proliferative effects and minimal effects on vascular pathology is relatively narrow since vascular pathobiological side effects are already detected at relatively low, but effective, doses of dexamethasone in the cuffs.

REFERENCES

1. Mehilli J, Kastrati A, Bollwein H, Didra A, Schuhlen H, Dirschinger J, et al. Gender and restenosis after coronary artery stenting. *Eur Heart J* 2003;24:1523-30.
2. Morice MC, Serruys PW, Sousa JE, Fajadet J, Ban Hayashi E, Perin M, et al. Randomized Study with the Sirolimus-Coated Bx Velocity Balloon-Expandable Stent in the Treatment of Patients with de Novo Native Coronary Artery Lesions. A randomized comparison of a sirolimus-eluting stent with a standard stent for coronary revascularization. *N Engl J Med* 2002;346:1773-80.
3. Grube E, Silber S, Hauptmann KE, Mueller R, Buellesfeld L, Gerckens U, et al. TAXUS I: six- and twelve-month results from a randomized, double-blind trial on a slow-release paclitaxel-eluting stent for de novo coronary lesions. *Circulation* 2003;107:38-42.
4. Parrillo JE, Fauci AS. Mechanisms of glucocorticoid action on immune process. *Annu Rev Pharmacol Toxicol* 1979;19:179-201.
5. Suzuki T, Kopia G, Hayashi S, Bailey LR, Llanos G, Wilensky R, et al. Stent-based delivery of sirolimus reduces neointimal formation in a porcine coronary model. *Circulation* 2001;104:1188-93.
6. Poon M, Gertz SD, Fallon JT, Wiegman P, Berman JW, Sarembock IJ, et al. Dexamethasone inhibits macrophage accumulation after balloon arterial injury in cholesterol fed rabbits. *Atherosclerosis* 2001;155:371-80.
7. Cronstein BN, Kimmel SC, Levin RI, Martiniuk F, Weissmann G. A mechanism for the antiinflammatory effects of corticosteroids: the glucocorticoid receptor regulates leukocyte adhesion to endothelial cells and expression of endothelial-leukocyte adhesion molecule 1 and intercellular adhesion molecule 1. *Proc Natl Acad Sci U S A* 1992;89:9991-5.
8. Marmur JD, Poon M, Rossikhina M, Taubman MB. Induction of PDGF-responsive genes in vascular smooth muscle. Implications for the early response to vessel injury. *Circulation* 1992;86:53-60.
9. Lee SW, Tsou AP, Chan H, Thomas J, Petrie K, Eugui EM, et al. Glucocorticoids selectively inhibit the transcription of the interleukin 1 beta gene and decrease the stability of interleukin 1 beta mRNA. *Proc Natl Acad Sci U S A* 1988;85:1204-8.
10. Reil TD, Sarkar R, Kashyap VS, Sarkar M, Gelabert HA. Dexamethasone suppresses vascular smooth muscle cell proliferation. *J Surg Res* 1999;85:109-14.
11. Yoon JJ, Kim JH, Park TG. Dexamethasone-releasing biodegradable polymer scaffolds fabricated by a gas-foaming/salt-leaching method. *Biomaterials* 2003;24:2323-9.
12. Berk BC, Gordon JB, Alexander RW. Pharmacologic roles of heparin and glucocorticoids to prevent restenosis after coronary angioplasty. *J Am Coll Cardiol* 1991;17:111-7.
13. Nichols NR, Olsson CA, Funder JW. Steroid effects on protein synthesis in cultured smooth muscle cells from rat aorta. *Endocrinology* 1983;113:1096-101.
14. Villa AE, Guzman LA, Chen W, Golomb G, Levy RJ, Topol EJ. Local delivery of dexamethasone for prevention of neointimal proliferation in a rat model of balloon angioplasty. *J Clin Invest* 1994;93:1243-9.
15. Muller DW, Golomb G, Gordon D, Levy RJ. Site-specific dexamethasone delivery for the prevention of neointimal thickening after vascular stent implantation. *Coron Artery Dis* 1994;5:435-42.
16. Lincoff AM, Furst JG, Ellis SG, Tuch RJ, Topol EJ. Sustained local delivery of dexamethasone by a novel intravascular eluting stent to prevent restenosis in the porcine coronary injury model. *J Am Coll Cardiol* 1997;29:808-16.
17. Strecker EP, Gabelmann A, Boos I, Lucas C, Xu Z, Haberstroh J, et al. Effect on intimal hyperplasia of dexamethasone released from coated metal stents compared with non-coated stents in canine femoral arteries. *Cardiovasc Intervent Radiol* 1998;21:487-96.
18. Guzman LA, Labhasetwar V, Song C, Jang Y, Lincoff AM, Levy R, et al. Local intraluminal infusion of biodegradable polymeric nanoparticles. A novel approach for prolonged drug delivery after balloon angioplasty. *Circulation* 1996;94:1441-8.
19. Colburn MD, Moore WS, Gelabert HA, Quinones-Baldrich WJ. Dose responsive suppression of myointimal hyperplasia by dexamethasone. *J Vasc Surg* 1992;15:510-8.
20. Liu X, Huang Y, Hanet C, Vandormael M, Legrand V, Dens J, et al. Study of antirestenosis with the BiodivYsio dexamethasone-eluting stent (STRIDE): a first-in-human multicenter pilot trial. *Catheter Cardiovasc Interv* 2003;60:172-8.

21. Hoffmann R, Langenberg R, Radke P, Franke A, Blindt R, Ortlepp J, et al. Evaluation of a high-dose dexamethasone-eluting stent. *Am J Cardiol* 2004;94:193-5.
22. Moroi M, Zhang L, Yasuda T, Virmani R, Gold HK, Fishman MC, et al. Interaction of genetic deficiency of endothelial nitric oxide, gender, and pregnancy in vascular response to injury in mice. *J Clin Invest* 1998;101:1225-32.
23. Quax PH, Lamfers ML, Lardenoye JH, Grimbergen JM, de Vries MR, Slomp J, et al. Adenoviral expression of a urokinase receptor-targeted protease inhibitor inhibits neointima formation in murine and human blood vessels. *Circulation* 2001;103:562-9.
24. Lardenoye JH, Delsing DJ, de Vries MR, Deckers MM, Princen HM, Havekes LM, et al. Accelerated atherosclerosis by placement of a perivascular cuff and a cholesterol-rich diet in ApoE3Leiden transgenic mice. *Circ Res* 2000;87:248-53.
25. Pires NM, van der Hoeven BL, de Vries MR, Havekes LM, Hennink WE, van Vlijmen BJ, et al. Local Perivascular Delivery of Anti-Restenotic Agents from a Drug-Eluting Poly(ϵ -Caprolactone) Stent Cuff. *Biomaterials* 2005;26:5386-94.
26. Jackson JK, Zhang X, Llewellyn S, Hunter WL, Burt HM. The characterization novel polymeric paste formulations for intratumoral delivery. *Int J Pharm* 2004;270:185-98.
27. van der Hoeven BL, Pires NM, Warda HM, Oemrawsingh PV, van Vlijmen BJ, Quax PH, et al. Drug-eluting stents: results, promises and problems. *Int J Cardiol* 2005;99:9-17.
28. Krane SM, Amento EP. Glucocorticoids and collagen diseases. *Adv Exp Med Biol* 1984;171:61-71.
29. Creel CJ, Lovich MA, Edelman ER. Arterial paclitaxel distribution and deposition. *Circ Res* 2000;86:879-84.



CHAPTER 3

The effect of interleukin-10 knock-out and overexpression on neointima formation in hypercholesterolemic ApoE3Leiden mice.

Daniel Eefting^{*1,2}, Abbey Schepers^{*1,2}, Margreet R. De Vries¹, Nuno M.M. Pires^{1,3}, Jos M. Grimbergen¹, Tonny Lagerweij¹, Lex M. Nagelkerken¹, Pascale S. Monraats³, J. Wouter Jukema³, J. Hajo van Bockel² and Paul H.A. Quax^{1,2}

¹Gaubius laboratory, TNO Quality of Life, Leiden, The Netherlands, Departments of ²Vascular Surgery and ³Cardiology, Leiden University Medical Center, Leiden, The Netherlands

* Both authors contributed equally to this study

Atherosclerosis 2007; 193 (2): 335-342

ABSTRACT

Objective: Inflammatory factors are thought to play a regulatory role in restenosis. Interleukin-10 (IL10) is an important anti-inflammatory cytokine with anti-atherogenic potentials. The aim of this study was to assess the effects of IL10 modulation on cuff-induced neointima formation in hypercholesterolemic ApoE3Leiden mice.

Methods: The involvement of IL10 in neointima formation was studied in a hypercholesterolemic mouse model of cuff-induced stenosis of the femoral artery by IL10 knocking-out or overexpression procedures. IL10^{+/-} mice were crossbred with ApoE3Leiden mice to generate hypercholesterolemic ApoE3LeidenIL10^{-/-} mice. To achieve IL10 overexpression in ApoE3Leiden mice, a single intramuscular injection of a murine IL10 overexpression plasmid was performed followed by electroporation.

Results: Knocking-out IL10, in hypercholesterolemic ApoE3Leiden mice, resulted in a significant 1.9-fold increase of neointima surface as compared to ApoE3LeidenIL10^{+/-} littermates ($p=0.02$). Conversely, a marked 45% inhibition on cuff-induced neointima formation was obtained after IL10 overexpression ($p=0.02$). Electrodelivery of IL10 vector leads to detectable IL10 serum levels, with a sustained expression over the experimental period of three weeks. IL10 overexpression reduced plasma cholesterol levels in ApoE3Leiden mice, whereas IL10 deficiency in these mice did not lead to altered cholesterol levels as compared to the IL10^{+/-} group. Finally, IL10 overexpression stimulated endogenous IL10 mRNA expression in the spleen and reduced the transcriptional responses of several pro-inflammatory cytokines.

Conclusion: Here, we clearly demonstrate the role of IL10 in the development of neointima formation in hypercholesterolemic mice and the potential therapeutic effect of non-viral electrodelivery of IL10 cDNA to inhibit post-angioplasty restenosis.

INTRODUCTION

Inflammation plays an important role in the development of restenosis. Like in atherosclerosis, several pro-inflammatory cytokines (e.g. IL1 β , TNF α and IFN γ) and immuno-inflammatory cells (e.g. T-lymphocytes and activated monocytes) are involved in the formation of restenosis in the vessel wall¹⁻⁴. Interfering in this inflammatory process to prevent post-angioplasty restenosis has potential as a therapeutic application.

Interleukin-10 (IL10) is known as an anti-inflammatory and anti-atherogenic cytokine. In addition, IL10 is a potent monocyte deactivator. This cytokine is produced by most of the cellular components of the vessel wall, such as endothelial cells and vascular smooth muscle cells, but also by lymphocytes and macrophages. Moreover, IL10 is endogenously produced in the atherosclerotic plaque to modulate the inflammatory process⁵⁻⁷.

IL10 protein administration was reported to inhibit post-injury intimal hyperplasia in hypercholesterolemic rabbits and exogenous IL10-protein delivering resulted in a reduced vascular injury response in normocholesterolemic mice and rats⁸⁻¹⁰. However, the effect of IL10 on neointima formation in hypercholesterolemic mice has never been described before.

In this study, we examined the effect of IL10 gene knock-out and overexpression on neointima formation in hypercholesterolemic ApoE3Leiden mice. In these ApoE3Leiden mice, a mutated human ApoE3Leiden gene is cloned and this leads to a defective clearance of ApoE-rich lipoproteins by the liver. Therefore these mice develop a diet dependent hyperlipidemia and diet induced atherosclerosis¹¹. After placement of a non-constricting polyethylene cuff around the femoral artery in these transgenic mice, restenosis with signs of accelerated atherosclerosis develops within two to three weeks¹². This model for cuff-induced neointima formation is very suitable to investigate the role of inflammatory factors in stenosis^{4,13}. The lesions formed after cuff placement in the hypercholesterolemic mice contain both smooth cells and macrophages that might become foam cells and therefore this model mimics both restenosis as it occurs in hypercholesterolemic patients as well as the very early steps of atherosclerotic plaque formation.

Knocking-out IL10 in these hypercholesterolemic mice enables us to study the involvement of IL10 on neointima formation in comparison to their IL10^{+/+} littermates.

Opposingly, non-viral intramuscular electroporation mediated gene transfer of interleukin-10 cDNA was used to assess the effect of high circulating levels of IL10 protein on neointima formation in ApoE3Leiden mice. With this method, disadvantages of viral gene delivery (like inflammatory and immunological responses) are circumvented. Moreover, in stead of daily protein administration, a single intervention will give long-term expression of transgenes^{14,15}. In this study, we show

that intramuscular electroporation mediated delivery of a murine IL10 expression plasmid results in sufficient IL10 serum levels and inhibits cuff-induced neointima formation in hypercholesterolemic ApoE3Leiden mice.

MATERIALS AND METHODS

Mice.

All animal experimental protocols were reviewed and approved by the animal welfare committee of the Netherlands Organization for Applied Scientific Research (TNO, Leiden, The Netherlands). The investigation conforms with the *Guide for Care and Use of Laboratory Animals* published by the US National Institutes of Health (NIH Publication No. 85-23, revised 1996). For the IL10 overexpression experiments, Specific Pathogen-Free transgenic ApoE3Leiden mice were crossbred for at least 18 generations with C57BL/6 mice. These mice develop a diet dependent hypercholesterolemia and spontaneous atherosclerosis^{11;16}. Male ApoE3Leiden animals, with a mean weight of 28.4±0.6 grams, were allocated randomly to one of the two experimental groups.

For the IL10 knock-out experiments, experimental mice (ApoE3LeidenIL10^{-/-} and control littermate ApoE3Leiden IL10^{+/+} mice) were obtained by crossbreeding IL10^{-/-} mice (Jackson Laboratory) with heterozygote ApoE3Leiden mice. Mice were characterized by PCR for IL10 from tail biopsies (Primers; forward: 5'-GCC TTC AGT ATA AAA GGG GGA CC-3', NEO primer: 5'-CCT GCG TGC AAT CCA TCT TG-3' and reverse: 5'-GTG GGT GCA GTT ATT GTC TTC CCG-3')¹⁷. Mean weight of all experimental male mice was 28.0±0.5 grams. No differences in weights were found between both groups.

Both in the IL10 knock-out study and in the IL10 overexpression study, animals were fed with a cholesterol-enriched high-fat diet (diet W, containing 1% cholesterol and 0.01% cholate, Arie Blok B.V.¹⁸), starting 4 weeks prior to surgery and continued during the whole experiment. All mice received water and food ad libitum.

Cholesterol levels in serum were determined one week before surgery and at sacrifice. Before electroporation and cuff placement, mice were anaesthetized by a combination of Midazolam (5 mg/kg; Roche), Medetomidine (0.5 mg/kg; Orion) and Fentanyl (0.05 mg/kg; Janssen).

Cuff-induced neointima formation.

Neointima formation and accelerated atherosclerosis was induced by means of vascular injury through cuff placement around the femoral artery of mice on a hypercholesterolemic diet as described previously^{12;19}. Briefly, femoral arteries were isolated from surrounding tissues and a non-constricting 3 mm polyethylene cuff (internal diameter 0.4 mm) was placed around the arteries. With this intervention, a profound neointima formation with signs of accelerated atherosclerosis develops within two to three weeks. Animals were sacrificed 14 days (IL10^{-/-} experiment) and

21 days (IL10 overexpression experiment) after cuff placement. Tissue segments were harvested after perfusion fixation and paraffin-embedded.

Quantification of neointima formation and immunohistochemistry.

To quantify the intimal thickening, elastic laminae were visualized with Weigert's elastin staining. Six sequential representative sections per vessel segment were used to quantify neointima formation, using image analysis software (Qwin, Leica).

The composition of neointima formation was visualized by haematoxylin-phloxine-saffron (HPS) staining and immunohistochemistry. Smooth muscle cells were visualized with α -smooth muscle cell actin staining (anti-SM α -actin, dilution 1:1600, Roche). AIA31240 (dilution 1:3000, Accurate Chemical) staining was used to detect monocytes/macrophages. The smooth muscle cells positive area and macrophages positive area in the neointima and media of the cuffed arteries were calculated as a percentage of the total intimal and medial area by means of image analysis software (Qwin, Leica).

Interleukin-10 overexpression.

For overexpression of IL10, intramuscular electroporation with a CAGGS plasmid encoding for murine IL10 (kindly provided by Dr. Miyazaki, Division of Stem Cell Regulation Research, Osaka University Medical School, Osaka, Japan) was applied one day before cuff placement. As a control, *pCAGGS-Luciferase* was used. Both CAGGS plasmids contain a cytomegalovirus immediate-early enhancer-chicken β -actin hybrid promoter, to obtain a long-lasting expression *in vivo*²⁰. All plasmid DNA was prepared using DH5 α E.coli (Invitrogen) and QIAfilter Plasmid Giga Kits (Qiagen). Plasmid DNA was dissolved in Endofree Tris-EDTA buffer (Qiagen) at a final concentration of 3.5 mg/ml.

For optimal transfection efficiency both calf muscles were injected with 30 μ l of hyaluronidase (13.5U, Sigma), one hour before electroporation, as described previously by McMahon et al.²¹. Subsequently, 50 μ g of either pCAGGS-mIL10 or pCAGGS-Luciferase as a control, dissolved in 30 μ l TE buffer, was injected in both calf muscles followed by eight electrical pulses of 10 milliseconds of 200V/cm with an interval of one second. The pulses were generated with a Square Wave Electroporator ECM 830 (BTX, Harvard Apparatus) using Caliper Electrodes.

At 7 and 21 days after electroporation, serum samples were collected and IL10 concentration was measured using a mouse IL10 ELISA kit (Endogen).

Furthermore, transfection efficiency was analyzed by luciferase activity quantification in the control mice, 7 and 21 days after electroporation with pLuciferase. For this purpose, mice were anesthetized and injected i.p. with luciferin (90 mg/kg body weight, Synchem OHG). Five minutes after injection, luciferase activity was measured with a cooled charged-coupled device (CCCD) bioluminescence camera (The Night-OWL LB 981 UltraSens Frontlit, Berthold Technologies) as described previously²².

Briefly, a gray-scale image of mice was recorded after placing the mice in the dark chamber. Hereafter, photon emission was integrated over a period of 30 seconds and recorded as pseudo-color images (pixel binning 7 x 7). For co-localization of the bioluminescent photon emission on the calf muscles, gray-scale and pseudo-color images were combined by using WinLight software (Berthold Technologies). Localization and measurement of luminescence emitted from the muscles was performed by using the overlay of the real image and the luminescence scan. Data were expressed as photon flux (counts/s).

RNA isolation and Real-Time RT-PCR procedure.

To assess the systemic regulation of inflammation-related genes after IL10 overexpression, mRNA from spleens was isolated after three weeks (n=5). For the 7 days time point, five extra mice were electroporated and sacrificed one week later. Directly after harvesting, spleens were snap-frozen in liquid nitrogen. Next, spleens were ground with pestle and mortar. RNA isolation was performed using Trizol (Invitrogen) according to manufacturer's protocol. Synthesis of cDNA was performed by means of Ready-To-Go Beads (Amersham Biosciences).

For TNF- α and HPRT, intron-spanning primer-probe sets were designed using Primer ExpressTM 1.5 software (Applied Biosystems, Table 3.1). TaqMan[®] Gene Expression Assays were used for IL6, IL1 β , IFN γ , IL4 and IL10 (Applied Biosystems). HPRT was used as a housekeeping gene. The PCR reaction was performed using qPCR Mastermix (Eurogentec). Analysis of mRNA expression by real time-PCR was performed on an ABI PrismTM 7700 sequence detection system (Perkin Elmer Biosystems).

Table 3.1

Taqman Primers and Probes for real-time quantitative RT-PCR	
TNF α	Sense: 5' CATCTTCTCAAATTCGAGTGACAA 3' Antisense: 5' TGGGAGTAGACAAGGTACAACCC 3' Probe: 5' CACGTCGTAGCAAACCACCAAGTGGGA 3'
HPRT	Sense: 5'-GGCTATAAGTTCTTTGCTGACCTG-3' Antisense: 5'-AACTTTTATGTCCCCCGTTGA-3' Probe: 5'-CTGTAGATTTTATCAGACTGAAGAGCTACTGTAATGACCA-3'

For the analysis, the average cycle threshold per time point was subtracted from the average cycle threshold of the housekeeping gene HPRT (dCt). ddCt was determined as the difference between dCt-values of the IL10 electroporated mice and the control group (luciferase). Data are presented as mean fold induction compared to the normalized luciferase group, calculated as 2^{-ddCt} .

Statistical analysis.

Results are expressed as mean \pm SEM. Statistical significance was calculated in SPSS 11.5 for Windows. Groups were compared to their controls and significant differences were determined using the Student's Tests. A value of $P < 0.05$ was considered statistically significant.

RESULTS

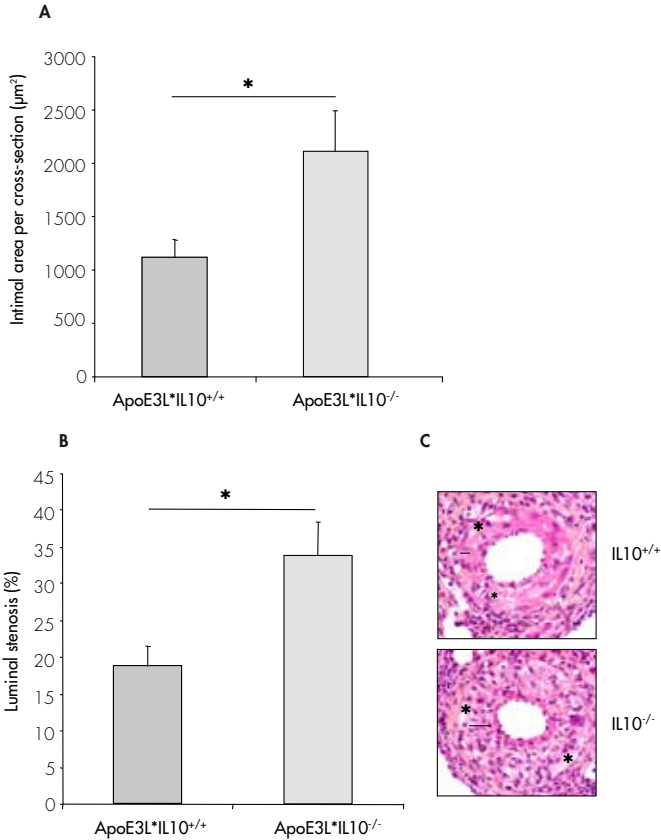
Neointima formation in hypercholesterolemic ApoE3LeidenIL10 knock-out mice.

To study the effect of lacking interleukin-10 on neointima formation in mice with a hypercholesterolemic background, IL10^{-/-} mice were crossbred with ApoE3Leiden mice. Twelve week old ApoE3LeidenIL10^{-/-} and control littermate (ApoE3LeidenIL10^{+/+}) mice were fed with a mild-type western-type diet for 4 weeks. One week prior to surgery, serum cholesterol levels were 8.4 \pm 0.6 mmol/L in the IL10^{-/-} group and 7.2 \pm 1.1 mmol/L in the IL10^{+/+} mice (difference not significant). At sacrifice, serum cholesterol levels were not changed significantly between both groups as well as compared to pre-surgery: 8.1 \pm 0.3 mmol/L (IL10^{-/-} group) versus 7.3 \pm 1.9 mmol/L (IL10^{+/+} group).

All mice underwent femoral artery cuff placement (n=8) to induce neointimal hyperplasia and subsequent accelerated foam cell accumulation. Lesions were composed of smooth muscle cells in combination with macrophages/foam cells. Mean bodyweights in both groups were comparable and no significant changes were registered in any of the animals during the whole experiment (data not shown).

Two weeks after surgery, femoral arteries were harvested and histomorphometric analysis showed a 1.9 fold increase of neointima formation in the IL10^{-/-} group as compared to the control group (control: 1.1 \pm 0.2 mm², IL10^{-/-}: 2.1 \pm 0.3 mm²; p=0.02; Figure 3.1, panel A and C). Medial area was similar in both groups (both 5.8 \pm 0.6 mm², data not shown). Finally, the lumens of the vessels were reduced by a factor 1.81 in the IL10^{-/-} group (lumen stenosis in control group: 18.7 \pm 2.8% and IL10^{-/-} group: 33.8 \pm 4.5%; p=0.01, Figure 3.1, panel B and C).

Figure 3.1: Effect of IL10 knock-out on neointimal formation in hypercholesterolemic mice. Total intimal thickening (Panel A) and percentage of lumen stenosis (B) of cuffed femoral arteries in ApoE3LeidenIL10^{-/-} and their IL10^{+/+} control littermates, 14 days after cuff placement (n=8 per group, *p<0.02). Panel C represents haematoxylin-phloxine-saffron (HPS) staining of cuffed femoral arteries of both groups. Neointimal surface (indicated by black line) is clearly increased in the IL10 knock-out group. Asterisks (*) indicate macrophage-derived foam cells (magnification 250x).



Expression of interleukin-10 and luciferase after electroporation mediated gene transfer.

Seven days after intramuscular injection and electroporation with pCAGGS-mIL10 or pCAGGS-Luciferase, serum levels of mIL10 were 43.7±4.8 ng/ml and 0.7±0.1 ng/ml, respectively (p<0.001). 21 days after electroporation, mIL10 concentration in the serum was 2.0±0.3 ng/ml in the IL10 treated group and 0.3±0.04 ng/ml in the control group (p=0.009, Figure 3.2, panel A). To verify expression of the transfected

transgene luciferase, bioluminescence imaging was performed and luciferase activity was quantified (see Figure 3.2, panel B and C).

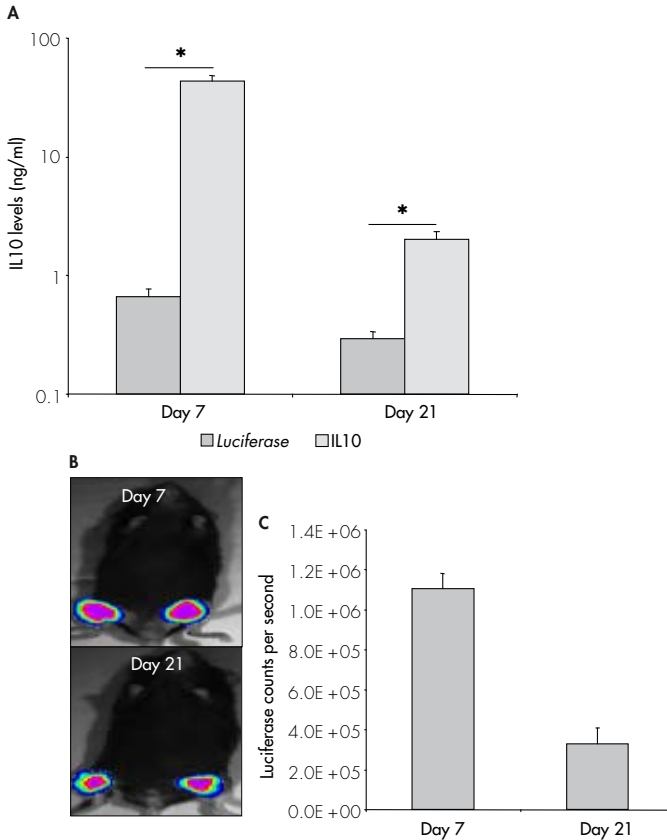
Effect of interleukin-10 overexpression on neointima formation in ApoE3Leiden mice.

To study the effect of IL10 on neointima formation in hypercholesterolemic mice, femoral arterial non-constricting cuffs were placed in male ApoE3Leiden mice (n=8 per group). Also these mice were fed with a mild-type western-type diet for 4 weeks before surgery and electroporation. Serum cholesterol levels were 14.8±1.4 mmol/L in the IL10 treated group and 14.0±0.4 mmol/L in the control mice (difference not significant). One day prior to surgery, the hindlimbs of the mice were electroporated with either an IL10 expression vector or a luciferase vector as a control. Three weeks after electroporation and surgery, mean cholesterol levels were reduced with 41.4% (8.7±0.5 mmol/L, p<0.001) in the IL10 treated group. The cholesterol levels in the control group were not changed significantly (14.7±1.2 mmol/L). No effects on body weights of all mice were observed (data not shown).

Histomorphometric analysis was performed on femoral arteries harvested 21 days after electroporation and surgery. It was anticipated to observe less neointima than in the experiment with the IL10 knock-out mice, therefore we decided to harvest the femoral arteries after three weeks instead of two weeks. A 45.4% reduction of neointima was found in the IL10 treated group as compared to the control group (control: 4.2±0.7 mm² and IL10: 2.3±0.4 mm²; p=0.02; Figure 3.3, panel A and C). The medial area was not changed significantly in both groups (control: 11.0±1.0 mm² and IL10: 9.5±0.7 mm²). The luminal stenosis was inhibited with 50.5% in the IL10 treated group (control: 25.5±3.8 % and IL10: 12.6±2.5 %, p=0.006, Figure 3.3, panel B and C).

To study the effect of IL10 modulation on the cellular composition of the lesion in the cuffed arterial wall, immunohistochemical analysis for the presence of SMCs and macrophage-derived foam-cells of both, IL10 knock-out and IL10 overexpression experiments was performed (Figure 3.4). Equally to the medial surface, the cellular composition of the media was not affected in both experiments. Relative SM α -actin positive areas in the IL10 knock-out experiment were: IL10^{+/+}: 40±5% and IL10^{-/-}: 40±6%, p=0.49 and in the IL10 overexpression experiment the relative SM α -actin positive areas were: IL10 overexpression: 23±5% and control: 25±4%, p=0.36. Also the relative macrophage positive areas did not change significantly after knocking-out IL10 as compared to IL10^{+/+} littermates (IL10^{+/+}: 2±1% and IL10^{-/-}: 3±1%, p=0.25). In addition, IL10 overexpression did not affect the relative macrophage positive areas either (IL10 overexpression: 26±5% and control: 27±5%, p=0.46).

Figure 3.2: Expression of IL10 and Luciferase after intramuscular, non-viral gene therapy. Panel A: Murine IL 10 serum levels in ng/ml, one and three weeks after intramuscular electroporation of mIL10 cDNA or Luciferase as a control (n=5 per group, *p<0.01). IL10 protein levels are significantly increased as compared to the control group after electroporation at both time points. Panel B: Representative bioluminescence images of intramuscular luciferase expression at t=7 and 21 days after electrodelivery of Luciferase. Panel C: Quantitative reproduction of luciferase expression as measured with bioluminescence imaging (n=3).



In spite of an increase of neointima formation in the IL10^{-/-} mice and a reduction of neointima formation after IL10 overexpression, differences in the relative SM α -actin positive area in the neointima were neither significant in the IL10^{-/-} mice as compared to their control littermates (IL10^{+/+}: 18±4% and IL10^{-/-}: 18±1%, p=0.50) nor in the IL10 overexpression group as compared to their controls (IL10 overexpression: 19±3%

and control: $24\pm 3\%$, $p=0.17$). The relative macrophage positive areas were also similar in the IL10 knock-out experiment (IL10^{-/-}: $9\pm 4\%$ and IL10^{-/-}: $7\pm 2\%$, $p=0.40$) and after IL10 overexpression (IL10 overexpression: $20\pm 2\%$ and control: $19\pm 3\%$, $p=0.41$).

Effect of interleukin-10 overexpression on inflammatory-related cytokines.

IL10 is known as an anti-inflammatory and atheroprotective cytokine⁵. Because inflammation is thought to play an important role in the restenotic process^{2,3}, we investigated the systemic effect of IL10 on inflammatory-related cytokines after electroporation mediated IL10 overexpression. Important inflammatory factors and mediators, like T-cells and several cytokines are matured and/or produced in the spleen. Therefore, mRNA of the spleen was isolated to assess effects of systemic IL10 overexpression. IL1 β , IL6, TNF α and IFN γ were chosen as prototypes for pro-atherogenic cytokines. As anti-inflammatory genes, IL4 and IL10 were selected. Both in the IL10 treated and in the control mice, transcriptional responses of these inflammatory related genes were determined with real-time RT-PCR, 7 and 21 days after electroporation.

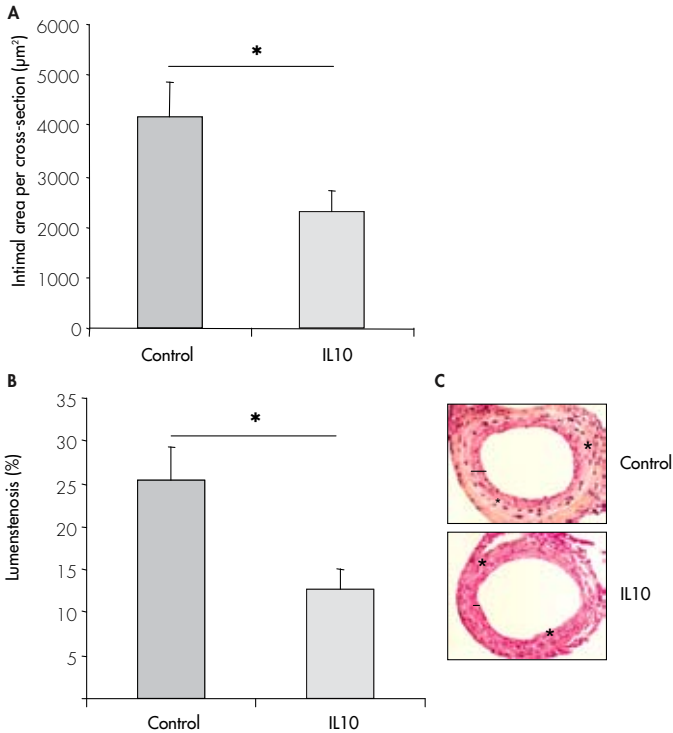
Seven days after IL10 overexpression, mRNA expression in the spleen of two important pro-atherogenic cytokines, TNF α and IL6, was strongly reduced ($55\pm 7\%$ ($p=0.006$) and $62\pm 7\%$ ($p=0.02$), respectively) in the IL10 treated group. Expression of TNF α mRNA remained low after 21 days ($40\pm 13\%$ as compared to the control group, $p=0.02$) and mRNA levels of IL6 normalized to control group level.

Both 7 as well as 21 days after electroporation, mRNA expression of IL1 β was not significantly altered. However, mRNA levels of IFN γ showed a 6.1 ± 0.2 fold increase 7 days after IL10 treatment ($p<0.001$). After three weeks, no significant difference was seen anymore in the expression of IFN γ mRNA as compared to observed levels in the control group. The mRNA expression of the anti-inflammatory gene IL10 was 3.0 ± 0.4 fold increased in the IL10 treated group as compared to the normalized control, 7 days after electroporation and surgery ($p=0.01$). Remarkable is that endogenous IL10 production in the spleen can be enhanced after exogenous administration of IL10 gene. IL10 mRNA expression normalized within 3 weeks. The levels of IL4 mRNA did not alter significantly after IL10 overexpression.

DISCUSSION

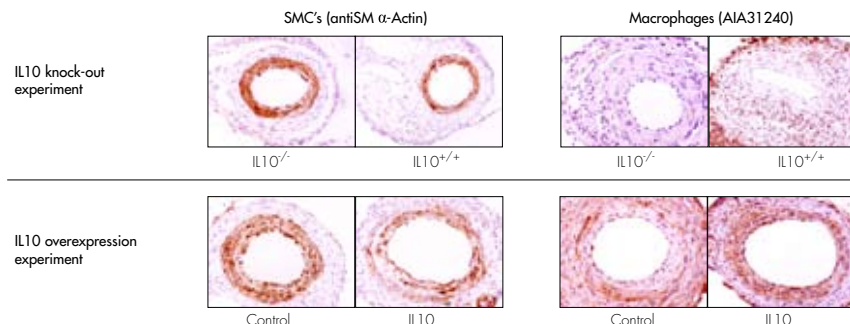
In spite of new therapies, like anti-proliferative drug eluting stents, restenosis still remains a clinical problem. For example, drug eluting stents are not that effective when applied in the femoropopliteal segment²³. Since inflammation is thought to play an important role in the development of restenosis, anti-inflammatory approaches are promising alternative strategies. IL10 is a well-known anti-inflammatory and anti-atherogenic cytokine, therefore this cytokine is attractive to use in the prevention of post-angioplasty restenosis.

Figure 3.3: Effect of IL10 overexpression on neointima formation in hypercholesterolemic ApoE3Leiden mice. Total intimal area (Panel A) and percentage of lumen stenosis (B) of cuffed femoral arteries in hypercholesterolemic ApoE3Leiden mice, three weeks after electroporation of pCAGGS-mIL10 and pCAGGS-Luciferase as a control (n=8 per group, *p<0.02). Panel C represents haematoxylin-phloxine-saffron (HPS) staining of cuffed femoral arteries after electroporation. IL10 overexpression results in a marked reduction of neointima formation (intimal area is indicated by black line and asterisks (*) indicate macrophage-derived foam cells, magnification 200x).



In this study, we demonstrate that interleukin-10 has a beneficial effect on restenosis in hypercholesterolemic mice. Knocking-out IL10 in ApoE3Leiden mice results in a 1.9-fold increase of neointima formation in the femoral artery after cuff placement. On the other hand, IL10 overexpression by non-viral gene transfer leads to a 45% reduction of neointima formation after cuff placement. Furthermore, this study shows that systemic IL10 overexpression inhibits the expression of several important pro-atherogenic cytokines and enhances the expression of endogenous IL10 mRNA in the spleen.

Figure 3.4: Effect of IL10 on relative SMC and macrophage content of medial and intimal areas. Representative cross-sections of cuffed femoral arteries of both, IL10 knock-out and IL10 overexpression experiments, immunohistochemically stained for smooth muscle cells (antiSM α -Actin) and macrophages (AIA31240). Magnification 200x.



It has previously been reported that IL10 deficiency resulted in augmented intimal hyperplasia after carotid artery wire injury in normocholesterolemic mice⁹. In our study, we crossbred ApoE3Leiden mice with IL10^{-/-} mice to generate diet-dependent hypercholesterolaemic IL10 knock-out mice and demonstrate that also the injury induced accelerated atherosclerosis is strongly reduced in the restenotic lesions. Caligiuri and colleagues described that IL10 deficiency in ApoE^{-/-} mice did increase spontaneous atherosclerosis and low-density lipoproteins, but not cholesterol levels and triglycerides²⁴. Also in ApoE3Leiden mice, after feeding a high-fat cholesterol rich diet up to six weeks, IL10 deficiency did not lead to significant higher cholesterol levels as compared to the levels in the IL10^{+/+} group. Therefore, the aggravation of neointima formation in the IL10 deficient mice is thought to be largely attributed to the lack of interleukin-10, rather than via indirect effect of IL10 such as modulation of plasma cholesterol levels.

To investigate the therapeutic potential of IL10 to prevent restenosis and post-interventional accelerated atherosclerosis in more detail, this cytokine was overexpressed by electroporation mediated non-viral gene therapy. Previous studies described the beneficial effect of IL10 protein administration on in-stent restenosis and vessel injury⁸⁻¹⁰. Also the effect of viral gene delivery of IL10 on atherosclerosis has been reported^{25;26}. These studies used either frequent protein injection or they used viral gene therapy, with all its drawbacks including the induction of an inflammatory response. None of these studies examined the effect of IL10 on restenosis in hypercholesterolemic mice. To address this issue, we used in our study single, non-viral administration of IL10 cDNA to assess the effect on cuff-induced neointima formation in hypercholesterolemic mice. With electroporation mediated non-viral gene transfer, drawbacks of daily protein administration and viral gene delivery can be prevented, while long term transgene expression can

be achieved. Luciferase and IL10 expression could be detected for at least 21 days after electroporation. A clear reduction in neointima formation and the accelerated atherosclerosis was observed (Figure 3.3).

In contrast to the IL10 knock-out experiments, the plasma cholesterol levels did alter after electroporation with the IL10 plasmid. This is in line with the findings of Von der Thüsen et. al and Yoshioka et al.^{26;27}. The latter showed that IL10 overexpression has a direct inhibitory effect on HMG-CoA reductase expression. Conversely, Namiki and colleagues did not find any differences in plasma cholesterol levels after IL10 gene transfer²⁵, probably due to differences in circulating IL10 levels after gene transfer.

Although IL10 overexpression affects plasma cholesterol levels in our study, this reduction of cholesterol levels certainly does not explain the entirely attenuation of neointima formation after IL10 overexpression. In the IL10^{-/-} mice, neointima formation increased without a significant rise of cholesterol levels. Most likely, as described in literature, the anti-inflammatory effect of IL10 contributes to the inhibitory effect of IL10 on neointima formation^{8;10}. To support this hypothesis, we assessed the effect of IL10 overexpression on several inflammatory-related cytokines. The mRNA expression of pro-inflammatory cytokines, like TNF α and IL6, was diminished after IL10 overexpression, whereas the expression of IL1 β was hardly affected. The expression of anti-inflammatory cytokine IL10 was augmented. Taken together, these data suggest that IL10 overexpression leads to a specific shift towards a Th2 phenotype. This Th2 phenotype has been reported to be more protective for inflammation related vascular remodeling^{24;28}. Nevertheless, the IFN γ response is not completely understood. In contrast to the alterations of neointima formation due to the IL10 modulation in the hypercholesterolemic ApoE3Leiden mice, the cellular composition of the neointimal area did not change as compared to their controls, i.e. the relative contribution of SMCs and macrophages was similar. Also the composition and size of the media was not affected in all groups. This suggests, next to a reducing effect on macrophages and monocytes influx, a direct inhibitory effect on smooth muscle cell activation of IL10. A similar inhibitory effect of IL10 on SMC activation was previously described and might be a result of NF-kappaB inactivation via IL10¹⁰.

Also in patients, the relationship between IL10 and restenosis becomes more and more clear. When examining the correlation of four known polymorphisms of the IL10 gene on the development of restenosis in the previously published population of the GENetic DEterminants of Restenosis (GENDER) project^{4;29} we were able to demonstrate that three out of four polymorphisms of the IL10 gene correlated with an increased risk of developing restenosis (unpublished data). Koss et al. demonstrated that one these polymorphisms was associated with decreased IL10 production³⁰. These data corroborate the hypothesis that lower levels of IL10 may increase the risk of developing restenosis.


In conclusion, in the present study we demonstrate both by knocking-out and by overexpressing the IL10 gene, that IL10 is significantly involved in the regulation

of neointima formation and accelerated atherosclerosis in hypercholesterolemic ApoE3Leiden mice. The therapeutic potential of IL 10 overexpression was demonstrated by the inhibitory effect of non-viral, electroporation mediated intramuscular delivery of IL10 cDNA on neointima formation and accelerated atherosclerosis in ApoE3Leiden mice. Because of the high and prolonged gene expression after a single intramuscular electroporation, non-viral IL10 gene delivery is a potential therapeutic approach to prevent post-angioplasty restenosis.

REFERENCES

1. Ross R. Atherosclerosis--an inflammatory disease. *N Engl J Med.* 1999;340:115-126.
2. Serrano CV, Jr., Ramires JA, Venturinelli M, Arie S, D'Amico E, Zweier JL, et al. Coronary angioplasty results in leukocyte and platelet activation with adhesion molecule expression. Evidence of inflammatory responses in coronary angioplasty. *J Am Coll Cardiol* 1997;29:1276-1283.
3. Welt FG, Rogers C. Inflammation and restenosis in the stent era. *Arterioscler Thromb Vasc Biol* 2002;22:1769-1776.
4. Monraats PS, Pires NM, Schepers A, Agema WR, Boesten LS, de Vries MR, et al. Tumor necrosis factor-alpha plays an important role in restenosis development. *FASEB J* 2005;19:1998-2004.
5. de Waal MR, Yssel H, Roncarolo MG, Spits H, de Vries JE. Interleukin-10. *Curr Opin Immunol* 1992;4:314-320.
6. Mallat Z, Besnard S, Duriez M, Deluze V, Emmanuel F, Bureau MF, et al. Protective role of interleukin-10 in atherosclerosis. *Circ Res* 1999;85:e17-e24.
7. Mallat Z, Heymes C, Ohan J, Faggin E, Leseche G, Tedgui A. Expression of interleukin-10 in advanced human atherosclerotic plaques: relation to inducible nitric oxide synthase expression and cell death. *Arterioscler Thromb Vasc Biol* 1999;19:611-616.
8. Feldman LJ, Aguirre L, Ziol M, Bridou JP, Nevo N, Michel JB, et al. Interleukin-10 inhibits intimal hyperplasia after angioplasty or stent implantation in hypercholesterolemic rabbits. *Circulation* 2000;101:908-916.
9. Zimmerman MA, Reznikov LL, Raeburn CD, Selzman CH. Interleukin-10 attenuates the response to vascular injury. *J Surg Res* 2004;121:206-213.
10. Mazighi M, Pelle A, Gonzalez W, Mtairag eM, Philippe M, Henin D, et al. IL-10 inhibits vascular smooth muscle cell activation in vitro and in vivo. *Am J Physiol Heart Circ Physiol* 2004;287:H866-H871.
11. van den Maagdenberg AM, Hofker MH, Krimpenfort PJ, de B, I, van Vlijmen B, van der BH, Havekes LM, Frants RR. Transgenic mice carrying the apolipoprotein E3-Leiden gene exhibit hyperlipoproteinemia. *J Biol Chem* 1993;268:10540-10545.
12. Lardenoye JH, Delsing DJ, de Vries MR, Deckers MM, Princen HM, Havekes LM, et al. Accelerated atherosclerosis by placement of a perivascular cuff and a cholesterol-rich diet in ApoE*3Leiden transgenic mice. *Circ Res* 2000;87:248-253.
13. Pires NM, Schepers A, van der Hoeven BL, de Vries MR, Boesten LS, Jukema JW, et al. Histopathologic alterations following local delivery of dexamethasone to inhibit restenosis in murine arteries. *Cardiovasc Res* 2005;68:415-424.
14. McMahan JM, Wells DJ. Electroporation for gene transfer to skeletal muscles: current status. *BioDrugs* 2004;18:155-165.
15. Andre F, Mir LM. DNA electrotransfer: its principles and an updated review of its therapeutic applications. *Gene Ther* 2004;11 Suppl 1:S33-S42.
16. van Vlijmen BJ, van den Maagdenberg AM, Gijbels MJ, van der BH, HogenEsch H, Frants RR, et al. Diet-induced hyperlipoproteinemia and atherosclerosis in apolipoprotein E3-Leiden transgenic mice. *J Clin Invest* 1994;93:1403-1410.
17. Kuhn R, Lohler J, Rennick D, Rajewsky K, Muller W. Interleukin-10-deficient mice develop chronic enterocolitis. *Cell* 1993;75:263-274.
18. Lardenoye JH, de Vries MR, Lowik CW, Xu Q, Dhore CR, Cleutjens JP, et al. Accelerated atherosclerosis and calcification in vein grafts: a study in APOE*3 Leiden transgenic mice. *Circ Res* 2002;91:577-584.
19. Moroi M, Zhang L, Yasuda T, Virmani R, Gold HK, Fishman MC, et al. Interaction of genetic deficiency of endothelial nitric oxide, gender, and pregnancy in vascular response to injury in mice. *J Clin Invest* 1998;101:1225-1232.

20. Nitta Y, Tashiro F, Tokui M, Shimada A, Takei I, Tabayashi K, et al. Systemic delivery of interleukin 10 by intramuscular injection of expression plasmid DNA prevents autoimmune diabetes in nonobese diabetic mice. *Hum Gene Ther* 1998;9:1701-1707.
21. McMahon JM, Signori E, Wells KE, Fazio VM, Wells DJ. Optimisation of electrotransfer of plasmid into skeletal muscle by pretreatment with hyaluronidase -- increased expression with reduced muscle damage. *Gene Ther* 2001;8:1264-1270.
22. Pillon A, Servant N, Vignon F, Balaguer P, Nicolas JC. In vivo bioluminescence imaging to evaluate estrogenic activities of endocrine disrupters. *Anal Biochem* 2005;340:295-302.
23. Palmaz JC. Intravascular stents in the last and the next 10 years. *J Endovasc Ther* 2004;11 Suppl 2:II200-II206.
24. Caligiuri G, Rudling M, Ollivier V, Jacob MP, Michel JB, Hansson GK, et al. Interleukin-10 deficiency increases atherosclerosis, thrombosis, and low-density lipoproteins in apolipoprotein E knockout mice. *Mol Med* 2003;9:10-17.
25. Namiki M, Kawashima S, Yamashita T, Ozaki M, Sakoda T, Inoue N, et al. Intramuscular gene transfer of interleukin-10 cDNA reduces atherosclerosis in apolipoprotein E-knockout mice. *Atherosclerosis* 2004;172:21-29.
26. Yoshioka T, Okada T, Maeda Y, Ikeda U, Shimpo M, Nomoto T, et al. Adeno-associated virus vector-mediated interleukin-10 gene transfer inhibits atherosclerosis in apolipoprotein E-deficient mice. *Gene Ther* 2004;11:1772-1779.
27. der Thusen JH, Kuiper J, Fekkes ML, De Vos P, Van Berkel TJ, Biessen EA. Attenuation of atherogenesis by systemic and local adenovirus-mediated gene transfer of interleukin-10 in LDLr^{-/-} mice. *FASEB J* 2001;15:2730-2732.
28. Mallat Z, Tedgui A. Immunomodulation to combat atherosclerosis: the potential role of immune regulatory cells. *Expert Opin Biol Ther* 2004;4:1387-1393.
29. Monraats PS, Pires NM, Agema WR, Zwinderman AH, Schepers A, de Maat MP, et al. Genetic inflammatory factors predict restenosis after percutaneous coronary interventions. *Circulation* 2005;112:2417-2425.
30. Koss K, Satsangi J, Fanning GC, Welsh KI, Jewell DP. Cytokine (TNF alpha, LT alpha and IL-10) polymorphisms in inflammatory bowel diseases and normal controls: differential effects on production and allele frequencies. *Genes Immun* 2000;1:185-190.



CHAPTER 4

Short-term dexamethasone treatment inhibits
vein graft thickening in hypercholesterolemic
ApoE3Leiden transgenic mice.

A. Schepers MD^{1,2}, N.M.M. Pires MSc^{1,3}, D. Eefting MD^{1,2}, M.R. de Vries BSc¹, J.H. van Bockel MD, PhD², P.H.A. Quax PhD^{1,2}

¹Gaubius Laboratory TNO Quality of Life, Leiden, The Netherlands, ²Dept. of Vascular Surgery and ³Dept. of Cardiology, Leiden University Medical Center, Leiden, The Netherlands,

Journal of Vascular Surgery 2006; 43: 809-815

ABSTRACT

Objective: The aim of this study was to assess whether the anti-inflammatory agent dexamethasone can inhibit vein graft thickening without the occurrence of serious side effects.

Methods: Venous interposition grafting was performed in the common carotid artery of hypercholesterolemic ApoE3Leiden transgenic mice. Mice were treated with dexamethasone (0.15 mg/kg/day orally) and after 28 days vein graft thickening was quantified.

Results: Treatment with dexamethasone resulted in a significant 43% reduction in lesion area without changes in lesion composition, when compared to nontreated controls. However, dexamethasone, when administered for a prolonged period of time, is known for its potential serious side-effects. To overcome these potential side-effects of prolonged dexamethasone treatment the effect of a short-term 7 days dexamethasone treatment was studied. This short dexamethasone treatment resulted in a 49% decrease of vein graft thickening at 28 days. Furthermore, it was demonstrated that dexamethasone treatment led to reduced local expression of several proinflammatory cytokines and factors in the vein grafts 24 hours after surgery. Finally, observations in mice were verified in human saphenous organ cultures. Exposure to dexamethasone for either 7 days or 28 days significantly reduced intimal hyperplasia formation on cultured saphenous vein segments.

Conclusion: Short-term anti-inflammatory treatment with dexamethasone leads to a significant reduction in vein graft thickening over an extended period, possibly by the reduction of early expression of proinflammatory cytokines. This 7-day treatment minimizes the risk of unwanted side-effects of long-term dexamethasone treatment and may be a new approach in order to prevent graft failure.

INTRODUCTION

Venous bypass grafting is the most common treatment to bypass an atherosclerotic obstruction of an artery. After grafting, a remodeling process is initiated in these veins as a consequence of the increased blood pressure and shear stress, but also by vessel injury due to surgery. This process results in the formation of intimal hyperplasia (IH) and accelerated atherosclerosis which may lead to obstruction of the graft. This process is also known as vein graft disease^{1,2}. Vein graft disease is the major cause of late graft failure, with failure rates of 10 to 40% after 1 year and 50 to 60% after 10 years³.

It has been well established that other forms of vascular remodeling- for instance atherosclerosis and post-angioplasty neointima formation- are inflammation-mediated processes⁴. However, the role of inflammation in vein graft disease is largely unknown. Morphological analysis shows that IH in a vein graft consists mainly of smooth muscle cells (SMC), macrophages and other inflammatory cells, such as T-cells. The important role of inflammatory mediators in both restenosis and atherosclerosis and the presence of inflammatory cells in vein grafts argue for a role of inflammation in vein graft disease.

Dexamethasone is known for its anti-inflammatory and antiproliferative properties and frequently used for the experimental treatment of atherosclerosis and restenosis⁵⁻⁹. Recently, clinical trials have been initiated to investigate the effect of dexamethasone in in-stent restenosis¹⁰⁻¹³.

Concerning vein graft disease, the effect of dexamethasone treatment on vein graft thickening of the vein graft is largely unknown and to our knowledge has only been studied once¹⁴. In this article the effects of dexamethasone on vein graft thickening are described. Because long-term dexamethasone treatment is accompanied by serious side effects (eg skin dystrophy, muscle atrophy, and impaired stress response), and because of its aggravating effect on spontaneous atherosclerosis development, we studied whether short-term 7 days-treatment with dexamethasone could be as efficient as continuous treatment in preventing vein graft thickening in a murine model for vein graft disease. To validate clinical relevance of the murine data, experiments were repeated in clinically relevant tissue: human saphenous vein organ cultures. In these organ cultures, the effect of both 7 days and 28 days of exposure to dexamethasone on IH formation was assessed.

MATERIALS AND METHODS

Mice.

All animal experiments were approved by the TNO animal welfare committee. For all experiments male ApoE3Leiden¹⁵ mice on a C57/BL6 background, aged between 14 and 20 weeks, were used. Animals were fed a cholesterol-enriched high-fat diet (1% cholesterol, 0.05% cholate, Arie Blok, Woerden, The Netherlands) starting 3

weeks before the beginning of each experiment. All mice received water and food *ad libitum*. Serum cholesterol levels were determined 1 week before the start of the experiment and at death. Before surgery, mice were anesthetized with Midazolam (5 mg/kg, Roche, Basel, Switzerland), Medetomidine (0.5 mg/kg, Orion, Helsinki, Finland), and Fentanyl (0.05 mg/kg, Janssen, Geel, Belgium).

Dexamethasone treatment.

For all experiments, mice were randomly divided in two groups. One group received approximately 0.15mg/kg/day dexamethasone dissolved in the drinking water (based on a daily water intake of 3 ml per mouse) throughout the entire experiment, starting one day before the start of each experiment.

Carotid vein graft model.

Mice were either treated with dexamethasone or received no treatment and served as controls (n=6 in both groups). A venous interposition in the carotid artery was placed in each mouse as described previously¹⁶. In brief, the right common carotid artery of the recipient was dissected free from its surroundings from the bifurcation at the distal end towards the proximal end. The artery was cut in the middle and ligated with an 8.0 silk suture. The caval veins were harvested from genetically identical donor mice and grafted between the 2 ends of the carotid artery by sleeving the ends of the vein over the artery cuff and ligating them together with an 8.0 silk suture. At death, animals were perfused *in vivo* with 4% formaldehyde for 5 minutes. Vein grafts were harvested and fixed overnight in 4% formaldehyde, dehydrated, and embedded in paraffin.

Quantification of vein graft thickening and immunohistochemistry.

Twenty-eight days after surgery, mice were sacrificed as described above, and vein grafts were harvested and embedded in paraffin. Serial cross-sections of the embedded vein graft were made through the entire specimen and routinely stained with hematoxylin-phloxin-saffron (HPS). Using serial cross-sections for the analysis, overestimation or underestimation of treatment effect due to a non-equally distributed occurrence of vein graft thickening (as we see both in human vein grafts as in our murine vein graft interpositions) is prevented.

Measurement of vein graft thickening in the samples was performed using image analysis software (Qwin, Leica, Wetzlar, Germany). Because only very few layers of cells are in the media of murine veins and because there is no morphological border between the neointima and media, vein graft thickening, i.e., the region between the lumen and adventitia, was used to define the lesion area. For each mouse five equally spaced perpendicular cross-sections were used to determine the vessel wall thickening.

All immunohistochemistry was performed on paraffin-embedded sections of vein grafts 28 days after surgery. The cellular composition of the thickened vein grafts was visualized by using antibodies against macrophages (AIA31240, Accurate Chemical, Westbury, USA), T-cells (CD3, Serotec, Oxford, UK) and vascular SMC (α -smooth muscle actin, Amersham, Buckinghamshire, UK). The amount of SMC and

macrophages was quantified by computed-assisted morphometric analysis (Qwin), and expressed as the percentage of total smooth muscle actin-positive or AIA-positive area in cross-sections. T-cell number was determined by counting CD3-positive cells in the vessel wall of 6 equally spaced cross-sections per vein graft and divided by vessel wall surface in these cross-sections.

Prolonged dexamethasone exposure and analysis of general well-being and atherosclerosis.

Side-effects of prolonged Dexamethasone treatment, including spontaneous atherosclerosis, were studied in mice (n=15) that received dexamethasone treatment 0.15 mg/kg/day for 25 weeks. A group of littermates (n=15) not exposed to dexamethasone served as control. Mice were extensively observed with regards to daily activity, fur quality, and infections. All mice were sacrificed after 25 weeks as described above. The aortic root and the heart were collected for histological analysis, as these locations were previously identified as atherosclerotic-prone regions¹⁷.

The hearts were dissected, stored overnight in phosphate-buffered 3.8% formalin fixation and embedded in paraffin. Serial cross sections (5µm thick) throughout the entire aortic valve area were used for histological analysis. Sections were routinely stained with HPS. Per mouse, 4 sections with 30 µm intervals were used for quantification of atherosclerotic lesion area. Lesion area was determined using morphometric software (Qwin).

Human saphenous vein (HSV) organ culture.

Segments of saphenous veins, obtained from patients undergoing saphenous vein stripping, (provided by Dr. H. Stigter, Deaconess Hospital, Leiden, The Netherlands) were used for these cultures. Healthy looking segments of the stripped veins were put into culture as previously described^{18,19}. Segments (n=4 per group) were exposed to dexamethasone (0.75 mg/ml medium) for either 7 or 28 days, or served as controls. After 28 days, segments were harvested, fixed overnight in formaldehyde (4%) and embedded in paraffin. All segments were routinely stained by HPS and neointimal surface was assessed on multiple sections (n=9 per vein segment) and quantified using Qwin Image analysis software.

Messenger RNA isolation, cDNA synthesis and real time RT-PCR.

To obtain vein grafts for Messenger RNA isolation (mRNA) isolation, mice (n=4 per group) were either treated with dexamethasone or received no treatment and were sacrificed one day after vein graft surgery. At sacrifice, mice were perfused with NaCl 0.9%, after which the vein grafts were harvested and snap-frozen. Total RNA was isolated using the RNeasy Mini Kit for Fibrous tissue (Qiagen, Venlo, The Netherlands) and DNA contamination was excluded with an on-column DNase treatment (Qiagen). Synthesis of cDNA was performed by using 250 ng mRNA and Ready-To-Go Beads (Amersham Biosciences) according to the manufacturer's protocol.

Intron-spanning primer-probe sets were designed using Primer Express™ 1.5 software (Applied Biosystems, Foster City, USA) for MCP-1, MIP-1 α , TNF- α , CD14 and TLR-4 (for sequences, Table 4.1). GAPDH was used as a housekeeping gene. The PCR reaction was performed using qPCR Mastermix (Eurogentec, Seraing, Belgium). Analysis of mRNA expression by real time RT-PCR was performed on an ABI Prism™ 7700 sequence detection system (Perkin Elmer Biosystems, Boston, USA).

For analysis, cycle threshold of the gene of interest was subtracted from the cycle threshold of the housekeeping gene GAPDH (Δ Ct). $\Delta\Delta$ Ct was determined as the difference between Δ Ct-values of the Dexamethasone-treated vein grafts and the normalized Δ Ct-value of vein grafts in the control group (being the average of Δ Ct-values in the control group). Data are presented as relative expression of all genes in the Dexamethasone-treated group calculated as $1/(2^{-\Delta\Delta Ct})$. In this presentation, mRNA expression of all genes in the control group is defined as 1.

Statistical analysis.

Before the start of each experiment a power analysis was made to obtain a statistically sound study. Data are presented as mean \pm SEM. Comparisons of morphometric data of murine vein grafts and RT-PCR data were performed with the Mann-Whitney rank sum test. Morphometric data of IH in human saphenous veins were compared with a paired Student T-test. P-values $<.05$ were considered statistical significant.

RESULTS

Continuous dexamethasone treatment inhibits vein graft thickening in a murine vein graft model.

The effect of dexamethasone on vein graft thickening was studied in ApoE3Leiden mice. Six mice received dexamethasone (0.15mg/kg/day) during the complete experimental period, starting 1 day before surgery and six mice served as controls. Mice were sacrificed after 28 days. Preoperative plasma cholesterol levels did not differ between the Dexamethasone and control group. However a modest, yet not significant increase in plasma cholesterol was seen in the dexamethasone-treated group at time of sacrifice (dexamethasone: before surgery 13.8 ± 1.26 mmol/L, at sacrifice 15.4 ± 1.28 mmol/L vs control: before surgery 12.7 ± 1.08 mmol/L, at sacrifice 12.7 ± 3.2 mmol/L). During the experiment four out of six mice receiving dexamethasone treatment did not gain weight, compared to one out of six in the control group. In the dexamethasone-treated group, thrombosis occurred in one vein graft and this vein graft was excluded from analysis.

Quantification of vein graft thickening showed a 43% reduction in the dexamethasone-treated group, compared with the control group (0.32 ± 0.04 mm² vs 0.56 ± 0.12 mm²; P=.028; Figure 4.1, panel A+B). Luminal area did not differ between the two treatment groups (dexamethasone 0.78 ± 0.1 mm², control 0.75 ± 0.08 mm², P=.75). The cellular composition of the thickened graft was not significantly different between the two groups, as analyzed by immunohistochemistry. The thickened

vein grafts were mainly composed of SMCs and macrophages. Furthermore, small numbers of T-cells were present in the vessel wall. The AIA-positive area, reflecting macrophages, was $20.8 \pm 3.5\%$ in the control group, compared to $22.7 \pm 3.3\%$ in the dexamethasone-treated group (Figure 4.1, panel D). The α -SM-actin positive area, reflecting vascular SMCs, was $39.3 \pm 7.2\%$ in the control group as compared to $40.6 \pm 4.2\%$ in the treated group (Figure 4.1, panel C). Also, the number of T-cells did not differ significantly between the groups (control: 6.20 ± 0.68 cells/mm²; dexamethasone: 5.79 ± 1.77 cells/mm²).

Prolonged dexamethasone treatment is accompanied by clinical side effects and increase spontaneous atherosclerosis in mice.

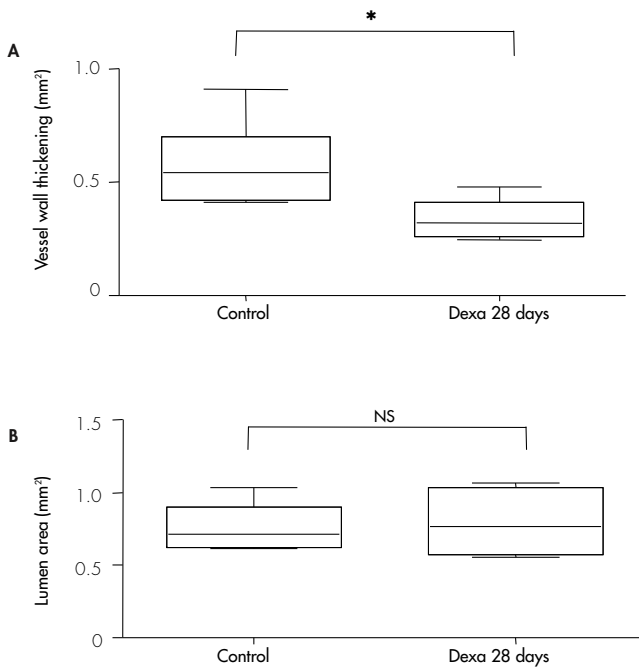
To study whether the slight increase in serum cholesterol and failure to gain weight in the dexamethasone-treated animals above, can be addressed as the start of adverse effects of dexamethasone, we next evaluated the effect of long-term exposure to dexamethasone in mice.

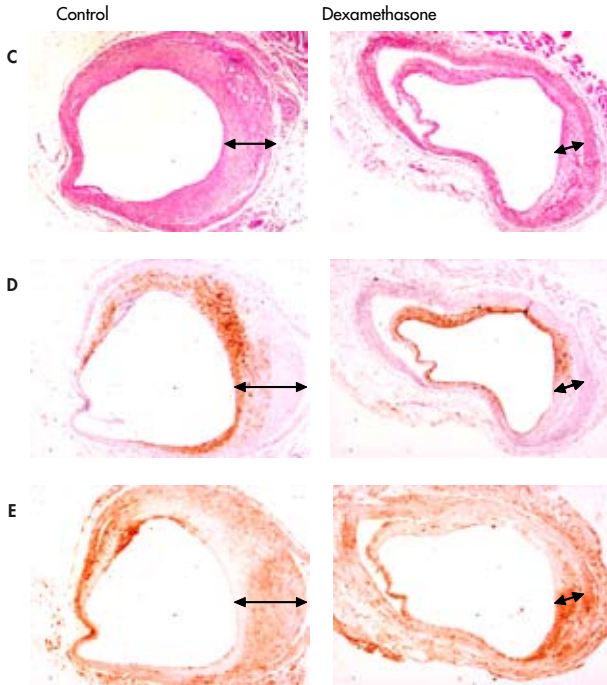
Therefore, ApoE3Leiden mice receiving a cholesterol-enriched diet were randomly divided in two groups. One group (n=15) was treated for 25 weeks with dexamethasone. During the course of this 25 weeks period, animals in the dexamethasone-treated group progressively showed several side-effects of the use of dexamethasone. Four mice revealed signs of infection and were terminated. Animals treated with dexamethasone gained less weight, leading to differences in body weight at time of sacrifice (25.3 ± 1.9 g vs 30.6 ± 2.8 g, $P < .001$). Serum cholesterol levels increased significantly in the dexamethasone-treated animals (33.7 ± 7.4 mmol/l), compared to the control group (15.0 ± 3.3 mmol/l, $P < .001$). Furthermore, dexamethasone-treated animals expressed reduced daily activity and had impaired fur quality. Moreover, dexamethasone treatment resulted in a 4.7-fold increase in atherosclerotic plaque area in the aortic root (dexamethasone treated 0.461 ± 0.199 mm²; control 0.098 ± 0.047 mm², $P < .001$).

Short-term 7 day treatment with dexamethasone reduces vein graft thickening.

Because long-term treatment with dexamethasone is accompanied by serious side-effects, the effect of short-term dexamethasone treatment on vein graft thickening was assessed. Six ApoE3Leiden mice underwent vein graft surgery and were treated for 1 week with dexamethasone, after which dexamethasone was withdrawn and mice were allowed to drink normal drinking water. The control group consisted of mice that underwent vein graft surgery and were not exposed to dexamethasone. After 4 weeks vessel wall thickness was determined. No difference was seen in plasma cholesterol levels and animal weight before to surgery and at time of sacrifice (data not shown). A reduction of vein graft thickening was seen in the vein grafts of the dexamethasone-treated mice (0.25 ± 0.07 mm²): there was a decrease of 49% when compared with the control group (0.62 ± 0.11 mm², $P = .04$; Figure 4.2). Luminal area did not differ significantly in both groups (Dexamethasone: 0.67 ± 0.09 mm², control 0.75 ± 0.08 mm², $P = .75$). Furthermore, the lesions of 7 days-treated animals showed a similar morphology as those of the group treated for 28 days with dexamethasone.

Figure 4.1: Dexamethasone treatment (0.15mg/kg/day in drinking water) reduces vein graft thickening in hypercholesterolemic ApoE3-Leiden mice after 28 days of treatment. Panel A: Quantification of vein graft thickening shows a reduction of 43% in the dexamethasone-treated animals, as compared to controls (n=6, * represents $P < .05$), whereas no significant changes in luminal area were observed (Panel B). Panel C: Representative cross-section, arrows indicate thickened vessel wall (HPS staining, magnification 40x). No differences are seen in the cellular composition of thickened grafts in both groups, as determined by computer-assisted morphometric analysis. Panel D: α -SM-actin staining representing vascular SMC. Panel E: AIA31240 staining representing macrophages.



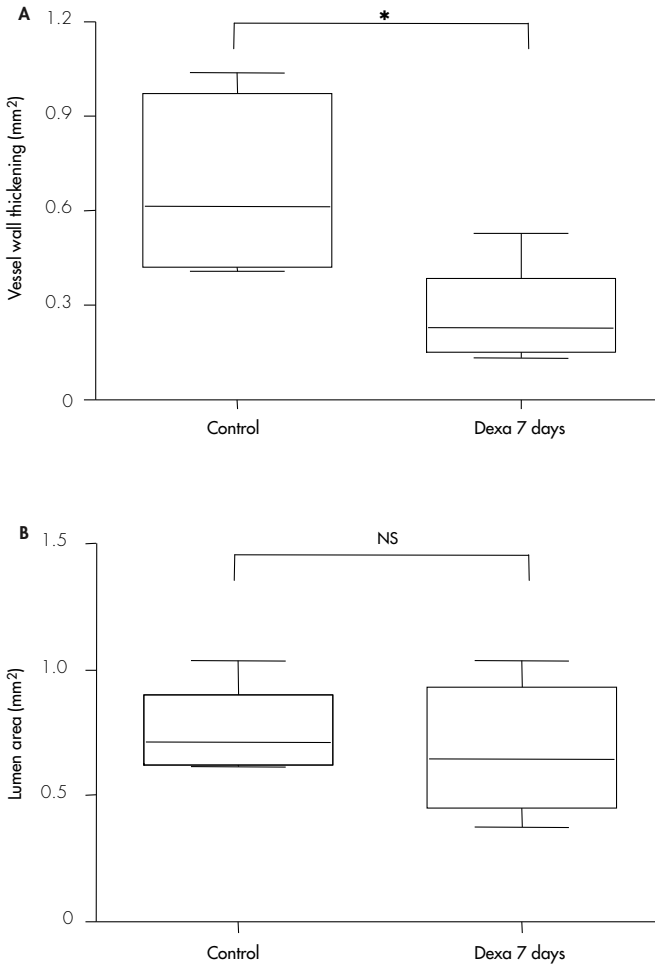


Effect of Dexamethasone on early expression of pro-atherogenic cytokines.

Because short-term dexamethasone treatment results in reduced graft thickening on the long term, we hypothesized that dexamethasone might reduce early expression of proinflammatory cytokines in the remodeling vein grafts and thereby hampers the initiation of the remodeling process in the vein grafts. To study this hypothesis, mRNA analysis of both dexamethasone-treated and control vein grafts was performed.

The effect of dexamethasone treatment on the early expression of several proinflammatory cytokines and inflammatory markers was studied in vein grafts, either dexamethasone-treated and control, harvested 24 hours after surgery. This time frame was chosen since previous data show that cytokines are rapidly upregulated in time (being hours after surgery; data not shown). The cytokines and inflammatory markers used in this experiment were selected on their involvement in the process of atherosclerosis or restenosis²⁰⁻²⁵.

Figure 4.2: Effect of 7 days dexamethasone treatment on vein graft thickening 28 days after surgery in hypercholesterolemic ApoE3-Leiden mice. Significant inhibition of vein graft thickening in the 7 days-treated animals (Panel A), when compared to controls (n=6, * represents $P<.05$). No significant difference in luminal area between the two groups (Panel B, n.s. represents not significant).



The proinflammatory cytokines TNF- α and MIP-1 α were significantly downregulated in vein grafts of dexamethasone-treated animals when compared to control vein grafts. The relative expression of TNF- α : in the dexamethasone group was 0.15 ± 0.07 ($P=.021$), that of MIP-1 α 0.12 ± 0.06 ($P=.029$). Another potent pro-atherogenic cytokine, MCP-1, showed a modest, yet not significant, down-regulation in the dexamethasone-treated vein grafts, with a relative expression of 0.32 ± 0.06 ($P=.25$). Dexamethasone treatment also resulted in decreased expression of TLR-4

(relative expression 0.036 ± 0.05 ; $P=0.21$) and its cofactor CD14 (relative expression 0.26 ± 0.08 ; $P=0.43$; Figure 4.3).

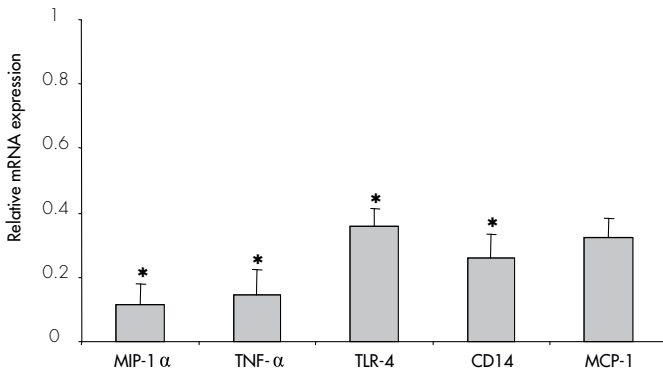
Effect of both continuous and short-term dexamethasone exposure on IH formation in human saphenous vein cultures.

To determine whether the murine in vivo vein graft model reacts in a similar way on stimuli as clinically relevant human tissue, we used human saphenous vein organ cultures to study the effects of dexamethasone exposure on the development of IH.

Human saphenous vein organ cultures were exposed for either 7 or 28 days to dexamethasone in the medium (0.75mg/ml) and compared them with untreated control segments.

Both 7 days as 28 days of exposure to dexamethasone resulted in a marked reduction of IH formation (Figure 4.4). In the untreated control veins IH surface was $0.059\pm 0.006\text{mm}^2$, whereas in the segments that underwent 28 days exposure to dexamethasone, IH was $0.014\pm 0.002\text{mm}^2$ ($P=0.006$). Short-term treatment by 7 days exposure to dexamethasone, resulted in lowered IH formation of $0.018\pm 0.002\text{mm}^2$ ($P=0.021$ when compared to untreated vessels, $p=0.19$ when compared to 28 days treated vessels).

Figure 4.3: Effect of dexamethasone treatment on the early mRNA expression of pro-inflammatory cytokines in injured vessels of ApoE3-Leiden mice ($n=4$ per group). Relative mRNA expression in time in the dexamethasone-treated group is depicted compared to mRNA expression the control group (expression in control group defined as "1", * represents $P<0.05$).



DISCUSSION

This study shows that short-term anti-inflammatory therapy using dexamethasone inhibits vein graft thickening in venous bypass grafts over an extended period of time. It is well appreciated that atherosclerosis and other forms of vascular remodeling, such

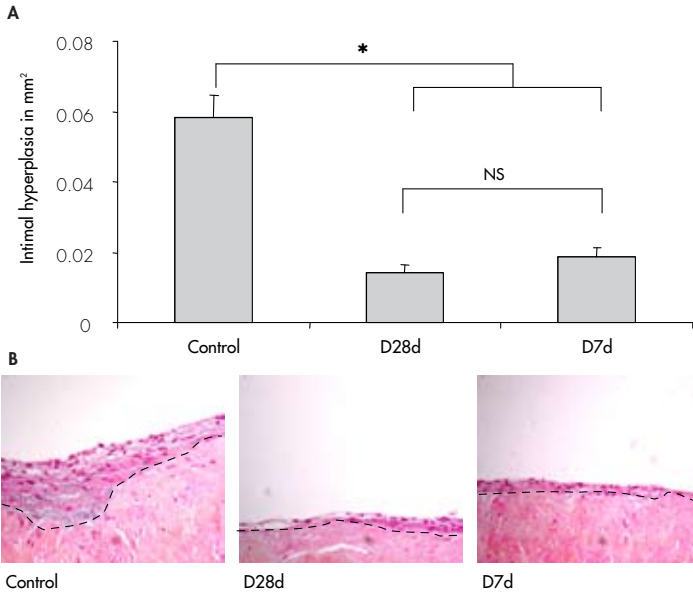
as postangioplasty neointimal formation and vein graft disease are inflammatory-mediated processes. Extending this observation to the clinical situation, it is obvious that some of the commonly used anti-inflammatory agents would deserve further investigation in this respect. One of the most widely used anti-inflammatory agents is the group of corticosteroids, commonly used for several diseases like rheumatoid arthritis, inflammatory bowel disease, organ transplantation and chronic obstructive pulmonary disease.

Several pre-clinical studies describe the effect of corticosteroids on postangioplasty restenosis. The effect of dexamethasone has often been studied in various *in vitro* and animal models for postinterventional neointima formation^{5,7,9,26,27}. Most animal studies show a decrease in neointimal formation in the dexamethasone-treated group. Even though it is well known that corticosteroid therapy is associated with several side-effects, these findings led to the initiation of several clinical studies to assess the beneficial effect of corticosteroid therapy on the development of in-stent restenosis; most of them are still ongoing. Two studies have been recently published that describe the effect of dexamethasone-eluting stents. Liu et al. showed that implantation of a dexamethasone-coated stent is safe and feasible¹². Recently another clinical study was published. Hoffmann et al. did not observe any beneficial effects of the dexamethasone-coated stent on the development of restenosis¹⁰. Two other studies have been published about the effect of oral corticosteroid treatment on the development of in stent restenosis with conflicting results. Versaci et al. report a striking decrease in restenosis rate in patients with persistently high CRP levels when treated with oral immunosuppressive therapy with prednisone¹³. The article of Lee et al. did not describe any beneficial effect on restenosis rate when patients were pre-treated with a single dose methylprednisolone¹¹.

Whereas the effect of corticosteroids on post-angioplasty neointimal formation is being thoroughly studied, the effect of corticosteroids on vein graft thickening is unknown. To our knowledge only one study describes a beneficial effect of dexamethasone treatment on vein graft thickening in rats¹⁴. However, this is not a hypercholesterolemic model and the thickened graft consisted mainly of SMCs, whereas in patients graft lesions consist of SMCs, macrophages and T-cells. In the study described in this article, we used hyperlipidemic ApoE3Leiden mice in a model of vein graft disease that highly resembles the morphology of human restenotic vein grafts.

In this model, we demonstrate that continuous treatment with dexamethasone for 28 days causes a significant reduction in vein graft thickening, without altering the cellular composition of the thickened vessel wall. An outward remodeling was seen in these vein grafts, which could be attributed to the fact that the vessel wall of the graft is initially very thin, and consists just a few cell layers. Hyperplasia results in vessel wall thickening, which will principally be outwards directed.

Figure 4.4: Effect of either short-term (D7d) or prolonged (D28d) dexamethasone exposure (0.75mg/ml medium) in IH formation in human saphenous vein organ cultures (n=12 per group). In both dexamethasone exposed groups a significantly lowered amount of IH was seen, when compared to the control segments (* represents $P < .05$, magnification 100x, dotted line indicates border separating media from intima).



However, prolonged dexamethasone treatment is known to be accompanied by serious side effects, like an impaired immune response, osteoporosis and an increased risk of atherosclerotic events (probably due to dyslipidemia)^{28,29} in humans. Moreover, although in the 28-day period of the vein graft experiment an effective inhibition of vein graft thickening was observed, the first signs of negative side-effects were detectable in the treated mice: these were failure to gain weight and slightly increased plasma cholesterol levels.

To prove that the occurrence of these clinical features was caused by dexamethasone treatment, we included an experiment in which ApoE3Leiden mice were treated with the same dose of dexamethasone as in the vein graft experiments, but for a prolonged period of time. The response of the animals to dexamethasone treatment highly mimicked what is seen in patients: an impaired well-being, infections and, most strikingly, increased atherosclerosis in the aortic root was observed.

To analyze whether the potential problem of unwanted side effects can be avoided, we tested whether a short treatment with dexamethasone (7 days) directly after surgery was as effective as a continuous treatment. A 49% reduction in vein graft thickening after a 7-day treatment with dexamethasone was observed that was comparable

to the reduction after a 28 days treatment. These data indicate that short-term dexamethasone treatment directly after surgery has the same potential to reduce graft thickening as a prolonged treatment.

This information is of great importance for eventual clinical application, since limiting duration of dexamethasone treatment may avoid potential side effects.

To gain further insight in the mechanism of how short-term dexamethasone treatment can result in a long-time reduction of vein graft thickening, we studied the hypothesis that dexamethasone hampers vein graft thickening by inhibiting early proinflammatory cytokine expression. Indeed, significant reduction mRNA expression of several proinflammatory cytokines could be detected in the dexamethasone-treated vein grafts.

Despite of a reduction in expression of proinflammatory cytokines, dexamethasone treatment did not result in a decreased macrophage content in the thickened grafts. This is in contrast with previous reports of Asai et al.⁵, who describes a reduction in macrophage content in atherosclerotic tissue of cholesterol-fed rabbits. A possible explanation for this difference might be the fact that dexamethasone also reduces SMC proliferation³⁰, and thereby keeps the balance between macrophages and SMCs in the vein graft unchanged.


As a final experiment and to study whether our findings in mice can be extrapolated to human tissue, we repeated the experiments in human saphenous vein organ cultures. Like the short-term dexamethasone treatment in murine vein grafts, IH formation was hampered in the vessel segments that were exposed to dexamethasone for 7 days. The fact that in the saphenous vein organ cultures IH is mainly a SMC proliferation-driven process underscores the effect of dexamethasone on SMCs proliferation as discussed above.

In conclusion, this study demonstrated that short-term dexamethasone treatment leads to a reduction of lesion area both in vein grafts in mice and in human saphenous organ cultures, thereby minimizing the risk of unwanted systemic side-effects that occur in prolonged dexamethasone treatment. Therefore, this approach might be suitable for further exploration in patients to reduce the risk of vein graft stenosis due to IH and accelerated atherosclerosis. However, as we learned from previous clinical trials for postinterventional restenosis, more research is necessary to obtain more insight about the optimal dose and treatment period.

REFERENCES

1. Motwani JG, Topol EJ. Aortocoronary saphenous vein graft disease: pathogenesis, predisposition, and prevention. *Circulation* 1998; 97(9):916-931.
2. Bourassa MG, Campeau L, Lesperance J, Grondin CM. Changes in grafts and coronary arteries after saphenous vein aortocoronary bypass surgery: results at repeat angiography. *Circulation* 1982; 65(7 Pt 2):90-97.
3. Bush HL, Jr., Jakubowski JA, Curl GR, Deykin D, Nabseth DC. The natural history of endothelial structure and function in arterialized vein grafts. *J Vasc Surg* 1986; 3(2):204-215.
4. Ross R. Atherosclerosis--an inflammatory disease. *N Engl J Med* 1999; 340(2):115-126.
5. Asai K, Funaki C, Hayashi T, Yamada K, Naito M, Kuzuya M *et al.* Dexamethasone-induced suppression of aortic atherosclerosis in cholesterol-fed rabbits. Possible mechanisms. *Arterioscler Thromb* 1993; 13(6):892-899.
6. Petrik PV, Law MM, Moore WS, Colburn MD, Quinones-Baldrich W, Gelabert HA. Dexamethasone and enalapril suppress intimal hyperplasia individually but have no synergistic effect. *Ann Vasc Surg* 1998; 12(3):216-220.
7. Poon M, Gertz SD, Fallon JT, Wiegman P, Berman JW, Sarembock IJ *et al.* Dexamethasone inhibits macrophage accumulation after balloon arterial injury in cholesterol fed rabbits. *Atherosclerosis* 2001 Apr; 155(2):371-80 155(2):371-380.
8. Van Put DJ, Van Hove CE, De Meyer GR, Wuyts F, Herman AG, Bult H. Dexamethasone influences intimal thickening and vascular reactivity in the rabbit collared carotid artery. *Eur J Pharmacol* 1995; 294(2-3):753-761.
9. Villa AE, Guzman LA, Chen W, Golomb G, Levy RJ, Topol EJ. Local delivery of dexamethasone for prevention of neointimal proliferation in a rat model of balloon angioplasty. *J Clin Invest* 1994; 93(3):1243-1249.
10. Hoffmann R, Langenberg R, Radke P, Franke A, Blindt R, Ortlepp J *et al.* Evaluation of a high-dose dexamethasone-cluting stent. *Am J Cardiol* 2004; 94(2):193-195.
11. Lee CW, Chae JK, Lim HY, Hong MK, Kim JJ, Park SW *et al.* Prospective randomized trial of corticosteroids for the prevention of restenosis after intracoronary stent implantation. *Am Heart J* 1999; 138(1 Pt 1):60-63.
12. Liu X, Huang Y, Hanet C, Vandormael M, Legrand V, Dens J *et al.* Study of antirestenosis with the BiodivYsio dexamethasone-cluting stent (STRIDE): a first-in-human multicenter pilot trial. *Catheter Cardiovasc Interv* 2003; 60(2):172-178.
13. Versaci F, Gasparidone A, Tomai F, Ribichini F, Russo P, Proietti I *et al.* Immunosuppressive Therapy for the Prevention of Restenosis after Coronary Artery Stent Implantation (IMPRESS Study). *J Am Coll Cardiol* 2002; 40(11):1935-1942.
14. Norman PE, House AK. Influence of dexamethasone on intimal thickening in experimental vein graft. *Cardiovasc Surg* 1993; 1(6):724-728.
15. van den Maagdenberg AM, Hofker MH, Krimpenfort PJ, de B, I, van Vlijmen B, van der BH *et al.* Transgenic mice carrying the apolipoprotein E3-Leiden gene exhibit hyperlipoproteinemia. *J Biol Chem* 1993; 268(14):10540-10545.
16. Lardenoye JH, de Vries MR, Grimbergen JM, Havekes LM, Knaapen MW, Kockx MM *et al.* Inhibition of accelerated atherosclerosis in vein grafts by placement of external stent in ApoE3Leiden transgenic mice. *Arterioscler Thromb Vasc Biol* 2002; 22(9):1433-1438.
17. Gijbels MJ, van der CM, van der Laan LJ, Emeis JJ, Havekes LM, Hofker MH *et al.* Progression and regression of atherosclerosis in APOE3-Leiden transgenic mice: an immunohistochemical study. *Atherosclerosis* 1999; 143(1):15-25.
18. Soyombo AA, Angelini GD, Bryan AJ, Jasani B, Newby AC. Intimal proliferation in an organ culture of human saphenous vein. *Am J Pathol* 1990; 137(6):1401-1410.
19. Quax PH, Lamfers ML, Lardenoye JH, Grimbergen JM, de Vries MR, Slomp J *et al.* Adenoviral expression of a urokinase receptor-targeted protease inhibitor inhibits neointima formation in murine and human blood vessels. *Circulation* 2001; 103(4):562-569.
20. Pasterkamp G, Van Keulen JK, de Kleijn DP. Role of Toll-like receptor 4 in the initiation and progression of atherosclerotic disease. *Eur J Clin Invest* 2004; 34(5):328-334.
21. Shimada K, Miyachi K, Mokuno H, Watanabe Y, Iwama Y, Shigeikiyo M *et al.* Promoter polymorphism in the CD14 gene and concentration of soluble CD14 in patients with in-stent restenosis after elective coronary stenting. *Int J Cardiol* 2004; 94(1):87-92.
22. Aiello RJ, Bourassa PA, Lindsey S, Weng W, Natoli E, Rollins BJ *et al.* Monocyte chemoattractant protein-1 accelerates atherosclerosis in apolipoprotein E-deficient mice. *Arterioscler Thromb Vasc Biol* 1999; 19(6):1518-1525.

23. Reape TJ, Groot PH. Chemokines and atherosclerosis. *Atherosclerosis* 1999; 147(2):213-225.
24. van Royen N, Hoefler I, Bottinger M, Hua J, Grundmann S, Voskuil M *et al.* Local monocyte chemoattractant protein-1 therapy increases collateral artery formation in apolipoprotein E-deficient mice but induces systemic monocytic CD11b expression, neointimal formation, and plaque progression. *Circ Res* 2003; 92(2):218-225.
25. Zimmerman MA, Selzman CH, Reznikov LL, Miller SA, Raeburn CD, Emmick J *et al.* Lack of TNF-alpha attenuates intimal hyperplasia after mouse carotid artery injury. *Am J Physiol Regul Integr Comp Physiol* 2002; 283(2):R505-R512.
26. Bailey JM, Butler J. Anti-inflammatory drugs in experimental atherosclerosis. I. Relative potencies for inhibiting plaque formation. *Atherosclerosis* 1973; 17(3):515-522.
27. Pires NM, Schepers A, van der Hoeven BL, de Vries MR, Boesten LS, Jukema JW *et al.* Histopathologic alterations following local delivery of dexamethasone to inhibit restenosis in murine arteries. *Cardiovasc Res* 2005 (68): 215-224.
28. Kalbak K. Incidence of arteriosclerosis in patients with rheumatoid arthritis receiving long-term corticosteroid therapy. *Ann Rheum Dis* 1972; 31(3):196-200.
29. Nashel DJ. Is atherosclerosis a complication of long-term corticosteroid treatment? *Am J Med* 1986; 80(5):925-929.
30. Voisard R, Seitzer U, Baur R, Dartsch PC, Osterhues H, Hoher M *et al.* Corticosteroid agents inhibit proliferation of smooth muscle cells from human atherosclerotic arteries in vitro. *Int J Cardiol* 1994; 43(3):257-267.



CHAPTER 5

Anti-MCP-1 gene therapy inhibits vascular smooth muscle cells proliferation and attenuates vein graft thickening both in vitro and in vivo.

A. Schepers*^{1,2}, D. Eefting*^{1,2}, P.I. Bonta³, J.M. Grimbergen¹, M.R. de Vries¹, V. van Weel^{1,2}, C. J. de Vries³, K. Egashira⁴, J.H. van Bockel², P.H.A. Quax^{1,2}

¹Gaubius laboratory TNO-Quality of Life, Leiden, The Netherlands; ²Department of Vascular Surgery, Leiden University Medical Centre, Leiden, The Netherlands; ³Department of Medical Biochemistry, Academic Medical Center, Amsterdam, The Netherlands, ⁴Graduate School of Medical Sciences, Kyushu University, Fukuoka, Japan,

*Both authors contributed equally to this study

Arteriosclerosis Thrombosis and Vascular Biology 2006; 26: 2063-2069

ABSTRACT

Objective:

Since late vein graft failure is caused by intimal hyperplasia (IH) and accelerated atherosclerosis, and these processes are thought to be inflammation driven, influx of monocytes is one of the first phenomena seen in IH, we would like to provide direct evidence for a role of the MCP-1 pathway in the development of vein graft disease.

Methods and Results:

MCP-1 expression is demonstrated in various stages of vein graft disease in a murine model in which venous interpositions are placed in the carotid arteries of hypercholesterolemic ApoE3Leiden mice and in cultured human saphenous vein (HSV) segments in which IH occurs.

The functional involvement of MCP-1 in vein graft remodeling is demonstrated by blocking the MCP-1 receptor CCR-2 using 7ND-MCP-1. 7ND-MCP1 gene transfer resulted in 51% reduction in IH in the mouse model, when compared to controls. In HSV cultures neointima formation was inhibited by 53%.

In addition, we demonstrate a direct inhibitory effect of 7ND-MCP-1 on the proliferation of smooth muscle cell (SMC) in HSV cultures and in SMC cell cultures.

Conclusion:

These data, for the first time, prove that MCP-1 has a pivotal role in vein graft thickening due to intimal hyperplasia and accelerated atherosclerosis.

INTRODUCTION

Venous bypass grafting is a common treatment for occlusive atherosclerotic vascular disease and establishes revascularization of ischemic tissue. Unfortunately, although primarily successful, it is accompanied by a high incidence of late graft failure (up to 40% after 10 years¹), leading to a high morbidity and mortality due to re-interventions.

Graft failure is mainly due to vein graft thickening due to intimal hyperplasia (IH) and accelerated atherosclerosis. It occurs as a response to altered shear and circumferential stress and loss of endothelial integrity caused by surgery². The process starts with monocyte adhesion and extravasation into the vessel wall, followed by smooth muscle cell (SMC) migration and proliferation, and macrophage accumulation in the intima³. Subsequently, lipids accumulate in macrophages resulting in foam-cell formation. Because of the high resemblance with atherosclerotic plaques, this is called accelerated atherosclerosis of the vein graft^{1,4,5}.

Several animal models have been developed to study vein graft thickening, including a venous interposition model in the mouse carotid artery⁶. Here, this venous interposition model was used in ApoE3Leiden mice. ApoE3Leiden mice contain the mutant human ApoE3Leiden gene, which leads to a defective clearance of ApoE by the LDL receptor, and therefore these mice develop a diet-dependent hyperlipidemia and diet-induced atherosclerosis⁷. When a venous interposition is placed in the carotid artery of these mice, venous thickening with signs of accelerated atherosclerosis develops within 4 weeks^{6,8}, highly resembling the morphology of the diseased human vein grafts.

Although the exact mechanism of vein graft thickening is unknown, accumulating evidence suggests that it is an inflammation-driven process^{9,10}. Monocyte chemoattractant protein-1 (MCP-1) and its receptor CCR2 are key mediators in vascular inflammation, acting as one of the most potent chemotactic agents to monocytes^{11,12}. MCP-1 has been shown to play a pivotal role in spontaneous atherosclerosis and post-angioplasty restenosis. Recently it has been described that blocking of the MCP-1/CCR2 pathway results in reduced atherosclerosis and restenosis by inhibition of monocyte adhesion to the vascular wall and to reduced macrophage content in the atherosclerotic lesion¹³⁻¹⁶. Because of the similarities between restenosis and vein graft disease, we hypothesize that MCP-1 may play a pivotal role in development of vein graft disease.

To prove this hypothesis we use 7ND-MCP-1, a competitive receptor antagonist of the CCR2 receptor. It is created by the deletion of amino acids 2-8 at the N-terminus of human MCP-1¹⁷ and has the potential to block the MCP-1/CCR-2 pathway *in vivo*. Recently, 7ND-MCP-1 has been shown to attenuate various disorders both vascular^{13,16,18} and non-vascular of nature^{19,20} by blocking MCP-1 mediated monocyte chemotaxis.

In the present study, the role of MCP-1 in vein graft remodeling was assessed. Therefore, the expression of MCP-1 in time was studied in both murine vein grafts and cultured human saphenous veins and the effect of blocking the MCP-1/CCR2 pathway in both models was investigated using 7ND-MCP-1. Furthermore, a direct inhibitory effect of 7ND-MCP-1 on SMC proliferation was studied. These data, for the first time, prove that the pro-inflammatory cytokine MCP-1 has a pivotal role in vein graft thickening.

MATERIALS AND METHODS

Mice.

Animal experiments were approved by the TNO-animal welfare committee. For all experiments male C57B/6-ApoE3Leiden mice were used. Animals were fed a cholesterol-enriched high-fat diet, containing 1% cholesterol and 0.05% cholate (AB Systems), starting 4 weeks prior to surgery. All mice received water and food ad libitum.

Cholesterol levels in serum were determined 1 week before surgery and at sacrifice. Mice were anaesthetized by Midazolam (5 mg/kg; Roche), Medetomidine (0.5 mg/kg; Orion) and Fentanyl (0.05 mg/kg; Janssen).

Vein graft surgery.

A venous interposition was placed in the carotid artery as described previously⁶. Grafts, being caval veins of donor mice, were harvested, and preserved in 0.9%NaCl containing 100IU of heparin. In the recipient, the right carotid artery was dissected from its surroundings and cut in the middle. A polyethylene cuff was placed at both ends of the artery. At both ends, the artery was everted around the cuff and ligated. Then, the graft was sleeved over the cuffs and ligated. Pulsations and turbulent blood flow within the graft confirmed successful engraftment.

At time of sacrifice, vein grafts were harvested after 5 minutes *in vivo* perfusion-fixation with formaldehyde (4%), fixated overnight and embedded in paraffin.

7ND-MCP-1 expression vector.

Human MCP-1 was modified into 7ND-MCP-1 by deletion of amino acids 2-8 and the 7ND-MCP-1 gene was cloned into the BamH1 (5') and Not1 (3') sites of a plasmid pcDNA3.1 expression vector (Invitrogen), as described before¹⁶. A pcDNA3.1 plasmid without an insert (pcDNA3.1-empty) was used as the control vector.

Gene-transfer by electroporation.

Gene-transfer of 7ND-MCP-1 was performed one day prior to vein graft surgery by injecting 75µg of plasmid, either pcDNA3-7ND-MCP-1or pcDNA3.1-empty, into the calf muscles of both legs, followed by electroporation (8 pulses of 10ms, field strength of 200V/cm (Square Wave Electroporator ECM 830, BTX) using Caliper Electrodes). Calf muscles were primed with an intramuscular injection containing

30µl of hyaluronidase (0.45U/µl, Sigma) one hour before electroporation²¹. Electroporation was called successful when the 7ND protein was detectable in serum using a human MCP-1 ELISA kit (Biosource). Protein expression was determined 1 day, 1, 2 and 4 weeks after surgery.

Analysis of intimal hyperplasia formation.

Serial perpendicular cross-sections of embedded vessels were made through the entire specimen. All samples were routinely stained with hematoxylline-phloxine-saffron (HPS).

Quantification of vein graft thickening was performed using image analysis software (Qwin, Leica). The thickened vessel wall surface was defined as the total vessel surface subtracted by the luminal surface. For each mouse six equally spaced cross-sections were used to determine vein graft thickening.

The composition of both murine vein grafts and human saphenous veins was visualized by immunohistochemistry. In the murine grafts, the amount of SMC (anti-SM α -actin, 1:1600, Roche) and macrophages (AIA31240, 1:3000, Accurate Chemical) was determined as the SM α -actin-positive and AIA-positive area in cross-sections, as a percentage of the total IH surface and quantified using image analysis software (Qwin, Leica). MCP-1 expression was determined using an anti-mouse JE/ MCP-1 antibody (1:20, BD Biosciences).

Production of 7ND-MCP-1 containing conditioned medium.

Human HER 911 were transfected with pcDNA3.1-7ND-MCP-1 or pcDNA3.1-empty by Lipofectamin as described by the manufacturer. Conditioned medium was collected every day and pooled. The 7ND-MCP-1 concentration produced was measured using a human MCP-1 ELISA kit (Biosource). Conditioned medium was diluted with culture medium (DMEM) until a final concentration of 7ND-MCP-1 was reached of 10 ng/ml (approximately 1:100). Medium from the pcDNA3.1-empty transfected HER 911's was collected and diluted in DMEM culture medium in a 1:100 ratio.

Production of purified 7ND-MCP-1 protein.

Recombinant 7ND-MCP-1 was purified from serum free conditioned medium from stably transfected CHO-cells. Medium diluted 1:1 with 0.02 M Phosphate-buffer (pH 7.4) was circulated over a SP Sephadex column (Pharmacia) overnight, followed by elution using a NaCl-gradient in 0.02 M Phosphate-buffer (pH 7.4). Recombinant 7ND-MCP-1 containing fractions, as determined by ELISA, were pooled to a final concentration of 28 µg/ml.

Human saphenous vein (HSV) organ culture.

Segments of saphenous veins were obtained from patients undergoing saphenous vein stripping (kindly provided by Dr. H. Stigter, Deaconess Hospital, Leiden, The Netherlands). Healthy looking segments of the stripped veins were put into culture as previously described^{22,23}. Segments (n=12 per group) were either exposed

to conditioned medium containing 10 ng/ml 7ND-MCP-1 or control conditioned medium. After 4 weeks, segments were harvested, fixed overnight in formaldehyde (4%) and embedded in paraffin. All segments were routinely stained by HPS and neointimal surface was assessed on multiple sections (n=9) per vein segment and quantified using Qwin Image analysis software (Leica).

For detection of proliferating cells by BrdU incorporation, the medium was supplemented with bromo-deoxyuridine (BrdU; 40mmol/l, Sigma) 7 days before harvesting of the vessels. Number of proliferating cells was quantified as the absolute number of BrdU-positive cells per microscopic view (magnification 100x). MCP-1 was visualized using a monoclonal anti human-MCP-1 (1:65; R&D Systems).

SMC culture and ³H-thymidine incorporation proliferation assay.

Human SMC, explanted from saphenous veins, were subsequently cultured, characterized and proliferation was measured as earlier described²⁴. Briefly, SMC were electroporated with plasmids encoding for 7ND-MCP-1, MCP-1 and/or an empty plasmid by Nucleofector Technology (Amaxa Biosystems) according to manufacture's protocol. After electroporation, cells were seeded at a density of at least 2×10^4 cells/24 well. Next, cells were made quiescent for 48 hours. Methyl-³H-thymidine incorporation (Amersham, 0.25 μ Cu/well) for 16 hours was measured by liquid-scintillation counting. In case purified, recombinant 7ND-MCP-1 and/or recombinant hMCP-1(R&D) was used, after quiescence, 7ND-MCP-1 was given 30 minutes before stimulation with MCP-1. Sixteen hours after stimulation methyl-³H-thymidine was added and incorporation was measured. All experiments were done in triplicate and at least repeated twice.

RNA isolation and PCR procedure.

Confluent monolayers of human SMC were grown in DMEM and synchronized for 24 hrs. To stimulate SMC, DMEM was supplemented with 0.1%FCS, 10% FCS and/or 10% FCS plus TNF- α (5ng/ml). After 40 hours cells were lysed with Tryzol (Invitrogen) and total RNA was extracted using the manufacturer's protocol. Synthesis of cDNA of all samples was performed using Ready-To-Go Beads (Amersham Biosciences). RT-PCR was performed, with gene specific primers for CCR2 (sense 5'CCAACTCCTGCCTCCGCTCTA, antisense 5'CCGCCAAAATAACCGATGTGATAC) on the cDNA samples of the 3 distinctly stimulated SMC. Amplification-conditions were: 5 minutes at 94°C, 35 cycles of 1 minute at 94°C, 1 minute at 55°C and 2 minutes at 72°C. PCR-products were run on a 1.2% agarose gel and visualized by ethidium bromide.

Statistical analysis.

All data are presented as mean \pm SEM. Statistical significance was calculated in SPSS 11.5 for Windows. In both the murine experiments and the SMC proliferation experiments overall comparisons between groups were performed with the one way ANOVA. If a significant difference was found, groups were compared to their controls using the Student's T test. Regarding the HSV experiments, 7ND-treated

and -untreated segments of an individual patient were compared using the paired T test. P-values less than 0.05 were regarded significant.

RESULTS

Expression of MCP-1 in murine vein grafts and human saphenous vein organ cultures.

To demonstrate the expression of MCP-1 in murine vein grafts in time, bypass surgery was performed in ApoE3Leiden mice (mean cholesterol levels: 13.1 ± 1.3 mmol/l) and animals were sacrificed at various time points after surgery (6 and 24 hours, 7, 14 and 28 days; n=3 per time point).

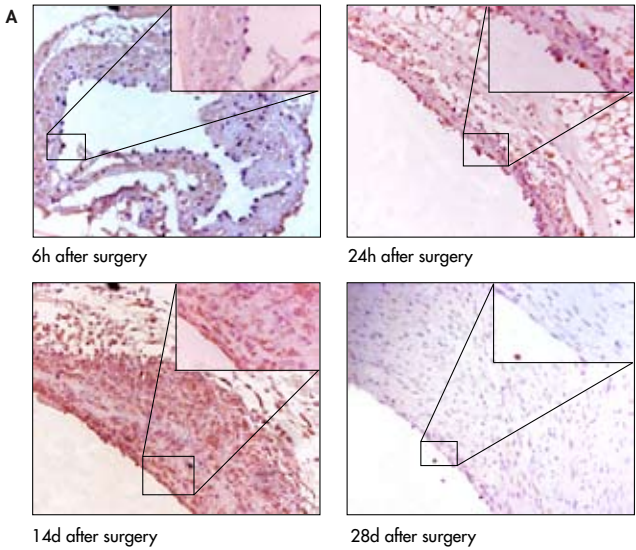
In the first days after engraftment, MCP-1 was mainly expressed by the remaining endothelial cells. Furthermore, a massive expression of MCP-1 could be detected in the adhering leukocytes. After 7 days, MCP-1 positive cells were detectable in the developing IH, co-localizing mainly with AIA positive cells, suggesting that this MCP-1 is predominantly expressed by infiltrating macrophages. After two weeks the expression in the IH decreased and it was scarcely detected after four weeks (Figure 5.1, Panel A).

In addition, MCP-1 expression was analyzed by immunohistochemistry in human saphenous vein organ cultures. From four HSV cultures, vessel wall specimens were collected at several time points (directly after excision, after 1, 7 and 28 days in organ culture). Hardly any MCP-1 could be detected in HSV directly after excision. In the cultured HSV, increased MCP-1 expression was detectable. In the early time points, it was present mainly in the circular SMC layer of the media. Besides expression in the media, profound MCP-1 expression was detectable in the developing IH from day 14 on. (Figure 5.1, Panel B).

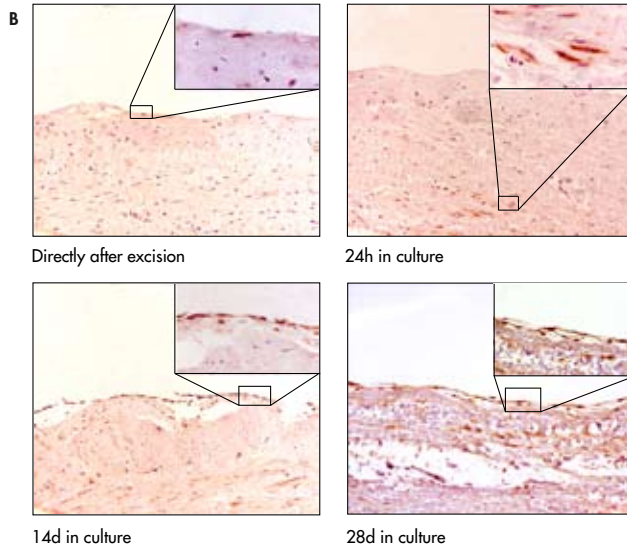
Inhibition of endogenous MCP-1 receptor by 7ND-MCP-1 inhibits vein graft thickening.

To study the effect of 7ND-MCP-1 on vein graft thickening, vein graft surgery was performed in ApoE3Leiden mice (n=6 per group). Twelve mice were electroporated one day prior to surgery with either the 7ND-MCP-1 plasmid or the empty plasmid, whereas 6 other were not electroporated. Electroporation of the calf muscle (n=6) with 75 µg of pcDNA3.1-7ND-MCP-1 led to a prolonged expression of 7ND-MCP-1, which was detected in serum. Peak expression (250 ± 79 pg/ml) was reached after 3-7 days and remained high even after 4 weeks (68 ± 21 pg/ml). No 7ND-MCP-1 could be detected in the control (pcDNA3.1-empty) group. Electroporation did not have an effect on the cholesterol levels or body weights of the mice (data not shown).

Figure 5.1: Panel A shows representative cross-sections of murine vein grafts harvested after several time points. MCP-1 expression in vein grafts identified by immunohistochemistry was seen mainly in endothelial cells, adhering monocytes and in the infiltrating cells of the developing IH. Inserts indicate adhering monocytes expressing MCP-1 (6h and 24h) and MCP-1 expression in the developing IH (14d).

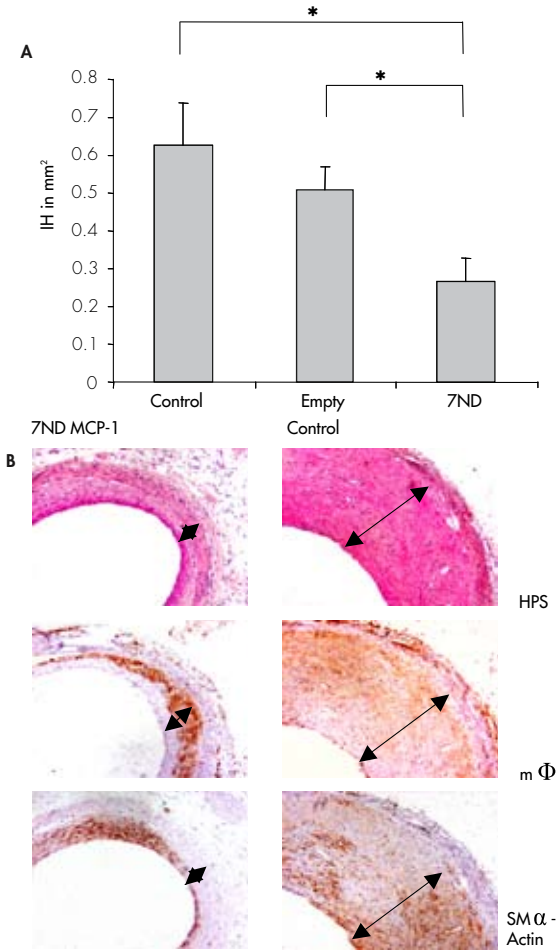


Panel B represents the immunohistochemical detection of MCP-1 in cultured human saphenous veins. MCP-1 is abundantly present in the media at early time points and predominantly in IH at later time points after 14 and 28 days. Inserts indicate MCP-1 expressing endothelium and SMC (directly after excision and 24h) and MCP-1 expression in IH (28d). Magnification of all pictures 150-600x.



A significant 51% reduction of vein graft thickening in the 7ND-MCP-1 treated group as compared to the control group and the empty plasmid group (control: $0.63 \pm 0.11 \text{ mm}^2$, empty: $0.51 \pm 0.05 \text{ mm}^2$, 7ND-MCP-1: $0.31 \pm 0.07 \text{ mm}^2$; $p=0.041$; Figure 5.2, panel A). Furthermore, the 7ND treated animals showed an increased luminal area when compared to both control groups (control: $0.36 \pm 0.06 \text{ mm}^2$, empty $0.37 \pm 0.03 \text{ mm}^2$, 7ND-MCP-1 $0.47 \pm 0.06 \text{ mm}^2$). However, this difference was not significant ($p=0.46$).

Figure 5.2: Effect of 7ND-MCP-1 gene-transfer on development of IH in murine vein grafts. Panel A: Significantly reduced IH surface is seen in the 7ND-MCP-1-treated group ($n=6$ per group, $p<0.05$). Panel B: Immunohistochemical staining for macrophages and smooth muscle cells. No differences in cellular composition of the lesions were observed (* represents $p<0.05$).



To study the possible effect of 7ND-MCP-1 on the cellular composition of IH of the vein grafts immunohistochemical analysis for macrophages and SMC was performed. Although vein graft thickening was reduced in the 7ND-MCP-1 treated group, no significant differences were seen in macrophage content in the 7ND-MCP-1 treated vessels (expressed as positive stained area as a percentage of the total area) when compared to the control group (control $22\pm4\%$, 7ND-MCP-1 $16\pm4\%$, $p=0.43$). Also,

no difference was seen in the SM α -actin positive area of the thickened vessel wall (control $39\pm 7\%$, 7ND-MCP-1 $27\pm 9\%$, $p=0.16$).

7ND-MCP-1 inhibits neointima formation in human saphenous vein (HSV) organ cultures.

The observation that both SMC and macrophage content of the murine lesions was reduced, prompted us to study the effects of 7ND-MCP-1 on the formation of SMC-rich lesions in HSV organ cultures. Segments of HSV ($n=12$ per group, from 4 separate patients) were cultured for 4 weeks. Segments exposed to conditioned medium with or without 7ND-MCP-1 (10 ng/ml) were compared.

In all samples a neointima formed within four weeks of culturing. However, quantification revealed reduced neointima formation in HSV exposed to conditioned medium containing 7ND-MCP-1, as compared to the control counterparts (7ND-MCP-1: 0.42 ± 0.11 mm² vs. control: 0.89 ± 0.16 mm², $p=0.012$, Figure 5.3).

Influx of macrophages in the human *ex vivo* model does not occur. Therefore 7ND-MCP-1 most likely may have a direct effect on SMC and not via the effect on monocyte chemotaxis. Therefore the effect of 7ND-MCP-1 on proliferation of SMC in the HSV organ cultures was assessed by BrdU staining. In the control vessels 26 ± 2 proliferating cells per microscopic field were detected in the neointima. A significantly lowered number of neointimal proliferating cells was seen in the 7ND-MCP-1 treated vessels (16 ± 2 cell/microscopic field, magnification 100x, $p=0.005$).

7ND-MCP-1 reduces SMC proliferation.

Since 7ND-MCP-1 treatment also seemed to have an effect on SMC proliferation in the HSV tissue culture, the direct inhibitory effect of 7ND-MCP-1 on SMC proliferation was studied.

First, the presence of the receptor for MCP-1, CCR2, on the human saphenous vein SMC was studied by means of mRNA analysis. CCR2 mRNA expression was detectable by PCR in three distinctly stimulated cell cultures (Figure 5.4).

Then, the effect of MCP-1 and 7ND-MCP-1 on SMC proliferation was studied in a human venous SMC cell culture. SMC were either transfected with an empty plasmid and/or plasmids encoding for MCP-1 or 7ND-MCP-1. Over-expression of MCP-1 resulted in increased DNA synthesis when compared to mock-transfected SMC, as determined by ³H-Thymidine incorporation (Empty $37\times 10^3\pm 0.84\times 10^3$ counts per mminute (cpm), MCP-1 $45\times 10^3\pm 0.25\times 10^3$ cpm, $p=0.035$). In addition, when SMC over-expressed 7ND-MCP-1, as expected, DNA synthesis was attenuated ($22\times 10^3\pm 0.14\times 10^3$ cpm, $P<0.001$), in comparison to mock-transfected cells. When a co-transfection with both MCP-1 and 7ND-MCP-1 plasmids was performed, a similar reduction was observed ($20\times 10^3\pm 0.71\times 10^3$ cpm, $p<0.001$, Figure 5.5A).

Figure 5.3: Effect of 7ND-MCP-1 on IH in HSV 28 days in culture. Panel A: Reduction in IH (n=12 per group) when exposed to conditioned medium containing 7ND-MCP-1 (* represents $p < 0.05$). Panel B: Representative cross section of HSV, strong reduction in both IH surface and BrdU-positive cells can be detected.

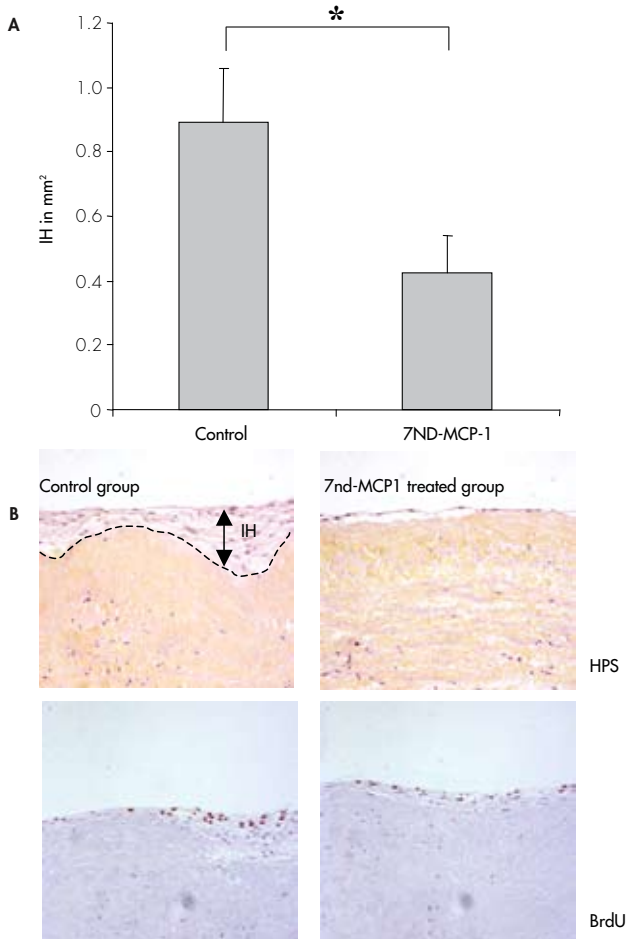
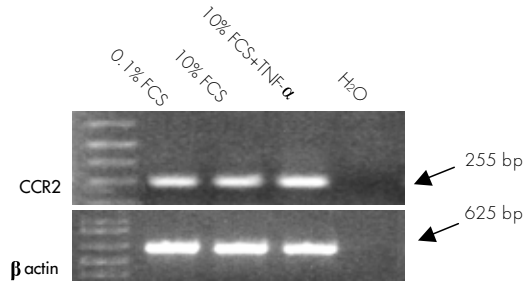


Figure 5.4: RT-PCR of total mRNA of cultured human SMC for expression of CCR2 mRNA under various culture conditions. Expression is seen under all conditions; however no difference in expression was seen between the various conditions. A: SMC/CCR2, B: SMC/ β -actin.



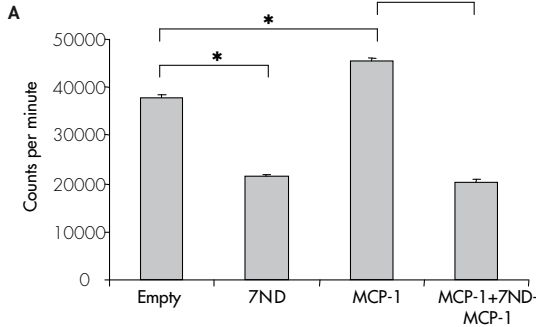
Next, SMC were exposed to either MCP-1 recombinant protein and/or 7ND-MCP-1 protein purified from CHO cells expressing the recombinant 7ND-MCP-1 protein. Exposure to increasing doses of MCP-1 recombinant protein resulted in a dose-dependent increase of DNA synthesis (data not shown).

When SMC were exposed to a fixed concentration of MCP-1 (10ng/ml) in combination with increasing concentrations of 7ND-MCP-1, a dose-dependent decrease of DNA synthesis was observed in the ³H-Thymidine assay. The relative reduction in SMC proliferation (expressed as percentage of control in which no 7ND-MCP-1 was added (0.3 ng/ml 7ND-MCP-1 added: 76 \pm 9%, p=0.07; 1 ng/ml 7ND-MCP-1: 59 \pm 3%, p=0.007; 3.3 ng/ml 7ND-MCP-1: 44 \pm 7%, p=0.006; 10 ng/ml 7ND-MCP-1: 59 \pm 1, p=0.006) is illustrated in Figure 5.5B).

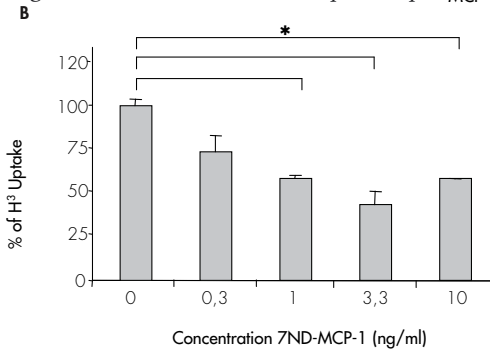
DISCUSSION

In the present study, the expression and causal involvement of MCP-1 in the development of intimal hyperplasia (IH) in a mouse *in vivo* or a human *ex vivo* model of vein graft disease is demonstrated. MCP-1 expression was shown to be present in the murine vein graft and was also detectable in a human saphenous vein (HSV) organ culture. Blocking the CCR2/MCP-1 pathway, using the receptor antagonist 7ND-MCP-1, resulted in a reduced vein graft thickening in both the murine vein graft and in HSV segments. Furthermore, we demonstrate that reduced vein graft thickening, besides the effect on monocyte chemotaxis, is caused by a direct anti-proliferative effect of 7ND-MCP-1 on vascular SMC.

Figure 5.5: Effect of MCP-1 or 7ND-MCP-1 on SMC proliferation ($n=3$ per condition). Panel A: SMC proliferation is increased upon transfection with MCP-1-encoding plasmids. Co-transfection with 7ND-MCP-1-encoding plasmids diminishes this MCP-1 induced proliferation. Transfection with 7ND-MCP-1 alone resulted decreased SMC proliferation (for all differences between the groups; $p<0.05$).



Panel B: Dose-dependent inhibition of SMC proliferation when cell are exposed to increasing concentrations of 7ND-MCP-1 purified protein ($n=3$ per condition, SMC of all conditions stimulated with a fixed concentration of 10ng/ml recombinant MCP-1) (* represents $p<0.05$).



Vein graft thickening due to development of IH and accelerated atherosclerosis is the major limitation in the long term survival of patent vein grafts. The mechanism of vein graft thickening development is largely unknown, but it is assumed that it is caused by an inflammatory response to damage of the graft^{9,10}.

MCP-1 is a well-known pro-inflammatory cytokine and one of the most potent chemoattractant agents for monocytes. Here, we show that MCP-1 is expressed in vein grafts in an *in vivo* murine model, early after engraftment and expressed mainly by the endothelium and adhering and infiltrating inflammatory cells. Furthermore, in HSV organ cultures, MCP-1 is predominantly expressed by SMC. These data are in line with a report of Stark et al, who showed an enhanced expression of MCP-1

in the healing vein graft which was accompanied by the influx of monocytes²⁵. However, this study was performed in normocholesterolemic rats without foam-cell formation in the vein grafts. In the current study, we applied ApoE3Leiden mice on a high-cholesterol diet. These mice have a human-like lipid profile and foam-cell accumulation in the vein grafts does take place. Therefore vein graft morphology in these mice highly resembles what is seen in human vein grafts.

In the processes of spontaneous atherosclerosis and post-angioplasty restenosis, two other disorders characterized by vascular inflammation, the role of MCP-1 is well known. Several clinical studies in humans describe the relation between circulating MCP-1 levels and the risk to develop in-stent restenosis^{26,27} and intervention in the MCP-1/CCR2 route results in a reduction of atherosclerosis and post-angioplasty restenosis in several animal models^{13,14,28-30}. Furthermore, in a mouse model of transplantation-induced graft vasculopathy after heterologous heart transplantation, 7ND MCP-1 overexpression significantly reduced accelerated atherosclerosis in the graft tissue³¹. However, the functional role of MCP-1 in the process of vein graft thickening, by intervening in the MCP-1/CCR2 pathway, was never studied. The data provided in this study demonstrate, to our knowledge for the first time, evidence for a pivotal, pro-restenotic role of MCP-1 in vein graft disease. Inhibition of the MCP-1/CCR2 pathway by 7ND-MCP-1 resulted in a significant reduction of vein graft thickening in murine vein grafts.

Since no difference was seen in the cellular composition of treated and untreated grafts, we hypothesized that besides chemotaxis of monocytes also proliferation of SMC is diminished by 7ND-MCP-1 exposure. This hypothesis is in line with several reports demonstrating that MCP-1 is a potent mitogenic agent for SMC^{32,33} *in vitro*. Therefore, the effect of 7ND-MCP-1 was studied in human saphenous vein organ cultures. IH in these veins consist mainly of SMC and endothelial cells and lacks macrophages³⁴. 7ND-MCP-1 reduced IH in HSV organ cultures and BrdU staining revealed a significant reduction in proliferating SMC in the 7ND-MCP-1 treated vein grafts.


To further asses the direct inhibitory effect of 7ND-MCP-1 on SMC proliferation, cultured SMC were exposed to MCP-1 and 7ND-MCP-1. MCP-1 exposure resulted in an increased proliferation of SMC. Oppositely, SMC proliferation was inhibited by exposure to 7ND-MCP-1. These data prove that, indeed, 7ND-MCP-1 directly inhibits SMC proliferation, in addition to its known effects on other (inflammatory) cell types present in the vascular lesion.

In conclusion, the present study establishes the important role of the MCP-1/CCR2 pathway in the development of vein graft thickening. Blocking this route (e.g. by 7ND-MCP-1) may be an interesting potential target for therapy in order to overcome the problems of vein graft failure in patients.

REFERENCES

1. Motwani JG, Topol EJ. Aortocoronary saphenous vein graft disease: pathogenesis, predisposition, and prevention. *Circulation* 1998;97:916-931.
2. Meng X, Mavromatis K, Galis ZS. Mechanical stretching of human saphenous vein grafts induces expression and activation of matrix-degrading enzymes associated with vascular tissue injury and repair. *Exp Mol Pathol* 1999;66:227-237.
3. Hilker M, Tellmann G, Buerke M, Gloger K, Moersig W, Oelert H, Hake U, Lehr HA. Proliferative activity in stenotic human aortocoronary bypass grafts. *Cardiovasc Pathol* 2002;11:284-290.
4. Bourassa MG, Campeau L, Lesperance J, Grondin CM. Changes in grafts and coronary arteries after saphenous vein aortocoronary bypass surgery: results at repeat angiography. *Circulation* 1982;65:90-97.
5. Campeau L, Enjalbert M, Lesperance J, Bourassa MG, Kwiterovich P, Jr., Wacholder S, Sniderman A. The relation of risk factors to the development of atherosclerosis in saphenous-vein bypass grafts and the progression of disease in the native circulation. A study 10 years after aortocoronary bypass surgery. *N Engl J Med* 1984;311:1329-1332.
6. Zou Y, Dietrich H, Hu Y, Metzler B, Wick G, Xu Q. Mouse model of venous bypass graft arteriosclerosis. *Am J Pathol* 1998;153:1301-1310.
7. van den Maagdenberg AM, Hofker MH, Krimpenfort PJ, de B, I, van Vlijmen B, van der BH, Havekes LM, Frants RR. Transgenic mice carrying the apolipoprotein E3-Leiden gene exhibit hyperlipoproteinemia. *J Biol Chem* 1993;268:10540-10545.
8. Lardenoye JH, de Vries MR, Lowik CW, Xu Q, Dhore CR, Cleutjens JP, van Hinsbergh VW, van Bockel JH, Quax PH. Accelerated atherosclerosis and calcification in vein grafts: a study in APOE*3 Leiden transgenic mice. *Circ Res* 2002;91:577-584.
9. Christiansen JF, Hartwig D, Bechtel JF, Kluter H, Sievers H, Schonbeck U, Bartels C. Diseased vein grafts express elevated inflammatory cytokine levels compared with atherosclerotic coronary arteries. *Ann Thorac Surg* 2004;77:1575-1579.
10. Hoch JR, Stark VK, Hullett DA, Turnipseed WD. Vein graft intimal hyperplasia: leukocytes and cytokine gene expression. *Surgery* 1994;116:463-470.
11. Leonard EJ, Skeel A, Yoshimura T. Biological aspects of monocyte chemoattractant protein-1 (MCP-1). *Adv Exp Med Biol* 1991;305:57-64.
12. Yoshimura T, Leonard EJ. Human monocyte chemoattractant protein-1: structure and function. *Cytokines* 1992;4:131-152.
13. Egashira K, Zhao Q, Kataoka C, Ohtani K, Usui M, Charo IF, Nishida K, Inoue S, Katoh M, Ichiki T, Takeshita A. Importance of monocyte chemoattractant protein-1 pathway in neointimal hyperplasia after periarterial injury in mice and monkeys. *Circ Res* 2002;90:1167-1172.
14. Inoue S, Egashira K, Ni W, Kitamoto S, Usui M, Otani K, Ishibashi M, Hiasa K, Nishida K, Takeshita A. Anti-monocyte chemoattractant protein-1 gene therapy limits progression and destabilization of established atherosclerosis in apolipoprotein E-knockout mice. *Circulation* 2002;106:2700-2706.
15. Mori E, Komori K, Yamaoka T, Tani M, Kataoka C, Takeshita A, Usui M, Egashira K, Sugimachi K. Essential role of monocyte chemoattractant protein-1 in development of restenotic changes (neointimal hyperplasia and constrictive remodeling) after balloon angioplasty in hypercholesterolemic rabbits. *Circulation* 2002;105:2905-2910.
16. Ni W, Egashira K, Kitamoto S, Kataoka C, Koyanagi M, Inoue S, Imaizumi K, Akiyama C, Nishida KK, Takeshita A. New Anti-Monocyte Chemoattractant Protein-1 Gene Therapy Attenuates Atherosclerosis in Apolipoprotein E-Knockout Mice. *Circulation* 2001;103:2096-2101.
17. Zhang YJ, Rutledge BJ, Rollins BJ. Structure/activity analysis of human monocyte chemoattractant protein-1 (MCP-1) by mutagenesis. Identification of a mutated protein that inhibits MCP-1-mediated monocyte chemotaxis. *J Biol Chem* 1994;269:15918-15924.
18. Niiyama H, Kai H, Yamamoto T, Shimada T, Sasaki K, Murohara T, Egashira K, Imaizumi T. Roles of endogenous monocyte chemoattractant protein-1 in ischemia-induced neovascularization. *J Am Coll Cardiol* 2004;44:661-666.
19. Kumai Y, Ooboshi H, Takada J, Kamouchi M, Kitazono T, Egashira K, Ibayashi S, Iida M. Anti-monocyte chemoattractant protein-1 gene therapy protects against focal brain ischemia in hypertensive rats. *J Cereb Blood Flow Metab* 2004;24:1359-1368.
20. Tsuruta S, Nakamura M, Enjoji M, Kotoh K, Hiasa K, Egashira K, Nawata H. Anti-monocyte chemoattractant protein-1 gene therapy prevents dimethylnitrosamine-induced hepatic fibrosis in rats. *Int J Mol Med* 2004;14:837-842.
21. McMahon JM, Signori E, Wells KE, Fazio VM, Wells DJ. Optimisation of electrotransfer of plasmid into skeletal muscle by pretreatment with hyaluronidase -- increased expression with reduced muscle damage. *Gene Ther* 2001;8:1264-1270.

22. Slomp J, Gittenberger-deGroot AC, van Munsteren JC, Huysmans HA, van Bockel JH, van Hinsbergh VW, Poelmann RE. Nature and origin of the neointima in whole vessel wall organ culture of the human saphenous vein. *Virchows Arch* 1996;428:59-67.
23. Soyombo AA, Angelini GD, Bryan AJ, Jasani B, Newby AC. Intimal proliferation in an organ culture of human saphenous vein. *Am J Pathol* 1990;137:1401-1410.
24. Arkenbout EK, de W, V, van Bragt M, van Achterberg TA, Grimbergen JM, Pichon B, Pannekoek H, De Vries CJ. Protective function of transcription factor TR3 orphan receptor in atherogenesis: decreased lesion formation in carotid artery ligation model in TR3 transgenic mice. *Circulation* 2002;106:1530-1535.
25. Stark VK, Hoch JR, Warner TF, Hullett DA. Monocyte chemoattractant protein-1 expression is associated with the development of vein graft intimal hyperplasia. *Arterioscler Thromb Vasc Biol* 1997;17:1614-1621.
26. Cipollone F, Marini M, Fazio M, Pini B, Iezzi A, Reale M, Paloscia L, Materazzo G, D'Annunzio E, Conti P, Chiarelli F, Cuccurullo F, Mezzetti A. Elevated circulating levels of monocyte chemoattractant protein-1 in patients with restenosis after coronary angioplasty. *Arterioscler Thromb Vasc Biol* 2001;21:327-334.
27. Hokimoto S, Oike Y, Saito T, Kitaoka M, Oshima S, Noda K, Moriyama Y, Ishibashi F, Ogawa H. Increased expression of monocyte chemoattractant protein-1 in atherectomy specimens from patients with restenosis after percutaneous transluminal coronary angioplasty. *Circ J* 2002;66:114-116.
28. Aiello RJ, Bourassa PA, Lindsey S, Weng W, Natoli E, Rollins BJ, Milos PM. Monocyte chemoattractant protein-1 accelerates atherosclerosis in apolipoprotein E-deficient mice. *Arterioscler Thromb Vasc Biol* 1999;19:1518-1525.
29. Furukawa Y, Matsumori A, Ohashi N, Shioi T, Ono K, Harada A, Matsushima K, Sasayama S. Anti-monocyte chemoattractant protein-1/monocyte chemoattractant and activating factor antibody inhibits neointimal hyperplasia in injured rat carotid arteries. *Circ Res* 1999;84:306-314.
30. Horvath C, Welt FG, Nedelman M, Rao P, Rogers C. Targeting CCR2 or CD18 inhibits experimental in-stent restenosis in primates: inhibitory potential depends on type of injury and leukocytes targeted. *Circ Res* 2002;90:488-494.
31. Saiura A, Sata M, Hiasa K, Kitamoto S, Washida M, Egashira K, Nagai R, Makuuchi M. Antimonocyte chemoattractant protein-1 gene therapy attenuates graft vasculopathy. *Arterioscler Thromb Vasc Biol* 2004;24:1886-1890.
32. Selzman CH, Miller SA, Zimmerman MA, Gamboni-Robertson F, Harken AH, Banerjee A. Monocyte chemoattractant protein-1 directly induces human vascular smooth muscle proliferation. *Am J Physiol Heart Circ Physiol* 2002;283:H1455-H1461.
33. Viedt C, Vogel J, Athanasiou T, Shen W, Orth SR, Kubler W, Kreuzer J. Monocyte chemoattractant protein-1 induces proliferation and interleukin-6 production in human smooth muscle cells by differential activation of nuclear factor-kappaB and activator protein-1. *Arterioscler Thromb Vasc Biol* 2002;22:914-920.
34. Lamfers ML, Aalders MC, Grimbergen JM, de Vries MR, Kockx MM, van Hinsbergh VW, Quax PH. Adenoviral delivery of a constitutively active retinoblastoma mutant inhibits neointima formation in a human explant model for vein graft disease. *Vascul Pharmacol* 2002;39:293-301.



CHAPTER 6

Both MIP-1 α and RANTES and their receptors are expressed in murine vein grafts and aggravate vein graft remodeling.

A. Schepers^{1,2}, M.R. de Vries¹, I. Bot³, H.J. Anders⁴, A.E.I. Proudfoot⁵, J.H. van Bockel², P.H.A. Quax^{1,2}

¹Gaubius Laboratory, TNO, Quality of Life, Leiden, The Netherlands, ²Department of Surgery, Leiden University Medical Centre, Leiden, The Netherlands, ³Division of Biopharmaceutics, Gorlaeus Laboratories, Leiden University, Leiden, The Netherlands, ⁴Nephrological Center, Medical Policlinic, University of Munich, Munich, Germany, ⁵Serono Pharmaceutical Research Institute, Geneva, Switzerland

Submitted

ABSTRACT

Objective: Venous bypass graft patency is compromised by development of intimal hyperplasia and accelerated atherosclerosis. Both are thought to be inflammatory driven and are characterized by early influx of inflammatory cells. Here, the involvement of CC-chemoattractants RANTES and MIP-1 α in vein graft thickening was studied.

Methods: Venous interpositions were placed in carotid arteries of hypercholesterolemic ApoE3Leiden mice. In this model massive influx of inflammatory cells is seen and vein graft thickening occurs within 28 days. Expression of MIP-1 α and RANTES and their receptors was studied by immunohistochemistry and RT-PCR at various time points after surgery. Receptor-antagonist Met-RANTES was administered to study the effect of blocking RANTES and MIP-1 α on monocyte adhesion and vein graft thickening.

Results: RANTES and MIP-1 α protein was detectable in the various stages of vein graft remodeling and mRNA expression appeared to be regulated after engraftment.

Met-RANTES-treatment resulted in significantly reduced adherence of monocytes 3 days after engraftment. Twenty-eight days after engraftment vein graft thickening was significantly reduced in Met-RANTES-treated mice and their vein grafts consisted of less foam cells.

Conclusion: This study shows that RANTES/MIP-1 α - receptor interactions are involved in monocyte-chemotaxis in the early phases of vein graft remodeling and blocking this axis reduces vein graft thickening. This might be an interesting new target in order to overcome the clinical problem of vein graft disease.

INTRODUCTION

Despite all recent advances in treatment of arterial atherosclerotic occlusions by percutaneous procedures like PT(C)A with or without (drug eluting) stent placement, bypass surgery is still considered the treatment of choice in occlusions in the distal vasculature or occlusions covering a long section of an artery. However, long term results of vein grafting are compromised by occlusion of venous bypass grafts. This often results in the necessity for renewed bypass surgery or amputation. Therefore bypass occlusion remains a major problem in clinical practice.

The main causes of occlusion of the vein graft, especially when occurring months to years after engraftment, are intimal hyperplasia (IH) formation and accelerated atherosclerosis. Both are believed to occur as a response to injury of the vein graft, e.g. the surgical procedure, altered shear stress after engraftment and other (pre-existing) causes of endothelial damage such as hypercholesterolemia, smoking or hyperglycemia. The response to injury can be characterized as an inflammation mediated process and consists of adhesion of various inflammatory cells and thrombocytes in the first days after grafting, followed by fibrin depositions and influx of inflammatory cells, predominantly monocytes. This finding points to a dominant role for the immune system at least in the early phases of vein graft remodeling.

Physiologically, monocytes and other leucocytes are attracted to the site of injury by the process of chemotaxis. Chemokines are a family of potent chemotactic cytokines that regulate the trafficking of leucocytes. One interesting group of chemotactic factors are CC-chemokines (also called β -chemokines), named after their capacity to attract leukocytes to the site of inflammation and the adjacency of the first two cysteine residues. CC-chemokines express their function via the CCR receptors, which are highly homologous, seven-transmembrane –domain G-protein coupled receptors and most chemokines interact with more than one CCR receptor¹.

Monocyte chemoattractant protein 1 (MCP-1/CCL2) is the most studied CC-chemokine and its role in vascular inflammation is widely recognized²⁻⁴. Recently our group defined its role in vein graft thickening and demonstrated that MCP-1 has a pro-stenotic and pro-mitogenic effect in the process of vein graft thickening⁵. Other well known CC-chemokines are MIP-1 α (CCL3) and RANTES (CCL5). Both have a potent chemoattractive effect on monocytes, but are also involved in the chemotaxis of activated T-cells, B-cells, dendritic cells and natural killer cells, of which monocytes and T-cells appear to be being the most important in vein graft thickening. Whilst the role of MCP-1 in vascular disease has been extensively studied, the role of other CC-chemokines is less clear. In this study we wanted to investigate the potential involvement of MIP-1 α and RANTES and their receptors, CCR1, CCR3 and CCR5 in vein graft remodeling.

In this study, MIP-1 α /RANTES pathways were blocked *in vivo* by the use of the CCR antagonist Met-RANTES. Met-RANTES is created by retention of the

initiating methionin in recombinant the RANTES protein⁶ and has the capacity to block ligand-induced chemotaxis for human CCR1, CCR3 and CCR5⁷. It also displays antagonistic activity for murine CCR1 and CCR5, but not murine CCR3⁸. Furthermore, it has been shown to inhibit macrophage and T-cell accumulation in various (animal) models of disease⁹⁻¹³. In this study, Met-RANTES was used in a murine model for vein graft disease, in which a venous interposition is placed in the common carotid artery¹⁴. When performed in hypercholesterolemic mice, this vein graft undergoes a striking remodeling with IH formation and atherosclerotic changes¹⁵, resulting in formation of lesions that are concentric and friable, with lipid deposition and foam cell accumulation in the intima and media, and have a poorly developed or absent fibrous caps. This morphology is highly similar to the changes seen in human vein grafts. More importantly, massive adhesion and influx of inflammatory cells is seen in the first days after surgery, making this model extremely suitable to study chemotactic factors, such as MIP-1 α and RANTES.

METHODS

Mice.

All animal experiments were approved by the TNO Animal Welfare Committee and conform to the *Guide for the Care and Use of Laboratory Animals* (published by the US National Institute of Health, No 85-23, revised 1996). For all experiments male C57Bl6/ApoE3Leiden mice, age between 16 and 20 weeks, were used. Mice were fed a mild cholesterol-enriched diet (containing e.g. 0.5% cholesterol, 0.05%choolate¹⁶) *ad libitum*, aiming at plasma cholesterol levels of 10-15 mmol/l). Serum cholesterol levels were determined at time of surgery and sacrifice.

Vein graft surgery.

Vein graft surgery was performed as previously described¹⁴. In summary, caval veins were harvested from genetically identical donor mice and placed as an interposition in the common carotid artery of ApoE3Leiden recipients. Therefore, the artery was dissected free from its surroundings and ligated. After clamping the vessel, a plastic cuff was sleeved over both ends, the artery was everted over the cuff and ligated with a 8.0 Silk ligature. Subsequently, the caval veins were sleeved over the cuffs and ligated, thereby creating a venous interposition. After clamp removal, turbulent flow through the vein graft confirmed successful engraftment. At time of sacrifice, 5 minutes of in vivo perfusion-fixation at 100mmHg with 4% Formaldehyde was followed by harvesting of the vein graft.

Met-RANTES treatment.

Met-RANTES was produced as previously described⁶. Mice received daily intra-peritoneal injections of 30 μ g Met-RANTES dissolved in 0.1ml of sterile 0.9%NaCl (dosages based on protocols from literature¹⁰). Mice in the control group received daily injections of 0.1ml of sterile 0.9%NaCl.

Histological assessment of vein grafts.

Harvested vein grafts were fixed overnight in 4% Formaldehyde, dehydrated and embedded in paraffin. Serial perpendicular cross-sections (5µm) were made of the specimen and routinely stained with Hemotoxilin, Phloxin and Saffron (HPS).

Presence and distribution of MIP-1α and RANTES was studied by immunohistochemistry. MIP-1α was detected using antibodies against murine MIP-1α (Abcam) and for RANTES antibodies against murine RANTES (R&D Biosystems) were used.

To assess vein graft thickening, the vessel wall surface was measured in 6 cross-sections per specimen, using Computes Assisted Image Analysis (QWin, Leica) and averaged. Since the barrier between intima and media in murine veins is difficult to identify, vein graft thickening was defined as all tissue inside the external elastic lamina minus the luminal area.

Different subsets of leukocytes were specified. The amount of macrophage derived foam cells within the thickened vessel wall was visualized by AIA31240 antibody (Accurate Chemical) and T-cells were detected using anti-CD3 antibodies (Serotec).

Adherence of inflammatory cells was studied in vein grafts, harvested 3 days after surgery. T-cells and monocytes were stained by immunohistochemistry and all positive cells adhering to the endothelium were counted. Per specimen this procedure was performed in 6 cross-sections and scoring was performed by two blinded observers.

RNA isolation and PCR.

To study the expression of MIP-1α, RANTES and their CCR receptors in the remodeling vein graft, a time-course was made. Mice underwent vein graft surgery and were sacrificed at several time-points after surgery (6h, 24h, 3d, 7d, 14d and 28d, n=4 per time point). The vein grafts was harvested and snap-frozen. Also, caval veins of donor mice were included.

To isolate RNA, a RNA Isolation Mini Kit for Fibrous Tissue (Qiagen) was used, following the protocol provided by the manufacturer. To overcome the risk of DNA contamination, a DNase treatment was included (RNase Free DNase set, Qiagen). RNA (250 ng) was reverse-transcribed using the Ready-To-Go You-Prime First-Strand Beats (Amersham Biosciences) according to the manufacturers protocol.

Gene expression analysis was performed on an ABI PRISM 7700 machine (Applied Biosystems) using SYBR Green technology. PCR primers (Table 6.1) were designed using Primer Express 1.7 software with the manufacturer's default settings (Applied Biosystems; amplicon size: 68-150 base pairs). In a MicroAmp optical 96-well plates (Applied Biosystems), 19 µl SYBR Green mix (2.5 µl 10X reaction buffer, 1.75 µl 50 mM MgCl₂, 1 µl 5 mM dNTP's, 0.125 µl 5 U/µl Hot GoldStar enzyme, 0.75 µl SYBR Green 1/2000 dilution in DMSO and 12.875 µl sterile water; Eurogentec)

was added to 5 μ l cDNA (25 ng) and 300 nM of forward and reverse primers. Plates were heated for 2 min at 50°C and 10 min at 95°C. Subsequently, 40 PCR cycles consisting of 15 at 95°C and 60 sec at 60°C were applied. Cyclophilin (Cyp) and hypoxanthine guanine phosphoribosyl transferase (HPRT) were used as the standard housekeeping genes. Ratios of target gene and housekeeping gene expression levels (relative gene expression numbers) were calculated by subtracting the mean threshold cycle number (Ct) of the housekeeping gene Ct (mean of CypA and HPRT) from the target gene ($=\Delta$ CT) and raising 2 to the power of $-\Delta$ CT.

Table 6.1: *Primer sequences used for RT-PCR mRNA analysis.*

Gene	GenB Acces	Forward (5'-3')	Reverse (5'-3')
HPRT	J00423	TTGCTCGAGATGTCATGAAGGA	AGCAGGTCAGCAAAGAACTTATAG
CCR1	NM_009912	CAATCAGTGTGAGCAGAGTAAGCA	CACAACAGTGGGTGTAGGCAA
CCR3	NM_009914	TGCAGGTGACTGAGGTGATTG	CGGAACCTCTCACCAACAAAG
CCR5	NM_009917	GACTGTCAGCAGGAAGTGAGCAT	CTTGACGCCAGCTGAGCAA
MIP-1 α	NM_011337	GCCACATCGAGGGACTCTTCA	GATGGGGTTGAGGAACGTG
RANTES	NM_013653	CTTCTCTGGGTGGCACACA	GCAAGTGCTCCAATCTTGCA

Statistical analysis.

Data are represented as mean \pm SEM. For statistical analysis of morphometric data and data concerning adherence of cells, a non-parametric Mann-Whitney test was executed. The significance of differences in relative gene expression numbers measured by SYBR Green was calculated using a two-tailed T-test on the differences in Ct (Δ CT = Ct_{target gene} - Ct_{housekeeping}). Probability values less than 0.05 were considered significant.

RESULTS

Presence of MIP-1 α and RANTES in murine vein grafts.

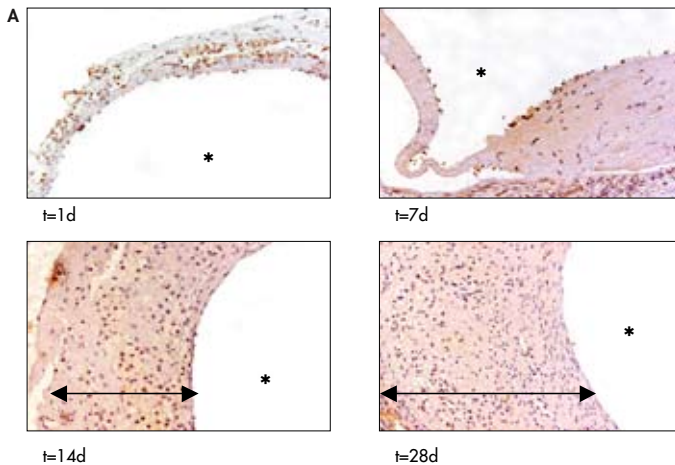
The presence of MIP-1 α and RANTES in remodeling vein grafts was studied by immunohistochemical staining. Therefore, vein grafts were harvested on several time-points ($t=$ directly after surgery, $t=3d$, $7d$, $14d$ and $28d$, $n=3$ per time-point). In the early phases directly after surgery, massive adhesion of inflammatory cells was seen, existing pre-dominantly of macrophages as determined by immunohistochemistry. From day three on, the vessel wall appeared very thin, and little viable cells could be detected. After 7 days cellular accumulation could be distinguished, resulting in a markedly thickened vein graft wall, existing mainly of smooth muscle cells and macrophage-derived foam cells.

Directly after surgery MIP-1 α could be detected in the adhering cells, whereas after a few days it was also expressed in cells of the native vein graft wall. Furthermore, MIP-1 α was also detected in the regenerating endothelium. The presence of MIP-1 α remained detectable until 14 days after surgery, and it subsequently declined and was not present in the 28 days vein grafts.

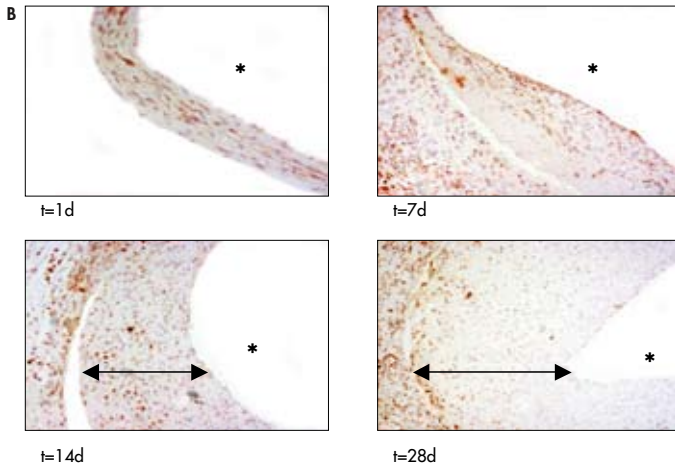
The distribution of RANTES was more concentrated in the adventitia of the remodeling grafts. A minority of the adhering cells in the specimen harvested directly after surgery were positive for RANTES protein just like approximately one third of the smooth muscle cells and fibroblasts of the vein graft vessel wall. In the later time points, RANTES could be detected diffusely in the thickened vein graft wall, but predominantly in the adventitia, up to 28 days after surgery.

Representative pictures are presented in Figure 6.1.

Figure 6.1: Expression of MIP-1 α and RANTES in remodeling vein grafts as shown by immunohistochemistry.



Panel A shows MIP-1 α - expression in the adhering leucocytes 1 day after engraftment, and presence of MIP-1 α in the thickened vessel wall at later time points. **Panel B** depicts RANTES presence in the vein graft wall at the early time-points. In the later stages of vein graft thickening diffuse distribution is seen in the intimal hyperplasia but predominantly in the adventitia of the vein grafts. (n=3 per time-point, magnification 125-300x, * represents lumen, arrow indicates vessel wall thickening).



Expression of MIP-1 α , RANTES and their receptors in murine vein grafts.

Since MIP-1 α and RANTES protein appeared to be present in remodeling vein grafts, the relative mRNA expression of these factors and their receptors CCR1, CCR3 and CCR5 were studied, to evaluate the presence of a possible time-dependent up- or downregulation.

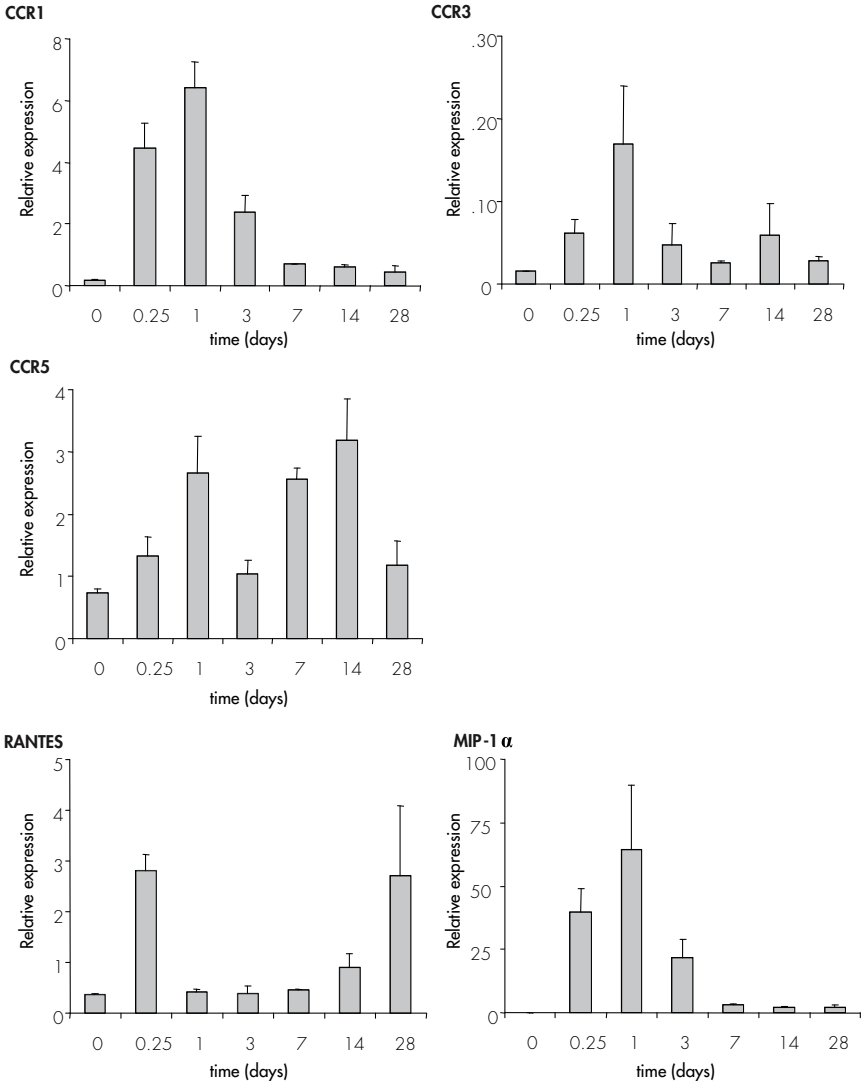
Therefore total mRNA of vein grafts, harvested at several time points, was analyzed. Real time RT-PCR was performed with specific primers for CCR1, CCR3, CCR5, MIP-1 α and RANTES and expression was correlated to expression of the housekeeping gene. The following data are summarized in Figure 6.2.

All three CCR receptors tested had baseline mRNA expression in normal caval veins and all displayed induction of mRNA expression in grafted veins. CCR1 showed a rapid upregulation as early as 6h after engraftment, when compared with expression in normal caval veins. Peak expression was seen after 1d (relative expression 6.4 ± 0.85 , $p < 0.0001$) after which expression declined to baseline level after 28d.

CCR3 expression was much lower than CCR1 expression (relative expression between 0.015 and 0.16, as compared to the housekeeping gene) however mRNA induction upon engraftment followed a similar pattern with peak expression after 1d (relative expression 0.17 ± 0.07 , $p = 0.03$).

CCR5 also demonstrated significant mRNA upregulation after engraftment (relative expression when compared with expression in normal caval veins after 1d 2.6 ± 0.59 , $p = 0.01$), but expression remained very variable over time and no evident pattern could be detected.

Figure 6.2: RNA synthesis of MIP-1 α , RANTES and their receptors at various time-points of vein graft remodeling.



MIP-1 α followed an expression profile that confirmed the immunohistochemistry results and was not detectable in normal caval veins, but after surgery a swift and strong upregulation occurred, with peak expression at 1d after surgery (relative expression 64.1 ± 24.7 , $p=0.0002$). Thereafter expression was reduced to a stable level from 7d.

RANTES mRNA was upregulated to peak expression after 6h (relative expression 2.8 ± 0.31 , $p=0.0001$), after which the expression diminished and then surprisingly was upregulated again at 14d and 28d.

Effect of Met-RANTES on leukocyte adhesion.

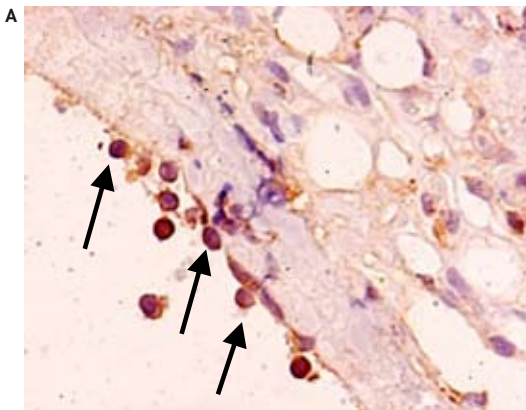
Since leukocyte adhesion is believed to be one of the first phenomena occurring in remodeling vein grafts and chemotaxis plays a vital role in this process, the effect of blocking CCR1 and CCR5 signaling on the early adherence of leukocytes was studied. Therefore, 16 mice were randomly divided in 2 groups. One group was treated with Met-RANTES (30 μ g/day, starting one day prior to surgery), the other group served as a control group and received daily injections of sterile 0.9%NaCl. Mice underwent vein graft surgery and were sacrificed after 3 days. Monocytes were identified using immunohistochemistry and adhering monocytes were counted on 6 cross-sections per vein graft.

As shown in Figure 6.3, massive adhesion of monocytes could be detected in the control group (31.4 ± 3.4 per cross section). In the Met-RANTES treated mice, adherence of monocytes was still detected, however a significant reduction in adhering monocytes was seen (16.7 ± 3.8 , $p=0.007$).

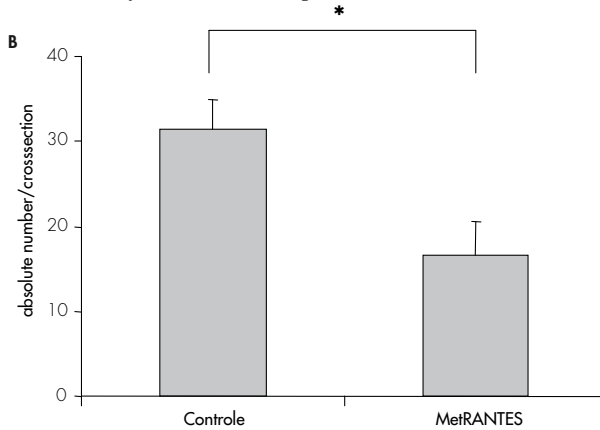
Interestingly, almost no adhering CD3-positive T-cells were present in the vein grafts harvested after 3 days (1-2 positive cells/ 6 cross-sections). This phenomenon was seen in both groups and therefore, no significant difference could be demonstrated between both treatment groups.

Figure 6.3:

Panel A: *Representative picture showing adhering AIA31240 positive cells (some are indicated by arrows; magnification 400x).*



Panel B: Number of adhering AIA31240 positive cells (monocytes) 3 days after engraftment in Met-RANTES-treated and control vein grafts (analysis by immunohistochemistry, $n=8$ per group, at least 6 cross-sections per mice were analyzed). Data are expressed as mean \pm SEM.



Effect of Met-RANTES on vein graft thickening.

To study the effects of inhibiting CCR1 and CCR5 on vein graft thickening, 8 mice were randomly divided into two groups; one group treated with Met-RANTES as described above, and one control group. Serum cholesterol (measured at sacrifice) did not differ between the two groups (control 14.6 ± 1.4 mmol/l, Met-RANTES 15.4 ± 4.1 mmol/l, $p=0.82$). Mice were sacrificed after 28 days and vein graft thickening was quantified.

In the control animals, vein graft thickening occurred (0.41 ± 0.08 mm²). Met-RANTES treatment resulted in a significantly decreased vein graft thickening (0.16 ± 0.01 mm², $p=0.042$ when compared to controls; Figure 6.4). To see whether treatment with Met-RANTES changed the inflammatory status of the thickened vein graft, read out by the presence of macrophages and macrophage-derived foam cells in the vessel wall, the AIA31240-positive area, was determined. The thickened vein graft wall in the control group consisted for $21\pm 2\%$ of AIA31240-positive cells, compared to $11\pm 5\%$ in the Met-RANTES-treated group ($p=0.032$; Figure 6.4). This finding indicates that upon Met-RANTES treatment not only adherence of monocytes is decreased, it also results in reduced foam cell content in the vessel wall. Immunohistochemical staining for T-cells, in vein grafts harvested after 28 days, disclosed that T-cells appeared pre-dominantly in the adventitia, whereas staining in the thickened vessel wall was clearly present but less abundant (data not shown).

DISCUSSION

The process of vascular remodeling has been thoroughly explored over the past decade. Multiple studies show a major role for inflammatory processes in the pathophysiology of atherosclerosis and post-interventional restenosis. Although it is often assumed that vein graft thickening can be seen as a similar inflammatory process, the important differences in the structure of vein grafts compared to arteries, require a separate approach.

Leukocyte migration to the site of vascular injury involves a concerted interaction of adhesion molecules, chemokines and their receptors. Although the role of chemokines in general, and CC-chemokines specifically, has been elaborately studied in atherosclerosis (as reviewed in ¹⁷), reports about their role in vein graft disease are scarce. Recently, our group demonstrated the important role of MCP-1 in the development of vein graft thickening and its effects on smooth muscle cell proliferation¹⁸. Furthermore Ali et al described the potent inhibitory effects of a single intravenous injection of the broad spectrum CC-chemokine inhibitor 35K on accelerated vein graft atherosclerosis¹⁹. Their study demonstrated very elegantly the potential therapeutic options of this approach, however the role of individual CC-chemokines was not further addressed. Therefore, the functional involvement of MIP-1 α and RANTES and their receptors CCR1, CCR3 and CCR5 in the process of vein graft thickening was studied.

The presence and expression of CC-chemokines MIP-1 α and RANTES has been demonstrated in various forms of vascular lesions. In advanced atherosclerotic plaques, for instance, RANTES is predominantly expressed in (approximately 5% of all) activated T-cells²⁰. In contrast, within the plaque area of accelerated atherosclerosis in organ transplants, RANTES was highly expressed in various cell types (e.g. macrophages, endothelial cells, myofibroblasts)²¹. In this study we found expression predominantly in the later stages of vascular remodeling, in the adventitia of the grafts, co-localizing with T-cells.

Expression of MIP-1 α is shown in the remodeling vein graft, predominantly by invading monocytes/macrophages and leukocytes in the adventitia. To our knowledge, there are no previous reports describing the presence of MIP-1 α in atherosclerotic plaques or other vascular lesions, but its presence has been demonstrated *in vitro* in various processes related to atherogenesis and vascular inflammation^{22, 23}. Additionally, in this manuscript a time-dependent upregulation of RANTES and MIP-1 α mRNA upon engraftment was demonstrated in the remodeling vein grafts, and a similar pattern was detected by immunohistochemistry.

Moreover, a time-dependent upregulation of CC-receptors mRNA was demonstrated in these grafts. These findings are in line with the report of Hayes and colleagues²⁴ who showed upregulation of CCR mRNA in cultured smooth muscle cells originating from atherosclerotic tissue and with the report of Veillard and colleagues²⁵, who showed expression of various CC-receptors in endothelial cells and monocytes.

These data show that besides MCP-1, other CC-chemokines might be involved in vascular remodeling in general and vein graft thickening in particular.

To obtain more insight in the functional involvement of these CC-chemokines and their receptors on chemotaxis and inflammatory cell adhesion to the vein graft wall in vivo, the receptor antagonist Met-RANTES was used to block signal transduction. Met-RANTES is an established CCR1 and CCR5 receptor antagonist and has been used to study the involvement of RANTES in atherosclerosis and arterial post-interventional neointima formation^{26, 27} in the past. Treatment with Met-RANTES resulted in significantly decreased numbers of adhering monocytes in vein graft harvested 3 days after surgery.

After 28 days, Met-RANTES treatment not only reduced vein graft thickening, but a reduction in foam cell content could also be detected. This morphology (with less foam cells in the plaque area) is assumed to be associated with plaque stability²⁸ and therefore a desirable situation.

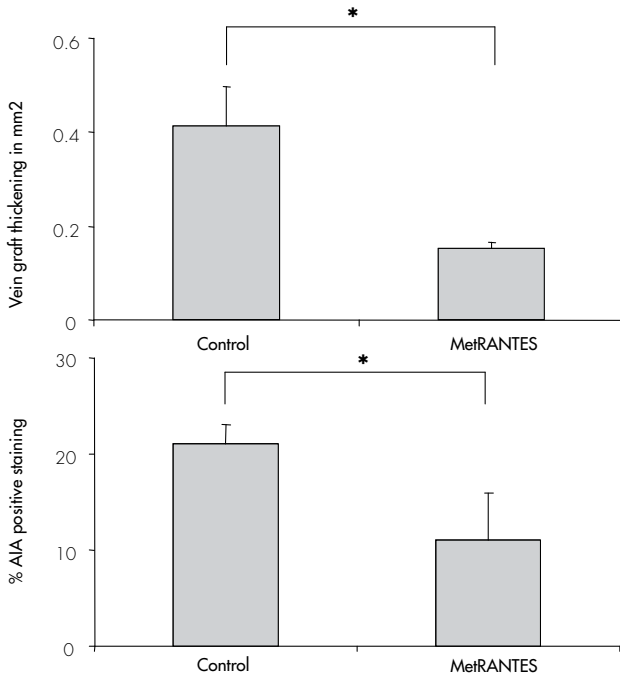
Interestingly, we found in vein grafts harvested after 3 days, hardly any T-cells present and this was not related to Met-RANTES-treatment. Although this study was not designed to study the involvement of T-cells in vein graft thickening, this observation might indicate that T-cells are less involved in the earlier stages of vascular remodeling in this model. Exploring the exact value of this finding, however, requires further studies.

Recently, Zerneck and colleagues demonstrated that CCR5 is more crucial than CCR1 for neointimal plaque formation. This might also be the case in our study. With the use of the CCR1/CCR5 antagonist Met-RANTES it is not possible to discriminate the individual contribution of both. The same question can be posed for the individual contribution of RANTES, MIP-1 α or other (unknown) CC-chemokines sharing the CCR1 and CCR5 receptor. Further studies in CC-chemokine knock-out mice with hypercholesterolemic features are needed to answer these questions.

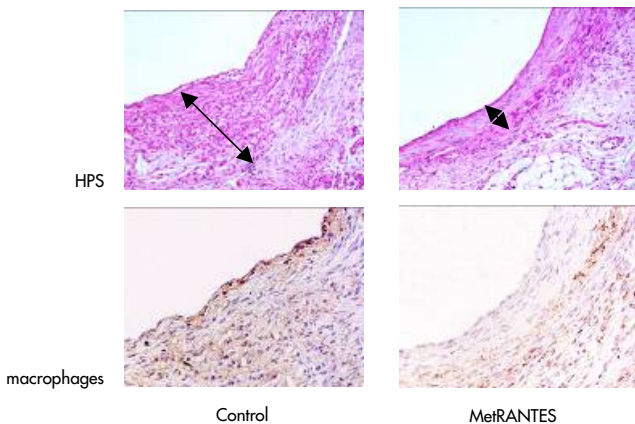
In conclusion, we have demonstrated a causal involvement of the CCR1/CCR5 pathway in vein graft thickening in a mouse model using hypercholesteremic ApoE3Leiden mice. This was demonstrated by the profound inhibition of vein graft thickening by Met-RANTES and was further underscored by the upregulation of both the CC-chemokines MIP-1 α and RANTES and their receptors.

Therefore, we have provided evidence that RANTES/MIP-1 α - CCR receptor interactions are an important early trigger for vein graft thickening. This establishes the hypothesis that inflammatory pathways are involved in the development of vein graft thickening. Therapy that interferes in the RANTES/MIP-1 α - CCR axis might be an interesting new target in order to overcome the clinical problem of vein graft disease.

Figure 6.4: Effect of Met-RANTES on vein graft thickening and plaque composition (n=8 per group). Panel A displays the quantified data of both vein graft thickening and macrophage content of the plaque as defined by percentage of staining positive for AIA31240.




Panel B shows representative pictures of HPS and AIA 31240 staining (magnification 200x, arrows indicate thickened vein graft wall).



REFERENCES

1. Adams DH, Lloyd AR. Chemokines: leucocyte recruitment and activation cytokines. *Lancet* 1997 February 15;349(9050):490-5.
2. Aiello RJ, Bourassa PA, Lindsey S, Weng W, Natoli E, Rollins BJ, Milos PM. Monocyte chemoattractant protein-1 accelerates atherosclerosis in apolipoprotein E-deficient mice. *Arterioscler Thromb Vasc Biol* 1999 June;19(6):1518-25.
3. de Lemos JA, Morrow DA, Sabatine MS, Murphy SA, Gibson CM, Antman EM, McCabe CH, Cannon CP, Braunwald E. Association between plasma levels of monocyte chemoattractant protein-1 and long-term clinical outcomes in patients with acute coronary syndromes. *Circulation* 2003 Feb 11;107(5):690-5 2003 February 11;107(5):690-5.
4. Egashira K, Zhao Q, Kataoka C, Ohtani K, Usui M, Charo IF, Nishida K, Inoue S, Katoh M, Ichiki T, Takeshita A. Importance of monocyte chemoattractant protein-1 pathway in neointimal hyperplasia after periarterial injury in mice and monkeys. *Circ Res* 2002 June 14;90(11):1167-72.
5. Schepers A, Eefting D, Bonta PI, Grimbergen JM, de Vries MR, van W, V, De Vries CJ, Egashira K, van Bockel JH, Quax PH. Anti-MCP-1 gene therapy inhibits vascular smooth muscle cells proliferation and attenuates vein graft thickening both in vitro and in vivo. *Arterioscler Thromb Vasc Biol* 2006 September;26(9):2063-9.
6. Proudfoot AE, Power CA, Hoogwerf AJ, Montjovent MO, Borlat F, Offord RE, Wells TN. Extension of recombinant human RANTES by the retention of the initiating methionine produces a potent antagonist. *J Biol Chem* 1996 February 2;271(5):2599-603.
7. Proudfoot AE, Buser R, Borlat F, Alouani S, Soler D, Offord RE, Schroder JM, Power CA, Wells TN. Amino-terminally modified RANTES analogues demonstrate differential effects on RANTES receptors. *J Biol Chem* 1999 November 5;274(45):32478-85.
8. Chvatchko Y, Proudfoot AE, Buser R, Juillard P, Alouani S, Kosco-Vilbois M, Coyle AJ, Nibbs RJ, Graham G, Offord RE, Wells TN. Inhibition of airway inflammation by amino-terminally modified RANTES/CC chemokine ligand 5 analogues is not mediated through CCR3. *J Immunol* 2003 November 15;171(10):5498-506.
9. Ajuebor MN, Hogaboam CM, Kunkel SL, Proudfoot AE, Wallace JL. The chemokine RANTES is a crucial mediator of the progression from acute to chronic colitis in the rat. *J Immunol* 2001 January 1;166(1):552-8.
10. Anders HJ, Frink M, Linde Y, Banas B, Wornle M, Cohen CD, Vielhauer V, Nelson PJ, Grone HJ, Schlondorff D. CC Chemokine Ligand 5/RANTES Chemokine Antagonists Aggravate Glomerulonephritis Despite Reduction of Glomerular Leukocyte Infiltration. *J Immunol* 2003 June 1;170(11):5658-66.
11. Bhatia M, Proudfoot AE, Wells TN, Christmas S, Neoptolemos JP, Slavin J. Treatment with Met-RANTES reduces lung injury in caerulein-induced pancreatitis. *Br J Surg* 2003 June;90(6):698-704.
12. Shahrara S, Proudfoot AE, Woods JM, Ruth JH, Amin MA, Park CC, Haas CS, Pope RM, Haines GK, Zha YY, Koch AE. Amelioration of rat adjuvant-induced arthritis by Met-RANTES. *Arthritis Rheum* 2005 June;52(6):1907-19.
13. Yun JJ, Whiting D, Fischbein MP, Banerji A, Irie Y, Stein D, Fishbein MC, Proudfoot AE, Laks H, Berliner JA, Ardehali A. Combined blockade of the chemokine receptors CCR1 and CCR5 attenuates chronic rejection. *Circulation* 2004 February 24;109(7):932-7.
14. Zou Y, Dietrich H, Hu Y, Metzler B, Wick G, Xu Q. Mouse model of venous bypass graft arteriosclerosis. *Am J Pathol* 1998 October;153(4):1301-10.
15. Lardenoye JH, de Vries MR, Lowik CW, Xu Q, Dhore CR, Cleutjens JP, van Hinsbergh VW, van Bockel JH, Quax PH. Accelerated atherosclerosis and calcification in vein grafts: a study in APOE*3 Leiden transgenic mice. *Circ Res* 2002 October 1;91(7):577-84.
16. Lardenoye JH, Delsing DJ, de Vries MR, Deckers MM, Princen HM, Havekes LM, van Hinsbergh VW, van Bockel JH, Quax PH. Accelerated atherosclerosis by placement of a perivascular cuff and a cholesterol-rich diet in ApoE*3Leiden transgenic mice. *Circ Res* 2000 August 4;87(3):248-53.
17. Reape TJ, Groot PH. Chemokines and atherosclerosis. *Atherosclerosis* 1999 December;147(2):213-25.
18. Schepers A, Eefting D, Bonta PI, Grimbergen JM, de Vries MR, van W, V, De Vries CJ, Egashira K, van Bockel JH, Quax PH. Anti-MCP-1 Gene Therapy Inhibits Vascular Smooth Muscle Cells Proliferation and Attenuates Vein Graft Thickening Both In Vitro and In Vivo. *Arterioscler Thromb Vasc Biol* 2006 July 6.
19. Ali ZA, Bursill CA, Hu Y, Choudhury RP, Xu Q, Greaves DR, Channon KM. Gene transfer of a broad spectrum CC-chemokine inhibitor reduces vein graft atherosclerosis in apolipoprotein E-knockout mice. *Circulation* 2005 August 30;112(9 Suppl):I235-I241.
20. Wilcox JN, Nelken NA, Coughlin SR, Gordon D, Schall TJ. Local expression of inflammatory cytokines in human atherosclerotic plaques. *J Atheroscler Thromb* 1994;1 Suppl 1:S10-S13.
21. Pattison JM, Nelson PJ, Huie P, Sibley RK, Krensky AM. RANTES chemokine expression in transplant-associated accelerated atherosclerosis. *J Heart Lung Transplant* 1996 December;15(12):1194-9.

22. Lukacs NW, Strieter RM, Elnor VM, Evanoff HL, Burdick M, Kunkel SL. Intercellular adhesion molecule-1 mediates the expression of monocyte-derived MIP-1 alpha during monocyte-endothelial cell interactions. *Blood* 1994 March 1;83(5):1174-8.
23. Kobayashi H, Koga S, Novick AC, Toma H, Fairchild RL. T-cell mediated induction of allogeneic endothelial cell chemokine expression. *Transplantation* 2003 February 27;75(4):529-36.
24. Hayes IM, Jordan NJ, Towers S, Smith G, Paterson JR, Earnshaw JJ, Roach AG, Westwick J, Williams RJ. Human vascular smooth muscle cells express receptors for CC chemokines. *Arterioscler Thromb Vasc Biol* 1998 March;18(3):397-403.
25. Veillard NR, Brauersreuther V, Arnaud C, Burger F, Pelli G, Steffens S, Mach F. Simvastatin modulates chemokine and chemokine receptor expression by geranylgeranyl isoprenoid pathway in human endothelial cells and macrophages. *Atherosclerosis* 2005 November 28.
26. Veillard NR, Kwak B, Pelli G, Mulhaupt F, James RW, Proudfoot AE, Mach F. Antagonism of RANTES receptors reduces atherosclerotic plaque formation in mice. *Circ Res* 2004 February 6;94(2):253-61.
27. Schober A, Manka D, von Hundelshausen P, Huo Y, Hanrath P, Sarembock IJ, Ley K, Weber C. Deposition of platelet RANTES triggering monocyte recruitment requires P-selectin and is involved in neointima formation after arterial injury. *Circulation* 2002 September 17;106(12):1523-9.
28. Libby P, Geng YJ, Aikawa M, Schoenbeck U, Mach F, Clinton SK, Sukhova GK, Lee RT. Macrophages and atherosclerotic plaque stability. *Curr Opin Lipidol* 1996 October;7(5):330-5.



CHAPTER 7

Inhibition of Complement Component C3 Reduces Vein Graft Atherosclerosis in ApoE3Leiden Transgenic Mice.

A. Schepers MD^{1,2}, M.R. de Vries BSc¹, C.J. van Leuven BSc¹, J.M. Grimbergen BSc¹, V.M. Holers MD PhD⁴, M.R. Daha PhD³, J.H. van Bockel MD PhD², P.H.A. Quax PhD^{1,2}

¹Gaubius Laboratory, TNO Quality of Life, Leiden, The Netherlands, ²Department of Vascular Surgery, Leiden University Medical Centre, Leiden, The Netherlands,

³Department of Renal Diseases, Leiden University Medical Centre, Leiden, The Netherlands, ⁴Department of Rheumatology, University of Colorado Health Sciences Center, Denver, Colorado, USA.

Circulation 2006; 114:2831-2838

ABSTRACT

Background: Venous bypass grafts may fail due to development of intimal hyperplasia and accelerated atherosclerosis. Inflammation plays a major role in these processes. Complement is an important part of the immune system and participates in the regulation of inflammation. However, the exact role of complement in the process of accelerated atherosclerosis of vein grafts has not yet been explored.

Methods and Results: To assess the role of complement on the development of vein graft atherosclerosis, a mouse model, in which a venous interposition is placed in the common carotid artery, was used. In this model vein graft thickening appears within four weeks. The expression of complement components was studied using immunohistochemistry on sections of the thickened vein graft. C1q, C3, C9 and the regulatory proteins CD59 and Crry could be detected in the lesions four weeks after surgery.

Quantitative mRNA analysis for C1q, C3, CD59 and Crry revealed expression for these molecules in the thickened vein graft, whereas C9 did not show local mRNA expression.

Furthermore, interference with C3 activation using Crry-Ig was associated with reduced vein graft thickening, reduced C3 and C9 deposition and reduced inflammation as assessed by analysis of influx of inflammatory cells, such as leucocytes, T-cells and monocytes. Also changes in apoptosis and proliferation were observed

When C3 was inhibited by Cobra Venom Factor, a similar reduction in vein graft thickening was observed.

Conclusion: The complement cascade is involved in vein graft thickening and may be a target for therapy in vein graft failure disease.

INTRODUCTION

Bypass graft surgery with venous grafts is one of the most frequently used therapies, both in cardiac as in peripheral vascular surgery, to treat atherosclerotic occlusive disease. However, graft patency is often compromised by formation of intimal hyperplasia (IH) and accelerated atherosclerosis, resulting in vein graft thickening. Failure rates as high as 50% after 10 years¹ have been reported, and re-interventions are often required.

The process of vein graft thickening is characterized by adhesion and influx of inflammatory cells and migration of vascular smooth muscle cells to the intima of the vein graft². Moreover, macrophages in the intima take up oxidized lipoproteins and become foam cells contributing to the development of accelerated atherosclerosis³⁻⁵. There is little information available about the mechanisms underlying these processes, but it is universally assumed that inflammation and, consequently the immune system plays a pivotal role⁵⁻⁷.

A major component of the immune system is the complement cascade^{8, 9}. Complement consists of a group of proteins, membrane-bound receptors and regulatory enzymes. Centrally in the complement cascade is complement component C3. Cleavage of C3 can be induced via three separate pathways; the classical pathway, alternative pathway and lectin pathway, all activated by specific substrates. Activation via one of the three pathways results in formation of C3 convertases. The convertases are capable of cleaving C3 into C3a and C3b, starting a cascade that ultimately results in activation of C5 and subsequently in formation of terminal complement component C5b-9 (also called Membrane-Attacking-Complex (MAC)). Furthermore, cleavage of C3 eventually leads to formation of potent chemotactic factors, such as C5a.

The role of complement in several inflammatory conditions is well recognized and described. It plays a major role in host defense to micro-organisms, hyperacute rejection after organ transplantation, in ischemia-reperfusion injury and in several auto-immune diseases. Atherosclerosis, like vein graft disease, is a form of vascular inflammation accompanied by intimal thickening, and several studies have been published pointing at a role for the complement system in the process. This hypothesis is supported by the detection of complement components in human atheroma while expression of several of these complement components is upregulated in atherosclerotic tissue. Furthermore, animal studies using knock-out mice and rabbits deficient in complement have been performed; however these show conflicting results^{10,11}. Data concerning the role of complement activation in vein graft thickening are lacking.

As mentioned above, C3 is the central component in complement activation. Inhibition of C3 activation provides good insight in the role of complement as a whole, since formation of biologically active end-products (e.g. C5b-9, C5a and C3a) is blocked. Several substances can be used to modify activation of C3. One of

the most widely used compounds is Cobra Venom Factor, derived of venom of *Naja* species. It functions as a C3b-like molecule and leads to unregulated C3 activation resulting in depletion of the complement cascade, however it is associated with generation of phlogistic component fragments from C3 and C5 indirectly leading to tissue activation. A more elegant approach to block C3 activation is using Crry-Ig, a recombinant protein of the mouse membrane complement inhibitor Crry (complement receptor-related gene γ) fused to IgG1-hinge¹². Crry-Ig demonstrates decay-accelerating activity for both the classical and alternative pathways of complement as well as cofactor activity for factor I-mediated cleavage of C3b and C4b and thus prevents increased activation of C3.

To study the role of complement activation in vein graft disease, we used a mouse model for vein graft disease in hypercholesterolemic ApoE3Leiden mice. This mouse model highly resembles graft morphology in patients regarding leukocyte adhesion and influx, foam cell accumulation, calcification in the vessel wall and development of a thin fibrous cap¹³. Not only expression of several complement factors, on both RNA and protein level, in the thickened vein graft was shown, but it was also demonstrated that treatment with Crry-Ig, which inhibits C3 activation, resulted in a significant decrease of intimal hyperplasia and accelerated atherosclerosis in murine vein grafts. With this study we show that activation of complement cascade plays a pivotal role in the development of vein graft thickening.

METHODS

Mouse model.

All experiments were approved by the institutes' Animal Welfare Committee. For all experiments male C57bl6 ApoE3Leiden mice¹⁴, age between 15 and 20 weeks, were used. During the experiment, animals were fed a high-fat high-cholesterol diet¹⁵, starting 3 weeks prior to surgery to induce hypercholesterolemia. All mice received water and food ad libitum. Cholesterol levels in serum were determined 1 day before surgery and at sacrifice. Mice were anesthetized by an intra-peritoneal (i.p.) injection with a combination of Midazolam (5mg/kg, Roche, Woerden, The Netherlands), Medetomidine (0.5mg/kg, Orion, Espoo, Finland) and Fentanyl (0.05mg/kg, Janssen, Berchem, Belgium).

Vein graft surgery was performed as described previously¹⁶. In summary, caval veins were harvested from genetically identical donor mice to serve as grafts and were preserved in 0.9% NaCl containing 100U/ml of heparin at 4 degrees Celcius. The right carotid artery was cut in the middle and a polyethylene cuff was placed at both ends of the artery. The artery was everted around the cuff and ligated with a silk 8.0 suture. Then the graft was sleeved over the two cuffs and ligated. Pulsations of the vein graft confirmed successful engraftment. Generally, this procedure is performed in 30min.

Crry-Ig.

Crry-Ig was produced as described¹². Crry-Ig treatment started one day prior to surgery and animals received 3mg of Crry-Ig i.p. every other day during the complete study period. The control group received a monoclonal murine IgG antibody (reactive with human CRP and no cross-reactivity in mice) of the same subtype in the same concentration every other day. This approach was previously described to be the proper control for Crry-Ig treatment¹⁷.

Cobra Venom Factor (CVF).

CVF (Quidel Corporation, San Diego, USA) was dissolved in sterile 0.9% NaCl. Animals received daily i.p. injections with 20IU/kg/day of CVF to deplete C3, throughout the whole study period starting one day prior to surgery. Animals in the control group received daily injections with sterile 0.9% NaCl.

Morphometric assessment of vein grafts.

Mice were sacrificed after either 7 or 28 days after surgery. Vein grafts were in vivo perfused with 4% formaldehyde, harvested and embedded in paraffin. Serial perpendicular cross sections were made of the specimen. All samples were routinely stained with hematoxylin-phloxine-saffron (HPS).

Morphometric analysis of vein grafts, harvested after 28d, was performed using image analysis software (Qwin, Leica, Wetzlar, Germany). Since only few layers of cells are in the media of murine veins and no morphological border exists between neointima and media, vein graft thickening, i.e. the region between lumen and adventitia, was used to define lesion area. For each mouse five equally spaced cross-sections were used to determine vessel wall thickening.

Immunohistochemistry.

To detect expression of complement factors, immunohistochemistry was performed on paraffin embedded sections of vein grafts harvested after 28d. The presence of C1q was assessed using rabbit-anti-mouse primary antibodies (Roche Applied Science, Basel, Switzerland) and C3 was detected with a rabbit-anti-mouse antibody (developed in our laboratory¹⁸). Anti-C9 (rabbit-anti-rat, cross reactive with mouse C9¹⁹), was a kind gift of Prof. B.P. Morgan (Cardiff University, Cardiff, UK). The antibody used to detect the complement regulatory enzyme CD59a (monoclonal rat-anti-mouse) was a kind gift of Dr Harris, (Cardiff University) and Crry was detected with a rat-anti-mouse anti-Crry antibody (BD Biosciences, Alphen a/d Rijn, the Netherlands).

Complement components were quantified using computer assisted morphometric analysis (Qwin), and expressed as total immuno-positive area as percentage of total vein graft area in cross-sections.

In grafts, smooth muscle cells (SMC) were stained using mouse-anti-rat anti-SM α -actin antibodies (cross reacts with mouse; Roche Applied Biosciences). Collagen was histochemically stained by Sirius Red. Leukocytes were detected using anti-

CD45 antibodies (Pharmingen, San Diego, USA). Different subsets of leukocytes were specified. The amount of macrophage derived foam cells within the thickened vessel wall was visualized by AIA31240 antibody (Accurate Chemical, Westbury, NY, USA).

T-cells were detected using anti-CD3 antibodies (Serotec, Raleigh, USA).

Cellular proliferation was quantified using PCNA staining (Calbiochem, San Diego, USA), whereas apoptotic cells were identified by TUNEL (Roche Applied Biosciences).

Quantification of all stainings, except those for smooth muscle cells and foam cells, occurred by counting the positive number of cells/slide and expressed as percentage of total number of nuclei (determined by Nucleus Red staining). Smooth muscle cell, collagen and foam cell quantification, due to their high occurrence in the vein grafts, was performed similar as the quantification of complement components.

RNA isolation, cDNA synthesis and RT-PCR.

RNA was isolated from caval veins and vein grafts harvested on several time points (t=6 and 24 hours after surgery and 3; 7; and 28d after surgery, n=4 per time point), using RNA Isolation Mini Kits for Fibrous Tissue (Qiagen, Venlo, the Netherlands; using the manufacturers protocol). DNase treatment was included (RNase Free DNase set, Qiagen). RNA (250 ng) was reverse-transcribed using the Ready-To-Go You-Prime-First-Strand Beads (Amersham Biosciences, Uppsala, Sweden).

Reverse-transcribed products were studied using semi-quantitative RT-PCR (Robocycler Gradient96, Stratagene, Cedar Creek, Texas, USA), with primers for C1q, C3, C9, CD59 and Crry (for sequences see Table 7.1). Samples were amplified for 35 cycles (30sec. at 94°C, 30sec at 56°C and 90sec. at 65°C) following an initial denaturation cycle for 2 min. at 94°C. The last cycle was followed by extension of 4 min. at 74°C. PCR products were visualized on 1.2% Agarose gel containing EthidiumBromide.

Table 7.1: *Primer sequences and length of PCR product of genes analyzed in RT-PCR.*

Gene	Forward primer	Reverse Primer	PCR-product
C1q	cagtggctgaagatgtctgc	ccgtgtggctctggtatgga	386
C3	gtagrtgcgcaacgaacaggtg	gtagtgtaccgcaatgactg	566
C9	cgtattcctctacaagacgac	ctccatttagacatgggtagc	402
Crry	catcacagcttcctctgcc	atcgttgctgtacagtata	500
CD59	tgtagctgaggagtgagatc	cctcctgagtactgagatc	405

Statistical Analysis.

All data were presented as mean±SEM. Statistical analysis was performed using SPSS 11.5 for Windows. Differences between groups were analyzed with a Student T-test. P-values<0.05 were regarded statistically significant.

RESULTS

Presence of complement components in intimal hyperplasia of murine vein grafts.

Twenty-eight days after surgery, mice (n=6) were sacrificed and vein grafts were harvested in order to detect complement factors and regulatory enzymes by immunohistochemistry (Figure 7.1). These factors were elicited on the basis that each represents a specific part of the complement cascade (e.g. C1q; early classical pathway, C3; central component, C9 part of the membrane attack complex, CD59 and Crry; regulatory molecules).

Regulatory enzymes CD59 and Crry in vein grafts demonstrate a different expression pattern. CD59 shows a diffuse expression throughout the thickened vein graft, whereas expression of the membrane-bound Crry shows a patchy, cell bound distribution, and is mainly localized in the media and adventitia of the murine vein graft. Magnification of all pictures 150x.

Massive presence of C1q was seen in thickened vein grafts, mainly deep in the intimal hyperplasia co-localizing with foam cells. Furthermore, inflammatory cells attached to the endothelium and in the adventitia of the veins showed positive staining. C3 was predominantly expressed in the same regions as C1q, being in macrophage derived foam cells, adhering and adventitial inflammatory cells and also in the endothelium. In addition, C9 co-localized highly with macrophages in the thickened intima but was not expressed by endothelial cells.

Complement inhibitor CD59 was detected diffusely distributed in all layers of the vessel wall. The membrane-bound Crry showed a patchy distribution in cells of the media and adventitia. Endothelial cells showed positive staining in about one-third of cells.

Presence of RNA coding for complement components in murine vein grafts.

Local production of complement component was examined by RNA analysis of vein grafts. Sixteen mice underwent vein graft surgery and were sacrificed on several time points (t= 6h, 24h, 3d, 7d and 28d). Also normal, not yet interposed, caval veins of donor mice were included. RT-PCR was performed for C1q, C3, C9, CD59 and Crry (Figure 7.2).

Figure 7.1: Expression of complement factors in thickened murine vein graft of ApoE3Leiden mice, 28 days after surgery. Massive intima hyperplasia formation vein graft thickening is observed, as indicated with arrows (HPS). The cellular composition (consisting of smooth muscle cells and macrophage-derived foam cells) of the thickened vein graft is shown. Immunohistochemical detection of complement factors C1q, C3 and C9. Both C1q and C3 are abundantly present in the deeper parts of the intimal hyperplasia co-localizing with foam cells. Furthermore, C1q and C3 are expressed in the endothelial layer and in inflammatory cells (mainly macrophages) adhering to the vessel wall and present in the adventitia. C9 is not detectable in the endothelium and inflammatory cells. However, like C1q and C3, it is present in the deeper parts of the intimal hyperplasia.

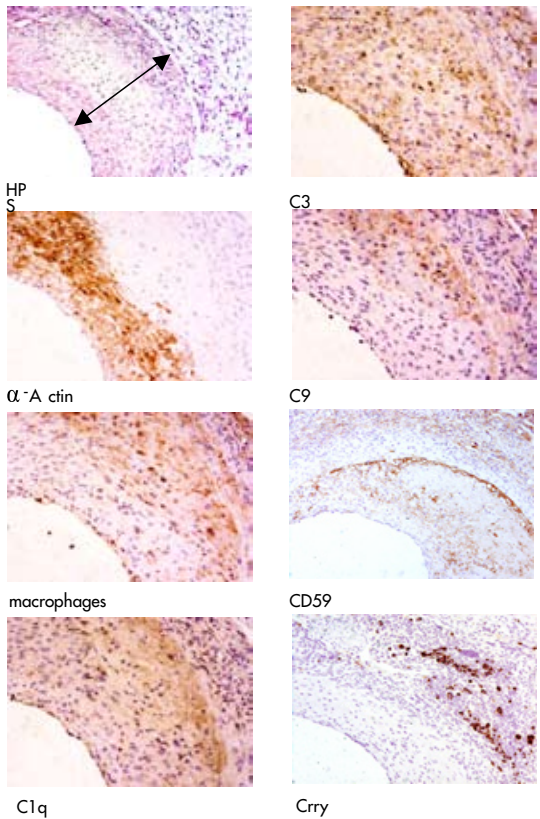
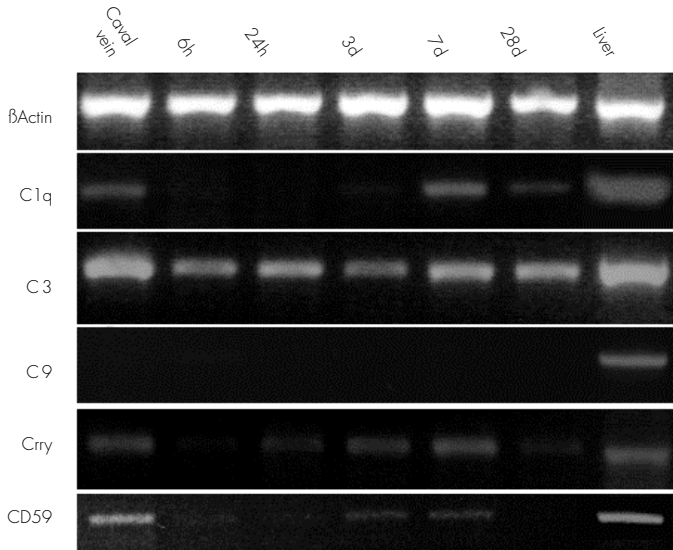


Figure 7.2: Expression of C1q-, C3- and Crry-mRNA in the caval vein and murine vein graft harvested at several time points after surgery (n=4 per time point). β -Actin was included as a housekeeping gene and sterile H₂O was used as a negative control.



Minimal expression of C1q mRNA was seen in caval veins. In vein grafts, C1q mRNA was not detectable in the first 24 hours after surgery. However, 3 days after surgery, C1q mRNA was clearly present and expression remained constant for the rest of the study period.

C3 showed an explicit expression in vein grafts in all stages of remodeling. Interestingly, an equal expression was seen in caval veins, showing that also without a remodeling process going on in the vessel, local production of C3 occurs. mRNA expression of complement component C9 could not be detected in vein grafts, whereas expression in liver tissue (positive control) appeared clearly positive, indicating that C9-protein is not produced locally in vein grafts.

Crry mRNA was clearly detectable in normal caval veins. Down-regulation of Crry mRNA expression was seen in the first days after surgery, whereas after 7d an increased expression was seen to the level of normal caval veins.

Complement inhibitor CD59 showed robust expression in normal caval veins, whereas expression in the remodeling vein graft was present but appeared lower.

Effect of Crry-Ig treatment on vein graft thickening and complement expression.

The studies above suggest involvement of the classical pathway on vein graft thickening. Earlier studies demonstrated efficient blockage of complement activation

by Crry-Ig. Twelve ApoE3Leiden mice were randomly divided into two treatment groups. One group received 3mg (i.p.) Crry-Ig every other day; controls received an injection with 3mg of non-relevant monoclonal antibody of the same isotype every other day. No significant differences were observed between groups in preoperative bodyweight, bodyweight at sacrifice and cholesterol levels before surgery and at sacrifice.

Vein grafts were harvested after 28d and vein graft thickening was quantified. Crry-Ig treated mice exhibited approximately 50% less vein graft thickening, when compared to controls (control $0.36\pm 0.07\text{mm}^2$, Crry-Ig $0.18\pm 0.01\text{mm}^2$, $p=0.028$). Luminal area was equal in both groups (control $0.53\pm 0.04\text{mm}^2$, Crry-Ig $0.40\pm 0.06\text{mm}^2$, $p=0.28$). Consequently, total vessel wall area was significantly larger in the control group ($0.56\pm 0.05\text{mm}^2$) when compared to Crry-Ig treated vein grafts ($0.89\pm 0.07\text{mm}^2$, $p=0.016$), indicating reduced outward remodeling in the Crry-Ig treated group.

C1q quantity in vein grafts was not affected by Crry-Ig and demonstrated no differences with control IgG treated mice (control: $25\pm 4\%$, Crry-Ig: $25\pm 2\%$, $p=0.48$).

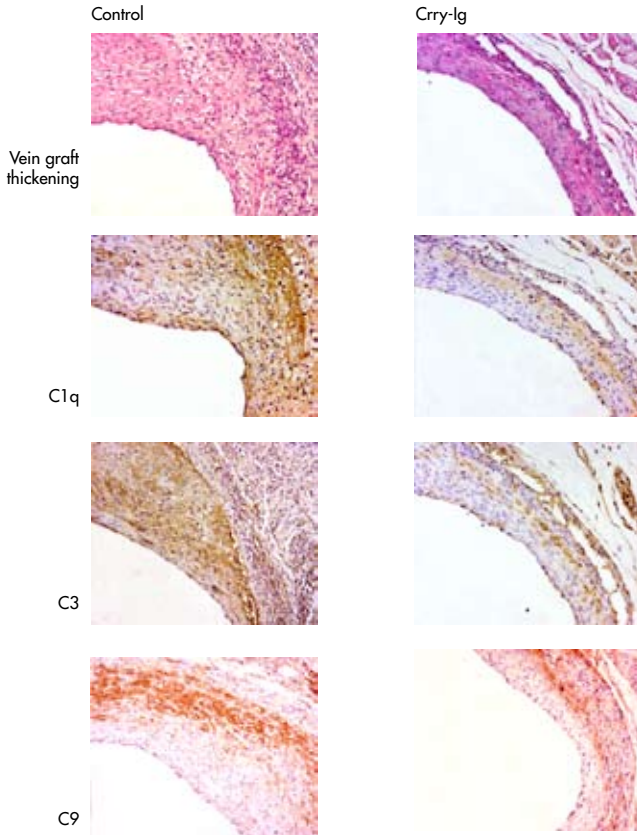
A significant decrease of C3 deposition was observed in Crry-Ig treated mice, compared to controls (control: $37\pm 4\%$, Crry-Ig: $21\pm 3\%$, $p=0.007$). Moreover, presence of C9 protein, was reduced in Crry-Ig treated vessels (control $19\pm 3\%$, Crry-Ig $9\pm 2\%$, $p=0.007$). Data are summarized in Figure 7.3.

Figure 7.3: *Effect of Crry-Ig treatment on development of intimal hyperplasia and accelerated atherosclerosis in murine vein grafts. Quantitative analysis of the effect of Crry-Ig treatment on development of intimal hyperplasia and accelerated atherosclerosis in murine vein grafts and C1q, C3 and C9 deposition in the vein grafts.*

	Control	Crry-Ig
Vein graft thickening (in mm^2)	$0.36\pm 0.07 \text{ mm}^2$	$0.18\pm 0.01 \text{ mm}^2$ *
C1q deposition (% of total IH)	$25\pm 4\%$	$25\pm 2\%$
C3 deposition (% of total IH)	$37\pm 4\%$	$21\pm 3\%$ *
C9 deposition (% of total IH)	$19\pm 3\%$	$9\pm 2\%$ *

* $p<0.05$

Representative cross section demonstrating reduced vein graft thickening, similar amounts of C1q deposition, and reduced C3 and C9 deposition (magnification 150x).



Effect of Crry-Ig treatment on cellular composition of remodeling vein grafts.

To study the effect of blocking complement activation on cellular composition, 24 mice underwent surgery, were treated with either Crry-Ig or a non-relevant monoclonal antibody (as described above) and were sacrificed after 7 or 28d (n=6 in each group).

Overall, as expected, vein grafts harvested after 28d contained more cells than the ones harvested after 7d, and Crry-Ig treated grafts contained less cells as their untreated controls after 28d (control 7d: 228±59, Crry-Ig 7d: 227±32, n.s and control 28d: 2296±565, Crry-Ig 28d: 1143±69, p=0.044).

SMC content was analyzed in vein grafts harvested after 28d, since in the first week after engraftment all SMC disappear in this model¹³. In the Crry-Ig treated group, thickened vein grafts had a significant higher relative SMC content than the control

group (control: 33±5%, Crry-Ig: 47±3%, p=0.04). The amount of collagen deposition, however, did not significantly differ between both groups (control 33±4%, Crry-Ig 29±2%, p=0.5).

Influx of CD45 positive leukocytes was especially seen after 7d and strongly reduced by Crry-Ig treatment (control: 31.3±10.2%, Crry-Ig: 9.6±1.5%, p=0.034). At 28d the relative amount of CD45-positive leukocytes was much lower and not significantly different between groups (control: 1.8±0.4%, Crry-Ig: 1.9±0.9%, p=0.44). In the seven-day vein grafts monocytes in both groups were predominantly adhering to the vessel wall and invading in the vein graft. Crry-Ig treatment resulted in a 42%, yet not significant reduction, in adhering monocytes (control: 7.0±1.8%, 4.1±0.9%, p=0.08). After 28d, AIA31240-immunostaining revealed mainly macrophage-derived foam cells in the plaque area. A significantly lowered foam cell content was seen in vein grafts of Crry-Ig treated animals (Crry-Ig: 16±1%, control: 25±5%, p=0.043) after 28d. Regarding CD3-positive T-cells, a significant difference could be seen after 7d (control: 1.9±0.6%, Crry-Ig: 0.7±0.1%, p=0.05), however after 28d, this difference could not be observed (control: 1.8±0.6, Crry-Ig: 1.2±0.3%, p=0.21). Results are summarized in Table 7.2.

Table 7.2: *Effect of Crry-Ig treatment on cellular composition and cytokinetics of remodeling vein grafts, both 7 and 28 days after surgery (determined by immunohistochemistry, n=6 for each value). Positively stained cells are expressed as a percentage of total number of cells. np: analysis not performed; * represents p<0.05.*

	Control 7d	Crry-Ig 7d	Control 28d	Crry-Ig 28d
Total # cells	228±59	227±32	2296±565	1143±69*
Smooth muscle cells	n.p.	n.p.	33±5%	47±3%*
Collagen	n.p.	n.p.	33±4%	29±2%
CD45	31±9%	10±2%*	1.8±0.4%	1.9±0.9%
Monocytes/ foam cells	7.0±1.9%	4.1±0.9%	25±5.0%	16±1.0%*
CD3	1.9±0.6%	0.7±0.1%*	1.8±0.6%	1.2±0.3%
TUNEL	0.7±0.4%	3.0±0.6%*	0.2±0.01%	0.2±0.03%
PCNA	11±1.3%	6.7±1.2%*	2.3±0.7%	1.8±0.6%

Effect of Crry-Ig treatment on cytokinetics of remodeling vein grafts.

To get insight on the possible mechanisms of the effect of complement inhibition on vein graft remodeling, we analyzed the effects of Crry-Ig treatment on cell

proliferation and apoptosis. Regarding proliferation, Crry-Ig treatment resulted in reduced cellular proliferation after 7d as assessed by PCNA immunohistochemistry (control: 10.6±1.3%, Crry-Ig: 6.7±1.2%, p=0.036) After 28d, cellular proliferation declined and no differences were seen between both groups (control: 2.3±0.7%, Crry-Ig: 1.8±0.6%, p=0.3).

Surprisingly, Crry-Ig treatment led to increased numbers of TUNEL-positive apoptotic cells in vein graft 7d after surgery (control: 0.7±0.4%, Crry-Ig: 3.0±0.6%, p=0.005). However, after 28d, the number of apoptotic cells was decreased in both groups to such a level that no conclusion was justified. All data are summarized in Table 7.2.

Effect of CVF treatment on vein graft thickening.

To demonstrate that the observed effect is not Crry-Ig-specific, an alternative treatment affecting C3 activation was tested. Therefore, Cobra Venom Factor (CVF) was administered. Vein grafting was performed in 12 mice and 6 were treated with CVF (20IU/kg/day). Mice were sacrificed after 28d. Quantification of vein graft thickening revealed a 63% reduction of intimal hyperplasia in CVF-treated animals (0.15±0.01mm²), when compared to controls (0.41±0.10mm², p=0.016). Luminal surface did not differ significantly between groups (CVF: 0.49±0.06mm², control 0.59±0.07mm², p=0.47).

DISCUSSION

This study argues for a causal role for complement activation in general, and C3 activation in particular, in the process of venous bypass graft thickening. To our knowledge, this is the first study that not only demonstrates presence of complement components in vein grafts but also provides evidence that inhibition of C3 activation results in a marked decrease of vein graft thickening *in vivo*.

Intimal hyperplasia formation and accelerated atherosclerosis in vein grafts is considered to be the result of an inflammatory process⁵⁻⁷. This process is initiated by mechanical vessel damage and hypoxia during surgery and by altered shear stress that the vein is being subjected to after surgery. Several animal models are developed to mimic this process. In this study a mouse model is used, in which caval veins of donor mice are placed as interposition in the common carotid artery¹⁶. When performed in hypercholesterolemic mice, vein graft thickening occurs with signs of accelerated atherosclerosis¹³. The morphology of the observed lesions highly resembles what is seen in human vein grafts, underlining the relevance of this model.

Since the complement cascade is an important part of the innate immune system and is also involved in initiation of adaptive immune responses, it might be one of the mediators of inflammatory processes in remodeling vein grafts.

The presence of complement components (C1q, C3 and C9) and regulatory molecules (CD59a and Crry) in murine vein grafts was shown by immunohistochemistry. Furthermore, we analyzed local synthesis of complement components, defined as mRNA expression in vein grafts. Although synthesis of complement components is believed to be localized in the liver, recently evidence of extra-hepatic synthesis of complement components has been published. RT-PCR analysis of vein grafts at various time points after surgery revealed local expression mRNA coding for C1q, C3, CD59 and Crry. No local production of C9 could be detected, indicating that C9 protein deposited in vein grafts, as seen by immunohistochemistry, is produced elsewhere.

Although C3 mRNA expression was detectable in the vessel wall of caval veins, no up- or downregulation of C3 on mRNA level could be detected in vein grafts. Several possible explanations for this finding could be given. One might be that, although mRNA C3 is produced locally in vein grafts, this may not tell us much about C3 activity and protein presence. Furthermore, C3 is mainly produced in the liver, as most of the complement components, and is abundantly present in plasma. This liver derived C3 might be crucial for mediating the effects on vein graft thickening, whereas the role of locally produced C3 is unclear. In addition, factors involved in regulating local levels of (active) C3 and the effects of C3 down stream molecules on C3 levels in vein graft remodeling are not completely understood.

We were unable to detect activated complement factors or MAC, because of the lack of specific antibodies against murine activated complement components e.g. murine iC3b, C5b-9 or C5a. Since C3 is the central protein in the complement cascade, it was used as a specific target for our interventional experiments. C3 activation was blocked using Crry-Ig, an inhibitor for all activation pathways by the inhibition of C3 convertases. Crry-Ig treatment resulted in a significantly lower C3 and C9 deposition in vein grafts, accompanied by an inhibition of vein graft thickening of approximately 50%. Analysis of cytokinetics and cellular composition of vein grafts at 7 and 28 days, provided insight in the mechanism by which complement inhibition may affect vein graft remodeling. When C3 was inhibited by Crry-Ig, one of the first phenomena seen is reduced adherence and influx of leucocytes, possibly as a result of absence of (complement activation-derived) chemotactic stimuli. This points at tempered inflammatory activity in remodeling vein grafts. Reduction in inflammatory activation of the vein graft wall is thought to be the main cause of reduced vein graft thickening. Reduction of leucocyte adhesion and influx is accompanied by reduced numbers of proliferating cells in the remodeling vein graft and induction of apoptosis. This induction of apoptosis is unexpected, since reduced inflammation is usually accompanied by reduced apoptosis. No specific cell type or location could be associated to the observed apoptosis.

After 28 days, plaque composition was significantly altered in the Crry-Ig treated group, favoring SMC and reduced numbers of foam cells. Increase numbers of SMC in thickened vein grafts reflect a desirably state, since this is believed to be one of the main contributions to plaque stability.²⁰ The observation that vein graft thickening

can also be hampered by Cvf (another potent C3 activation inhibitor) shows that the phenomena seen after Crry-Ig treatment, are not Crry-Ig specific, but are caused by C3 inhibition. Inhibition of vein graft thickening following treatment with Crry-Ig also suggests that circulating complement components play a role in the remodeling process.

The demonstrable C1q in vein grafts suggest involvement of the classical pathway. Interestingly, we found a reduced C1q mRNA expression in the early phases after surgery, followed by enhanced expression in later stages. Regrettably, very little is known about *in vivo* C1q mRNA regulation in various cell types. However, since C1q in this model is predominantly expressed by monocytes and macrophages, and macrophage C1q mRNA expression has been shown to alter during the various stages of macrophage maturation *in vitro*²¹, this reduced C1q mRNA expression in the early stages might be due to a temporary lowered C1q mRNA expression as a consequence of ongoing maturation during the transition of adhering monocytes into tissue macrophages.

Furthermore, we found that in the early phases after surgery, Crry mRNA expression was decreased, and therefore diminishing complement inhibition potential of the vein graft. This might be one of the causes responsible for complement activation in this model. However, other questions need to be considered. For instance, what triggers complement activation in venous bypass grafts, and which of the activation routes are accountable for activation? There are several possibilities.

A venous interposition can be seen as an autologous transplant; it undergoes ischemia-reperfusion injury during the procedure. In other models for ischemia-reperfusion the production of “natural antibodies” by CD5 positive B- cells is described, leading to deposition of IgM antibodies and thereby triggering the classical pathway²². This is confirmed by the study of Fitzmaurice²³, he was able to detect immunoglobulins and C3 depositions in human saphenous vein grafts. We show the presence of C1q protein and mRNA in various phases of the remodeling process, suggesting that the classical pathway actually might play a role. Besides the classical pathway as the major activating pathway of the complement system in ischemia-reperfusion, recently Stahl et al described the role of the alternative pathway in (intestinal) ischemia-reperfusion injury²⁴ and Thurman et al found that the alternative pathway alone was required for renal ischemia-reperfusion injury²⁵.

In addition, LDL depositions in the vessel wall might be responsible for complement activation in this model. Torzewski et al previously described co-localization of C5b-9 and enzymatically altered LDL in deeper parts of the intima of early atherosclerotic lesions²⁶. Furthermore, it was shown that this enzymatically modified LDL is atherogenic and can induce complement activation via the alternative route *in vitro*^{27, 28}. However, since fat deposition and foam cell formation occurs relatively late in the model used in this study and the observed effects on cellular influx were present after 7d, it is not likely that this route of complement activation plays a role in this model.

Furthermore, the vein graft is liable to an arterial blood pressure and an increased shear stress, causing damage to the vein graft wall. Also the surgical procedure leads to damage of the vein graft. This results in a mechanical denudation of the endothelium and apoptosis of remaining endothelial cells. It has been described before, that apoptotic (endothelial) cells can induce complement activation both via the classical²⁹ and alternative pathway³⁰. Which of the three activation pathways, alone or in combination, is responsible for the activation of complement and by what kind of injury this activation is triggered remains to be determined and further research is necessary to indicate the role of each of these modalities in vein graft disease.


When translating data from mouse studies to the human situation, several issues should be taken into account. Firstly, mice do not develop spontaneously atherosclerosis. Therefore usually genetically-altered hypercholesterolemic mice are used to induce atherosclerotic lesions, either spontaneously after prolonged exposure to a hypercholesterolemic environment or in an accelerated way after vascular intervention. Although the ApoE3Leiden mice used in this study suffered relatively mild hypercholesterolemia (serum cholesterol between 8-10 mmol/l), cholesterol levels still exceed serum levels seen in most of the patients. As previous reports have shown, severe hypercholesterolemia might induce increased vascular inflammatory reactions^{13, 31} and consequently atherosclerotic lesion formation. Furthermore, due to anatomic variations between human and mice, it can be assumed that after engraftment, as a result of the 10-fold increase in blood pressure, more extensive graft distension and subsequent vascular damage and SMC apoptosis is occurring in (only a few cell-layers thick) murine vein grafts when compared to the human counterpart.

In conclusion, several complement factors (both on protein and mRNA level) are present in thickened vein grafts, and treatment with Crry-Ig (interfering in C3 activation) results in marked reduction of vein graft thickening. This reduction coincides with reduced numbers of leucocytes in early stages of vein graft remodeling, and increased numbers of smooth muscle cells in the later stage. Therefore, we have provided evidence that activation of C3, and thereby the complement cascade, is an important early trigger for vein graft thickening. Therapy that interferes in the function of C3 might be an interesting new target in order to overcome the clinical problem of vein graft disease.

REFERENCES

1. Bush HL, Jr., Jakubowski JA, Curl GR, Deykin D, Nabseth DC. The natural history of endothelial structure and function in arterialized vein grafts. *J Vasc Surg* 1986 February;3(2):204-15.
2. Eslami MH, Gangadharan SP, Belkin M, Donaldson MC, Whittemore AD, Conte MS. Monocyte adhesion to human vein grafts: a marker for occult intraoperative injury? *J Vasc Surg* 2001 November;34(5):923-9.
3. Bulkley BH, Hutchins GM. Accelerated "atherosclerosis". A morphologic study of 97 saphenous vein coronary artery bypass grafts. *Circulation* 1977 January;55(1):163-9.
4. Davies MG, Hagen PO. Pathophysiology of vein graft failure: a review. *Eur J Vasc Endovasc Surg* 1995 January;9(1):7-18.
5. Ratliff NB, Myles JL. Rapidly progressive atherosclerosis in aortocoronary saphenous vein grafts. Possible immune-mediated disease. *Arch Pathol Lab Med* 1989 July;113(7):772-6.

6. Christiansen JF, Hartwig D, Bechtel JF et al. Diseased vein grafts express elevated inflammatory cytokine levels compared with atherosclerotic coronary arteries. *Ann Thorac Surg* 2004 May;77(5):1575-9.
7. Hoch JR, Stark VK, Hullett DA, Turnipseed WD. Vein graft intimal hyperplasia: leukocytes and cytokine gene expression. *Surgery* 1994 August;116(2):463-70.
8. Walport MJ. Complement. First of two parts. *N Engl J Med* 2001 April 5;344(14):1058-66.
9. Walport MJ. Complement. Second of two parts. *N Engl J Med* 2001 April 12;344(15):1140-4.
10. Oksjoki R, Kovanen PT, Pentikainen MO. Role of complement activation in atherosclerosis. *Curr Opin Lipidol* 2003 October;14(5):477-82.
11. Niculescu F, Rus H. The role of complement activation in atherosclerosis. *Immunol Res* 2004;30(1):73-80.
12. Quigg RJ, Kozono Y, Berthiaume D et al. Blockade of antibody-induced glomerulonephritis with Crry-Ig, a soluble murine complement inhibitor. *J Immunol* 1998 May 1;160(9):4553-60.
13. Lardenoey JH, de Vries MR, Lowik CW et al. Accelerated atherosclerosis and calcification in vein grafts: a study in APOE*3 Leiden transgenic mice. *Circ Res* 2002 October 1;91(7):577-84.
14. van den Maagdenberg AM, Hofker MH, Krimpenfort PJ et al. Transgenic mice carrying the apolipoprotein E3-Leiden gene exhibit hyperlipoproteinemia. *J Biol Chem* 1993 May 15;268(14):10540-5.
15. Lardenoey JH, Delsing DJ, de Vries MR et al. Accelerated atherosclerosis by placement of a perivascular cuff and a cholesterol-rich diet in ApoE*3Leiden transgenic mice. *Circ Res* 2000 August 4;87(3):248-53.
16. Zou Y, Dietrich H, Hu Y, Metzler B, Wick G, Xu Q. Mouse model of venous bypass graft arteriosclerosis. *Am J Pathol* 1998 October;153(4):1301-10.
17. Park P, Haas M, Cunningham PN et al. Inhibiting the complement system does not reduce injury in renal ischemia reperfusion. *J Am Soc Nephrol* 2001 July;12(7):1383-90.
18. Trouw LA, Seelen MA, Duijs JM et al. Activation of the lectin pathway in murine lupus nephritis. *Mol Immunol* 2005 April;42(6):731-40.
19. Matsuo S, Nishikage H, Yoshida F, Nomura A, Piddlesden SJ, Morgan BP. Role of CD59 in experimental glomerulonephritis in rats. *Kidney Int* 1994 July;46(1):191-200.
20. Libby P, Aikawa M. Stabilization of atherosclerotic plaques: new mechanisms and clinical targets. *Nat Med* 2002 November;8(11):1257-62.
21. Kaul M, Loos M. Expression of membrane C1q in human monocyte-derived macrophages is developmentally regulated and enhanced by interferon-gamma. *FEBS Lett* 2001 June 29;500(1-2):91-8.
22. Chan RK, Ibrahim SI, Verna N, Carroll M, Moore FD, Jr., Hechtman HB. Ischaemia-reperfusion is an event triggered by immune complexes and complement. *Br J Surg* 2003 December;90(12):1470-8.
23. Fitzmaurice M, Ratliff NB. Immunoglobulin deposition in atherosclerotic aortocoronary saphenous vein grafts. *Arch Pathol Lab Med* 1990 April;114(4):388-93.
24. Stahl GL, Xu Y, Hao L et al. Role for the alternative complement pathway in ischemia/reperfusion injury. *Am J Pathol* 2003 February;162(2):449-55.
25. Thurman JM, Ljubanovic D, Edelstein CL, Gilkeson GS, Holers VM. Lack of a functional alternative complement pathway ameliorates ischemic acute renal failure in mice. *J Immunol* 2003 February 1;170(3):1517-23.
26. Torzewski M, Klouche M, Hock J et al. Immunohistochemical demonstration of enzymatically modified human LDL and its colocalization with the terminal complement complex in the early atherosclerotic lesion. *Arterioscler Thromb Vasc Biol* 1998 March;18(3):369-78.
27. Bhakdi S, Dorweiler B, Kirchmann R et al. On the pathogenesis of atherosclerosis: enzymatic transformation of human low density lipoprotein to an atherogenic moiety. *J Exp Med* 1995 December 1;182(6):1959-71.
28. Seifert PS, Hugo F, Tranum-Jensen J, Zahringer U, Muhly M, Bhakdi S. Isolation and characterization of a complement-activating lipid extracted from human atherosclerotic lesions. *J Exp Med* 1990 August 1;172(2):547-57.
29. Nauta AJ, Trouw LA, Daha MR et al. Direct binding of C1q to apoptotic cells and cell blebs induces complement activation. *Eur J Immunol* 2002 June;32(6):1726-36.
30. Tsuji S, Kaji K, Nagasawa S. Activation of the alternative pathway of human complement by apoptotic human umbilical vein endothelial cells. *J Biochem (Tokyo)* 1994 October;116(4):794-800.
31. Xu Q. Mouse models of arteriosclerosis: from arterial injuries to vascular grafts. *Am J Pathol* 2004 July;165(1):1-10.



CHAPTER 8

Blocking of the Chemotactic Complement Endproduct C5a Inhibits Accelerated Atherosclerosis in Vein Grafts.

Abbey Schepers, MD^{1,2}, Margreet R. de Vries, BSc¹, Trent M. Woodruff, PhD³,
Steven M. Taylor, PhD³, Mohamed R. Daha, PhD⁴, J. Hajo van Bockel, MD, PhD²,
Paul H.A. Quax, PhD^{1,2}

¹Gaubius Laboratory, TNO Quality of Life, Leiden, The Netherlands, ²Department
of Surgery, Leiden University Medical Centre, Leiden, The Netherlands, ³Promics
Ltd, School of Biomedical Sciences, University of Queensland, Brisbane, Australia,

⁴Department of Renal Diseases, Leiden University Medical Centre, Leiden, The
Netherlands.

Submitted

ABSTRACT

Objective: Vein graft thickening based on intimal hyperplasia formation and accelerated atherosclerosis is the main cause of vein graft failure. Influx of monocytes is one of the first phenomena seen in this process. C5a is a bioactive end-product of the complement cascade and a chemotactic factor for monocytes. Since evidence to support a definite role of C5a in vein graft remodeling is lacking, we sought to establish the functional involvement of C5a is involved in this process.

Methods and Results: Time-dependent C5 expression was demonstrated by immunohistochemistry in murine vein grafts (consisting of venous interpositions placed in carotid arteries) of hypercholesterolemic ApoE3Leiden mice, whereas mRNA-analysis revealed a up-regulation of C5a receptor (C5aR) mRNA post-surgery.

Functional involvement of C5a in vein graft remodeling was demonstrated by a dose-dependent increase of vein graft thickening upon C5a application. Conversely, blocking the C5aR with C5aR-antagonists inhibited vein graft thickening for 50%, accompanied by decreased numbers of adhering monocytes and reduced foam cell accumulation in the lesions.

Conclusions: These data establishes the important role of the complement cascade in general, and C5a in particular in vein graft thickening. This indicates that C5a-antagonists may be potential therapies in the prevention of vein graft failure in patients.

INTRODUCTION

Saphenous vein grafting remains the treatment of choice to overcome the symptoms of coronary and peripheral atherosclerosis. However, vein graft failure is a frequent outcome resulting in a relapse of symptoms. Late vein graft failure is predominantly caused by the development of intimal hyperplasia (IH) and accelerated atherosclerosis¹. It is believed to be the result of an inflammatory reaction in the vein graft wall, initiated by mechanical damage during surgery, cyclic stretching and increased shear stress in the arterial circulation^{2,3}. One of the first occurring phenomena in this remodeling process is chemotaxis followed by adhesion and migration of inflammatory cells, predominantly monocytes, into the intima of the vein graft⁴. Monocytes produce pro-inflammatory cytokines and growth factors, being potent stimuli for smooth muscle cell migration and foam cell accumulation⁵, eventually resulting in a thickened vessel wall and a reduced luminal diameter. Interfering in chemotactic processes could potentially result in reduced monocyte influx and thereby ultimately in less vein graft thickening.

Recently, our group provided evidence for pivotal involvement of the complement cascade in the abovementioned processes⁶. Activation of the complement cascade leads to cleavage of complement component C3, which upon further activation results in formation of biological active end-products. Inhibition of C3 inhibited vein graft thickening and reduced inflammatory cell content in the thickened vein graft wall. To further clarify the mechanism and to identify the crucial proteins that led to this effect, complement component C5a was further studied in this setting. C5a is one of the biologically active components of the complement cascade and a potent chemotactic protein. C5a exerts its function via the C5a receptors (C5aR) and induces chemotaxis of numerous cell types including monocytes, T- lymphocytes, and granulocytes⁷. It has been shown to be of importance in several inflammatory mediated processes, such as SIRS response after extracorporeal circulation^{8,9}, sepsis¹⁰, bronchial asthma¹¹ and ischemia/reperfusion injury^{12,13}. However, involvement of C5a in vascular inflammatory processes such as atherosclerosis and post-interventional vessel remodeling (e.g. post-angioplasty restenosis and vein graft thickening) is less clearly assessed.

In this study, we hypothesized that C5a plays a pro-inflammatory, pro-stenotic role in vein graft disease. In line with this hypothesis, interference of C5a function should lead to reduced vein graft thickening and decreased numbers of macrophage-derived foam cells in the lesion. This hypothesis was studied in a murine model for vein graft disease. When performed in hypercholesterolemic mice, within 28 days vein graft thickening occurs due to IH formation and accelerated atherosclerosis, thereby highly resembling the changes seen in human diseased vein grafts.

In this mouse model, the presence and expression of C5 and its receptor (C5aR) was assessed. To study the effect of C5a exposure on vein graft thickening, recombinant C5a was applied to the vein graft. Furthermore, C5a function was abrogated by treating mice that underwent vein graft surgery with two potent C5a receptor

antagonists (C5aRA), AcF-[OP-(D-Cha)WR] and HC-[OP-(D-Cha)WR]¹⁴. Previous reports demonstrate that these C5aRA are suitable to inhibit C5a function *in vivo*¹⁵⁻¹⁷. Furthermore, these compounds are highly stable and easy to work with, in contrast to C5a receptor blockage by e.g. monoclonal antibodies.

The results of this study provide clear evidence for the functional role of C5a in the development of vein graft thickening, and point to blockade of C5a as a potential target for therapy, in order to overcome vein graft failure in patients.

METHODS

Mice.

Experiments were approved by the Animal Welfare Committee of the institution. For all experiments 12 week old male C57Bl6-ApoE^{-/-} mice, bred at the TNO laboratory, were used. Mice were fed a standard chow diet and received water and food *ad libitum*. Serum cholesterol levels were determined using a cholesterol-esterase, cholesterol-oxidase reaction (CholR1, Roche Diagnostics, Almere, The Netherlands) at sacrifice. Before surgery, mice were anesthetized by an intra-peritoneal injection with Midazolam (5 mg/kg, Roche, Woerden, The Netherlands), Medetomidine (0.5 mg/kg, Orion, Espoo, Finland) and Fentanyl (0.05 mg/kg, Janssen, Berchem, Belgium).

Vein graft model.

Vein graft surgery was performed as described previously¹⁸. Briefly, caval veins were harvested from (genetically identical) donor mice and before implantation preserved (at 4 degrees Celsius) in 0.9% NaCl containing 100U/ml of heparin. In recipients, the right carotid artery was dissected and cut in the middle. A polyethylene cuff was placed at both ends of the artery. The artery was everted around the cuff and ligated with a silk 8.0 suture. The caval vein was sleeved over the two cuffs, and ligated. Pulsations and turbulent blood flow within the graft confirmed successful engraftment.

At sacrifice, after 5 minutes of *in vivo* perfusion-fixation with 4% Formaldehyde, vein grafts were harvested and fixed overnight in 4% Formaldehyde, dehydrated and paraffin-embedded. Serial perpendicular cross sections (5µm) of the vessel were made through the entire specimen.

Detection of C5 in vein grafts by immunohistochemistry.

Twenty-four mice were sacrificed at several time points after surgery (6h, 24h, 3d, 7d, 14d and 28d after surgery). Vein grafts were harvested and processed as described above. Rat monoclonal antibodies against murine C5 were used to study presence of C5 in vein grafts by immunohistochemistry (1:25 dilution, HyCult Biotechnology, Uden, The Netherlands). Rabbit-anti-rat polyclonal antibodies were used as secondary antibody. Normal caval veins were included to assess baseline C5 expression.

RNA isolation, cDNA synthesis and RT-PCR.

Total RNA was isolated from 16 vein grafts harvested on several time points (24h, 3d; 7d; and 28d after surgery). Also, caval veins of donor mice were included.

RNA was isolated, including DNase treatment, using a RNeasy Fibrous Tissue Mini Kit and RNase Free DNase set according to the manufacturer's protocols (Qiagen, Venlo, the Netherlands). RNA (250 ng) was reverse-transcribed using Ready-To-Go You-Prime First-Strand Beads (Amersham Biosciences, Roosendaal, The Netherlands).

Semi-quantitative RT-PCR (Robocycler Gradient 96, Stratagene, Cedar Creek, Texas, USA) was performed with primers for C5a receptor (Fw: gaccatagataacagca Rev: cagaggcaacacaaacca¹⁹) and β -Actin (Perker-Elmar, Überlingen, Germany). Samples were amplified for 35 cycles following an initial cycle for 2 min. at 94°C (each cycle consisted of 30sec. at 94°C, 30sec at 56°C and 90sec. at 65°C), followed by an extension-cycle of 4 min. at 74°C. PCR products were visualized on a 1.2% Agarose gel containing EthidiumBromide.

Applying recombinant C5a in pluronic gel to vein grafts.

Twenty-one mice were randomly divided in three groups. In the treatment groups, either 0.5 μ g or 5 μ g of recombinant mouse C5a (E. Coli derived, HyCult Biotechnology) was dissolved in 0.1 ml of 20% Pluronic Gel (PG) and applied around the vein grafts at time of surgery. In the control group 0.1ml of 20% PG was applied without protein. Mice were sacrificed after 28 days.

Blocking C5aR by ACF-[OP-(D-CHA)WR] and HC-[OP-(D-CHA)WR] treatment.

In order to inhibit C5a function, 21 mice were randomly divided in three groups and were either treated with AcF-[OP-(D-Cha)WR] (AcF) and hydrocinnamate-[OP-(D-Cha)WR] (HC). Both compounds display potent antagonizing activity for the C5a receptor and were synthesized as described previously²⁰. AcF was administered subcutaneously in a daily dose of 3mg/kg in 0.1ml 30% propylene glycol and 70% sterile water, starting one day prior to surgery. Since HC displays an increased *in vivo* potency over AcF, in a dose-dependent function, as recently described by Woodruff et al²¹, it was administered in 2 dosages, 3 mg/kg/day and 0.3mg/kg/day, both in 0.1ml 30% propylene glycol and 70% sterile water. A control group (n=7) received daily injections of 0.1ml 30% propylene glycol and 70% sterile water.

All mice were sacrificed 28 days after surgery.

Quantification and histological assessment of intimal hyperplasia.

Cross sections of vein grafts were routinely stained with hematoxylin-phloxine-saffron (HPS). Morphometric analysis of vein grafts harvested after 28d was performed using image analysis software (Qwin, Leica, Wetzlar, Germany). Since only few layers of cells are in the media of murine veins and there is no morphological border between neointima and media, vein graft thickening, i.e. the region between lumen and

adventitia, was used to define lesion area. For each mouse five equally spaced cross-sections were used to determine vessel wall thickening.

Different subsets of leukocytes were specified. The amount of macrophage derived foam cells within the thickened vessel wall was visualized by AIA31240 antibody (Accurate Chemical, Westbury, NY, USA). Granulocytes were detected using anti-mouse neutrophils antibodies (MCA 771GA, Serotec, Raleigh, USA).

Quantification of granulocytes occurred by counting the positive number of cells/slide and expressed as a percentage of total number of nuclei (determined by Nucleus Red staining). Foam cell quantification was performed by computer assisted analysis (Qwin, Leica) as AIA31240-positive area in the graft and expressed as a percentage of total vein graft surface.

Statistical analysis.

All data are presented as mean \pm SEM. Statistical analysis was performed using SPSS 11.5 for Windows. To determine statistical significance overall comparisons were made using the one-way ANOVA. In case of significance, each group was separately compared to the control group using the student T test. Probability-values < 0.05 were regarded significant.

RESULTS

Presence of C5 protein in remodeling vein grafts.

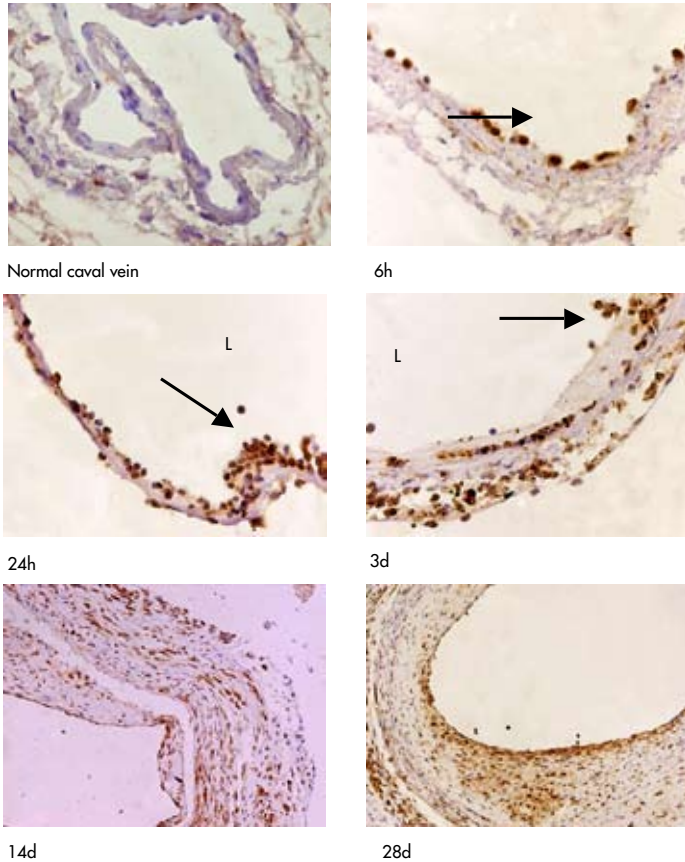
Presence of C5 in remodeling vein graft was assessed in vein grafts (n=4 per time point), harvested at several time points after surgery (6h, 24h, 3d, 7d, 14d and 28d) by immunohistochemistry.

In normal caval veins no baseline expression of C5 could be detected. Interestingly, in vein grafts harvested 6 hours and one day after surgery, strong staining of C5 was detected in adhering monocytes and in adventitial fibroblasts. C5 was also detected in the regenerating endothelium as from 7 days after surgery. At this stage, staining appeared most pronounced and diffusely present, indicating high amounts of C5 in the vessel wall. At the later time points (14 and 28 days post-operatively), along with thickening of the graft, expression of C5 was seen in endothelial cells, adhering monocytes, adventitial fibroblasts and foam cells (Figure 8.1).

Expression of C5a receptor mRNA in remodeling vein grafts.

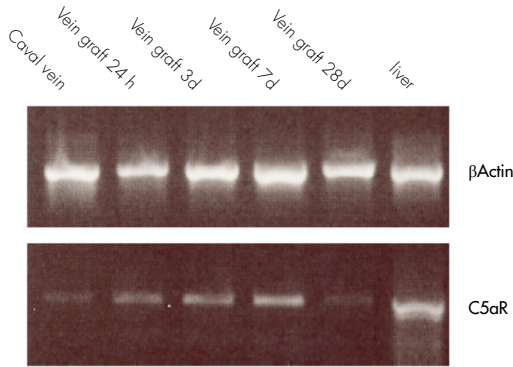
To assess whether mRNA of the C5a-receptor was present in vein grafts, total RNA was isolated and studied for presence of C5aR mRNA by RT-PCR. Vein grafts were harvested on several time points (24h, 3d, 7d and 28d, n=4 per time point) and normal caval veins served as controls. Amount of total cDNA in all specimens was studied by the housekeeping gene β -Actin.

Figure 8.1: Detection of C5 in time in venous bypass grafts by immunohistochemistry. As soon as 6 hours after surgery, presence of C5 is seen in adhering leucocytes (appointed by arrows). Highest amounts of C5 are seen 3 to 7 days after surgery, and C5 remains present in later time-points predominantly in endothelial cells, foam cells and adventitial fibroblasts (magnification 150x (28d)-400x (6h)).



Caval veins revealed minimal expression of C5aR. In vein grafts, C5aR mRNA expression gradually increased in a time-dependent fashion. Peak expression of C5aR was seen at 7 days after surgery, after which expression declined to levels seen in normal caval veins (Figure 8.2). These data confirm that the C5aR is present in vein grafts and up-regulated in the early stages vein graft remodeling.

Figure 8.2: Expression of C5a receptor mRNA by semi-quantitative RT-PCR, compared with basic expression in caval veins. Very small amounts of C5aR mRNA are present in caval veins. After surgery, an up-regulation of C5aR mRNA is seen with peak expression 7 days after surgery, after which the expression normalizes again.

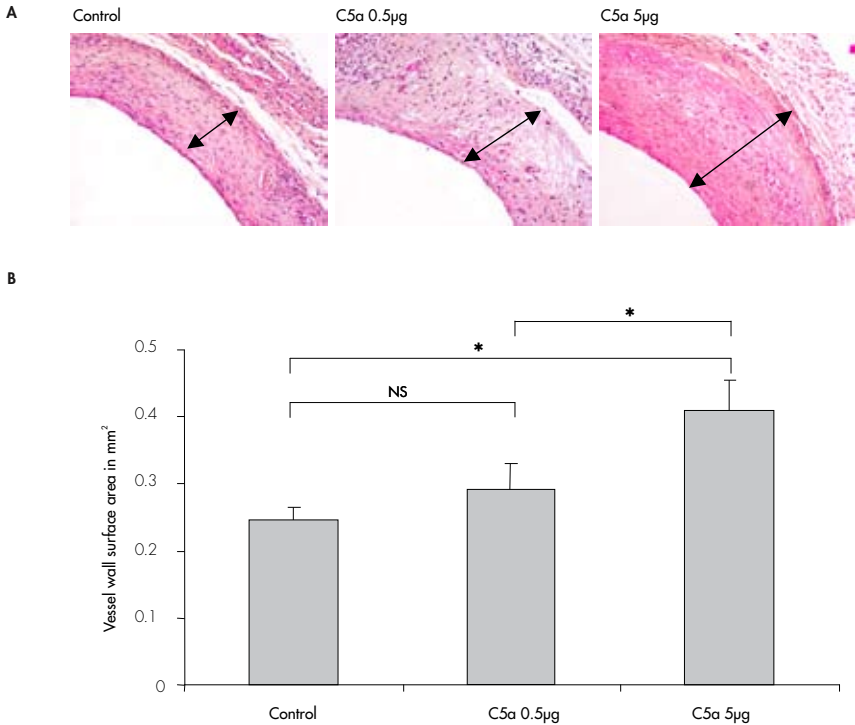


Effect of application of recombinant C5a on vein graft thickening.

To study involvement of C5a in development of vein graft thickening, we applied recombinant C5a in two concentrations (0.5µg and 5µg, dissolved in 100 µl 20% PG, n=7 per group, dose based on previous reports in literature²²) directly to the vein graft at time of surgery. Pluronic gel was used as a vehicle to achieve a local, sustained delivery of C5a. In controls 100µl of 20% PG without C5a was applied. Serum cholesterol did not differ between groups and did not change during the experiment (data not shown).

Vein graft thickening, by measuring vessel wall surface, was quantified 28 days after surgery. Topical application of C5a resulted in a dose dependent increase of vessel wall surface, when compared to control vein grafts (control 0.24±0.02 mm², 0.5µg C5a: 0.29±0.03 mm², p=0.14, 5µg C5a: 0.41±0.04 mm², p=0.002 when compared to controls, p=0.037 when compared to 0.5µg C5a-treated group) (Figure 8.3A+B). No significant differences in luminal area were seen between the three different groups (control 0.64±0.06 mm², 0.5µg C5a: 0.60±0.05 mm², p=0.3, 5µg C5a: 0.58±0.06 mm², p=0.25 when compared to controls, p=0.39 when compared to 0.5µg C5a-treated group).

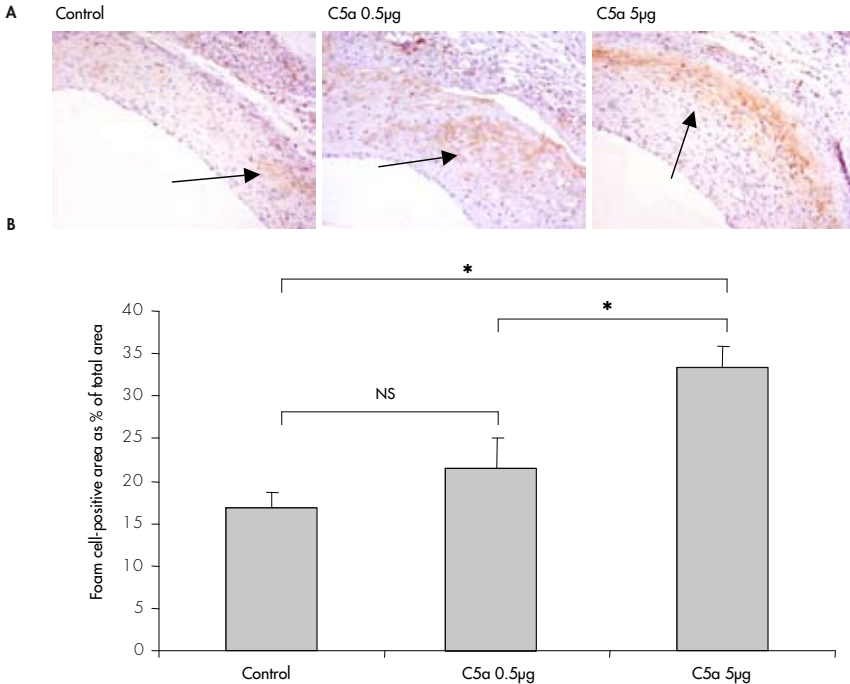
Figure 8.3: Effect of C5a recombinant protein application to vein grafts of hypercholesterolemic mice. Representative cross-sections of vein grafts exposed to either 20% PG and 20% PG containing 0.5 μ and 5 μ g C5a recombinant protein (panel A, HPS staining). A dose-dependent increase in vein graft thickening was seen in the C5a-treated mice (panel B) (0.5 μ g: $p=0.1$, 5 μ g: $p=0.002$; arrows indicate vessel wall surface, magnification 200 \times).



Effect of application of recombinant C5a on cellular composition of vein grafts.

Since C5a is a potent chemotactic factor for monocytes/macrophages, numbers of macrophages and macrophage-derived foam cells in thickened vein grafts, harvested 28 days after surgery, were studied. A dose-dependent increase in macrophages contribution in thickened vein grafts was seen in C5a treated vein grafts (Figure 8.4A+B). In controls, approximately 17% ($\pm 2\%$) of the thickened vessel wall surface consisted of macrophages and macrophage-derived foam cells. When 0.5 μ g C5a was applied, this percentage increased to 22% $\pm 3\%$ ($p=0.11$). Application of 5 μ g C5a to the grafts significantly increased macrophage/foam cell content of 33 $\pm 2\%$ ($p<0.001$ when compared to control grafts; $p=0.008$ when compared to grafts treated with 0.5 μ g C5a).

Figure 8.4: *Effect of C5a application to vein grafts on foam cell contribution in lesion. Increased exposure to C5a results in a significant increase in foam cell contribution in the lesions (panel B). Panel A displays representative cross sections of immunohistochemistry using antibodies against macrophage derived foam cells, whereas arrows indicate positive staining against monocytes/foam cell (0.5µg: p=0.1, 5µg: p<0.001; magnification 200x).*



Granulocytes contributed to a much lesser extent to the vessel wall surface of thickened vein grafts (quantified 28 days after surgery) and application of C5a did not appear to have a significant effect on presence of granulocytes (control $1.3 \pm 0.35\%$, $0.5\mu\text{g}$ C5a: $1.54 \pm 0.43\%$, $p=0.31$, $5\mu\text{g}$ C5a: $1.14 \pm 0.48\%$, $p=0.29$ when compared to controls, $p=0.16$ when compared to $0.5\mu\text{g}$ C5a-treated group).

Effect of C5a receptor antagonists (C5aRA) treatment on vein graft thickening and foam cell contribution.

Twenty-eight mice received either AcF in 30% propylene glycol (3mg/kg/day subcutaneously (s.c.), $n=7$) or HC in 30% propylene glycol (3 and 0.3 mg/kg/day/s.c. , $n=7$ each), or daily injections of 30% propylene glycol s.c. ($n=7$). No differences were observed in bodyweight or serum cholesterol between the different treatment groups (data not shown).

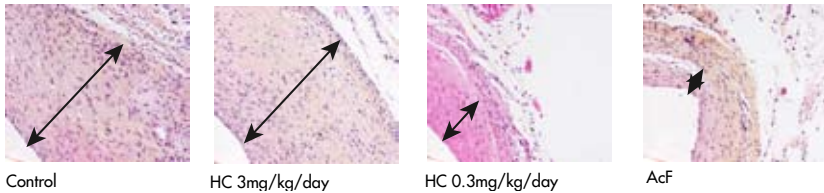
When mice were sacrificed after 28 days, analysis of the thickened vein graft revealed that treatment with AcF resulted in a 53% decrease in vessel wall surface, when

compared to control mice (AcF: $0.19 \pm 0.03 \text{ mm}^2$, control: $0.39 \pm 0.06 \text{ mm}^2$, $p=0.046$), whereas treatment with similar doses HC did not result in decreased vessel wall surface ($0.33 \pm 0.03 \text{ mm}^2$, $p=0.23$). However, treatment with a 10-fold lower dose of 0.3 mg/kg HC did lead to significantly reduced vessel wall surface when compared to control animals ($0.23 \pm 0.03 \text{ mm}^2$, $p=0.035$) (Figure 8.5A+B).

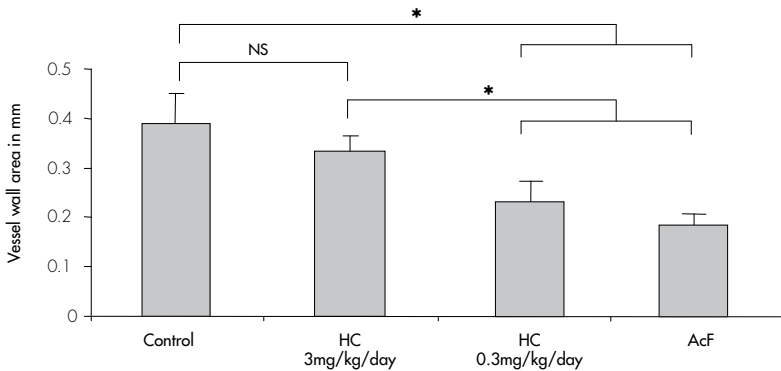
Figure 8.5: Effect of treatment with C5a receptor antagonists, HC and AcF.

Panel A: Representative cross sections of control and treated vein grafts 28 days after surgery; a decrease in vein graft thickening is seen in the AcF and HC 0.3mg/kg/day treated groups (HPS staining, magnification 200x).

A

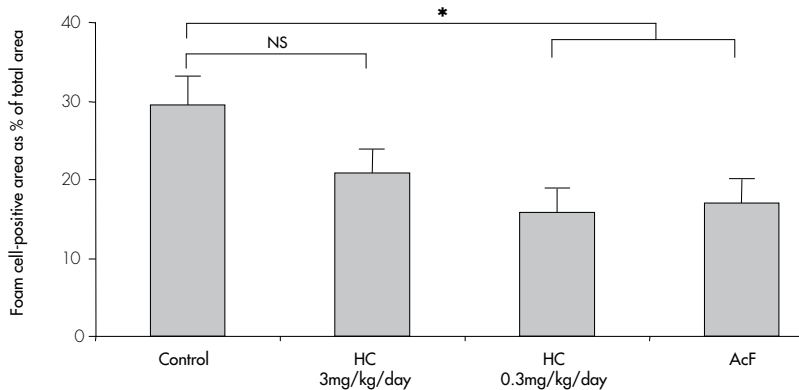


Panel B: Quantification of vessel wall surface in mm^2 control and treated vein grafts 28 days after surgery ($n=7$ per group, *represents $p<0.05$); C5aRA treatment results in decrease in vein graft thickening 28 days after surgery.



Panel C: Quantification of macrophages-derived foam cells contribution in the vessel wall by immunohistochemistry, described as percentage of total vessel wall surface; treatment with C5aRA results in a decrease in foam cell content in the vessel wall (n=7 per group, *represents p<0.05).

C



Regarding luminal size, no differences were seen between the control group, AcF and HC 3mg/kg, whereas treatment with HC 0.3mg/kg resulted in a significantly increased luminal area (control: $0.42 \pm 0.04 \text{mm}^2$; AcF: $0.41 \pm 0.08 \text{mm}^2$, $p=0.48$; HC 3mg/kg: $0.48 \pm 0.03 \text{mm}^2$, $p=0.15$; HC 0.3mg/kg: $0.61 \pm 0.04 \text{mm}^2$, $p=0.005$).

The thickened vessel wall of control, untreated vein grafts, analyzed 28 days after surgery, consisted approximately 30% ($\pm 4\%$) of foam cells. In AcF-treated vein grafts, a significant reduction of this foam cell contribution was seen ($17 \pm 3\%$, $p=0.01$ when compared to controls). No significant reduction was seen in the HC 3mg/kg/day treated group ($22 \pm 3\%$ of foam cells in lesion, $p=0.07$ when compared to controls), whereas administration of HC 0.3 mg/kg/day, resulted in a significantly lowered contribution of foam cells (16 ± 3 , $p=0.01$) (Figure 8.5C).

DISCUSSION

The role of the complement system in vascular remodeling has not been studied in detail yet, regardless of its crucial role in the immune system and inflammatory processes. Recently, we demonstrated that complement activation is one of the crucial phenomena in vein graft disease⁶. Of all end-products of the complement cascade, C5a is one of the most important downstream proteins, exerting chemotactic properties for various inflammatory cells including monocytes, granulocytes and T-cells. It has been shown to modulate pro-inflammatory effects in several diseases (reviewed in⁷), and since chemotaxis of inflammatory cells is one of the first phenomena seen in bypass graft remodeling, it is highly interesting to study the role

of C5a in the context of vein graft remodeling. This report further specifies this role and demonstrates the involvement of C5a in the process of vein graft thickening.

The presence of C5 protein in vein grafts was shown by immunohistochemistry at several time points after surgery. In normal caval veins no C5 could be detected but a strong induction of expression occurred directly after surgery. C5 was predominantly expressed in adhering monocytes, adventitial fibroblasts, endothelial cells and foam cells and staining appeared to be most intense 7 days after surgery. We detected all forms of C5, including C5 and C5a, since the antibody used can not discriminate between these forms. In addition, expression of mRNA encoding for the C5a receptor was followed in time by RT-PCR. At baseline, in normal caval veins, very low levels of C5aR mRNA were detected. A fast up-regulation was seen in the first days after engraftment. Peak-expression occurred 7 days after surgery, coinciding with the highest levels of C5 staining seen with immunohistochemistry, after which expression declined to baseline levels.

In order to study functional involvement of C5a in vein graft thickening, the effect of increased exposure to C5a was studied by applying murine recombinant C5a protein to vein grafts, hypothesizing that increased exposure to C5a would result in increased vein graft thickening. Indeed, increased exposure to C5a dose-dependently aggravated vein graft thickening, and additionally also resulted in dose-dependently increased macrophage-derived foam cell content in the thickened vessel wall. Surprisingly, no significant effect on granulocyte content in the lesion could be observed after increased topical exposure to recombinant C5a. This might be explained by the relatively limited contribution of granulocytes in the thickened vessel wall 28 days after surgery, even in the control group.

When C5a function was blocked, using two potent C5aR antagonists (C5aRA), AcF and HC, the opposite effect was seen. Hampering C5aR function inhibited vein graft thickening and reduced contribution of foam cells in the lesion.

In this study we found a dose-dependent effect of HC. When administered in the highest dose of 3 mg/kg/day, treatment did not inhibit vein graft thickening in our model. This is in line with a recently published article of Woodruff et al²¹. Authors hypothesized that a lack of therapeutic effect, when HC was administered in high dosages, might be due to deleterious effects at unidentified receptors, to local toxicity or other factors not yet recognized. Similar results were found in the present study. The results of the present study, using both C5a overexpression as well as two separate C5a receptor antagonists, clearly indicate a role for the C5a in the pathogenesis of vein graft remodeling in the mouse. Regarding the role of C5a in other forms of inflammation related vascular remodeling, little is known.

Interestingly, because of the well known complement activation in extracorporeal circulation^{9,23}, several reports discuss the role of C5a in patients undergoing cardiac surgery, especially coronary bypass grafts (CABG)^{8,24}. However, all clinical studies focus on early mortality and adverse cardiovascular outcomes, instead of intimal

hyperplasia formation and accelerated atherosclerosis of the bypass. It might be of interest to follow these study populations with special regards to graft failure.

Several studies that argue for a role of C5a in spontaneous atherosclerosis have been published. However, these studies report inconclusive results. Yasojima and colleagues showed for the first time both C5 mRNA and protein present in normal arteries²⁵. Moreover, an impressive increase of mRNA and protein was shown in atherosclerotic arteries. In addition, Patel and colleagues reported that ApoE/C5 double knock-out mice develop spontaneous atherosclerosis to a similar extent as their ApoE-/- littermates²⁶. However, C5 knock-out mice are not suitable to solely study the role of C5a, since with C5 depletion, the formation of C5b-9 is also hampered. Speidl and colleagues reported that increased serum levels of C5a in patients with advanced atherosclerosis was associated with increased cardiovascular risk (as determined by the occurrence of major adverse cardiovascular events)²⁷, indicating that C5a might be a valuable marker for risk-assessment in patients.


Reports that describe the role of C5a in another form of vascular remodeling, namely post-angioplasty restenosis, are scarce. Recently, in line with their data on spontaneous atherosclerosis, Speidl and colleagues described the positive correlation between increasing C5a levels after PTA of the femoral artery with the development of restenosis during follow up. However, further research remains necessary to define the exact role of C5a in the broad perspective of vascular remodeling.

In conclusion, this report provides compelling evidence for involvement of the complement fragment C5a in vein graft thickening. Inhibition of complement activation in general, and specifically C5a, might be a valuable new approach in order to overcome the problems of graft failure in patients. In this point of view, the potent anti-restenotic effects of C5aR antagonists, such as HC-[OP-(D-Cha)WR] and AcF-[OP-(D-Cha)WR], make them attractive as potential candidates for human therapy.

REFERENCES

1. Davies MG, Hagen PO. Pathophysiology of vein graft failure: a review. *Eur J Vasc Endovasc Surg* 1995;9:7-18.
2. Gibbons GH. The pathogenesis of graft vascular disease: implications of vascular remodeling. *J Heart Lung Transplant* 1995;14:S149-S158.
3. Meng X, Mavromatis K, Galis ZS. Mechanical stretching of human saphenous vein grafts induces expression and activation of matrix-degrading enzymes associated with vascular tissue injury and repair. *Exp Mol Pathol* 1999;66:227-237.
4. Stark VK, Hoch JR, Warner TF, Hullett DA. Monocyte chemoattractant protein-1 expression is associated with the development of vein graft intimal hyperplasia. *Arterioscler Thromb Vasc Biol* 1997;17:1614-1621.
5. Fujiyama S, Amano K, Uehira K, Yoshida M, Nishiwaki Y, Nozawa Y, Jin D, Takai S, Miyazaki M, Egashira K, Imada T, Iwasaka T, Matsubara H. Bone marrow monocyte lineage cells adhere on injured endothelium in a monocyte chemoattractant protein-1-dependent manner and accelerate reendothelialization as endothelial progenitor cells. *Circ Res* 2003;93:980-989.
6. Schepers A, de Vries MR, van Leuven CJ, Grimbergen JM, Holers VM, Daha MR, van Bockel JH, Quax PH. Inhibition of complement component C3 reduces vein graft atherosclerosis in apolipoprotein E3-Leiden transgenic mice. *Circulation* 2006;114:2831-2838.
7. Guo RF, Ward PA. Role of C5a in inflammatory responses. *Annu Rev Immunol* 2005;23:821-852.

8. Fitch JC, Rollins S, Matis L, Alford B, Aranki S, Collard CD, Dewar M, Elefteriades J, Hines R, Kopf G, Kraker P, Li L, O'Hara R, Rinder C, Rinder H, Shaw R, Smith B, Stahl G, Shernan SK. Pharmacology and biological efficacy of a recombinant, humanized, single-chain antibody C5 complement inhibitor in patients undergoing coronary artery bypass graft surgery with cardiopulmonary bypass. *Circulation* 1999;100:2499-2506.
9. Rinder CS, Rinder HM, Smith BR, Fitch JC, Smith MJ, Tracey JB, Matis LA, Squinto SP, Rollins SA. Blockade of C5a and C5b-9 generation inhibits leukocyte and platelet activation during extracorporeal circulation. *J Clin Invest* 1995;96:1564-1572.
10. Guo RF, Riedemann NC, Ward PA. Role of C5a-C5aR interaction in sepsis. *Shock* 2004;21:1-7.
11. Hasegawa K, Tamari M, Shao C, Shimizu M, Takahashi N, Mao XQ, Yamasaki A, Kamada F, Doi S, Fujiwara H, Miyatake A, Fujita K, Tamura G, Matsubara Y, Shirakawa T, Suzuki Y. Variations in the C3, C3a receptor, and C5 genes affect susceptibility to bronchial asthma. *Hum Genet* 2004;115:295-301.
12. Arumugam TV, Shiels IA, Woodruff TM, Reid RC, Fairlie DP, Taylor SM. Protective effect of a new C5a receptor antagonist against ischemia-reperfusion injury in the rat small intestine. *J Surg Res* 2002;103:260-267.
13. Arumugam TV, Shiels IA, Strachan AJ, Abbenante G, Fairlie DP, Taylor SM. A small molecule C5a receptor antagonist protects kidneys from ischemia/reperfusion injury in rats. *Kidney Int* 2003;63:134-142.
14. Finch AM, Wong AK, Paczkowski NJ, Wadi SK, Craik DJ, Fairlie DP, Taylor SM. Low-molecular-weight peptidic and cyclic antagonists of the receptor for the complement factor C5a. *J Med Chem* 1999;42:1965-1974.
15. Haynes DR, Harkin DG, Bignold LP, Hutchens MJ, Taylor SM, Fairlie DP. Inhibition of C5a-induced neutrophil chemotaxis and macrophage cytokine production in vitro by a new C5a receptor antagonist. *Biochem Pharmacol* 2000;60:729-733.
16. Woodruff TM, Arumugam TV, Shiels IA, Reid RC, Fairlie DP, Taylor SM. Protective effects of a potent C5a receptor antagonist on experimental acute limb ischemia-reperfusion in rats. *J Surg Res* 2004;116:81-90.
17. Woodruff TM, Arumugam TV, Shiels IA, Reid RC, Fairlie DP, Taylor SM. A potent human C5a receptor antagonist protects against disease pathology in a rat model of inflammatory bowel disease. *J Immunol* 2003;171:5514-5520.
18. Zou Y, Dietrich H, Hu Y, Metzler B, Wick G, Xu Q. Mouse model of venous bypass graft arteriosclerosis. *Am J Pathol* 1998;153:1301-1310.
19. Van Beek J, Bernaudin M, Petit E, Gasque P, Nouvelot A, MacKenzie ET, Fontaine M. Expression of receptors for complement anaphylatoxins C3a and C5a following permanent focal cerebral ischemia in the mouse. *Exp Neurol* 2000;161:373-382.
20. March DR, Proctor LM, Stoermer MJ, Sbaglia R, Abbenante G, Reid RC, Woodruff TM, Wadi K, Paczkowski N, Tyndall JD, Taylor SM, Fairlie DP. Potent cyclic antagonists of the complement C5a receptor on human polymorphonuclear leukocytes. Relationships between structures and activity. *Mol Pharmacol* 2004;65:868-879.
21. Woodruff TM, Pollitt S, Proctor LM, Stocks SZ, Manthey HD, Williams HM, Mahadevan IB, Shiels IA, Taylor SM. Increased potency of a novel C5a receptor antagonist in a rat model of inflammatory bowel disease. *J Pharmacol Exp Ther* 2005.
22. Bouma G, Nikolic T, Coppens JM, Helden-Meeuwse CG, Leenen PJ, Drexhage HA, Sozzani S, Versnel MA. NOD mice have a severely impaired ability to recruit leukocytes into sites of inflammation. *Eur J Immunol* 2005;35:225-235.
23. Chenoweth DE, Cooper SW, Hugli TE, Stewart RW, Blackstone EH, Kirklin JW. Complement activation during cardiopulmonary bypass: evidence for generation of C3a and C5a anaphylatoxins. *N Engl J Med* 1981;304:497-503.
24. Shernan SK, Fitch JC, Nussmeier NA, Chen JC, Rollins SA, Mojcik CF, Malloy KJ, Todaro TG, Filloon T, Boyce SW, Gangahar DM, Goldberg M, Saidman LJ, Mangano DT. Impact of pexelizumab, an anti-C5 complement antibody, on total mortality and adverse cardiovascular outcomes in cardiac surgical patients undergoing cardiopulmonary bypass. *Ann Thorac Surg* 2004;77:942-949.
25. Yasojima K, Schwab C, McGeer EG, McGeer PL. Generation of C-reactive protein and complement components in atherosclerotic plaques. *Am J Pathol* 2001;158:1039-1051.
26. Patel S, Thelander EM, Hernandez M, Montenegro J, Hassing H, Burton C, Mundt S, Hermanowski-Vosatka A, Wright SD, Chao YS, Detmers PA. ApoE(-/-) mice develop atherosclerosis in the absence of complement component C5. *Biochem Biophys Res Commun* 2001;286:164-170.
27. Speidl WS, Exner M, Amighi J, Kastl SP, Zorn G, Maurer G, Wagner O, Huber K, Minar E, Wojta J, Schillinger M. Complement component C5a predicts future cardiovascular events in patients with advanced atherosclerosis. *Eur Heart J* 2005.



CHAPTER 9

Discussion

SUMMARY

The aim of this thesis was to gain more insight in the involvement of inflammatory processes in vessel wall remodeling seen after PTA or bypass surgery and put these processes in the perspective of restenosis, vein graft failure and potential therapeutic preventive strategies. Therefore, we firstly focused on inflammation in general, using the anti-inflammatory agent Dexamethasone, assessing the effects of such a broad approach on restenosis and vein graft remodeling. Then, we further focused on some specific parts of the immune system, namely Interleukin 10 (IL10), chemokines and the complement cascade. IL10 was chosen because it is one of the most studied anti-inflammatory cytokines and this property makes it a potential candidate for ant-restenosis therapy. Furthermore, it was hypothesized that chemokines are involved in vascular remodeling, since they are generally known for their regulatory properties regarding influx of inflammatory cells to tissues and this is one of the first phenomena seen in vascular remodeling.

The complement cascade was studied in this context since it contains pro-inflammatory activity and some end-products of the cascade, like chemokines, are potent chemotactic agents.

Several preclinical and clinical studies have assessed the anti-restenotic properties of the glucocorticoid Dexamethasone, showing inconsistent outcomes. Recently, several studies have been performed with Dexamethasone-eluting stents. However, none of them focused on the (possible adverse) pathophysiologic changes in the vessel wall. In **Chapter 2**, the anti-restenotic properties of Dexamethasone were assessed, and more importantly the pathophysiologic effects of local application of Dexamethasone to the vessel wall were studied in a mouse model of cuff-induced stenotic remodeling. Both systemic and local treatment with Dexamethasone resulted in reduction of intimal hyperplasia in the cuffed vessel segment, indicating an inflammatory component in vascular remodeling regulation. However, systemic treatment with Dexamethasone was accompanied by serious side-effects (mice showed reduced daily activity, gained less weight, reduced fur quality). Local delivery of Dexamethasone to the cuffed vessel segment in the mouse, prevented these side-effects, but was associated loss of vascular integrity, particularly at high concentrations of Dexamethasone, as was revealed by medial atrophy, reduced SMC and collagen content, increased apoptosis and internal elastic lamina fracture in the treated vessel segments. The results of this study indicate that although local Dexamethasone delivery, for instance via Dexamethasone-eluting stents, has the potential to inhibit restenosis, the toxic-therapeutic window is relatively narrow and loss of vascular integrity is already detected at relatively low doses of Dexamethasone. This loss of vascular integrity may reflect potential “weak spots” in the vessel wall, hypothetically vulnerable for thrombus- or aneurysm formation. For daily practice, caution should be taken when using overlapping stents. Studies that study this phenomenon of loss of vascular integrity after drug-eluting stent placement should be performed with other anti-restenotic drugs that might influence vessel wall composition.

The role of inflammation in regulation of vascular remodeling is clarified in more detail in **Chapter 3**. **Chapter 3** deals with the effects of the cytokine Il10 on post-angioplasty restenosis. Generally, Il10 displays anti-inflammatory activity and therefore might be an interesting target in the search towards anti-restenotic therapy, in which for example over-expression of the Il10 protein might reduce post-angioplasty restenosis. Effect of Il10 on cuff-induced vascular remodeling was studied in two models. In the first the effect of absence of Il10 on cuff-induced restenosis was studied in ApoE3Leiden-Il10 knock-out mice. Then, over-expression of Il10 was achieved using an electroporation-mediated gene transfer in the calf muscle of ApoE3Leiden mice and effects on restenosis were studied similar as in the knock-out experiment. These approaches both show that IL10 indeed is significantly involved in the regulation of neointima formation and accelerated atherosclerosis and has anti-restenotic potential: absence of Il10 aggravated intimal hyperplasia, whereas in contrast over-expression of Il10 inhibited intimal hyperplasia formation. The pathophysiologic mechanism of this effect is presumably due to induction of a more Th2-like response as was suggested by mRNA expression of various Th2-related cytokines in the spleen; several pro-inflammatory cytokines were down regulated in response to Il-10 over-expression. Furthermore, over-expression of Il10 resulted in reduced serum cholesterol levels in hypercholesterolemic ApoE3Leiden mice, a phenomenon that also might partially contribute to inhibition of intimal hyperplasia.

Both **Chapter 2** and **Chapter 3** further underscore the role of inflammation in post-angioplasty restenosis and discuss some potential therapeutic options and safety considerations, in order to prevent restenosis in patients that underwent PTA of a stenotic vessel. Using the glucocorticoid Dexamethasone, as a general inhibitor of inflammation to prevent vascular remodeling, at a first glance is a promising, but definitely has adverse effects, which indicates that refinement in Dexamethasone treatment is required. Il10-overexpression on the other hand seems to be a potentially suitable anti-restenotic strategy.

In the remaining part of the thesis, the role of inflammation in vein graft remodeling was studied. As in **Chapter 2**, we started with a general approach, a proof of principle of the hypothesis that inflammatory processes are involved in vein graft remodeling, using Dexamethasone as a potent and broadly active anti-inflammatory agent.

In **Chapter 4** ApoE3Leiden mice that underwent vein graft surgery were treated with 28 days of orally administered Dexamethasone treatment and the effect in vein graft thickening was assessed 28 days after surgery. Treatment resulted in reduced vein graft thickening, however the 28 days treatment was accompanied by severe side-effects related to prolonged use of corticosteroids. As an alternative, a short term treatment with Dexamethasone for 7 days was evaluated. Short term treatment did not lead to any side-effects, but led to a similar reduction of vein graft thickening as the 28 days treatment. mRNA analysis of vein grafts harvested on different time-points after engraftment revealed that treatment with Dexamethasone resulted in reduced expression of various pro-inflammatory cytokines in the vein graft wall,

already as fast as 24 hours after engraftment. For testing the applicability in human, we used human saphenous vein organ culture, in which neointima formation is mimicked. When Dexamethasone was applied to human saphenous veins in culture, either 7 or 28 days, the same results as in mice were observed, namely a similar reduction in neointima formation unrelated to the duration of exposure to Dexamethasone. This indicates that these effects of short term treatment are not mouse-specific. Extrapolating this to clinical practice, where long term treatment of patients with Dexamethasone is not acceptable, it seems that Dexamethasone can be used for a limited period of time in order to prevent vein graft thickening. In that way, serious side effects of prolonged Dexamethasone-treatment can be avoided whereas the anti-restenotic properties, most likely by reducing the inflammatory response directly after surgery, might be already present.

More generally, these data suggest that inhibiting inflammatory pathways in the very early phases of vein graft remodeling might result in reduced vein graft thickening on the long run.

Having established the hypothesis that indeed inflammatory processes play a role in vein graft remodeling, some specific parts of the inflammatory reaction were further studied, namely the role of chemokines (**Chapter 5 and 6**) and of the complement cascade (**Chapter 7 and 8**).

CC-chemokines are a group of pro-inflammatory cytokines, which have been shown to be involved in various inflammatory processes. They display chemo-attractant properties to a variety of (inflammatory) cell types and therefore it was hypothesized that they might well be involved in vein graft remodeling, as one of the first phenomena seen in remodeling grafts is influx of inflammatory cells.

MCP-1 is the most potent and most frequently studied chemokine in the CC-family. It has been shown to be a major participant in various remodeling processes such as spontaneous atherosclerosis, post-angioplasty restenosis and transplant accelerated atherosclerosis. In **Chapter 5** the role of MCP-1 in vein graft disease is studied. In this chapter its role in vein graft thickening was assessed in ApoE3Leiden mice, using both the murine vein graft model and in human saphenous veins organ cultures. MCP-1 was shown to be both present in the vein graft as well as in the human saphenous vein, in various stages of the remodeling process. A significant reduction of vein graft thickening was seen after inhibition of MCP-1 activity by electroporation mediated over-expression of a dominant receptor antagonist, 7ND-MCP-1. Similar findings were seen in human saphenous vein organ culture, wherein neointima formation was significantly reduced in the presence of 7ND-MCP-1 protein in the culture medium. Furthermore, in addition to its known effects on macrophage influx and subsequent macrophages presence in the vascular lesion, also a direct inhibitory effect of 7ND-MCP-1 on smooth muscle cell proliferation was demonstrated, as assessed by proliferation assays on cultured smooth muscle cells.

From these data we conclude that MCP-1 is an important mediator in vein graft remodeling and it might be a potential target for anti-restenosis therapy in vein grafts.

Other CC-chemokines are less extensively studied in the field of vascular remodeling as a whole. MIP-1 α and RANTES also belong to the CC-chemokine family and have chemoattractant properties for macrophages, T-cells and (to a lesser extent) granulocytes, and share receptors (predominantly CCR1, CCR3 and CCR5, whereas MCP-1 binds to CCR2). Therefore they were studied together in **Chapter 6**.

A possible causal involvement of the MIP-1 α / RANTES-CCR1/CCR5 pathway in vein graft thickening was studied in the murine vein graft model using hypercholesteremic ApoE3Leiden mice. Alike MCP-1, MIP-1 α and RANTES expression could be detected in the vein graft wall, shortly after engraftment, whereas they were absent in normal caval veins and time-dependent upregulation of MIP-1 α and RANTES mRNA and their receptors was observed after surgery. When mice were treated with the CCR1/CCR5 antagonist Met-RANTES, inhibition of adherence of monocytes was seen three days after surgery. Furthermore, a profound inhibition of vein graft thickening occurred after treatment with Met-RANTES after 28 days, coinciding with reduced numbers of foam cells in the lesion. These data indicate that not only MCP-1, but also other CC-chemokines are involved in vein graft remodeling, and therefore blocking function of these chemokines by (receptor) antagonists in the direct post-operative phase might be a rational, and possibly additional, approach to prevent vein graft disease.

Another part of the innate immune system is the complement cascade. Complement, being a group of proteins, membrane-bound receptors and regulatory enzymes, regulates inflammation by several different biological functions (opsonisation, chemotaxis etc.) and is involved in many (patho-) physiological responses to stimuli. However, regarding its role in the regulation of vascular remodeling only limited information is available. In **Chapter 7**, we demonstrated that several complement factors (both on protein and mRNA level) are present in thickened vein grafts, including complement component C3, the key player in the complement cascade. Treatment of mice that underwent vein graft surgery with Crry-Ig (interfering in C3 activation) results in marked reduction of vein graft thickening. This reduction coincides with reduced numbers of (adhering) leucocytes and reduced proliferation indexes in early stages of vein graft remodeling. Furthermore, treatment with Crry-Ig resulted in an increased relative contribution of smooth muscle cells in the thickened vein graft in the later stage. A similar reduction in vein graft remodeling as after treatment with Crry-Ig, was seen after treatment with Cobra Venom Factor, another inhibitor of C3 activation, indicating that the observed effects are really due to inhibition of C3 activity and not Crry-Ig specific. These results suggest that activation of the complement cascade is one of the crucial events in initiation of vein graft remodeling.

In **Chapter 8**, the involvement of the most potent chemotactic factor of the complement cascade, C5a, was studied in our murine model of vein graft disease. Immunohistochemistry showed that C5 appears to be predominantly expressed in adhering monocytes, adventitial fibroblasts, endothelial cells and foam cells in the thickened vein graft, whereas it is not detectable in normal caval veins. Furthermore, increased exposure to C5a (during surgery by topical application of recombinant C5a dissolved in pluronic gel directly to the vein graft) dose-dependently aggravated vein graft thickening, and also dose-dependently increased macrophage-derived foam cell content in the lesion. Oppositely, hampering signal transduction of the C5a receptor (C5aR) using specific C5aR-antagonists resulted in a decreased vein graft thickening with reduced contribution of foam cells to lesion formation. These results demonstrate that besides CC-chemokines, also other chemotactic factors (in this case C5a) are involved in vein graft remodeling, and that these factors can be used to hamper vein graft remodeling.

The above-mentioned results in **Chapter 7 and 8** clearly specify at least one of the pathways by which complement is involved in vein graft remodeling, being induction of influx of various inflammatory cells to the vessel wall and cytokinetic processes such as proliferation. More specifically we show that C5a is an end-product of great importance in the process of vein graft remodeling and it might actually be the predominant end-product of the complement cascade involved in the influx of inflammatory cells.

CONCLUSIONS

Occurrence of restenosis after PTA or development of vein graft disease is a significant clinical problem, often requiring new interventions. Insight in the pathophysiology of vascular remodeling will provide possible targets for therapy. This thesis has focused on the role of inflammation in post-interventional vascular remodeling in general. However, since inflammation can be seen as an orchestra, with contributors acting at different time points and influencing each other, the several components were studied separately. Taking all the studies together, this thesis clearly shows that specific parts of the inflammatory reaction (chemokines, as well as the complement cascade) are involved in the early phases of post-interventional vascular remodeling and that inhibition of the inflammatory response, by counteracting separate components, results in reduced vascular remodeling.

Therefore, we believe that we did not only gained more insight in the mechanism of post-interventional vascular remodeling, but also indicated several potential targets for therapy to defeat the clinical problem of restenosis. Future research will reveal whether these targets are truly applicable in patients.

FUTURE PERSPECTIVES

In the last years, a great amount of work generated valuable data that provided insight in the pathophysiology of post-interventional remodeling. As endorsed by this thesis, inflammation is importantly involved in the early steps of the remodeling process and the regulation of influx of inflammatory cells is performed by several different factors. However, it remains difficult to put all events in place and to survey the complete process. We believe that future research should aim at a better understanding of the consecutive events in vascular remodeling and seek for hierarchical series herein. One of our major challenges is to appoint which of all inflammatory factors that have been shown (either described in this thesis or by other groups) to be involved in the process of vascular remodeling in murine or other animal models, the one to be chosen for further therapy development in patients. Given the complex and multi-factorial character of the problem, a close collaboration between clinicians and basic researchers appears to be of utmost importance. This represents the area of *translational research*. In this thesis, we pursued this by attempting to test data gained from murine experiments for applicability in human tissue (Chapter 4 and 5). Another study (although not included in this thesis) that nicely illustrates a translational approach is the one wherein TNF- α -polymorphism is identified as a risk factor for coronary restenosis in patients that underwent PTA and this hypothesis is conformed in various murine experiments¹.

Taking all recent advances in the field of atherosclerosis and vascular remodeling research together, what will be the benefit for the patient? What changes in therapy can be expected for patients suffering from the clinical consequences from advanced atherosclerosis? We believe that therapies aiming at modulation of the immune response will enter the clinical field of vascular medicine.

One of the first questions that need to be asked is: which patients should be considered for therapy?

Since the first signs of atherosclerosis can already be detected in the second and third decade of life and these early stages of the disease are not accompanied by clinical symptoms, therapies aiming at *prevention of atherosclerosis* do not appear feasible as it implies that virtually the whole population should be treated protractedly, not knowing whether the specific individuals will ever develop clinically overt atherosclerosis. Clearly, this approach results in serious over-treatment of a lot of healthy adults. However, *secondary prevention*, defined as treatment to prevent recurrent cardiac and vascular morbidity and mortality and to improve quality of life in people who had a prior manifestation of complicated atherosclerosis, overcomes the problem of over-treatment and selects patients that might benefit from treatment. Therapies for secondary prevention will change in the upcoming years. It is this kind of therapies this thesis has focused on and since this thesis dealt solely with post-interventional remodeling, we will further discuss future therapeutic measures aimed at inhibiting post-PTA restenosis and vein graft disease.

The last years, prevention of restenosis after PTA has evolved using the drug-eluting stents, and with good results (although long-term studies show conflicting results). Until now, coatings has focused on inhibition of proliferation, using Paclitaxel and Sirolimus. In the upcoming years, anti-inflammatory agents might be introduced as a coating to stents, taking into account the growing amount of evidence pointing at an important role for inflammatory processes in the early stages of post-PTA restenosis. Furthermore, pre-intervention assessment by micro-array analysis of snips and other polymorphisms can indicate patients with high risk of restenosis and new complications of atherosclerosis, and identify individualized targets for therapy, an approach demonstrated in the GENDER study². Ideally, multiple coated stents are available, each with a different coating (for example antagonists of MCP-1, TNF- α or C3, IL10 overexpression, anti-proliferative agents, lipid lowering compounds etc.) and pre-intervention analysis allocate the proper coated stent to a specific patient, thereby customizing treatment in the individual patient undergoing PTA.

In case of bypass surgery, a similar approach can be made. Specific groups of patients with high risk of bypass failure should be identified, either by experiences from previous bypasses, or based on micro-array data as described above. Once high-risk patients are indicated, one can hypothesize that these patients can be treated post-operatively with regular (corticosteroids) or newly developed anti-inflammatory agents (e.g. anti-MCP-1, anti-C5a).

One other approach would be to treat the bypass locally. Although the phenomenon of drug-eluting stents does not exist in the field of bypass surgery, theoretically vein grafts are highly suitable for ex-vivo manipulation. In this line of thinking, coatings containing therapeutic agents can be directly applied or gene transfer can be used to over-express or block expression of certain proteins involved in vein graft remodeling.


Finally, aside of the future perspectives, one remark regarding studying vein graft remodeling should be brought under attention. Insight in the pathophysiology of vein graft diseases is to a large extent gained by extrapolating observations in other forms of vascular remodeling (post-angioplasty restenosis, spontaneous atherosclerosis) to the failing bypass, thereby assuming that pathophysiologies in the different forms of vascular remodeling are alike. This assumption even led to publications of review papers dealing about vein graft disease, wherein the majority of the cited references concerns studies of atherosclerosis and post-interventional restenosis.

There are multiple arguments to oppose this assumption. Firstly, venous endothelium is distinct from arterial endothelium with regards to origin, response to hemodynamic changes and inflammatory stimuli. Secondly, the vessel wall of vein grafts exist of less smooth muscle cells in the media, making them more vulnerable to circumferential forces. Finally, restenosis occurring after PTA, is developing in diseased tissue (an underlying atherosclerotic plaque is present) and therefore response to mechanical injury may be different than that of a principally healthy greater saphenous vein that is used as a venous bypass graft.

To our opinion, although a lot of the processes and mediators in vein graft disease, post-PTA restenosis and spontaneous atherosclerosis might be alike, no remarks about pathophysiology of vein graft disease can be made, unless studied in a proper model. For the reasons mentioned above, good research aimed specifically on vein graft disease remains necessary in the future.

REFERENCE LIST

1. Monraats PS, Pires NM, Schepers A, Agema WR, Boesten LS, de Vries MR, Zwinderman AH, de Maat MP, Doevendans PA, de Winter RJ, Tio RA, Waltenberger J, 't Hart LM, Frants RR, Quax PH, van Vlijmen BJ, Havekes LM, van Der LA, van der Wall EE, Jukema JW. Tumor necrosis factor-alpha plays an important role in restenosis development. *FASEB J* 2005 December;19(14):1998-2004.
2. Monraats PS, Pires NM, Agema WR, Zwinderman AH, Schepers A, de Maat MP, Doevendans PA, de Winter RJ, Tio RA, Waltenberger J, Frants RR, Quax PH, van Vlijmen BJ, Atsma DE, van Der LA, van der Wall EE, Jukema JW. Genetic inflammatory factors predict restenosis after percutaneous coronary interventions. *Circulation* 2005 October 18;112(16):2417-25.



NEDERLANDSE SAMENVATTING

Atherosclerose is de meest voorkomende van alle van hart en vaatziekten in de westerse wereld, en daarmee een belangrijke doodsoorzaak. Het is te karakteriseren als een aandoening van de grote slagaderen die zich kenmerkt door vaatvernauwingen ontstaan uit vetdeposities in de vaatwand met een tegelijk optredende ontstekingsreactie ter plaatse. Meerdere behandelingsstrategieën worden toegepast om de klinische symptomen van atherosclerose te behandelen, te verdelen in medicamenteuze behandelingen en interventies. Deze interventies zijn te verdelen in percutane procedures zoals een percutane transluminale angioplastie (ook wel “Dotter procedure” genaamd, PTA) waarbij een vernauwd deel van een slagader wordt opgerekt, al dan niet met achterlaten van een zogenaamde stent en de bypass operaties waarbij er een omleiding wordt gemaakt langs een vernauwd stuk slagader. Van beide therapieën zijn de lange termijn resultaten niet altijd positief, en een significant aantal patiënten krijgt een recidief van zijn klachten als gevolg van het opnieuw vernauwen van de eerder opgerekte slagader of het occluderen van de bypass. Dit wordt veroorzaakt door remodelering van de vaatwand als gevolg van gladde spiercel proliferatie en migratie, de influx van monocyt/macrophagen en de versnelde atherosclerose in een het betreffende vaatsegment (een arterieel segment dat een PTA heeft ondergaan, of een vein graft dat als bypass is geplaatst). Dit proces wordt vaak als “restenose” aangeduid.

Het doel van dit proefschrift was het vergroten van de kennis omtrent de rol van ontstekingsprocessen in deze bovengenoemde veranderingen in de vaatwand en deze rol te bezien in het licht van potentiële therapieën om dit fenomeen te voorkomen zowel na PTA als na het plaatsen van een bypass.

Studies beschreven in dit proefschrift zijn met name uitgevoerd in muismodellen die deze processen nabootsten. In deze modellen hebben we allereerst voor een zeer algemene aanpak gekozen, namelijk het ontstekingsproces verminderen door de muizen te behandelen met het sterk-werkende anti-inflammatoire medicijn dexamethason, en te zien of deze aanpak een vermindering van restenose en bypass wandverdikking zou kunnen bewerkstelligen. Daarna heeft de nadruk zich verlegd op specifieke aspecten van het immuunsysteem die mogelijk betrokken zouden kunnen zijn bij de ontstekingsreacties die worden gezien in de vaatwand na PTA en bypass operaties, namelijk Interleukine 10 (Il10), chemokinen en het complement systeem.

Il10 werd gekozen omdat dit een van de meest bestudeerde anti-inflammatoire cytokinen is en dat maakt het een interessante kandidaat voor anti-restenose therapie. Verder zijn verschillende chemokinen bestudeerd in verschillende studies, vanwege hun potentie om ontstekingscellen aan te trekken naar weefsels (chemotaxis). Chemotaxis van ontstekingscellen naar de wand van de bypass wordt gezien in de eerste fase na een bypass operatie.

Het complement systeem werd bestudeerd in deze context omdat het een sterke pro-inflammatoire activiteit vertoont in vele ziektebeelden en sommige eindproducten van de cascade eveneens sterke chemotactische eigenschappen hebben, terwijl nog nauwelijks iets bekend was over een mogelijke rol bij vasculaire remodeling.

Meerdere pre-klinische en klinische studies hebben de anti-restenotische eigenschappen van het glucocorticoid dexamethason onderzocht en met wisselende uitkomst. Recent zijn er enkele studies verricht naar het effect van dexamethason-eluerende stents na PTA in patiënten. Echter geen van deze studies heeft de potentiële bijwerkingen van dit medicijn op de vaatwandsamenstelling onderzocht. In **Hoofdstuk 2** worden de anti-restenotische eigenschappen van zowel lokale dexamethason applicatie als systemische behandeling met dexamethason op de vaatwand onderzocht. Dit werd bestudeerd in een muismodel van cuff-geïnduceerde stenoserende vaatremodellering. Zowel lokale applicatie en systemische behandeling resulteerde in een vermindering van neointima vorming in het vaatsegment ter plaatse van de cuff. Dit suggereert een inflammatoire component in vaat remodelering zoals neointima vorming. Echter, systemische behandeling met dexamethason ging samen met ernstige bijwerkingen bij de dieren (zoals verminderde vachtkwaliteit, verminderde activiteit en verminderde gewichtstoename). Lokale applicatie van dexamethason liet deze bijwerkingen niet zien maar ging wel samen met een verlies van vasculaire integriteit ter plaatse van de cuff, gekenmerkt door atrofie van de media, een verminderde gladde spiercel- en collageen bijdrage aan de vaatwand, toename van apoptose en breuken in de lamina elastica interna. Dit fenomeen deed zich met name voor bij cuffs die waren opgeladen met een hogere dosering dexamethason. De resultaten van deze studie suggereren dat ondanks het feit dat dexamethason-eluerende stents potentieel een anti-restenotische werking hebben, het therapeutisch window erg smal is en lokale bijwerkingen aan de vaatwand reeds bij relatief lage doseringen worden gezien. Dit verlies van vaatwand integriteit zou kunnen leiden tot zwakke plekken in de vaatwand en hypothetisch gezien is een op deze manier aangedane vaatwand gevoelig voor thrombus- en aneurysmavorming. Voorzichtigheid is geboden als in de klinische praktijk de zogenaamde “overlappende” stents worden gebruikt. Aanvullende studies naar het optreden van vaatwandveranderingen als gevolg van lokale effecten van het vrijgekomen medicijn zouden moeten volgen bij alle medicijn-eluerende stents, om te zien of deze ook de bovenbeschreven effecten op de vaatwand hebben.

De rol van ontsteking in regulatie van vaatwand remodelering werd verder onderzocht in **Hoofdstuk 3**. **Hoofdstuk 3** bespreekt de effecten van het cytokine Interleukine 10 (Il10) op restenose na PTA. In het algemeen heeft Il10 een anti-inflammatoire werking en daarom is dit een interessant cytokine om verder te onderzoeken in het licht van restenose. Hypothetisch zou overexpressie van IL10 kunnen leiden tot vermindering van post-PTA restenose. Om dit te bewijzen werd het effect van Il10 bestudeerd in een tweetal modellen. Allereerst werd het effect van ontbreken van Il10 onderzocht in het cuffmodel waarbij gebruik werd gemaakt van dubbel transgene ApoE3Leiden/ Il10^{-/-} muizen. Deze muizen ontwikkelen hypercholesterolemie wanneer zij een pro-atherogeen dieet krijgen en hebben een aangeboren Il10 deficiëntie. Daarna werd het tegenovergestelde bewerkstelligd, namelijk werd het effect van overexpressie van Il10, door middel van electroporatie-gemedieerde gentherapie in de kuitspier van ApoE3Leiden muizen, op cuff-geïnduceerde stenose bestudeerd. Beide benaderingen laten zien dat Il10 inderdaad

is betrokken bij de regulatie van het ontstaan van neointima vorming. Il10 heeft duidelijk anti-restenotische capaciteiten; afwezigheid van Il10 verergerde neointima vorming in het gecuffte vaatsegment, terwijl overexpressie van Il10 een vermindering van neointima veroorzaakte. De pathofysiologie van dit effect berust waarschijnlijk op inductie van een zogenoemde Th2-responsie. Dit werd meer waarschijnlijk gemaakt door het aantonen van een opregulatie van verschillende Th2-cytokinen in de milt, terwijl andere pro-inflammatoire cytokinen werden de down-reguleerd. Verder daalde het serum-cholesterol van Il10-overexpressie muizen. Dit kan mogelijk ook hebben bijgedragen aan het anti-stenotische effect van de behandeling.

Zowel **Hoofdstuk 2** als **Hoofdstuk 3** leveren bewijs voor een rol van ontsteking in het ontstaan van post-PTA restenose en bespreken sommige potentiële therapeutische opties en veiligheidsoverwegingen in de preventie van restenose bij patiënten die een PTA hebben ondergaan.

Het gebruik van dexamethason, een potent glucocorticoid en algemene ontstekingsremmer, om restenose te remmen heeft ernstige bijwerkingen, die laten zien dat aanpassingen nodig voordat dexamethason eventueel veilig gebruikt zou kunnen worden voor dit doeleinde. Il10 overexpressie daarentegen, lijkt wel potentiële kandidaat voor anti-restenose therapie.

In de overige hoofdstukken van het proefschrift wordt de rol van ontsteking in veneuze bypass remodelering bestudeerd. Net als in **Hoofdstuk 2**, wordt begonnen met een algemene benadering van deze hypothese, een “proof of principle” dat ontsteking betrokken is bij het ontstaan van intima hyperplasie en versnelde atherosclerose. Ook hier maakten we gebruik van dexamethason.

In **Hoofdstuk 4** werd het effect van dexamethason behandeling getest op het ontstaan van vaatwandverdikking in de veneuze bypass. Hiervoor ondergingen ApoE3Leiden muizen een operatie waarbij een veneus interponaat in de arteria carotis werd geplaatst en ze gedurende 28 dagen werden met dexamethason. Behandeling resulteerde in een vermindering van vaatwandverdikking, echter ernstige bijwerkingen gerelateerd aan het lange corticosteroiden gebruik, traden op.

Om dit te voorkomen werden muizen na operatie 7 dagen behandeld met dexamethason en het effect van deze kortdurende behandeling werd geëvalueerd na 28 dagen. Deze kortdurende behandeling resulteerde in een even grote afname van vaatwandverdikking van de bypass wanneer dit werd vergeleken met de 28 dagen durende behandeling met dexamethason, maar het optreden van ongewenste bijwerkingen werd voorkomen.

mRNA analyse van bypasses, geoogst op verschillende tijdstippen na operatie, liet zien dat behandeling met dexamethason resulteerde in een verminderde expressie van verschillende pro-inflammatoire cytokinen in de vaatwand van de bypass, vergeleken met expressie van cytokinen in bypasses van muizen die niet werden behandeld. Deze

verminderde expressie was reeds 24 uur na operatie aantoonbaar en dit effect hield enkele dagen aan.

Om de toepasbaarheid in patiënten aan te tonen, werden vaatsegmenten afkomstig uit de humane vena Saphena magna specimen gekweekt. In deze orgaankweek ontstaat in 4 weken een neointima die voornamelijk bestaat uit gladde spiercellen. Ontstekingscellen ontbreken in dit model. Toevoeging van dexamethason aan het medium (wederom voor 7 of 28 dagen) resulteerde in gelijke effecten als in de muizen experimenten, namelijk een vermindering van neointima vorming onafhankelijk van duur van de toevoeging van dexamethason. Het impliceert dat effecten van kortdurende behandeling niet muis-specifiek zijn, maar ook potentieel toepasbaar op de humane situatie. Het wijst tevens op een potentieel anti-proliferatief effect op gladde spiercellen van dexamethason. Als men dit extrapoleert naar de klinische situatie, zou een kortdurende behandeling met dexamethason (een zogenaamde stootkuur) van waarde kunnen zijn om vaatwandverdikking door intima hyperplasie en versnelde atherosclerose te voorkomen, zonder optreden van bijwerkingen gerelateerd aan langdurig corticosteroidengebruik.

Algemener gesteld suggereren deze data dat vermindering van de ontstekingsreactie na een bypass operatie de initiatie van het remodeleringsproces zou kunnen verhinderen en daarmee vaatwandverdikking door intimal hyperplasie en versnelde atherosclerose, zou kunnen voorkomen.

Aangezien de hypothese dat ontsteking inderdaad een rol speelt in remodelering van de veneuze bypass kon worden onderschreven, werden enkele specifieke delen van de ontstekingscascade onderzocht (namelijk chemokinen in **Hoofdstuk 5 en 6** en de complement cascade in **Hoofdstuk 7 en 8**).

CC-chemokinen zijn een groep van pro-inflammatoire cytokinen. Ze zijn betrokken bij verschillende ontstekingsprocessen en hebben chemotactische eigenschappen voor verschillende ontstekingscellen. Om die reden zou kunnen worden aangenomen dat ze betrokken zouden zijn bij remodelering van de bypass.

MCP-1 is een van de meest potente chemokine en het meest bestudeerd in allerlei contexten. Het is bekend om zijn rol in spontane atherosclerose, post-PTA restenose en versnelde atherosclerose van orgaantransplantaten. In Hoofdstuk 5 werd de rol van MCP-1 in versnelde atherosclerose van de bypass bestudeerd. Hiervoor werd gebruik gemaakt van een tweetal modellen; (1) het muismodel voor bypass remodelering bij ApoE3Leiden muizen en (2) het vena Saphena magna orgaankweek model. Met immunohistochemie werd de uitgebreide aanwezigheid van MCP-1 aangetoond in de verschillende stadia van intima hyperplasie en versnelde atherosclerose vorming in beide modellen. Behandeling met de dominante receptor antagonist 7ND-MCP-1 resulterend in verminderde MCP-1/CCR2 pathway activatie, leidde tot een significante vermindering van bypass vaatwandverdikking. Tevens leidde blokkade van MCP-1 met 7ND-MCP-1 in het orgaan kweek model tot een vermindering van

intima hyperplasie. Daarbij werd, behalve een bekend effect op macrofagen influx, ook een effect van MCP-1 op gladde spiercelproliferatie aangetoond.

Uit deze data mag worden geconcludeerd dat MCP-1 een belangrijke speler is in intima hyperplasie vorming en versnelde atherosclerose van veneuze bypasses. Blokkeren van MCP-1 zou een potentiële anti-restenose therapie na veneuze bypass plaatsing kunnen zijn.

Andere CC-chemokinen zijn minder bestudeerd in het veld van vasculaire biologie in het algemeen en in de bypass remodelling in het bijzonder. MIP-1 α en RANTES (Regulated on Activation Normal T-cell Expressed and Secreted) zijn ook leden van de CC-chemokinen familie en hebben net als MCP-1 chemoattractieve eigenschappen voor macrofagen, maar ook voor T-cellen en in mindere mate granulocyten. Ze delen hun receptor; CC-receptor 1 (CCR1), CCR3 en CCR5, daar waar MCP-1 bindt aan de CCR-2. Gezien het feit dat ze ongeveer hetzelfde werkingsprofiel hebben en tevens hun receptoren delen werden ze tezamen bestudeerd in Hoofdstuk 6.

Een mogelijke functionele betrokkenheid van MIP-1 α en RANTES in bypass wandverdickning werd bestudeerd in het muizen bypass model, gebruik makend van hypercholesterolemische ApoE3Leiden muizen. Net als MCP-1, konden ook MIP-1 α en RANTES gedetecteerd worden in de bypass vaatwand, reeds kort na implantatie, terwijl deze eiwitten niet tot expressie komen in een “gewone” vene wand. Tevens kon een tijdsgelateerde mRNA upregulatie van zowel MIP-1 α en RANTES en hun receptoren worden aangetoond na de operatie. Om het effect van het blokkeren van MIP-1 α en RANTES op het ontstaan van bypass vaatwandverdickning te onderzoeken, werden muizen behandeld met de CCR1/CCR5 antagonist MetRANTES. Na behandeling hiermee werd een vermindering van aantal adherente monocytten aan de vaatwand gezien, gemeten 3 dagen na de operatie. Verder werd op 28 dagen na de operatie een duidelijke vermindering gezien van vaatwand verdickning in de met MetRANTES behandelde groep. Tevens werden in deze bypasses ook minder schuimcellen in de lesie gezien. Deze data impliceren dat niet alleen MCP-1, maar ook andere chemokinen uit de CC-chemokine familie betrokken zijn bij bypass remodelling, en dat het blokkeren van deze chemokinen een rationele en additionele benadering zijn van therapie gericht op het verminderen van bypass falen.

Een ander deel van het aangeboren immuunsysteem is de complement cascade. Complement is een groep van circulerende eiwitten, membraan gebonden receptoren en regulatoire enzymen. Deze cascade reguleert ontstekingsprocessen via verschillende biologische principes (zoals o.a. obsonisatie, cel-lysis en chemotaxis van ontstekingscellen). Het complement systeem is betrokken bij de afweer tegen verschillende stimuli en in vele ziekteprocessen. Echter, de rol ervan in vasculaire remodelering, zoals bijvoorbeeld in spontane atherosclerose en restenose vorming, is onduidelijk.

In **Hoofdstuk 7** werd de aanwezigheid van verschillende delen van het complement systeem, inclusief het sleuteleiwit C3, aangetoond in de verdikte bypass wand

van geopereerde ApoE3Leiden muizen. Dit werd aangetoond op zowel eiwit- als op mRNA niveau. Behandeling van de muizen met Crry-Ig (een remmer van C3 activatie) leidde tot een significante afname van bypass vaatwandverdikking, samengaan met een vermindering van (adherente) leukocyten en een vermindering van de proliferatie-indexen in de vroege stadia van remodelering van de bypass. Verder leidde behandeling met Crry-Ig tot een toename van de hoeveelheid gladde spiercellen in de vaatwand, gemeten in bypasses geoogst na 28 dagen. Deze effecten waren niet Crry-Ig specifiek, aangezien ze ook werden bereikt door de muizen te behandelen met Cobra Venom Factor (CVF), een andere remmer van C3-activering. Dit betekent dat de geobserveerde effecten inderdaad toe zijn te schrijven aan een remming van C3, en dat activering van de complement cascade een van de cruciale fenomenen is in de initiatie van bypass vaatwandverdikking.

Hierop wordt verder gegaan in **Hoofdstuk 8**. Hierin wordt de rol van een van de meest potente chemotactische factoren van het complement systeem, namelijk C5a, onderzocht in ons muismodel voor bypass remodelering. Reeds herhaaldelijk werd aangetoond dat chemotaxis een van de eerste fenomenen is dat optreedt bij vaatwandverdikking van de bypass, en dat maakt C5a een potentieel interessant eiwit om te onderzoeken. Immunohistochemische analyse laat zien dat C5a voornamelijk tot expressie komt in adherente monocyten, fibroblasten uit de adventitia, endotheelcellen en schuimcellen in de verdikte bypass wand, terwijl het niet aantoonbaar is in de normale venewand. Het tijdens de operatie aanbrengen van recombinant C5a op de vein graft/bypass, leidde tot een sterke, dosisafhankelijke toename van bypass verdikking en versnelde atherosclerose in de bypass na 28 dagen. Tegenovergesteld, wanneer C5a wordt geblokkeerd door gebruik te maken van een C5a receptor-antagonist, werd een vermindering gezien van zowel vaatwandverdikking als hoeveelheid schuimcellen. Deze bevindingen laten zien dat naast CC-chemokinen, ook andere chemotactische factoren een rol spelen bij het ontstaan van bypass remodelering en deze factoren ook een therapeutisch target zouden kunnen zijn om bypass vaatwandverdikking te verminderen.

De resultaten zoals beschreven in **Hoofdstuk 7 en 8** laten (in ieder geval een van) de functionele routes zien waarop de complement cascade is betrokken bij bypass remodelering: door inductie van influx van verschillende ontstekingscellen in de vaatwand en cytotkinetische processen zoals proliferatie in het algemeen, en meer specifiek dat C5a is een belangrijk eindproduct van de complement cascade, in het licht van bypass falen.

CONCLUSIES

Het optreden van restenose na PTA of het ontwikkelen van bypass vaatwandverdikking is een ernstig klinisch probleem. Het beperkt het effect van therapie welke wordt gegeven voor klachten van ischemisch vaatlijden, en leidt vaak tot de noodzaak van hernieuwde interventie zoals opnieuw bypass chirurgie of soms, indien revascularisatie niet meer mogelijk is, zelfs amputatie. Inzicht

in de pathofysiologie van vasculaire remodelering zal mogelijkheden bieden om deze gevolgen te vermijden en mogelijk leiden tot potentiële therapieën voor deze problemen. Dit proefschrift heeft zich gericht op de rol van ontsteking in postinterventie vasculaire remodeling in het algemeen. Echter, omdat ontsteking een complex samenwerkingsverband is tussen allerlei verschillende componenten, waarin de verschillende componenten op verschillende tijdstippen werken en elkaar complex beïnvloeden, kan ontsteking nooit als een geheel worden onderzocht. Dat is de reden dat in dit proefschrift is gekozen voor een aanpak waarin de afzonderlijke componenten afzonderlijk zijn onderzocht.

Als alle studies beschreven in dit onderzoek tezamen worden genomen kan duidelijk worden geconcludeerd dat specifieke delen van de ontstekingsreactie een belangrijke rol spelen in de vroege fases van vasculaire remodelering. Tevens is aangetoond dat het verminderen van deze delen van de ontstekingsreactie leidt tot het verminderen van restenose en bypass falen.

TOEKOMSPERSPECTIEVEN

In de afgelopen jaren is een enorme hoeveelheid werk verricht om meer inzicht te krijgen in de ontstaansmechanismen van postinterventie vasculaire remodelering. Zoals onderschreven bij dit proefschrift, is ontsteking een belangrijke speler, met name bij de initiatie van het proces en de regulatie van influx van ontstekingscellen. Het blijft echter moeilijk om al deze processen en afzonderlijke componenten hiervan in een hiërarchisch systeem te plaatsen en op die manier het hele proces te overzien.

Een van de belangrijkste uitdagingen op dit moment, is het aanwijzen van een specifiek doel (in de zin van gen/eiwit of proces) in de richting van een therapeutische benadering voor patiënten. Met andere woorden, welk van alle ontstekingsfactoren onderzocht in dit proefschrift, of welk van de andere eiwitten of biologische processen beschreven in de literatuur, is het meest veelbelovend voor verder ontwikkeling richting een voor patiënten ontwikkelde therapie.

Gegeven het complexe en multi-factoriële karakter van het probleem, is een nauwe samenwerking tussen klinici en wetenschappers in deze, van groot belang en zal leiden tot het zogenaamde translationele onderzoek. In dit proefschrift (**Hoofdstuk 4 en 5**), wordt dit translationele karakter nagestreefd door onze data, verkregen uit muisexperimenten, in humaan weefsel te reproduceren. Een andere studie die dit translationele principe ondersteunt (hoewel niet opgenomen in dit proefschrift), is die waarin een polymorfisme in het gen voor de ontstekingsfactor TNF- α is geïdentificeerd als een risicofactor voor het ontwikkelen van coronaire restenose na PTA in patiënten, en in dezelfde studie is deze hypothese bevestigd door middel van verschillende muisexperimenten.

Als we nu alle vooruitgang in het cardiovasculaire onderzoek van het laatste decennium samenvoegen, rijst de vraag wat het voordeel voor de patiënt uiteindelijk zal zijn. Welke veranderingen in therapie kunnen patiënten die lijden aan de klinische symptomen van hart en vaatziekten verwachten? Een optie is dat therapie, ontwikkeld om de ontstekingsreactie te reguleren, zijn entree zal maken in de klinische praktijk.

Maar een van de eerste vragen die men zich moet stellen is: welke patiënten komen in aanmerking voor therapie?

Aangezien de eerste verschijningsvormen van atherosclerose reeds in het tweede en derde decade van het leven bij gezonde mensen kunnen worden aangetoond, en deze vroege afwijkingen niet lijden tot klinische symptomen, zijn therapieën die gericht zijn op het voorkomen van atherosclerose niet gemakkelijk haalbaar. Het zou betekenen dat zo goed als de hele populatie zou moeten worden behandeld zonder te weten wie van deze individuen uiteindelijk klinisch relevant vaatlijden gaat ontwikkelen. Het is duidelijk dat deze benadering zal leiden tot ernstige overbehandeling van op dat moment gezonde mensen.

Secondaire preventie, echter, gedefinieerd als behandeling om complicaties van aangetoonde ziekte te voorkomen en kwaliteit van leven te verbeteren, heeft dit probleem van overbehandeling niet, aangezien patiënten reeds gediagnosticeerd zijn met klinische symptomen van hart en vaatziekten. Op dit moment bestaat secundaire preventie met name uit medicamenteuze therapieën onder andere gericht op het verlagen van serum cholesterol en de bloeddruk. In de komende jaren zal secundaire preventie veranderen. Aangezien dit proefschrift is gericht op secundaire preventie van restenose en bypass vaatwandverdikking, zullen de toekomstperspectieven in dit veld bediscussieerd worden.

De afgelopen jaren heeft de preventie van restenose na PTA zich toegespitst op het gebruik van de zogenaamde drug-eluting stents. De effecten van deze stents (die een meestal een antiproliferatief medicijn afgeven) op restenose zijn bemoedigend, hoewel lange termijn studies tegenstrijdige resultaten laten zien.

Tot op heden zijn de coatings van drug-eluting stents met name gericht op afremmen van proliferatie, gebruik makend van Paclitaxel of Sirolimus. De komende jaren zullen anti-inflammatoire therapeutica worden geïntroduceerd als medicijnen die kunnen elueren uit stentcoatings, met name door de groeiende hoeveelheid bewijs die ontsteking als een van de belangrijkste processen in restenose vorming aanwijst. Verder wordt de pre-interventie evaluatie van een individueel risico voor restenose door middel van micro-array of SNP analyse genoemd als een van de toekomstige ontwikkelingen. Patiënten met een hoog risico op restenose of complicaties kunnen worden geïdentificeerd en een op hun profiel aangepaste therapie krijgen. Deze benadering wordt beschreven in de GENDER studie. Idealiter zijn er in de toekomst meerdere stents op de markt, elk met een verschillende coating (bijvoorbeeld met anti-MCP-1, anti-TNF- α , anti-C3, Il10 overexpressie, etc.). Pre-interventie analyse wijst dan een op het individu toegespitste stent aan, die ingrijpt op een bij SNP-

analyse aangetoonde metabole afwijking van een individuele patiënt. Op deze manier wordt een geïndividualiseerde therapie voor elke patiënt verkregen.

In het geval van de bypass chirurgie kan een zelfde benadering worden gekozen. Specifieke groepen met een hoog risico op bypass falen zullen moeten worden geïdentificeerd. Dit kan doordat zij eerder een bypass operatie hebben ondergaan, waarbij de bypass is geoccludeerd, of gebaseerd op pre-interventie analyse. Als deze hoogrisico patiënten zijn aangewezen, kan men zich voorstellen dat deze patiënten postoperatief kunnen worden behandeld met reguliere (corticosteroïden) of nieuw ontwikkelde anti-inflammatoire medicijnen (bijv. anti-MCP-1 of anti-C5a).

Een andere benadering kan zijn om tijdens de operatie de bypass lokaal te behandelen. Daarmee wordt gebruik gemaakt van het feit dat bypass grafts zijn zeer toegankelijk voor ex-vivo manipulatie voor en gedurende chirurgie. Zo kunnen bijvoorbeeld coatings op de bypass worden aangebracht die therapeutica bevatten. In theorie kan zelfs gentransfer kan worden toegepast om overexpressie of blokkering te verkrijgen van een bepaald gen.

Tenslotte volgt nog een opmerking inzake bypass vaatwand verdikking en het wetenschappelijk onderzoek hiernaar. Het huidige inzicht in de pathofysiologie van bypass vaatwandverdickking en bypass falen berust grotendeels op het extrapoleren van observaties in andere vormen van vasculaire remodelering (post-interventie restenosis, spontane atherosclerose) naar de bypass. Hiermee wordt verondersteld dat de onderliggende mechanismen voor al deze biologische processen dezelfde zijn. Deze aanname heeft zelfs geresulteerd in de publicatie van reviews waarin de meerderheid van de geciteerde referenties studies naar atherosclerose betreft.

Er zijn meerdere argumenten om aan te nemen dat deze benadering niet de juiste is. Allereerst is het endotheel van een vene anders dan endotheel van een arterie, voor wat betreft origine en respons op hemodynamische veranderingen en inflammatoire stimuli. Ten tweede, de vaatwand van venen bestaat uit minder gladde spiercellen in de media, daarbij is een vene dus kwetsbaarder voor circumferentiële krachten en zal daar ook anders op reageren.

Tenslotte, restenose na PTA ontwikkelt zich in ziek weefsel, er is namelijk een onderliggende atherosclerotische plaque in de arteriewand aanwezig. Men zich voorstellen dat de response op een willekeurige stimulus in een zieke arterie anders kan zijn dan een die van een gezonde vene, die gebruikt wordt als bypass conduit.

Ondanks dat naar alle waarschijnlijkheid een groot deel van de processen en mediators in spontane atherosclerose, post-interventie restenose hetzelfde zullen zijn in bypass vaatwandverdickking, kan er naar onze mening geen uitspraken worden gedaan over pathofysiologische processen, tenzij deze zijn onderzocht in het juiste model. De redenen zoals besproken hierboven maken duidelijk dat de pathofysiologie van bypass falen onderzocht moet worden in modellen voor bypass remodelering en niet door extrapolatie van kennis over atherosclerose.

LIST OF PUBLICATIONS

ARTICLES

van Weel V, Toes RE, Seghers L, Deckers MM, de Vries MR, Eilers PH, Sipkens J, **Schepers A**, Eefting D, van Hinsbergh VW, van Bockel JH and Quax PHA.

Natural Killer Cells and CD4+ T-Cells Modulate Collateral Artery Development. *Arterioscler Thromb Vasc Biol.* 2007 Aug 23; [Epub ahead of print]

Schepers A, de Vries MR, van Leuven CJ, Holers VM, Daha MR, van Bockel JH and Quax PHA. Inhibition of Complement Component C3 Reduces Intimal Hyperplasia in Murine Vein Grafts. *Circulation.* 2006 Dec 19;114(25):2831-8

Eefting D, **Schepers A**, de Vries MR, Pires NMM, Grimbergen JM, Lagerweij T, Nagelkerken LM, Monraats PS, Jukema JW, van Bockel JH and Quax PHA. The effect of interleukin-10 knock-out and overexpression on neointima formation in hypercholesterolemic ApoE3Leiden mice. *Atherosclerosis.* 2006 Nov 4; [Epub ahead of print]

Schepers A, Eefting D, Bonta PI, Grimbergen JM, de Vries MR, van Weel V, de Vries CJ, Egashira K, van Bockel JH, Quax PHA. Anti-MCP-1 gene therapy inhibits vascular smooth muscle cells proliferation and attenuates vein graft thickening both in vitro and in vivo. *Arterioscler Thromb Vasc Biol.* 2006 Sep;26(9):2063-9

Schepers A, Pires NNM, Eefting D, de Vries MR, van Bockel JH, Quax PHA. Short-term dexamethasone treatment inhibits vein graft thickening in hypercholesterolemic ApoE3Leiden transgenic mice. *J Vasc Surg.* 2006 Apr;43(4):809-15

Monraats PS., Pires NNM, **Schepers A** et al (GENDER research group). Tumor Necrosis Factor- α Plays a Pivotal Role in Restenosis Development. *FASEB J.* 2005 Dec;19(14):1998-2004.

Pires NM, **Schepers A**, van der Hoeven BL, de Vries MR, Boesten LS, Jukema JW, Quax PH. Histopathologic alterations following local delivery of dexamethasone to inhibit restenosis in murine arteries. *Cardiovasc Res.* 2005 Dec 1;68(3):415-24

Monraats P, Pires NMM, Agema WRP., Zwinderman AH, **Schepers A**, de Maat MPM, Doevendans PA, de Winter RJ, Tio RA, J Waltenberger J, Frants RR, Quax PHA, van Vlijmen BJM, Atsma DE, van der Laarse A, van der Wall EE, Jukema JW. Genetic inflammatory factors predict restenosis after percutaneous coronary interventions. *Circulation.* 2005 Oct 18;112(16):2417-25.

Monraats, PS et al (GENDER research group). Lipoprotein Lipase gene; Polymorphisms and the Risk of Target Vessel Revascularization after Percutaneous Coronary Intervention. *J Am Coll Cardiol.* 2005 Sep 20;46(6):1093-100

Van den Berg R, **Schepers A**, de Bruine FT, Liauw L, Mertens BJ, van der Mey AG, van Buchem MA. The value of MR angiography techniques in the detection of head and neck paragangliomas. *Eur J Radiol.* 2004;52:240-245.

Schepers A, Klinkert P, Vrancken Peeters MP, Breslau PJ. Complication registration in patients after peripheral arterial bypass surgery. *Ann Vasc Surg.* 2003;17:198-202.

Klinkert P, **Schepers A**, Burger DH, van Bockel JH, Breslau PJ. Vein versus polytetrafluoroethylene in above-knee femoropopliteal bypass grafting: five-year results of a randomized controlled trial. *J Vasc Surg.* 2003;37:149-155.

Tjeenk RM, **Schepers A**, van de Linde P, Breslau PJ, Vrancken Peeters M-PFM. Mortality Registration in Patients with a Proximal Femoral Fracture Admitted to a Surgical Ward. *Eur J Trauma.* 2002;28:95-99

Tjeenk RM, van de Linde P, **Schepers A**, Kastelein GW, Breslau PJ. Registration of Complications in Operative Treatment of Proximal Femoral Fractures in the Elderly. *Eur J Trauma.* 2001;27:129-132

BOOK CHAPTERS

Perivascular cuff-, electronic and chemical injury-induced stenosis
Pires NMM, de Vries MR, **Schepers A**, Eefting D, Lardenoye JHP, Quax PHA.
In: Xu Q, Editor. *A Handbook of Mouse Models for Cardiovascular Disease.* London: John Wiley and Sons Ltd. 2006;89-102

CURRICULUM VITAE


The author of this thesis was born May 22, 1976 in Delft, the Netherlands. She graduated from the Erasmus College (VWO) in Zoetermeer in 1994. In that same year she started her medical training at the University of Leiden.

During her medical training she worked on various research projects of the Department of Radiology, Leiden University Medical Center (Professor Dr. M.A. van Buchem and Dr. R. van der Berg), focussing on different MRI imaging techniques of the brain.

From 1999 to 2000 she performed her medical rotations, resulting in the obtaining of her medical degree in January 2001. Until September 2002, she worked as AGNIO (Assistent Geneeskundige niet in opleiding) at the Red Cross Hospital in Den Haag (Dr. P.J. Breslau). Thereafter, she started as AGIKO (Assistent Geneeskundige in combinatie met Klinisch Onderzoek) with the work described in this thesis (Prof. Dr. J.H. van Bockel and Prof. Dr. P.H.A. Quax; under auspicien of the Dutch Heart Foundation, Molecular Cardiology Program, Grant M93.001).

From September 2005 to September 2007 she worked as a surgical resident at the Leiden University Medical Center (Prof. Dr. J.F. Hamming) and is presently continuing her surgical training at the Haga Hospital in The Hague (Dr. J. Merkus).

The author and her partner Richard Bruijn have two sons; Fynn and Jory.



APPENDICIES

Colour Figure Overview

LEGENDS CHAPTER 1

Figure 1.1: Schematic representation (A) and microphotograph (B) of femoral artery cuff positioning.

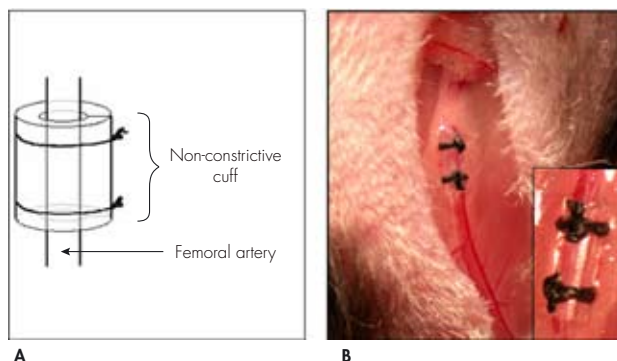
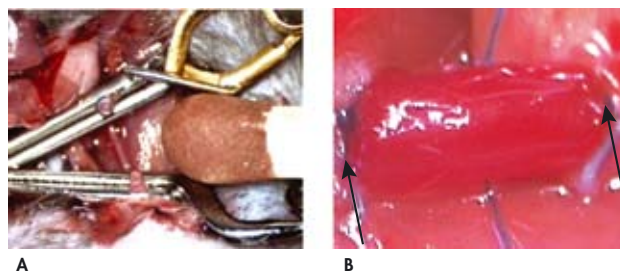


Figure 1.2: Bypass model in a mouse. Panel A: The common carotid artery is divided and occluded with 2 clamps. The inferior caval vein of a donor mouse will be implanted as interposition. Panel B: Venous interponate in situ, arrows indicate anastomotic side.



LEGENDS CHAPTER 2

Figure 2.1: Representative cross-sections of cuffed murine femoral arteries. A: Placebo treatment. **B:** *i.p.* dexamethasone treatment. **C:** Oral dexamethasone treatment. HPS staining, magnification 400x (arrow indicates the internal elastic lamina; arrowheads indicate the external elastic lamina). **D:** Total intimal area of cuffed murine femoral arteries 21 days after cuff placement. Total intimal area was quantified by image analysis using ten serial cross-sections from each cuffed artery and expressed in μm^2 (mean \pm SEM, $n=6$). NS, $P>0.05$ (NS, not significant); ** $P<0.01$.

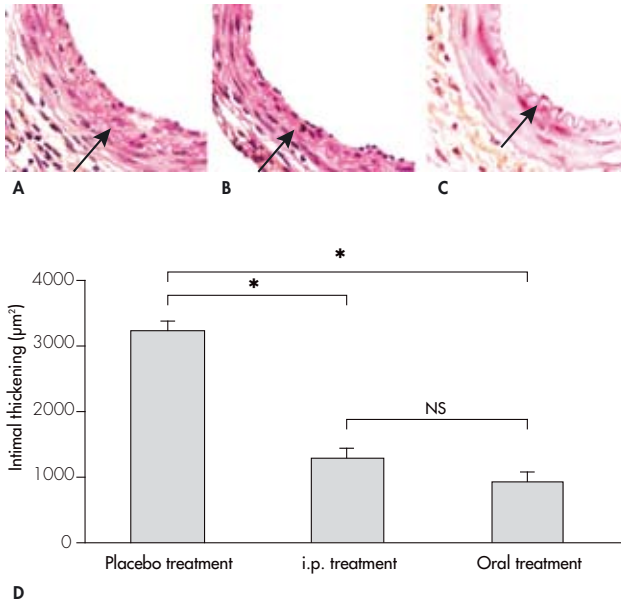


Figure 2.3: Representative cross-sections of cuffed murine femoral arteries treated with increasing concentrations of dexamethasone 21 days after cuff placement. A: Control empty drug-eluting PCL cuff. B: 1% (w/w) dexamethasone-eluting PCL cuff. C: 5% (w/w) dexamethasone-eluting PCL cuff. D: 20% (w/w) dexamethasone-eluting PCL cuff. HPS staining, magnification 400x (arrow indicates the internal elastic lamina; arrowheads indicate the external elastic lamina). E: Total intimal area of cuffed murine femoral arteries 21 days after drug-eluting PCL cuff placement. Total intimal area was quantified by image analysis using ten serial cross-sections from each cuffed artery and expressed in μm^2 (mean \pm SEM, n=6). NS, $P>0.05$ (NS, not significant); * $P<0.05$; ** $P<0.01$.

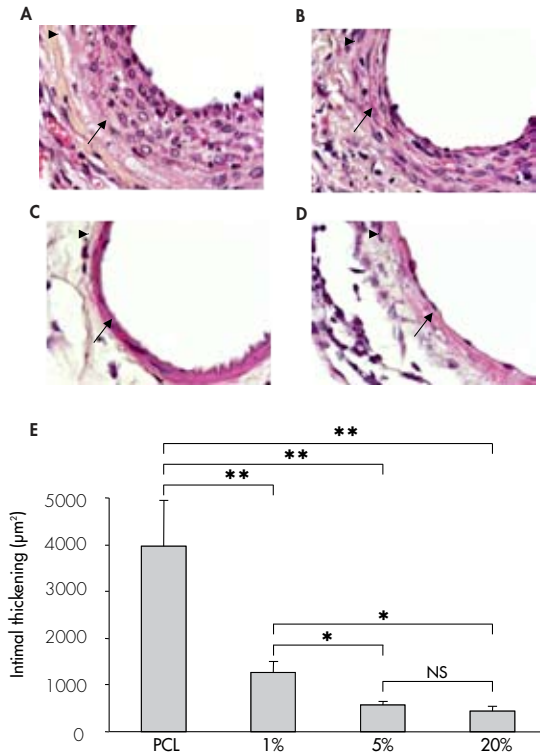


Figure 2.4: Histomorphometrical quantification of cuffed femoral arteries treated with increasing concentrations of dexamethasone. Percentage of TUNEL-positive nuclei (A), total medial area (B) and internal elastic lamina (IEL) disruption (C) of cuffed femoral arteries treated with increasing concentrations of dexamethasone 21 days after drug-eluting PCL cuff placement. TUNEL-positive nuclei were counted in six equally spaced cross-sections from each cuffed artery and expressed as a percentage of the total number of nuclei. Medial area was quantified by image analysis using ten serial cross-sections in each cuffed artery and expressed in μm^2 . IEL disruption was assessed in ten serial cross-sections from each cuffed femoral artery and expressed as the number of broken IEL per cuffed artery segment. Mean \pm SEM, n=6. NS, P>0.05 (NS, not significant); *P<0.05.

Inserts: A: TUNEL staining; femoral artery segments locally treated with 20% (w/w) dexamethasone (20% Dexa) show an increase in TUNEL-positive nuclei as compared to control empty PCL (PCL) cuffed segments. Arrows indicate TUNEL-positive nuclei, magnification 600x. **B:** Weigert's elastin staining; cuffed artery segments treated with 20% (w/w) dexamethasone show a striking medial atrophy. Bars indicate cross-sectional medial area, magnification 600x. **C:** Weigert's elastin staining; control empty PCL cuffed femoral arteries show an intact IEL while local delivery of dexamethasone enhances IEL disruption. Arrows indicate IEL disruption, magnification 600x.

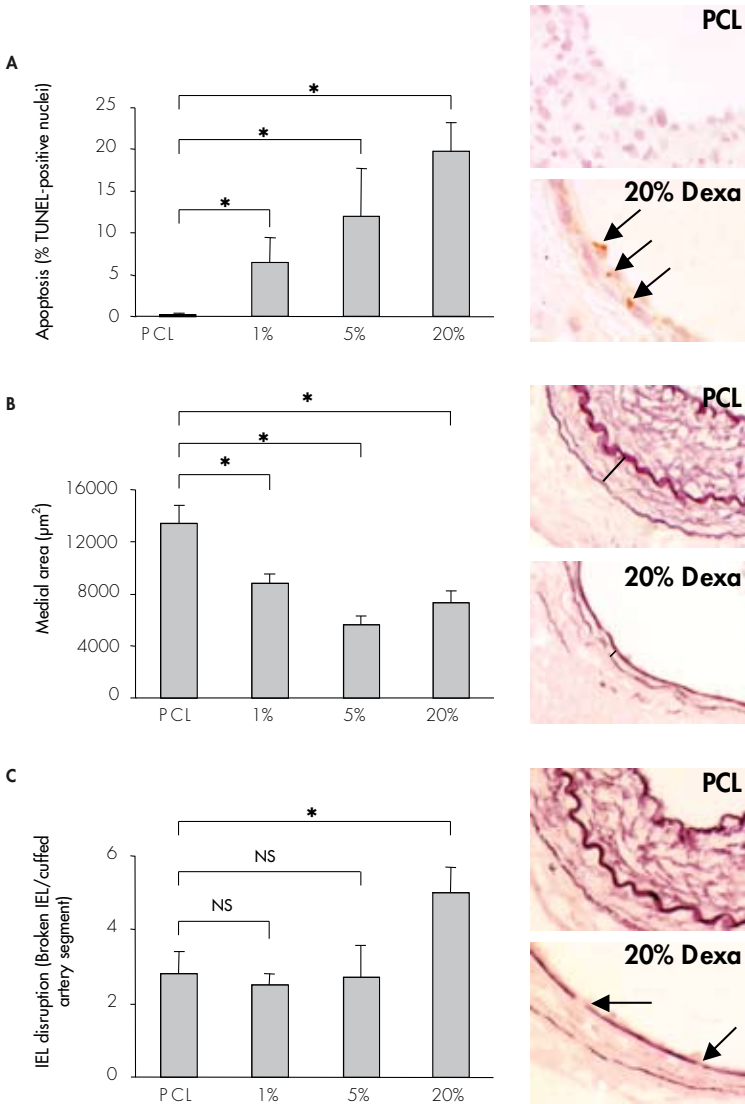
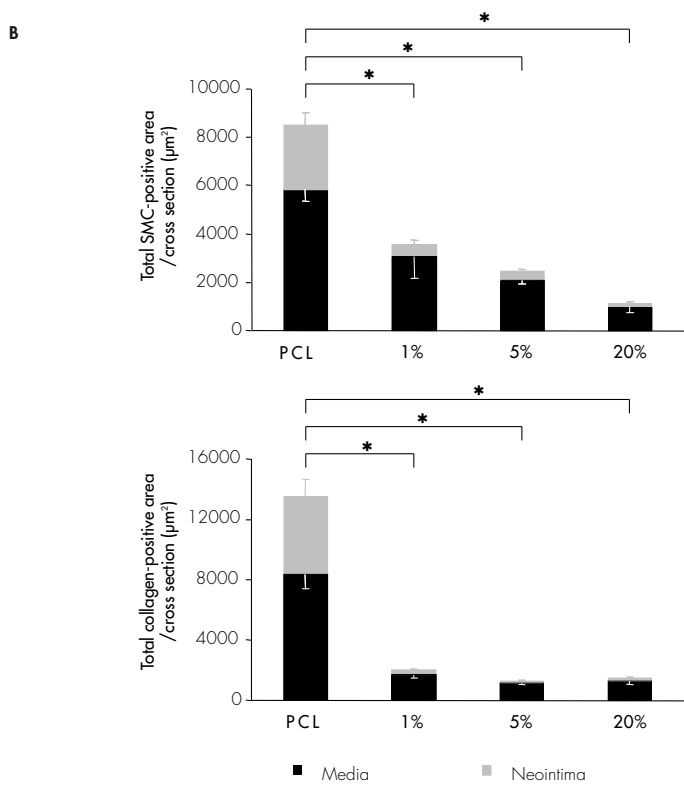
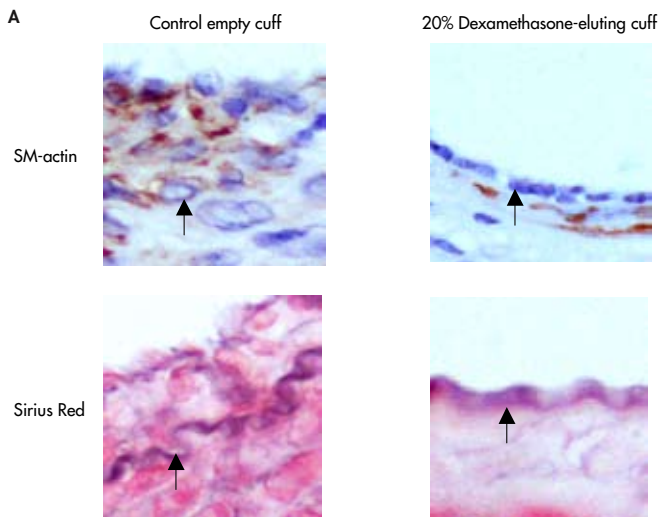


Figure 2.5: A: Representative cross-sections of cuffed murine femoral artery 21 days after placement of either a control empty PCL cuff or a 20% (w/w) dexamethasone-eluting PCL cuff. Alpha smooth muscle cell actin staining for smooth muscle cells; a striking decrease in alpha SMC-positive cells content is observed in the cuffed vessel perivascularly treated with dexamethasone. Sirius red stain for collagen; a reduced vascular collagen content is present in vessel segments locally treated with dexamethasone. Magnification 600x (arrow indicates the internal elastic lamina). **B:** Total SMC- (top) and collagen-positive (bottom) area of cuffed murine femoral arteries treated with increasing concentrations of dexamethasone at 21 days after drug-eluting PCL cuff placement. SMC- and collagen-positive areas were quantified both in the media (black bars) and in the neointima (grey bars) by image analysis using six serial sections in each cuffed artery and expressed in μm^2 . Mean \pm SEM, n=6. *P<0.05.



LEGENDS CHAPTER 3

Figure 3.1: Effect of IL10 knock-out on neointimal formation in hypercholesterolemic mice. Total intimal thickening (Panel A) and percentage of lumen stenosis (B) of cuffed femoral arteries in ApoE3LeidenIL10^{-/-} and their IL10^{+/+} control littermates, 14 days after cuff placement (n=8 per group, *p<0.02). Panel C represents haematoxylin-phloxine-saffron (HPS) staining of cuffed femoral arteries of both groups. Neointimal surface (indicated by black line) is clearly increased in the IL10 knock-out group. Asterisks (*) indicate macrophage-derived foam cells (magnification 250x).

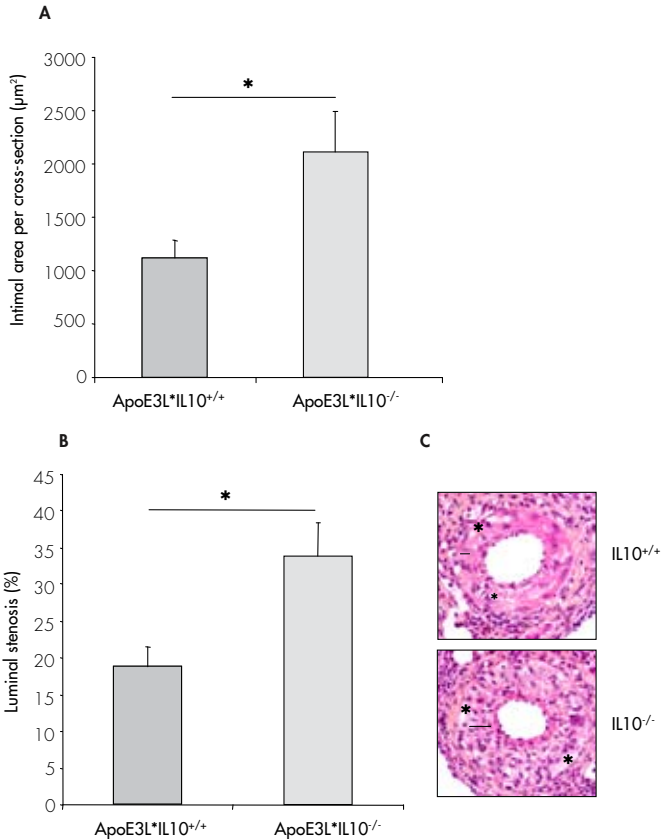


Figure 3.2: Expression of IL10 and Luciferase after intramuscular, non-viral gene therapy. Panel A: Murine IL 10 serum levels in ng/ml, one and three weeks after intramuscular electroporation of mIL10 cDNA or Luciferase as a control (n=5 per group, *p<0.01). IL10 protein levels are significantly increased as compared to the control group after electroporation at both time points. Panel B: Representative bioluminescence images of intramuscular luciferase expression at t=7 and 21 days after electrodelivery of Luciferase. Panel C: Quantitative reproduction of luciferase expression as measured with bioluminescence imaging (n=3).

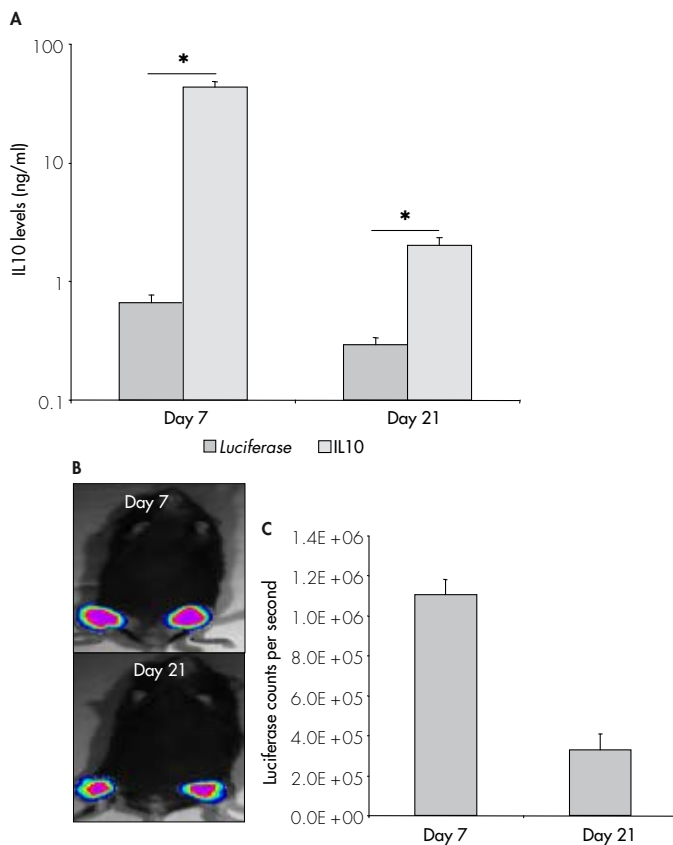


Figure 3.3: Effect of IL10 overexpression on neointima formation in hypercholesterolemic ApoE3Leiden mice. Total intimal area (Panel A) and percentage of lumen stenosis (B) of cuffed femoral arteries in hypercholesterolemic ApoE3Leiden mice, three weeks after electroporation of pCAGGS-mIL10 and pCAGGS-Luciferase as a control (n=8 per group, *p<0.02). Panel C represents haematoxylin-phloxine-saffron (HPS) staining of cuffed femoral arteries after electroporation. IL10 overexpression results in a marked reduction of neointima formation (intimal area is indicated by black line and asterisks (*) indicate macrophage-derived foam cells, magnification 200x).

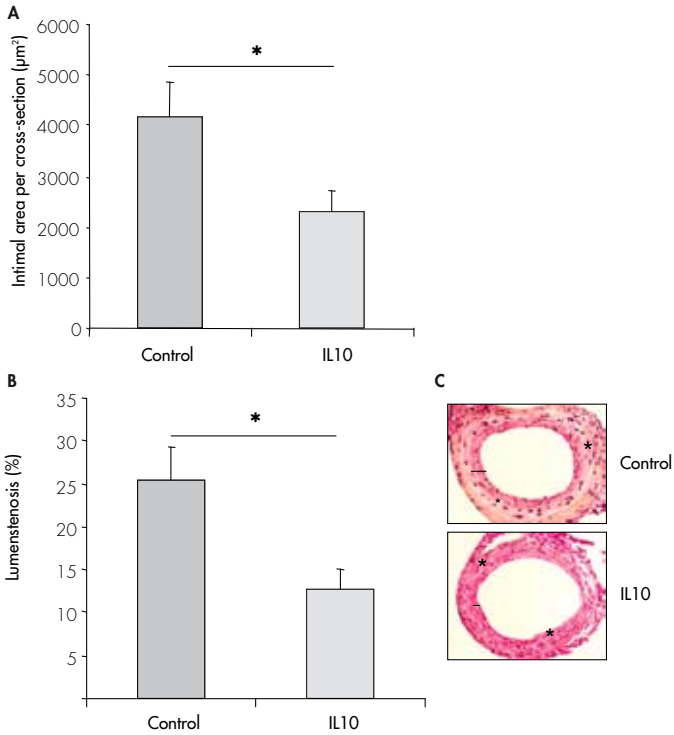
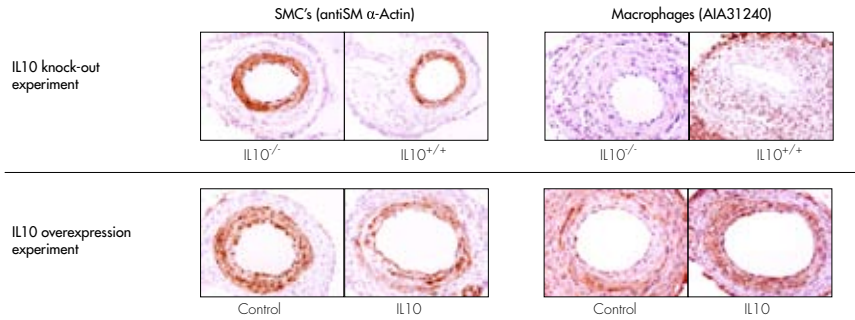
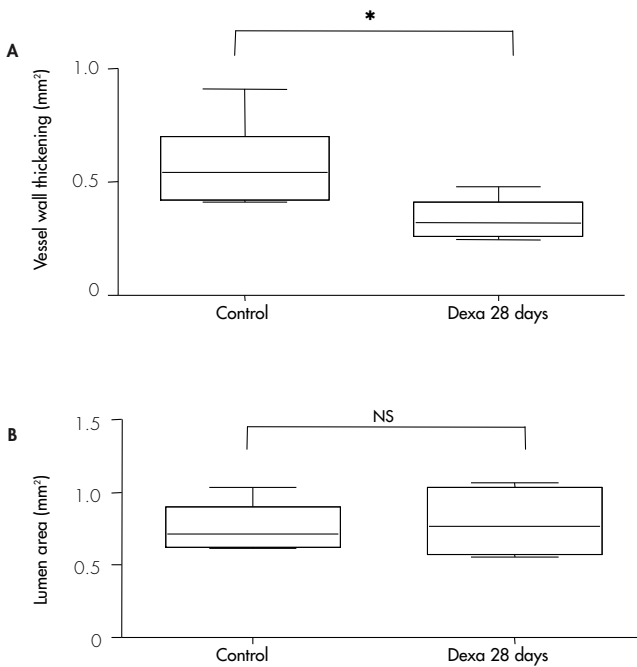


Figure 3.4: Effect of IL10 on relative SMC and macrophage content of medial and intimal areas. *Representative cross-sections of cuffed femoral arteries of both, IL10 knock-out and IL10 overexpression experiments, immunohistochemically stained for smooth muscle cells (antiSM α -Actin) and macrophages (AIA31240). Magnification 200x.*



LEGENDS CHAPTER 4

Figure 4.1: Dexamethasone treatment (0.15mg/kg/day in drinking water) reduces vein graft thickening in hypercholesterolemic ApoE3-Leiden mice after 28 days of treatment. Panel A: Quantification of vein graft thickening shows a reduction of 43% in the dexamethasone-treated animals, as compared to controls (n=6, * represents $P < .05$), whereas no significant changes in luminal area were observed (Panel B). Panel C: Representative cross-section, arrows indicate thickened vessel wall (HPS staining, magnification 40x). No differences are seen in the cellular composition of thickened grafts in both groups, as determined by computer-assisted morphometric analysis. Panel D: α -SM-actin staining representing vascular SMC. Panel E: AIA31240 staining representing macrophages.



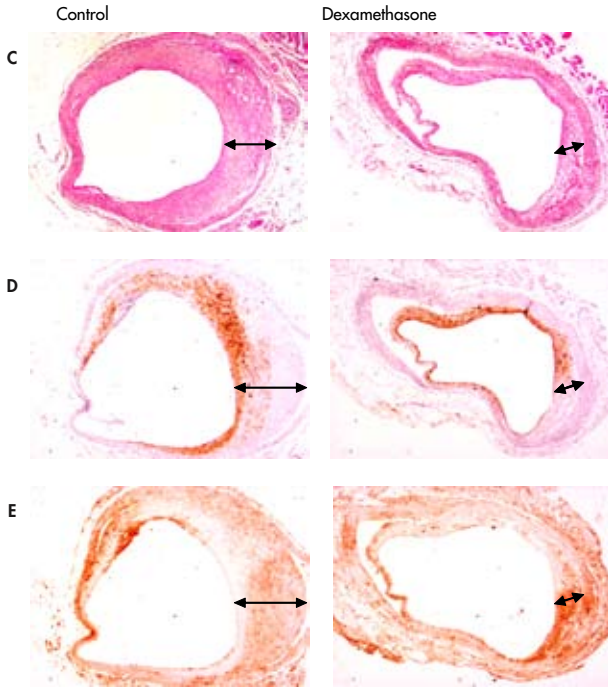
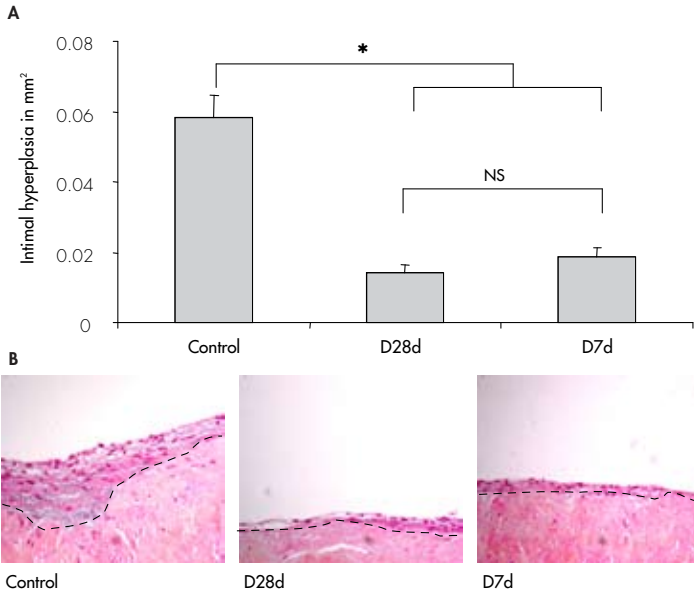
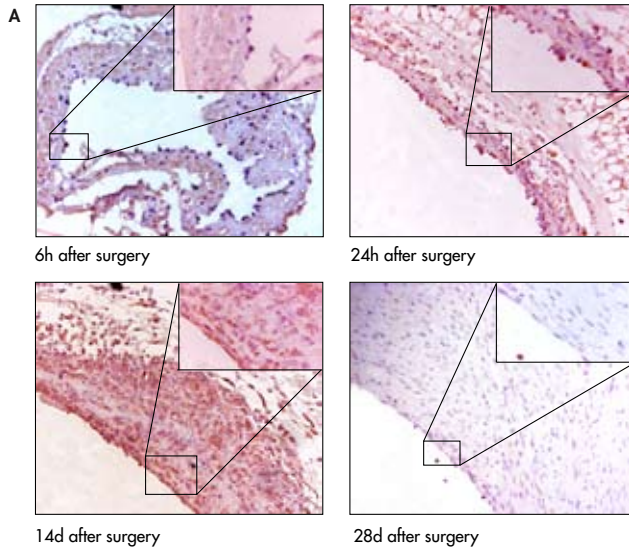


Figure 4.4: Effect of either short-term (D7d) or prolonged (D28d) dexamethasone exposure (0.75mg/ml medium) in IH formation in human saphenous vein organ cultures (n=12 per group). In both dexamethasone exposed groups a significantly lowered amount of IH was seen, when compared to the control segments (* represents $P < .05$, magnification 100x, dotted line indicates border separating media from intima).



LEGENDS CHAPTER 5

Figure 5.1: Panel A shows representative cross-sections of murine vein grafts harvested after several time points. MCP-1 expression in vein grafts identified by immunohistochemistry was seen mainly in endothelial cells, adhering monocytes and in the infiltrating cells of the developing IH. Inserts indicate adhering monocytes expressing MCP-1 (6h and 24h) and MCP-1 expression in the developing IH (14d).



Panel B represents the immunohistochemical detection of MCP-1 in cultured human saphenous veins. MCP-1 is abundantly present in the media at early time points and predominantly in IH at later time points after 14 and 28 days. Inserts indicate MCP-1 expressing endothelium and SMC (directly after excision and 24h) and MCP-1 expression in IH (28d). Magnification of all pictures 150-600x.

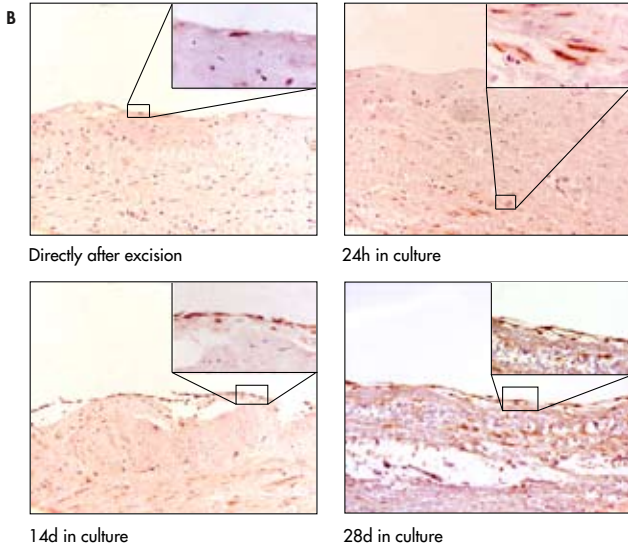


Figure 5.2: Effect of 7ND-MCP-1 gene-transfer on development of IH in murine vein grafts. Panel A: Significantly reduced IH surface is seen in the 7ND-MCP-1-treated group ($n=6$ per group, $p<0.05$). Panel B: Immunohistochemical staining for macrophages and smooth muscle cells. No differences in cellular composition of the lesions were observed (* represents $p<0.05$).

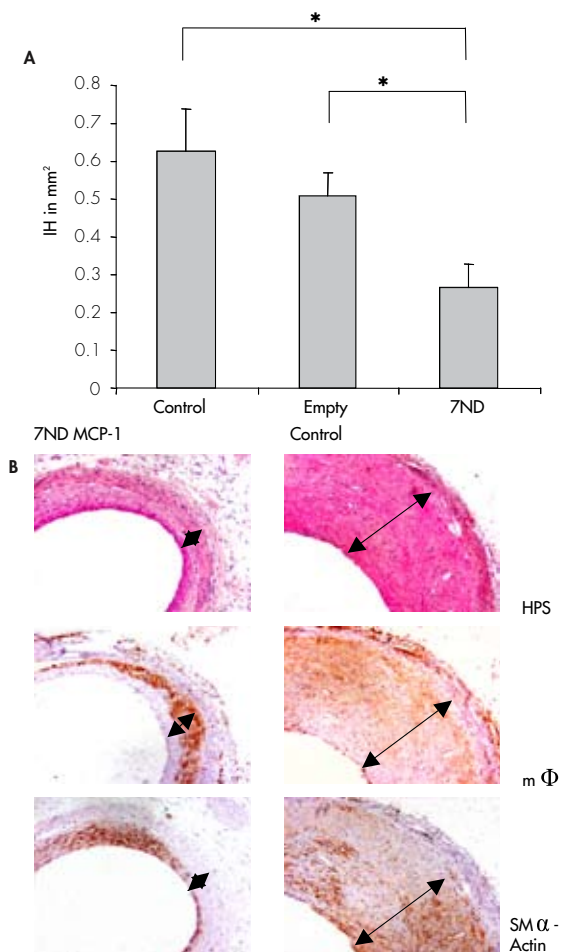
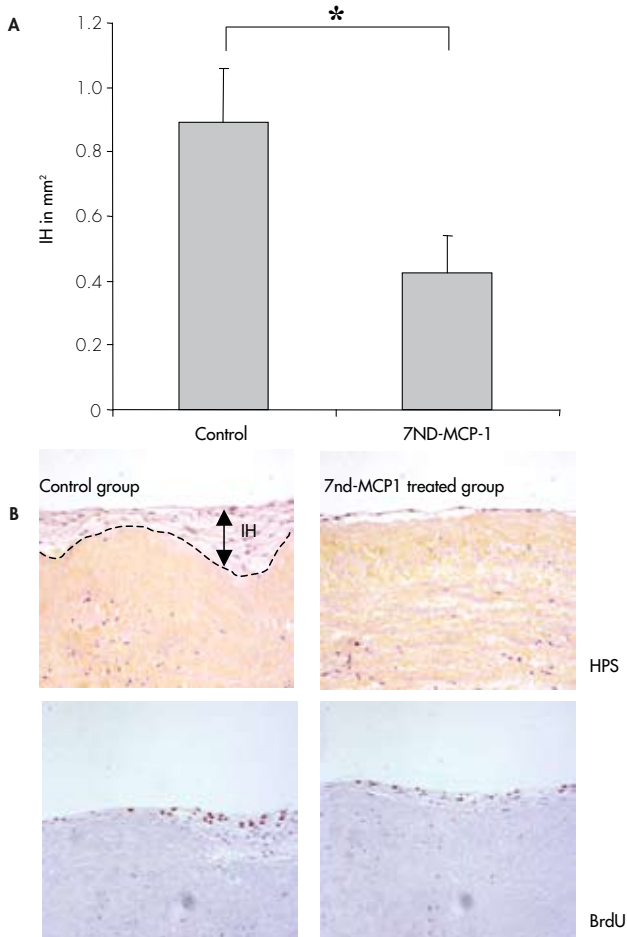


Figure 5.3: Effect of 7ND-MCP-1 on IH in HSV 28 days in culture. Panel A: Reduction in IH ($n=12$ per group) when exposed to conditioned medium containing 7ND-MCP-1 (* represents $p<0.05$). Panel B: Representative cross section of HSV, strong reduction in both IH surface and BrdU-positive cells can be detected.



LEGENDS CHAPTER 6

Figure 6.1: Expression of MIP-1 α and RANTES in remodeling vein grafts as shown by immunohistochemistry. Panel A shows MIP-1 α - expression in the adhering leucocytes 1 day after engraftment, and presence of MIP-1 α in the thickened vessel wall at later time points. Panel B depicts RANTES presence in the vein graft wall at the early time-points. In the later stages of vein graft thickening diffuse distribution is seen in the intimal hyperplasia but predominantly in the adventitia of the vein grafts. (n=3 per time-point, magnification 125-300x, * represents lumen, arrow indicates vessel wall thickening).

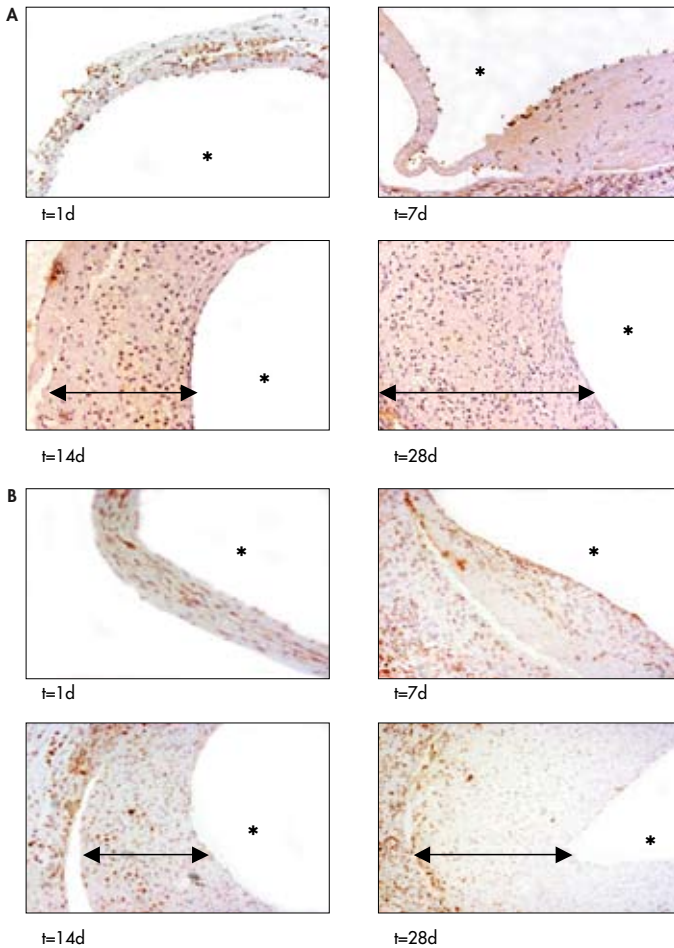
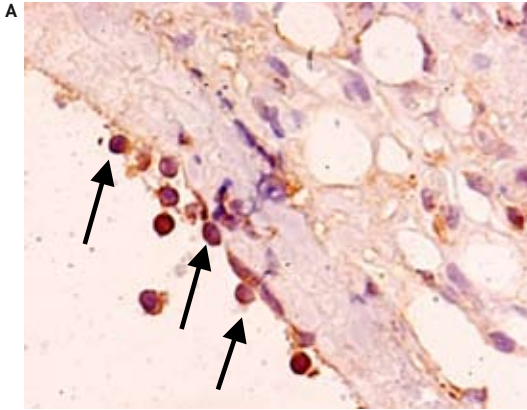


Figure 6.3: Panel A: Representative picture showing adhering AIA31240 positive cells (some are indicated by arrows; magnification 400x).



Panel B: Number of adhering AIA31240 positive cells (monocytes) 3 days after engraftment in Met-RANTES-treated and control vein grafts (analysis by immunohistochemistry, $n=8$ per group, at least 6 cross-sections per mice were analyzed). Data are expressed as mean \pm SEM.

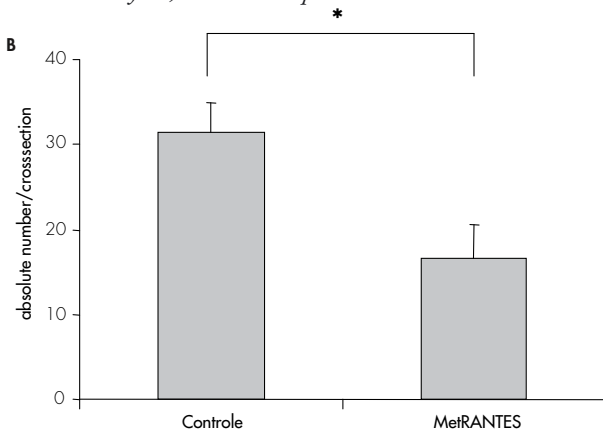
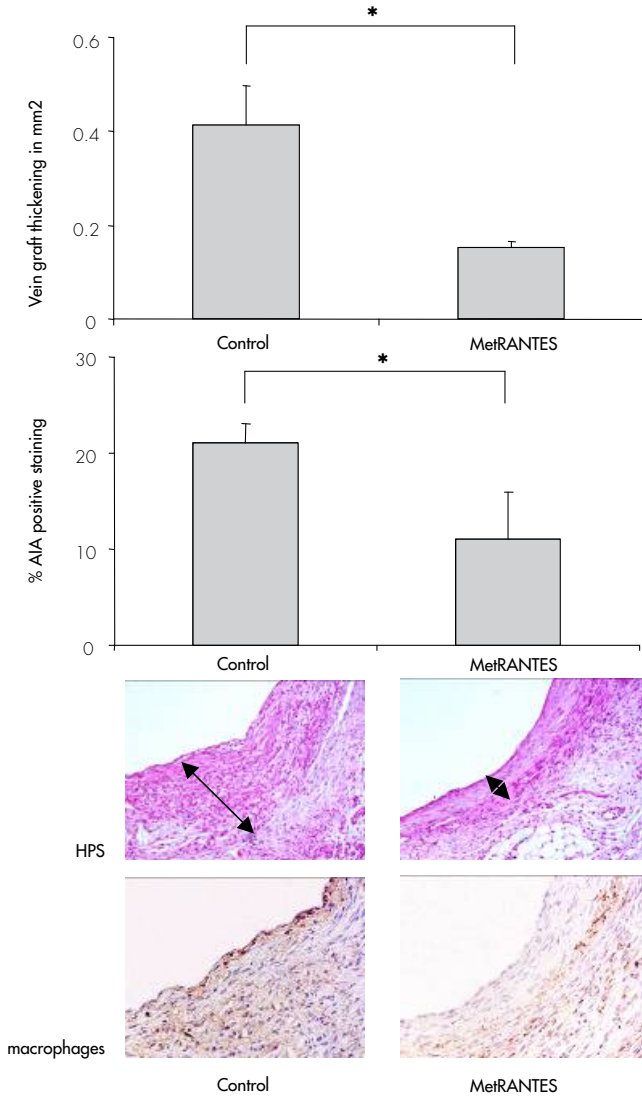


Figure 6.4: Effect of Met-RANTES on vein graft thickening and plaque composition (n=8 per group). Panel A displays the quantified data of both vein graft thickening and macrophage content of the plaque as defined by percentage of staining positive for AIA31240. Panel B shows representative pictures of HPS and AIA 31240 staining (magnification 200x, arrows indicate thickened vein graft wall).



LEGENDS CHAPTER 7

Figure 7.1: Expression of complement factors in thickened murine vein graft of ApoE3Leiden mice, 28 days after surgery. Massive intima hyperplasia formation vein graft thickening is observed, as indicated with arrows (HPS). The cellular composition (consisting of smooth muscle cells and macrophage-derived foam cells) of the thickened vein graft is shown. Immunohistochemical detection of complement factors C1q, C3 and C9. Both C1q and C3 are abundantly present in the deeper parts of the intimal hyperplasia co-localizing with foam cells. Furthermore, C1q and C3 are expressed in the endothelial layer and in inflammatory cells (mainly macrophages) adhering to the vessel wall and present in the adventitia. C9 is not detectable in the endothelium and inflammatory cells. However, like C1q and C3, it is present in the deeper parts of the intimal hyperplasia.

Regulatory enzymes CD59 and Crry in vein grafts demonstrate a different expression pattern. CD59 shows a diffuse expression throughout the thickened vein graft, whereas expression of the membrane-bound Crry shows a patchy, cell bound distribution, and is mainly localized in the media and adventitia of the murine vein graft. Magnification of all pictures 150x.

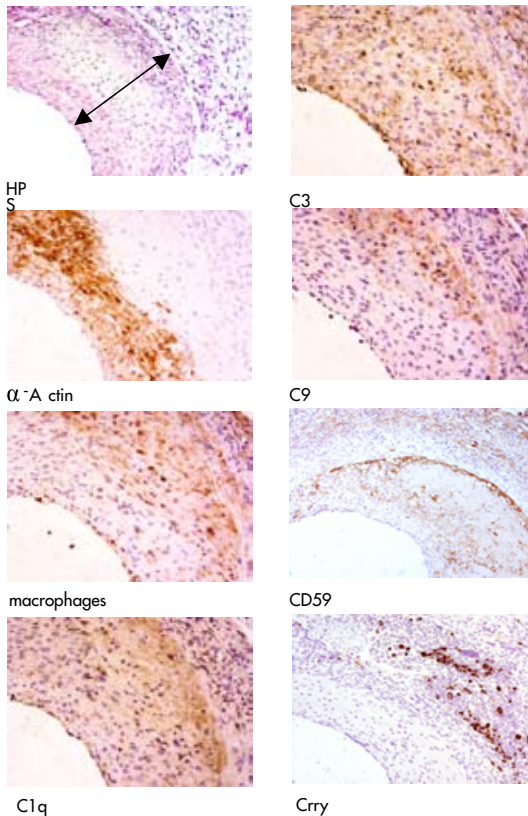
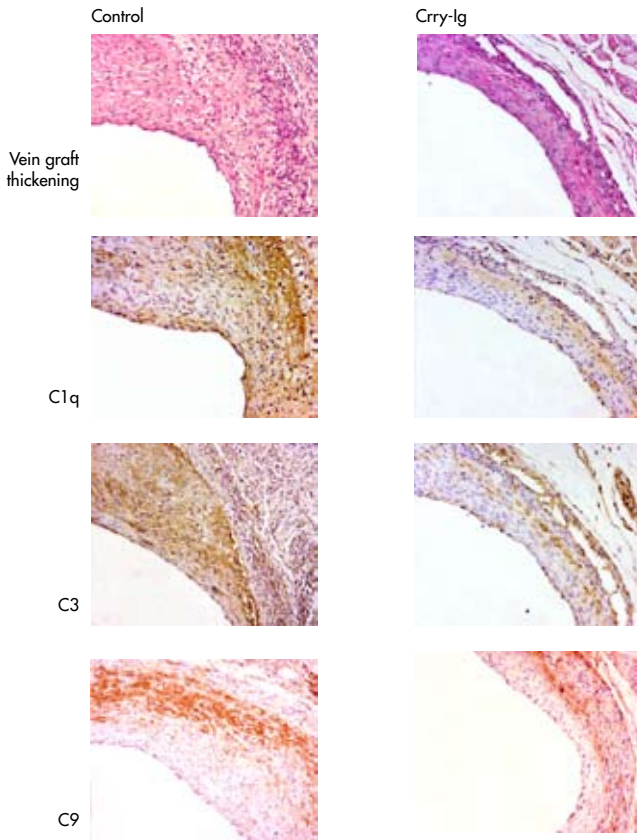


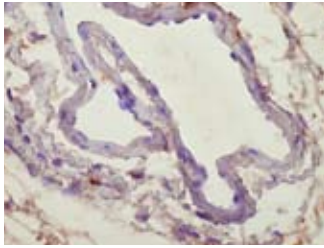
Figure 7.3: Effect of Crry-Ig treatment on development of intimal hyperplasia and accelerated atherosclerosis in murine vein grafts. Quantitative analysis of the effect of Crry-Ig treatment on development of intimal hyperplasia and accelerated atherosclerosis in murine vein grafts and C1q, C3 and C9 deposition in the vein grafts.



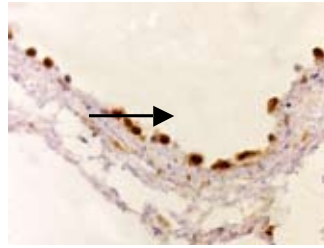
Representative cross section demonstrating reduced vein graft thickening, similar amounts of C1q deposition, and reduced C3 and C9 deposition (magnification 150x).

LEGENDS CHAPTER 8

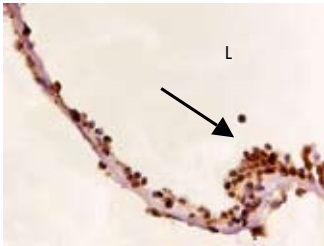Figure 8.1: *Detection of C5 in time in venous bypass grafts by immunohistochemistry. As soon as 6 hours after surgery, presence of C5 is seen in adhering leucocytes (appointed by arrows). Highest amounts of C5 are seen 3 to 7 days after surgery, and C5 remains present in later time-points predominantly in endothelial cells, foam cells and adventitial fibroblasts (magnification 150x (28d)-400x (6h)).*



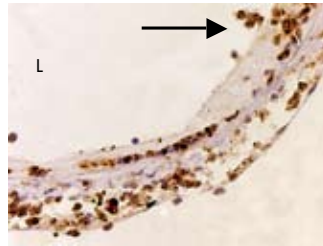
Normal caval vein



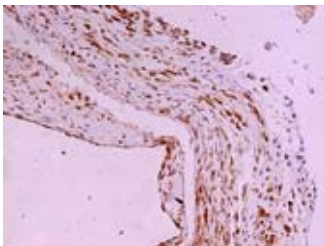
6h



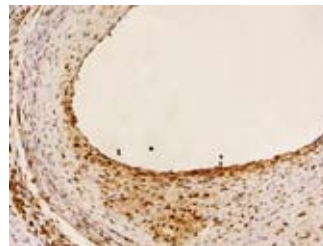
24h



3d



14d



28d

Figure 8.3: Effect of C5a recombinant protein application to vein grafts of hypercholesterolemic mice. Representative cross-sections of vein grafts exposed to either 20% PG and 20% PG containing 0.5 μ and 5 μ C5a recombinant protein (panel A, HPS staining). A dose-dependent increase in vein graft thickening was seen in the C5a-treated mice (panel B) (0.5 μ : $p=0.1$, 5 μ : $p=0.002$; arrows indicate vessel wall surface, magnification 200x).

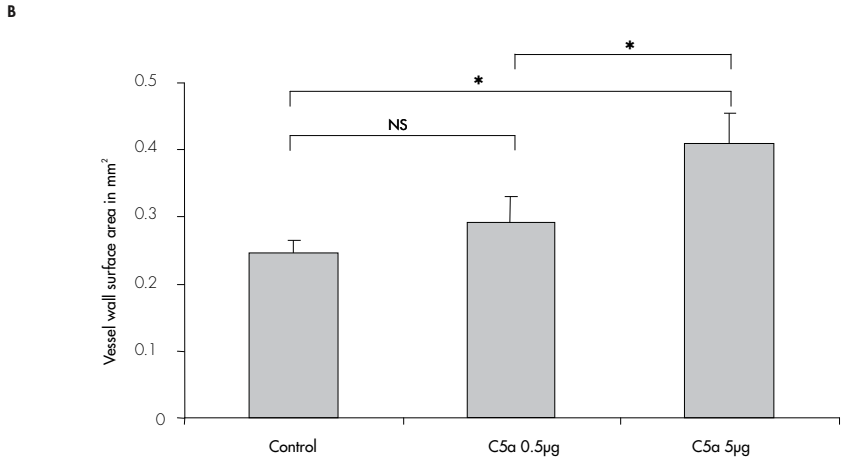
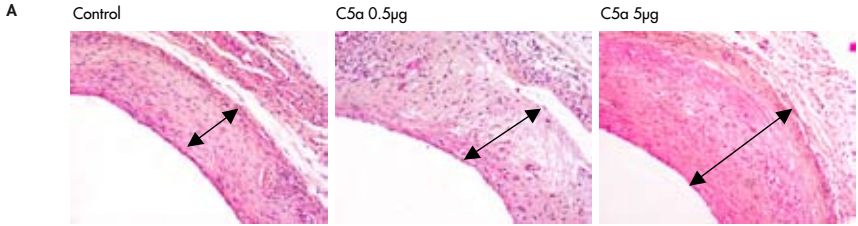


Figure 8.4: Effect of C5a application to vein grafts on foam cell contribution in lesion. Increased exposure to C5a results in a significant increase in foam cell contribution in the lesions (panel B). Panel A displays representative cross sections of immunohistochemistry using antibodies against macrophage derived foam cells, whereas arrows indicate positive staining against monocytes/foam cell (0.5µg: $p=0.1$, 5µg: $p<0.001$; magnification 200x).

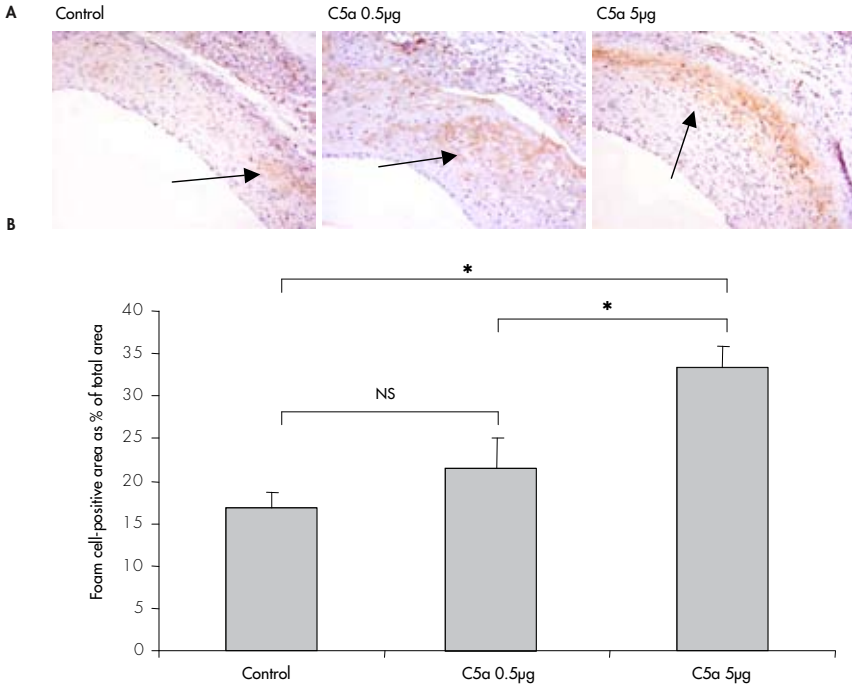
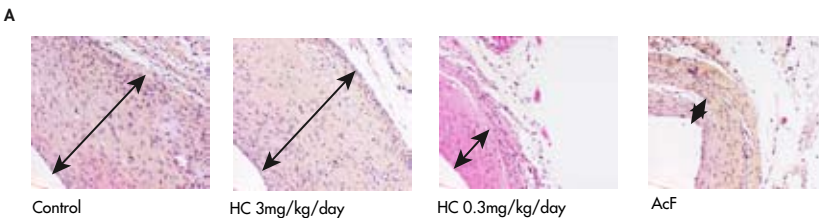
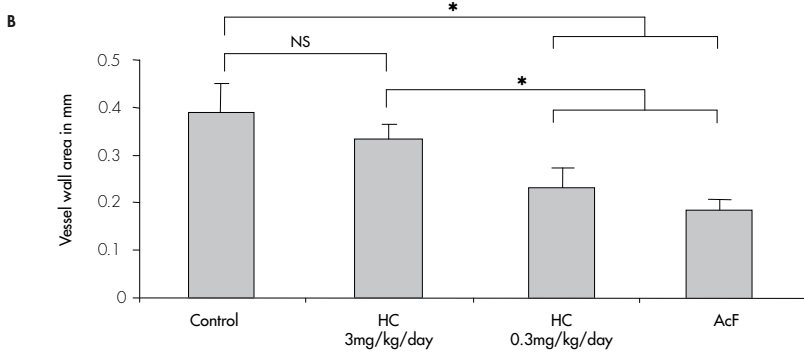


Figure 8.5: Effect of treatment with C5a receptor antagonists, HC and AcF. Panel A: Representative cross sections of control and treated vein grafts 28 days after surgery; a decrease in vein graft thickening is seen in the AcF and HC 0.3mg/kg/day treated groups (HPS staining, magnification 200x).



*Panel B: Quantification of vessel wall surface in mm² control and treated vein grafts 28 days after surgery (n=7 per group, *represents p<0.05); C5aRA treatment results in decrease in vein graft thickening 28 days after surgery.*



*Panel C: Quantification of macrophages-derived foam cells contribution in the vessel wall by immunohistochemistry, described as percentage of total vessel wall surface; treatment with C5aRA results in a decrease in foam cell content in the vessel wall (n=7 per group, *represents p<0.05).*

