



Universiteit
Leiden
The Netherlands

Vasectomy and vasectomy reversal : development of newly designed nonabsorbable polymeric stent for reconstructing the vas deferens

Vrijhof, Henricus Joesphus Elisabeth Johannes

Citation

Vrijhof, H. J. E. J. (2006, November 2). *Vasectomy and vasectomy reversal : development of newly designed nonabsorbable polymeric stent for reconstructing the vas deferens*. Retrieved from <https://hdl.handle.net/1887/4964>

Version: Corrected Publisher's Version

License: [Licence agreement concerning inclusion of doctoral thesis in the Institutional Repository of the University of Leiden](#)

Downloaded from: <https://hdl.handle.net/1887/4964>

Note: To cite this publication please use the final published version (if applicable).

Chapter 8

New nonabsorbable stent versus a microsurgical procedure for vasectomy reversal: evaluating tissue reactions at the anastomosis in rabbits.

Eric J. Vrijhof ^a, Adriaan de Bruine^b, Aeilko Zwinderman ^c, August. A.B. Lycklama à Nijeholt^d, and Leo Koole ^e

Department of Urology, Catharina Hospital, Eindhoven, The Netherlands ^a

Department of Pathology, University Hospital of Maastricht, Maastricht, The Netherlands ^b

Department of Medical Statistics, University of Leiden, Leiden, The Netherlands ^c

Department of Urology, Leiden University Medical Centre, Leiden, The Netherlands ^d

Centre for Biomaterials Research, University of Maastricht, Maastricht, The Netherlands ^e

Introduction

Several factors influence the clinical result of a vasovasostomy, including surgical technique, antisperm-antibodies, long-term high intravasal and epididymal pressure after vasectomy, and the obstruction interval between the vasectomy and reversal ¹⁻³.

Moreover, complications can occur locally in the anastomosis area, such as the development of scar tissue and granuloma formation. These reactions are mostly due to traction and/or devascularization of the vas wall, eventually leading to sperm leakage which compromises the anastomosis ⁴. Several weeks to months after the reversal procedure, stricturing in the anastomosis area can develop, resulting in a partial or complete stenosis. Initial patency will be compromised due to this stricturing. Several studies indicate that a large proportion of vasovasostomy failures are the result of inadequate sperm passage and/or testicular/epididymal tissue damage. Most of the sperm in the ejaculate passes from the epididymis to the vesicles at the time of the intercourse ⁵. As a result, a poor anastomosis will have a deleterious effect on fertility ^{4,6}. Because of this risk of obstruction, but also because of the time required for a microsurgical anastomosis, we started to develop a technique with a hollow non-absorbable polymeric stent.

The use of this hydrophilic stent, with autodilating capacity, could theoretically help to prevent the secondary stricturing of the anastomosis area. It was assumed that narrowing of the anastomosis by fibrosis would be prevented because of the solid structure of the stent. Local sperm leakage could be prevented by the use of an intraluminal stent covering the anastomosis. A very important issue in favor of using a stent is proven inertness of the biomaterial stent, limiting inflammatory reaction in the vas wall that would probably impair patency. Because of the permanent position of the implanted stent, any intraluminal migration would expose the anastomotic site leading to possible secondary stricturing. To prevent this,

the stent was constructed with a central ridge to avoid migration.

The aim of this study was to examine the histological consequences of a stented vasovasostomy at the site of the anastomosis. Because we performed an immediate reconstruction after transection, we did not examine the effect of a prolonged obstruction on the tissue of testes and epididymi. We studied the testicular and epididymal tissues for possible tissue changes in those rabbits with partially or fully obstructed vas deferens at the time that they were sacrificed either in the stented group or in the conventional group.

The microscopical reconstruction was performed using a single layer anastomosis so that operating time would be reduced considerably compared to a two-layer anastomosis. The beneficial effect of a two-layer anastomosis over a one-layer anastomosis is still under discussion ^{7,8}. Finally, the histologic results were correlated with the clinical semen outcomes.

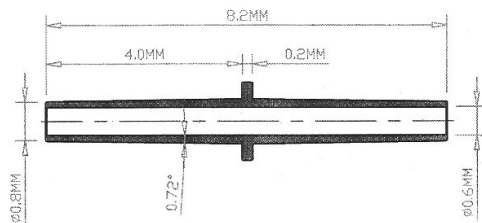

Materials and Methods

We used a total of 30 New Zealand White rabbits for this study. All animal experiments were conducted according to the Principles of Laboratory Animals Care (prepared by the National Institutes of Health, NIH Pub. No. 85-23 rev. 1995). These rabbits (age ranging between 1/2 to 1 year) were chosen because of their easily accessible vas deferens, situated in a stretched prepubic area. Proven patency was a condition for being admitted to this study.

Two rabbits acted as normal controls and 28 rabbits were included in a randomized comparative study between the conventional microsurgical procedure and the vasovasostomy using the newly developed biocompatible hollow stent. During follow-up two rabbits died soon after the operation; one because of pneumonia and the other of a gastric hair ball. Eventually, 26 rabbits (13 stents and 13 microscopically sutured) were available for examination.

The stent itself consists of biocompatible material and has several physical characteristics to simplify the insertion into the vas. In the dry state the stent has certain stiffness and is conically shaped at both ends to facilitate the introduction. After 1 to 2 minutes it starts to absorb seminal en serous fluids. This initiates swelling of the stent which then becomes more flexible. There is a transverse ridge in the middle part of the stent to prevent the stent from migrating from its original anastomosis area (fig 1).

Fig 1. Configurations and measurements of the polymeric stent.



The stent was constructed of n-vinylpyrrolidone, n-butylmethacrylate, and the bifunctional cross-linking agent tetraethyleneglycol dimethacrylate. These reactive substances were polymerized using 2,2'-azobisisobutyronitrile (AIBN) as the radical initiator. The stent thus comprises a hydrophilic and a hydrophobic component in a 2:3 molar ratio. The hydrophilic component of biocompatible material provides the rubbery characteristics of the material after insertion into the vas deferens.

Ketamine 0.5 mL/kg and xylazine 0.5 mL/kg were injected IM to induce anaesthesia; anaesthesia was maintained by a mixture of ketamine/xylazine (2:1) 0.2 mL/30 min. IV throughout the operation. The rabbit was placed in a supine position and a transverse skin incision was made over both spermatic funiculi. The spermatic internal fascia was opened and the vas deferens, lying loose and next to the funiculus, was easily exposed leaving the scrotal contents in situ. The vas was cut transversally and reconstructed immediately. The animals were randomized either for bilateral microscopical reconstruction with 4 to 5 one-layer prolene 8-0 sutures or for placement of stents bilaterally. Both vas ends were approximated with three 8-0 prolene sutures overlying the stent. The vas was repositioned underneath the funiculus and the spermatic internal fascia and overlying skin were closed with 4.0 vicryl. During the postoperative period the animals obtained buprenorfin 0.1 mL/kg IM for a maximum of 48 hours.

Semen for semen analysis was obtained 3-4 days before the operation. After the operation at least 4 to 5 semen samples were taken per animal with time intervals of 7-10 weeks. For collection of semen, an artificial vagina system was used, which is normally applied in agricultural artificial insemination stations for rabbits. Sperm parameters that were collected were: total sperm count (mil/ml), average motility (%) and progressive motile sperm density (PMSD; mil/ml).

Histological examinations were performed on the rabbits, including the two normal rabbits that acted as normal controls. The autopsies were performed shortly after taking the final semen sample. Histological sections in the stented group were taken at an average of 41 weeks (39-44) after the initial operation versus 42 weeks (40-47) in the conventional group. The vasa deferentia, the testes, and the epididymi were excised and fixed in neutral buffered 4% formalin and paraffin embedded for further sectioning. Multiple tissue segments of each vas deferens were taken: one from the anastomosis area (stent or conventional) and four segments immediately proximal and distal to the anastomosis. Two to three samples were taken from the testes and epididymi for evaluation of histological changes after both procedures. All samples were cut at 4µm thickness, and slides were stained with hemotoxylin/eosin and were microscopically examined by the same pathologist.

Results

Morphologic findings in stented rabbits:

During excision of the anastomotic areas, for further histological examination, minimal adhesions of the anastomosis site were seen with its surrounding tissue. In one case there was a migration of the stent. The stent was found 2 cm more distally and proved to be patent. Microscopy showed that the stented rabbits all had patent vasa on either side of the implant, without any signs of complete or partial stenosis. After extensive examination two groups of stented animals could be distinguished (fig 2);

- The first group of 11 stented rabbits showed a very similar histological pattern among all cases at the site of the stent. A minor subepithelial inflammatory reaction within the vas wall, adjacent to the stent, was noted. This reaction consisted mainly of

eosinophilic granulocytes, incidental macrophages, and in one case histiocytes. The mainly eosinophilic infiltrate did not appear to lead to destruction of the stent or invasion of the vas wall. The testes and epididymi appeared to be normal and all the transverse sections through the stent demonstrated patency.

- The second group consisted of two rabbits. One had a major transmural histiocytic reaction to the stent and the other presented with severe eosinophilic infiltration involving the epithelium, resulting in epithelial destruction and atrophy. In both cases the testes and epididymi appeared to be normal.

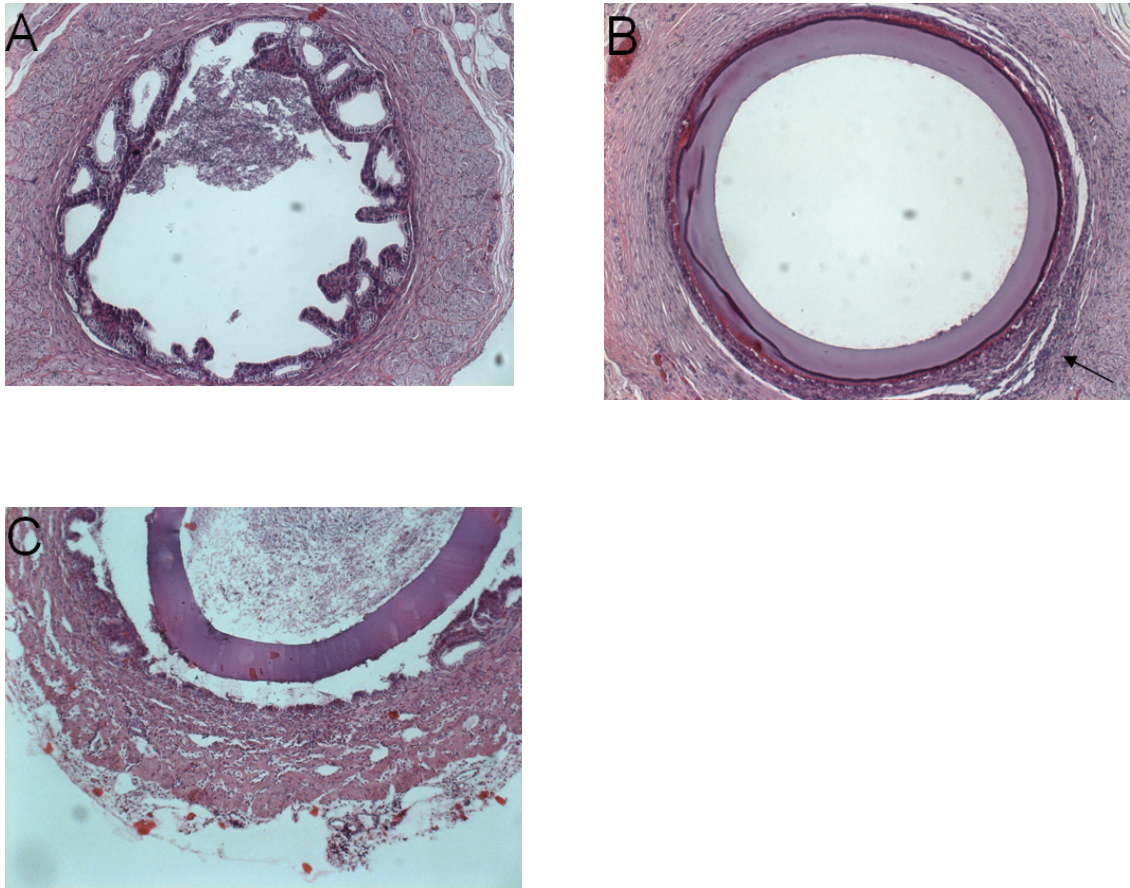


Fig 2. Hematoxylin & eosin stained sections through vas deferens of sten- reconstructed animals at the anastomosis area.

A: transverse section through normal vas deferens away from the stent area.

B: stent lying adjacent to the vas wall with epithelial flattening and the presence of paraluminal eosinophilic reaction (arrow).

C: detailed section of a severe histiocytic transmural reaction.

Morphologic findings in the microscopically sutured rabbits:

Surgical excision of the anastomosis area subjectively revealed more adhesions compared to the stent group. All the anastomoses were patent, as proven by the finding that all transverse sections of the vas distal to the anastomosis contained sperm cells. Remarkable was the fairly large number of partial obstructions in this group. We divided these rabbits in two groups (fig 3).

- The first group consisted of eight rabbits that presented with normal anastomotic site and normal vas diameters. Histologically, complete recovery of the epithelial layers was found without stricturing of the anastomosis. Except for one rabbit, who developed chronic epididymitis with lymphocytic infiltrates, all the testes and epididymi tissue segments appeared normal with no distension of the tubules compared to normal controls. The tubules were fully filled with sperm.
- The second group of five rabbits presented with partial obstruction. Transmural infiltration of lymphocytes and histiocytes was seen, resulting in fibrotic reaction with collagen dispositions and stricturing. Severe foreign body reactions were seen at the site of the sutures. Despite these partial obstructions, the parenchyma of testes and epididymi appeared normal.

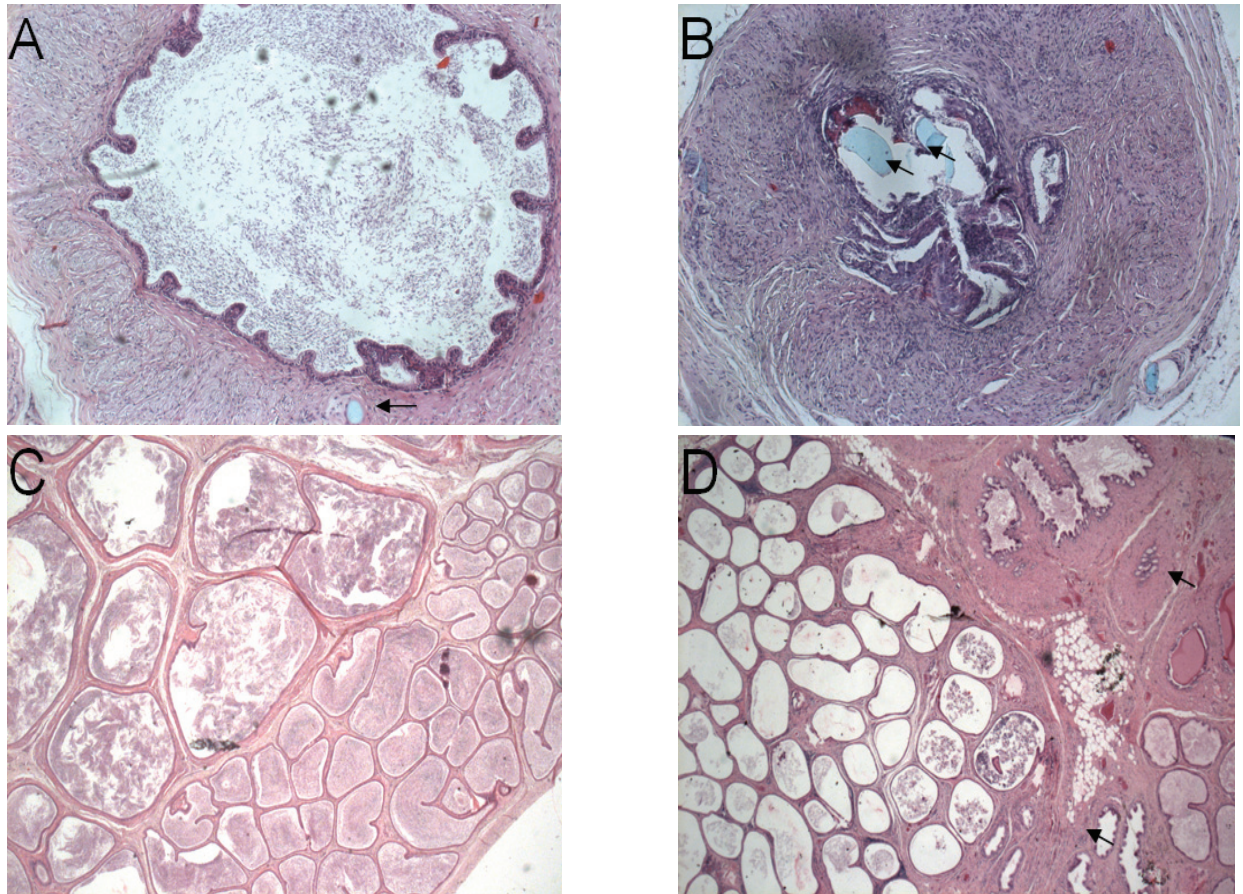


Fig 3. Various histologic sections of vas deferens and epididymis in conventionally microscopically reconstructed animals using 8.0 prolene sutures.

- A: normal anastomoses with no stricturing and complete recovery of epithelial layer; remnants of prolene sutures are seen (arrow).*
- B: severe stenosis with paraluminal fibrotic reactions and intraluminal remnants of prolene sutures (arrows).*
- C: normal epididymis, tubules filled with sperm cells.*
- D: chronic epididymitis with histiocytes, lymphocytes and edema showing thickening of intertubular stromal spaces (arrows).*

Morphologic findings in relation to clinical outcome after vasovasostomy:

All the vasa were patent in both the stent group and the conventional group. All the animals underwent a preoperative semen analysis to prove their patency. The 26 animals treated, provided 141 semen specimens (26 presurgery and 115 postsurgery). The specimens were taken at regular intervals from 2 weeks to 47 weeks after surgery. Mean, median, minimum, maximum and standard deviation levels were measured for total sperm count, motility and progressive motile sperm density (PMSD) in both groups. Following surgery, there was a statistically significant difference between conventionally and stent-treated animals with respect to the total sperm count ($p=0.050$, linear regression analysis with random effects). The average total sperm count or concentration increased in both groups, but more so in the stent group. When calculating the average postsurgery motility per animal, we initially observed a decrease in motility which later on improved. Overall no statistical significant difference in motility between the conventionally and stent-treated animals was noted ($p=0.11$, non-linear regression with random effects). This same course was seen for the average PMSD concentrations, again showing no statistical differences between the two groups ($p=0.71$, non-linear regression with random effects).

Discussion

Influence of partial or total anastomotic obstruction after vasectomy reversal.

Surgeons are aware of the fact that secondary stricturing of the anastomosis is detrimental for patency rates. In searching Pubmed for this subject (1980-2004) only a limited number of articles are found discussing this problem. Carbone et al ⁴ described the role of partial obstruction causing infertility after vasovasostomy. It is a general believe that persistent infertility after vasectomy reversal is highly attributed to the presence of antisperm antibodies. In this study 20 patients obtained a vasectomy reversal, 14 of them were believed to have a partial obstruction based on mild to moderate epididymal fullness by palpation. All the patients had a significant binding of antisperm antibodies to the sperm surface. These 14 patients underwent a repeat vasectomy reversal and revealed markedly improved semen motility (mean of 4.4% to a mean of 52.3%). Sperm concentration levels increased from 17.1 to $35.8 \times 10^6/\text{ml}$. The overall antisperm antibodies binding did not change after re-vasovasostomy. These results led to the conclusion that the poor sperm quality after the first vasectomy reversal was mainly the result of partial obstruction and not the mere presence of antisperm antibodies. Royle and Hendry ⁹ explored the scrota of 32 men who had a failed vasectomy reversal resulting in azoospermia or extreme oligozoospermia. Of 23 men who had azoospermia 12 patients had a completely blocked anastomosis. After repeat vasovasostomy normal sperm counts were produced in 10 of the 12 patients.

The importance of total or partial obstruction after vasectomy reversal was also highlighted in several other studies. The main message of all these studies was that microsurgical vas reconstruction following failed vasectomy reversal, due to total or partial obstruction, is associated with high patency and pregnancy rate at short-term follow-up ¹⁰⁻¹³.

Prevention of total or partial obstruction of the anastomosis is crucial for good patency

rates. Therefore it is of extreme importance that the first reconstruction is technically successful. Stricture of the anastomosis is very often technically difficult to repair frequently forcing a surgeon to perform vasoepididymostomy with less favorable results.

Biodegradable stents versus suture ligatures.

In the literature stents used for vasovasostomy are all biodegradable. The reason for most authors for using such a stent was that a perfect alignment of the vas ends was obtained and possible leakage was prevented. Several studies tried to prove that intraluminal stenting showed less stricture than sutured anastomosis. Flamm et al.¹⁴ presented a study using polyglycolic acid stents in the reconstruction of vas deferens in rats. One side underwent a microscopic conventional sutured reconstruction with interrupted 10-0 Dermalon, and continuity of the collateral vas was restored with an absorbable polyglycolic acid stent. After 6 weeks the stent was degraded and just a slight mucosal inflammation was left. Narrowing of the anastomoses occurred in both groups but was more present in the non-stented group in combination with more perivasal inflammation and late cicatrization, probably due to extravasation of sperm. Flamm et al. pointed out that prevention of sperm leakage at the site of the anastomosis was of importance in preventing secondary stricturing.

Montie et al.¹⁵ also used absorbable material as an intravasal stent. They described the histological effects in dogs in the wall of the vas deferens at the site of the anastomosis. They compared a conventional sutured vasovasostomy (6-0 silk) with intraluminal stents using either 3-0 Dexon (polyglycolic acid synthetic absorbable stent) or 3-0 chromic catgut using different types of approximation sutures. In the silk group, severe granuloma formation and local inflammatory reactions were seen. Minimal intraluminal tissue reaction in the vas wall was seen after reconstruction with an intravasal chromic catgut stent as well as with chromic catgut as approximation sutures.

Nuwaysir et.al.¹⁶ experimented with different materials. They used starch, collagen and polyester as a stent in an animal study. Polyester biodegradable stents demonstrated the best results with 100% patency and rapid absorption within 10-14 days. The anastomosis site showed excellent healing with normal vas epithelium and no stricture. Finally Berger et al.¹⁷ presented a stent study in rats and dogs using a polyglycolic acid absorbable stent. They compared a stented vasovasostomy group with a modified two-layer technique. Scanning electron microscopy showed superior re-epithelialization and normalization of morphology in the stented group.

In all the above-mentioned studies superior healing of the anastomosis was seen with stents compared to suture ligatures.

Why a non-absorbable polymeric stent?

Histological alterations of the vas anastomosis were observed in our study. Especially borderline inflammatory reactions of the vas were seen in the stent group with a subepithelial eosinophilic and histiocytic reaction. In the conventional microsurgical sutured group, more partial obstructions due to severe fibrotic changes in the anastomotic area were noted. The idea of developing a nonabsorbable stent was born from the concept that stricturing at the site of the microsurgical sutured anastomosis was caused by sperm leakage owing to lack of water tightness, eventually leading to sperm granuloma development and cicatrization. This leakage could possibly be prevented by a permanent stent in situ covering the anastomosis.

Our study is the first to investigate a nonabsorbable polymeric stent in the reconstruction of the vas deferens. Despite the fact that slight inflammatory reactions in the vas wall of the stented group were observed, we assume that these minor reactions are less relevant than the fibrotic stricturations occurring from the conventional microscopic one or two layer reconstructions. Absorbable stents are generally not made of inert polymeric biomaterial.

With the dissolving of these absorbable stents the anastomosis area is exposed within several weeks. It is our believe that even after the absorption of the stent the anastomosis area is still at risk of stricturation owing to the fact that the anastomosis area is still biologically active or that the inflammatory respons to resolve the stent, could cause secondary stricturing of the anastomosis. The permanent position of a nonabsorbable biocompatible polymeric stent at the site of the anastomosis could prevent any danger of secondary stricturation and thus provide persistent patency. The development of inert biocompatible materials justifies the consideration of permanent stent implants. Therefore we will continue to investigate this stent in human studies.

References

1. Silber S J. Microscopic vasectomy reversal. *Fertil Steril* 1977; 28: 1191-202.
2. Vrijhof HJEJ, Delaere KPJ. Vasovasostomy results in 66 patients related to obstructive intervals and serum agglutinin titres. *Urol Int* 1994; 53:143-6,
3. Belker AM, Thomas AJ, Fuchs EF, Konnak JW, Sharlip ID. Results of 1,469 microsurgical vasectomy reversals by the Vasovasostomy Study Group. *J Urol* 1991; 145: 505-11.
4. Carbone DJ, Shah A, Thomas A J, Agarwal A.. Partial obstruction, not antisperm antibodies, causing infertility after vasovasostomy. *J Urol* 1998; 159: 827-36.
5. Freund M, Davis JE. Disappearance rate of spermatozoa from the ejaculate following vasectomy. *Fertil Steril* 1969; 20: 163-70.
6. Belker AM. Editorial: Evaluation of partial anastomotic obstruction after vasovasostomy and predictors of success after vasoepididymostomy. *J Urol* 1998; 159: 835-36.
7. Fuse H, Kimura H, Katayama T. Modified one-layer microsurgical vasovasostomy in vasectomized patients. *Int. Urol. Nephrol.* 1995;27: 451-56.
8. Fischer MA, Grantmyre JE. Comparison of a modified one- and two-layer microsurgical vasovasostomy. *BJU Int* 2000; 85:1085-88
9. Royle MG, Hendry WF. Why does vasectomy reversal fail? *BJU Int* 1985; 57: 780-3
10. Hernandez J. Sabanegh ES. Repeat vasectomy reversal after initial failure: overall results and predictors for success. *J Urol* 1999; 161: 1153-56
11. Fox M. Failed vasectomy reversal: is a further attempt using microsurgery worthwhile? *BJU Int.* 2000; 86: 474-8

12. Paick JS, Park JY, Park DW, Park K, Son H, Kim SW. Microsurgical vasovasostomy after failed vasovasostomy. *J Urol* 2003; 169: 1052-55
13. Matthews GJ, McGee KE, Goldstein M. Microsurgical reconstruction following failed vasectomy reversal. *J Urol* 1997; 157: 844-6
14. Flam TA, Roth RA, Silverman ML, Gagne RG. Experimental study of hollow, absorbable polyglycolic acid tube as stent for vasovasostomy. *Urology* 1989; 33: 490-4
15. Montie JE, Stewart BH, Howards SL. Intravasal stents for vasovasostomy in canine subjects. *Fertil Steril* 1973; 24: 877-83
16. Nuwayser ES, Wu TC, Hotchkiss RS, Farcon EE, Hulka JJ, Mohr K, et al. An absorbable artificial vas deferens for vasovasostomy. *Trans Am Soc Artif Intern Organs*. 1975; 21: 523-30
17. Berger RE, Jessen JW, Patton DL, Bardin ED, Burns MW, Chapman WH. Studies of polyglycolic acid hollow self-retaining vasal stent in vasovasostomy. *Fertil Steril* 1989; 51: 504-8

