



Universiteit
Leiden
The Netherlands

Vasectomy and vasectomy reversal : development of newly designed nonabsorbable polymeric stent for reconstructing the vas deferens

Vrijhof, Henricus Joesphus Elisabeth Johannes

Citation

Vrijhof, H. J. E. J. (2006, November 2). *Vasectomy and vasectomy reversal : development of newly designed nonabsorbable polymeric stent for reconstructing the vas deferens*. Retrieved from <https://hdl.handle.net/1887/4964>

Version: Corrected Publisher's Version

License: [Licence agreement concerning inclusion of doctoral thesis in the Institutional Repository of the University of Leiden](#)

Downloaded from: <https://hdl.handle.net/1887/4964>

Note: To cite this publication please use the final published version (if applicable).

Chapter 7

The use of a newly designed nonabsorbable polymeric stent in reconstructing the vas deferens: a feasibility study in New Zealand white rabbits

**H. J. E. J. Vrijhof^a, A. De Bruine^b, A. H. Zwinderman^c, A. A. B. Lycklama à Nijeholt^d,
L. H. Koole^e**

Department of Urology, Catharina Hospital, Eindhoven, The Netherlands^a

Department of Pathology, University Hospital of Maastricht, Maastricht, The Netherlands^b

Department of Medical Statistics, University of Leiden, Leiden, The Netherlands^c

Department of Urology, Leiden University Medical Centre, Leiden, The Netherlands^d

Centre for Biomaterials Research, University of Maastricht, Maastricht, The Netherlands^e

Introduction

The mean operation time for a bilateral microscopical procedure is 2 hours and 30 minutes ¹.

It is generally accepted that the microscopical reconstruction leads to better patency- and pregnancy rates than the macroscopical procedure ²⁻⁴. We use a one-layer anastomosis because the duration of surgery would be considerably less than a two-layer anastomosis and according to several authors a two-layer anastomosis has little if any additional benefit over a one-layer anastomosis ^{5,6}.

Apart from the technical aspects of the procedure, obstruction interval between vasectomy and reversal, and the presence of antisperm antibodies, determine the patency and pregnancy rates ⁷⁻¹². Technical failure of human vas deferens reconstruction mainly occurs several weeks to months after surgery usually as a result of stricturing of the anastomosis. These strictures occur because of granuloma formation, and traction on or devascularization of the vas wall, which eventually leads to sperm leakage. Absorbable hollow stents have been used to simplify the procedure and prevent this sperm leakage. By preventing sperm extravasation, there is less perivasal inflammation, reducing secondary stricturing at the site of the anastomosis. Despite contradictory published results, absorbable stents might have the disadvantage of migrating easily and absorbing rapidly (10-14 days), leading to early denudation of the anastomosis, with possible stricturing. Non-absorbable hollow stents made of inert biomaterial, with a design that prevents migration, might improve patency rates by providing a permanent open lumen at the site of the anastomosis.

To reduce the operative duration and to improve patency rates, we developed an “easy to perform technique” with a newly-designed hollow nonabsorbable polymeric stent. This hydrophilic stent, with auto-dilating capacity, could help to prevent secondary stricturing of the

anastomotic area. The present randomized comparative study between stent and conventional microscopic reconstruction was designed to study the effects of both reconstructive techniques on the anastomosis area and semen quality, so the transected vas deferens was immediately repaired. This eliminated the influence of obstruction time resulting from vasectomy. Thus the purpose of this study was to investigate the use of a newly designed nonabsorbable polymeric stent in the reconstruction of the vas deferens, comparing it to the conventional microscopic reconstruction in a randomized study in rabbits.

Materials and methods

New Zealand White rabbits (32) were used, the experiments being conducted according to the Principles of Laboratory Animals Care (prepared by the National Institutes of Health, NIH Pub. No. 85-23 rev. 1995). Anaesthesia was induced by an intramuscular injection with ketamine 0.5ml/kg and xylazine 0.5 ml/kg, and maintained by an intravenous mixture of ketamine/xylazine (2:1, 0.2ml/30min) during surgery. The rabbit was placed supine and a transverse skin incision made over both spermatic funiculi. The spermatic internal fascia was opened and the vas deferens, lying loose and next to the funiculus, was easily luxated, leaving the scrotal contents *in situ*. The vas deferens was cut transversely and reconstructed immediately. The rabbits were randomized either to microscopic reconstruction with four or five one-layer 8/0 nonabsorbable polypropylene sutures (Prolene, Ethicon Inc., Somerville, NJ) or had stents placed bilaterally, after which both ends of the vas deferens were approximated with three 8/0 Prolene sutures, overlying the stent. Water tightness was checked in both procedures by milking sufficient epididymal contents towards the anastomosis area. The vas deferens was repositioned, and the fascia and overlying skin closed with 4/0 synthetic

absorbable polyglactin suture. After surgery the rabbits received narcotic analgesia (temgesic 0.1 ml/kg) for up to 48 hours.

Semen was obtained before surgery to establish the presence of sperm, and at regular intervals (2-47 weeks) after surgery; at least four semen samples were taken from each rabbit. The semen was collected with an artificial vagina system normally used in agricultural artificial insemination for rabbits. The sperm characteristics consisted of total sperm count, mean motility and progressive motile sperm density (PMSD). After the final semen analysis, the rabbits were killed and patency assessed histologically at the site of the anastomosis.

In the dry state the stent has some stiffness that facilitates its placement. Shortly after introduction, the stent starts to absorb seminal and serous fluids, which alter the mechanical characteristics and make the stent more flexible and elastic. The construction material of the stent was N-vinylpyrrolidone and n-butylmethacrylate, and the bifunctional cross-linking agent was tetraethyleneglycol dimethacrylate. These reactive substances were polymerised using 2,2'-azobisisobutyronitrile as the radical initiator. Thus the stent comprises a hydrophilic biocompatible material containing a hydrophilic and a hydrophobic component, at a molar ratio of 2:3. The hydrophilic component provides the rubbery characteristics of the material after insertion into the vas deferens. To facilitate the rejoining of the two loose ends of the vas deferens over the stent, a specific shape of the stent was developed. The stent is a hollow tube which is conical at both ends, facilitating insertion in the vas deferens ends. The total length of the stent is 8.2mm. The outside diameter, at the site of the central ridge is 1.6mm and the internal diameter is 0.6mm. This ridge, in the middle of the stent, prevents the stent from migrating from its original anastomotic area (fig. 1).

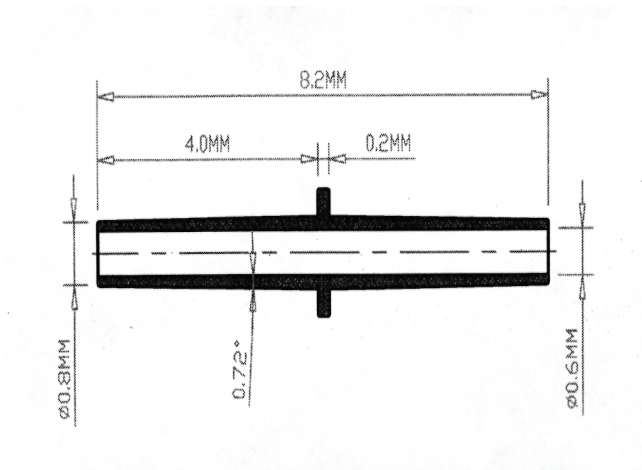
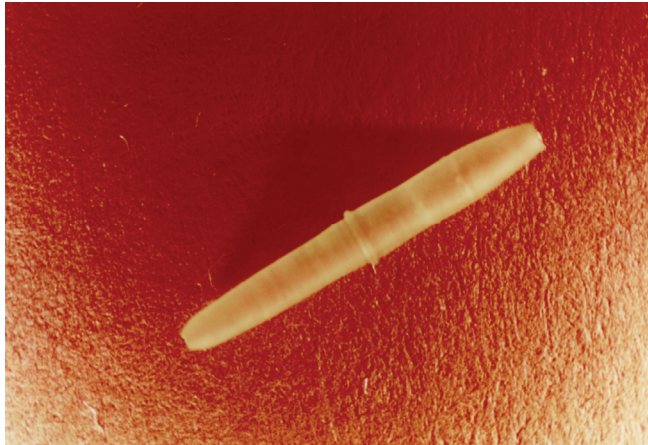


Fig 1. Configuration and dimensions of the polymeric stent

Results

Four rabbits had a vasectomy to evaluate the mean time needed to gain azoospermia in case a reconstruction would lead to a total obstruction. Before sterilization, semen was analysed to establish the presence of sperm in all four rabbits. The semen analysis was repeated after 6-7 weeks and 3 months; all four rabbits were azoospermic at the first semen control and remained azoospermic during follow-up; the rabbits were then killed.

In all, 28 rabbits were used to compare the conventional microscopic reconstructive procedure (“conventional group”) and vasovasostomy using the biocompatible hollow stent (“stent group”). Two rabbits died soon after surgery (pneumonia and gastric hair ball), one in the stent group and the other in the conventional group, so only 26 rabbits (13 stents and 13 conventional) were evaluable. The 26 rabbits provided 141 semen specimens; 26 before surgery and 115 after surgery. To establish whether the polymeric stent allows actual propagation, one rabbit was matched with a female, and after 4 weeks of pregnancy, eight healthy young rabbits were born.

Total sperm count (or concentration):

The total sperm counts before surgery (table1) did not differ significantly between groups (P=0.08, Mann-Whitney U-test). After surgery, there was a significant difference between conventional and stented rabbits in the increased concentrations during the follow-up (P=0.050, linear regression analysis with random effects); the total sperm count increased in both treatment groups, but more in the stent group (fig.2). The mean sperm counts during follow-up did not differ significantly (table 1).

Table1. Sperm analyses before and after conventional one-layer microscopic reconstructions and stented reconstructions of the vas deferens in rabbits

<i>Variable</i>	<i>Stent</i>	<i>Conventional</i>
<i>Mean (median,range) [SD]</i>		
<i>Before surgery</i>		
<i>Total sperm count, millions/ml</i>	439 (261, 54-1400) [418]	544 (477,249-88900 [240.6]
<i>Motility %</i>	75 (80, 50-950 [12.9]	68 (75, 20-900 [18.4]
<i>PMSD, millions/ml</i>	164 (81, 0-560) [193.4]	212 (164, 0-556) [180.7]
<i>After surgery</i>		
<i>Total sperm count, millions/ml</i>	459 (445, 114.8-776) [163.9]	450 (437, 270.3-651) [122.8]
<i>Motility %</i>	25 (32, 0.2-51) [18.6]	40 (43, 2.7-70) [17.9]
<i>PMSD, millions/ml</i>	45 (43, 0.2-128) [46.2]	78 (71, 0.1-175) [50.6]

Motility:

The motility measurements before surgery (table 1) did not differ significantly between both groups ($P=0.29$, Mann-Whitney *U*- test). After surgery (table 1), motility decreased during the first 0-12 weeks in both groups ($P<0.001$), but increased significantly thereafter ($P=0.002$). There was no significant difference between groups (fig.2B) in this decrease or increase in the course of motility ($P=0.11$, non-linear regression with random effects).

Progressive motile sperm density (PMSD):

The PMSD before surgery (table 1) did not differ significantly between groups ($p=0.45$, Mann-Whitney *U*-test); after surgery, the PMSD decreased initially ($p=0.002$) followed by a slight but insignificant increase ($p=0.061$). There was no significant difference between conventional and stented rabbits (fig. 2C) in this decrease/increase ($p=0.71$, non-linear regression with random effects)

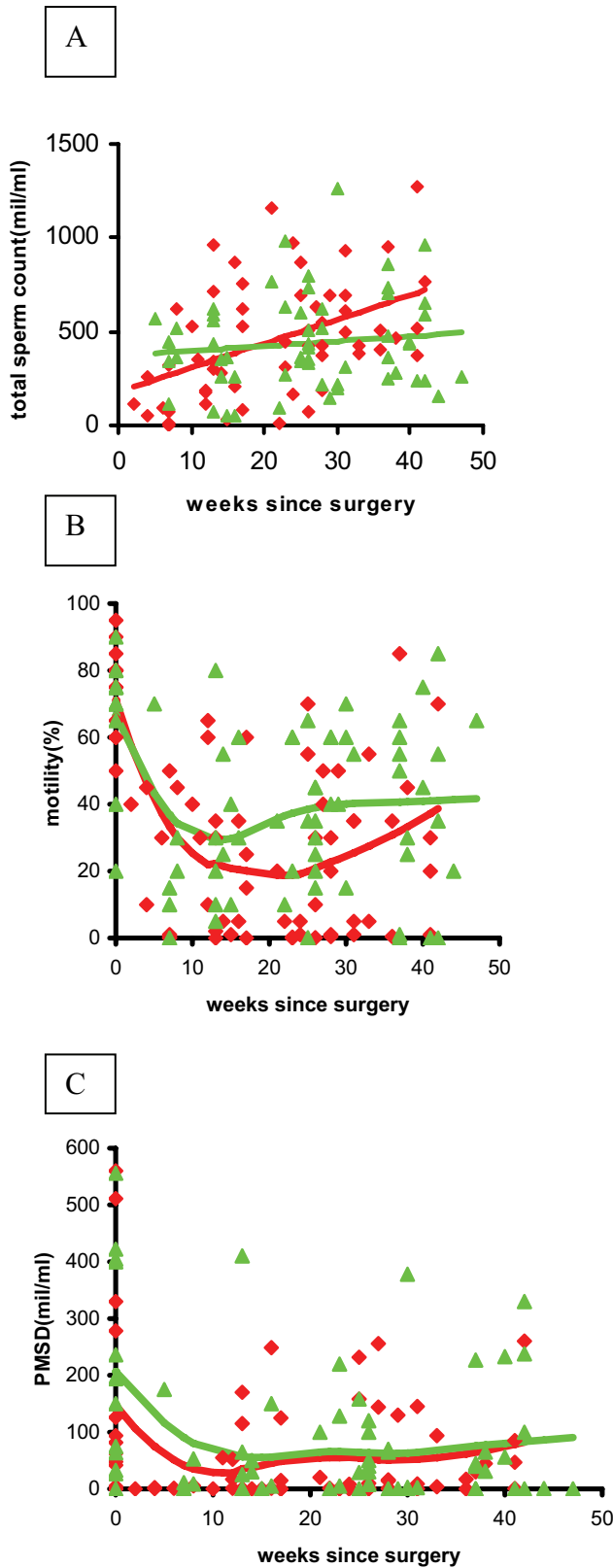


Fig 2. The available **A**, sperm counts; **B**, motility results; and **C**, PMSD results after surgery. The red (stented group) and green (conventional group) lines are regression lines with follow-up time, estimated using random-effect linear regression analysis to account for the correlation between repeated measures in the same animal. In **B** and **C** spline functions were used to estimate the regression lines nonparametrically.

Histological features:

All conventional and stented reconstructed vasovasostomies, were evaluated histologically. Histological sections in the stented group were taken at a mean (range) of 41 (39-44) weeks after the initial operation, vs 42 (40-47) weeks in the conventional group.

In five of 13 conventional reconstructed vasa deferentia there was partial obstruction (>50% narrowing of the original lumen diameter) but with sufficient patency. In the stented group there was no partial or complete obstruction. In all 13 stented rabbits there was flattening and atrophic changes of the epithelium of the vas deferens wall, and eosinophilic inflammatory reaction (fig.3). The atrophy was probably a result of the pressure of the stent wall against the vas deferens wall. All the proximal and distal transverse luminal sections contained sperm cells, showing good patency.

Operation time:

The mean (range) operative duration was 132 (99-168) min in the conventional and 98 (62-113) min in the stented group ($p<0.001$), giving a mean reduction of 34 min.

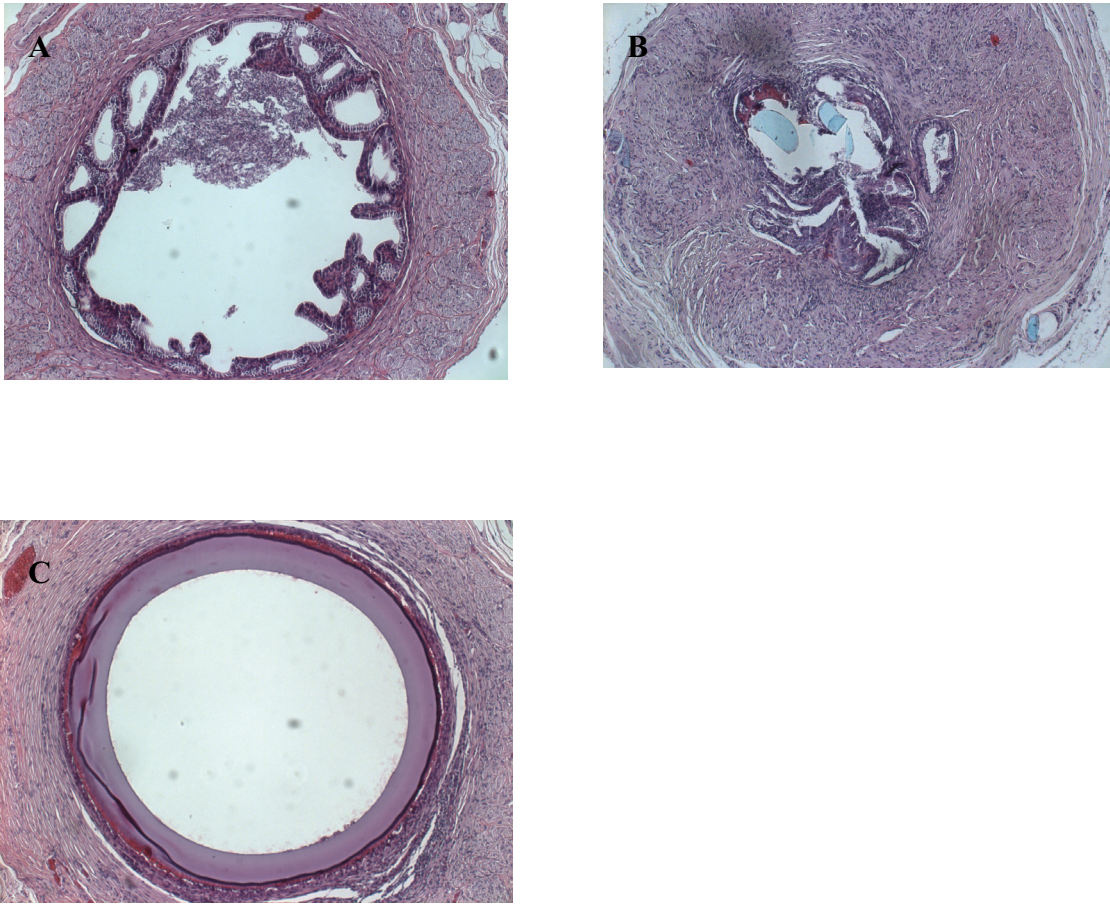


Fig 3. Hematoxylin and eosin-stained transverse sections of rabbit vas deferens in various presentations. **A**, section of a normal vas deferens with wide lumen, containing sperm in the centre. **B**, severe stenosis after a conventional (end-to-end) sutured microscopic reconstruction, note 8/0 Prolene sutures running through anastomosis (light blue remnants). **C**, stent in situ, note the epithelial flattening

Discussion

Temporary exteriorized stents

Most previous studies on exteriorized stents used a temporary stent that was removed after several days or weeks after surgery¹³⁻¹⁵. Temporary stented reconstructions have disadvantages: because the stents are exteriorized they provide a greater risk for sperm leakage and infection; this could lead to sperm granuloma, antisperm antibody formation, vasitis and loss of patency from scar tissue formation.

Absorbable intravasal stents

In the early 1980s more studies were reported using absorbable material as an intravasal stent. Redman¹⁶ used an intraluminal stent of catgut in 20 patients and achieved an overall pregnancy rate of 65%; the successful group included three patients who had a vasectomy >10 years earlier. Montie et. al.¹⁷ reported a study in a dog model; one group had a conventional sutured vasovasostomy with 6/0 silk and another three groups were reconstructed with intraluminal stents using either 3/0 polyglycolic acid or 3/0 chromic catgut, using different types of approximation sutures. The best results were with the chromic catgut stents, and 6/0 catgut sutures for the anastomosis. Silk sutures resulted in severe granuloma formation and should therefore be rejected as a suturing material.

Absorbable hollow stents were created to simplify the procedure and reduce operating time; these created perfect alignment of the vas deferens ends, and after 2-4 weeks most stents were dissolved. Nuwayser et.al.¹⁸ were amongst the first to develop such a stent; they used starch, collagen and polyester as stent materials. The best results were seen in the polyester group, with patency in all 19 samples and rapid absorption at 10-14 days. The histological assessment showed excellent healing at the anastomotic site, with the presence of normal epithelium and

no stricturing. There was plentiful sperm in the lumen, with normal sperm morphology. Flam et.al.¹ used an absorbable hollow polyglycolic acid stent, and described advantages of ease of anastomosis, reduction of perivascular inflammation as a result of minimal extravasation of sperm, maintenance of luminal patency, and satisfactory approximation of the vas deferens ends after placing of the stent. Remarkably, they reported more perivascular inflammation at the anastomotic site of an unstented control group. This sperm leakage and inflammatory reaction could increase the risk of late scarring. Hollow, biflanged, hydrolyzable, self-retaining stents of polyglycolic acid were used by Berger et al.¹⁹ in a randomized prospective comparative study between a stented and a modified two-layer vasovasostomy group in rats and dogs. The outcome suggested better patency rates in the stented group (80% vs 20%).

By contrast Rothman et.al.²⁰ in 1997 reported an extensive prospective randomized study comparing a microscopic two-layer vasovasostomy with an absorbable polyglycolic acid stent in 116 men who had a vasectomy reversal. In all, 64 men had a stented reconstruction and 52 were repaired with a two-layer microscopic reconstruction. Paternity rates were significantly better in the unstented group. A bias in this study was the incomplete follow-up; in many cases only one semen sample was investigated per subject after surgery, and this undermines a well documented comparison of patency rate. Nevertheless, information (by letter, telephone or outpatient visits) on paternity was available for 95% of patients, showing significantly better results in the non-stented group (51 vs 22%).

Non-absorbable stent

Because of these conflicting results with absorbable hollow stents, we decided to assess the present stent, a permanent, non-absorbable inert polymeric stent made of biomaterials with a different configuration. We considered that the non-absorbable property of this stent and the

inertness of the material would provide a permanent open lumen of the vas deferens at the site of the anastomosis. By contrast with previously discussed animal studies, we decided to provide a longer follow-up with more frequent semenanalyses. In the present study there were no significant differences in the outcome of the total sperm count, motility and PMSD between groups. The present study is the first to use a non-absorbable polymeric hollow stent, with results similar to the one-layer vasovasostomy technique. There was no late stricturing in the stented group; the benefit of this is stressed by Carbone et al.²¹ and Belker²², who described the adverse effect of partial obstruction on the final outcome of a vasectomy reversal. In humans, the procedure should be easy and can be done by a surgeon not necessarily skilled in microscopy. Further investigations will be conducted in men to support the present findings with this polymeric stent.

References

1. Flam AT, Roth RA, Silverman ML, Gagne GR. Experimental study of hollow, absorbable polyglycolic acid tube as stent for vasovasostomy. *Urology* 1989; 33: 490-49
2. Donovan Jr JF. Microscopic vasovasostomy: current practice and future trends. *Microsurgery* 1995; 16: 325-332.
3. Cos LR, Valvo JR, Davis RS, Cockett ATK. Vasovasostomy, current state of the art. *Urology* 1983; 22: 567-575
4. Kabalin JN and Kessler R. Macroscopic vasovasostomy re-examined. *Steril Fertil* 1991; 36:135-138
5. Fuse H, Kimura H, Katayama T. Modified one-layer microsurgical vasovasostomy in vasectomized patients. *Int Uro Nephrol* 1995; 27: 451-456
6. Fischer MA, Grantmyre JE. Comparison of a modified one- and two-layer microsurgical vasovasostomy. *Br J Urol* 2000; 85: 1085-1088
7. Flickinger CJ, Vagnetti M, Howards SS, Herr JC. Antisperm autoantibody response is reduced by early repair of a severed vas deferens in the juvenile rat. *Fertil Steril* 2000; 73:229-237
8. Aitken RJ, Parslow JM, Hargreave TB, Hendry WF. Influence of antisperm antibodies on human sperm function. *Br J Urol* 1988; 62: 367-373
9. Silber SJ. Pregnancy after vasovasostomy for vasectomy reversal: a study of factors affecting long-term return of fertility in 282 patients followed for 10 years. *Human Reprod* 1989; 4: 318-322
10. Meinertz H, Linnet L, Andersen PL, Hjort T. Antisperm antibodies and fertility after vasovasostomy a follow-up of 216 men. *Fertil Steril* 1990; 54: 315-321

11. Vrijhof HJ, Delaere KP. Vasovasostomy results in 66 patients related to obstructive intervals and serum agglutinin titres. *Urol Int* 1994; 53: 143-146
12. Belker AM, Thomas Jr AJ, Fuchs EF, Konnak JW, Sharlip ID. Results of 1469 microsurgical vasectomy reversals by the vasovasostomy study group. *J Urol* 1991; 145: 505-511
13. Urry RL, Thompson J, Cockett ATK. Vasectomy and vasovasostomy.II. A comparison of two methods of vasovasostomy: silastic versus chromic stents. *Fertil. Steril* 1976; 27: 945-950
14. Lawrence EL, Witherington R. Splinted vasovasostomy, comparison of polyglycolic acid and polypropylene sutures. *Urology* 1978; 11: 260-265
15. Shessel FS, Lynne CM, Politano VA. Use of exteriorized stents in vasvasostomy. *Urology* 1981; 17: 163-165
16. Redman JF. Clinical experience with vasovasostomy utilizing absorbable intravasal stent. *Urology* 1982; 20: 59-61
17. Montie JE, Stewart BH, Levin HS. Intravasal stents in canine subjects. *Fertil Steril* 1973, 24: 877-883
18. Nuwayser ES, Wu TC, Hotchkiss RS, Farcon EE, Hulka JJ, Mohr K, Poddar A. An absorbable artificial vas deferens for vasovasostomy. *Trans Am Soc Artif Int Organs* 1975; 21: 523-530
19. Berger RE, Jessen JW, Patton DL, Bardin ED, Burns MW, Chapman WH. Studies of polyglycolic acid hollow self retaining vasal stent in vasovasostomy. *Fertil Steril* 1989;51: 504-508
20. Rothman I, Berger RE, Cummings P, Jessen J, Muller CH, Chapman W. Randomized clinical trial of an absorbable stent for vasectomy reversal . *J Urol* 1997; 157: 1697-1700

21. Carbone Jr DJ, Shah A, Thomas AJ, Agarwal A. Partial obstruction, not antisperm antibodies, causing infertility after vasovasostomy. *J Urol* 1998; 159: 827-830
22. Belker AM. Editorial: evaluation of partial anastomotic obstruction after vasovasostomy and predictors of success after vasoepididymostomy. *J Urol* 1998; 159: 835